POLITECNICO DI TORINO
Repository ISTITUZIONALE

Experimental Investigation of Fluid-Structure-Acoustic Interaction in a Rectangular Duct Impedance Facility

Original
Experimental Investigation of Fluid-Structure-Acoustic Interaction in a Rectangular Duct Impedance Facility / Fabbri, D., Bruzzone, F., Rosso, C., Avallone, F., Cordioli, J.A., Bonomo, L.A., Pereira, L.M.. - (2026). (32nd AIAA/CEAS Aeroacoustics Conference (2026) Brussels (BEL) 26-29 May 2026) [10.2514/6.2026-3567].

Availability:
This version is available at: 11583/3011203 since: 2026-06-15T09:59:57Z

Publisher:
American Institute of Aeronautics and Astronautics

Published
DOI:10.2514/6.2026-3567

Terms of use:

This article is made available under terms and conditions as specified in the corresponding bibliographic description in the repository

Publisher copyright
AIAA preprint/submitted version e/o postprint/Author's Accepted Manuscript

(Article begins on next page)

27 November 2026

JACC: CASE REPORTS VOL. 31, NO. 40, 2026
© 2026 THE AUTHORS. PUBLISHED BY ELSEVIER ON BEHALF OF THE AMERICAN COLLEGE OF CARDIOLOGY FOUNDATION. THIS IS AN OPEN ACCESS ARTICLE UNDER THE CC BY-NC-ND LICENSE (http://creativecommons.org/licenses/by-nc-nd/4.0/).

SURGERY

CLINICAL CASE

Progressive Giant Left Atrium After Valve Surgery With Preserved Hemodynamics



Giulia Agostini, MD, Marco Pocar, MD, PhD, Matteo Marro, MD, Luca Deorsola, MD, Massimo Boffini, MD, Antonino Loforte, MD, PhD, Mauro Rinaldi, MD

ABSTRACT

BACKGROUND Giant left atrium (GLA) is a rare complication of rheumatic heart disease that may continue to enlarge despite successful valve surgery.

CASE SUMMARY A 69-year-old man with rheumatic valvular disease and previous mechanical mitral and aortic valve replacement developed progressive GLA and heart failure symptoms. Redo aortic valve replacement was performed for prosthetic dysfunction. Long-term follow-up demonstrated progressive atrial enlargement (indexed left atrial volume up to 1,172 mL/m^2), mediastinal displacement, and pulmonary compression. Despite these findings, right heart catheterization confirmed normal pulmonary artery and filling pressures, with preserved left ventricular ejection fraction and sustained clinical stability.

DISCUSSION GLA is typically associated with pulmonary hypertension and heart failure progression. This case is notable for extreme progressive atrial remodeling over 2 decades despite correction of the underlying valve disease, while preserving pulmonary hemodynamics and ventricular function.

TAKE-HOME MESSAGES Progressive GLA may remain compatible with prolonged survival after successful valve surgery when ventricular function and pulmonary hemodynamics are preserved. Long-term multimodality imaging and invasive hemodynamic assessment are essential for patient management. (JACC Case Rep. 2026;31:110242)
© 2026 The Authors. Published by Elsevier on behalf of the American College of Cardiology Foundation. This is an open access article under the CC BY-NC-ND license (http://creativecommons.org/licenses/by-nc-nd/4.0/).

HISTORY OF PRESENTATION

A 69-year-old man was referred to our institution for left-sided heart failure due to cardiomegaly, after having previously undergone double valve replacement. His main symptom was dyspnea at rest for approximately 3 years, corresponding to NYHA functional class IV. His medical therapy included a beta-blocker, an angiotensin-converting enzyme inhibitor, diuretics, and warfarin.

TAKE-HOME MESSAGES

- Giant left atrium may persist and progressively enlarge despite successful valve surgery yet remain compatible with prolonged survival when ventricular function and pulmonary hemodynamics are preserved.
- Multimodality imaging and hemodynamic assessment are essential to characterize disease progression and guide management in patients with extreme atrial remodeling.

From the Cardiac Surgery Division, Department of Surgical Sciences, City of Health and Science University Hospital, University of Turin, Turin, Italy.

The authors attest they are in compliance with human studies committees and animal welfare regulations of the authors' institutions and Food and Drug Administration guidelines, including patient consent where appropriate. For more information, visit the Author Center.

Manuscript received June 15, 2026; revised manuscript received August 2, 2026, accepted August 12, 2026.

ISSN 2666-0849 https://doi.org/10.1016/j.jaccas.2026.110242

ABBREVIATIONS AND ACRONYMS

COPD = chronic obstructive pulmonary disease

GLA = giant left atrium

LVEF = left ventricular ejection fraction

RHD = rheumatic heart disease

DIFFERENTIAL DIAGNOSIS

The differential diagnosis of progressive dyspnea included prosthetic aortic valve dysfunction, chronic obstructive pulmonary disease (COPD) exacerbation, heart failure due to ventricular dysfunction, pulmonary hypertension, and symptoms related to massive left atrial enlargement.

PAST MEDICAL HISTORY

The patient had a history of acute articular rheumatism during childhood, which later led to valvular heart disease. His medical history was also significant for COPD, permanent atrial fibrillation, and active smoking as a cardiovascular risk factor.

In 2004, he underwent aortic valve replacement with a Carbomedics "Top Hat 19" mechanical prosthesis and mitral valve replacement with a Carbomedics 27-mm mechanical prosthesis at another institution. A transthoracic echocardiogram performed before the surgery demonstrated a cardiomegaly characterized by a giant left atrium (GLA) (indexed end-systolic volume: 350 mL/m^2).

In 2010, a ventricular pacemaker was implanted for bradyarrhythmia.

VISUAL SUMMARY Timeline of the Case

Time	Events
2004	Rheumatic mitral and aortic valve disease treated with mechanical mitral valve replacement and mechanical aortic valve replacement.
2010	Permanent atrial fibrillation complicated by bradyarrhythmia requiring ventricular pacemaker implantation.
2014	Progressive dyspnea (NYHA functional class IV), palpitations, and weight loss. Echocardiography demonstrated giant left atrium and prosthetic aortic valve dysfunction with increased transvalvular gradients.
2015	Hospitalization for heart failure. Cardiac catheterization and transesophageal echocardiography confirmed prosthetic aortic valve dysfunction. Redo aortic valve replacement successfully performed.
2015-2024	Regular cardiological follow-up showed progressive left atrial enlargement despite correction of valvular disease.
2024	Computed tomography demonstrated massive giant left atrium with mediastinal displacement and pulmonary compression. Echocardiography showed: • Left atrial volume: 1,700 mL • Indexed left atrial volume: 1,172 mL/m^2 • Left ventricular ejection fraction: 50% Right heart catheterization demonstrated: • Mean pulmonary artery pressure: 17 mm Hg • Pulmonary capillary wedge pressure: 11 mm Hg • Central venous pressure: 8 mm Hg • Cardiac output: 5.8 L/min
Clinical outcome	Despite progressive extreme atrial remodeling, the patient remained alive with preserved ventricular function, normal pulmonary hemodynamics, and NYHA functional class II-III symptoms during long-term follow-up.
Key message	Extreme giant left atrium may persist and progressively enlarge after successful valve surgery while remaining compatible with prolonged survival when ventricular function and pulmonary hemodynamics are preserved.
Key observation	Progressive giant left atrium (350 → 702 → 1,172 mL/m^2) despite preserved pulmonary hemodynamics.

Timeline illustrating the long-term clinical course of a patient with rheumatic heart disease who developed progressive giant left atrium despite successful valve surgery.

INVESTIGATIONS

Beginning in early 2014, the patient developed worsening dyspnea, palpitations, and weight loss. Pulmonary function tests revealed severe airway obstruction consistent with COPD, requiring daily bronchodilator therapy.

A transthoracic echocardiogram performed in November 2014 demonstrated restricted mobility of the prosthetic aortic leaflet, resulting in mild intraprosthetic regurgitation and increased transvalvular gradients, in the setting of marked cardiomegaly characterized by a GLA (indexed end-systolic volume: 702 mL/m^2).

The patient was subsequently hospitalized for heart failure. Cardiac catheterization and transesophageal echocardiography confirmed a moderate increase in aortic gradients (peak and mean gradients: 77/41 mm Hg; aortic valve area: 0.45 cm^2) due to hypomobility of the aortic prosthetic leaflets, along with severe left atrial dilation. The left ventricle was dilated but with preserved ejection fraction.

MANAGEMENT

In January 2015, the patient underwent redo aortic valve replacement via resternotomy with implantation of a 21-mm St Jude mechanical aortic prosthesis at our institution (EuroSCORE II: 2.44%). At surgical inspection, pannus overgrowth was identified as the cause of prosthetic dysfunction, whereas no macroscopic thrombus was observed. The postoperative course was uneventful.

OUTCOME AND FOLLOW-UP

The patient underwent regular cardiological follow-up over the subsequent years.

A contrast-enhanced computed tomography scan (Video 1, **Figure 1**) performed in January 2024 confirmed massive dilation of the left atrium, with rightward displacement within the mediastinum and bilateral pulmonary compression. The atriomegaly exerted a mass effect on the superior vena cava, esophagus, and extrahepatic inferior vena cava, without causing symptoms such as dysphagia, hepatic congestion, or intracardiac thrombus formation.[1]

A chest 3-dimensional reconstruction performed by Medics3D Company shows the volumes and relationships that the pathology has created (**Figure 1C**).

FIGURE 1 **Findings on Computed Tomography**

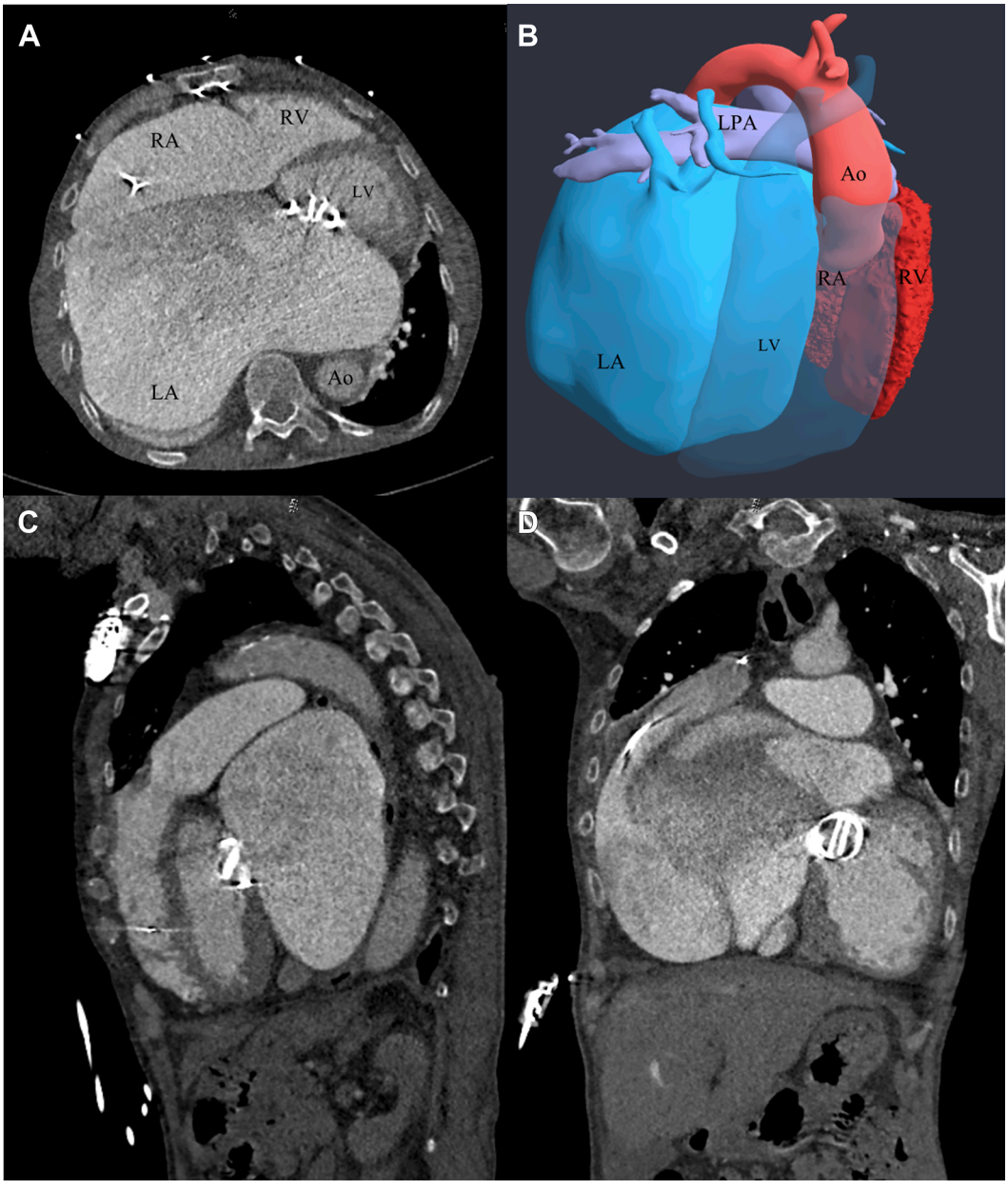

(A) Transverse contrast-enhanced CT section: mitral and aortic mechanical valve prosthesis are visible in cardiomegaly context. The lung parenchyma is compressed and the thoracoabdominal aorta displaced to the left. (B) Chest 3-dimensional CT scan reconstruction (Medics3D Company). (C) Sagittal contrast-enhanced CT scan: mechanical mitral prosthesis is visible in the systolic phase. (D) Frontal (coronal) contrast-enhanced CT scan: mechanical mitral prosthesis is visible in the diastolic phase. Ao = aorta; CT = computed tomography; LA = left atrium; LPA = left pulmonary arteries; LV = left ventricle; RA = right atrium; RV = right ventricle.

Cardiomegaly resulted in atelectasis of the adjacent lung parenchyma; notably, this did not lead to increased pulmonary artery pressures over time, and the patient's respiratory symptoms remained stable.

The most recent echocardiogram, performed in February 2024, showed severe right atrial dilation (36 cm^2) and a GLA (atrial volume: 1,700 mL; indexed atrial volume: 1,172 mL/m^2), with a left ventricular ejection fraction (LVEF) of 50%.

The most recent right heart catheterization showed no increase in mean pulmonary artery pressure (17 mm Hg), pulmonary capillary wedge pressure (11 mm Hg), or central venous pressure (8 mm Hg), with a cardiac output of 5.8 L/min. The patient remained clinically stable at NYHA functional class II to III, despite progressive atrial enlargement and preserved pulmonary hemodynamics.

Surgical intervention was not pursued because a third reoperation was considered to carry an unfavorable risk-benefit profile, despite evidence that left atrial volume reduction procedures, including partial plication, atrial wall excision, and partial cardiac autotransplantation, may improve outcomes.[2] The patient remained free of GLA-related complications, with preserved ventricular function and normal invasive hemodynamics, while operative risk was increased by 2 previous cardiac surgeries, 2 mechanical prostheses, and COPD. This management strategy was confirmed throughout follow-up.

DISCUSSION

GLA syndrome is a rare condition most commonly associated with rheumatic heart disease (RHD).[3] GLA is typically associated with pulmonary hypertension and heart failure progression.[4]

A recent review[5] defined GLA as a cardiothoracic ratio of >0.7 on chest x-ray. As our primary reference for atrial diameter, we adopted the more conservative threshold proposed by Piccoli et al[6] (left atrial anteroposterior diameter >8 cm on parasternal long-axis transthoracic echocardiography); the lower threshold proposed by Oh et al[7] (>6.5 cm) is cited for comparison rather than as a coequal definition. In our patient, the cardiothoracic ratio was approximately 0.9, and the left atrial anteroposterior diameter exceeded 8 cm, meeting both thresholds by a wide margin.

The pathophysiology is thought to involve a combination of fibrotic and inflammatory processes characteristic of RHD.[8]

In patients with GLA, in addition to morphological myocardial change, histological alterations occur, including loss of Aschoff bodies replaced by chronic inflammatory infiltrates.[9]

Chest x-ray in our patient revealed the characteristic “walking man” sign, reflecting posterior displacement of the left main bronchus.[10]

GLA is a recognized marker of adverse outcomes in RHD and is commonly associated with atrial fibrillation, pulmonary hypertension, and heart failure progression. In contrast, our patient maintained preserved LVEF and normal pulmonary hemodynamics despite progressive atrial enlargement after successful valve surgery. To our knowledge, this case represents one of the largest indexed left atrial volumes reported (1,172 mL/m^2), documented by serial quantitative measurements over 2 decades (350 → 702 → 1,172 mL/m^2), with invasively confirmed normal pulmonary artery and filling pressures. This unique combination of extreme progressive atrial remodeling, preserved ventricular function, and sustained normal hemodynamics has not previously been described.

The preservation of normal pulmonary hemodynamics may reflect several factors. Correction of the underlying mitral and aortic valve disease likely normalized left atrial filling pressures despite ongoing structural remodeling. In addition, chronic rheumatic remodeling may have resulted in a highly compliant, low-pressure atrial reservoir, consistent with the Laplace relationship. Finally, preserved LVEF may have limited retrograde transmission of filling pressures to the pulmonary circulation. These mechanisms remain speculative and require further investigation.

CONCLUSIONS

This case demonstrates that GLA enlargement may persist and continue to progress despite successful surgical correction of rheumatic mitral and aortic valve disease. Nevertheless, long-term survival and relative clinical stability were maintained over nearly 2 decades, likely owing to preserved LVEF and the absence of significant pulmonary hypertension or elevated filling pressures.

Despite massive GLA, mediastinal displacement, and pulmonary compression, right heart catheterization showed normal pulmonary artery pressures and filling pressures.

This case highlights the heterogeneous clinical course of GLA and suggests that extreme atrial remodeling may remain compatible with prolonged survival when valve dysfunction is corrected and ventricular performance is preserved.

ACKNOWLEDGEMENTS The authors thank Medics3D Company for providing the 3-dimensional reconstruction of the computed tomography images.

FUNDING SUPPORT AND AUTHOR DISCLOSURES

The authors have reported that they have no relationships relevant to the contents of this paper to disclose.

ADDRESS FOR CORRESPONDENCE: Dr Giulia Agostini, Università degli Studi di Torino, Corso Bramante 88-90, Turin 10126, Italy. E-mail: giulia.agostini@unito.it.

REFERENCES

1. Vincent ML, Del Valle KT, Bennett CE. Giant left atrium causing inferior vena cava obstruction and dysphagia. *Mayo Clin Proc*. 2023;98(8):1254–1255. https://doi.org/10.1016/j.mayocp.2023.04.001

2. Ríos-Ortega JC, Talledo-Paredes L, Yepez-Calderón C, et al. A new surgical technique for left atrial reduction in giant left atrium. *JTCVS Tech*. 2023;17:56–64. https://doi.org/10.1016/j.xjtc.2022.10.013

3. Raffa GM, Cappai A, Tarelli G. Giant left atrium syndrome. *J Cardiovasc Med (Hagerstown)*. 2011;12(10):745–746. https://doi.org/10.2459/JCM.0b013e32834a65b1

4. Borizanova A, Kinova E, Beyti S, Goudev A. The giant left atrium: when the heart outgrows the chest. *Eur Heart J Case Rep*. 2026;10(3):ytag135. https://doi.org/10.1093/ehjcr/ytag135

5. El Maghraby A, Hajar R. Giant left atrium: a review. *Heart Views*. 2012;13:46–52. https://doi.org/10.4103/1995-705X.99227

6. Piccoli GP, Massini C, Di Eusanio G, et al. Giant left atrium and mitral valve disease: early and late results of surgical treatment in 40 cases. *J Cardiovasc Surg (Torino)*. 1984;25:328–336.

7. Oh JK. Echocardiographic evaluation of morphological and hemodynamic significance of giant left atrium. An important lesson. *Circulation*. 1992;86:328–330. https://doi.org/10.1161/01.CIR.86.1.328

8. Sadiq MA, Ba Omar HA. Giant left atrium with a large thrombus. *Sultan Qaboos Univ Med J*. 2021;21(1):e137–e138. https://doi.org/10.18295/squmj.2021.21.01.021

9. Apostolakis E, Shuhaiber JH. The surgical management of giant left atrium. *Eur J Cardiothorac Surg*. 2008;33:182–190. https://doi.org/10.1016/j.ejcts.2007.11.003

10. Affronti A, Quintana E, Castellà M. Giant left atrium in previous mitral valve repair. *Rev Esp Cardiol (Engl Ed.)*. 2023;76(10):833. https://doi.org/10.1016/j.rec.2023.04.012

KEY WORDS **atrial remodeling, cardiac catheterization, giant left atrium, pulmonary hypertension, rheumatic heart disease**

APPENDIX **For a supplemental video, please see the online version of this paper.**