POLITECNICO DI TORINO
Repository ISTITUZIONALE

Reliability of implant-supported rehabilitations after mandibular reconstruction with vascularized fibula free flaps: A systematic review and meta-analysis

Original
Reliability of implant-supported rehabilitations after mandibular reconstruction with vascularized fibula free flaps: A systematic review and meta-analysis / Molinero-Mourelle, P., Srivastava, G., Kumar Padhiary, S., Gibello, U., Schimmel, M., Naveau, A., Roccuzzo, A.. - In: THE JOURNAL OF PROSTHETIC DENTISTRY. - ISSN 0022-3913. - (2026). [10.1016/j.prosdent.2026.08.030]

Availability:
This version is available at: 11583/3016120 since: 2026-09-30T05:00:11Z

Publisher:
Elsevier

Published
DOI:10.1016/j.prosdent.2026.08.030

Terms of use:

This article is made available under terms and conditions as specified in the corresponding bibliographic description in the repository

Publisher copyright

(Article begins on next page)

27 November 2026

THE JOURNAL OF PROSTHETIC DENTISTRY

SYSTEMATIC REVIEW

Reliability of implant-supported rehabilitations after mandibular reconstruction with vascularized fibula free flaps: A systematic review and meta-analysis

Pedro Molinero-Mourelle, Dr. med. dent., DDS, MAS, PhD,[a] Gunjan Srivastava, BDS, MDS,[b] Subrat Kumar Padhiary, BDS, MDS,[c] Umberto Gibello, DDS, PhD,[d] Martin Schimmel, Dr. med. dent., DDS, MAS,[e] Adrien Naveau, DDS, PhD,[f] and Andrea Roccuzzo, Dr. med. dent., DDS, MAS, PhD[g]

ABSTRACT

Statement of problem. Mandibular reconstruction with a vascularized fibular free flap (VFFF) is well established, but information on implant survival rates, prosthesis survival and associated complications, and their impact on patient quality of life (QoL) remains limited.

Purpose. The purpose of this systematic review and meta-analysis was to evaluate the reliability of implant-supported rehabilitation after mandibular reconstruction with a VFFF in terms of implant survival, prosthesis survival and associated technical, biological, and esthetic complications, and patient-reported QoL measures.

Material and methods. Following Preferred Reporting Items for Systematic Reviews and Meta-Analyses (PRISMA) guidelines, 4 electronic databases, PubMed, Embase, Scopus, and Web of Science, were systematically searched for articles in the English language up to August 2025 to identify studies reporting on implant-supported rehabilitation after mandibular reconstruction. Data on clinical outcome variables were pooled and analyzed using a proportional risk meta-analysis with 95% confidence intervals (CIs). The quality of the included observational studies was assessed using the Newcastle-Ottawa scale (NOS), while randomized controlled trials (RCTs) were evaluated using the risk of bias (ROB 2.0) tool.

Results. From 2712 studies identified, 26 were included, of which 21 were retrospective studies, 4 were prospective studies, and only 1 was an RCT. The pooled survival rate for implants with less than 5 years of follow-up was 96% (95% confidence interval (CI) ranging from 0.92 to 0.98) based on 1260 implants across 17 studies. In contrast, implants with more than 5 years of follow-up demonstrated a slightly reduced pooled survival rate of 92% (95% CI: 0.86 to 0.97), based on 936 implants across 9 studies, with no significant differences between short-term and long-term follow-up. This study showed a pooled prosthesis survival rate of 100% (95% CI: 0.98 to 1.00) at a mean ±standard deviation follow-up of 30 ±12 months. Prosthesis-related complications were poorly reported across studies. QoL was significantly improved, particularly in speech, mastication, and overall patient satisfaction with implant-supported rehabilitation.

Conclusions. Implant-supported rehabilitation after VFFF reconstruction showed high implant and prosthesis survival and contributed to improved functional outcomes and QoL. Standardized protocols and validated outcomes are needed to enhance evidence quality and support consistent clinical decision-making. (J Prosthet Dent xxxx;xxx:xxx-xxx)

This research did not receive any specific grant from funding agencies in the public, commercial, or not-for-profit sectors.
None.

[a]Senior Lecturer, Department of Reconstructive Dentistry and Gerodontology, School of Dental Medicine, University of Bern, Bern, Switzerland; Assistant Professor, Department of Conservative Dentistry and Prosthodontics, Faculty of Dentistry, Complutense University of Madrid (UCM), Madrid, Spain; and Assistant Professor, Complutense University of Madrid (UCM), Ramon y Cajal Research Institute (IRYCIS), Madrid, Spain.
[b]Professor, Department of Prosthodontics, Institute of Dental Sciences, Siksha' O' Anusandhan Deemed to be University, Bhubaneswar, India.
[c]Professor, Department of Dentistry, Saheed Laxman Naik Medical College and Hospital (SLNMCH), Koraput, Odisha, India.
[d]Doctoral student, CIR Dental School, Department of Surgical Sciences, University of Turin, Turin, Italy; and Doctoral student, Department of Mechanical and Aerospace Engineering (DIMEAS), Politecnico di Torino, Turin, Italy.
[e]Professor, Department of Reconstructive Dentistry and Gerodontology, School of Dental Medicine, University of Bern, Bern, Switzerland.
[f]Professor, Department of Prosthodontics, Faculty of Dentistry, University of Bordeaux, Bordeaux, France.
[g]Full Professor and Vice-Chairman, Shanghai Perio-Implant Innovation Center, Institute of Integrated Oral, Craniofacial and Sensory Research, Shanghai Ninth People's Hospital, Shanghai Jiao Tong University School of Medicine; College of Stomatology, Shanghai Jiao Tong University; National Center for Stomatology; National Clinical Research Center for Oral Diseases; Shanghai Key Laboratory of Stomatology; Shanghai Research Institute of Stomatology, Shanghai, PR China; and Privatdozent, Department of Periodontology, School of Dental Medicine, University of Bern, Bern, Switzerland.
[1]P. M-M. and G. S. contributed equally to this article and share first authorship.

Clinical Implications

Vascularized fibula free flap (VFFF) reconstruction offers a reliable foundation for implant- supported mandibular rehabilitation. High implant and prosthesis survival rates support long-term functional stability. Early implant placement may facilitate definitive prosthetic rehabilitation and improve function, esthetics, and quality of life.

Head and neck cancers (HNCs) account for approximately 4% of all malignant tumors and represent a significant global health burden, with prevalence ranging from 25% to 30% in Asia compared with 2% to 4% in the United States and Europe.[1] Mandibular involvement in oral cancer frequently requires segmental resection, resulting in profound functional impairments affecting speech, mastication, deglutition, respiration, and facial esthetics.[2–4]

Vascularized bone flaps have emerged as the preferred reconstructive option after oncologic mandibular resection, with common donor sites including the fibula, radius, iliac crest, ribs, and scapula.[5,6] The VFFF was first described by Taylor et al in 1975 for tibial defect reconstruction[7] and later adapted by Hidalgo et al in 1989[8] has since gained widespread acceptance. The VFFF is favored for its abundant bone stock, favorable cortical thickness, versatility, and long vascular pedicle, providing up to 25 to 27 cm of bone for comprehensive oromandibular reconstruction and the placement of osseointegrated implants.[8,9] Despite these advantages, the technique demands precise microsurgical expertise and carries potential donor and recipient site complications.[10] Implant-supported prosthetic rehabilitation has markedly improved quality of life (QoL) after mandibulectomy by restoring mastication, speech, and facial support, including cheek and lip contour.[11,12] Over recent decades, osseointegrated implants have become an established treatment option, supported by robust evidence demonstrating high survival rates, functional predictability, and the ability to reestablish dental continuity within a single surgical course.[13,14]

Various prosthetic options, including removable dentures, implant-supported overdentures, and fixed implant-supported prostheses may be used depending on patient factors and anatomic constraints.[15] Given the complexity of postoncologic reconstruction, radiotherapy remains an important determinant of implant survival and rehabilitation outcomes.[16] Previous systematic reviews[17,18] have demonstrated significantly lower implant survival in irradiated compared with nonirradiated fibula flaps. Another review examined implant survival after 1 year of prosthetic loading and reinforced the reliability of implant-supported rehabilitation, irrespective of immediate or delayed implant placement.[11] In addition to implant survival, long-term marginal bone stability is an important determinant of implant success in reconstructed mandibles.[19–21]

However, the authors are unaware of a previous systematic review that has comprehensively evaluated prosthetic rehabilitation outcomes following VFFF mandibular reconstruction. This gap highlights the need for the present review, which systematically evaluated implant and prosthesis survival rates, patient characteristics, prosthesis type, and the spectrum of technical, biological, and esthetic complications, as well as QoL outcomes in patients rehabilitated with implants following VFFF mandibular reconstruction. The purpose of this systematic review and meta-analysis was to evaluate the reliability of implant-supported rehabilitation following VFFF mandibular reconstruction by assessing implant and prosthesis survival, prosthetic complications, and patient-reported QoL. The null hypothesis was that implant-supported prosthetic rehabilitation after VFFF mandibular reconstruction would not demonstrate favorable implant and prosthesis survival or improvement in patient-reported QoL.

MATERIAL AND METHODS

This systematic review was conducted according to the current guidelines of the Preferred Reporting Items for Systematic Reviews and Meta-Analyses (PRISMA) statement.[22] The protocol for this review was registered in the International Prospective Register of Systematic Reviews (PROSPERO) database (CRD42020185305). Two independent reviewers (P.M.M., G.S.) systematically searched published and unpublished ongoing studies in the English language up to August 2025. A combination of MeSH terms, Emtree terms, and free-text keywords was applied across 4 electronic databases: PubMed, Embase, Scopus, and Web of Science. Non-peer-reviewed literature was additionally screened through the OpenGrey database, while ongoing trials were identified through international registries, including ClinicalTrials.gov. The reference lists of retrieved articles and previously published systematic reviews were also screened to identify relevant articles.

Two independent reviewers (P.M.M., G.S.) screened the titles and abstracts of all the studies obtained through electronic search. Studies that met the inclusion criteria or lacked sufficient information in the title and abstract were retrieved for full-text evaluation. The full text of all the relevant articles was obtained and assessed for possible inclusion. Any disagreement in the inclusion of an article was resolved through discussion with a third reviewer (A.R.). Interrater reliability was assessed using the Cohen kappa statistic. The search strategy is detailed in Supplemental Table 1 (available online).

Table 1. Reasons for exclusion

Systematic Review (*n*=17)	Wijbenga et al 2016,[25] Panchal et al 2020,[17] Vosselman et al 2021,[4] Gangwani et al 2022,[12] Illand et al 2023,[11] Tahmasebi et al 2023,[26] Sriram et al 2024,[16] Michael et al 2025,[27] Anne-Gaelle et al 2011,[15] Brown et al 2017,[2] Dholam et al 2018,[28] Patel et al 2019,[5] Pappalardo et al 2018,[29] Gu et al 2021,[10] Ja et al 2022,[30] Ardisson et al 2023,[19] Nham et al 2024[31]
Outcome did not meet the inclusion criteria (*n*=10)	Barber et al 1995,[32] Chiapasco et al 2000,[13] Kovacs et al 2000,[33] Gbara et al 2007,[34] Chiapasco et al 2008,[35] Bodard et al 2011,[36] He et al 2011,[37] Momoh et al 2011,[38] Chang et al 2014,[39] Hakim et al 2015[40]
Intervention did not meet the inclusion criteria (*n*=14)	Meloni et al 2015,[41] Wang et al 2015,[42] Brandao et al 2016,[43] Kumar et al 2016,[44] Chuka et al 2017,[45] Attia et al 2018,[14] Kumar et al 2018,[46] Menapace et al 2018,[21] Petrovic et al 2019,[6] Goker et al 2020,[47] Lodders et al 2021,[18] Zhang et al 2022,[48] Tumuluri et al 2023,[49] K et al 2021[50]
Sample size did not meet the inclusion criteria (*n*=2)	Patel et al 2019,[23] Sass et al 2021[24]

The inclusion criteria comprised studies involving participants with segmental mandibulectomy reconstructed with VFFF, studies including information on the placement and survival of osseointegrated dental implants followed by prosthetic rehabilitation, associated complications, and QoL, and studies having at least 5 participants, 20 implants, and a minimum follow-up of 12 months. Exclusion criteria included studies evaluating reconstructive techniques other than VFFF: all nonvascularized bone grafts, other vascularized bone flaps, or metal reconstruction plates. Additionally systematic reviews, editorials, case reports, and case series with fewer than 5 participants and studies lacking detailed reporting on the primary outcome were excluded. The excluded studies, along with reasons for exclusion, are presented in Table 1.

Data were extracted by 2 independent reviewers (P.M.M., G.S.) using a standardized form that included study characteristics (author, year of publication, study design, follow-up period), participant characteristics (age, sex, and sample size), number of participants receiving implants in VFFF, prosthesis type, implant survival (primary outcome), and prosthesis survival, associated complications, and QoL (secondary outcomes).

The methodological quality of the included observational studies was assessed using the Newcastle-Ottawa scale (NOS).[51] The NOS assesses study quality across 3 domains: selection (S), comparability (C), and exposure (E), and consists of 9 items. Studies scoring 7 to 9 points were considered to have a low risk of bias, 5 to 6 points indicate a moderate risk of bias, and <5 points indicate a high risk of bias. The risk of bias (ROB 2.0) tool[52] was used for randomized controlled trials (RCTs).

The meta-analysis was performed using software (Stata Version 18.0; StataCorp LLC). Implant survival rates were pooled using proportion meta-analysis with corresponding 95% confidence intervals (CIs), applying either a fixed-effects or random-effects model according to the degree of heterogeneity among the included studies. Statistical heterogeneity was assessed using the I^2 statistic. I^2 value above 50% indicates substantial heterogeneity, and pooled estimates were calculated using a random-effects model. Between-study variance (τ^2) was estimated as part of the random-effects analysis in the statistical software program.

RESULTS

A total of 2712 records were identified through the electronic search. After duplicate removal, 1504 titles and abstracts were screened, and 69 were selected for full-text analysis. Twenty-six studies met the inclusion criteria and were included, while 43 were excluded (Cohen kappa=0.85 indicated a high interreviewer agreement). The study selection process is presented in Figure 1. Of the 26 included studies, 21 were retrospective,[3,53–72] 4 were prospective,[73–76] and 1 was an RCT.[77] The cause of bone defects was most commonly squamous cell carcinoma, followed by benign tumors such as ameloblastoma, ossifying fibroma, or bone pathology including osteoradionecrosis and osteomyelitis. The mean age of the included participants was 52.1 years.

A total of 611 mandibular reconstructions were reported across the included studies, with 2212 implants placed in VFFF and 80 implants placed in native mandibular bone. The overall mean follow-up after implant placement was 43.2 months, with 9 studies[3,63,64,66–70,76] reporting outcomes beyond 5 years. The characteristics of included studies are summarized in Table 2.

Prosthetic rehabilitation was initiated between 3 and 12 months after VFFF reconstruction in most studies, with 1 outlier reporting initiation as late as 32 months after reconstruction.[71] Additionally, the timing of prosthetic loading varied between irradiated and nonirradiated patients, with irradiated individuals generally requiring longer healing periods before loading.[58,77] The proportion of participants completing prosthetic rehabilitation ranged from 10.4% to 100%, with studies published after 2015 consistently reporting higher rehabilitation rates than earlier studies.

The most frequently reported technical complications were screw fracture, ceramic chipping, and bar fracture.[3,62] Biological complications were infrequently reported, and gingival hyperplasia was described in only 1

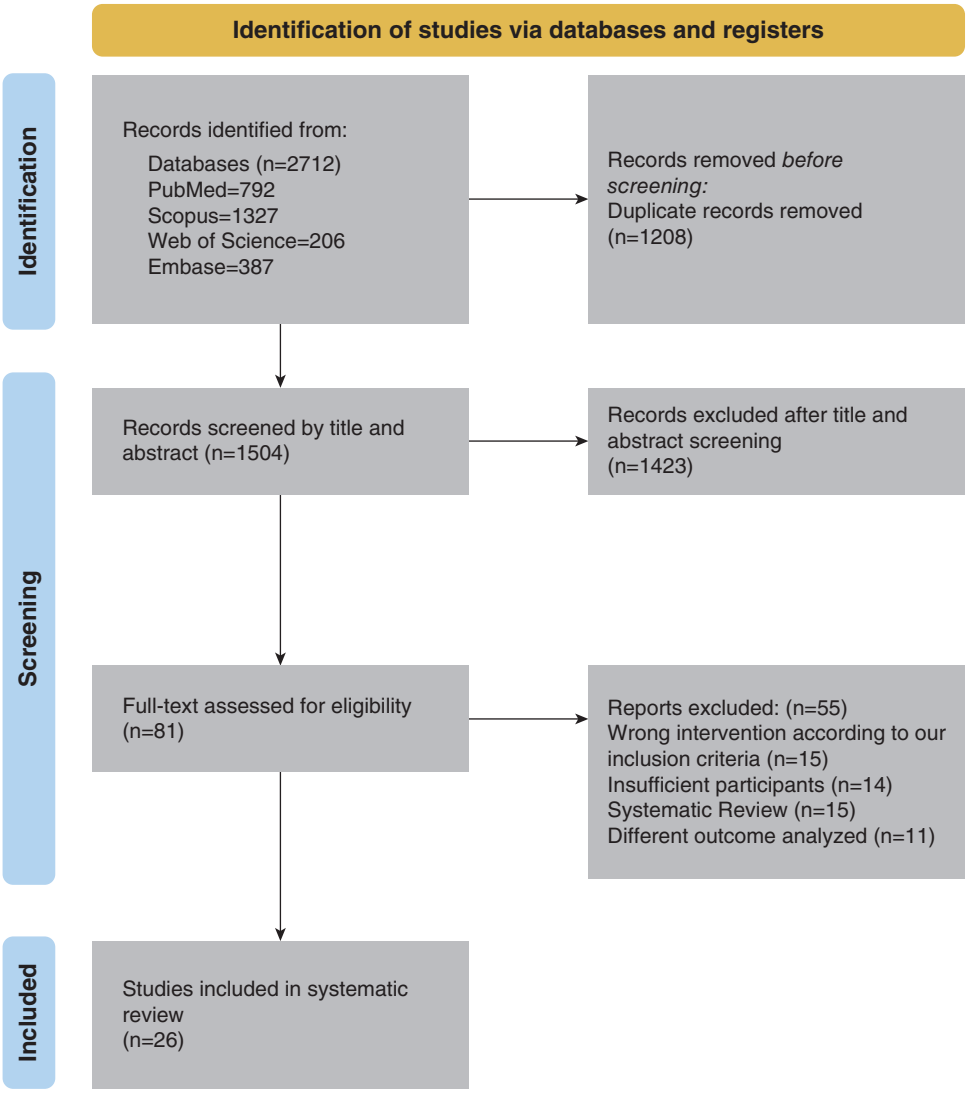

Figure 1. Flow diagram of included studies.

study.[62] Implant-related complications were reported in 16 studies, with osseointegration failure identified as the most common cause of implant loss in 12 studies.[3,58,62,64–66,71,72,74–77] Peri-implantitis was reported in 5 studies.[58,59,62,67,76] Nguyen et al[69] reported osteoradionecrosis resulting in the removal of 5 implants, while Jacobsen et al[76] also reported osteoradionecrosis involving irradiated grafted bone. Khadembaschi et al[70] highlighted an association between prosthesis design and oral hygiene; 18 of the 33 participants with fixed prostheses demonstrated poor oral hygiene compared with 11 of the 38 participants using removable prostheses. Prosthodontic outcomes, complications, and QoL parameters are summarized in Table 3.

QoL was assessed in 7 studies.[3,58,64,68,69,76,77] All reported consistent improvements following reconstructive treatment. However, heterogeneity in the assessment tools precluded meaningful comparison across studies. Bodard et al[64] specifically evaluated patient satisfaction, including prosthetic function, dietary improvement, speech, and esthetics, and reported a favorable overall satisfaction score of 7.3 out of 10. Detailed QoL outcomes are presented in Table 3.

The quality assessment of the included cohort studies is summarized in Table 4. According to the NOS, 5 studies[54,55,61,62,75] had a low risk of bias, 19 studies had a moderate risk of bias, and 1 study[53] had a high risk of bias. The RCT demonstrated a low risk of bias across all domains according to the ROB 2.0 tool[77] (Table 5).

Seventeen studies reported implant survival with a follow-up of less than 5 years, whereas 9 studies reported outcomes beyond 5 years. The pooled analysis of 1260 implants identified 85 implant failures, corresponding to an estimated implant survival of 96% (95% CI: 0.92 to 0.98) within 5 years of follow-up (Fig. 2A). Most studies reported survival rates above 90%, with

Table 2. Characteristics of included studies

Author/y	Study Design	Cause of Bone Defect	Patients N, (M/F)	Age (y)	Average Follow-up Period After Implant Placement (mo)	No of Patients/Implants
Sclaroff et al 1994[53]	Retrospective	Head and Neck Cancer	22 (16/6)	54 (17-65)	18	22 patients/83 implants
Chang et al 1998[54]	Retrospective	Head and Neck Cancer, ORN.	12 (5/7)	36.3 (17-65)	25 (1-43)	8 patients/34 implants
Gürlek et al 1998[55]	Retrospective	Cancer, Osteoradionecrosis	20 (9/11)	47.4 (27-74)	47 (18-84)	20 patients/60 implants in VFFF 11 implants in native bone
Foster et al 1999[56]	Retrospective	Malignant diseases, osteoradionecrosis, trauma	75 (49/26)	49 (12-82)	36 ±12	14 patients/71 implants
Schliephake et al 1999[57]	Retrospective	Squamous Cell Carcinoma, Ameloblastoma, ossifying fibroma, osteosarcoma	44 (32/12)	NR	41.2 ±23	11 patients/43 implants
Iizuka et al 2005[73]	Prospective		28 (19/9)	58.2	45 (24-48)	13 patients/37 implants
Chiapiasco et al 2006[74]	Prospective	Tumors and Osteoradionecrosis	46 (30/16)	48.7 (13-69)	50.2 (24-96)	11 patients/42 implants
Garrett et al 2006[75]	Prospective	Oral Tumor (Primary or Secondary), Osteoradionecrosis, Plate Fracture, Metastatic Disease	46 (22/24)	60 (19-83)	22.6 (14.5-30.7)	17 patients/58 implants
Hundepool et al 2008[58]	Retrospective	Oral tumors (benign or malignant), osteoradionecrosis, or osteomyelitis	70 (40/30)	53 (6-82)	39.5 (6-89)	24 patients/90 implants (69 in VFFF and 21 in native mandible)
Smolka et al 2008[59]	Retrospective	Ablative surgery of Oral Cancer	56 (43/13)	55.6 (40.7-78.8)	50.4 (1-142.8)	30 patients/108 implants
Salinas et al 2010[60]	Retrospective	Oral Tumors, Osteoradionecrosis, Traumatic mandibular discontinuity	44 (25/19)	NR	41.1 (4-108)	44 patients/114 implants
Bianchi et al 2013[61]	Retrospective	Mandibular Ameloblastoma	17 (10/7)	50.9 (33-76)	53.6 (18-120)	15 patients/70 implants
Parbo et al 2013[62]	Retrospective	Oral Tumors, osteoradionecrosis, salivary gland tumour	36 (23/13)	54 (9-77)	22 (0-89)	16 patients/67 implants
Jacobsen et al 2014[63]	Retrospective	facial trauma, osteomielitis, malignancy	33 (17/16)	52.4 (20-69)	67	23 patients/140 implants
Bodard et al 2015[64]	Retrospective	NR	26 (17/9)	54.14 (19-72)	72	26 patients/80 implants
Fang et al 2015[3]	Retrospective	Oral Tumors, oral Trauma, and osteoradionecrosis	74 (61/13)	47 (19-75)	120 (60-240)	74 patients/192 implants
Kumar et al 2016[77]	Randomized Clinical Trial	Oral Tumors	46 (33/13)	34	12	46 patients/140 implants
Jackson et al 2016[65]	Retrospective	Oral Tumors, Oral Trauma, and osteoradionecrosis	46 (31/15)	58 (16-80)	22 (11.8-30.1)	46 patients 183 implants in VFFF and 44 in native bone
Jacobsen et al 2016[76]	Prospective	Malignant Tumors, Benign Tumors	26 (17/9)	49.6	66 (12-132)	26 patients/94 implants
Sozzi et al 2017[66]	Retrospective	Squamous cell carcinoma, Oral Tumors	14 (8/6)	48 (12-70)	93.6 (15.6-210)	14 patients/57 implants in VFFF and 4 in native bone
Pellegrino et al 2018[67]	Retrospective	Malignant and benign oral tumors	21 (15/6)	49.6	90.2 (20-204)	21 patients/108 implants
Attia et al 2019[68]	Retrospective	Squamous cell carcinoma, Ameloblastoma, osteomyelitis	28 (20/8)	54 (17-69)	132	28 patients/120 implants
Nguyen et al 2020[69]	Retrospective	Oral Tumors	7 (3/4)	54.4 (35-78)	64.3 (46-88)	7 patients/39 implants
Khadembaschi et al 2021[70]	Retrospective	Squamous cell carcinoma	45 (16/29)	55	47	34 patients/106 implants
Olden et al 2023[71]	Retrospective	Squamous Cell Carcinoma, osteoradionecrosis	41 (20/21)	66.5 (43-85)	21.5 (8-59)	11 patients/34 implants
Ostrander et al 2024[72]	Retrospective	Malignancy, osteoradionecrosis	35	59.8 ±6.4	16.4 ±15.2	10 patients/42 implants

NR, not reported; VFFF, vascularized fibula free flap.

Table 3. Prosthodontic characteristics, reported complications, and quality of life

Author/y	Follow-up After Implant Placement (Average/mo)	No of Patients/Implants	Prosthesis Type	Time from Implant Placement to Implant Loading (mo)	Prosthetic Success Rate	Quality of Life/Patient Satisfaction	Prosthodontic Complications
Sclaroff et al 1994[53]	18	22 patients/83 implants	IFDP/IRDP	8-10	NR	NR	NR
Chang et al 1998[54]	25 (1-43)	8 patients/34 implants	IFDP=5 Overdentures=2	3	87.5%	NR	NR
Schliephake et al 1999[57]	41.2 ±23	11 patients/43 implants	IFDP=11	NR	100%	NR	NR
Iizuka et al 2005[73]	45 (24-48)	13 patients/37 implants	IFDP=2 Bar supported Overdentures=3 Removable Dentures=1	NR	21%	NR	NR
Chiapiasco et al 2006[74]	50.2 (24-96)	11 patients/42 implants	IFDP=9 Conventional removable denture=3 Implant supported overdentures=2	4-6	24 % (11/46)	NR	One implant failed to integrate before prosthetic loading, and 4 implants, although osseointegrated, later developed peri-implant bone resorption.
Garrett et al 2006[75]	22.6 (14.5-30.7)	17 patients/58 implants	Conventional RPD=33 IFDP=16		35% (16/46)	NR	Three implants failed, 1 due to loss of osseointegration and 2 due to poor positioning. One participant discontinued implant-supported rehabilitation and reverted to a conventional prosthesis.
Hundepool et al 2008[58]	39.5 (6-89)	24 patients/90 implants (69 in VFFF and 21 in native mandible)	IFDP/IRDP=18	6 mo for irradiated patient and 3 mo for non-irradiated patient	26% (18/70)	EORTC H&N35	Three implants failed, and for 2 participants, dental rehabilitation was not possible due to unfavorable implant positioning. Few participants developed periimplantitis secondary to tissue hypertrophy, which was managed conservatively
Smolka et al 2008[59]	50.4 (1-142.8)	30 patients/108 implants	Implant bar- supported over dentures=17 IFDP=2 Conventional RPD=5	NR	42.9% (24/56)	NR	Four implants were lost late due to periimplantitis. Two participants required an additional preprosthetic procedure to correct the jaw relationships.
Bianchi et al 2013[61]	53.6 (18-120)	15 patients/70 implants	IFDP=13 IRDP=2	3-5 mean 4.1	100%	NR	NR
Parbo et al 2013[62]	22 (0-89)	16 patients/67 implants	IFDP=10 IRDP=4 No Prosthesis=2	4-9 mean 8.9	87.5% (14/16)	NR	Three implants lost due to infection. One prosthesis fractured and repaired, while another participant experienced recurrent gingival hyperplasia. Additionally, 8 implants were not included into final prosthetic rehabilitation.
Jacobsen et al 2014[63]	67	23 patients/140 implants	IFDP=5	NR	22% (5/23)	NR	Osteoradionecrosis of irradiated grafted bone.
Bodard et al 2015[64]	72	26 patients/80 implants	IFDP-15 IRDP-11	3-6	100% (26/26)	Mean score, 7.3 of 10	Two implants failed before loading, and 3 remained unloaded.
Fang et al 2015[3]	120 (60-240)	74 patients/192 implants	Screw retained FDP- 27 Cement retained FDP-30 Implant supported bar retained overdentures-14 Implant retained crowns-3	5-11.4 mean 7.5	100%	The success criteria were recorded with OHIP-14 questionnaire.	Eighteen implants failed. Reported prosthetic complications included bar fracture, overdenture base fracture, abutment screw fracture, and porcelain chipping.
Kumar et al 2016[77]	12	46 patients/140 implants	Group I: Implant supported overdenture on 2 implants. Group II: Implant supported overdenture on 4 implants.	Immediate loading only for participant who had not undergone radiotherapy, for others loading only after 6 mo.	100%	EORTC QLQ C30, H&N35, OHIP, DSI	1 implant failure, 1 flap necrosis

Table 3 (*Continued*)

Author/y	Follow-up After Implant Placement (Average/mo)	No of Patients/Implants	Prosthesis Type	Time from Implant Placement to Implant Loading (mo)	Prosthetic Success Rate	Quality of Life/Patient Satisfaction	Prosthodontic Complications
Jackson et al 2016[65]	22 (11.8-30.1)	46 patients 183 implants in VFFF and 44 in native bone	IFDP=45	8	98% (45/46)	NR	Implant failure- 10 Granulation or soft-tissue overgrowth- 6 Exposed bone around implant-6
Jacobsen et al 2016[76]	66 (12-132)	26 patients/94 implants	IFDP=23	NR	88.4% (23/26)	EORTC QLQ C30, H&N35,	One implant failed at exposure, and 4 additional implants were lost later due to periimplantitis.
Sozzi et al 2017[66]	93.6 (15.6-210)	14 patients/57 implants in VFFF and 4 in native bone	Cemented IFDP=3 Screw retained IFDP=3 Overdentures=8	NR	100%	NR	Two implants were lost in separate patients, both occurring 2 mo after loading with an overdenture.
Pellegrino et al 2018[67]	90.2 (20-204)	21 patients/108 implants	Implant-supported Overdenture=3 IFDP=18	4-6	100%	NR	Peri-implantitis 14.8% and mucositis were 20.3%
Attia et al 2019[68]	132	28 patients/120 implants	Telescopic denture=9 IFDP=19	NR	100%	76% of participants could eat normally without dietary restrictions, 73% achieved intelligible speech, and 31% rated their esthetic outcome as good to excellent.	NR
Nguyen et al 2020[69]	64.3 (46-88)	7 patients/39 implants	IFDP=3 Bar retained overdentures=2 O-ring retained overdenture=1 Conventional partial denture=1	NR	100%	QoL was assessed	Five implants were removed 3 mo after placement due to post operative radiotherapy.
Khadembaschi et al 2021[70]	47	34 patients/106 implants	IFDP=12 IRDP=10 Overdenture=11	NR	97%	NR	Reported significantly poorer oral hygiene in participants with fixed prostheses 18 of 33 compared with those with removable prostheses 11 of 38.
Olden et al 2023[71]	21.5 (8-59)	11 patients/34 implants	IFDP=8	8.8-32	20% (8/34)	NR	Five patients lost a total of 16 implants after placement, and 2 patients experienced bone-flap fractures.
Ostrander et al 2024[72]	16.4 ±15.2	10 patients/42 implants	Temporary dental prosthesis=2 Final prosthesis=3	NR	10.4% (5/42)	NR	One patient experienced recurrent infections requiring hardware removal, while another showed poor osseointegration of multiple implants.

DSI, denture satisfaction index; EORTC QLQ-C30, European organization for research and treatment of cancer quality of life questionnaire version 3; H&N 35, head and neck 35; IFDP, implant-supported fixed dental prostheses; IRDP, implant-supported removable dental prostheses; NR, not reported; OHIP, oral health impact profile; QoL, quality of life; VFFF, vascularized fibula free flap.

Table 4. Quality assessment of included studies applying Newcastle-Ottawa scale

	Selection				Comparability		Exposure			Nº of Stars
Study/y	S1	S2	S3	S4	C1	C2	E1	E2	E3	
Sclaroff et al 1994[53]	★	★					★	★		4
Chang et al 1998[54]	★	★	★				★	★		5
Gürlek et al 1998[55]	★	★	★				★	★		5
Foster et al 1999[56]	★	★	★	★	★	★	★	★		8
Schliephake et al 1999[57]	★	★	★	★	★	★	★	★	★	9
Iizuka et al 2005[73]	★	★	★				★	★	★	6
Chiapiasco et al 2006[74]	★		★	★			★	★	★	6
Garrett et al 2006[75]	★	★	★				★		★	5
Hundepool et al 2008[58]	★	★	★				★	★	★	6
Smolka et al 2008[59]	★	★	★				★	★	★	6
Salinas et al 2010[60]	★	★	★	★	★	★	★	★	★	9
Bianchi et al 2013[61]	★	★	★				★		★	5
Parbo et al 2013[62]	★		★	★				★	★	5
Jacobsen et al 2014[63]	★	★	★	★				★	★	6
Bodard et al 2015[64]	★		★	★			★	★	★	6
Fang et al 2015[3]	★	★	★				★	★	★	6
Jackson et al 2016[65]	★	★	★				★	★	★	6
Jacobsen et al 2016[76]	★	★	★				★	★	★	6
Sozzi et al 2017[66]	★	★	★				★	★	★	6
Pellegrino et al 2018[67]	★	★	★	★	★		★		★	7
Attia et al 2019[68]	★		★	★			★	★	★	6
Nguyen et al 2020[69]	★	★	★				★	★	★	6
Khadembaschi et al 2021[70]	★	★		★	★		★	★	★	7
Olden et al 2023[71]	★	★	★				★	★	★	6
Ostrander et al 2024[72]	★	★		★			★	★	★	6

Table 5. Risk of Bias 2.0 assessment for included RCT

Author/ y	Study Design	Randomization Process	Deviations from Intended Interventions	Missing Outcome Data	Measurement of the Outcome	Selection of the Reported Result	Overall
Kumar et al 2016[77]	RCT	Low	Low	Low	Low	Low	Low

several reporting 100% survival.[54,57,61,73] One study[71] reported substantially lower survival, likely contributing to substantial heterogeneity (I^2=85.5%, P<.001). The pooled analysis of 936 implants across 9 studies showed an implant survival rate of 92% (95% CI: 0.86 to 0.97) beyond 5 years of follow-up (Fig. 2B). Individual study estimates ranged from 80% to 100%,[67,68] and considerable heterogeneity was again observed (I^2=88.9%, P<.001).

Prosthesis survival was evaluated in 10 studies and was defined as the proportion of prostheses remaining functional and retained on the supporting implants.[62] The pooled prosthesis survival rate was 100% (95% CI: 0.98 to 1.00), based on 220 prostheses. No heterogeneity was detected (I^2=0.0%, P=.95), indicating highly consistent outcomes across studies (Fig. 3).

DISCUSSION

The findings of the present systematic review and meta-analysis led to the rejection of the null hypothesis that implant-supported prosthetic rehabilitation after VFFF mandibular reconstruction would not demonstrate favorable implant and prosthesis survival or improve patient-reported QoL outcomes. The pooled evidence demonstrated high implant survival (92% to 96%) and excellent prosthesis survival (100%), with consistent improvements in oral function and QoL. These findings supported implant-supported rehabilitation as a predictable treatment approach following VFFF mandibular reconstruction and were consistent with those of previous reports demonstrating reliable osseointegration and favorable prosthetic outcomes in reconstructed jaws.[11,16,17]

Smolka et al[59] reported stable implant survival and favorable functional outcomes in fibula-reconstructed mandibles, attributing these results to the favorable bone volume and cortical characteristics of the fibula. In their cohort, poor patient compliance, rather than surgical or prosthetic limitations, was the principal reason for incomplete dental rehabilitation. Similarly, Iizuka et al[73] reported excellent prosthetic outcomes using their proposed classification of mandibulectomy defects, further supporting the predictability of implant-supported rehabilitation. Fang et al[3] observed that many patients did not proceed with dental rehabilitation when implants were not placed at the time of flap reconstruction, with only 10 of 28 participants completing definitive rehabilitation. Comparable findings were reported by Hundepool et al,[58] where only 24 of 70 participants (34%) received dental implants, and only 18 (26%)

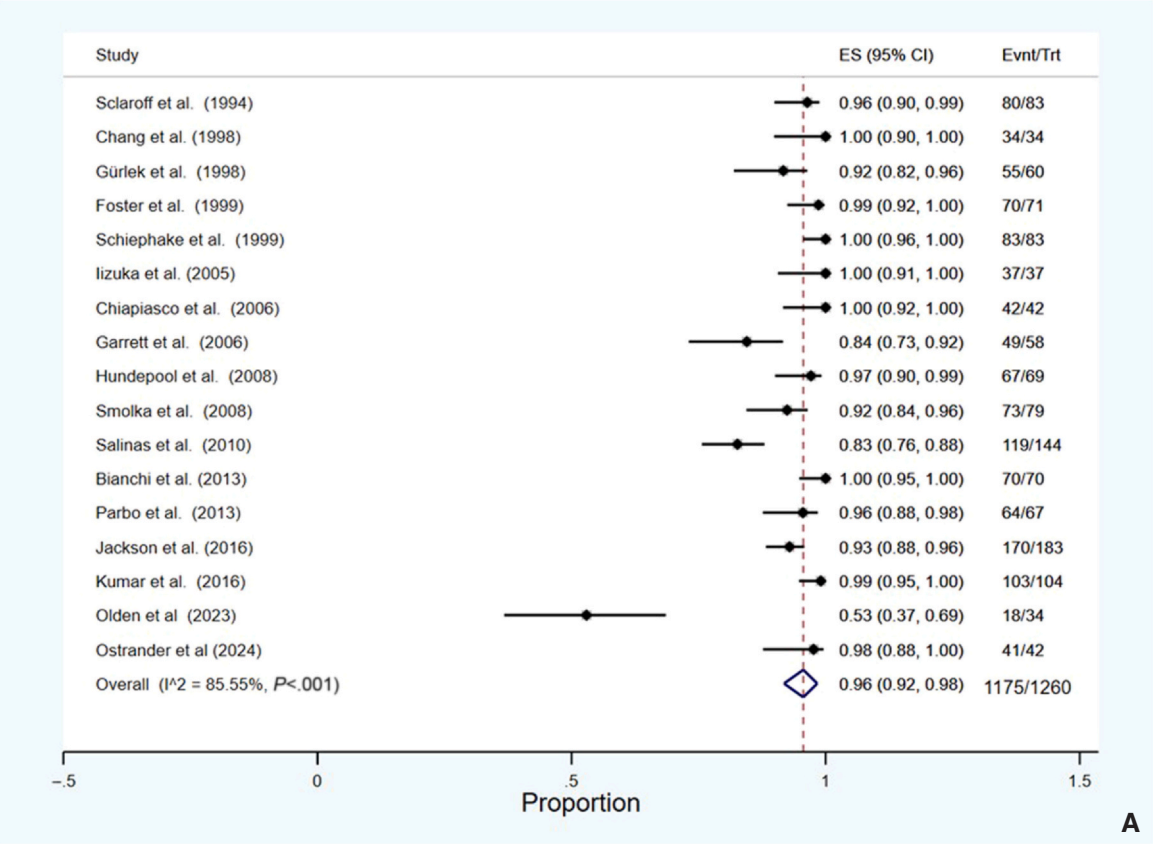

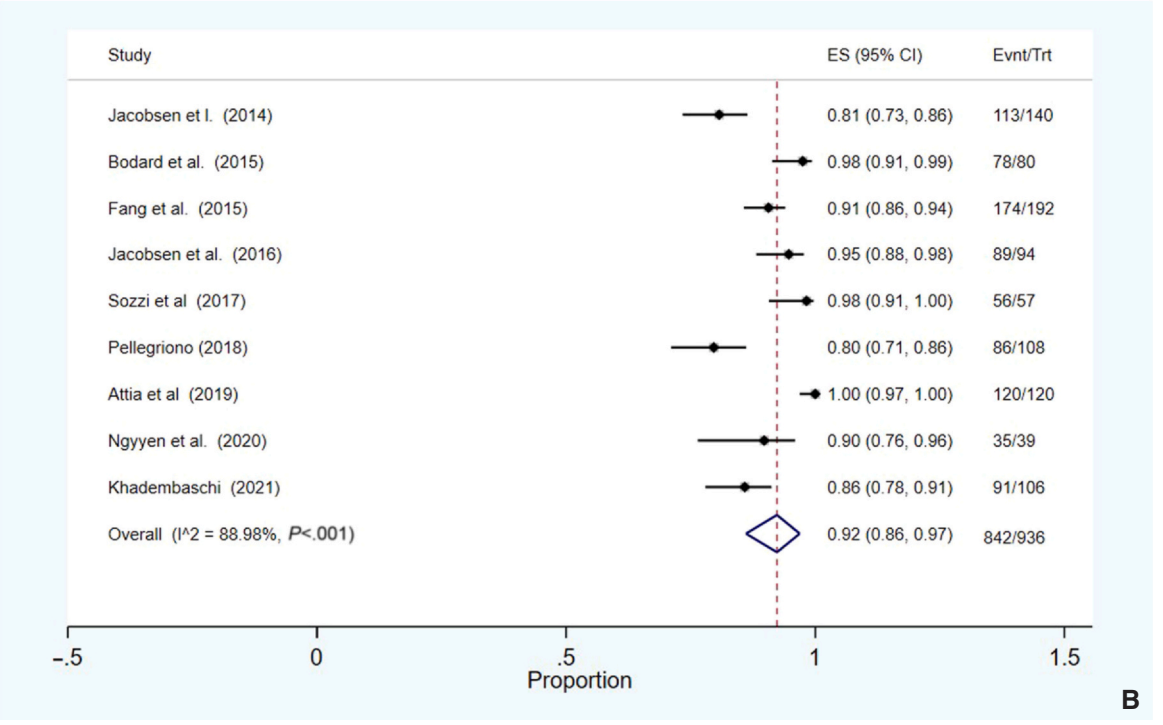

Figure 2. Estimated implant survival rate. A, Within 5 years of follow-up. B, Beyond 5 years of follow-up.

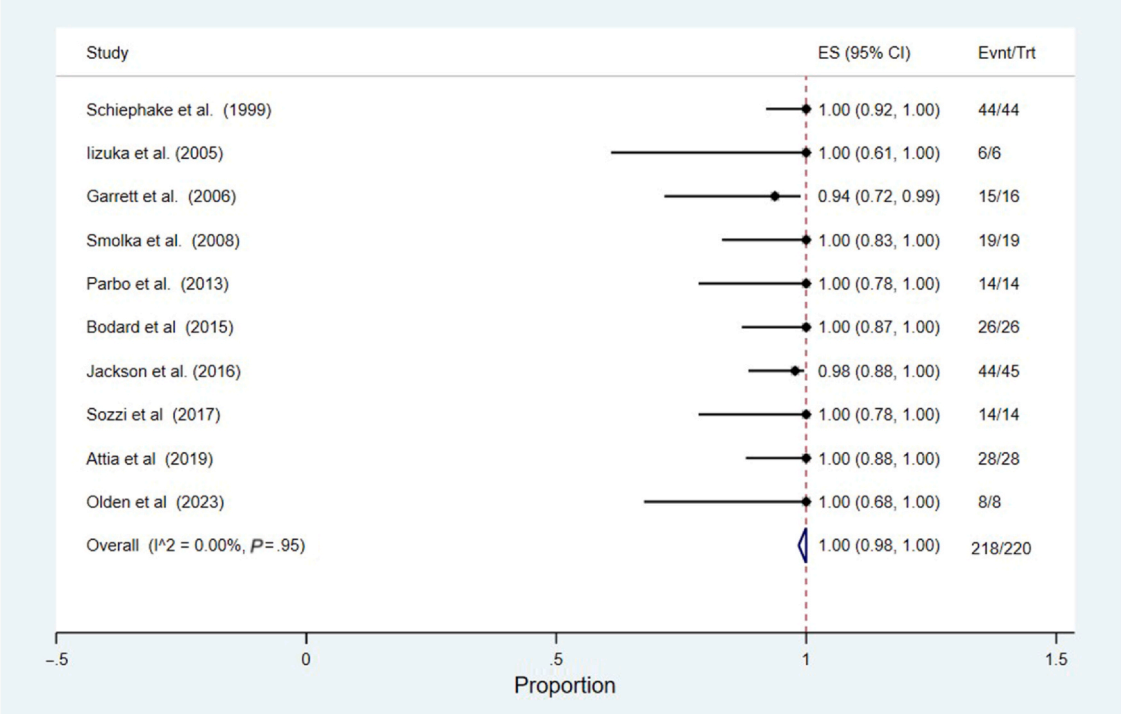

Figure 3. Estimated prosthesis survival rate.

completed definitive rehabilitation. Likewise, a more recent study[71] found that only 8 of 11 participants (20% of the overall cohort) who received implants proceeded to definitive rehabilitation. Collectively, these findings highlighted that completion of prosthetic rehabilitation remains a significant challenge despite excellent implant survival because of patient compliance, prolonged treatment, financial constraints, and radiation-related morbidity.

Previous studies have shown that irradiated fibula flaps are at greater risk of implant loss because of impaired vascularity, increased susceptibility to peri-implant disease, and delayed bone healing.[17,18] Despite these biological challenges, long-term prosthesis survival appears to be less affected. Hundepool et al[58] demonstrated that although implant survival gradually declined beyond 10 years, largely because of peri-implant disease, radiation effects, and biomechanical overload, prosthesis survival remained high. These findings were consistent with the present pooled analysis, in which prosthesis survival remained stable throughout the available follow-up. Prosthesis survival was reported in 10 studies, with follow-up after prosthesis loading ranging from approximately 1 to more than 10 years, including 4 studies[58,59,62,64] with follow-up beyond 5 years. Although follow-up duration varied, the available evidence consistently demonstrated high prosthesis survival, supporting the long-term predictability of implant-supported rehabilitation following VFFF mandibular reconstruction. This favorable trend may reflect advances in reconstructive planning, implant placement protocols, and greater emphasis on definitive implant-supported rehabilitation following mandibular reconstruction.[72]

Long-term marginal bone stability is a critical determinant of implant success, particularly in reconstructed mandibles. Although few included studies[3,69,77] reported marginal bone loss (MBL) in a standardized manner, the limited available evidence suggested that implants placed in VFFF exhibited bone remodeling patterns comparable to those in native mandibular bone.[19] The predominantly cortical nature of the fibula may offer resistance against early crestal bone loss.[20] Fang et al[3] provided the most robust long-term assessment, reporting 20-year data with measurements at 5-year intervals. Notably, crestal bone changes after 1 year of loading were similar between implant-retained and implant-supported prostheses. Long-term prospective studies with standardized radiographic protocols are needed to determine whether VFFF exhibits greater late-stage bone resorption than other reconstructive options and the implications for implant longevity.

Although implant and prosthesis survival rates were generally high, the reporting of complications across studies was inconsistent and frequently incomplete. Technical complications, including screw loosening, veneering fractures, bar fractures, and loss of retention,

were reported inconsistently and lacked standardized definitions. Biological complications, including peri-implant mucositis, peri-implantitis, soft-tissue dehiscence, and flap-related concerns, were similarly underreported. This inconsistency limited the accurate estimation of the long-term prosthetic maintenance burden in patients reconstructed with VFFF.

Despite heterogeneity in assessment instruments, all the studies assessing QoL consistently demonstrated improvements in QoL following implant-supported rehabilitation, particularly in mastication, speech, comfort, and psychosocial well-being. Patients who completed definitive rehabilitation consistently reported better functional and psychosocial outcomes than those who remained partially rehabilitated or edentulous.[3,58]

Despite encouraging outcomes, several limitations must be acknowledged. Considerable heterogeneity existed across studies regarding patient selection, timing of implant placement, radiation protocols, and prosthetic designs. Follow-up durations varied markedly, potentially masking late failures and long-term complications. Most included studies were retrospective, reflecting the practical and ethical challenges of conducting randomized clinical trials in this patient population. In addition, outcome reporting was inconsistent, with a predominant focus on implant survival rather than prosthetic or patient-reported outcomes, leading to potential bias in interpretation.

Future research should focus on multicenter prospective studies using standardized outcome measures and patient-centered assessments, including QoL, masticatory efficiency, and esthetics. The role of digital workflows, guided implant placement, and advanced prosthetic designs also warrants further investigation.

CONCLUSIONS

Based on the findings of this systematic review and meta-analysis, the following conclusions were drawn:

1. Implant-supported rehabilitation following VFFF mandibular reconstruction was associated with high implant and prosthesis survival, with improvements in function and QoL.
2. In addition to survival outcomes, this review provided a comprehensive synthesis of prosthetic rehabilitation, including prosthesis survival, complications, and patient-reported outcomes.
3. However, substantial heterogeneity in study designs and outcome reporting limits direct comparison across studies.
4. Standardized outcome measures and reporting protocols are needed to strengthen the evidence base and facilitate future evidence synthesis.

APPENDIX A. SUPPORTING INFORMATION

Supplementary data associated with this article can be found in the online version at doi:10.1016/j.prosdent.2026.08.030.

REFERENCES

1. Ferlay J, Colombet M, Soerjomataram I, et al. Estimating the global cancer incidence and mortality in 2018: GLOBOCAN sources and methods. *Int J Cancer*. 2019;144:1941–1953.
2. Brown JS, Lowe D, Kanatas A, Schache A. Mandibular reconstruction with vascularised bone flaps: A systematic review over 25 years. *Br J Oral Maxillofac Surg*. 2017;55:113–126.
3. Fang W, Liu YP, Ma Q, Liu BL, Zhao Y. Long-term results of mandibular reconstruction of continuity defects with fibula free flap and implant-borne dental rehabilitation. *Int J Oral Maxillofac Implants*. 2015;30:169–178.
4. Vosselman N, Alberga J, Witjes MHJ, et al. Prosthodontic rehabilitation of head and neck cancer patients—Challenges and new developments. *Oral Dis*. 2021;27:64–72.
5. Patel SY, Kim DD, Ghali GE. Maxillofacial reconstruction using vascularized fibula free flaps and endosseous implants. *Oral Maxillofac Surg Clin North Am*. 2019;31:259–284.
6. Petrovic I, Baser R, Blackwell T, et al. Long-term functional and esthetic outcomes after fibula free flap reconstruction of the mandible. *Head Neck*. 2019;41:2123–2132.
7. Taylor GI, Miller GD, Ham FJ. The free vascularized bone graft. A clinical extension of microvascular techniques. *Plast Reconstr Surg*. 1975;55:533–544.
8. Hidalgo DA. Fibula free flap: A new method of mandible reconstruction. *Plast Reconstr Surg*. 1989;84:71–79.
9. Wei FC, Chen HC, Chuang CC, Noordhoff MS. Fibular osteoseptocutaneous flap: Anatomic study and clinical application. *Plast Reconstr Surg*. 1986;78:191–200.
10. Gu Y, Ma H, Shujaat S, et al. Donor- and recipient-site morbidity of vascularized fibular and iliac flaps for mandibular reconstruction: A systematic review and meta-analysis. *J Plast Reconstr Aesthet Surg*. 2021;74:1470–1479.
11. Illand C, Destruhaut F, Porporatti AL, Wulfman C, Naveau A, Rignon-Bret C. Implant survival rate in mandible reconstructed with free fibula flaps after oral tumors: A systematic review and meta-analysis. *Int J Oral Maxillofac Implants*. 2023;38:976–985.
12. Gangwani P, Almana M, Barmak B, Kolokythas A. What is the success of implants placed in fibula flap? A systematic review and meta-analysis. *J Oral Maxillofac Res*. 2022;13:e3.
13. Chiapasco M, Abati S, Ramundo G, Rossi A, Romeo E, Vogel G. Behavior of implants in bone grafts or free flaps after tumor resection. *Clin Oral Implants Res*. 2000;11:66–75.
14. Attia S, Wiltfang J, Pons-Kühnemann J, et al. Survival of dental implants placed in vascularised fibula free flaps after jaw reconstruction. *J Craniomaxillofac Surg*. 2018;46:1205–1210.
15. Anne-Gaëlle B, Samuel S, Julie B, Renaud L, Pierre B. Dental implant placement after mandibular reconstruction by microvascular free fibula flap: Current knowledge and remaining questions. *Oral Oncol*. 2011;47:1099–1104.
16. Sriram S, Njoroge MW, Lopez CD, et al. Optimal treatment order with fibula-free flap reconstruction, oncologic treatment, and dental implants: A systematic review and meta-analysis. *J Craniofac Surg*. 2024;35:1065–1073.
17. Panchal H, Shamsunder MG, Petrovic I, et al. Dental implant survival in vascularized bone flaps: A systematic review and meta-analysis. *Plast Reconstr Surg*. 2020;146:637–648.
18. Lodders JN, Leusink FKJ, Ridwan-Pramana A, et al. Long-term outcomes of implant-based dental rehabilitation in head and neck cancer patients after reconstruction with the free vascularized fibula flap. *J Craniomaxillofac Surg*. 2021;49:845–854.
19. Ardisson A, de Senna PM, Granato R, Bergamo ETP, Bonfante EA, Marin C. Success rate of mandible implants placed in vascularized fibula bone graft: A systematic review. *J Oral Implantol*. 2023;49:85–92.
20. Gurav S, Singh GP, Jain R, Kumar S, Bindu A, Puranik AD. Anatomical characteristics of the fibula as a guide to dental implant installation. *Int J Oral Maxillofac Surg*. 2026;55:472–480.
21. Menapace DC, Van Abel KM, Jackson RS, Moore EJ. Primary vs secondary endosseous implantation after fibular free tissue reconstruction of the mandible for osteoradionecrosis. *JAMA Facial Plast Surg*. 2018;20:401–408.
22. Page MJ, McKenzie JE, Bossuyt PM, et al. The PRISMA 2020 statement: An updated guideline for reporting systematic reviews. *BMJ*. 2021;372:n71.
23. Patel A, Harrison P, Cheng A, Bray B, Bell RB. Fibular reconstruction of the maxilla and mandible with immediate implant-supported prosthetic

rehabilitation: Jaw in a day. *Oral Maxillofac Surg Clin North Am*. 2019;31:369–386.
24. Sass T, Piffkó J, Braunitzer G, Oberna F. Esthetic and functional reconstruction of large mandibular defects using free fibula flap and implant-retained prosthetics - A case series with long-term follow-up. *Head Face Med*. 2021;17:43.
25. Wijbenga JG, Schepers RH, Werker PMN, Witjes MJH, Dijkstra PU. A systematic review of functional outcome and quality of life following reconstruction of maxillofacial defects using vascularized free fibula flaps and dental rehabilitation reveals poor data quality. *J Plast Reconstr Aesthet Surg*. 2016;69:1024–1036.
26. Tahmasebi E, Keykha E, Hajisadeghi S, et al. Outcomes and influential factors in functional and dental rehabilitation following microvascular fibula flap reconstruction in the maxillomandibular region: A systematic review and meta-analysis. *Maxillofac Plast Reconstr Surg*. 2023;45:24.
27. Michael M, Baker B, Fernandes R. Long-term outcomes of dental implants placed in fibula-free flaps used for reconstruction of Maxillo-Mandibular defects. *Oral Maxillofac Surg Clin*. 2025;37:109–120.
28. Dholam KP, Singh GP, Gurav SV, Yadav P. Factors affecting dental rehabilitation following jaw reconstruction with free-fibular graft in patients with head and neck cancer. *J Craniofac Surg*. 2018;29:2070–2074.
29. Pappalardo M, Tsao CK, Tsang ML, Zheng J, Chang YM, Tsai CY. Long-term outcome of patients with or without osseointegrated implants after resection of mandibular ameloblastoma and reconstruction with vascularized bone graft: Functional assessment and quality of life. *J Plast Reconstr Aesthet Surg*. 2018;71:1076–1085.
30. Ja V, Ask P, Rj de G, Hs B, Cm S. Mastication in health-related quality of life in patients treated for oral cancer: A systematic review. *Eur J Cancer Care (Engl)*. 2022;31:e13744.
31. Nham TT, Koudougou C, Piot B, Corre P, Bertin H, Longis J. Prosthetic rehabilitation in patients with jaw reconstruction by fibula free flap: A systematic review. *J Stomatol Oral Maxillofac Surg*. 2024;125:101735.
32. Barber HD, Seckinger RJ, Hayden RE, Weinstein GS. Evaluation of osseointegration of endosseous implants in radiated, vascularized fibula flaps to the mandible: A pilot study. *J Oral Maxillofac Surg*. 1995;53:640–645.
33. Kovács AF. Influence of the prosthetic restoration modality on bone loss around dental implants placed in vascularized iliac bone grafts for mandibular reconstruction. *Otolaryngol Head Neck Surg*. 2000;123:598–602.
34. Gbara A, Darwich K, Li L, Schmelzle R, Blake F. Long-term results of jaw reconstruction with microsurgical fibula grafts and dental implants. *J Oral Maxillofac Surg*. 2007;65:1005–1009.
35. Chiapasco M, Colletti G, Romeo E, Zaniboni M, Brusati R. Long-term results of mandibular reconstruction with autogenous bone grafts and oral implants after tumor resection. *Clin Oral Implants Res*. 2008;19:1074–1080.
36. Bodard AG, Bémer J, Gourmet R, et al. Dental implants and free fibula flap: 23 patients. *Rev Stomatol Chir Maxillofac*. 2011;112:e1–e4.
37. He Y, Zhang ZY, Zhu HG, Wu YQ, Fu HH. Double-barrel fibula vascularized free flap with dental rehabilitation for mandibular reconstruction. *J Oral Maxillofac Surg*. 2011;69:2663–2669.
38. Momoh AO, Yu P, Skoracki RJ, Liu S, Feng L, Hanasono MM. A prospective cohort study of fibula free flap donor-site morbidity in 157 consecutive patients. *Plast Reconstr Surg*. 2011;128:714–720.
39. Chang YM, Wallace CG, Hsu YM, Shen YF, Tsai CY, Wei FC. Outcome of osseointegrated dental implants in double-barrel and vertically distracted fibula osteoseptocutaneous free flaps for segmental mandibular defect reconstruction. *Plast Reconstr Surg*. 2014;134:1033–1043.
40. Hakim SG, Kimmerle H, Trenkle T, Sieg P, Jacobsen HC. Masticatory rehabilitation following upper and lower jaw reconstruction using vascularised free fibula flap and enossal implants-19 years of experience with a comprehensive concept. *Clin Oral Investig*. 2015;19:525–534.
41. Meloni SM, Tallarico M, De Riu G, et al. Guided implant surgery after free-flap reconstruction: Four-year results from a prospective clinical trial. *J Craniomaxillofac Surg*. 2015;43:1348–1355.
42. Wang F, Huang W, Zhang C, Sun J, Kaigler D, Wu Y. Comparative analysis of dental implant treatment outcomes following mandibular reconstruction with double-barrel fibula bone grafting or vertical distraction osteogenesis fibula: A retrospective study. *Clin Oral Implants Res*. 2015;26:157–165.
43. Brandão TB, Filho AJV, Ribeiro ACP, et al. Evaluation of use of acrylic resin-based surgical guide in the function and quality of life provided by mandibular prostheses with microvascular free fibula flap: A four-year, randomized, controlled trial. *J Prosthet Dent*. 2016;116:457–463.e2.
44. Kumar VV, Ebenezer S, Kämmerer PW, et al. Implants in free fibula flap supporting dental rehabilitation - Implant and peri-implant related outcomes of a randomized clinical trial. *J Craniomaxillofac Surg*. 2016;44:1849–1858.
45. Chuka R, Abdullah W, Rieger J, et al. Implant utilization and time to prosthetic rehabilitation in conventional and advanced fibular free flap reconstruction of the maxilla and mandible. *Int J Prosthodont*. 2017;30:289–294.
46. Kumar VV, Srinivasan M. Masticatory efficiency of implant-supported removable partial dental prostheses in patients with free fibula flap reconstructed mandibles: A split-mouth, observational study. *Clin Oral Implants Res*. 2018;29:855–863.
47. Goker F, Baj A, Bolzoni AR, Maiorana C, Giannì AB, Del Fabbro M. Dental implant-based oral rehabilitation in patients reconstructed with free fibula flaps: Clinical study with a follow-up 3 to 6 years. *Clin Implant Dent Relat Res*. 2020;22:514–522.
48. Zhang J, Wang Y, Yuan L, Wang W. Masticatory performance in patients undergoing free fibula flap for mandible reconstruction. *BMC Oral Health*. 2022;22:78.
49. Tumuluri V, Leinkram D, Froggatt C, et al. Outcomes of immediate dental implants in vascularised bone flaps for mandibular reconstruction. *ANZ J Surg*. 2023;93:1682–1687.
50. Zeman-Kuhnert K, Gaggl AJ, Bottini GB, et al. Long-term outcomes of dental rehabilitation and quality of life after microvascular alveolar ridge reconstruction in patients with head and neck cancer. *J Clin Med*. 2024;13.
51. Stang A. Critical evaluation of the Newcastle-Ottawa scale for the assessment of the quality of nonrandomized studies in meta-analyses. *Eur J Epidemiol*. 2010;25:603–605.
52. Sterne JAC, Savović J, Page MJ, et al. RoB 2: A revised tool for assessing risk of bias in randomised trials. *BMJ*. 2019;366:l4898.
53. Sclaroff A, Haughey B, Gay WD, Paniello R. Immediate mandibular reconstruction and placement of dental implants. At the time of ablative surgery. *Oral Surg Oral Med Oral Pathol*. 1994;78:711–717.
54. Chang YM, Santamaria E, Wei FC, et al. Primary insertion of osseointegrated dental implants into fibula osteoseptocutaneous free flap for mandible reconstruction. *Plast Reconstr Surg*. 1998;102:680–688.
55. Gürlek A, Miller MJ, Jacob RF, Lively JA, Schusterman MA. Functional results of dental restoration with osseointegrated implants after mandible reconstruction. *Plast Reconstr Surg*. 1998;101:650–659.
56. Foster RD, Anthony JP, Sharma A, Pogrel MA. Vascularized bone flaps versus nonvascularized bone grafts for mandibular reconstruction: An outcome analysis of primary bony union and endosseous implant success. *Head Neck*. 1999;21:66–71.
57. Schliephake H, Schmelzeisen R, Husstedt H, Schmidt-Wondera LU. Comparison of the late results of mandibular reconstruction using nonvascularized or vascularized grafts and dental implants. *J Oral Maxillofac Surg*. 1999;57:944–950.
58. Hundepool AC, Dumans AG, Hofer SOP, et al. Rehabilitation after mandibular reconstruction with fibula free-flap: Clinical outcome and quality of life assessment. *Int J Oral Maxillofac Surg*. 2008;37:1009–1013.
59. Smolka K, Kraehenbuehl M, Eggensperger N, et al. Fibula free flap reconstruction of the mandible in cancer patients: Evaluation of a combined surgical and prosthodontic treatment concept. *Oral Oncol*. 2008;44:571–581.
60. Salinas TJ, Desa VP, Katsnelson A, Miloro M. Clinical evaluation of implants in radiated fibula flaps. *J Oral Maxillofac Surg*. 2010;68:524–529.
61. Bianchi B, Ferri A, Ferrari S, et al. Mandibular resection and reconstruction in the management of extensive ameloblastoma. *J Oral Maxillofac Surg*. 2013;71:528–537.
62. Parbo N, Murra NT, Andersen K, Buhl J, Kiil B, Nørholt SE. Outcome of partial mandibular reconstruction with fibula grafts and implant-supported prostheses. *Int J Oral Maxillofac Surg*. 2013;42:1403–1408.
63. Jacobsen C, Kruse A, Lübbers HT, et al. Is mandibular reconstruction using vascularized fibula flaps and dental implants a reasonable treatment? *Clin Implant Dent Relat Res*. 2014;16:419–428.
64. Bodard AG, Salino S, Desoutter A, Deneuve S. Assessment of functional improvement with implant-supported prosthetic rehabilitation after mandibular reconstruction with a microvascular free fibula flap: A study of 25 patients. *J Prosthet Dent*. 2015;113:140–145.
65. Jackson RS, Price DL, Arce K, Moore EJ. Evaluation of clinical outcomes of osseointegrated dental implantation of fibula free flaps for mandibular reconstruction. *JAMA Facial Plast Surg*. 2016;18:201–206.
66. Sozzi D, Novelli G, Silva R, Connelly ST, Tartaglia GM. Implant rehabilitation in fibula-free flap reconstruction: A retrospective study of cases at 1-18 years following surgery. *J Craniomaxillofac Surg*. 2017;45:1655–1661.
67. Pellegrino G, Tarsitano A, Ferri A, Corinaldesi G, Bianchi A, Marchetti C. Long-term results of osseointegrated implant-based dental rehabilitation in oncology patients reconstructed with a fibula free flap. *Clin Implant Dent Relat Res*. 2018;20:852–859.
68. Attia S, Wiltfang J, Streckbein P, et al. Functional and aesthetic treatment outcomes after immediate jaw reconstruction using a fibula flap and dental implants. *J Craniomaxillofac Surg*. 2019;47:786–791.
69. Nguyen TTH, Eo MY, Myoung H, Kim MJ, Kim SM. Implant-supported fixed and removable prostheses in the fibular mandible. *Int J Implant Dent*. 2020;6:44.

70. Khadembaschi D, Russell P, Beech N, Batstone MD. Osseointegrated implant survival, success and prosthodontic outcomes in composite free flaps: A 10-year retrospective cohort study. *Clin Oral Implants Res.* 2021;32:1251–1261.
71. Oldén A, Wamalwa AO, Jonsson EL, Thor A, Lorenzo AR. Factors affecting complete oral rehabilitation in patients with vascularized free fibula flap mandibular reconstruction: A 10-year retrospective study. *J Craniofac Surg.* 2023;34:1635–1639.
72. Ostrander BT, Meller L, Harmon M, et al. Free flap jaw reconstruction with dental implantation: A single-institution experience. *Head Neck.* 2024;46:1370–1379.
73. Iizuka T, Häfliger J, Seto I, Rahal A, Mericske-Stern R, Smolka K. Oral rehabilitation after mandibular reconstruction using an osteocutaneous fibula free flap with endosseous implants. Factors affecting the functional outcome in patients with oral cancer. *Clin Oral Implants Res.* 2005;16:69–79.
74. Chiapasco M, Biglioli F, Autelitano L, Romeo E, Brusati R. Clinical outcome of dental implants placed in fibula-free flaps used for the reconstruction of maxillo-mandibular defects following ablation for tumors or osteoradionecrosis. *Clin Oral Implants Res.* 2006;17:220–228.
75. Garrett N, Roumanas ED, Blackwell KE, et al. Efficacy of conventional and implant-supported mandibular resection prostheses: Study overview and treatment outcomes. *J Prosthet Dent.* 2006;96:13–24.
76. Jacobsen HC, Wahnschaff F, Trenkle T, Sieg P, Hakim SG. Oral rehabilitation with dental implants and quality of life following mandibular reconstruction with free fibular flap. *Clin Oral Investig.* 2016;20:187–192.
77. Kumar VV, Jacob PC, Ebenezer S, et al. Implant supported dental rehabilitation following segmental mandibular reconstruction-quality of life outcomes of a prospective randomized trial. *J Craniomaxillofac Surg.* 2016;44:800–810.

Corresponding author:
Prof. Dr. med. dent. Andrea Roccuzzo PhD
Shanghai Perio-Implant Innovation Center
Institute of Integrated Oral, Craniofacial and Sensory Research
Shanghai Ninth People's Hospital
Shanghai Jiao Tong University School of Medicine
Pudong Research Campus
4F Building 1
115 Jinzun Road
Shanghai 200115
PR CHINA
Email: andrea.roccuzzo@unibe.ch

Acknowledgments
The authors thank Drs Fabian Pérez, Alvaro Limones, and Jaime Amador for their collaboration in this research.

CRediT authorship contribution statement
Pedro Molinero-Mourelle: Conceptualization, Writing - original draft, Writing - review and editing, Project administration, Funding acquisition. **Gunjan Srivastava**: Conceptualization, Methodology, Software, Validation, Formal analysis, Investigation, Data curation, Writing - original draft, Writing - review and editing, Project administration, Funding acquisition. **Subrat Kumar Padhiary**: Conceptualization, Methodology, Software, Validation, Formal analysis, Investigation, Data curation, Writing - original draft, Writing - review and editing, Project administration, Funding acquisition. **Umberto Gibello**: Writing - original draft, Writing - review and editing. **Martin Schimmel**: Visualization, Supervision. **Adrien Naveau**: Writing - review and editing, Visualization, Supervision. **Andrea Roccuzzo**: Conceptualization, Writing - original draft, Writing - review and editing.

Copyright © 2026 The Authors. Published by Elsevier Inc. on behalf of the Editorial Council of *The Journal of Prosthetic Dentistry*. This is an open access article under the CC BY license (http://creativecommons.org/licenses/by/4.0/).
https://doi.org/10.1016/j.prosdent.2026.08.030