POLITECNICO DI TORINO
Repository ISTITUZIONALE

The effect of different hemostatic agents on hemorrhage control, pain and quality of life after endodontic microsurgery

Original
The effect of different hemostatic agents on hemorrhage control, pain and quality of life after endodontic microsurgery / Alovisi, M., Giordano, L., Fenoglio, V., Oricco, S., Balocco, A., Baldi, A., Comba, A., Scotti, N., Pasqualini, D.. - In: BMC ORAL HEALTH. - ISSN 1472-6831. - (2026). [10.1186/s12903-026-09884-1]

Availability:
This version is available at: 11583/3015762 since: 2026-09-21T12:06:44Z

Publisher:
BMC Oral Health

Published
DOI:10.1186/s12903-026-09884-1

Terms of use:

This article is made available under terms and conditions as specified in the corresponding bibliographic description in the repository

Publisher copyright

(Article begins on next page)

29 November 2026

RESEARCH | Article in Press

The effect of different hemostatic agents on hemorrhage control, pain and quality of life after endodontic microsurgery

Mario Alovisi · Lia Giordano · Vittorio Fenoglio · Sofia Oricco · Alice Balocco · Andrea Baldi · Allegra Comba · Nicola Scotti · Damiano Pasqualini

Received: 30 December 2025 / Accepted: 8 September 2026
© The Author(s) 2026

Abstract

Background This randomized clinical trial evaluated the effect of two different hemostatic materials for endodontic microsurgery on bleeding control, postoperative pain and patients' quality of life.

Methods Thirty-four subjects with apical periodontitis requiring endodontic microsurgery were randomized (computer-generated allocation list, allocation concealment by sequentially numbered opaque sealed envelopes) to receive N-hexyl cyanoacrylate surgical glue ($n=15$) or ferric sulfate 15.5% ($n=19$) for intraoperative haemostasis. The primary outcome was the hemorrhage control score after application of the hemostatic agent. Secondary outcomes were intraoperative bleeding control before agent application, surgical field visibility, bleeding recovery after agent removal, daily postoperative pain on the Numerical Rating Scale (NRS), daily analgesic intake, postoperative swelling and the Oral Health Impact Profile-14 (OHIP-14) quality-of-life score, all collected over seven days. Categorical variables were analysed using the chi-square or Fisher's exact test; continuous variables were analysed using independent-samples t-tests or Mann–Whitney U tests as appropriate, with significance set at $P<0.05$.

Results The mean lesion volume and diameter were higher in the surgical glue group ($P=0.022$ and $P=0.031$ respectively). There was no significant difference regarding the bleeding control before ($P=0.15$) and after ($P=0.27$) hemostatic agent use in both groups; at T1, complete hemorrhage control was observed in 60.0% and 52.6% of patients, respectively (absolute difference 7.4% points; 95% CI -24.1 to 36.4). The visibility of the surgical field appeared similar in the two groups ($P=0.092$). After the removal of the surgical glue, there was a significant increase in bleeding recovery compared to ferric sulfate ($P=0.045$). In unadjusted between-group comparisons, postoperative swelling was more frequently reported in the surgical glue group ($P=0.026$), and analgesic consumption was also higher in this group ($P=0.040$). However, these postoperative differences should be interpreted in light of the significant baseline imbalance in lesion size between groups. The postoperative pain curves showed parallel trends ($P=0.31$) and the overall QoL showed no significant differences between groups ($P=0.54$).

Conclusion Both ferric sulfate and N-hexyl cyanoacrylate surgical glue provided comparable intraoperative haemostasis during endodontic microsurgery under the conditions of the present study. Moreover, these statistical

This Article in Press is shared early to give you faster access to new research. It is citable and carries a permanent DOI. The final edited version will replace it automatically.

https://doi.org/10.1186/s12903-026-09884-1

Published online: 14 September 2026

differences were not accompanied by significant between-group differences in postoperative pain or overall quality of life and should therefore not be interpreted as establishing a clinically meaningful overall disadvantage of either material. Because follow-up was limited to seven days, the present study provides information only on intraoperative performance and early postoperative morbidity and does not allow conclusions regarding periapical healing, late complications, radiographic healing, or long-term surgical success.

Trial registration ClinicalTrials.gov NCT07311291 (registered 20 November 2025; registration was retrospective with respect to the start of recruitment in November 2023). The study was approved by the local Ethics Committee and Institutional Review Board (Protocol ID: 0272/2023).

Keywords Endodontic microsurgery · Surgical glue · Ferric sulfate · Cone-beam computed tomography · Hemostatic agents

Background

Endodontic microsurgery aims to achieve complete cleansing and three-dimensional obturation of the apical portion of the root canal system through a surgical approach [1]. The introduction of new technologies, instruments and materials has simplified the procedural steps and improved clinical outcomes, allowing more predictable management of the apical anatomy [2]. The use of cone beam computed tomography (CBCT) has improved the preoperative assessment of the root apical anatomy and of the lesion landmarks, which is critical for clinical success [3, 4]. In addition, the surgical microscope and the ultrasonic tips for apical preparation enable a minimally invasive approach that may reduce postoperative discomfort and favour wound healing [5, 6]. Adequate haemostasis is an essential intra-operative requirement of endodontic microsurgery: it improves visibility of the surgical field, reduces operative time and may indirectly influence the post-operative course [7–9]. The use of an appropriate hemostatic agent therefore helps to control bleeding within the bone crypt and is one of several factors that, together with lesion size, surgical access and patient-related variables, can influence the post-operative prognosis [10, 11].

The ideal characteristics of a hemostatic agent for periradicular surgery are a rapid onset of action, ease of handling, biocompatibility and absence of interference with bone and soft-tissue healing [12]. Ferric sulfate is widely used in endodontic microsurgery because the ferric ions induce blood clotting through the denaturation of plasma proteins and platelets, forming a physical barrier that arrests bleeding, while its astringent effect further promotes soft-tissue contraction and local haemostasis [12]. However, ferric sulfate has been associated with cytotoxic effects on the underlying bone when retained in the crypt and with delayed osseous healing in animal models [11], and the discoloured superficial layer of bone must be carefully removed before suturing. These limitations have motivated the search for alternative hemostatic agents with a more favourable biological profile and a more controllable mechanism of action [11].

Medical cyanoacrylate-based glues have been used for bleeding control in general, visceral and laparoscopic surgery [13, 14] and, in oral surgery, as tissue adhesives to promote wound healing and stabilize free gingival grafts [15–17]. To the best of our knowledge, no clinical data are available regarding the use of a surgical hemostatic glue as an intraoperative agent in the management of the endodontic microsurgical field. Available evidence on the biological behaviour of cyanoacrylates is largely derived from in vitro cytotoxicity assays and from short-term preclinical in vivo studies in animal models of hernia repair and intraperitoneal mesh fixation, which have shown variable degrees of local foreign-body reaction and modulation of the early inflammatory response [18–20]. The clinical implications of these biological findings for periapical tissues and bone healing remain unclear and provide the rationale for the present investigation.

The N-hexyl cyanoacrylate hemostatic glue investigated in the present study is commonly employed in digestive, visceral, urogenital and breast surgery [13, 20]. Given the multifactorial nature of postoperative pain and the indirect relationship between intra-operative haemostasis and patient-reported outcomes, the present randomized

clinical trial was designed as a hypothesis-generating comparison of N-hexyl cyanoacrylate surgical glue and ferric sulfate during endodontic microsurgery. The primary outcome was the hemorrhage control score after application of the hemostatic agent; secondary outcomes were intra-operative bleeding control before application, surgical field visibility, bleeding recovery after agent removal, postoperative pain on the NRS, daily analgesic intake, postoperative swelling and oral-health-related quality of life measured with the OHIP-14. Accordingly, the study was designed to assess intraoperative haemostatic performance and early postoperative morbidity and was not intended to evaluate periapical healing or long-term surgical success.

Methods

Ethical considerations

This randomized controlled clinical trial was approved by the local Ethics Committee and Institutional Review Board (Protocol ID: 0272/2023). Recruitment took place between November 2023 and September 2025; the seven-day follow-up of the last enrolled patient was completed in October 2025. The trial was registered at ClinicalTrials.gov (NCT07311291) on 20 November 2025. The authors acknowledge that registration was retrospective with respect to the start of recruitment. No protocol changes were introduced after the first participant was enrolled, and the outcomes reported in the present manuscript correspond to those defined in the ethics-approved protocol. Therefore, the ethics-approved protocol and predefined outcomes were maintained throughout recruitment. All recruited subjects provided written informed consent. The manuscript was prepared in accordance with the CONSORT 2010 statement and the Preferred Reporting Items for Randomized Trials in Endodontics (PRIRATE) 2020 guidelines [21], and the corresponding checklists are provided as Supplementary Material.

Eligibility criteria

Consecutive informed and consenting healthy subjects (ASA 1–2) of both genders with no medical history of systemic disease and presenting a diagnosis of symptomatic or asymptomatic apical periodontitis in correspondence of endodontically treated teeth with periapical lesions were enrolled. The diagnosis was performed clinically and radiographically through periapical radiographs and small field of view (FOV) Cone-Beam Computed Tomography (CBCT). The lesions volume and diameters were evaluated using the dedicated software Mimics 24.0 (Materialise, Belgium). Only periapical defects with one or two residual cortical walls were considered, while bone cavity designs with no cortical walls were excluded. The clinical indications for retrograde endodontic retreatment were reported for all cases: the teeth presented inadequate root canal treatment with periapical radiolucency and impossible access through orthograde retreatment due to the presence of prosthetic restorations, posts, canal blocks and ledges. Moreover, the teeth presented an adequate coronal seal and absence of pathological periodontal records.

The subjects affected by diabetes mellitus, hypertension and hepatic or renal diseases were excluded from the study. Similarly, exclusion criteria included bleeding disorders, pregnancy and antiplatelet or anticoagulant therapy. The teeth that were considered unrestorable and the elements affected by fractures or extensive periodontal defects were also dismissed. A written consensus reporting information about the surgical procedure and the clinical and radiographical follow-up was supplied.

Sample size calculation

The sample size was estimated a priori using G*Power v.3.1 (Heinrich-Heine-Universität, Düsseldorf, Germany). At the study-design stage, the sample-size calculation was based on postoperative pain measured using the Numerical Rating Scale (NRS), because this was considered the most variable patient-reported outcome for which a

quantitative estimate of variability was available from a comparable endodontic microsurgery study. Specifically, a common standard deviation of 6.24, derived from the postoperative NRS pain data reported by Bharathi et al. [8], was used together with a two-sided α of 0.05 and a power (1 − β) of 80%, resulting in a minimum required sample of 10 subjects per group. An appropriate variance or effect-size estimate for the hemorrhage-control score for the specific comparison between N-hexyl cyanoacrylate and ferric sulfate was not available at the time of study design. Because the hemorrhage-control score is an ordinal outcome, no sufficiently reliable quantitative basis was therefore available to power the study directly on this endpoint. To compensate for a foreseen dropout rate of approximately 20%, recruitment was extended to a total of 34 subjects. Postoperative pain was assessed throughout the trial using the NRS, consistent with the operational definition adopted in all study documents and outcome forms.

Randomization and allocation

The allocation sequence was generated by a researcher not involved in patient recruitment or clinical treatment using a computer-generated random number list with simple 1:1 randomization. Allocation concealment was ensured by sequentially numbered, opaque, sealed envelopes that were opened by the surgical assistant only after the bone crypt had been prepared and the T0 hemorrhage control assessment had been completed. Patients were not informed of the type of hemostatic agent assigned to them. Because the two materials differ markedly in physical appearance and handling, blinding of the operator was not feasible; however, postoperative patient-reported outcomes were collected through standardized self-report diaries completed by the patients at home, and the statistician who performed the analyses was blinded to group allocation.

Treatment procedure

All procedures were performed by a single experienced operator in a sterile environment using an operating microscope (OPMI Pro Ergo, Carl Zeiss, Germany). Local anaesthesia followed a two-step protocol routinely used by the operating team to ensure both deep pulpal/periapical anaesthesia and prolonged local haemostasis from the vasoconstrictor: first, a buccal infiltration of articaine 4% with epinephrine 1:100,000 (Septodont, Saint-Maur-des-Fossés, France) was administered (one to two 1.7 mL cartridges, depending on tooth location); ten minutes later, supplementary buccal infiltration with lidocaine 2% with epinephrine 1:50,000 (Dentsply Sirona, Charlotte, NC, USA) was given (one 1.8 mL cartridge). The total epinephrine dose never exceeded 0.2 mg, and the total doses of articaine and lidocaine were kept well within the manufacturers' recommended maxima (7 mg/kg each). The same two-anaesthetic protocol was used in both arms and was completed before the allocation envelope was opened, so that any vasoconstrictor-related haemostatic effect was expected to influence the two groups equally. A full-thickness mucoperiosteal flap was then elevated, the periradicular lesion was debrided with surgical curettes (Hu-Friedy, Chicago, IL, USA) and the bone crypt was refined with a #557 SL Lindemann bur (Brasseler USA, Savannah, GA). Immediately after curettage and before disclosure of the allocation, the operator and two independent calibrated assistants assigned the hemorrhage control and the surgical field visibility scores reported in Table 1 [8]. Before the trial, the three examiners had been calibrated on five pilot cases not included in the study; Cohen's kappa for inter-examiner agreement on hemorrhage control was 0.82 (very good

Table 1 Hemorrhage control and surgical field view scores

Score	Hemorrhage Control	Surgical Field View
0	no hemorrhage control or profuse bleeding that covers the surgical site hampering the root-end filling procedures	not clear view of the surgical field
1	slight intermittent bleeding that allowed root-end filling procedures	clear view that allowed root-end filling procedures
2	complete hemorrhage control that allowed root-end filling procedures	

agreement), and in case of disagreement the median of the three independent scores was used. The envelope was then opened. In group 1 ($n=15$), the N-hexyl cyanoacrylate surgical glue (IfaBond, Dipromed, Mondovi, Italy) was applied to the bone crypt with a 23G needle in a single drop of approximately 0.05 mL and was allowed to polymerize in contact with blood for 60 s without active compression (Fig. 1a). In group 2 ($n=19$), ferric sulfate 15.5% (Astringedent, Ultradent Products Inc., South Jordan, UT, USA) was applied with a sterile cotton pellet under light digital pressure for 60 s and the area was then gently rinsed with sterile saline (Fig. 1b). After application of the hemostatic agent, the hemorrhage control score and the surgical field visibility score were re-evaluated independently by the same three examiners (T1) using the criteria reported in Table 1.

Apical resection of 2–3 mm with a 0º–10º bevel angle was performed with a #557 SL Lindemann bur (Brasseler USA, Savannah, GA). The apical portion of the root was then stained with 2% methylene blue to visualize the canal anatomy, isthmuses and possible microfractures. In both groups, the apical 3 mm were prepared along the long axis of the root with a piezoelectric device (MiniPiezon, EMS, Nyon, Switzerland) and dedicated ultrasonic tips (ProUltra Surgical Tips, Dentsply Sirona, Charlotte, NC, USA). Root-end filling was completed with super-EBA cement (SuperSeal, OGNA, Muggiò, Italy); super-EBA was preferred to MTA or bioceramic putty because

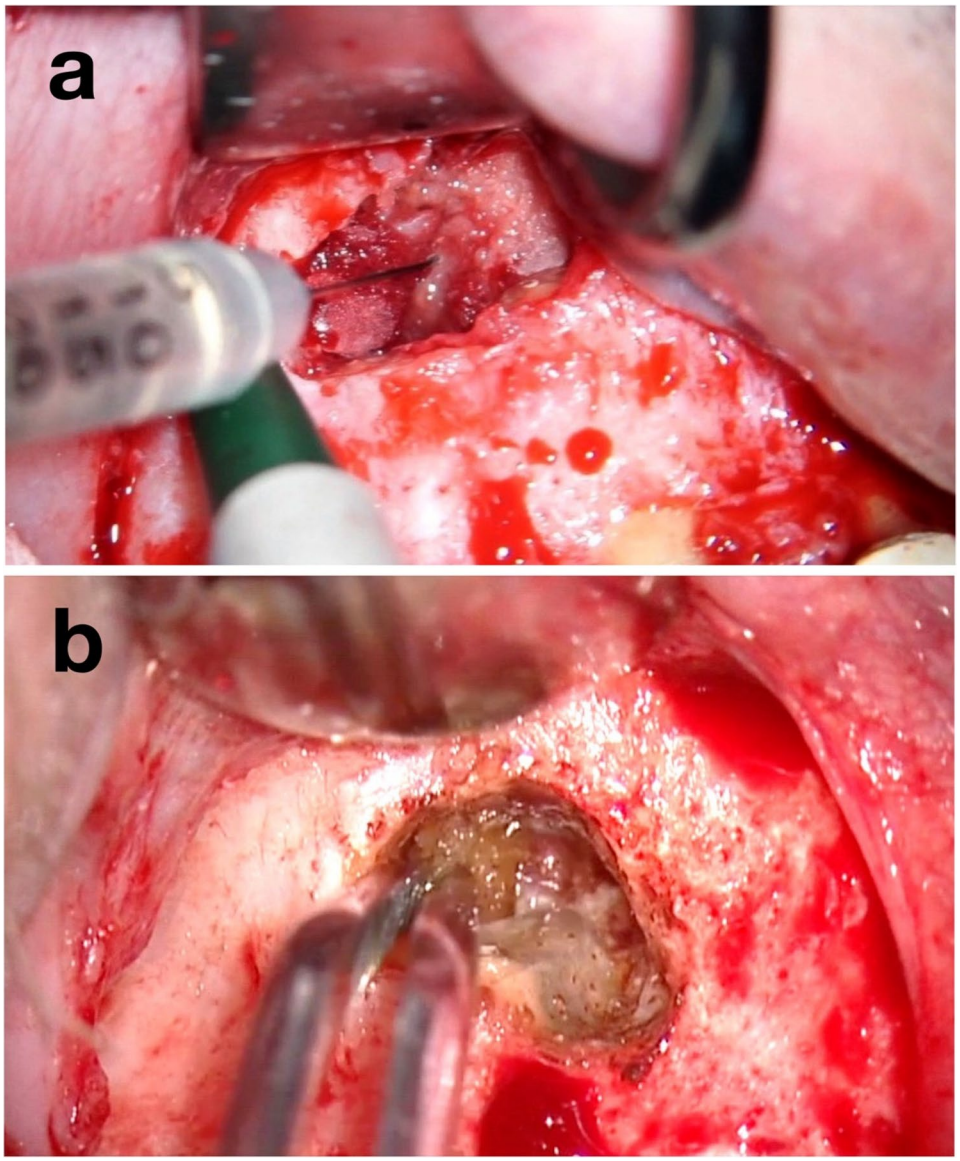

Fig. 1 The application of the surgical glue in the bone crypt with a needle (**a**) and the application of a cotton pellets soaked with ferric sulfate (**b**)

of its short setting time, moisture tolerance, well-documented long-term clinical performance in endodontic microsurgery and the operator's prior calibration with this material [1, 5, 6]. After completion of root-end filling, the surgical glue was removed by gentle mechanical detachment with a microsurgical curette followed by copious irrigation with sterile saline (approximately 20 mL), while ferric sulfate was removed by saline irrigation and curettage of the superficial layer of discoloured bone until clean cortical and medullary bone was visible. In both groups, the bone crypt was then allowed to refill with a blood clot, and the bleeding recovery was scored using the hemorrhage control score by the same three calibrated examiners and compared with the previous records. The flap was sutured with 5−0 resorbable sutures (Vicryl, Ethicon, Sankt Stefan, Switzerland). A standardized postsurgical protocol was given to the patients according to Bharathi et al. [8]: a soft, room-temperature diet for 48 h, abstention from strenuous physical activity and smoking for 7 days and chlorhexidine digluconate 0.2% mouth rinses twice daily for seven days. Postoperative analgesia consisted of ibuprofen 600 mg to be taken as needed for pain, up to a maximum of three doses per 24 h (1800 mg/day); no other analgesic was permitted and no antibiotic prophylaxis was prescribed. Patients were instructed to record each ibuprofen intake on the same diary used for pain assessment. No participant was excluded for excessive analgesic use. Sutures were removed at five days.

Outcomes

The primary outcome was the hemorrhage control score after application of the hemostatic agent (time T1). Secondary outcomes were the hemorrhage control score before application of the agent (T0, immediately after curettage of the bone lesion), the bleeding recovery score after removal of the hemostatic agent, the surgical field visibility score at T0 and T1, postoperative pain on the NRS over seven days, daily analgesic intake over seven days, the presence of postoperative swelling and the OHIP-14 questionnaire score at one week. Scores were assigned by the operator and two calibrated assistants using the criteria reported in Table 1 [8]. Cohen's kappa for inter-examiner agreement on the hemorrhage control score was 0.82 (very good agreement); discrepancies were resolved by using the median of the three independent scores.

Patient-reported oral-health-related quality of life was assessed with the Oral Health Impact Profile-14 (OHIP-14) questionnaire [8, 22]. The instrument explores seven domains (functional limitations, physical pain, psychological discomfort, physical disability, psychological disability, social disability and handicap) and the responses are graded on a 5-point Likert-like scale (1 = never, 2 = hardly ever, 3 = occasionally, 4 = fairly often, 5 = very often). Postoperative pain was assessed with the 0–10 Numerical Rating Scale (NRS), where higher values indicate greater pain; a 1-point between-group difference is conventionally regarded as the smallest clinically relevant change [23]. Patients recorded the worst pain they had experienced over each of the seven postoperative days. The same diary was used to record analgesic intake (each ibuprofen 600 mg dose) and postoperative swelling: each day, the patient indicated whether oral or facial swelling was present (binary outcome, yes/no). In addition, an extra-oral and intra-oral clinical examination at the suture-removal visit on day 5 documented any clinically detectable swelling. Patients were classified as having postoperative swelling if any self-reported or clinically detected episode occurred during the seven-day window. To minimize missing data, patients were contacted by telephone on day 1 and day 4 to verify completion of the diary and to answer queries about the forms.

Statistical analysis

Statistical analyses were performed by an independent biostatistician who was blinded to group allocation, using SPSS Statistics v.23.0 (IBM Corp, Armonk, NY, USA). The normality of continuous variables was assessed with the Shapiro–Wilk test. Between-group comparisons of categorical variables — hemorrhage control score, surgical field visibility score, presence of postoperative swelling and daily analgesic intake — were performed using Pearson's chi-square test, with Fisher's exact test applied when expected cell counts were below five. Individual OHIP-14 items were compared between groups using Fisher's exact test and the OHIP-14 summary score was compared with an independent-samples t-test. Daily NRS pain scores were compared between groups using the

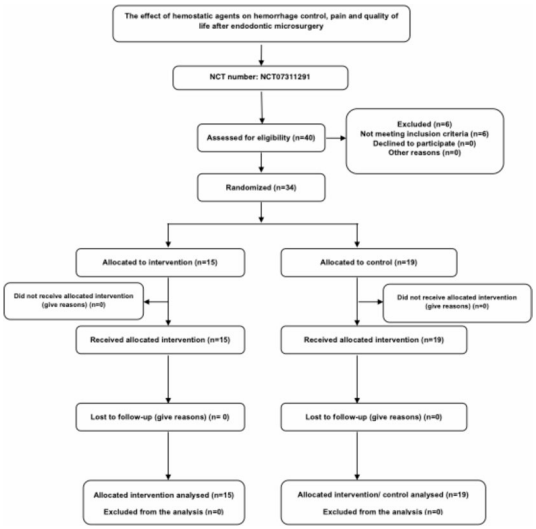

Fig. 2 CONSORT flow diagram

Table 2 Demographic data and lesion characteristics according to groups

Variable		Surgical Glue ($n=15$)	Ferric Sulfate ($n=19$)	P value
Age (yrs.) Mean ± SD		49.1 ± 6.1	51 ± 8.3	0.411
(range)		(21–75)	(23–79)	
Gender	Females	7 (46.6%)	8 (42.2%)	0.871
	Males	8 (53.4%)	11 (57.8%)	
Lesion characteristics	One cortical plate	9 (60%)	10 (52.6%)	0.712
	Two cortical plates	6 (40%)	9 (47.4%)	

Mann–Whitney U test on each postoperative day. To complement P values and facilitate interpretation of the magnitude and precision of the observed differences, absolute between-group differences with corresponding 95% confidence intervals were additionally reported for selected outcomes for which a directly interpretable contrast was available. For lesion-size variables, mean between-group differences with 95% confidence intervals were reported. For the ordinal hemorrhage-control outcome, the original comparison of the full score distribution was retained, and the proportion achieving complete hemorrhage control (score 2) was additionally summarized as an absolute between-group difference with a 95% confidence interval. Inter-examiner reliability for the hemorrhage control score was quantified using Cohen's kappa, which yielded a value of 0.82 (very good agreement). The significance level was set at $P<0.05$. All between-group analyses were unadjusted. Given the limited sample size and the resulting risk of model instability, no covariate-adjusted analysis for baseline lesion size was performed.

Results

The study followed the CONSORT guidelines, and a summary is provided in the diagram (Fig. 2). Forty subjects were enrolled in the study, and six were excluded because not meeting the inclusion criteria. Demographic data and lesions characteristics are reported in Table 2. The medullary bone surface limits in correspondence of the lesions were 74.14% and 63.37% of the cases in the surgical glue and ferric sulfate groups respectively ($P>0.05$). All the lesions presented chronic inflammatory tissue typical of periapical granuloma.

In the overall sample, no correlation was observed between lesion type (one- vs. two-walled bone defect) and the hemorrhage control score. However, the mean volume and the mean diameter of the periapical lesions were significantly greater in the surgical glue group than in the ferric sulfate group ($P=0.022$ and $P=0.031$

Table 3 Averages and standard deviations of the periapical lesion volumes and diameters in the two groups, with observed mean between-group differences and 95% confidence intervals

	Surgical glue ($n=15$)	Ferric sulfate ($n=19$)	P value	Mean difference (95% CI)
Mean CBCT lesion volume (mm^3±SD)	459±95	238±11	0.022	221 (168.2 to 273.8)
Mean lesion diameter (mm±SD)	9.12±3.75	6.02±1.4	0.031	3.10 (0.95 to 5.25)

Table 4 Analgesic consumption after treatment (number and rate of subjects recurring to analgesic therapy during the first seven days), with absolute between-group differences and 95% confidence intervals

	Prevalence of analgesic consumption (number of subjects and %)						
	Day 1	Day 2	Day 3	Day4	Day 5	Day6	Day7
Surgical glue ($n=15$)	12 (80%)	11 (73.3%)	11 (73.3%)	9 (60%)	7 (46.6%)	6 (40%)	5 (33.3%)
Ferric sulfate ($n=19$)	8 (42.1%)	8 (42.1%)	6 (31.5%)	4 (21.0%)	3 (15.7%)	2 (10.5%)	1 (5.26%)
P-value	0.022	0.031	0.043	0.039	0.042	0.045	0.048
Absolute difference, percentage points (95% CI)	37.9 (4.7 to 60.9)	31.2 (2.0 to 55.9)	41.8 (8.0 to 64.4)	38.9 (6.0 to 62.7)	30.9 (2.6 to 56.3)	29.5 (0.4 to 54.9)	28.1 (1.5 to 53.4)

respectively) (Table 3). The observed mean between-group differences were 221 mm^3 (95% CI 168.2 to 273.8) for lesion volume and 3.10 mm (95% CI 0.95 to 5.25) for lesion diameter.

Statistical analysis confirmed that there was no significant difference between the two groups regarding the bleeding control before hemostatic agent use (T0): the lesions examined after surgical curettage showed comparable degree of bleeding ($P=0.15$). Moreover, data suggested there was no significant difference between the two groups in the control of bleeding after hemostat use (T1) ($P=0.27$). At T1, complete hemorrhage control (score 2) was observed in 60.0% of patients in the surgical glue group and 52.6% in the ferric sulfate group, corresponding to an absolute difference of 7.4% points (95% CI -24.1 to 36.4). No statistically significant between-group difference was observed in surgical field visibility after application of the hemostatic agents ($P=0.092$). A clear surgical field was observed in 26.7% and 57.9% of patients, respectively, corresponding to an absolute difference of -31.2% points (95% CI -55.9 to 2.0).

Bleeding recovery scores measured immediately after removal of the hemostatic agent were significantly higher in the surgical glue group than in the ferric sulfate group ($P=0.045$): bleeding rebound was observed in 79% of cases in the surgical glue group compared with 52% in the ferric sulfate group. Based on the corresponding patient counts, the observed absolute between-group difference was approximately 27% points (95% CI 4.8 to 52.0).

In unadjusted between-group comparisons, postoperative swelling was more frequently reported in the surgical glue group ($P=0.026$), while analgesic consumption was higher in the surgical glue group ($P=0.040$) (Table 4). Absolute between-group differences in daily analgesic use, with corresponding 95% confidence intervals, are reported in Table 4 to complement the P values. Because no covariate-adjusted analysis for the baseline imbalance in lesion size was performed, these findings represent unadjusted associations and should not be interpreted as independent effects of the hemostatic agent.

Regarding the postoperative pain, an average value of the NRS scale was calculated for each day for the two groups. The curves representing the two groups showed parallel trends with values deviating not significantly ($P=0.31$) (Fig. 3a). Patient perception of the impact of hemostatic agents on overall QoL showed no significant differences between groups ($P=0.54$) (Fig. 3b).

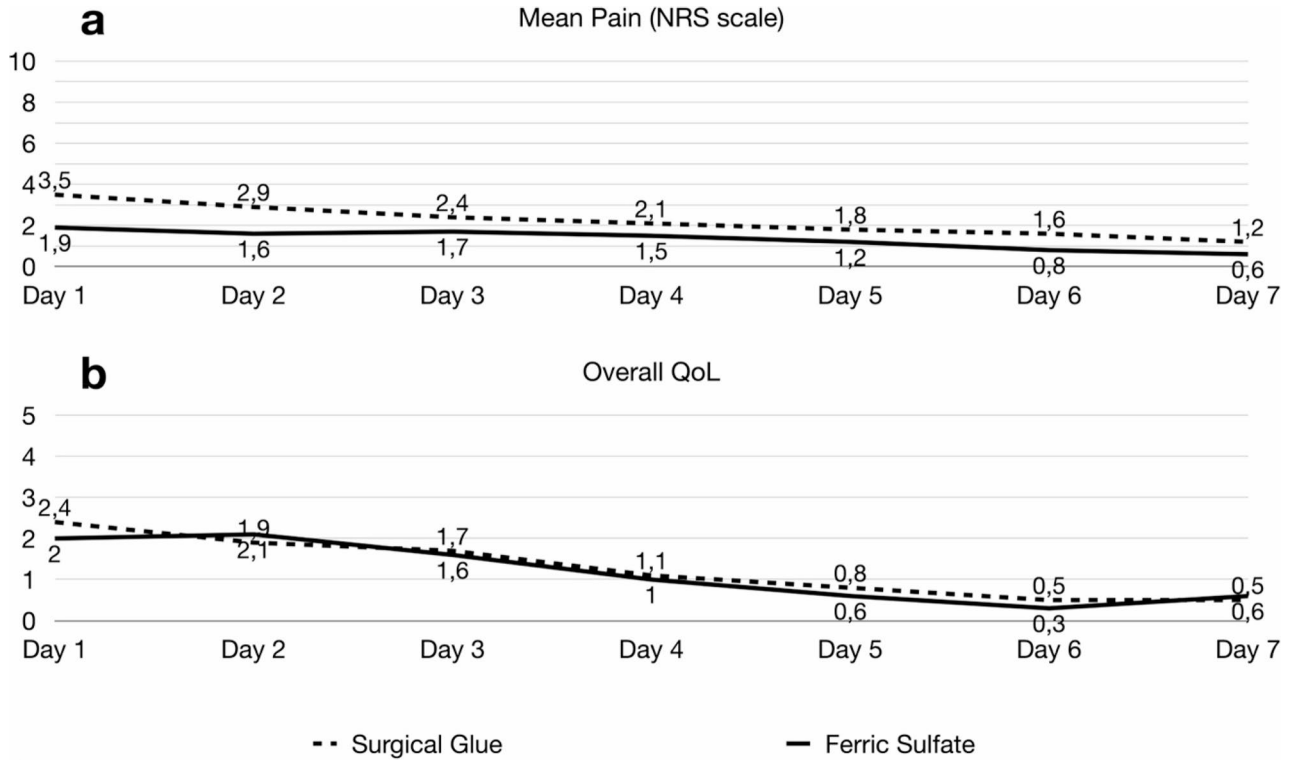

Fig. 3 The mean pain value (NRS scale) (**a**) and the overall QoL trend (**b**) for seven days after treatment in both groups

Discussion

Endodontic microsurgery relies on minimally invasive techniques and on adjunctive technologies such as the operating microscope and CBCT [5, 6]. Within this framework, adequate intra-operative haemostasis is essential to ensure visibility of the surgical field and to allow a controlled root-end filling [11, 24]. A variety of hemostatic agents has been proposed, including bone wax, collagen sponges, adrenaline-impregnated pellets and ferric sulfate [7, 11], some of which have been associated with cytotoxic effects on bone tissue, foreign-body reactions and impaired healing [7, 18]; an ideal agent — rapid, biocompatible, easy to handle and fully resorbable without interfering with bone healing — has not yet been identified. The present trial compared a N-hexyl cyanoacrylate surgical glue with ferric sulfate, the most widely used reference material in this field.

The baseline imbalance in lesion size represents an important potential confounder. As a chance finding of simple randomization in a small sample, possibly amplified by the absence of stratification by lesion size, this imbalance may have influenced bleeding recovery, postoperative swelling and analgesic intake. Accordingly, any apparent disadvantage of the surgical glue in these outcomes could, at least in part, reflect the larger lesions in that arm rather than an independent effect of the agent itself. Because a sufficiently reliable covariate-adjusted analysis was not feasible within the present sample, residual confounding by lesion size cannot be excluded. Future trials should therefore use stratified or block randomization by lesion volume and prespecified covariate-adjusted analyses to disentangle the contribution of lesion size from that of the hemostatic agent.

The comparable intraoperative haemostatic performance and surgical field visibility observed with the two agents suggest that both approaches can provide a clinically workable operative field under the conditions investigated [11]. However, these findings should be interpreted specifically in relation to short-term intraoperative performance. They do not establish equivalence between the materials and should not be extrapolated to postoperative tissue response, periapical healing or long-term surgical success. Moreover, the baseline imbalance in lesion size remains a potential source of confounding when interpreting subsequent outcomes.

The greater bleeding recovery observed after removal of the surgical glue is biologically and mechanically plausible. Ferric sulfate produces a denatured protein-blood matrix that remains physically and chemically integrated with the underlying tissue, whereas the cyanoacrylate polymer forms a discrete plug that is mechanically detached when the agent is removed, thereby re-exposing the underlying microvasculature [25, 26]. Both materials must in any case be removed from the bony crypt before suturing to optimize the postoperative prognosis [4, 26–27]. Importantly, bleeding recovery was assessed using a subjective ordinal score by examiners who were necessarily aware of the material used. This observation should therefore be interpreted primarily as a mechanically plausible consequence of the different physical behaviour and removal procedures of the two materials rather than as evidence of inferior haemostatic efficacy of the surgical glue. Its clinical relevance remains uncertain and should not be inferred from statistical significance alone. Future investigations should incorporate objective endpoints such as bleeding duration after removal, the weight of blood absorbed by standardized gauzes, or blinded photographic/video assessment.

The postoperative findings require cautious interpretation. Although differences emerged in some secondary measures of early morbidity, they were not accompanied by a consistent between-group pattern in patient-reported pain or overall oral-health-related quality of life [8, 22]. This argues against interpreting the isolated postoperative findings as evidence of a clinically meaningful overall disadvantage of either material. In particular, the baseline imbalance in lesion size is a major potential confounder, because larger periapical lesions may be associated with greater postoperative inflammation and analgesic requirements [8]. The observed differences in swelling and analgesic use may therefore reflect, at least in part, differences in lesion characteristics rather than an independent effect of the haemostatic agent. A direct pro-inflammatory effect of the cyanoacrylate cannot be established from the present data. Although preclinical studies suggest that some cyanoacrylate adhesives can induce foreign-body reactions and modulate early inflammatory responses [18, 20], no biological, histological or biomarker measurements were collected in this trial. Such a mechanism therefore remains speculative and hypothesis-generating. Adequately powered randomized trials incorporating stratification by lesion volume and objective inflammatory outcomes are required to clarify whether the surgical glue independently influences early postoperative morbidity. These findings should also not be extrapolated beyond the seven-day follow-up period investigated.

From a clinical perspective, the choice of a haemostatic agent is likely to depend on the characteristics of the surgical field. Ferric sulfate permits focal application and intimate contact with the bleeding bone surface, whereas bulk polymerization of cyanoacrylate may offer a practical haemostatic barrier when bleeding is more diffuse [1, 11, 25, 26]. However, the present trial does not establish lesion size as an indication for selecting one material over the other, because the larger lesions in the surgical-glue arm resulted from baseline imbalance rather than prespecified stratification. Any lesion-specific advantage should therefore be considered hypothesis-generating and tested prospectively in trials stratified by lesion volume.

The present study has several limitations. First, the sample-size calculation was based on postoperative NRS pain rather than on the primary haemostatic endpoint. At the study-design stage, postoperative pain was selected because a quantitative estimate of variability was available from a comparable endodontic microsurgery study, whereas no appropriate variance or effect-size estimate was available for the ordinal hemorrhage-control score for the specific comparison investigated here. Nevertheless, basing the sample-size calculation on a secondary patient-reported outcome rather than on the primary haemostatic endpoint represents an important methodological limitation. The study may therefore have been insufficiently powered to detect clinically relevant between-group differences in hemorrhage control, and its comparative efficacy estimates should be interpreted as hypothesis-generating. The limited sample size also reduces the precision of estimates for secondary outcomes. Importantly, the seven-day observation period of the present study was designed to capture intraoperative performance and early postoperative morbidity and therefore does not provide information on periapical bone healing, late complications, radiographic healing, or long-term surgical success. Recent evidence from Lu et al., who evaluated through-and-through periapical lesions after endodontic microsurgery using both two-dimensional radiographic criteria and three-dimensional CBCT assessment over a minimum follow-up of 24 months, further highlights the

importance of lesion characteristics and of long-term, three-dimensional assessment of periapical regeneration [29]. Their findings also illustrate the additional information provided by CBCT-based evaluation of bone healing compared with conventional two-dimensional radiographic assessment. This is particularly relevant to the present study, in which baseline lesion volume differed significantly between groups and was assessed preoperatively using CBCT. Accordingly, the comparable intraoperative haemostatic performance observed in the present study should not be interpreted as evidence of equivalence between the two materials with respect to long-term periapical healing. Future trials should therefore incorporate longer clinical and radiographic follow-up, preferably including three-dimensional CBCT-based assessment of lesion healing and volumetric bone regeneration.

The haemostatic outcomes are intrinsically subjective, and, despite operator calibration and good inter-examiner agreement, the absence of operator blinding may have introduced assessment bias. The primary endpoint relied on subjective ordinal assessment and examiners could not be blinded at T1 because of material appearance. Future studies should incorporate adjusted analysis, blinded photographic or video assessment and, where feasible, quantitative measures such as bleeding duration or the weight of absorbent materials. Postoperative swelling was recorded as a binary present/absent outcome supplemented by a single clinical examination at suture removal, which is less informative than three-dimensional volumetric assessment. The baseline imbalance in lesion volume, together with the absence of a sufficiently reliable covariate-adjusted analysis, leaves residual confounding that should be addressed in future trials through stratified randomization and prespecified adjusted analyses. An additional methodological limitation is the retrospective registration of the trial. Although the outcomes reported in the present study correspond to those defined in the ethics-approved protocol and no protocol changes were introduced after enrolment began, registration occurred after the start of patient recruitment. Retrospective registration provides less assurance regarding the transparency of prespecified outcomes and analyses than prospective registration and should therefore be considered when interpreting the present findings. Larger, prospectively registered, stratified randomized trials are needed to validate the present observations.

Conclusions

Within the limitations of this randomized clinical trial, N-hexyl cyanoacrylate surgical glue and ferric sulfate provided comparable intraoperative haemostatic performance during endodontic microsurgery. The greater bleeding recovery observed after glue removal may reflect the different physical behaviour and removal procedures of the materials and should not be interpreted as evidence of inferior haemostatic efficacy. Differences in selected secondary postoperative outcomes cannot be attributed independently to the haemostatic agent because of the baseline imbalance in lesion size and the absence of a sufficiently reliable, adjusted analysis. Overall, the findings do not establish a clinically meaningful advantage or disadvantage of either material and should be regarded as hypothesis-generating. Larger, prospectively registered trials adequately powered for the primary haemostatic endpoint, stratified by lesion size and incorporating objective outcome assessment and longer-term follow-up are required.

Abbreviations

ASA	American society of anaesthesiologists
CONSORT	CONsolidated standards of reporting trials
NRS	Numerical rating scale
OH-QoL	Oral health related quality of life
PRIRATE	Preferred reporting items for randomized trials in endodontics
QoL	Quality of life
VAS	Visual analogue scale
CBCT	Cone beam computed tomography

FOV	Field of view
MTA	Mineral trioxide aggregate
OHIP-14	Oral health impact profile-14
super-EBA	Super ethoxybenzoic acid

Supplementary Information The online version contains supplementary material available at https://doi.org/10.1186/s12903-026-09884-1.

Acknowledgements For the development of this study no funds have been received.

Authors' contributions Conceptualization: M.A, D.P. Methodology: A.C, A.B, S.O, L.G., V.F. Software: N.S., A.B, A.B., V.F. Validation: M.A., D.P., L.G. Formal Analysis: A.B., V.F., S.O., A.C. Investigation: S.O., A.B., A.B., M.A. Resources: D.P, M.A., L.G. Data curation: V.F., A.C., S.O., A.B. Writing-original draft preparation: S.O., V.F., L.G., A.B Writing-review and editing: M.A., D.P., A.C., N.S. Visualization: N.S., A.C., M.A., L.G. Supervision: D.P. Project administration: N.S., D.P., M.A., L.G., A.C. Funding acquisition: NA.

Funding No funding.

Data availability The datasets used and/or analyzed during the current study are available from the corresponding author on reasonable request.

Declarations

Ethics approval and consent to participate This randomized controlled clinical trial was approved by the local Ethics Committee and Institutional Review Board (Protocol ID: 0272/2023). All participants provided written informed consent before enrolment. The trial was registered at ClinicalTrials.gov on 20 November 2025 (NCT07311291); registration was retrospective with respect to the start of recruitment in November 2023, as detailed in the Methods section. The manuscript was prepared in accordance with the CONSORT 2010 statement and the PRIRATE 2020 guidelines [21].

Consent for publication Not applicable.

Competing interests The Authors declare no competing conflict of interests with the materials discussed in this manuscript.

Open Access This article is licensed under a Creative Commons Attribution-NonCommercial-NoDerivatives 4.0 International License, which permits any non-commercial use, sharing, distribution and reproduction in any medium or format, as long as you give appropriate credit to the original author(s) and the source, provide a link to the Creative Commons licence, and indicate if you modified the licensed material. You do not have permission under this licence to share adapted material derived from this article or parts of it. The images or other third party material in this article are included in the article's Creative Commons licence, unless indicated otherwise in a credit line to the material. If material is not included in the article's Creative Commons licence and your intended use is not permitted by statutory regulation or exceeds the permitted use, you will need to obtain permission directly from the copyright holder. To view a copy of this licence, visit http://creativecommons.org/licenses/by-nc-nd/4.0/.

References

1. Setzer FC, Kratchman SI. Present status and future directions: Surgical endodontics. Int Endod J. 2022;55:1020–58. https://doi.org/10.1111/iej.13783.
2. Kim S, Kratchman S. Modern endodontic surgery concepts and practice: a review. J Endod. 2006;32(7):601–23. https://doi.org/10.1016/j.joen.2005.12.010.
3. Lavasani SA, Tyler C, Roach SH, McClanahan SB, Ahmad M, Bowles WR. Cone-beam Computed Tomography: Anatomic Analysis of Maxillary Posterior Teeth-Impact on Endodontic Microsurgery. J Endod. 2016;42(6):890–5. https://doi.org/10.1016/j.joen.2016.03.002.
4. Pallarés-Serrano A, Glera-Suarez P, Tarazona-Alvarez B, Peñarrocha-Oltra D, Peñar-rocha-Diago M, Peñarrocha-Diago M. Healing of 295 Endodontic Microsurgery Cases After Long-Term (5–9 Years) Versus Middle-Term (1–4 Years) Follow-up. J Endod. 2022;48(6):714–21. https://doi.org/10.1016/j.joen.2022.03.001.

5. Setzer FC, Shah SB, Kohli MR, Karabucak B, Kim S. Outcome of endodontic surgery: a meta-analysis of the literature–part 1: Comparison of traditional root-end surgery and endodontic microsurgery. J Endod. 2010;36(11):1757–65. https://doi.org/10.1016/j.joen.2010.08.007.
6. Setzer FC, Kohli MR, Shah SB, Karabucak B, Kim S. Outcome of endodontic surgery: a meta-analysis of the literature–Part 2: Comparison of endodontic microsurgical techniques with and without the use of higher magnification. J Endod. 2012;38(1):1–10. https://doi.org/10.1016/j.joen.2011.09.021.
7. Peñarrocha-Oltra D, Soto-Peñaloza D, Peñarrocha-Diago M, Cervera-Ballester J, Cabanes-Gumbau G, Peñarrocha-Diago M. Hemostatic agents in endodontic surgery of maxillary molars: A randomized controlled pilot study of polytetrafluoroethylene (PTFE) strips as an adjunct to epinephrine impregnated gauze versus aluminum chloride. Med Oral Patol Oral Cir Bucal. 2020;25(5):e634-e643. Published 2020 Sep 1. https://doi.org/10.4317/medoral.23652.
8. Bharathi J, Mittal S, Tewari S, et al. Effect of the Piezoelectric Device on Intraoperative Hemorrhage Control and Quality of Life after Endodontic Microsurgery: A Random-ized Clinical Study. J Endod. 2021;47(7):1052–60. https://doi.org/10.1016/j.joen.2021.04.013.
9. Chong BS, Rhodes JS. Endodontic surgery. Br Dent J. 2014;216(6):281–90. https://doi.org/10.1038/sj.bdj.2014.220.
10. Tsesis I, Rosen E, Taschieri S, Telishevsky Strauss Y, Ceresoli V, Del Fabbro M. Outcomes of surgical endodontic treatment performed by a modern technique: an updated meta-analysis of the literature. J Endod. 2013;39(3):332–9. https://doi.org/10.1016/j.joen.2012.11.044.
11. Khater AGA, Al-Hamed FS, Safwat EM, Hamouda MMA, Shehata MSA, Scarano a. Efficacy of hemostatic agents in endodontic surgery: a systematic review and network meta-analysis. J Evid Based Dent Pract. 2021;21(3):101540. https://doi.org/10.1016/j.jebdp.2021.101540.
12. von Arx T, Jensen SS, Hänni S, Schenk RK. Haemostatic agents used in periradicular surgery: an experimental study of their efficacy and tissue reactions. Int Endod J. 2006;39(10):800–8. https://doi.org/10.1111/j.1365-2591.2006.01152.x.
13. Bellón JM, Fernández-Gutiérrez M, Rodríguez M, et al. Bioassay of cyanoacrylate tissue adhesives used for intraperitoneal mesh fixation. J Biomed Mater Res B Appl Biomater. 2017;105(2):312–9. https://doi.org/10.1002/jbm.b.33558.
14. Kang R, Li H, Lysdahl H, et al. Cyanoacrylate medical glue application in intervertebral disc annulus defect repair: Mechanical and biocompatible evaluation. J Biomed Mater Res B Appl Biomater. 2017;105(1):14–20. https://doi.org/10.1002/jbm.b.33524.
15. Mahardawi B, Jiaranuchart S, Rochanavibhata S, Siriwat K, Mattheos N, Pimkhao-kham A. Cyanoacrylate tissue adhesive versus silk sutures for mandibular third molar surgery: a systematic review and meta-analysis. Clin Oral Investig. 2024;28(3):180. https://doi.org/10.1007/s00784-024-05578-6. Published 2024 Feb 29.
16. Gümüş P, Buduneli E. Graft stabilization with cyanoacrylate decreases shrinkage of free gingival grafts. Aust Dent J. 2014;59(1):57–64. https://doi.org/10.1111/adj.12149.
17. Kulkarni S, Dodwad V, Chava V. Healing of periodontal flaps when closed with silk sutures and N-butyl cyanoacrylate: a clinical and histological study. Indian J Dent Res. 2007;18(2):72–7. https://doi.org/10.4103/0970-9290.32424.
18. Lee YJ, Jung GB, Choi S, et al. Biocompatibility of a novel cyanoacrylate based tissue adhesive: cytotoxicity and biochemical property evaluation. PLoS ONE. 2013;8(11):e79761. https://doi.org/10.1371/journal.pone.0079761. Published 2013 Nov 22.
19. Borie E, Rosas E, Kuramochi G, Etcheberry S, Olate S, Weber B. Oral Applications of Cyanoacrylate Adhesives: A Literature Review. Biomed Res Int. 2019;2019:8217602. https://doi.org/10.1155/2019/8217602. Published 2019 Mar 17.
20. Pascual G, Sotomayor S, Rodríguez M, et al. Cytotoxicity of Cyanoacrylate-Based Tissue Adhesives and Short-Term Preclinical In Vivo Biocompatibility in Abdominal Hernia Repair. PLoS ONE. 2016;11(6):e0157920. https://doi.org/10.1371/journal.pone.0157920. Published 2016 Jun 20.
21. Nagendrababu V, Duncan HF, Bjørndal L, Kvist T, Priya E, Jayaraman J, Pulikkotil SJ, Pigg M, Rechenberg DK, Vaeth M, Dummer PMH. PRIRATE 2020 guidelines for reporting randomized trials in Endodontics: a consensus-based development. Int Endod J. 2020;53(6):764–73. https://doi.org/10.1111/iej.13294.
22. Del Fabbro M, Taschieri S, Weinstein R. Quality of life after microscopic periradicular surgery using two different incision techniques: a randomized clinical study. Int Endod J. 2009;42(4):360–7. https://doi.org/10.1111/j.1365-2591.2008.01534.x.
23. Ghabraei S, Afkhami F, Kiafar MM, Kharazifard MJ, Peters OA. Effect of intracanal cryotherapy on post-operative pain in single-visit endodontic retreatment: a randomized clinical trial. BMC Oral Health. 2024;24(1):1539. https://doi.org/10.1186/s12903-024-05249-8 . PMID: 39710651; PMCID: PMC11663323.
24. Niemczyk SP. Essentials of endodontic microsurgery. Dent Clin North Am. 2010;54(2):375–99. https://doi.org/10.1016/j.cden.2009.12.002.
25. Scarano A, Artese L, Piattelli A, Carinci F, Mancino C, Iezzi G. Hemostasis control in endodontic surgery: a comparative study of calcium sulfate versus gauzes and versus ferric sulfate. J Endod. 2012;38(1):20–3. https://doi.org/10.1016/j.joen.2011.09.019.
26. Lemon RR, Steele PJ, Jeansonne BG. Ferric sulfate hemostasis: effect on osseous wound healing. Left in situ for maximum exposure. J Endod. 1993;19(4):170–3. https://doi.org/10.1016/s0099-2399(06)80681-3.

27. Azargoon H, Williams BJ, Solomon ES, Kessler HP, He J, Spears R. Assessment of hemostatic efficacy and osseous wound healing using HemCon dental dressing. J Endod. 2011;37(6):807–11. https://doi.org/10.1016/j.joen.2011.02.023.
28. Iqbal MK, Kim S. A review of factors influencing treatment planning decisions of single-tooth implants versus preserving natural teeth with nonsurgical endodontic therapy. J Endod. 2008;34(5):519–29. https://doi.org/10.1016/j.joen.2008.01.002.
29. Lu L, Xu K, Shen Y, Liu H. Two- and three-dimensional evaluation of endodontic microsurgery outcomes in maxillary anterior teeth with through-and-through lesions: a retrospective cohort study. BMC Oral Health. 2026;26(1):220. https://doi.org/10.1186/s12903-025-07614-7.

Publisher's note Springer Nature remains neutral with regard to jurisdictional claims in published maps and institutional affiliations.

Authors and Affiliations

Mario Alovisi[1] · Lia Giordano[1] · Vittorio Fenoglio[1] · Sofia Oricco[1] · Alice Balocco[1] · Andrea Baldi[1] · Allegra Comba[1] · Nicola Scotti[1] · Damiano Pasqualini[1]

✉ Mario Alovisi
mario.alovisi@unito.it

[1] Department of Surgical Sciences, Dental School, University of Turin, Endodontics, via Nizza, Turin 230–10126 , Italy