POLITECNICO DI TORINO
Repository ISTITUZIONALE

Comparison between Bone-Level and Tissue-Level Implants in Immediate-Loading Full-Arch Rehabilitations: A Retrospective Multi-Center 1-Year Follow-Up Study

Original
Comparison between Bone-Level and Tissue-Level Implants in Immediate-Loading Full-Arch Rehabilitations: A Retrospective Multi-Center 1-Year Follow-Up Study / Pera, F., Carossa, M., Bagnasco, F., Crupi, A., Ambrogio, G., Isola, G., Menini, M., Pesce, P.. - In: PROSTHESIS. - ISSN 2673-1592. - 5:4(2023), pp. 1301-1311. [10.3390/prosthesis5040089]

Availability:
This version is available at: 11583/3013533 since: 2026-07-25T14:20:04Z

Publisher:
Multidisciplinary Digital Publishing Institute (MDPI)

Published
DOI:10.3390/prosthesis5040089

Terms of use:

This article is made available under terms and conditions as specified in the corresponding bibliographic description in the repository

Publisher copyright

(Article begins on next page)

25 November 2026

prosthesis

MDPI

Article

Comparison between Bone-Level and Tissue-Level Implants in Immediate-Loading Full-Arch Rehabilitations: A Retrospective Multi-Center 1-Year Follow-Up Study

Francesco Pera [1,†], Massimo Carossa [1,*,†], Francesco Bagnasco [2], Armando Crupi [1], Giulia Ambrogio [1], Gaetano Isola [3], Maria Menini [2,‡] and Paolo Pesce [2,‡]

[1] Department of Surgical Sciences, C.I.R. Dental School, University of Turin, 10126 Turin, Italy
[2] Department of Surgical Sciences (DISC), University of Genoa, 16132 Genoa, Italy
[3] Unit of Periodontology, Department of General Surgery and Surgical-Medical Specialties, University of Catania, 95124 Catania, Italy
* Correspondence: massimo.carossa@unito.it
† These authors contributed equally to this work.
‡ These authors also contributed equally to this work.

Abstract: The objective of the present retrospective multi-center study was to analyze the outcomes of bone-level (BL) implants and tissue-level (TL) implants in immediate-loading full-arch rehabilitations. Patients who were previously rehabilitated with full-arch immediate-loading rehabilitations with either BL or TL implants were considered. Data regarding implant survival rate, marginal bone loss (MBL), peri-implant probing depth (PPD), plaque index (PI), and bleeding on probing (BOP) were recorded, and the 1-year follow-up data were statistically analyzed between the two groups. In total, 38 patients were evaluated for a total implant number of 156 (n = 80 TL implants and n = 76 BL implants). An implant survival rate of 97.37% was recoded for the BL group while an implant survival rate of 100% was noted for the TL group. A total MBL of 1.324 ± 0.64 mm was recorded for BL implants, while a total MBL of 1.194 ± 0.30 mm was recorded for TL implants. A statistically significant difference was highlighted regarding MBL at the mesial aspect ($p = 0.01552$) of the implants, with BL implants presenting with higher MBL. Within the range of acceptable healthy values, a statistically significant difference was also highlighted regarding BOP ($p < 0.00001$), with TL implants presenting higher values. No statistically significant difference ($p > 0.05$) was recorded for any of the other variables analyzed. Within the limitations of the present retrospective study, both TL and BL implants seem to provide good clinical outcomes after a 12-month observational period when employed in immediate-loading full-arch rehabilitation.

Keywords: dental implants; immediate loading; full-arch; bone-level; tissue-level; abutments

check for updates

Citation: Pera, F.; Carossa, M.; Bagnasco, F.; Crupi, A.; Ambrogio, G.; Isola, G.; Menini, M.; Pesce, P. Comparison between Bone-Level and Tissue-Level Implants in Immediate-Loading Full-Arch Rehabilitations: A Retrospective Multi-Center 1-Year Follow-Up Study. *Prosthesis* **2023**, *5*, 1301–1311. https://doi.org/10.3390/prosthesis5040089

Academic Editor: Kelvin Ian Afrashtehfar

Received: 10 October 2023
Revised: 25 November 2023
Accepted: 28 November 2023
Published: 30 November 2023

Copyright: © 2023 by the authors. Licensee MDPI, Basel, Switzerland. This article is an open access article distributed under the terms and conditions of the Creative Commons Attribution (CC BY) license (https://creativecommons.org/licenses/by/4.0/).

1. Introduction

Nowadays, immediate-loading full-arch implant rehabilitation represents the elective treatment plan for the fixed rehabilitation of patients suffering from edentulism or with residual terminal dentition [1], offering them a transformative solution with profound implications for both their oral health and quality of life [2–4]. Unlike traditional delayed implant techniques that involve prolonged waiting periods, immediate-loading full-arch implant rehabilitation allows for the insertion of dental implants and rehabilitation with a fixed full-arch prostheses within 24–48 h after surgery [5,6]. This groundbreaking approach not only provides patients with an immediate restoration of their smile and oral function but also significantly reduces treatment time. However, despite high long-term survival rates [1,5], complications continue to be undesirable events [7–9], and therefore, research on the topic remains prominent.

Traditionally, implants were initially proposed in the morphology of Branemark implants as bone-level (BL) implants presenting an external connection [10]. This connection

has been widely used and studied [11,12]. It is reported to present different advantages, such as an optimal passive-fit with the prosthesis [13] and better management facility in case of multiple implants [14]. However, over the years, some criticism has been raised, linked to the fact that this connection type may exhibit slight micro-movements between components, potentially affecting long-term stability [15,16] and increasing the risk of complications such as screw loosening and bacterial micro-leakage [17].

To avoid these possible complications, internal connections, also commonly adopted as BL implants, were later introduced, aiming to improve the implant–prosthetic mechanical stability by minimizing micro-movements between the implant components [18]. This stability was reported to be particularly crucial in full-arch rehabilitations where multiple implants need to work together to distribute the load effectively [14]. Furthermore, the internal connection led to the development of the platform switching concept [19] in which decreasing the diameter of the abutment in relation to the connection diameter provides increased space for the peri-implant soft tissue. As a consequence, the sealing around the implant's neck is improved, with the goal to better preserve the marginal bone level [19].

To date, different articles have investigated and compared the usage of BL implants with external and internal connections in immediate-loading full-arch rehabilitation [20,21]. Menini et al. [20] and Pera et al. [21] followed for 1 year and 3 years of follow-up, respectively, 20 full-arch rehabilitations supported by internal or external connections. According to their findings, no variations in the peri-implant soft and hard tissue were highlighted between the two connection designs, and therefore, both the designs can be considered clinically reliable for this type of rehabilitation.

Furthermore, another implant design called tissue-level (TL) implant with a convergent collar was introduced in contrast to the above-mentioned traditional BL implants [22,23]. Unlike their BL counterparts, where the most coronal part of the implant is positioned at the bone level, TL implants are characterized by their collar, which emerges at or just above the level of the mucosal tissues. Therefore, this implant design is composed altogether by the implant body that is placed into the bone and by the collar that serves as a trans-mucosal component. Among its advantages, this implant design is reported to avoid the presence of possible micro-gaps in the trans-mucosal area [24] and to increase soft tissue sealing, minimizing irritation and inflammation of the surrounding gums while promoting healthy soft tissue integration and long-term stability [23]. The increased soft tissue sealing is obtained by moving the prosthetic platform at the coronal level of the soft tissue and, therefore, the possible damages of the tissues during the prosthetic procedures are avoided [24]

Currently, few articles are available on the employment of TL implants in immediate-loading full-arch rehabilitations [24,25]. According to the available results, this implant design appears to be a viable option, even for the rehabilitation of fully edentulous patients.

However, to the authors knowledges, while different articles compared TL implants and BL implants in single- [23,26] and multi-unit [27] rehabilitations, no previous articles are available comparing these two implant designs in immediate-loading full-arch rehabilitations.

Therefore, the first objective of the present article was to retrospectively compare the outcomes of BL implants and TL implants in immediate-loading full-arch rehabilitations. The second objective was to analyze possible factors influencing marginal bone loss (MBL) including implant diameters and lengths, type of abutment, jaw distribution, and implant inclination. The first null hypothesis was that no clinical outcome differences are present between the two implant designs. The second null hypothesis was that no differences in MBL exist between the different subgroups analyzed in the study.

2. Materials and Methods

Patients who were previously rehabilitated with full-arch immediate-loading rehabilitation with either BL or TL implants at the University of Turin and University of Genoa were evaluated for the present study at the 1-year follow-up. The present research was performed following the Declaration of Helsinki. All the participants signed an informed consent form. The present study was approved by the local ethical committee of the University of Genoa (protocol n. 527) and of the University of Turin (protocol n. 0130929). The

present study was reported following the Strengthening the Reporting of Observational Studies in Epidemiology (STROBE) guidelines.

2.1. Patient Selection

All the patients initially presented with residual dentition with unfavorable prognosis, either in the mandibular or in the maxilla, and were seeking immediate fixed rehabilitations. Bone availability was evaluated based on ortopantomography and Tc cone beam. After the clinical and radiological evaluation, patients who were found eligible were then rehabilitated with an immediate-loading implant-supported full-arch rehabilitation.

Patients who met the following inclusion/exclusion criteria were enrolled in the present study.

Inclusion criteria: Age $\geq$ 18 years; previously rehabilitated with immediate-loading full-arch rehabilitation with BL or TL implants; systemically healthy. Exclusion criteria: smokers; requirement of bone regeneration procedures; presence of diabetes; intake of drugs that could possibly interfere with bone remodeling and healing; previous radiotherapy of head and neck area; inability to attend the control visit.

2.2. Study Design

Firstly, implants were divided into two primary groups based on the division between BL implants (Group 1) and TL implants (Group 2).

Secondly, macro-topography of the implants—including implant length and diameter—jaw distribution (mandible vs. maxilla), implant inclination (tilted vs. axial), and abutment type with different inclinations were considered as subgroups.

2.3. Surgery Procedures

The workflow adopted (Columbus Bridge Protocol, CBP), including the surgical and prosthetic aspects, is reported in detail in previously published articles [5].

All the surgeries were performed by two experienced surgeons (one per center) specialized in implant surgery. Patients underwent professional oral hygiene on the day prior to surgery, including scaling and root planing to decrease the bacterial load of the mouth. Pre-operative antibiotic coverage with Amoxicillina 875 mg + Clavulanic acid 125 mg every 12 h for 6 days was prescribed [28,29], beginning one day before the surgery appointment. Chlorhexidina digluconate solution was provided to the patient to rinse for one minute prior to start the surgery.

A dose of 4% articaine with 1:10.000 adrenaline (Alfacaina SP; Dentsply Italy, Rome, Italy) was used to locally perform anesthesia. Patients who presented with residual terminal dentition underwent teeth extractions, and residual sockets were carefully debrided. A full thickness mucoperiostal flap was elevated. Four to six implants, based on the bone availability, were then inserted. Implant sites were prepared with dedicated drills following the manufacturer's instructions. BL implants (Syra or Shelta implants, Sweden & Martina, Due Carrare, Padova, Italy) or TL implants (Prama, Sweden & Martina, Due Carrare, Padova, Italy) were used (Figure 1).

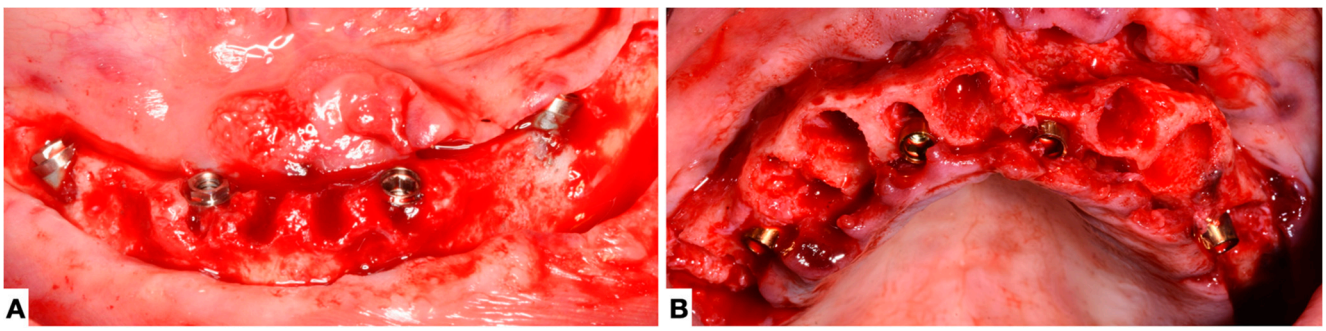

Figure 1. Clinical images after the surgical insertion of the implants: (**A**) bone-level implants; (**B**) tissue-level implants.

The two frontal implants were inserted straight, and the two posterior implants were tilted when necessary to avert the anatomical boundaries (alveolar nerve and sinus) following the CBP [5]. The length and diameter of the inserted implants were decided according to the bone availability evaluated on X-rays (ortopantomography and Tc cone beam) acquired prior to the surgery. BL implants were all connected to either straight or angulated abutments (PAD, Sweden & Martina, Due Carrare, Padova, Italy), while TL implants were connected to angulated abutments (PAD 330-303, Sweden & Martina, Due Carrare, Padova, Italy) in the posterior tilted implants and left with no abutment in the frontal straight implants (Figure 2).

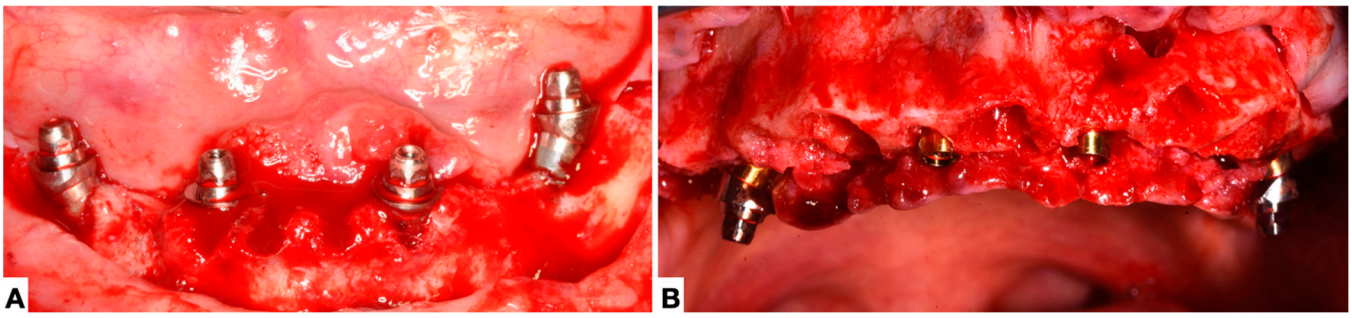

Figure 2. Clinical images after insertion of the abutments. (**A**) Bone-level implants; the two posterior tilted implants are linked to angulated abutments, while the two straight frontal ones are linked to straight abutments. (**B**) Tissue-level implants; the two posterior tilted implants are linked to angulated abutments, while the two straight frontal ones are left without abutments.

Sutures were made using silk multifilament (PERMA-HAND SILK 4-0, Ethicon, Somerville, NJ, USA). Impressions were made using open tray and impression plaster (BF-Plaster Dental, Turin, Italy). Post-operative instructions including soft diet and hygienic instructions were provided to the patients. Provisional screw-retained full-arch prosthesis made of resin with a metal framework was delivered to the patients within 24–48 h after the surgery. Peri-apical X-rays were acquired. Patients returned for suture removal one week after the surgery (Figure 3).

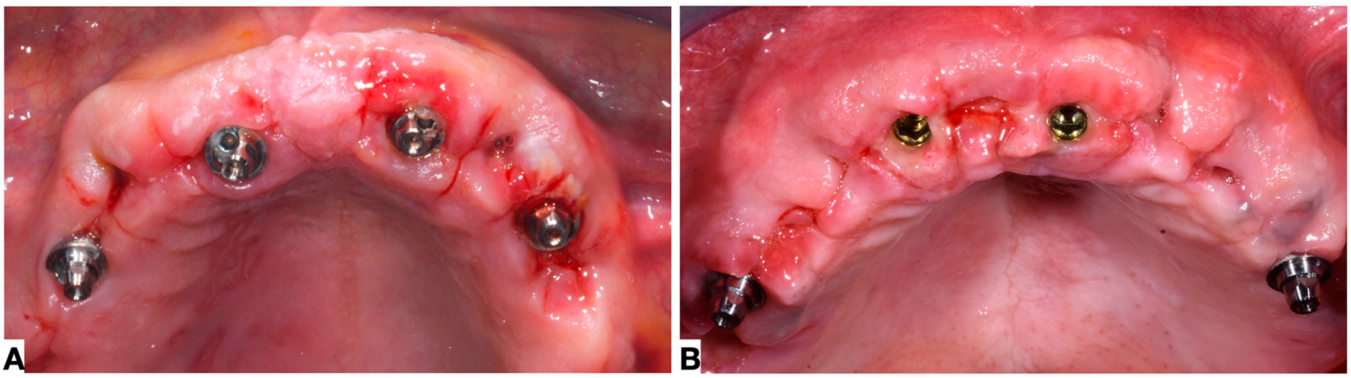

Figure 3. Clinical images at the sutures removal appointment one week after the surgery: (**A**) bone-level implants; (**B**) tissue-level implants.

Six months after the surgery, a new analogic impression (open-tray) was taken, and final composite with metal framework screw-retained prostheses was then fabricated and delivered. Patients were then evaluated for the present study 12 months after surgery and follow-up periapical X-rays were acquired.

2.4. Outcomes

The following clinical outcomes were considered:

- Implant survival rate;
- MBL assessed 12-months after surgery (T12). Digital intraoral periapical radiographs acquired using the parallel approach were used to assess MBL following the methods described in previous published articles [30,31]. The bone level was calculated as the distance between the head of the implant and the most coronal bone at both the mesial and distal aspect of the implants. Both the X-rays taken immediately following surgery (T0) and the ones taken at T12 were used. The MBL resulted as difference between T12 and T0;
- Plaque index (PI), peri-implant probing depth (PPD), and bleeding on probing (BOP) were evaluated as peri-implant soft tissue parameters at the 12-month follow-up. A periodontal UNC 15 probe (Hu-Friedy, Chicago, IL, USA) was used to measure PI, PD, and BI at 4 locations for each implant. PI and BOP were expressed as number of surfaces per implant presented with plaque or bleeding.

All the measurements were performed by two calibrated and trained clinicians per center.

2.5. Statistical Analysis

Data regarding MBL, PPD, BOP, and PI were analyzed to investigate any differences between the two groups (BL and TL implants). T-test for independent means was used to compare variables that were normally distributed. For all the other variables that did not meet the requirement of normal distribution, the Mann–Whitney *U* nonparametric test was adopted. All the subgroups were then analyzed to investigate any differences in MBL among them, both within and between the primary groups. Results were considered statistically significant with $p < 0.05$. All analyses were performed using SAS Software version 9.4 (SAS Institute Inc., Cary, NC, USA).

3. Results

A total of 38 (n = 38) patients (mean age at the control visit 62.9 years, 24 males 63.16%) were recalled for a total implant number of 156 (n = 156). Of these, 80 implants (n = 80) were TL implants, while 76 were BL implants (n = 76). Ten patients were rehabilitated at the University of Genova, and twenty-eight patients were rehabilitated at the University of Turin. Two posterior BL implants failed within the first six months. The failure was ascribed to insufficient osseointegration. Therefore, a total of 154 implants (n = 154) were considered at the 12-month follow-up (n = 80 TL implants and n = 74 BL implants). An implant survival rate of 97.37% was recoded for the BL group, while an implant survival rate of 100% was recorded for the TL one.

A total MBL of 1.324 ± 0.64 mm (mesial 1.412 ± 0.75 mm and distal 1.264 ± 0.81) was recorded for BL implants, while a total MBL of 1.194 ± 0.30 mm (mesial 1.165 ± 0.38 mm and distal 1.222 ± 0.37 mm) was noted for TL implants. Table 1 reports mean ± standard deviation and statistical results in regard to MBL, PPD, BOP, and PI between BL and TL implants.

A statistically significant difference was recorded in regard to MBL at the mesial aspect of the implants ($p = 0.01552$) with BL implants presenting with a statistically higher MBL compared to TL implants. A statistically significant difference was also highlighted regarding BOP ($p < 0.00001$) with TL implants presenting with higher BOP values. No statistical significance different ($p > 0.05$) was recorded for any of the other variables analyzed.

Table 2 shows the distribution and analysis of the total MBL between the subgroups (abutment type, implant inclination, jaw distribution, lengths and diameters) for both BL and TL groups.

Table 1. The table shows the analysis of the findings for each variable among the two groups (BL and TL implants). *T*-test for independent means was adopted for Distal MBL, Total MBL, and PPD since they were normally distributed. For all the other variables which did not meet the requirement of normally distribution, the Mann–Whitney *U* nonparametric test was adopted. Significant statistical differences are highlighted with *.

Bone-Level/ Tissue-Level	Variable	Mean (mm)	Standard Deviation	*p*-Value
BL TL	Mesial MBL	1.412 1.165	0.75 0.38	* 0.01552
BL TL	Distal MBL	1.264 1.222	0.81 0.37	0.8839
BL TL	Total MBL	1.324 1.194	0.64 0.30	0.10302
BL TL	BOP	0.905 1.7	1.05 1.15	* <0.00001
BL TL	PI	1.892 1.938	1.51 1.27	0.61708
BL TL	PPD	2.155 2.066	0.46 0.44	0.22004

Table 2. MBL comparison between subgroups for both BL and TL groups and tested through Mann–Whitney *U* nonparametric test.

		MBL Bone-Level Implants				
Parameter	**Variable**	**N**	**Mean (mm)**	**Std Dev**	**Median**	***p*-Value**
Abutment	0° 17° 30°	25 16 33	1.13 1.39 1.44	0.69 0.52 0.65	1 1.25 1.5	0.1386
Implant inclinations	Tilted Upright	34 40	1.39 1.27	0.59 0.69	1.5 1.25	0.26
Jaw distribution	Mandible Maxilla	20 54	1.11 1.40	0.75 0.59	1 1.5	0.083
Lengths (mm)	11.5 13 15	1 4 69	2 1.5 1.3	- 1.08 0.62	2 1.75 1.25	0.33
Diameters (mm)	3.8 4.25	15 59	1.12 1.38	0.76 0.61	1 1.25	0.25
		MBL tissue-level implants				
Abutment	None 17° 30°	40 24 16	1.16 1.21 1.27	0.31 0.25 0.32	1.2 1.25 1.21	0.482
Implant inclinations	Tilted Upright	40 40	1.23 1.16	0.28 0.31	1.25 1.20	0.2485
Jaw distribution	Mandible Maxilla	36 44	1.14 1.24	0.26 0.32	1.175 1.25	0.2945
Lengths (mm)	10 11.5 13 15	8 18 27 27	1.04 1.30 1.12 1.16	0.23 1.28 1.25 1.15	0.925 1.28 1.25 1.15	0.1114
Diameters (mm)	3.8 4.25	48 32	1.18 1.21	0.28 0.32	1.21 1.25	0.89

Table 3 shows the analysis of the MBL between the two groups (BL and TL implants) by each subgroups' parameters.

Table 3. MBL is compared in the two groups (BL and TL) by each subgroup parameter and tested through Mann–Whitney *U* nonparametric test.

Parameter	Variable	MBL BL Group Mean (SD)	MBL TL Group Mean (SD)	*p*-Value
Abutment	17°	1.39 (0.52)	1.21 (0.25)	0.4272
	30°	1.44 (0.65)	1.27 (0.32)	0.1139
Implant inclinations	Tilted	1.39 (0.59)	1.23 (0.28)	0.069
	Upright	1.27 (0.69)	1.16 (0.31)	0.4556
Jaw distribution	Mandible	1.11 (0.75)	1.14 (0.26)	0.6674
	Maxilla	1.40 (0.59)	1.24 (0.32)	0.085
Lengths (mm)	11.5	2	1.30 (1.28)	0.1397
	13	1.5 (1.08)	1.12 (1.25)	0.1835
	15	1.3 (0.62)	1.16 (1.15)	0.242
Diameters (mm)	3.8	1.12 (0.76)	1.18 (0.28)	0.8777
	4.25	1.38 (0.61)	1.21 (0.32)	0.1438

No statistically significant difference was highlighted ($p > 0.05$) for any of the subgroups analyzed.

4. Discussion

The first objective of the present article was to retrospectively compare the outcomes of BL implants and TL implants in immediate-loading full-arch rehabilitations after 12-months of functional follow-up. For this purpose, patients who were previously treated with immediate-loading full-arch rehabilitations using either BL or TL implants were evaluated, and data about implant survival rate, MBL (mesial, distal and total), PPD, BOP, and PI were collected and analyzed. Based on the results, some statistically significant differences were highlighted between the groups. Therefore, the first null hypotheses were rejected.

An implant survival rate of 97.37% was recorded for the BL group while an implant survival rate of 100% was recorded for the TL group. A slightly less non-significant total MBL was recorded in favor of TL implants (1.194 ± 0.30 mm) against BL ones (1.324 ± 0.64 mm), while a statistically significant difference was highlighted when considering MBL at the mesial aspect of the implants (TL 1.165 ± 0.38 mm, BL 1.412 ± 0.75 mm, $p = 0.01552$). The aforementioned results regarding the implant survival rate and MBL for both groups are in agreement with those reported in the literature regarding full-arch implant-supported rehabilitation after the 12-month follow-up [32–35]. The lower MBL detected for TL implants may be attributed to the different position of the implant–abutment interface and to the possibility of using TL implants without an abutment. This topic has surfaced recently, with different articles highlighting how the implant–abutment interfaces as well

as the mechanical procedure of screwing and unscrewing at the trans-mucosal level may be related to increased risks of bacterial contamination and, therefore, bone loss [17,36]. Indeed, the present results are in agreement with other studies that compared BL and TL implants in different types of rehabilitations and found a lower MBL in favor of TL implants [23,26]. One of the possible main advantages of TL implants may be the possibility of using them without abutment, as documented in previously published articles [24,25]. When an abutment is used, two possible micro-gaps are present: one between the abutment and the implant and one between the abutment and the prosthesis. In the present study, the two frontal implants were functionalized without using an abutment and, therefore, this may represent a possible reason for the lower MBL detected. However, further studies are required to more deeply investigate the topic.

In an interesting study by Afrashtehfar et al. [37], the authors compared the reliability of bone height measurements between BL and TL implants. According to their results, no statistically significant difference was highlighted between the two implant designs and, therefore, the measurement of bone loss between them can be considered reliable.

Furthermore, a statistically significant difference was also highlighted with BOP ($p < 0.00001$), which was calculated as the number of surfaces per implant with bleeding after probing, with TL implants showing higher values than BL ones. This result is in contrast with those reported in the literature, where TL implants are reported to possibly improve soft tissue health [24]. However, it must be noted that the increased BOP values recorded in the present study were not correlated with any increased PPD nor MBL nor any sign of peri-implantitis and were within clinical and radiological health guidelines in accordance with the last Workshop of Periodontology [38]. TL implants with a convergent collar, contrary to those with a divergent one [39], are described in articles with follow-up ranging between 18 months and 60 months [23,26,40] to improve the space and thickness of the soft tissue and thus promote peri-implant health [23,26]. Therefore, assuming that even in the present study the values were within clinical health guidelines for both groups, a longer follow-up period and further studies are required to confirm the result. Indeed, the main limitation of the present retrospective study is represented by the short-term follow-up period. Further studies with medium- and long-term follow-ups are required to further understand the differences between BL and TL implants in immediate-loading full-arch rehabilitation.

The second objective of the present study was to analyze possible factors influencing MBL, including implant diameters and lengths, type of abutments, jaw distribution, and implant inclination. Based on the results, no statistically significant difference ($p > 0.05$) was recorded for any of the analyzed subgroups, both within and between BL and TL implants. Therefore, the second null hypotheses was accepted. However, it must be noted that an additional limitation of the research is linked to the fact that most of the subgroups analyzed were imbalanced. This limitation is inherent to the retrospective design of the study, where randomization among the subgroups was not possible. However, the present results may indicate that as long as the CBP is followed within the implant range of the study, such as minimum implant length of 10 mm and minimum diameter of 3.8; all the other variables do not seem to influence the MBL. This result, together with the high implant survival rate recorded, are in agreement with the articles that analyzed the outcomes of the CBP in the medium- and long-term observational periods [5]. Indeed, in accordance with the literature, the CBP is reported to provide an implant survival rate higher than 92.25% even after a 10-year observational period post load [1].

In conclusion, research on different implant designs as well as new materials and protocols is consistently advancing [41–44]. To the authors' knowledge, the present article represents the first study reporting data on the comparison between BL and TL implants with a convergent collar in immediate-loading full-arch rehabilitations. The data observed in this study seem to indicate that both of the implant designs may be a good option for this type of rehabilitation. However, further research is required to confirm the results.

5. Conclusions

Within the limitations of the present retrospective study, both TL and BL implants seem to provide good clinical outcomes after a 12-month observational period when employed in immediate-loading full-arch rehabilitation. Further clinical trials with longer observational times are required to confirm the results and further understand the possibility of different clinical outcomes between the two implant designs in this type of implant rehabilitation.

Author Contributions: Conceptualization, F.P., M.C., M.M. and P.P.; methodology F.P., M.C., M.M. and P.P.; software, F.B., A.C., G.A. and G.I.; formal analysis, F.P., M.C., F.B., M.M. and P.P.; data curation, F.B., A.C., G.A. and G.I.; writing—original draft preparation, M.C.; writing—review and editing, M.C. and P.P.; supervision, F.P., M.C., M.M. and P.P.; project administration, F.P., M.C., M.M. and P.P.; All authors have read and agreed to the published version of the manuscript.

Funding: This research received no external funding.

Institutional Review Board Statement: The present study was approved by the local ethical committee of the University of Genoa (protocol n. 527) and of the University of Turin (protocol n. 0130929).

Informed Consent Statement: Informed consent was obtained from all subjects involved in the study.

Data Availability Statement: The datasets generated during and/or analyzed during the current study are available from the corresponding author on reasonable request.

Acknowledgments: The authors wish to acknowledge Sweden & Martina (Due Carrare, Padova, Italy for providing part of the surgical materials.

Conflicts of Interest: The authors declare no conflict of interest.

References

1. Barootchi, S.; Askar, H.; Ravidà, A.; Gargallo-Albiol, J.; Travan, S.; Wang, H.L. Long-term Clinical Outcomes and Cost-Effectiveness of Full-Arch Implant-Supported Zirconia-Based and Metal-Acrylic Fixed Dental Prostheses: A Retrospective Analysis. *Int. J. Oral Maxillofac. Implant.* **2020**, *35*, 395–405. [CrossRef] [PubMed]
2. Schropp, L.; Isidor, F.; Kostopoulos, L.; Wenzel, A. Patient experience of, and satisfaction with, delayed-immediate vs. delayed single-tooth implant placement. *Clin. Oral Implant. Res.* **2004**, *15*, 498–503. [CrossRef] [PubMed]
3. Catapano, S.; Ortensi, L.; Mobilio, N.; Grande, F. The New Elderly Patient: A Necessary Upgrade. *Prosthesis* **2021**, *3*, 99–104. [CrossRef]
4. Ortensi, L.; Ortensi, M.; Minghelli, A.; Grande, F. Implant-Supported Prosthetic Therapy of an Edentulous Patient: Clinical and Technical Aspects. *Prosthesis* **2020**, *2*, 140–152. [CrossRef]
5. Tealdo, T.; Menini, M.; Bevilacqua, M.; Pera, F.; Pesce, P.; Signori, A.; Pera, P. Immediate versus delayed loading of dental implants in edentulous patients' maxillae: A 6-year prospective study. *Int. J. Prosthodont.* **2014**, *27*, 207–214. [CrossRef] [PubMed]
6. De Bruyn, H.; Raes, S.; Ostman, P.O.; Cosyn, J. Immediate loading in partially and completely edentulous jaws: A review of the literature with clinical guidelines. *Periodontology 2000* **2014**, *66*, 153–187. [CrossRef] [PubMed]
7. Wittneben, J.G.; Buser, D.; Salvi, G.E.; Bürgin, W.; Hicklin, S.; Brägger, U. Complication and failure rates with implant-supported fixed dental prostheses and single crowns: A 10-year retrospective study. *Clin. Implant Dent. Relat. Res.* **2014**, *16*, 356–364. [CrossRef]
8. Sailer, I.; Karasan, D.; Todorovic, A.; Ligoutsikou, M.; Pjetursson, B.E. Prosthetic failures in dental implant therapy. *Periodontology 2000* **2022**, *88*, 130–144. [CrossRef]
9. Catapano, S.; Ferrari, M.; Mobilio, N.; Montanari, M.; Corsalini, M.; Grande, F. Comparative Analysis of the Stability of Prosthetic Screws under Cyclic Loading in Implant Prosthodontics: An In Vitro Study. *Appl. Sci.* **2021**, *11*, 622. [CrossRef]
10. Brånemark, P.; Adell, R.; Breine, U.; Hansson, B.O.; Lindstrom, J.; Ohlsson, A. Intra-osseous anchorage of dental prostheses. I. Experimental studies. *Scand. J. Plast. Reconstr. Sug.* **1969**, *3*, 81–100. [CrossRef]
11. Balshi, T.J.; Wolfinger, G.J.; Slauch, R.W.; Balshi, S.F. A retrospective analysis of 800 Brånemark System implants following the All-on-Four protocol. *J. Prosthodont.* **2014**, *23*, 83–88. [CrossRef] [PubMed]
12. Palacios-Garzón, N.; Mauri-Obradors, E.; Roselló-LLabrés, X.; Estrugo-Devesa, A.; Jané-Salas, E.; López-López, J. Comparison of Marginal Bone Loss Between Implants with Internal and External Connections: A Systematic Review. *Int. J. Oral Maxillofac. Implant.* **2018**, *33*, 580–589. [CrossRef] [PubMed]
13. Manzella, C.; Burello, V.; Bignardi, C.; Carossa, S.; Schierano, G. A method to improve passive fit of frameworks on implant-supported prostheses: An in vivo study. *Int. J. Prosthodont.* **2013**, *26*, 577–579. [CrossRef] [PubMed]
14. Gil, F.J.; Herrero-Climent, M.; Lazaro, P.; Rios, J.V. Implant-abutment connections: Influence of the design on the microgap and their fatigue and fracture behavior of dental implants. *J. Mater. Sci. Mater. Med.* **2014**, *25*, 1825–1830. [CrossRef] [PubMed]

15. Almeida, E.O.; Freitas, A.C., Jr.; Bonfante, E.A.; Marotta, L.; Silva, N.R.; Coelho, P.G. Mechanical testing of implant-supported anterior crowns with different implant/abutment connections. *Int. J. Oral Maxillofac. Implant.* **2013**, *28*, 103–108. [CrossRef] [PubMed]
16. Maeda, Y.; Satoh, T.; Sogo, M. In vitro differences of stress concentrations for internal and external hex implant-abutment connections: A short communication. *J. Oral Rehabil.* **2006**, *33*, 75–78. [CrossRef] [PubMed]
17. Canullo, L.; Penarrocha-Oltra, D.; Soldini, C.; Mazzocco, F.; Penarrocha, M.; Covani, U. Microbiological assessment of the implant-abutment interface in different connections: Cross-sectional study after 5 years of functional loading. *Clin. Oral Implant. Res.* **2015**, *26*, 426–434. [CrossRef] [PubMed]
18. Vetromilla, B.M.; Brondani, L.P.; Pereira-Cenci, T.; Bergoli, C.D. Influence of different implant-abutment connection designs on the mechanical and biological behavior of single-tooth implants in the maxillary esthetic zone: A systematic review. *J. Prosthet. Dent.* **2019**, *121*, 398–403. [CrossRef]
19. Lazzara, R.J.; Porter, S.S. Platform switching: A new concept in implant dentistry for controlling postrestorative crestal bone levels. *Int. J. Periodontics Restor. Dent.* **2006**, *26*, 9–17.
20. Menini, M.; Pesce, P.; Bagnasco, F.; Carossa, M.; Mussano, F.; Pera, F. Evaluation of internal and external hexagon connections in immediately loaded full-arch rehabilitations: A within-person randomised split-mouth controlled trial. *Int. J. Oral Implantol.* **2019**, *12*, 169–179.
21. Pera, F.; Menini, M.; Bagnasco, F.; Mussano, F.; Ambrogio, G.; Pesce, P. Evaluation of internal and external hexagon connections in immediately loaded full-arch rehabilitations: A within-person randomized split-mouth controlled trial with a 3-year follow-up. *Clin. Implant Dent. Relat. Res.* **2021**, *23*, 562–567. [CrossRef]
22. Taheri, M.; Akbari, S.; Shamshiri, A.R.; Shayesteh, Y.S. Marginal bone loss around bone-level and tissue-level implants: A systematic review and meta-analysis. *Ann. Anat.* **2020**, *231*, 151525. [CrossRef] [PubMed]
23. Canullo, L.; Menini, M.; Covani, U.; Pesce, P. Clinical outcomes of using a prosthetic protocol to rehabilitate tissue-level implants with a convergent collar in the esthetic zone: A 3-year prospective study. *J. Prosthet. Dent.* **2020**, *123*, 246–251. [CrossRef] [PubMed]
24. Carossa, M.; Alovisi, M.; Crupi, A.; Ambrogio, G.; Pera, F. Full-Arch Rehabilitation Using Trans-Mucosal Tissue-Level Implants with and without Implant-Abutment Units: A Case Report. *Dent. J.* **2022**, *10*, 116. [CrossRef] [PubMed]
25. Pera, F.; Pesce, P.; Menini, M.; Fanelli, F.; Kim, B.C.; Zhurakivska, K.; Mayer, Y.; Isola, G.; Cianciotta, G.; Crupi, A.; et al. Immediate loading full-arch rehabilitation using transmucosal tissue-level implants with different variables associated: A one-year observational study. *Minerva Dent. Oral Sci.* **2023**, *72*, 230–238. [CrossRef] [PubMed]
26. Canullo, L.; Menini, M.; Bagnasco, F.; Di Tullio, N.; Pesce, P. Tissue-level versus bone-level single implants in the anterior area rehabilitated with feather-edge crowns on conical implant abutments: An up to 5-year retrospective study. *J. Prosthet. Dent.* **2022**, *128*, 936–941. [CrossRef] [PubMed]
27. Menini, M.; Dellepiane, E.; Deiana, T.; Fulcheri, E.; Pera, P.; Pesce, P. Comparison of Bone-Level and Tissue-Level Implants: A Pilot Study with a Histologic Analysis and a 4-Year Follow-up. *Int. J. Periodontics Restor. Dent.* **2022**, *42*, 535–543. [CrossRef]
28. El-Kholey, K.E. Efficacy of two antibiotic regimens in the reduction of early dental implant failure: A pilot study. *Int. J. Oral Maxillofac. Surg.* **2014**, *43*, 487–490. [CrossRef]
29. Tan, W.C.; Ong, M.; Han, J.; Mattheos, N.; Pjetursson, B.E.; Tsai, A.Y.; Sanz, I.; Wong, M.C.; Lang, N.P.; ITI Antibiotic Study Group. Effect of systemic antibiotics on clinical and patient-reported outcomes of implant therapy—A multicenter randomized controlled clinical trial. *Clin. Oral Implant. Res.* **2014**, *25*, 185–193. [CrossRef]
30. Pera, F.; Menini, M.; Alovisi, M.; Crupi, A.; Ambrogio, G.; Asero, S.; Marchetti, C.; Canepa, C.; Merlini, L.; Pesce, P.; et al. Can Abutment with Novel Superlattice CrN/NbN Coatings Influence Peri-Implant Tissue Health and Implant Survival Rate Compared to Machined Abutment? 6-Month Results from a Multi-Center Split-Mouth Randomized Control Trial. *Materials* **2023**, *16*, 246. [CrossRef]
31. Menini, M.; Pesce, P.; Delucchi, F.; Ambrogio, G.; Canepa, C.; Carossa, M.; Pera, F. One-stage versus two-stage technique using two splinted extra-short implants: A multicentric split-mouth study with a one-year follow-up. *Clin. Implant Dent. Relat. Res.* **2022**, *24*, 602–610. [CrossRef] [PubMed]
32. Testori, T.; Del Fabbro, M.; Capelli, M.; Zuffetti, F.; Francetti, L.; Weinstein, R.L. Immediate occlusal loading and tilted implants for the rehabilitation of the atrophic edentulous maxilla: 1-year interim results of a multicenter prospective study. *Clin. Oral Implant. Res.* **2008**, *19*, 227–232. [CrossRef] [PubMed]
33. Capelli, M.; Zuffetti, F.; Del Fabbro, M.; Testori, T. Immediate rehabilitation of the completely edentulous jaw with fixed prostheses supported by either upright or tilted implants: A multicenter clinical study. *Int. J. Oral Maxillofac. Implant.* **2007**, *22*, 639–644.
34. Albrektsson, T.; Zarb, G.A. Current interpretations of the osseointegrated response: Clinical significance. *Int. J. Prosthodont.* **1993**, *6*, 95–105.
35. Albrektsson, T.; Zarb, G.; Worthington, P.; Eriksson, A.R. The long-term efficacy of currently used dental implants: A review and proposed criteria of success. *Int. J. Oral Maxillofac. Implant.* **1986**, *1*, 11–25.
36. Tallarico, M.; Canullo, L.; Caneva, M.; Ozcam, M. Microbial colonization of the implant-abutment interface and its possible influence on the development of peri-implantitis: A systematic review with meta-analysis. *J. Prosthodont. Res.* **2017**, *61*, 233–241. [CrossRef]

37. Afrashtehfar, K.I.; Brägger, U.; Hicklin, S.P. Reliability of Interproximal Bone Height Measurements in Bone- and Tissue-Level Implants: A Methodological Study for Improved Calibration Purposes. *Int. J. Oral Maxillofac. Implant.* **2020**, *35*, 289–296. [CrossRef]
38. Caton, J.G.; Armitage, G.; Berglundh, T.; Chapple, I.L.C.; Jepsen, S.; Kornman, K.S.; Mealey, B.L.; Papapanou, P.N.; Sanz, M.; Tonetti, M.S. A new classification scheme for periodontal and peri-implant diseases and conditions—Introduction and key changes from the 1999 classification. *J. Clin. Periodontol.* **2018**, *45*, S1–S8. [CrossRef]
39. Agustín-Panadero, R.; Martínez-Martínez, N.; Fernandez-Estevan, L.; Faus-López, J.; Solá-Ruíz, M.F. Influence of Transmucosal Area Morphology on Peri-Implant Bone Loss in Tissue-Level Implants. *Int. J. Oral Maxillofac. Implant.* **2019**, *34*, 947–952. [CrossRef]
40. Canullo, L.; Tallarico, M.; Pradies, G.; Marinotti, F.; Loi, I.; Cocchetto, R. Soft and hard tissue response to an implant with a convergent collar in the esthetic area: Preliminary report at 18 months. *Int. J. Esthet. Dent.* **2017**, *12*, 306–323.
41. Lepidi, L.; Grande, F.; Baldassarre, G.; Suriano, C.; Li, J.; Catapano, S. Preliminary clinical study of the accuracy of a digital axiographic recording system for the assessment of sagittal condylar inclination. *J. Dent.* **2023**, *135*, 104583. [CrossRef] [PubMed]
42. Grande, F.; Pozzan, M.C.; Marconato, R.; Mollica, F.; Catapano, S. Evaluation of Load Distribution in a Mandibular Model with Four Implants Depending on the Number of Prosthetic Screws Used for OT-Bridge System: A Finite Element Analysis (FEA). *Materials* **2022**, *15*, 7963. [CrossRef] [PubMed]
43. Grande, F.; Celeghin, G.; Gallinaro, F.; Mobilio, N.; Catapano, S. Comparison of the accuracy between full-arch digital scans and scannable impression materials: An in vitro study. *Minerva Dent. Oral Sci.* **2023**, *72*, 168–175. [CrossRef] [PubMed]
44. Montanari, M.; Grande, F.; Lepidi, L.; Piana, G.; Catapano, S. Rehabilitation with implant-supported overdentures in preteens patients with ectodermal dysplasia: A cohort study. *Clin. Implant Dent. Relat. Res.* 2023; *early view*. [CrossRef]

Disclaimer/Publisher's Note: The statements, opinions and data contained in all publications are solely those of the individual author(s) and contributor(s) and not of MDPI and/or the editor(s). MDPI and/or the editor(s) disclaim responsibility for any injury to people or property resulting from any ideas, methods, instructions or products referred to in the content.