POLITECNICO DI TORINO
Repository ISTITUZIONALE

Immediate loading full-arch rehabilitation using transmucosal tissue-level implants with different variables associated: a one-year observational study

Original
Immediate loading full-arch rehabilitation using transmucosal tissue-level implants with different variables associated: a one-year observational study / Pera, F., Pesce, P., Menini, M., Fanelli, F., Kim, B.-C., Zhurakivska, K., Mayer, Y., Isola, G., Cianciotta, G., Crupi, A., Ambrogio, G., Scotti, N., Carossa, M.. - In: MINERVA DENTAL AND ORAL SCIENCE. - ISSN 2724-6329. - 72:5(2023), pp. 230-238. [10.23736/S2724-6329.23.04782-4]

Availability:
This version is available at: 11583/3013528 since: 2026-07-25T14:00:42Z

Publisher:
Edizioni Minerva Medica

Published
DOI:10.23736/S2724-6329.23.04782-4

Terms of use:

This article is made available under terms and conditions as specified in the corresponding bibliographic description in the repository

Publisher copyright

(Article begins on next page)

25 November 2026

© 2023 THE AUTHORS
Open access at https://www.minervamedica.it

Minerva Dental and Oral Science 2023 October;72(5):230-8
DOI: 10.23736/S2724-6329.23.04782-4

ORIGINAL ARTICLE

Immediate loading full-arch rehabilitation using transmucosal tissue-level implants with different variables associated: a one-year observational study

Francesco PERA [1], Paolo PESCE [2], Maria MENINI [2], Francesco FANELLI [3], Byung-Chan KIM [3], Khrystyna ZHURAKIVSKA [3], Yaniv MAYER [4], Gaetano ISOLA [5], Giulia CIANCIOTTA [1], Armando CRUPI [1], Giulia AMBROGIO [1], Nicola SCOTTI [1], Massimo CAROSSA [1] *

[1]C.I.R. Dental School, Department of Surgical Sciences, University of Turin, Turin, Italy; [2]Department of Surgical Sciences (DISC), University of Genoa, Genoa, Italy; [3]Department of Clinical and Experimental Medicine, University of Foggia, Foggia, Italy; [4]School of Graduate Dentistry, Health Care Campus Rambam, Haifa, Israel; [5]School of Dentistry, Department of General Surgery and Surgical-Medical Specialties, University of Catania, Catania, Italy

*Corresponding author: Massimo Carossa, C.I.R. Dental School, Department of Surgical Sciences, University of Turin, Via Nizza 230, 10126 Turin, Italy. E-mail: massimo.carossa@unito.it

This is an open access article distributed under the terms of the Creative Commons CC BY-NC license which allows users to distribute, remix, adapt and build upon the manuscript, as long as this is not done for commercial purposes, the user gives appropriate credits to the original author(s) and the source (with a link to the formal publication through the relevant DOI), provides a link to the license and indicates if changes were made. Full details on the CC BY-NC 4.0 are available at https://creativecommons.org/licenses/by-nc/4.0/.

ABSTRACT

BACKGROUND: The aim of the present observational study was to investigate the application of transmucosal tissue-level implants in immediate loading full-arch rehabilitation with different variables associated.

METHODS: Patients needing a full-arch implant rehabilitation were recruited and rehabilitated with four transmucosal tissue level implants. Data related to implants' diameters and lengths, jaw distributions, and presence of angulated abutments were collected. The following outcomes were evaluated: survival rate, marginal bone loss (MBL), Plaque Index (PI), bleeding on probing (BoP), probing depth (PD). Descriptive statistical analysis was reported and univariate linear regression models were built to assess a significant correlation between MBL and the different implant related factors.

RESULTS: Twenty patients were rehabilitated for a total implant number of 80; 11 rehabilitations were performed on the maxilla, while 9 were performed on the mandible; 48 implants presented a 3.8 mm diameter and 32 implants presented a 4.25 mm diameter. Implants length varied between 10 to 15 mm; 40 tilted implants were connected to angulated abutment, while 40 straight implants were connected directly to the prostheses (no abutments). At the one year follow-up visit no implants failed resulting in an implant survival rate of 100%. The overall MBL was 1.19±0.30 mm. No statistically significant difference (P>0.05) was highlighted among any of the subgroups analyzed.

CONCLUSIONS: Despite different variables associated, tissue level implants seem to represent a valid option when applied in immediate loading full-arch rehabilitation. Further research and longer observational periods are encouraged to confirm the result.

(*Cite this article as*: Pera F, Pesce P, Menini M, Fanelli F, Kim BC, Zhurakivska K, *et al.* Immediate loading full-arch rehabilitation using transmucosal tissue-level implants with different variables associated: a one-year observational study. Minerva Dent Oral Sc 2023;72:230-8. DOI: 10.23736/S2724-6329.23.04782-4)

KEY WORDS: Bone diseases, metabolic; Dental implants; Immediate dental implant loading.

Implant supported fixed rehabilitations have nowadays become a routine treatment option to rehabilitate both partial and full edentulous patients.[1] After the surgical insertion of the implants into the bone, the prosthodontic components are connected to the implants allowing the

rehabilitation of both the previously lost function and esthetic.[2, 3] Different articles have investigated the long-term prognosis of this rehabilitation, concluding how the implant prosthodontic treatment can be considered a predictable treatment with high survival rate[4] and patient satisfaction.[5] However, complications continue to be an undesirable clinical occurrence capable of negatively influencing the success of the rehabilitation[6] and, in the worst case, leading to a failure.[7] Despite different prosthetic risk factors for the onset of complications,[8, 9] different authors have recently begun to highlight how the implant-abutment interface could play a role in the onset of peri-implant inflammation reaction.[10, 11] Implant abutments are commonly adopted to avoid excessive stress on the peri-implant tissues;[12] increase the passive fit of the prosthodontic component;[13] and to avoid the possible trauma of the soft tissue which can occur due to the screw-unscrew procedures.[14] Furthermore, angulated abutments allow the possibility of tilting the distal implant by correcting the axis to obtain a posterior located crown and, at the same time, avoiding the anatomical boundaries (lower jaw alveolar nerve and upper jaw sinus).[15] This possibility has led to the chance of performing full arch rehabilitations using four implants, two tilted in the posterior area and two straight implants in the anterior area. Nowadays, this procedure represents the best treatment option for the fixed rehabilitation of fully edentulous patients with high levels of bone resorption in the posterior area, avoiding bone grafting procedures.[4]

However, when an abutment is used, two interfaces are present: one between the implant head and the abutment, and the other between the abutment and the prosthodontic structure. In a recent systematic review on the topic,[16] which analyzed 14 articles totaling 1126 implants, it was pointed out how the interfaces between the abutment components usually present microgaps that can be colonizable by peri-implant pathogens. Consequently, this can lead to soft tissue inflammation and to the development of peri-implantitis[17, 18] and, ultimately, to bone resorption.[19]

To overcome this clinical problem, research has recently tried to investigate different implant connection types[20-22] and different abutment configurations.[23-26] However, a final solution is still absent and research on the topic remains open.

In recent years, tissue-level implants with convergent collars were introduced in contrast to the traditional bone level implants. This implant design, also called one-piece implant, presents the advantage of placing the implant-abutment interface at a supracrestal position, possibly avoiding the above-mentioned risks. To date, different research studies have investigated the outcomes of tissue-level implants with a convergent collar in single[27] and multi-unit[25] implant rehabilitation, finding promising results. However, research on their application in full-arch rehabilitation is currently lacking.

In a recent case report, Carossa *et al.*[28] hypothesized how transmucosal tissue level implants could be a valid alternative to the traditional implant design when adopted in full-arch rehabilitation, even when applied without the implant-abutment unit. However, the Authors pointed out how the scientific evidence on the topic is currently weak and more prospective studies are required to confirm the hypothesis.

Therefore, the first aim of the present 1-year observational study was to investigate the outcomes of transmucosal tissue level implants applied in immediate loading full arch rehabilitations. The second aim was to analyze factors that could affect the clinical outcome of the implants.

The first null hypothesis was that tissue level implants are a valid implant option for immediate loading full arch rehabilitation. The second null hypothesis was that there is no difference in terms of marginal bone loss (MBL) between the implants considering the use of angulated abutment, implant diameter, maxilla or mandible, and length of the implant.

Materials and methods

This clinical study was performed following the principles outlined in the Declaration of Helsinki on experimentation involving human subjects. All patients were thoroughly informed about the procedures and signed an informed consent form, and the research was approved by the local ethical committee of the University of Genoa (CERA).

Study design

The same experienced dental surgeon performed all the surgeries. Two experienced calibrated and trained clinicians performed all the measurements (FP and MC). Cohen's kappa statistic was adopted to calculate observer agreement. No randomization was performed considering implants' length and diameter, jaw distribution (mandible *vs*. maxilla). The different implant' lengths and diameters were decided according to the availability of horizontal and vertical bone evaluated prior to the surgery.

Patients' selection

Consecutively examined patients needing a full-arch implant rehabilitation were screened to be included in the present research. Exclusion criteria were: 1) history of bisphosphonate therapy; 2) uncontrolled diabetes (HbA1c>6%, glycemic level >110 mg/dL); 3) relevant medical conditions contraindicating oral surgery; 4) regenerative procedures needed.

Surgery procedure

Preoperative evaluation including clinical examination (Figure 1), orthopantomography exam (Figure 2), as well as a cone beam computed tomography (CBCT) of the relevant arch were performed. Prior to surgery dental hygiene was performed and preoperative antibiotic therapy with Amoxicillin 875 mg + Clavulanic acid 125 mg every 12 h for 6 days was prescribed starting 1 day prior to the surgery.[29, 30] Patients were asked to rinse with chlorhexidine digluconate solution (0.2%) for 1 min before surgery.

Local anesthesia with 4% articaine and 1:10,000 adrenaline (Alfacaina SP; Dentsply Italy, Rome, Italy) was used. All the hopeless teeth (if present) were extracted on the day of surgery (Figure 3), and a full-thickness mucoperiosteal flap was elevated (Figure 4).

Implant were positioned according to the Columbus Bridge Protocol (CBP). This is a surgical and prosthodontic protocol used to rehabilitate maxillae and mandibles using distal tilted im-



Figure 1.—Clinical preoperative image of a patient requiring full-arch rehabilitation in the upper jaw.



Figure 3.—Clinical image after the extraction of the hopeless teeth.



Figure 2.—Preoperative orthopantomography.

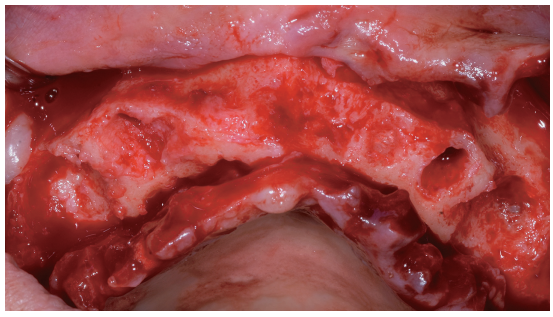

Figure 4.—Clinical image after mucoperiosteal flap elevation.

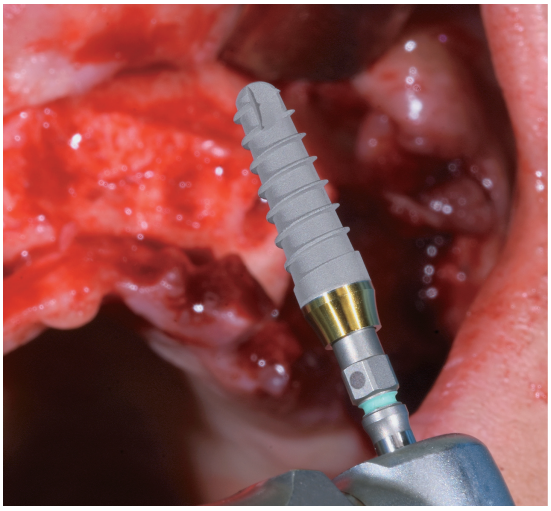

Figure 5.—Clinical image of the transmucosal implant design adopted in the study.

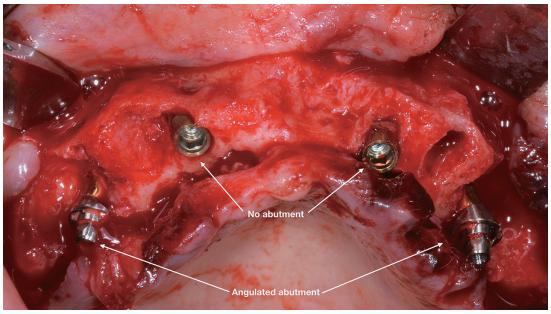

Figure 6.—Clinical image after the implants insertion. The two tilted distal implants are connected to the abutments, while the two anterior implants are left without.

plants (upper jaw: implants placed parallel to the anterior sinus wall; lower jaw: implants placed obliquely angled above the mental foramen) and anterior upright implants.[4, 31]

Four implants were inserted (Prama, Sweden & Martina, Due Carrare PD, Italy) (Figure 5). Two angulated implant-abutment units (Abutment P.A.D 330-303, Sweden & Martina, Due Carrare) were screwed onto the two distal implants. The two anterior implants were left without any implant-abutment units (Figure 6) and connected directly into the prosthesis.

The Prama is a transmucosal implant presenting a titanium conically shaped collar tapered in the occlusal direction. The platform had an internal hexagon connection with a 3.4-mm diameter. The collar is treated with the UTM (Ultrathin Threaded Microsurface) technique to promote soft tissue adhesion[32, 33] whereas the implant body is treated with the ZirTi surface technique (Zirconium sand-blasted acid-etched surface). All the PRAMA implants used in the present study presented a collar with 2.8 mm length.

Before suturing, impression-transfers were screwed on the anterior implants (L-TRA-380, Sweden & Martina, Due Carrare, Padua, Italy) and on the posterior PAD (PAD-TRA, Sweden & Martina). An analogic open-tray technique impression taken with plaster was collected (Snow-White Plaster, Kerr, Salerno, Italy) and sent to the dental laboratory.

Flaps were sutured using silk multifilament sutures (PERMA-HAND SILK 4-0; Ethicon, Somerville, NJ, USA).

Postoperative instructions included a 0.2% chlorhexidine digluconate rinse (Corsodyl, GlaxoSmithKline, Verona, Italy) twice a day for two weeks, soft diet, and hygienic recommendations.

A screw-retained provisional prosthesis made with resin and an embedded metal framework was delivered after 48 hours[34-36] (Figure 7, 8).

Sutures were removed one week after surgery,



Figure 7.—Clinical image of the screw-retained provisional prosthesis delivered 48 hours from the surgery.

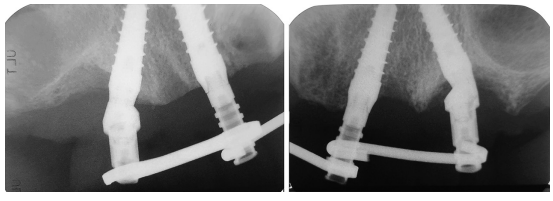

Figure 8.—Radiographic images after delivery of provisional prostheses (TO).

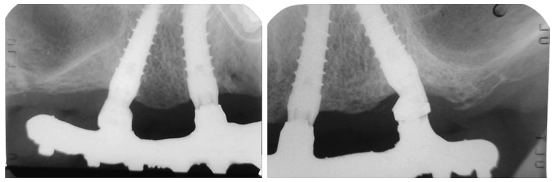

Figure 9.—Radiographic images at the 1-year follow-up visit (T12).



Figure 10.—Clinical image of the screw-retained final prosthesis at the 1-year follow-up visit (T12).

and recalls were planned at 2 weeks, 3 months, 6 months and subsequently every 6 months (Figure 9, 10).

The occlusion was checked at each appointment.

The final prosthesis made with composite resin and a metal framework was realized 6 months after the surgery.

Clinical outcomes

Data related to implants' diameters and lengths, jaw distributions, and presence of angulated abutments were collected.

The following clinical outcomes were considered:

- implant survival rate;
- MBL evaluated 12 months after surgery (T12). MBL was evaluated using intraoral digital periapical radiographs taken with the parallel technique. It was evaluated on both the X-rays acquired immediately after surgery (T0) and on the ones acquired at T12. The difference between T12 and T0 produced the MBL;
- periodontal parameters:[37] Plaque Index (PI), probing depth (PD), and bleeding on probing (BoP) evaluated at the one-year follow-up visit. PI, PD and BoP were assessed at 4 points for each implant using a periodontal UNC 15 probe (Hu-Friedy, Chicago, IL, USA).

Statistical analysis

The descriptive statistical analysis included age, gender, implant position, implant length, torque insertion Ncm, angled abutment inclination. Peri-implant health parameters such as BOP, PD, PI, and bone resorption were described as mean and SD values.

Univariate linear regression models were built in order to assess the correlation between the use of an angulated abutment, different implant diameters, different location of the implant rehabilitation (mandible or maxilla) and different lengths of the implant on MBL at either mesial and distal site. A significance level of 5% was adopted in all tests and SPSS IBM (version 25) was used.

Results

In total, twenty patients were treated for a total implant number of 80 (N.=80). 40 implants were connected to angulated abutments (N.=40) and 40 implants were connected directly to the prostheses (no abutment) (N.=40). Main patients and implants' characteristics are reported in Table I.

At the one year follow-up visit no implants failed and the cumulative survival rate was 100%. Bone loss and main periodontal indexes are reported in Table II.

At the one-year follow-up visit the over-

TABLE I.—*Patients and implants characteristics.*

Patient	N.
Male/female	12/8
Mean age (years)	62
Mandible	9
Maxilla	11
Implants	
Implant diameter 3.8 mm	48
Implant diameter 4.25 mm	32
Implant length 15 mm	27
Implant length 13 mm	27
Implant length 11.5 mm	18
Implant length 10 mm	8
Torque <50Ncm	12
Torque >50Ncm	68
PAD 17°	24
PAD 30°	30

TABLE II.—*Bone loss and periodontal indexes.*

	Mesial	Distal	Total	Without abutments	With abutments
Mean bone loss	1.16±0.32	1.21±0.28	1.19±0.30	1.16±0.28	1.22±0.32
Plaque Index	-	-	0.48±0.50	0.49±0.50	0.48±0.50
Bleeding on probing	-	-	0.43±0.50	0.45±0.50	0.4±0.49
Probing depth	-	-	2.07±0.65	2.1±0.58	2.04±0.71

TABLE III.—*Statistical analysis related to mesial and distal MBL.*

Variable	Mesial (P value)	Distal (P value)
Presence of angulated abutment	0.342	0.391
Diameter of the implant	0.489	0.888
Length of the implant	0.821	0.929
Location of the implant rehabilitation (maxilla or mandible)	0.842	0.071

all mean bone loss was 1.19±0.30 mm (mesial 1.16±0.21 mm and distal 1.22±0.28 mm). The bone loss at the posterior implants connected with angulated abutments was 1.22±0.32 mm while the bone loss at the implants without abutment was 1.16±0.28. Excellent intraobserver (kappa values of 0.78 and 0.80) and inter-observer (a kappa value of 0.80) agreement was recorded in this study.

The univariate linear regression identified no statistically significant difference (P>0.05) among any of the examined correlation (Table III).

Discussion

The first aim of the present 1-year observational study was to investigate the outcomes of transmucosal tissue level implants in immediate loading full arch rehabilitation.

Twenty patients requiring a full-arch rehabilitation with high level of bone resorption in the posterior area were enrolled for a total implant number of 80 (N.=80). They were consequently rehabilitated using four transmucosal tissue level implants supporting an immediate loaded full-arch rehabilitation according to the Columbus Bridge Protocol. After a 1-year observational period, an implants survival rate of 100% was recorded and all the rehabilitations were seen to be successful. Mean MBL was 1.19±0.30 mm (mesial 1.16±0.21 mm and distal 1.22±0.28 mm) and no technical or biological complications were recorded. Therefore, the first null hypothesis was accepted.

To date, different studies have investigated the outcomes of immediate loading full arch rehabilitation. Pera *et al.* reported the outcomes of immediate loaded full-arch rehabilitations after 6[31] and 10 [4] years observational period, finding a survival rate higher than 93%. In agreement, Testori *et al.*[38] and Francetti *et al.*[39] followed 41 patients for 1 year and 47 patients for 5 years respectively, rehabilitated with immediate loaded full-arch rehabilitation finding similar survival rate >95%. Furthermore, consistencies were also shown in a recent systematic review and meta-analysis by Del Fabbro *et al.*[40] who analyzed 24 articles focused on full arch rehabilitations with tilted and axial implants. The author's finding highlighted how this type of rehabilitation represents a predictable treatment option for the rehabilitation of the edentulous arches.

Consequently, the one-year result of the present study is in agreement with the results currently described in the literature.[41] Therefore, transmucosal tissue level implants seem to represent a valid alternative to the traditional implant design when applied in full-arch rehabilitation. However, longer follow-up is required to confirm the present result.

To the author's knowledge, the only data currently available on the use of transmucosal tissue level implants in full arch rehabilitation are from a single case report,[28] which is difficult to compare due to the low scientific evidence inherent to the study design. On the other hand, different studies have investigated the outcomes of transmucosal tissue-level implants in implant supporting single unit and multi-unit rehabilitation. Studies from Canullo *et al.* reported the

outcomes of 16,[27] and 48[23] transmucosal tissue-level implants followed over 3 years, and 5 years, respectively. Results from the studies were in agreement and reported optimal results in terms of both soft and hard tissue outcomes. Consistencies were also shown in a retrospective study by Castillo *et al.*[42] who analyzed three implant designs with different transmucosal configurations supporting single implant unit rehabilitation. The Authors highlighted how the transmucosal configuration had a significant influence on hard tissue behavior, and the implants with transmucosal convergent collar presented less bone resorption compared to the ones presented cylindrical transmucosal neck. In regards to multi-unit implant rehabilitation, Menini *et al.*[25] compared traditional bone level implant and transmucosal tissue level implants in a 4 years prospective study. Results from the study showed no differences in any clinical parameters between the two implant designs.

Consequently, data from the literature on the use of this implant design is promising and research is encouraged to continue deepening the knowledge on the advantages that it may offer.

The second aim of the present study was to analyze factors affecting MBL of the implants. Implants' length and diameter, jaw distribution and use of angulated abutment were collected and considered as variables. Based on the results, no statistical difference ($P>0.05$) was found between any of the subgroups analyzed. Therefore, also the second null hypothesis was accepted. In total, a MBL of 1.22±0.32 mm (mesial 1.19±0.36 mm and distal 1.24±0.28 mm) was recorded for the implants with abutment (posterior ones), while a MBL of 1.16±0.28 mm (mesial 1.12±0.28 mm and distal 1.19±0.29 mm) was recorded for the implants with no abutment (anterior ones).

Despite the biomechanical advantages of using an implant-abutment,[43] this prosthetic component also represents an additional cost for the patient, as well as an additional prosthetic procedure which was described as a potential risk factor for the bacteria colonization and peri-implantitis onset.[16] Consequently, the possibility of using an implant without abutment certainly represents a simplification of the prosthetic procedure,[44, 45] as well as an advantage by avoiding the presence of microgaps at two interfaces. However, the procedure needs to have scientific evidence in order to be routinely applied in daily clinical practice. The study of Göthberg *et al.*,[46] who tested implants with and without abutments in multi-unit implant supported rehabilitation, disagrees with the result of the present study. The Authors found statistically more MBL for the implants without abutment, compared to the implants with it. However, the Authors adopted a traditional bone level implant, which differs from the implant design used in the present study. Among the advantages of transmucosal tissue level implants with convergent collar,[23] such as soft tissue thickness increasing,[28] this implant design is characterized by a prosthetic platform which is far from the bone level and, consequently, avoids the presence of micro-gaps at the transmucosal level. Therefore, also the possible soft tissue trauma, that can occur during the prosthesis phases, are avoided.[47]

However, probably because of their recent introduction, research on this implant design is still open. The present article represents the first observational study investigating the use of transmucosal tissue level implants with a convergent collar in immediate loading full-arch rehabilitation, both with and without abutment units. Based on the results, this new implant design seems to be an optimal alternative to the traditional implants, both with and without abutments. However, a longer observational period is required to confirm the result of the study.

Limitations of the study

The main limitations of the present study are the short observational period and the absence of a control group rehabilitated with traditional bone level implants. No scatter diagram was performed prior to the univariate linear regression analysis to ensure the statistical power of the analysis. Additionally, in the present study, tissue level implants were only tested in healthy patients in accordance with the inclusion/exclusion criteria. It would be interesting to investigate in further study the possible advantages of applying this implant design also in patients presenting systemic conditions. Indeed, this class of patients

are reported to often present alteration in both the hard and soft tissue healing and different dedicated implant-prosthodontics protocols are still a matter of research.

Conclusions

Within the limitations of the present 1-year observational study, despite different variables associates, tissue level implants with a convergent collar seem to represent a valid option when applied in immediate loading full-arch rehabilitation, both with and without abutments. Further research and longer observational periods are encouraged to confirm the present result.

References

1. Jung RE, Zembic A, Pjetursson BE, Zwahlen M, Thoma DS. Systematic review of the survival rate and the incidence of biological, technical, and aesthetic complications of single crowns on implants reported in longitudinal studies with a mean follow-up of 5 years. Clin Oral Implants Res 2012;23(Suppl 6):2–21.

2. Catapano S, Ferrari M, Mobilio N, Montanari M, Corsalini M, Grande F. Comparative Analysis of the Stability of Prosthetic Screws under Cyclic Loading in Implant Prosthodontics: An In Vitro Study. Appl Sci (Basel) 2021;11:622.

3. Piscopo M, Grande F, Catapano S. Full Digital Workflow for Prosthetic Full-Arch Immediate Loading Rehabilitation Using OT-Bridge System: A Case Report. Prosthesis 2022;4:213–23.

4. Pera P, Menini M, Pesce P, Bevilacqua M, Pera F, Tealdo T. Immediate Versus Delayed Loading of Dental Implants Supporting Fixed Full-Arch Maxillary Prostheses: A 10-year Follow-up Report. Int J Prosthodont 2019;32:27–31.

5. Yao J, Tang H, Gao XL, McGrath C, Mattheos N. Patients' expectations to dental implant: a systematic review of the literature. Health Qual Life Outcomes 2014;12:153.

6. Sailer I, Strasding M, Valente NA, Zwahlen M, Liu S, Pjetursson BE. A systematic review of the survival and complication rates of zirconia-ceramic and metal-ceramic multiple-unit fixed dental prostheses. Clin Oral Implants Res 2018;29(Suppl 16):184–98.

7. Esposito M, Hirsch JM, Lekholm U, Thomsen P. Biological factors contributing to failures of osseointegrated oral implants. (I). Success criteria and epidemiology. Eur J Oral Sci 1998;106:527–51.

8. Pesce P, Canullo L, Grusovin MG, de Bruyn H, Cosyn J, Pera P. Systematic review of some prosthetic risk factors for periimplantitis. J Prosthet Dent 2015;114:346–50.

9. Apaza Alccayhuaman KA, Soto-Peñaloza D, Nakajima Y, Papageorgiou SN, Botticelli D, Lang NP. Biological and technical complications of tilted implants in comparison with straight implants supporting fixed dental prostheses. A systematic review and meta-analysis. Clin Oral Implants Res 2018;29(Suppl 18):295–308.

10. Canullo L, Penarrocha-Oltra D, Soldini C, Mazzocco F, Penarrocha M, Covani U. Microbiological assessment of the implant-abutment interface in different connections: cross-sectional study after 5 years of functional loading. Clin Oral Implants Res 2015;26:426–34.

11. Tsuge T, Hagiwara Y, Matsumura H. Marginal fit and microgaps of implant-abutment interface with internal anti-rotation configuration. Dent Mater J 2008;27:29–34.

12. Natali AN, Gasparetto A, Carniel EL, Pavan PG, Fabbro S. Interaction phenomena between oral implants and bone tissue in single and multiple implant frames under occlusal loads and misfit conditions: A numerical approach. J Biomed Mater Res B Appl Biomater 2007;83:332–9.

13. Manzella C, Bignardi C, Burello V, Carossa S, Schierano G. Method to improve passive fit of frameworks on implant-supported prostheses: an in vitro study. J Prosthet Dent 2016;116:52–8.

14. Koutouzis T, Koutouzis G, Gadalla H, Neiva R. The effect of healing abutment reconnection and disconnection on soft and hard peri-implant tissues: a short-term randomized controlled clinical trial. Int J Oral Maxillofac Implants 2013;28:807–14.

15. Menini M, Signori A, Tealdo T, Bevilacqua M, Pera F, Ravera G, *et al.* Tilted implants in the immediate loading rehabilitation of the maxilla: a systematic review. J Dent Res 2012;91:821–7.

16. Tallarico M, Canullo L, Caneva M, Özcan M. Microbial colonization at the implant-abutment interface and its possible influence on periimplantitis: A systematic review and meta-analysis. J Prosthodont Res 2017;61:233–41.

17. Alovisi M, Carossa M, Mandras N, Roana J, Costalonga M, Cavallo L, *et al.* Disinfection and Biocompatibility of Titanium Surfaces Treated with Glycine Powder Airflow and Triple Antibiotic Mixture: An In Vitro Study. Materials (Basel) 2022;15:4850.

18. Pesce P, Menini M, Tealdo T, Bevilacqua M, Pera F, Pera P. Peri-implantitis: a systematic review of recently published papers. Int J Prosthodont 2014;27:15–25.

19. Menini M, Pesce P, Delucchi F, Ambrogio G, Canepa C, Carossa M, *et al.* One-stage versus two-stage technique using two splinted extra-short implants: A multicentric split-mouth study with a one-year follow-up. Clin Implant Dent Relat Res 2022;24:602–10.

20. Corvino E, Pesce P, Camodeca F, Moses O, Iannello G, Canullo L. Clinical and radiological outcomes of implants with two different connection configurations: A randomised controlled trial. Int J Oral Implantol (New Malden) 2020;13:355–68. [Berl]

21. Gherlone EF, Capparé P, Pasciuta R, Grusovin MG, Mancini N, Burioni R. Evaluation of resistance against bacterial microleakage of a new conical implant-abutment connection versus conventional connections: an in vitro study. New Microbiol 2016;39:49–56.

22. Montemezzi P, Ferrini F, Pantaleo G, Gherlone E, Capparè P. Dental Implants with Different Neck Design: A Prospective Clinical Comparative Study with 2-Year Follow-Up. Materials (Basel) 2020;13:1029.

23. Canullo L, Menini M, Bagnasco F, Di Tullio N, Pesce P. Tissue-level versus bone-level single implants in the anterior area rehabilitated with feather-edge crowns on conical implant abutments: an up to 5-year retrospective study. J Prosthet Dent 2022;128:936–41.

24. Canullo L, Menini M, Santori G, Rakic M, Sculean A, Pesce P. Titanium abutment surface modifications and periimplant tissue behavior: a systematic review and meta-analysis. Clin Oral Investig 2020;24:1113–24.

25. Menini M, Dellepiane E, Deiana T, Fulcheri E, Pera P,

Pesce P. Comparison of Bone-Level and Tissue-Level Implants: A Pilot Study with a Histologic Analysis and a 4-Year Follow-up. Int J Periodont Restor Dent 2022;42:535–43.

26. Canullo L, Pesce P, Patini R, Antonacci D, Tommasato G. What Are the Effects of Different Abutment Morphologies on Peri-implant Hard and Soft Tissue Behavior? A Systematic Review and Meta-Analysis. Int J Prosthodont 2020;33:297–306.

27. Canullo L, Menini M, Covani U, Pesce P. Clinical outcomes of using a prosthetic protocol to rehabilitate tissue-level implants with a convergent collar in the esthetic zone: A 3-year prospective study. J Prosthet Dent 2020;123:246–51.

28. Carossa M, Alovisi M, Crupi A, Ambrogio G, Pera F. Full-Arch Rehabilitation Using Trans-Mucosal Tissue-Level Implants with and without Implant-Abutment Units: A Case Report. Dent J 2022;10:116.

29. Caiazzo A, Canullo L, Pesce P; Consensus Meeting Group. Consensus Report by the Italian Academy of Osseointegration on the Use of Antibiotics and Antiseptic Agents in Implant Surgery. Int J Oral Maxillofac Implants 2021;36:103–5.

30. Canullo L, Troiano G, Sbricoli L, Guazzo R, Laino L, Caiazzo A, *et al.* The Use of Antibiotics in Implant Therapy: A Systematic Review and Meta-Analysis with Trial Sequential Analysis on Early Implant Failure. Int J Oral Maxillofac Implants 2020;35:485–94.

31. Tealdo T, Menini M, Bevilacqua M, Pera F, Pesce P, Signori A, *et al.* Immediate versus delayed loading of dental implants in edentulous patients' maxillae: a 6-year prospective study. Int J Prosthodont 2014;27:207–14.

32. Canullo L, Masucci L, Quaranta G, Patini R, Caponio VC, Pesce P, *et al.* Culturomic and quantitative real-time-polymerase chain reaction analyses for early contamination of abutments with different surfaces: A randomized clinical trial. Clin Implant Dent Relat Res 2021;23:568–78.

33. Corvino E, Pesce P, Mura R, Marcano E, Canullo L. Influence of Modified Titanium Abutment Surface on Peri-implant Soft Tissue Behavior: A Systematic Review of In Vitro Studies. Int J Oral Maxillofac Implants 2020;35:503–19.

34. Menini M, Pesce P, Bevilacqua M, Pera F, Tealdo T, Barberis F, *et al.* Effect of Framework in an Implant-Supported Full-Arch Fixed Prosthesis: 3D Finite Element Analysis. Int J Prosthodont 2015;28:627–30.

35. Pera F, Pesce P, Bagnasco F, Pancini N, Carossa M, Baldelli L, *et al.* Comparison of Milled Full-Arch Implant-Supported Frameworks Realised with a Full Digital Workflow or from Conventional Impression: A Clinical Study. Materials (Basel) 2023;16:833.

36. Pesce P, Lagazzo A, Barberis F, Repetto L, Pera F, Baldi D, *et al.* Mechanical characterisation of multi vs. uni-directional carbon fiber frameworks for dental implant applications. Mater Sci Eng C 2019;102:186–91.

37. Tecco S, Grusovin MG, Sciara S, Bova F, Pantaleo G, Capparé P. The association between three attitude-related indexes of oral hygiene and secondary implant failures: A retrospective longitudinal study. Int J Dent Hyg 2018;16:372–9.

38. Testori T, Del Fabbro M, Capelli M, Zuffetti F, Francetti L, Weinstein RL. Immediate occlusal loading and tilted implants for the rehabilitation of the atrophic edentulous maxilla: 1-year interim results of a multicenter prospective study. Clin Oral Implants Res 2008;19:227–32.

39. Francetti L, Romeo D, Corbella S, Taschieri S, Del Fabbro M. Bone level changes around axial and tilted implants in full-arch fixed immediate restorations. Interim results of a prospective study. Clin Implant Dent Relat Res 2012;14:646–54.

40. Del Fabbro M, Pozzi A, Romeo D, de Araújo Nobre M, Agliardi E. Outcomes of Fixed Full-Arch Rehabilitations Supported by Tilted and Axially Placed Implants: A Systematic Review and Meta-Analysis. Int J Oral Maxillofac Implants 2022;37:1003–25.

41. Gherlone EF, D'Orto B, Nagni M, Capparè P, Vinci R. Tilted Implants and Sinus Floor Elevation Techniques Compared in Posterior Edentulous Maxilla: A Retrospective Clinical Study over Four Years of Follow-Up. Appl Sci (Basel) 2022;12:6729.

42. Costa Castillo M, Laguna Martos M, Marco Pitarch R, García Selva M, Del Cid Rodríguez S, Fons-Badal C, *et al.* Analysis of Peri-Implant Bone Loss with a Convergent Transmucosal Morphology: Retrospective Clinical Study. Int J Environ Res Public Health 2022;19:3443.

43. Pera F, Menini M, Alovisi M, Crupi A, Ambrogio G, Asero S, *et al.* Can Abutment with Novel Superlattice CrN/NbN Coatings Influence Peri-Implant Tissue Health and Implant Survival Rate Compared to Machined Abutment? 6-Month Results from a Multi-Center Split-Mouth Randomized Control Trial. Materials (Basel) 2022;16:246.

44. Ortensi L, Ortensi M, Minghelli A, Grande F. Implant-Supported Prosthetic Therapy of an Edentulous Patient: Clinical and Technical Aspects. Prosthesis 2020;2:140–52.

45. Grande F, Pozzan MC, Marconato R, Mollica F, Catapano S. Evaluation of Load Distribution in a Mandibular Model with Four Implants Depending on the Number of Prosthetic Screws Used for OT-Bridge System: A Finite Element Analysis (FEA). Materials (Basel) 2022;15:7963.

46. Göthberg C, Gröndahl K, Omar O, Thomsen P, Slotte C. Bone and soft tissue outcomes, risk factors, and complications of implant-supported prostheses: 5-Years RCT with different abutment types and loading protocols. Clin Implant Dent Relat Res 2018;20:313–21.

47. Pozzan MC, Grande F, Mochi Zamperoli E, Tesini F, Carossa M, Catapano S. Assessment of Preload Loss after Cyclic Loading in the OT Bridge System in an "All-on-Four" Rehabilitation Model in the Absence of One and Two Prosthesis Screws. Materials (Basel) 2022;15:1582.

Conflicts of interest

The authors certify that there is no conflict of interest with any financial organization regarding the material discussed in the manuscript.

Authors' contributions

Paolo Pesce and Francesco Pera share the first authorship; Nicola Scotti and Massimo Carossa share the last authorship. Francesco Pera, Paolo Pesce, Maria Menini and Massimo Carossa have given substantial contributions to the conception or the design of the manuscript; Armando Crupi, Giulia Ambrogio, Giulia Cianciotta, Francesco Fanelli and Byung Chan Kim to acquisition, analysis and interpretation of the data, Massimo Carossa and Paolo Pesce drafted the manuscript and Yaniv Mayer, Gaetano Isola, Khrystyna Zhurakivska and Nicola Scotti revised it critically. All authors read and approved the final version of the manuscript.

Acknowledgements

The authors wish to acknowledge Sweden & Martina for provided part of the surgical materials.

History

Article first published online: May 16, 2023. - Manuscript accepted: April 11, 2023. - Manuscript revised: March 23, 2023. - Manuscript received: December 29, 2022.