

Minimally Invasive Lateral Retroperitoneal Approach for Resection of Extraforaminal Lumbar Schwannomas: Results After 1-Year Follow-Up

Original

Minimally Invasive Lateral Retroperitoneal Approach for Resection of Extraforaminal Lumbar Schwannomas: Results After 1-Year Follow-Up / Ajello, M.; Lo Bue, E.; Colonna, S.; De Marco, R.; Panico, F.; Morello, A.; Castaldo, M.; Palmieri, G.; Marengo, N.; Garbossa, D.; Cofano, F.. - In: WORLD NEUROSURGERY. - ISSN 1878-8750. - 198:(2025). [10.1016/j.wneu.2025.124004]

Availability:

This version is available at: 11583/3008587 since: 2026-03-11T08:28:03Z

Publisher:

Elsevier

Published

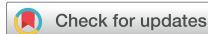DOI:10.1016/j.wneu.2025.124004

Terms of use:

This article is made available under terms and conditions as specified in the corresponding bibliographic description in the repository

Publisher copyright

(Article begins on next page)



Minimally Invasive Lateral Retroperitoneal Approach for Resection of Extraforaminal Lumbar Schwannomas: Results After 1-Year Follow-Up

Marco Ajello, Enrico Lo Bue, Stefano Colonna, Raffaele De Marco, Flavio Panico, Alberto Morello, Margherita Castaldo, Giuseppe Palmieri, Nicola Marengo, Diego Garbossa, Fabio Cofano

■ **OBJECTIVE:** Extradural spinal nerve sheath tumors with foraminal involvement are rare, and the gold standard for surgical resection is not established yet. Traditionally, lumbar intra-extraforaminal schwannomas have been resected through a posterior midline or paraspinous open approach. The lateral transposas approach represents a suitable, minimally invasive approach which can provide direct access to the extraforaminal and lumbar plexus region avoiding bone removal, hence the necessity of lumbar fusion. The aim of this study is to share our experience of extraforaminal lumbar schwannomas approached through a minimally invasive lateral transposas technique with intraoperative neurophysiological monitoring.

■ **METHODS:** This is a single-center retrospective case series study. Seven adult patients who underwent extraforaminal lumbar schwannoma removal through a lateral retroperitoneal approach were enrolled. A detailed description of the surgical technique is reported. The outcome measures included mean surgical duration, mean blood loss, postoperative mobilization, day of discharge, complication, postoperative symptoms, and extent of removal. All patients had a minimum follow-up of 1 year.

■ **RESULTS:** The average age was 51 years. Surgery lasted 225 minutes on average, with minimal blood loss. One patient had a cerebrospinal fluid leak, which was successfully repaired. Most patients were mobilized the day after surgery and 6 were discharged within 2–4 days. At a 12-month follow-up, 6 patients showed symptom

improvement and magnetic resonance imaging confirmed complete tumor resection in all cases.

■ **CONCLUSIONS:** Retroperitoneal transposas approach represents a safe tool in the neurosurgeon's armamentarium, particularly suitable for this subset of tumors representing a short and direct way to approach them. Surgeon confidence of working inside the psoas and close to the lumbar plexus is increased using continuous electromyography monitoring. At the end, the retroperitoneal transposas approach for extraforaminal lumbar schwannoma can provide minimal soft tissue damage, better pain control, decreased blood loss, and short hospitalization.

INTRODUCTION

Extradural spinal nerve sheath tumors that extend through the intervertebral foramen are rare and represent only the 0.7%–4.2% of all spinal nerve sheath tumors.¹ Due to their rarity, the gold standard for surgical resection of lumbar intra-extraforaminal schwannomas is not yet established. Traditionally, lumbar foraminal and extraforaminal schwannomas have been resected via posterior midline approach, or a paraspinous open approach. Based on tumor size, location, and characteristics, these strategies often require concomitant hemilaminectomy and facetectomy to expose and remove the tumor completely. Complete facetectomy results in loss of stability in the lumbar spine; hence, fusion for stabilization is usually recommended.^{2–7} More recently, less invasive techniques such as endoscope-assisted or

Key words

- Extraforaminal tumor
- Lateral retroperitoneal approach
- Lumbar schwannoma
- Minimally invasive spine surgery

Abbreviations and Acronyms

- CSF:** Cerebrospinal fluid
EMG: Electromyography
MRI: Magnetic resonance imaging
WHO: World Health Organization

Neurosurgery Unit, Department of Neuroscience "Rita Levi Montalcini", "Città della Salute e della Scienza" University Hospital, University of Turin, Turin, Italy

Marco Ajello and Enrico Lo Bue both contributed equally to this work.

To whom correspondence should be addressed: Alberto Morello, M.D.
[E-mail: alberto.morello@unito.it]

Citation: *World Neurosurg.* (2025) 198:124004.

<https://doi.org/10.1016/j.wneu.2025.124004>

Journal homepage: www.journals.elsevier.com/world-neurosurgery

Available online: www.sciencedirect.com

1878-8750/© 2025 The Author(s). Published by Elsevier Inc. This is an open access article under the CC BY license (<http://creativecommons.org/licenses/by/4.0/>).

lateral transposas approach have become increasingly used and only case report or small case series have been reported.⁸⁻¹² The advantages of these approaches are minimal soft tissue damage, better pain control, reduction of intraoperative blood loss, short hospitalization, and better control of neural structures such as lumbar plexus during resection. The lateral transposas approach represents a suitable, minimally invasive approach which can provide direct access to the extraforaminal and lumbar plexus region avoiding bone removal, hence the necessity of lumbar fusion.¹³⁻¹⁶

The surgical nuances of this approach were described only in some case reports.^{17,18} Considering this, the aim of the study is to share our experience, consisting of 7 cases of extraforaminal lumbar schwannomas approached via a minimally invasive lateral transposas technique with intraoperative neurophysiological monitoring, and to analyze the clinical and radiological outcomes after surgery.

MATERIALS AND METHODS

This is a single-center retrospective case series study that was conducted at the Department of Neurosurgery of the University Hospital of Turin, Italy. All adult patients who underwent foraminal-extraforaminal lumbar schwannoma removal with a minimally invasive lateral retroperitoneal approach were considered eligible for the study.

Inclusion criteria were as follows: patients aged more than 18 years, patients with a symptomatic foraminal-extraforaminal tumor, patients with foraminal-extraforaminal tumor in growth, tumor size more than 1.5 cm, and histological confirmation of benign schwannoma diagnosis (Grade I, World Health Organization [WHO] 2016 or Grade I, WHO 2021). In all cases, surgical indication was based on the presence of neurological symptoms such as motor deficit, paresthesia, and radiculopathy, or in case of dimensional growth of the tumor.

Exclusion criteria were as follows: tumors with intracanal involvement that surpass the medial margin of the pedicle regardless of the dural involvement and tumor size more than 7 cm with eventual extrapsoas extension. In case of large lesion size, there is a higher possibility of extrapsoas extension, and thus a greater risk of involvement of arterial and venous vessels. For this reason, a postero-lateral approach with a traditional extracavitary laparotomy was preferred for the management of a possible complication. All the surgeries were performed by the same surgeon (M. A.).

The outcomes measures included mean surgical duration, mean intraoperative blood loss, day of postoperative mobilization, day of discharge, complication rate, postoperative symptoms, and extent of tumor removal. The same surgical technique was applied in all the cases.

Surgical Technique

The patients were all placed in lateral position depending on the side of the schwannoma. The upper leg was slightly flexed over the pelvis and the hips were positioned just below the bed tilting point to minimize chest and iliac crest obstruction after the bed folding (Figure 1). The bed folding should not be excessive to avoid psoas

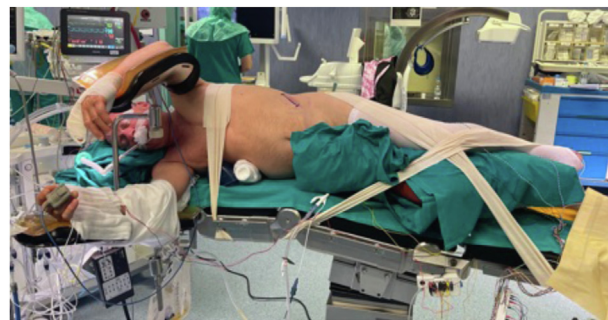

Figure 1. Operative room setup and patient positioning.

tension and lumbar plexopathies due to patient positioning (no more than 15°–20°).

The lumbar vertebral bodies and adjacent foramen involved were identified with fluoroscopy and then marked on the patient's skin. An oblique incision was made in the lateral abdominal wall at the fluoroscopic reference point, following the superior border of the iliac crest or the inferior border of the costal arch, depending on the level of interest (Figure 1). A sharp dissection of oblique muscles and transverse fascia was performed to reach the retroperitoneal space (Figure 2). Following the access to the retroperitoneal space, ileo-psoas muscle was identified and blunt dissection between the fibers was performed until the tumor was identified. An initial dilator was used (Figure 3) and secured on the anterior-lateral aspect of the tumor sparing the psoas. The dilator used in this case series

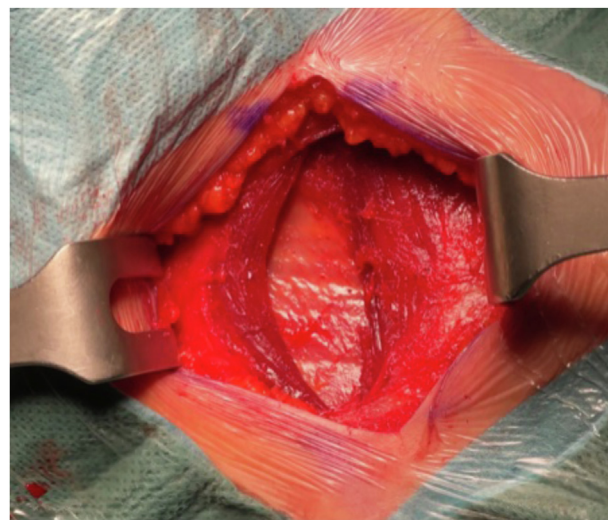


Figure 2. Intraoperative procedure: exposure of transverse fascia after oblique muscles dissection.

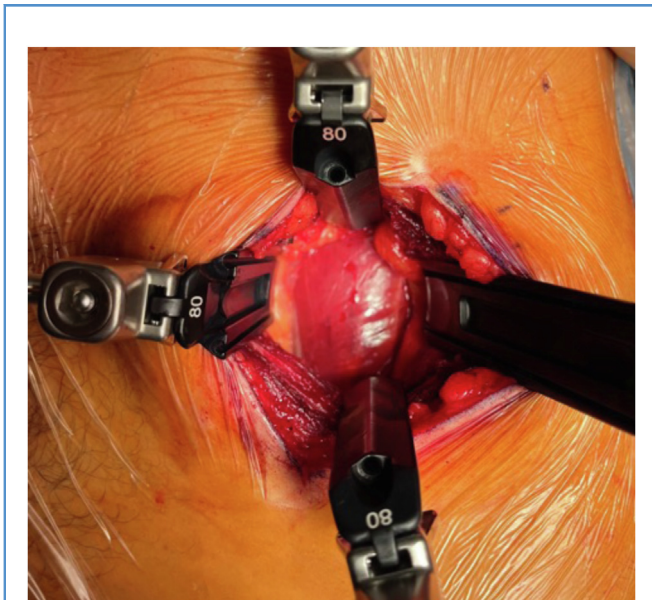


Figure 3. Intraoperative procedure: exposure of psoas muscle.

was the Supine ALIF Access System (Nuvasive) or the SynFrame (Johnson & Johnson), although any type of classic rings for the anterior approach to the spine is recommended. Through digital palpation, the presence of a neurinoma within the psoas muscle was identified. If it is not felt upon palpation, intraoperative fluoroscopy is recommended to determine the optimal entry point into the psoas muscle.

Fibers and lumbar plexus nerves were found ventral/medial to the tumor in 5 cases and dorsal/lateral in 2 cases; the role of fiber disposition during tumor excision is discussed below. Using a microscopic or exoscope-assisted technique, the dorsal segmental vessels were recognized; after direct stimulation, the vessels were coagulated and then cut. The tumor capsule was exposed and circumferentially dissected. After tumor surface direct stimulation (Figure 4), the tumor capsule was incised (Figure 5) and the tumor was centrally debulked (Figure 6). After electromyography (EMG) root stimulation demonstrating absence of activity, the nerve was coagulated and divided with bipolar cautery and the tumor was radically removed. The surgical technique included the support of microscope or exoscope. Given the length of the work using the retroperitoneal corridor, the requirements for the use of specific microsurgical instruments were the long handpiece for the Sonopet Ultrasonic Aspirator and in addition the dissectors and bipolars routinely used in abdominal surgery.

RESULTS

Seven consecutive patients underwent mini-open surgical treatment of lumbar-extradural and extraforaminal tumors between September 2017 and March 2023. Patients' consent and clinical information were obtained under the guidelines of the institutional review board.

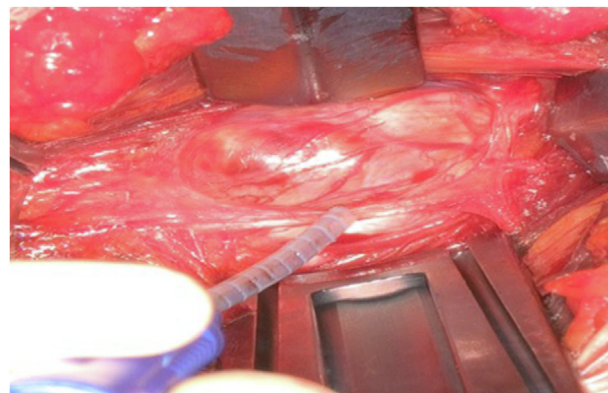


Figure 4. Intraoperative procedure: tumor exposure and nerve fibers stimulation (exoscope view).

The mean patient age of our case series was 51 years (range: 38–61 years), including 4 male patients and 3 female patients. Preoperative evaluation consisted of physical examination and imaging, including contrast-enhanced magnetic resonance imaging (MRI) and abdominal computed tomography angiography scan. In all our cases, a preoperative contrast-enhanced MRI revealed the presence of a lumbar extradural and extraforaminal tumor. Pathologic examination of the specimen confirmed the diagnosis of a benign schwannoma (Grade I, WHO 2016 or Grade I, WHO 2021) for all the patients.

The mean duration of the surgical procedure was 225 minutes (range: 200–245 minutes). All the patients had less than 200 mL intraoperative blood loss. In 1 case, there was a surgical complication consisting in an accidental cerebrospinal fluid (CSF) leak at the point of spinal root emergence, during traction maneuvers. The CSF leak was repaired with the application of medicated sponge coated with human fibrinogen and human thrombin and fibrin glue, with no postoperative sequelae. No other postoperative complications were reported. Most patients (6 cases of the total of 7) were mobilized 1 day after surgery. In 4 cases, the patients were discharged at home after 2 days; in 2 cases, the

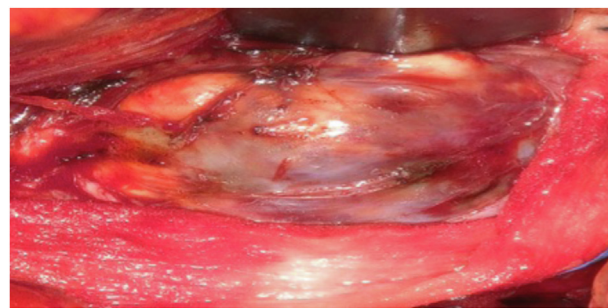


Figure 5. Intraoperative procedure: exposure and coagulation of tumor capsule (exoscope view).

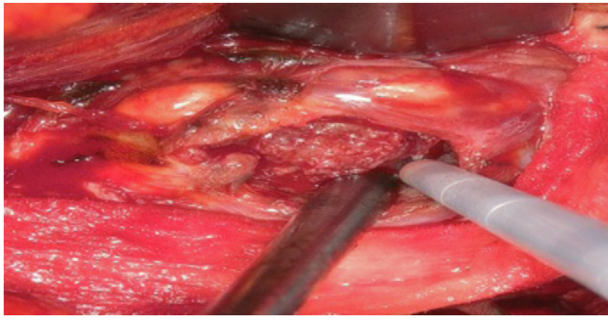


Figure 6. Intraoperative procedure: debulking of the tumor with ultrasonic aspirator (exoscope view).

patients were discharged after 4 days due to a new-onset transient paresthesia. Only 1 patient was mobilized 3 days after surgery and discharged 5 days after surgery, as a precaution for the CSF leak.

The mean follow-up was 12 months. During the follow-up, most patients (6 cases of the total of 7) reported an improvement of the preoperative symptoms: in 4 cases, there was an improvement of preoperative radiculopathy; in 1 case, there was a total recovery of the preoperative motor deficit; in 1 case, there was a neurological stability, considering the absence of preoperative symptoms; in only 1 case, there was a new onset of L3 paresthesia, which responded to pharmacological therapy. The MRI obtained 3 months after surgery confirmed the gross total resection of the tumor with no residual pathological signs in all cases (Figures 7 and 8). The complete results are reported in Table 1.

DISCUSSION

Schwannomas are benign tumors arising from the peripheral nerve sheath. They are the most common spinal tumors, accounting for almost one third of primary spinal neoplasm. Approximately 4% of these tumors arise in the setting of Neurofibromatosis 2, while they are predominantly sporadic and the 70%–80% of them are purely intradural.^{19–21} Lumbar schwannomas are generally benign and present with radicular symptoms

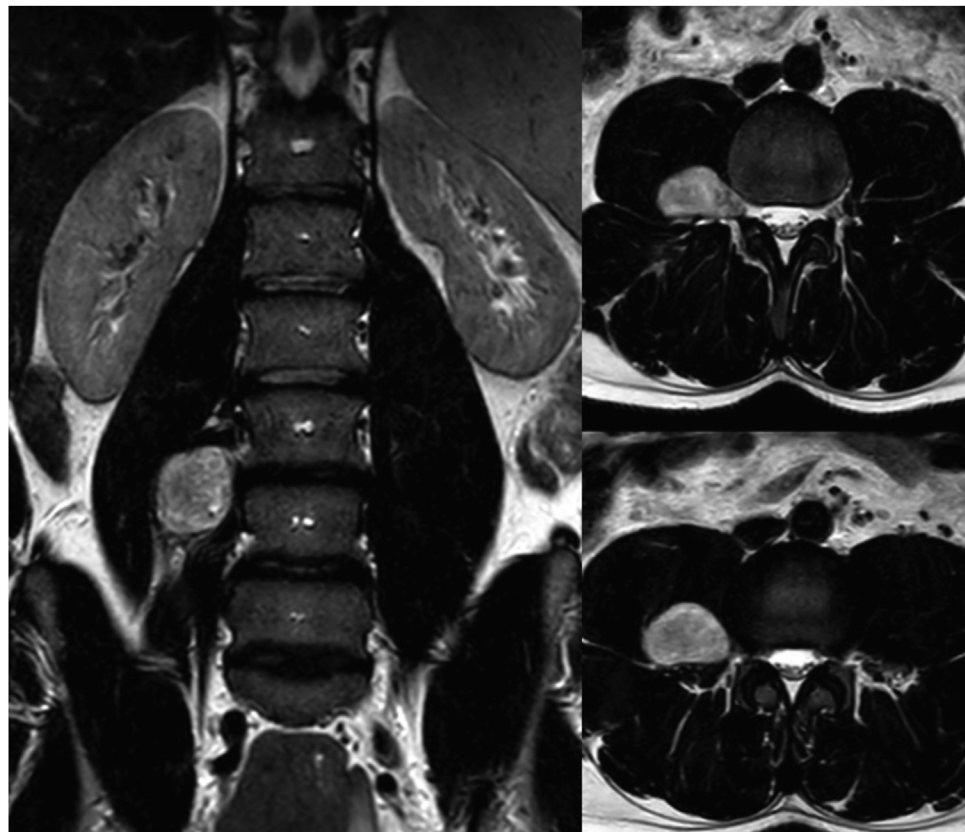


Figure 7. Preoperative contrast-enhanced MRI imaging showing right L3–L4 intra-extraforaminal schwannoma. MRI, magnetic resonance imaging.

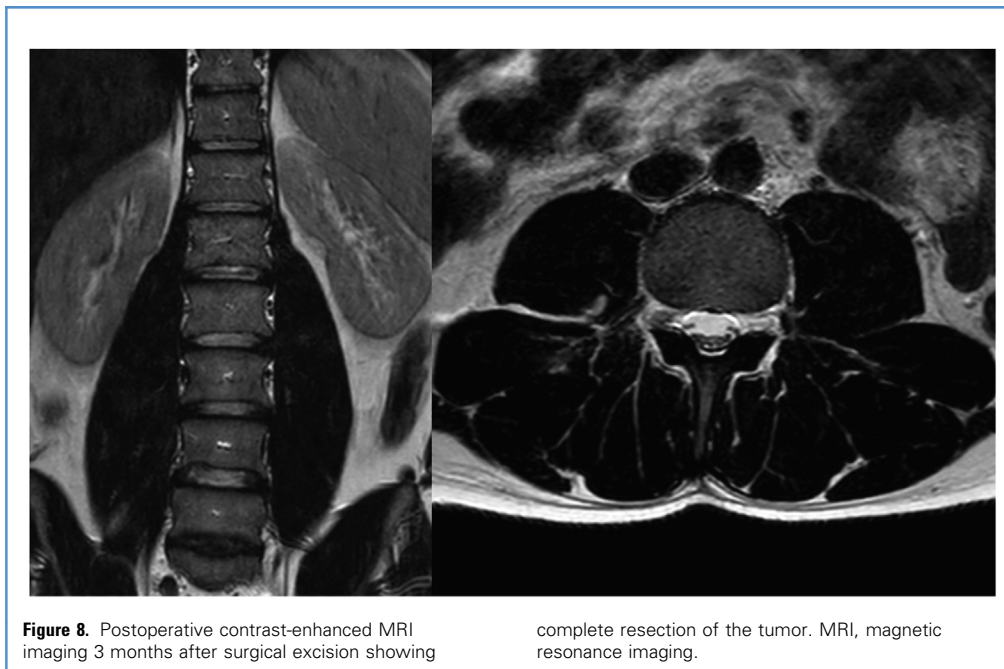


Figure 8. Postoperative contrast-enhanced MRI imaging 3 months after surgical excision showing

complete resection of the tumor. MRI, magnetic resonance imaging.

including pain, paresthesia, and weakness in the lower extremities depending on the involved nerve.^{22,23} The traditional surgical approach for lumbar foraminal and extraforaminal schwannomas involves resection through a posterior midline approach, or a paraspinous open approach, which often requires concomitant hemilaminectomy and/or facetectomy to expose and remove the tumor completely.²⁻⁷

The first case of minimally invasive approach for resection of lumbar plexus schwannoma was described in 2015 by Lee and Srikantha in a patient with 5 cm lumbar plexus schwannoma and concomitant L4–L5 spondylolisthesis.²⁴ The patient underwent minimally invasive retroperitoneal approach and L4–L5 interbody fusion; the patient presented a transient postoperatively hip flexor weakness, completely resolved at 3-month follow-up. In 3 other case reports, the retroperitoneal approach was evaluated for the resection of extraforaminal schwannomas, with transient or absent postoperative motor weakness.^{25,26}

It was recently reported the use of less invasive approaches to these lesions, including the endoscope-assisted surgery which combines the advantages of all the minimal invasive approaches in comparison with the classical open posterior approach and the advantages offered by the endoscope magnification.²⁷

In the subset of extraforaminal and lumbar plexus schwannomas, the minimal invasive lateral transposas approach provides direct access with minimal disruption of normal tissue, as showed in our case series. It is also confirmed by recent studies that demonstrated an association between this approach and minor intraoperative blood loss and shorter hospital stay.²⁸⁻³¹

The direct visualization of the tumor and the plexus nerves, the continuous EMG stimulation, and the minimal tissue damage are the most important advantages of this procedure. It can reach a

maximal safe gross total resection of the tumor with minimal blood loss and without the need of muscle skeletonization or bone disruption. This results in better pain control and, consequently, earlier mobilization.

The role of intraoperative EMG monitoring and stimulation is crucial for this approach. Direct stimulation allows for the identification of the lumbar plexus and its relationship to the tumor. In most cases (5 of 7), the lumbar plexus was located ventrally/medially in relation to the tumor. As a result, during the removal, no traction or trauma occurred on the nerves, as they were only visualized at the end of the procedure. In 2 of 7 cases, the plexus fibers were situated dorsally/laterally to the tumor. In these instances, we opted to debulk the tumor before proceeding with dissection to avoid nerve injuries caused by direct trauma or traction. Additionally, thanks to EMG monitoring and direct stimulation, and considering the minimal manipulation of the plexus, our series did not report any cases of postoperative psoas muscle weakness or other neurological complications.

Moreover, the use of retroperitoneal transposas approach in extraforaminal/intraforaminal schwannomas appears extremely beneficial due to the avoidance of bone removal. In particular, the access to the foraminal region with a lumbar facetectomy would often require stabilization and fusion surgery that could be associated with higher morbidities than mini-invasive approaches. Nevertheless, in case of intra-extraforaminal tumor or in case of large tumors (> 7 cm), it could be necessary to perform an open posterior approach (with or without subsequently fusion surgery) or a bigger traditional laparotomy for a better control of retroperitoneal structures. Hence, a tailored management must be considered for each patient.²⁴ Furthermore, the advantage of this approach is for patients of all ages: in young patients, it could be safe

Table 1. Complete Intraoperative and Postoperative Results

Patient	Sex, Age (years)	Location	Tumor Dimension (mm, Maximum Diameter)	Operative Time (minutes)	Preoperative Symptoms	Neurophysiologic Monitoring	Intraoperative Blood Loss (mL)	Postoperative Complications	Postoperative Mobilization Day	Late Complications	Postoperative Psoas Deficit	Day of Discharge	Postoperative Clinical Features	Extent of Removal
1	M, 38	L2–L3	20	220	Radiculopathy	Stable monitoring during surgery	<200	No	1	No	No	2	Improvement of radiculopathy	GTR
2	F, 48	L3–L4	15	240	None	Stable monitoring during surgery	<200	CSF leak	3	No	No	4	New onset L3 paresthesia	GTR
3	M, 54	L4–L5	50	240	None	Increase of femoral nerve stimulation threshold	<200	No	1	No	No	2	Neurological stability	GTR
4	M, 46	L2–L3	40	245	Radiculopathy	Stable monitoring during surgery	<200	No	1	No	No	2	Improvement of radiculopathy	GTR
5	M, 49	L3–L4	30	215	Motor deficit	Decreased evoked motor potentials of left quadriceps nerve	<200	No	1	No	Yes	6	Total recovery of the deficit	GTR
6	F, 61	L3–L4	25	200	Radiculopathy	Stable monitoring during surgery	<200	No	1	No	No	4	Improvement of radiculopathy	GTR
7	F, 60	L4–L5	35	220	Radiculopathy	Stable monitoring during surgery	<200	No	1	No	No	2	Improvement of radiculopathy	GTR

M, male; F, female; CSF, cerebrospinal fluid; GTR, gross total resection.

avoiding fusion surgery; in adult/older patients, lower blood loss and early postoperative mobilization are truly beneficial aspects.

Our experience suggests that retroperitoneal transpsoas approach is safe and it is associated with low morbidities in selected cases. Only 1 case of CSF leak during surgery has been observed and treated during the tumor excision surgery, without evidence of postoperative CSF leak. In just 1 case, the patient presented a transient postoperative neurological deficit with a prompt recovery.

The most relevant limitation of this work is the retrospective design with the absence of a comparison control group treated with traditional surgical approach. The rarity of tumors respecting the inclusion criteria and the single-center type of study influenced the small sample size of only 7 patients, causing a lack of statistical evaluations and generalizability. Furthermore, the follow-up period of minimum 1 year limited the evaluations of possible longer-term complications. An aspect that could limit the use of this approach is the need for various elements, such as the abdominal surgery ring, intraoperative monitoring, microscope, or exoscope. In future, a multicentric prospective study with a larger population and a group control is encouraged to better define the advantages of this minimally invasive approach.

CONCLUSION

Our experience, although far from statistic inference, confirms the literature in terms of minimal soft tissue damage, better pain control, decreased blood loss, and short hospitalization in the retroperitoneal transpsoas approach for foraminal-extraforaminal lumbar schwannoma. Retroperitoneal transpsoas approach represents a safe tool in the neurosurgeon's armamentarium and particularly suitable for this subset of tumors because it represents a short, safe, and direct way to approach them. Moreover, surgeon confidence of working inside the psoas and very close to the lumbar plexus is further increased using continuous and directional EMG monitoring.

CRedit AUTHORSHIP CONTRIBUTION STATEMENT

Marco Ajello: Writing – review & editing, Methodology, Conceptualization. **Enrico Lo Bue:** Writing – review & editing, Methodology, Conceptualization. **Stefano Colonna:** Writing – review & editing, Investigation. **Raffaele De Marco:** Investigation, Data curation. **Flavio Panico:** Investigation, Data curation. **Alberto Morello:** Validation, Formal analysis. **Margherita Castaldo:** Data curation. **Giuseppe Palmieri:** Data curation. **Nicola Marengo:** Methodology, Conceptualization. **Diego Garbossa:** Writing – review & editing, Supervision. **Fabio Cofano:** Writing – review & editing, Supervision.

REFERENCES

- Celli P, Trillò G, Ferrante L. Spinal extradural schwannoma. *J Neurosurg Spine*. 2005;2:447-456.
- Shen Y, Zhong Y, Wang H, et al. MR imaging features of benign retroperitoneal paragangliomas and schwannomas. *BMC Neurol*. 2018;18:1.
- Vialle R, Court C, Khouri N, et al. Anatomical study of the paraspinous approach to the lumbar spine. *Eur Spine J*. 2005;14:366-371.
- Datta G, Gnanalingham KK, Peterson D, et al. Back pain and disability after lumbar laminectomy: is there a relationship to muscle retraction? *Neurosurgery*. 2004;54:1413-1420.
- Mummaneni PV, Rodts GE. The mini-open transforaminal lumbar interbody fusion. *Neurosurgery*. 2005;57(4 suppl):256-261.
- Gonçalves VM, Santiago B, Ferreira VC, et al. Minimally invasive resection of an extradural far lateral lumbar schwannoma with zygapophyseal joint sparing: surgical nuances and literature review. *Case Rep Med*. 2014;2014:739862.
- Resnick DK, Choudhri TF, Dailey AT, et al. Guidelines for the performance of fusion procedures for degenerative disease of the lumbar spine. Part 12: pedicle screw fixation as an adjunct to posterolateral fusion for low-back pain. *J Neurosurg Spine*. 2005;2:700-706.
- Moro T, Kikuchi S, Konno S, et al. An anatomic study of the lumbar plexus with respect to retroperitoneal endoscopic surgery. *Spine (Phila Pa 1976)*. 2003;28:423-427.
- Safaei MM, Ames CP, Deviren V, et al. Minimally invasive lateral retroperitoneal approach for resection of extraforaminal lumbar plexus schwannomas: operative techniques and literature review. *Oper Neurosurg (Hagerstown)*. 2018;15:516-521.
- Alqahtani A, N AlAli M, Allehiani S, et al. Laparoscopic resection of retroperitoneal intra-psoas muscle schwannoma: a case report and extensive literature review. *Int J Surg Case Rep*. 2020;74:1-9.
- Lu DC, Dhall SS, Mummaneni V. Mini-open removal of extradural foraminal tumors of the lumbar spine. *J Neurosurg Spine*. 2009;10:46-50.
- Calvanese F, Boari N, Spina A, et al. MIS removal of extraforaminal lumbar spine schwannoma using MAS-TLIF retractor: technical note. *Br J Neurosurg*. 2023;37:1901-1903.
- Ahmadian A, Deukmedjian AR, Abel N, et al. Analysis of lumbar plexopathies and nerve injury after lateral retroperitoneal transpsoas approach: diagnostic standardization. *J Neurosurg Spine*. 2013;18:289-297.
- Berends HI, Journée HL, Rácz I, et al. Multimodality intraoperative neuromonitoring in extreme lateral interbody fusion. Transcranial electrical stimulation as indispensable reevaluation. *Eur Spine J*. 2016;25:1581-1586.
- Laratta JL, Weegens R, Malone KT, et al. Minimally invasive lateral approaches for the treatment of spinal tumors: single-position surgery without the "flip". *J Spine Surg (Hong Kong)*. 2020;6:62-71.
- Uribe JS, Arredondo N, Dakwar E, et al. Defining the safe working zones using the minimally invasive lateral retroperitoneal transpsoas approach: an anatomical study. *J Neurosurg Spine*. 2010;13:260-266.
- Dakwar E, Smith WD, Malone KT, et al. Minimally invasive lateral extracavitary resection of foraminal neurofibromas. *J Clin Neurosci*. 2011;18:1510-1512.
- Uribe JS, Dakwar E, Cardona RF, et al. Minimally invasive lateral retropleural thoracolumbar approach: cadaveric feasibility study and report of 4 clinical cases. *Neurosurgery*. 2011;68:32-39.
- Jinnai T, Hoshimaru M, Koyama T, et al. Clinical characteristics of spinal nerve sheath tumors: analysis of 149 cases. *Neurosurgery*. 2005;56:510-515.
- McCormick PC, Post KD, Stein BM. Intradural extramedullary tumors in adults. *Neurosurg Clin N Am*. 1990;1:591-608.
- Umana GE, Ferini G, Harikar MM, et al. Detection of "incidentalomas" on brain and body 68Ga-DOTATOC-PET scans: a retrospective study and case illustration. *Anticancer Res*. 2022;42:5867-5873.
- Benglis DDM, Vanni S, Levi AD. An anatomical study of the lumbosacral plexus as related to the minimally invasive transpsoas approach to the lumbar spine: laboratory investigation. *J Neurosurg Spine*. 2009;10:139-144.
- Celli P. Treatment of relevant nerve roots involved in nerve sheath tumors: removal or preservation? *Neurosurgery*. 2002;51:684-692 [discussion: 692].
- Lee S, Srikantha U. Surgical management of giant lumbar extradural schwannoma: report of 3 cases. *Int J Spine Surg*. 2015;9:18.
- Benjamin CG, Oermann EK, Thomas JA, et al. Minimally invasive direct lateral transpsoas approach for the resection of a lumbar plexus schwannoma: technique report. *Surg J (New York)*. 2016;2:e66-e69.
- Boah AO, Perin NI. Lateral access to paravertebral tumors. *J Neurosurg Spine*. 2016;24:824-828.
- Shi W, Su X, Li W, et al. Laparoscopic-assisted resection for retroperitoneal dumbbell-shaped

- lumbar spinal schwannomas: operative technique and surgical results. *World Neurosurg.* 2016;91:129-132.
28. Bergey DL, Villavicencio AT, Goldstein T, et al. Endoscopic lateral transpoas approach to the lumbar spine. *Spine (Phila Pa 1976)*. 2004;29:1681-1688.
29. O'Toole JE, Eichholz KM, Fessler RG. Minimally invasive approaches to vertebral column and spinal cord tumors. *Neurosurg Clin N Am.* 2006;17:491-506.
30. Ozgur BM, Aryan HE, Pimenta L, et al. Extreme Lateral Interbody Fusion (XLIF): a novel surgical

- technique for anterior lumbar interbody fusion. *Spine J.* 2006;6:435-443.
31. Shah M, Kaminsky J, Vougioukas VI. Minimally invasive removal of an extradural intradiscal lumbar schwannoma. *Acta Neurochir (Wien)*. 2008;150:691-693.

Conflict of interest statement: The authors declare that the article content was composed in the absence of any

commercial or financial relationships that could be construed as a potential conflict of interest.

Received 31 March 2025; accepted 16 April 2025

Citation: World Neurosurg. (2025) 198:124004.

<https://doi.org/10.1016/j.wneu.2025.124004>

Journal homepage: www.journals.elsevier.com/world-neurosurgery

Available online: www.sciencedirect.com

1878-8750/© 2025 The Author(s). Published by Elsevier Inc.

This is an open access article under the CC BY license

(<http://creativecommons.org/licenses/by/4.0/>).