POLITECNICO DI TORINO
Repository ISTITUZIONALE

Handling Extensive Mitral Annular Calcification via a Minimally Invasive Right Mini-Thoracotomy Approach

Original
Handling Extensive Mitral Annular Calcification via a Minimally Invasive Right Mini-Thoracotomy Approach / Barbero, C., Spitaleri, A., Pocar, M., Parrella, B., Santonocito, A., Bozzo, E., Depaoli, A., Faletti, R., Rinaldi, M.. - In: APPLIED SCIENCES. - ISSN 2076-3417. - 13:4(2023). [10.3390/app13042563]

Availability:
This version is available at: 11583/2999838 since: 2025-05-04T13:58:51Z

Publisher:
MDPI

Published
DOI:10.3390/app13042563

Terms of use:

This article is made available under terms and conditions as specified in the corresponding bibliographic description in the repository

Publisher copyright

(Article begins on next page)

26 November 2026

applied sciences

IMPACT FACTOR 2.838

CITESCORE 3.7

Article

Handling Extensive Mitral Annular Calcification via a Minimally Invasive Right Mini-Thoracotomy Approach

Cristina Barbero, Antonio Spitaleri, Marco Pocar, Barbara Parrella, Ambra Santonocito, Elena Bozzo, Alessandro Depaoli, Riccardo Faletti and Mauro Rinaldi

Special Issue

Biomedical Imaging Technologies for Cardiovascular Disease - Volume II

Edited by

Dr. Julio Garcia Flores

MDPI

https://doi.org/10.3390/app13042563

applied sciences

MDPI

Article

Handling Extensive Mitral Annular Calcification via a Minimally Invasive Right Mini-Thoracotomy Approach

Cristina Barbero [1,*], Antonio Spitaleri [1], Marco Pocar [1,2], Barbara Parrella [1], Ambra Santonocito [3], Elena Bozzo [3], Alessandro Depaoli [3,4], Riccardo Faletti [3] and Mauro Rinaldi [1]

[1] Division of Cardiac Surgery, Città della Salute e della Scienza & Department of Surgical Sciences, University of Turin, Corso Dogliotti 14, 10126 Turin, Italy
[2] Department of Clinical Sciences and Community Health, University of Milan, 20122 Milan, Italy
[3] 1st Unit of Radiology, Department of Surgical Sciences, University of Turin, 10124 Turin, Italy
[4] Unit of Radiology, Diagnostic Area Department, Hospital of Ivrea ASL TO4, 10015 Ivrea, Italy
* Correspondence: cristina.barbero@unito.it; Tel.: +39-011-6335511; Fax: +39-011-6336130

Abstract: Mitral annular calcification is a chronic and degenerative process of the fibrous base of the mitral valve. Surgical management of mitral valve dysfunction with severe annular calcification remains technically demanding and, to date, the preferred approach is still a standard full sternotomy. We aimed to analyze and report our experience with mitral valve surgery addressing annular calcification via the minimally invasive approach through a right mini-thoracotomy. Data of patients with mitral valve disease and underlying annular calcification undergoing minimally invasive surgery from 2018 to 2022 were prospectively collected and retrospectively analyzed. The severity of mitral annular calcification was categorized with an angio-computerized tomography scan analysis as mild, moderate or severe according to calcium thickness, calcium distribution, and trigone and leaflet involvement using the Mitral Annular Calcification Computerized Tomography-score. During the study period, 27 patients with mitral valve disease and associated mitral annular calcification were enrolled. The most common etiology was advanced Barlow's disease, which was encountered in 18 cases (67%). Mitral valve replacement was performed in 21 patients (78%). No intraoperative death, atrioventricular disruption, or circumflex coronary artery injury occurred. Conversion to sternotomy was necessary in a single case. Residual moderate periprosthetic leak requiring early reoperation and permanent heart block mandating permanent pacemaker implantation were reported in one and in three patients, respectively. No cases of stroke were reported. Two patients died, accounting for a 7.4% perioperative mortality. At a median follow-up of 9 months, one patient had residual moderate mitral regurgitation, whereas two patients required short-term reoperation and prosthetic valve (re)replacement. Minimally invasive mitral valve surgery via right mini-thoracotomy should be considered an and effective approach to be indicated also in patients with mild-to-severe mitral annular calcification. Routine angio-computerized tomography scan during work-up is a mandatory step to stratify the anatomical extension and severity of the mitral annular calcification.

Keywords: mitral valve; minimally invasive cardiac surgery; mitral annular calcification; Barlow's disease; mitral valve repair; mitral valve replacement; mitral valve prolapse; cardiac rupture

check for updates

Citation: Barbero, C.; Spitaleri, A.; Pocar, M.; Parrella, B.; Santonocito, A.; Bozzo, E.; Depaoli, A.; Faletti, R.; Rinaldi, M. Handling Extensive Mitral Annular Calcification via a Minimally Invasive Right Mini-Thoracotomy Approach. *Appl. Sci.* **2023**, *13*, 2563. https://doi.org/10.3390/app13042563

Academic Editor: Julio Garcia Flores

Received: 5 December 2022
Revised: 15 January 2023
Accepted: 30 January 2023
Published: 16 February 2023

Copyright: © 2023 by the authors. Licensee MDPI, Basel, Switzerland. This article is an open access article distributed under the terms and conditions of the Creative Commons Attribution (CC BY) license (https://creativecommons.org/licenses/by/4.0/).

1. Introduction

Mitral annular calcification (MAC) is a chronic and degenerative process of the fibrous base of the mitral valve (MV). Most commonly, MAC extends along the hinge of a variable portion of the posterior mitral annulus, but at times may extend to the body of the MV leaflets, to the anterior MV annulus, to one or more of the MV papillary muscles, to the posterior free wall of the left ventricle, and to the left atrium. The prevalence of MAC in the general population may reach 8 to 15% and it is associated with advanced age, female gender, risk factors for cardiovascular disease, atrial fibrillation, and variable degrees

of chronic kidney disease [1–3]. Overall, evidences in the literature depict an increased incidence of MV stenosis or regurgitation, or both, and arrhythmias in patients with MAC. Not surprisingly, the reported outcomes following MV surgery in patients with associated MAC are often less than satisfactory.

Since MAC may be viewed as a relative contraindication for surgery, the surgical management of MV dysfunction, particularly in the occurrence of severe MAC, remains a controversial issue and always implies one of the most technically demanding scenarios in contemporary adult cardiac surgery. MV operations in patients with MAC portend a higher risk of technical injury of perivalvular structures, namely, circumflex coronary injury, paravalvular leak, patient-prosthesis mismatch, and atrioventricular groove disruption [2,4,5].

In this anatomically challenging context, the preferred approach by the vast majority of cardiac surgeons is still a standard full sternotomy, and only few centers have reported limited experiences through a minimally invasive access. This is primarily dictated by the reluctance to approach the anatomical difficulties in suturing through heavily calcified annular or perivalvular tissues and effectively positioning prosthetic devices via a restricted and, at times, deep operative field. In recent years, however, institutions with long-standing experience with mini-thoracotomy MV operations have progressively extended indications also to include patients with MAC.

We aimed to analyze and report our experience with MV surgery addressing MAC via the minimally invasive approach through a right mini-thoracotomy.

2. Patients and Methods

2.1. Study Design

An observational study consisting of retrospective analysis on prospectically collected data related to patients with MAC undergoing minimally invasive MV operations since September 2018 was undertaken. Associated cardiac procedures were exclusion criteria, except for those accessible through one or more atrial incisions, most typically tricuspid valve repair or replacement, radiofrequency or cryoablation for atrial fibrillation, and atrial septal defect or patent foramen ovale closure. The study design was approved by our Institutional Review Board (protocol number 0095187). Clinical and echocardiographic follow-up was carried out through hospital outpatient controls, telephone interviews, or both. Median follow-up was 271 days (interquartile range, 102–671 days), and was 100% complete.

2.2. Echocardiographic Evaluation

Echocardiography is the preferred imaging tool to assess valvular disease. Although, traditionally, MAC may be suspected or diagnosed on chest radiographs or more clearly on cine angiograms, which also serve to define the anatomical relationships with the coronary circulation, echocardiography represents the first-line step to depict the diseased MV with MAC. More in particular, transesophageal imaging is mandatory to define leaflet involvement by the calcification and secondary restricted motion, along with the corresponding variable degree of stenosis or regurgitation, or more often both. Extension of the MAC deep into the posterior basal or, at times, mid portion of the left ventricular free must be mandatorily assessed to estimate the risk of disruption. Also the extension of the MAC to the subaortic curtain and eventual involvement of the aortic valve must be excluded when planning the feasibility of a minimally invasive MV operation. Some degree of mild or mild-to-moderate aortic insufficiency is common in this clinical setting and can safely be tolerated, whereas more severe aortic incompetence would jeopardize the effective delivery of cardioplegia in the aortic root. Three-dimensional transesophageal echocardiography is also useful to simulate the MV anatomy as viewed by the surgeon from the left atrial side. Whereas echocardiography well depicts the dynamics of the MV and MAC during the cardiac cycle, we now routinely indicate computed tomography (CT) scan to better define the density of the MAC.

2.3. Computed Tomography Imaging

The protocol included preoperative CT scan to assess and stratify the severity of the MAC in all patients. Imaging analysis was performed by two experienced radiologists. The DICOM "OsiriX MD" viewer was used for post-processing, whereby a short-axis view of the MV annulus was obtained by means of multiplanar reformatting (MPR). Mitral annular analysis was carried out through angio-CT scan with or without cardiac gating, or through basal CT scan (Figure 1). MAC severity was categorized as mild, moderate or severe according to calcium thickness, calcium distribution, and trigone and leaflet involvement using a MAC CT-score ranging from a minimum of 1 to a maximum of 10 (Figure 2). Each category was further divided into three subgroups of severity. Briefly, the MAC was considered mild with a score from 1 to 3 points, moderate from 4 to 6 and severe when the score reached or exceeded 7 points [6]. From a surgical standpoint the annular extension of the MAC is a crucial issue, with extreme circumferential 360° lesions being the most difficult to approach.

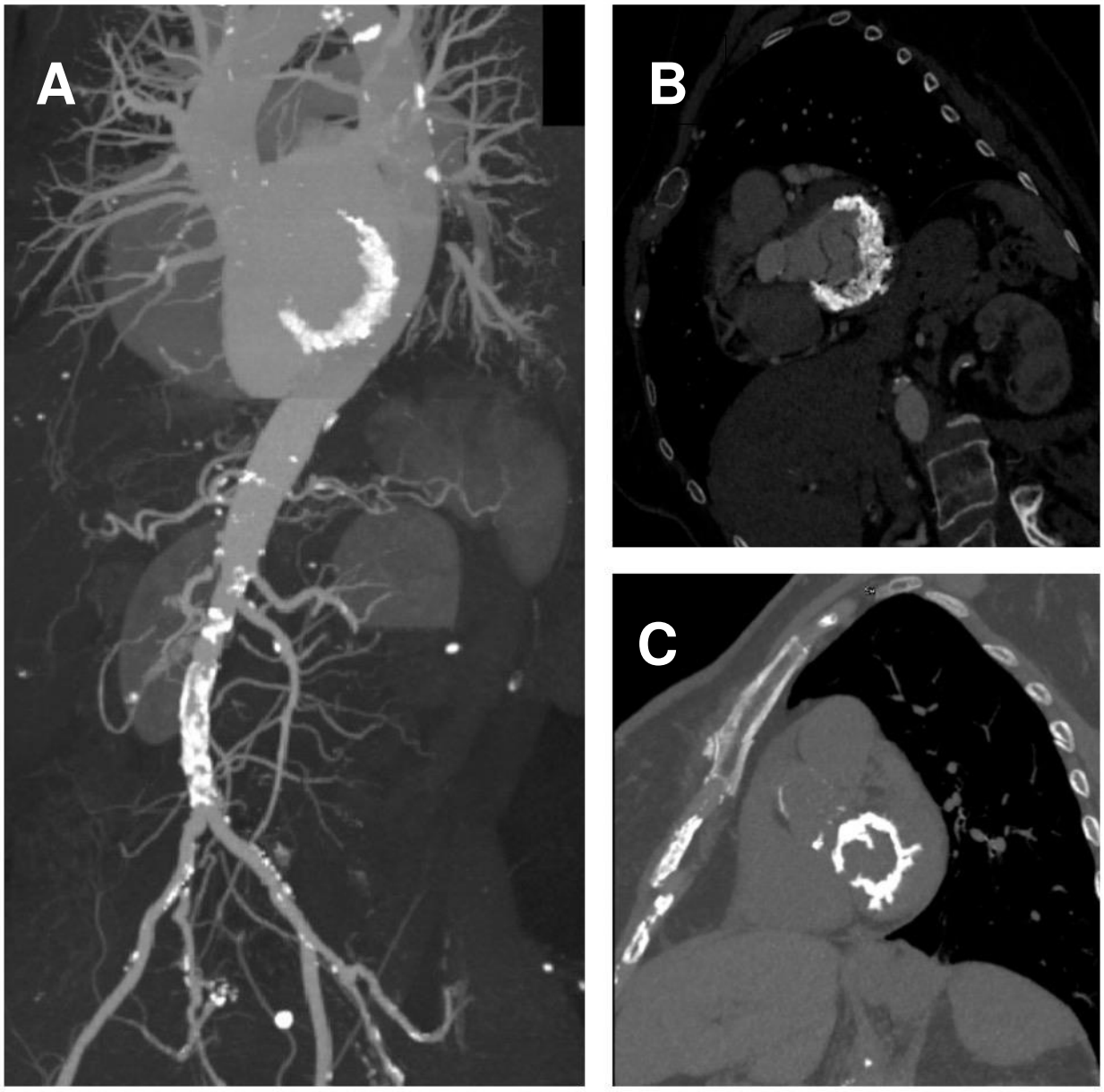

Figure 1. Severe MAC. (**A**,**B**): Heavily calcified annulus with a calcium thickness > 10 mm. (**C**): Calcium infiltration of the left ventricular free wall.

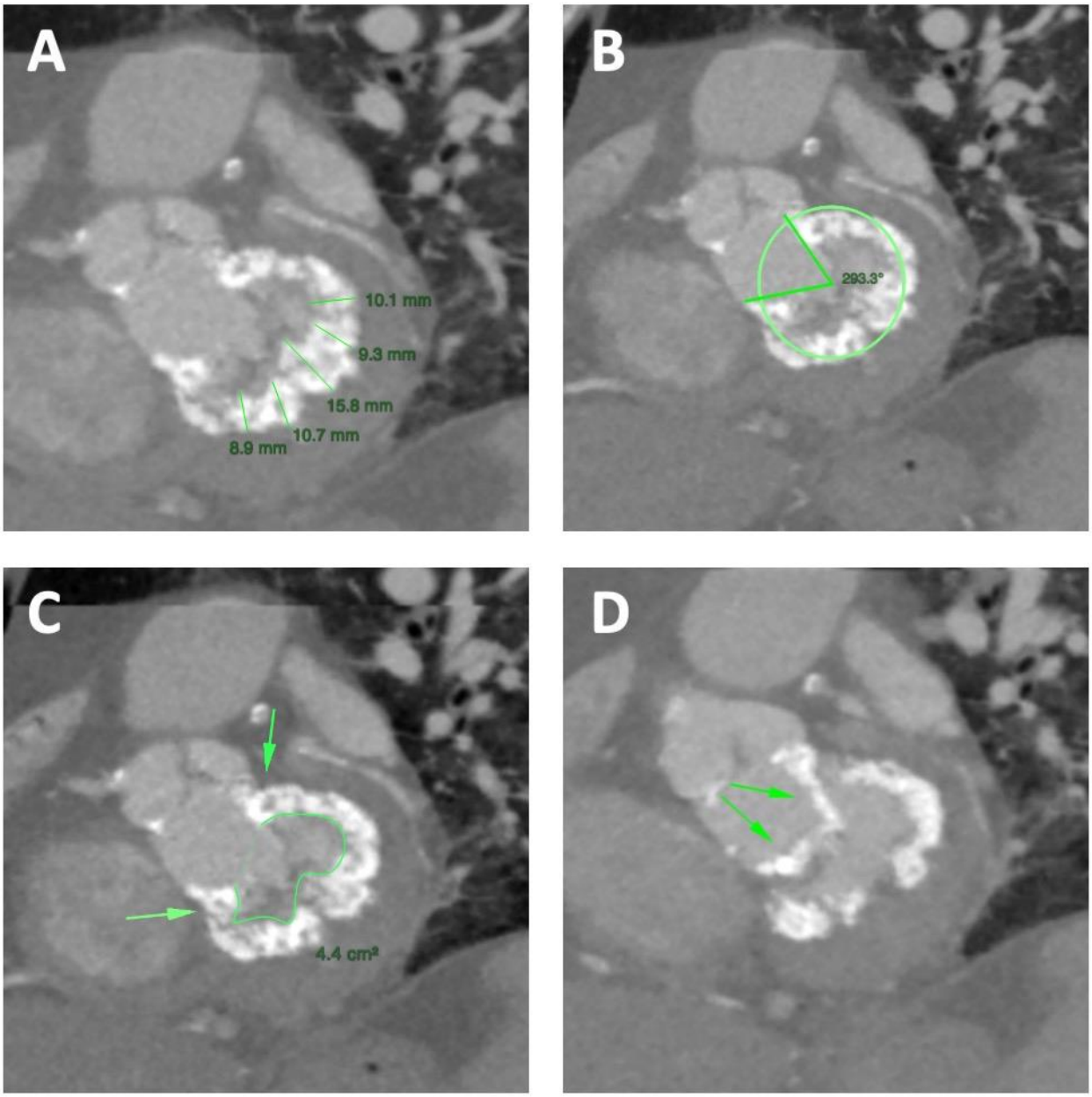

Figure 2. Cardiac computed tomography-based measurements of MAC using DICOM "OsiriX MD" viewer. (**A**) Calcium thickness measurement simulating a surgical short axis view. (**B**) Calcium distribution along the perimeter of the annulus. (**C**) Trigone involvement (arrows) and internal area of the annulus. (**D**) Leaflet involvement (arrows).

2.4. Surgical Technique

The right mini-thoracotomy approach, perfusion strategies and aortic clamping techniques adopted at our institution have been described previously [7–12]. Briefly, a double lumen endotracheal tube was positioned to allow single left lung ventilation. All patients underwent operation through a right anterolateral mini-thoracotomy in the fourth intercostal space. A soft-tissue retractor was used to expose the surgical port. No rib resection was performed in any of the patients. To improve the vision, an endoscope was inserted in an accessory port created below the working port, which also served for carbon dioxide insufflation to saturate the chest and minimize the hazards of air trapping and systemic embolism. An additional sixth intercostal space port was created for pump suction. After full heparinization, cardiopulmonary bypass was established with the patient cooled to

28–32 °C, depending on the anticipated complexity of the operation. Arterial perfusion was routinely gained with a peripheral femoral or axillary cannulation, while venous drainage was obtained via double femoral and percutaneous jugular cannulation. Axillary cannulation was indicated to provide antegrade systemic perfusion in the case of severe atherosclerotic burden [9].

Aortic clamping strategies adopted during the study period were the endoaortic clamping occlusion and the trans-thoracic clamp. In the endoaortic clamping setting, aortic occlusion and cardioplegia delivery were gained with a balloon catheter inserted through the sidearm of a 21–23F femoral arterial cannula (Intraclude®, Edwards Lifesciences, Irvine, CA, USA). In the trans-thoracic clamping setting the clamp was addressed towards the ascending aorta through the first intercostal space with a Chitwood clamp or through the main port with a Cygnet® flexible clamp. Cardioplegia was delivered through a 7F cardioplegia needle (CalMed Technologies, Santa Inez, CA, USA) placed into the proximal ascending aorta. Antegrade myocardial protection was provided with St. Thomas (Plegisol™, Hospira Inc., Lake Forest, IL, USA) or, more commonly, Custodiol (Bretschneider histidine, tryptophan, ketoglutarate solution, Köhler Chemie, Bensheim, Germany) cold crystalloid cardioplegia [12]. No additional topical cooling, nor retrograde cardioplegia through the coronary sinus, were used on any patient. Superior and inferior vena cava snaring was obtained by placing tourniquets around the vessels or by placing endovascular balloons (7F, 65 cm) (Meditech Boston Scientific Corporation, Natick, MA, USA) to provide a temporary mini right atriotomy to drain the cardioplegic solution and in patients requiring associated right atrial procedures.

The MV was exposed through a standard left atriotomy, parallel and posterior to the interatrial septum with minimal dissection of the interatrial groove. The extension of the calcification bar, leaflet involvement and the chances of valve repair were assessed. In case of valve replacement, the anterior leaflet was resected, while the posterior leaflet and corresponding chordae were left intact whenever possible to minimize the hazards of fragilization of the atrioventricular junction. In general, the least possible debridement was undertaken, primarily aimed to remove only protruding calcium which might interfere with the proper seating of the prosthesis. Nevertheless, a variable extension of posterior leaflet resection, possibly leaving in place the basal chordae, was unavoidable in some cases. Non-everting polyester 2-0 pledgetted mattress sutures were passed through the calcium just deep enough to encircle the annulus with the MAC itself, taking care to avoid injury to the circumflex artery and to the His bundle in proximity of the right trigone. In the case of caseous abscess collections, the cavity was debrided and excluded directly with the sutures used to secure the prosthetic valve. Extensive and aggressive annular decalcification was preferably avoided. Clamp release was obtained at the end of appropriate air venting at a core temperature above 33 °C.

Although we now consider this step unneccesary in younger and healthier patients undergoing minimally invasive MV operations, two epicardial temporary pacing wires were routinely placed on the right ventricle before unclamping, in relation to the hazards of atrioventricular conduction disturbances. Importantly, the latter may ensue at a later onset in the intensive care unit. This did not apply to patients with prior permanent pacemaker implantation.

Intraoperative transesophageal echocardiography was used in all the patients to guide the correct positioning of the cannulae before the onset of cardiopulmonary bypass and to analyze cardiac function, residual MV regurgitation, paravalvular leaks, and prosthetic valve gradients after the intracardiac phase of the operation.

2.5. Definitions of Adverse Events

Perioperative myocardial infarction is defined as cardiac troponin T value >10 times the 99th percentile of the upper reference limit during the first postoperative 48 h with associated electrocardiographic abnormalities and/or angiographic or imaging evidence of new onset myocardial ischemia and/or new loss of myocardial viability [13]. Low

cardiac output syndrome refers to a cardiac index lower than 2 L/min/m^2 and systolic blood pressure lower than 90 mmHg, in conjunction with signs of tissue hypoperfusion (cold periphery, clammy skin, confusion, oliguria, elevated lactate level) in the absence of hypovolemia [14]. Postoperative stroke refers to a new onset, permanent neurological disability or deficit [15]. Perioperative mortality includes all deaths occurring during hospitalization or within 30 days of the surgical procedure.

3. Results

During the study period 538 patients underwent minimally invasive MV surgery at our institution. MAC was diagnosed preoperatively and assessed with the CT scan protocol in 27 (5%). Baseline characteristics are reported in Table 1. Mean age was 71 years and the majority of patients were women (20/27, 74%). The most common etiology was advanced Barlow's disease or fibroelastic deficiency (18/27, 67%), whereas 4 cases were reoperations (15%). Long standing persistent atrial fibrillation was reported in 12 patients (44%).

Table 1. Preoperative characteristics (n = 27).

Age (Years)	71 ± 13
Female	20 (74)
BMI (kg/m^2)	23 ± 5
Euroscore II (%)	5 ± 6
Logistic Euroscore I (%)	10 ± 11
Diabetes	5 (19)
eGFR (mL/min/1.73 m^2)	53 ± 25
Previous cardiac surgery	4 (15)
LVEF (%)	62 ± 9
PAPs (mmHg)	45 ± 17
MV dysfunction	
Regurgitation	20 (74)
Regurgitation and stenosis	7 (26)
Moderate to severe tricuspid valve regurgitation	9 (33)
MV disease etiology	
Barlow/FED	18 (67)
Degenerative fibro-calcific	4 (15)
Rheumatic	3 (11)
Endocarditis	1 (4)
Failure of previous repair	1 (4)

SD: standard deviation; BMI: body mass index; eGFR: estimated glomerular filtration rate; LVEF: left ventricular ejection fraction; PAPs: pulmonary artery pressure, systolic; MV: mitral valve; FED: fibroelastic deficiency. Data are expressed as mean ± SD or as n (%).

All the patients enrolled underwent CT scan examination. Intravenous non-ionic contrast agents for cardiac gating were used in 16 patients (59%). In the latter, the analysis was performed with a Revolution CT (GE Healthcare, General Electric) scanner. Eight patients (30%) underwent standard angio CT examination, while 3 patients (11%) underwent basal CT examination. The degree of MAC severity is reported in Table 2.

Intraoperative data and postoperative outcomes are reported in Table 3. MV replacement was performed in 21 patients (78%), of whom 9 were diagnosed with severe MAC, whereas 12 showed a mild to moderate MAC. Bioprosthetic pericardial (Carpentier-Edwards Magna Ease, Edwards Lifesciences, Irvine, CA, USA) or porcine (Mosaic™, Medtronic Inc., Minneapolis, MN, USA) valves were used in almost all of the patients (20/21, 95%), confining mechanical MV replacement to a single case. The mean size in the implanted prosthetic valves was 27 ± 2.6. In the 6 patients undergoing MV repair, two patients had a severe degree of MAC, while four had mild to moderate MAC. Annuloplasty alone was sufficient in 3 patients (50%) whereas leaflet resection or artificial chordae in ePTFE (W. L. Gore & Associates Inc., Flagstaff, AZ, USA) were used in the remaining.

Table 2. Calcium distribution and MAC CT grading (n = 27).

Calcium thickness	
<5 mm	4 (15)
5–10 mm	11 (41)
>10 mm	12 (44)
Calcium distribution	
>180°	10 (37)
180°–270°	12 (44)
>270°	5 (19)
Trigones involved	
None	20 (74)
One	7 (26)
Two	–
Leaflets involved	
None	–
One	14 (52)
Two	13 (48)
MAC CT grading	
Mild	3 (11)
Moderate	13 (48)
Severe	11 (41)

MAC: mitral annular calcification; CT: computed tomography. Data are expressed as n (%).

Table 3. Intraoperative variables and postoperative outcomes (n = 27).

MV repair	6 (22)
Annuloplasty ring	6 (100)
Posterior leaflet resection	3 (50)
Artificial chords	2 (33)
MV replacement, prosthesis	21 (78)
Biological	20 (95)
Mechanical	1 (5)
Extensive annular decalcification	5 (19)
Concomitant TV Surgery	6 (22)
RAP	20 (74)
EAC	7 (26)
TTC	19 (70)
CPB (mins)	147 (127–173)
Cross-clamp (mins)	106 (84–119)
Conversion to sternotomy	1 (4)
Redo for early failure	1 (4)
Re-exploration for bleeding	2 (7)
Permanent PM implantation	3 (11)
Low cardiac output syndrome	4 (15)
Acute kidney injury	1 (4)
Dialysis	2 (7)
Vascular complication	1 (4)
Stroke	–
Perioperative myocardial infarction	–
Mechanical ventilation (hours)	15 (10–22)
ICU stay (days)	1 (1–1)
Hospital-stay (days)	7 (7–9)
30-day mortality	2 (7)
FU MV regurgitation, moderate or more	2 (7)
FU patient prosthesis mismatch (n=21)	
None or mild	19 (90)
Moderate	2 (10)
Severe	–

Table 3. *Cont.*

FU iEOA (cm^2/m^2)	1.44 ± 0.29
Follow-up (days)	271 (102–671)

MV: mitral valve; TV: tricuspid valve; RAP: retrograde arterial perfusion; EAC: endo-aortic clamp; TTC: transthoracic clamp; CPB: cardio-pulmonary bypass; IQR: interquartile range; SD: standard deviation; ICU: intensive care unit; FU: follow-up; iEOA: indexed effective orifice area. Data are expressed as median (IQR), mean ± SD, or n (%).

Extensive annular decalcification was unavoidable in 5 patients (18%) because of the impossibility to pass the sutures through the calcific bar in extremely severe MAC.

No cases of intraoperative death, atrioventricular disruption, or circumflex coronary artery injury occurred. Conversion to sternotomy was necessary in one case due to extremely unfavorable chest anatomy, with the impossibility to safely gain sufficient exposure of the ascending aorta to ensure adequate cross-clamp and safe myocardial protection.

Residual moderate periprosthetic leak requiring early reoperation on the first postoperative day, and permanent heart block requiring permanent pacemaker implantation were reported in one and in three patients, respectively. Importantly, stroke rate was zero. Two patients died, accounting for an operative mortality of 7.4%. The causes of death were multiorgan failure and septic shock on postoperative day 24 in the former, and multiorgan failure on postoperative day 14 in a patient with pre-existing severe chronic kidney disease and cirrhosis. Both displayed severe degree MAC and required MV replacement. Residual MV regurgitation at discharge was absent to mild in all patients. At follow-up, no death was observed. One patient developed moderate regurgitation following MV repair, and another patient required redo surgery for significant periprosthetic leak 14 months after surgery. Actually, this adverse event occurred in the same patient who had initially required redo surgery on postoperative day 1. At early reoperation the leak had been primarily closed through the right mini-thoracotomy with additional pledgetted sutures, but the later procedure was carried out via sternotomy and the patient underwent MV re-replacement.

4. Discussion

MAC requires technically demanding surgery, increases operative risk, and impairs the repair feasibility in patients with degenerative MV disease [16–18].

Several surgical techniques have been described to tackle this issue with varying results. These include isolated leaflet repair or resection, or implantation of artificial ePTFE chordae with or without annuloplasty [19,20], edge-to-edge MV repair [21], valve replacement with no annular calcium debridement securing the prosthesis inside the calcified annulus [22], intra-atrial insertion of a mitral prosthesis eventually with Dacron or pericardial patch interposition to form an external skirt or prosthetic neo-annulus [23,24], partial debridement of the calcific bar [25], en bloc decalcification and annular reconstruction with Dacron or pericardial patch [16], and ultrasonic debridement of the calcification [26]. Finally, extra-anatomical left atrial to left ventricular apex bypass with a valved conduit has been described by the Mayo Clinic team as an extra-anatomical solution in patients with extensive MAC [27], mimicking a technique originally performed during the Eighties at the Bambino Gesù Hospital in Rome to correct congenitally hypoplastic atrioventricular valve stenosis in children [28].

Clearly, the strategies that avoid altogether the manipulation of the MV annulus and that thus do directly address the MAC are technically more straightforward. Unfortunately, successful repair with no annuloplasty is applicable only in a minority of patients and, paradoxically, in those with less severe MACs and with minor leaflet involvement. Similarly, edge-to-edge procedures can be very easy and not time-consuming to perform, but almost invariably at the expense of some degree of residual MV regurgitation, in analogy to transcatheter edge-to-edge repair with MitraClip™ technology (Abbott Vascular, Abbott Park, IL, USA). Conversely, intra-atrial fixation of a MV prosthesis might appear a clever and appealing solution, but may not uniformly allow secure anchoring in an ectopic position and also often determines implantation of a smaller valve because the annular orifice

is blocked by the MAC, with consequently higher postoperative transvalvular gradients. Although successful off-label implantation of an upside down 23 mm or in extreme cases 21 mm St. Jude Regent (St. Jude Medical, Inc., St. Paul, MN, USA) aortic mechanical prosthesis in the mitral position has been reported, predominantly in smaller size women with MAC or prior mediastinal radiation therapy [29], gradients may be a critical issue and often imply clinically relevant patient-prosthesis mismatch with persistently elevated left atrial and pulmonary pressures and reduced long-term survival [30]. Mid- or long-term results with extra-anatomical bypass still await to be validated.

A somewhat more conservative approach to MAC with no or minimal annular debridement and a prosthesis secured to the near-intact calcium bar may offer reliable results, but should be balanced with the hazards of periprosthetic leak, circumflex artery injury and atrioventricular heart block, related to the sutures being driven through or around the calcified material, and with the difficulties in implanting a prosthesis of adequate size. Conversely, the risks related to more aggressive techniques with radical debridement and reconstruction of the annular anatomy are well recognized, with non-negligible mortality and major morbidity, i.e., heart block requiring permanent pacemaker insertion, perioperative myocardial infarction and hemorrhagic complications at the level of the atrioventricular junction or proximal left ventricular free wall, often uncontrollable and fatal [31–34].

The recent adoption of the so-called microinvasive options, such as transcatheter prosthetic MV implantation procedures may represent an appealing alternative, particularly in high-risk patients, but to date outcome is suboptimal and indications are anatomically stringent, particularly in case of a relatively small left ventricle and a narrow mitroaortic angle, which imply a hazard of left ventricular outflow tract obstruction. In this scenario, the earliest experience with severe MAC was collected from the MAC Global Registry and reported a 30-mortality rate of 25% [34]. In a systematic review by Alexis et al., on 354 patients with MAC disease undergoing trans-septal and trans-apical valve-in-valve, the risk of left ventricular outflow tract obstruction was 11.2%, the incidence of at least moderate post-procedural mitral regurgitation was 4.1%, the rate of device embolism was 3.7%, and the risk of reintervention was 16.7%. The reported 30-day and 1-year mortality rates were 23%, and 43% respectively [35].

Our surgical practice in patients with MV disease and MAC is, whenever possible, to prefer repair techniques, and this is usually feasible in cases of mild to moderate MAC without significant leaflet involvement. In our series, however, repair was feasible only in 6/27 patients (22%), always with implantation of a complete prosthetic ring, while posterior leaflet resection and artificial chordal positioning were performed in three and in two patients, respectively. In case of valve replacement our technique of choice includes the least debridement of annular calcifications in order to drive the sutures and to achieve a good seating of the prosthesis. Aggressive decalcification is seldom necessary, avoiding time-consuming annular reconstruction coupled by a reduced hazard of atrioventricular disruption, coronary injury and, ultimately, intraoperative death. Besides, minimally invasive techniques are more straightforward and less cumbersome with this approach.

The extent of the annular calcium bar impacts the feasibility of MV repair. In case of extensive or near-circumferential MAC or leaflet involvement, the MV flexibility is severely impaired and the chances of a durable repair are jeopardized. In our population, severe and moderate MAC grading was reported in 11 (41%) and 13 (49%) patients, respectively, whereas involvement of one or both MV leaflets was observed in 48% and 52% of the cases. Not surprisingly, as already stated, the repair rate was only 22% (6/27).

Traditionally, MAC has been primarily addressed through a conventional full sternotomy. Nevertheless, the promising results reported by minimally invasive cardiac surgical programs have drawn the attention toward more complex cases, including MV disease with MAC. The benefits of a minimally invasive approach are particularly evident in elderly or frail patients, as well as in case of prior cardiac operations with the inherent risks of re-sternotomy and coronary bypass graft injury, if present. Besides, MV exposure may be more favorable with a lateral approach in patents with a relatively small left atrium.

In our experience with minimally invasive MV surgery during the last two decades, this case series indicates the feasibility and effectiveness also in patients with MAC with low perioperative mortality and rate of complications.

Patients enrolled in the present report display a consistently high preoperative risk profile with multiple comorbidities, namely, chronic kidney disease in near-90%, diabetes in 19%, severe pulmonary hypertension in 22%, previous cardiac surgery in 15%, peripheral vascular disease in 15% of the patients, and complex MV anatomy with a MAC grade of 6 or more in 55%. Overall 30-day mortality was 7%. No case of intraoperative bleeding due to annular injury or perioperative myocardial infarction were observed. Notably, no perioperative stroke occurred. Periprosthetic leak was detected in two patients (one early failure, and one at follow-up).

In a case series by Feindel et al., MAC led to a 6-fold increase in the operative mortality of patients undergoing isolated MV surgery [17]. Other authors have reported early mortality after MV replacement in MAC as high as 28% [31]. The lower than expected mortality and morbidity in the present study can be justified by experience in minimally invasive MV surgery, with a tailored approach to each patient in our everyday practice [7–12], progressively extended to also include patients with mild-to-moderate and, more recently, severe MAC. The technique of choice in the latter has been, whenever feasible, MV replacement with minimal annular calcium debridement, allowing the surgeon to dramatically reduce the risk of heart rupture and coronary lesions.

Limitations

This was a retrospective, single-center study, and a control group of patients with MV disease and MAC undergoing surgery through standard sternotomy was not available. Moreover, not all the patients enrolled had a preoperative angio-CT scan with cardiac gating. Conversely, a strength of this report relates to the fact that perioperative mortality was stratified according to the EuroSCORE, which does not include specific variables related to MAC anatomy and thus underestimates the risks related to the complexity of the surgical procedure and to the fragility of the MV anulus in this specific population.

5. Conclusions

MAC increases the complexity of surgical procedure and operative mortality and morbidity. Results of the present study show that in experienced high-volume centers, the benefits of the minimally invasive approach can be safely extended to MAC patients as well. CT scans and, eventually, angiography are mandatory for total-body vascular assessment and decision-making in relation to perfusion and cardioplegia techniques. MV repair is preferred whenever possible, but more often, MAC precludes a durable result. When MV replacement is indicated, the technique of choice is minimal debridement of annular calcifications for the suturing and proper seating of the prosthesis.

Author Contributions: Conceptualization, C.B., A.S. (Antonio Spitaleri), M.P. and A.D.; methodology, C.B., M.P. and M.R.; software, A.S. (Antonio Spitaleri), A.S. (Ambra Santonocito), A.D. and R.F.; validation, C.B., M.P. and M.R.; formal analysis, C.B., A.S., M.P. and R.F.; investigation, A.S. (Antonio Spitaleri), B.P., A.S. (Ambra Santonocito) and E.B.; resources, C.B., A.S. (Antonio Spitaleri), M.P. and M.R.; data curation, C.B., A.S. (Antonio Spitaleri), B.P., A.S. (Ambra Santonocito) and E.B.; writing—original draft preparation, C.B., A.S. (Antonio Spitaleri) and A.S. (Ambra Santonocito); writing—review and editing, M.P.; visualization, C.B., A.S. (Antonio Spitaleri), B.P., A.S. (Ambra Santonocito) and E.B.; supervision, C.B., M.P., A.D. and R.F.; project administration, A.D., R.F. and M.R.; funding acquisition, R.F. and M.R. All authors have read and agreed to the published version of the manuscript.

Funding: This research received no external funding.

Institutional Review Board Statement: The study was conducted in accordance with the Declaration of Helsinki, and approved by the Institutional Review Board of the "AOU Città della Salute e della Scienza di Torino", Turin, Italy (protocol code 0095187; 9 October 2020).

Informed Consent Statement: Written informed consent has been obtained from the patients to publish this paper, when applicable.

Data Availability Statement: The data presented in this study are available upon request from the corresponding author.

Conflicts of Interest: The authors declare no conflict of interest.

References

1. Kanjanauthai, S.; Nasir, K.; Katz, R.; Rivera, J.J.; Takasu, J.; Blumenthal, R.S.; Eng, J.; Budoff, M.J. Relationships of mitral annular calcification to cardiovascular risk factors: The Multi-Ethnic Study of Atherosclerosis (MESA). *Atherosclerosis* **2010**, *213*, 558–562. [CrossRef] [PubMed]
2. O'Neal, W.T.; Efird, J.T.; Nazarian, S.; Alonso, A.; Heckbert, S.R.; Soliman, E.Z. Mitral annular calcification and incident atrial fibrillation in the Multi-Ethnic Study of Atherosclerosis. *Europace* **2014**, *17*, 358–363. [CrossRef] [PubMed]
3. Abramowitz, Y.; Hasan, J.; Tarun, C.; Michael, J.M.; Raj, R.M. Mitral annulus calcification. *J. Am. Coll. Cardiol.* **2015**, *66*, 1934–1941. [CrossRef] [PubMed]
4. Okada, Y. Surgical management of mitral annular calcification. *Gen. Thorac. Cardiovasc. Surg.* **2013**, *61*, 619–625. [CrossRef] [PubMed]
5. Di Stefano, S.; López, J.; Flórez, S.; Rey, J.; Arevalo, A.; Román, A.S. Building a new annulus: A technique for mitral valve replacement in heavily calcified annulus. *Ann. Thorac. Surg.* **2009**, *87*, 1625–1627. [CrossRef]
6. Guerrero, M.; Wang, D.D.; Pursnani, A.; Eleid, M.; Khalique, O.; Urena, M.; Salinger, M.; Kodali, S.; Kaptzan, T.; Lewis, B.; et al. A cardiac computed tomography–based score to categorize mitral annular calcification severity and predict valve embolization. *JACC Cardiovasc. Imaging* **2020**, *13*, 1945–1957. [CrossRef]
7. Barbero, C.; Marchetto, G.; Ricci, D.; El Qarra, S.; Attisani, M.; Filippini, C.; Boffini, M.; Rinaldi, M. Minimal access mitral valve surgery: Impact of tailored strategies on early outcome. *Ann. Thorac. Surg.* **2016**, *102*, 1989–1994. [CrossRef]
8. Barbero, C.; Marchetto, G.; Ricci, D.; Cura Stura, E.; Clerici, A.; El Qarra, S.; Filippini, C.; Boffini, M.; Rinaldi, M. Steps forward in minimally invasive cardiac surgery: 10-year experience. *Ann. Thor. Surg.* **2019**, *108*, 1822–1829. [CrossRef]
9. Barbero, C.; Pocar, M.; Marchetto, G.; Cura Stura, E.; Calia, C.; Boffini, M.; Rinaldi, M.; Ricci, D. Antegrade perfusion for mini-thoracotomy mitral valve surgery in patients with atherosclerotic burden. *Heart Lung Circ.* **2022**, *31*, 415–419. [CrossRef]
10. Barbero, C.; Rinaldi, M. Preoperative vascular screening: A novel breakthrough in minimally invasive mitral valve surgery. *Interact. Cardiovasc. Thorac. Surg.* **2017**, *24*, 368. [CrossRef]
11. Barbero, C.; Ricci, D.; El Qarra, S.; Marchetto, G.; Boffini, M.; Rinaldi, M. Aortic cannulation system for minimally invasive mitral valve surgery. *J. Thorac. Cardiovasc. Surg.* **2015**, *149*, 1669–1672. [CrossRef] [PubMed]
12. Barbero, C.; Pocar, M.; Marchetto, G.; Cura Stura, E.; Calia, C.; Dalbesio, B.; Filippini, C.; Salizzoni, S.; Boffini, M.; Rinaldi, M.; et al. Single-dose St. Thomas versus Custodiol® cardioplegia for right mini-thoracotomy mitral valve surgery. *J. Cardiovasc. Transl. Res.* **2022**. [CrossRef] [PubMed]
13. Thygesen, K.; Alpert, J.S.; Jaffe, A.S.; Chaitman, B.R.; Bax, J.J.; Morrow, D.A.; White, H.D. The Executive Group on behalf of the Joint European Society of Cardiology (ESC)/American College of Cardiology (ACC)/American Heart Association (AHA)/World Heart Federation (WHF) Task Force for the universal definition of myocardial infarction. Fourth universal definition of myocardial infarction. *Eur. Heart J.* **2019**, *40*, 237–269. [PubMed]
14. Lomivorotov, V.V.; Efremov, S.; Kirov, M.; Fominskiy, E.; Karaskov, A.M. Low-cardiac-output syndrome after cardiac surgery. *J. Cardiothorac. Vasc. Anesth.* **2017**, *31*, 291–308. [CrossRef]
15. Barbero, C.; Rinaldi, M.; Marchetto, G.; Valentini, M.C.; Cura Stura, E.; Bosco, G.; Pocar, M.; Filippini, C.; Boffini, M.; Ricci, D. Magnetic resonance imaging for cerebral micro-embolizations during minimally invasive mitral valve surgery. *J. Cardiovasc. Transl. Res.* **2022**, *15*, 828–833. [CrossRef]
16. Carpentier, A.F.; Pellerin, M.; Fuzellier, J.-F.; Relland, J.Y. Extensive calcification of the mitral valve anulus: Pathology and surgical management. *J. Thorac. Cardiovasc. Surg.* **1996**, *111*, 718–730. [CrossRef] [PubMed]
17. Feindel, C.M.; Tufail, Z.; E David, T.; Ivanov, J.; Armstrong, S. Mitral valve surgery in patients with extensive calcification of the mitral annulus. *J. Thorac. Cardiovasc. Surg.* **2003**, *126*, 777–782. [CrossRef]
18. Fusini, L.; Ali, S.G.; Tamborini, G.; Muratori, M.; Gripari, P.; Maffessanti, F.; Celeste, F.; Guglielmo, M.; Cefalù, C.; Alamanni, F.; et al. Prevalence of calcification of the mitral valve annulus in patients undergoing surgical repair of mitral valve prolapse. *Am. J. Cardiol.* **2014**, *113*, 1867–1873. [CrossRef]
19. Chan, V.; Ruel, M.; Hynes, M.; Chaudry, S.; Mesana, T.G. Impact of mitral annular calcification on early and late outcomes following mitral valve repair of myxomatous degeneration. *Interact. Cardiovasc. Thorac. Surg.* **2013**, *17*, 120–125. [CrossRef]
20. Morisaki, A.; Kato, Y.; Takahashi, Y.; Shibata, T. Mitral valve repair without mitral annuloplasty with extensive mitral annular calcification. *Interact. Cardiovasc. Thorac. Surg.* **2014**, *19*, 1080–1082. [CrossRef]
21. Maisano, F.; Caldarola, A.; Blasio, A.; De Bonis, M.; La Canna, G.; Alfieri, O. Midterm results of edge-to-edge mitral valve repair without annuloplasty. *J. Thorac. Cardiovasc. Surg.* **2003**, *126*, 1987–1997. [CrossRef] [PubMed]
22. Coselli, J.S.; Crawford, E.S. Calcified mitral valve annulus: Prosthesis insertion. *Ann. Thorac. Surg.* **1988**, *46*, 584–586. [CrossRef] [PubMed]

23. Nataf, P.; Pavie, A.; Jault, F.; Bors, V.; Cabrol, C.; Gandjbakhch, I. Intraatrial insertion of a mitral prosthesis in a destroyed or calcified mitral annulus. *Ann. Thorac. Surg.* **1994**, *58*, 163–167. [CrossRef] [PubMed]
24. Atoui, R.; Lash, V.; Mohammadi, S.; Cecere, R. Intra-atrial implantation of a mitral valve prosthesis in a heavily calcified mitral annulus. *Eur. J. Cardiothorac. Surg.* **2009**, *36*, 776–778. [CrossRef] [PubMed]
25. Iida, H.; Mochizuki, Y.; Matsushita, Y.; Mori, H.; Yamada, Y.; Miyoshi, S. A valve replacement technique for heavily calcified mitral valve and annulus. *J. Heart Valve Dis.* **2005**, *14*, 209–211. [PubMed]
26. Vander Salm, T.J.; Perras, M. As originally published in 1989: Mitral annular calcification: A new technique for valve replacement. *Ann. Thorac. Surg.* **1997**, *63*, 1819–1820. [PubMed]
27. Nguyen, A.; Schaff, H.V. Left atrial to left ventricle bypass for mitral valve stenosis. *J. Thorac. Cardiovasc. Surg.* **2019**, *157*, e361–e362. [CrossRef]
28. Amodeo, A.; Di Donato, R.; Corno, A.; Mazzera, E.; Giannico, S.; Nava, S.; Marcelletti, C. Systemic atrioventricular conduit for extracardiac bypass of hypoplastic systemic atrioventricular valve. *Eur. J. Cardiothorac. Surg.* **1990**, *4*, 601–603. [CrossRef]
29. Barac, Y.D.; Zwischeberger, B.; Schroder, J.N.; Daneshmand, M.A.; Haney, J.C.; Gaca, J.G.; Wang, A.; Milano, C.A.; Glower, D.D. Using a Regent aortic valve in a small annulus mitral position is a viable option. *Ann. Thorac. Surg.* **2018**, *105*, 1200–1204. [CrossRef]
30. Joury, A.; Duran, A.; Stewart, M.; Gilliland, Y.E.; Spindel, S.M.; Qamruddin, S. Prosthesis-patient mismatch following aortic and mitral valves replacement—A comprehensive review. *Prog. Cardiovasc. Dis.* **2022**, *72*, 84–92. [CrossRef]
31. D'Alessandro, C.; Vistarini, N.; Aubert, S.; Jault, F.; Acar, C.; Pavie, A.; Gandjbakhch, I. Mitral annulus calcification: Determinants of repair feasibility, early and late surgical outcome. *Eur. J. Cardiothorac. Surg.* **2007**, *32*, 596–603. [CrossRef] [PubMed]
32. Saran, N.; Greason, K.L.; Schaff, H.V.; Cicek, S.M.; Daly, R.C.; Maltais, S.; Stulak, J.M.; Pochettino, A.; King, K.S.; Dearani, J.A.; et al. Does mitral valve calcium in patients undergoing mitral valve replacement portend worse survival? *Ann. Thorac. Surg.* **2019**, *107*, 444–452. [CrossRef] [PubMed]
33. Bedeir, K.; Kaneko, T.; Aranki, S. Current and evolving strategies in the management of severe mitral annular calcification. *J. Thorac. Cardiovasc. Surg.* **2019**, *157*, 555–566. [CrossRef]
34. Guerrero, M.; Urena, M.; Himbert, D.; Wang, D.D.; Eleid, M.; Kodali, S.; George, I.; Chakravarty, T.; Mathur, M.; Holzhey, D.; et al. 1-Year outcomes of transcatheter mitral valve replacement in patients with severe mitral annular calcification. *J. Am. Coll. Cardiol.* **2018**, *71*, 1841–1853. [CrossRef] [PubMed]
35. Alexis, S.L.; Malik, A.H.; El-Eshmawi, A.; George, I.; Sengupta, A.; Kodali, S.K.; Hahn, R.T.; Khalique, O.K.; Zaid, S.; Guerrero, M.; et al. Surgical and transcatheter mitral valve replacement in mitral annular calcification: A systematic review. *J. Am. Heart Assoc.* **2021**, *10*, e018514. [CrossRef]

Disclaimer/Publisher's Note: The statements, opinions and data contained in all publications are solely those of the individual author(s) and contributor(s) and not of MDPI and/or the editor(s). MDPI and/or the editor(s) disclaim responsibility for any injury to people or property resulting from any ideas, methods, instructions or products referred to in the content.