

Programmed-release intraosseus anesthesia as an alternative to lower alveolar nerve block in lower third molar extraction: a randomized clinical trial.

Original

Programmed-release intraosseus anesthesia as an alternative to lower alveolar nerve block in lower third molar extraction: a randomized clinical trial / Pol, Renato; Ruggiero, Tiziana; Bezzi, Marta; Camisassa, Davide; Carossa, Stefano. - In: JOURNAL OF DENTAL ANESTHESIA AND PAIN MEDICINE. - ISSN 2383-9309. - 22:3(2022), pp. 217-226. [[10.17245/jdapm.2022.22.3.217](https://doi.org/10.17245/jdapm.2022.22.3.217)]

Availability:

This version is available at: 11583/2998638 since: 2025-03-27T14:03:44Z

Publisher:

Kwang-Suk Seo

Published

DOI:[10.17245/jdapm.2022.22.3.217](https://doi.org/10.17245/jdapm.2022.22.3.217)

Terms of use:

This article is made available under terms and conditions as specified in the corresponding bibliographic description in the repository

Publisher copyright

(Article begins on next page)



Programmed-release intraosseus anesthesia as an alternative to lower alveolar nerve block in lower third molar extraction: a randomized clinical trial

Renato Pol, Tiziana Ruggiero, Marta Bezzi, Davide Camisassa, Stefano Carossa

Oral Surgery Unit, Dentistry Section, Department of Surgical Sciences, University of Turin, Dental School, Turin, Italy

Background: Intraosseous anesthesia is the process by which an anesthetic solution, after penetration of the cortical bone, is directly injected into the spongiosa of the alveolar bone supporting the tooth. This study aimed to compare the effectiveness of the traditional inferior alveolar nerve block (IANB) and computerized intraosseous anesthesia in the surgical extraction of impacted lower third molars, compare their side effects systemically by monitoring heart rate, and assess patients' a posteriori preference of one technique over the other.

Methods: Thirty-nine patients with bilaterally impacted third molars participated in this study. Each patient in the sample was both a case and control, where the conventional technique was randomly assigned to one side (group 1) and the alternative method to the contralateral side (group 2).

Results: The traditional technique was faster in execution than anesthesia delivered via electronic syringe, which took 3 min to be administered. However, it was necessary to wait for an average of 6 ± 4 min from the execution to achieve the onset of IANB, while the latency of intraosseous anesthesia was zero. Vincent's sign and lingual nerve anesthesia occurred in 100% of cases in group 1. In group 2, Vincent's sign was recorded in 13% of cases and lingual anesthesia in four cases. The average duration of the perceived anesthetic effect was 192 ± 68 min in group 1 and 127 ± 75 min in group 2 ($P < 0.001$). The difference between the heart rate of group 1 and group 2 was statistically significant. During infiltration in group 1, heartbeat frequency increased by 5 ± 13 beats per minute, while in group 2, it increased by 22 ± 10 beats per minute ($P < 0.001$). No postoperative complications were reported for either technique. Patients showed a preference of 67% for the alternative technique and 20% for the traditional, and 13% of patients were indifferent.

Conclusion: The results identified intraosseous anesthesia as a valid alternative to conventional anesthesia in impacted lower third molar extraction.

Keywords: Anesthesia; Inferior Alveolar Nerve; Intraosseous; Nerve Block; Tooth Extraction.



This is an Open Access article distributed under the terms of the Creative Commons Attribution Non-Commercial License (<http://creativecommons.org/licenses/by-nc/4.0/>) which permits unrestricted non-commercial use, distribution, and reproduction in any medium, provided the original work is properly cited.



INTRODUCTION

Inferior alveolar nerve (IAN, third branch of the trigeminal nerve) block (IANB) is by definition a loco-regional anesthesia that is performed by infiltration of the anesthetic solution near the mandibular nerve before

it enters the mandibular canal [1]. The resulting effect is the interruption of impulse transmission downstream of the injection point, with consequent loss of sensitivity in the innervated territories, resulting in desensitization of the pulp of all mandibular teeth of the quadrant, vestibular mucoperiosteum anterior to the first molar (mental nerve), and ipsilateral lower lip. Vincent's sign

Received: September 12, 2021 • Revised: May 9, 2022 • Accepted: May 23, 2022

Corresponding Author: Tiziana Ruggiero, Oral Surgery Unit, Dentistry Section, Department of Surgical Sciences, University of Turin, Dental School, Via Nizza 230, 10100, Turin, Italy

Tel: +39 334 9835933 E-mail: tiziana.ruggiero@unito.it

Copyright© 2022 Journal of Dental Anesthesia and Pain Medicine

is the collateral effect of the traditional IANB with anesthesia of the ipsilateral lower lip but is used by clinicians as a proof of success of the anesthetic procedure.

This technique produces rather deep and long-lasting anesthesia, which allows routine treatments from the simplest to the most prolonged and complex. However, it can produce important side effects, such as a burning sensation and suffocation. Moreover, it is not free from risks, such as biting and burns of the lip and tongue (because of lip anesthesia), injury of the mandibular nerve, lesion of the lingual nerve, intravascular injection, vascular lesion hematoma, facial nerve anesthesia for injection into the parotid region, and injection into the internal pterygoid muscle, with possible trismus. It has a large learning curve to be successful as it has a high rate of failure at 20–25% [2,3].

Intraosseous anesthesia is the process by which an anesthetic solution, after penetration of the cortical bone, is injected directly into the spongiosa of the alveolar bone supporting the tooth. The advantages of this method are instant anesthesia after injection, without soft tissue numbness, and requirement of less anesthetic than that required in the conventional technique [4]. This technique is widely used in pediatric dentistry as it avoids the risk of biting and pain upon infiltration [4–6].

As for osteocentral maxillary anesthesia, with a single point of injection, a larger area is anesthetized than in conventional anesthesia, extending both mesial and distal to the injection site and with its effect on the lingual side as well. In the jaw, however, diffusion occurs in the mesial direction: the injection point needs to be distal to the tooth to be treated [4]. Additionally, duration of the anesthetic effect is shorter [7]. This may be because of the dense network vascular network of the jaw, which determines the rapid absorption of the anesthetic. Therefore, there is a need to use a vasoconstrictor with the anesthetic solution to increase the duration of its effect. In most patients, the vascularity and confined infusion space increase heart rate (beats per minute, bpm).

Several studies have validated the effectiveness of this type of anesthesia, indicating that the advantages of this

technique can compensate for its disadvantages. These studies show that using the intraosseous technique can significantly reduce pain perceived by the patient, expressed using the visual analog scale [8]. This technique is valid for all dental sectors and significantly increases the control that the surgeon has over various aspects of anesthesia. Furthermore, it increases the speed and safety of the operation, decreases the pain, decreases the time of onset of the anesthetic effect, has better predictability, has fewer side effects, and involves no distinction between maxillary and mandibular anesthesia [9].

The purpose of this study was to compare the traditional IANB and computerized intraosseous anesthesia in the surgical extraction of lower third molars by comparing various parameters of effectiveness of the two anesthetic techniques during all phases of surgical extraction of impacted lower third molars, comparing systemic side effects by monitoring the heart rate, and retrospectively evaluating patients' preferences regarding the two techniques.

METHODS

This randomized controlled single-blind parallel-design clinical trial was designed according to the CONSORT statement for improving the quality of reports of randomized controlled trials (<http://www.consort-statement.org/>). The study protocol was approved by internal ethics committee (Ref. No. 711.260). The study conformed to the tenets of the Declaration of Helsinki and its later amendments and institutional ethical guidelines.

1. Study sample

This single-blind, single-center, randomized controlled clinical trial included 39 patients who visited the Oral Surgery Department of the Dental School of Turin between January and August 2021. All patients presented fully formed or dental germs of bilaterally impacted lower third molars with total mucosal inclusion. All elements had indications for extraction.

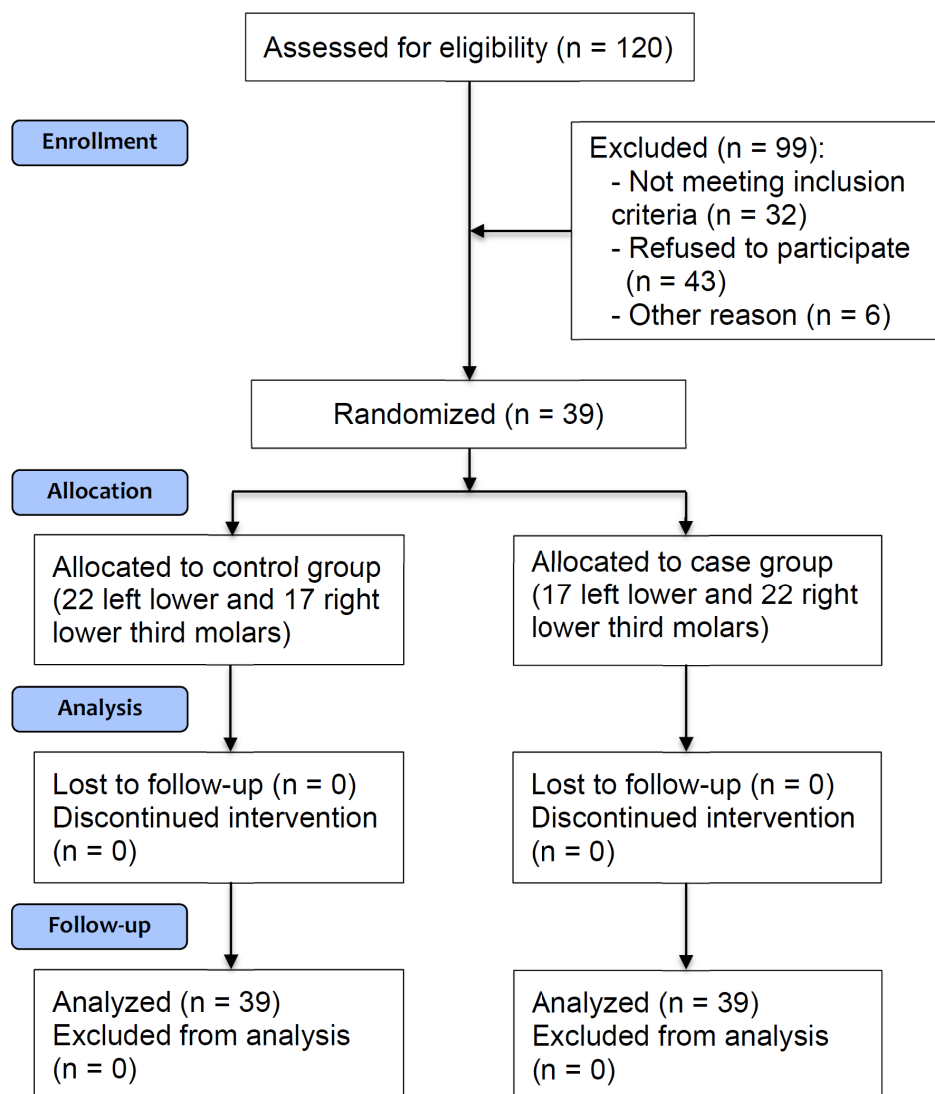


Fig. 1. CONSORT table: randomization of samples. CONSORT, consolidated standards of reporting trials; n, number.

The inclusion criteria were as follows: no serious systemic disorder or pathological condition, no heart diseases, no mental disorder, lower third molars/lower third molar germs bilaterally in semi-inclusion or inclusion in the mucosa, and lower third molars/lower third molar germs in a symmetrical position. Patients who voluntarily participated in the study were included.

Each patient included was both the case and the control. The two impacted third molars were extracted in a single session or two different sessions within 14 days according to the patient's choice. The treated sides were divided into two groups (both comprising 39 elements) (Fig. 1). Group

1 was treated with a conventional IANB (control; 22 left lower and 17 right lower third molars) and group 2 was treated with intraosseus anesthesia (case; 17 left lower and 22 right lower third molars).

2. Operation protocol

After anamnestic chart recording, patients underwent an objective examination of the oral cavity, a contextual analysis of orthopantomography, and if necessary, cone beam computed tomography analysis. During the visit, the patient was informed about the types of anesthesia that would be administered in the surgery but was not

told which of the two techniques would be performed first.

Informed consent was obtained from the patients. The following details were recorded: 1) the active ingredient, dosage, and the time elapsed since the last intake of drugs that affect the pain threshold (non-steroidal anti-inflammatory drugs, steroid anti-inflammatory drugs, opioids, antidepressants, and antiepileptics); 2) signs and symptoms related to the teeth to be extracted, including spontaneous pain, edema, bleeding, and discharge of pus; 3) assessment of psychological state with a Hospital Anxiety and Depression Scale (HADS) questionnaire; 4) assessment of the anesthetic difficulty; and 5) assessment of extraction difficulty.

Patients were monitored with a pulse oximeter (Rad-5, Masimo Corp., Irvine CA, USA) before anesthesia, during the injection of the anesthetic, and at the end of the operation, to determine changes in heart rate.

For both anesthetic procedures, the following was recorded: pain on execution, execution time, latency period, amount of anesthetic used, presence of Vincent's sign, anesthesia of the lingual nerve, any breakage or obstruction of the needle, and patient malaise.

The duration of the anesthetic effect was recorded by reporting the time of execution and asking the patient to complete the data recording at home with the time of the end of the effect.

Anesthetic difficulty and extraction difficulty of the third molars to be extracted were evaluated. The degree of extraction difficulty was obtained from radiographic analysis and recorded as low, medium, or high according to Mozzati's classification of operative difficulty [10] by assigning a score from 1 to 3.

The degree of anesthetic difficulty was deduced from the sum of a score derived from an understanding of the patient's psychological profile (1 - cooperative, 2 - suspicious, 3 - not collaborating) through the observation of behaviors, anxiety score (1 - normal, 2 - borderline, 3 - anxious), depression score (1 - normal, 2 - borderline, 3 - depressed) from the HADS questionnaire, and the inflammation index of the site to be treated (1 - inflammation

absent, 2 - localized inflammation, 3 - diffuse inflammation). The obtained parameter was a number between 4 and 12 and was then calculated in proportion from 1 to 10.

Pain was recorded at five time points of the intervention: T0, anesthesia; T1, incision and detachment of the flap; T2, osteotomy; T3, odontotomy; T4, avulsion of the element; and T5, hemostasis.

To perform conventional anesthesia, a regular syringe with two vial-holder rings was used, with a plunger fitted with a corkscrew-shaped end allowing suction. An omnipic needle (OMNIA Pharma S.r.l., Milano, Italy) with 36-mm length, 0.40-mm diameter and 27 gauge was used for the traditional local anesthesia of IAN and lingual nerve, and one 21-mm-long, 0.30-mm-diameter, 30-gauge needle was used for administering anesthesia to the buccal nerve.

For troncular, 1.8-mL vials of 3% mepivacaine without vasoconstrictor were used (Optocain, Molteni Dental Srl, Firenze, Italy) and 2% mepivacaine with epinephrine 1:100000 (Optocain, Molteni Dental Srl, Firenze, Italy) for the buccal nerve.

To perform intraosseous anesthesia, the computerized anesthetic Quicksleeper[®] system (Dental Hi-Tec, Cholet, France) was used. It consists of a wireless pedal, a control unit connected via USB to a handpiece with a sterilizable tip. The pedal has four keys that allow it to be screwed or unscrewed and put in a rotation of the needle, inject with two-speed profiles, and withdraw the plunger.

It is also possible to administer different types of anesthesia, namely osteocentral, intraligamentous, and intraseptal, in addition to the conventional periapical type. For each technique, there is a special DHT[®] needle, which has a tip with a scalpel-like bevel that allows an almost painless perforation of the soft tissue, which are incised and not torn, and easy bone perforation. A 27-gauge DHT[®] needle with 16-mm length and 0.40-mm diameter was used for the anesthetic procedures. The computerized system managed the rate of injection at approximately 0.9 mL/min or double speed.

Table 1. Baseline characteristics of enrolled patients

Patients	Sex	Age	Systemic pathologies (0: no; 1: yes)	Smoke (0: no; 1: yes)	Weight (kg)	Height (cm)
Pt. 1	F	21/5/91	0	0	57	165
Pt. 2	F	2/6/03	0	0	58	171
Pt. 3	F	5/7/2000	1	0	61	167
Pt. 4	M	13/11/2000	0	0	78	175
Pt. 5	F	29/1/97	0	1	66	170
Pt. 6	M	19/12/02	0	0	58	172
Pt. 7	F	30/8/01	0	0	48	158
Pt. 8	M	6/9/01	0	1	71	183
Pt. 9	F	6/12/96	0	0	47	162
Pt. 10	M	12/8/02	0	0	96	178
Pt. 11	M	19/12/89	0	0	73	177
Pt. 12	M	14/12/94	1	1	83	182
Pt. 13	F	27/1/97	1	1	77	178
Pt. 14	F	5/15/98	0	0	51	164
Pt. 15	M	11/8/93	0	0	68	170
Pt. 16	F	2/11/00	0	1	61	156
Pt. 17	M	16/1/98	0	1	88	187
Pt. 18	M	31/3/93	1	0	73	171
Pt. 19	F	4/10/97	0	1	55	168
Pt. 20	F	1/15/92	0	0	58	168
Pt. 21	M	5/11/00	0	0	69	176
Pt. 22	M	9/15/97	0	0	77	180
Pt. 23	M	6/3/98	0	0	93	184
Pt. 24	M	6/10/00	0	0	87	178
Pt. 25	M	9/12/00	0	0	71	173
Pt. 26	M	9/13/03	0	0	88	184
Pt. 27	F	8/31/01	0	0	63	167
Pt. 28	M	2/4/01	0	0	69	175
Pt. 29	M	10/16/99	0	0	70	182
Pt. 30	M	7/28/98	0	0	70	185
Pt. 31	M	8/11/99	0	0	81	185
Pt. 32	F	2/13/95	0	0	50	168
Pt. 33	M	7/19/01	0	0	68	178
Pt. 34	F	4/2/98	0	0	47	158
Pt. 35	F	4/27/94	0	1	58	167
Pt. 36	M	9/4/95	0	0	91	186
Pt. 37	M	12/17/01	0	1	72	178
Pt. 38	M	7/24/93	0	1	78	173
Pt. 39	F	9/20/90	0	1	73	170

F, female; M, male; Pt., patient.

3. Statistical analysis

Categorical variables are presented as absolute numbers and percentages, while quantitative variables are presented as mean \pm standard deviation (SD) unless otherwise specified. Comparison between groups for quantitative variables was performed using the Student's t-test for two independent samples.

RESULTS

Of 39 patients, 23 were men (59%) and 16 were women (41%); the sex distribution was the same in both the groups. The patients were between 13 and 27 years (mean 20 ± 3 years) of age (Table 1). Of the 78 extracted teeth, anesthetic difficulty and extraction difficulty were

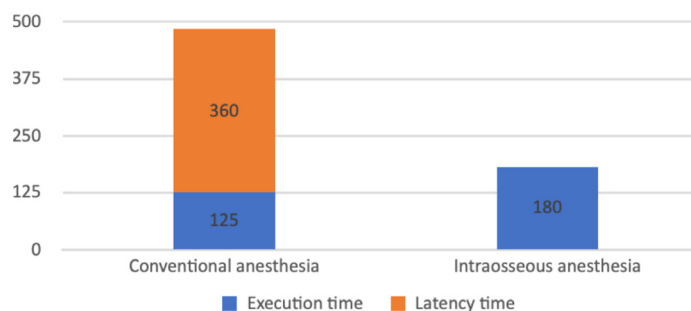


Fig. 2. Onset time of anesthesia, summation of execution time and latency (min). P < 0.001

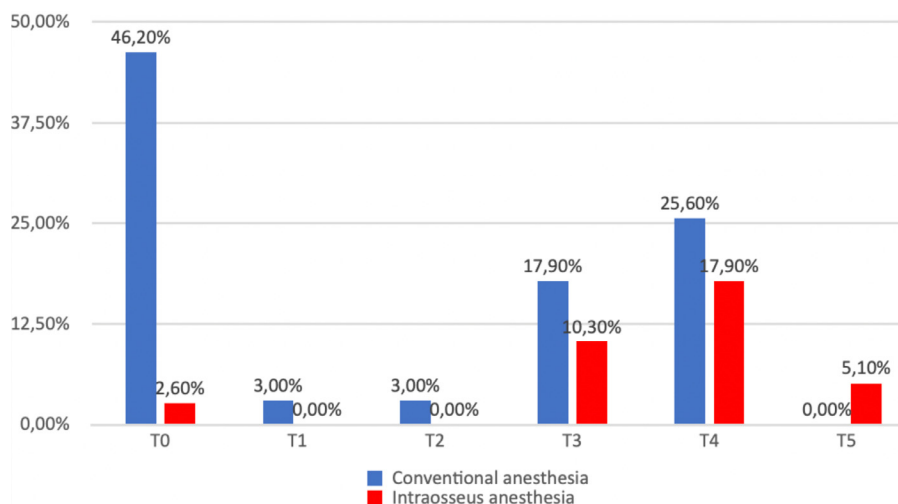


Fig. 3. The distribution of pain in the different moments of the intervention. T0: execution of anesthesia; T1: incision and detachment of the flap; T2: osteotomy; T3: odontotomy; T4: avulsion of the element; T5: hemostasis.

evaluated. The mean ± SD value of anesthetic difficulty was 4.7 ± 1.2 for both groups. The average operative difficulty was 1.82 ± 0.72 for group 1 and 1.79 ± 0.66 for group 2, with no significant differences between the two groups (P = 0.85).

The time required to administer the conventional block was 125 ± 44 s, while it was 180 ± 0 s for alternative anesthesia (the computerized release system always required the same time), and the difference was significant (P < 0.001). Regarding the latency period (time between the execution and administration of anesthesia), the conventional technique required an average of 6 ± 4 min, while the alternative method had immediate effect, and the difference was significant (P < 0.001) (Fig. 2). The amount of anesthetic injected to obtain conventional anesthesia was on average 2.08 ± 0.24 vials, compared to 1.84 ± 0.28 vials for the intraosseous technique, with

a difference significant (P < 0.001).

Vincent's sign and lingual nerve anesthesia occurred in 100% of cases in group 1. In group 2, Vincent's sign was recorded in 13% of cases and lingual anesthesia was achieved in four cases. The duration of the perceived anesthetic effect for group 1 was 192 ± 68 min, while it was 127 ± 75 min for group 2 (P < 0.001).

Pain was recorded at five time points in the intervention. At T0, pain was reported in 46.2% of cases in group 1 and 2.6% of cases in group 2. At T1 and T2, an episode of pain was reported only in group 1. At T3, pain was reported in seven of 39 cases in group 1 (17.9%) and four of 39 cases in group 2 (10.3%). At T4, pain was reported in 10 of 39 cases in group 1 and seven of 39 cases in group 2 (25.6% vs 17.9%). At T5, no pain was reported in group 1, while two cases (5.1%) reported pain in group 2 (Fig. 3).

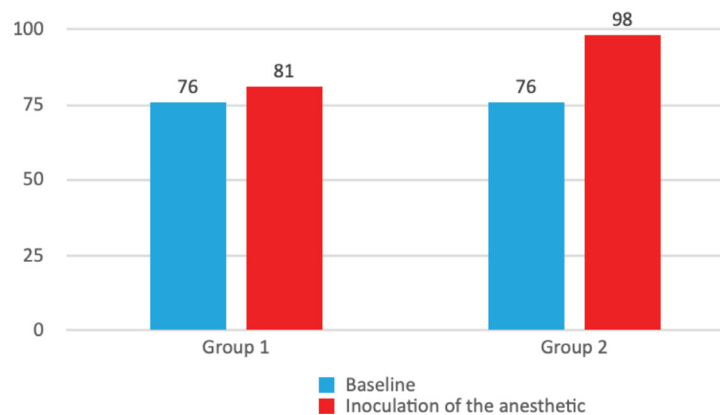


Fig. 4. Heart rhythm at baseline and during injection in anesthetic group 1: treated with a conventional inferior alveolar nerve block (control) and group 2: treated with intraosseus anesthesia (case)

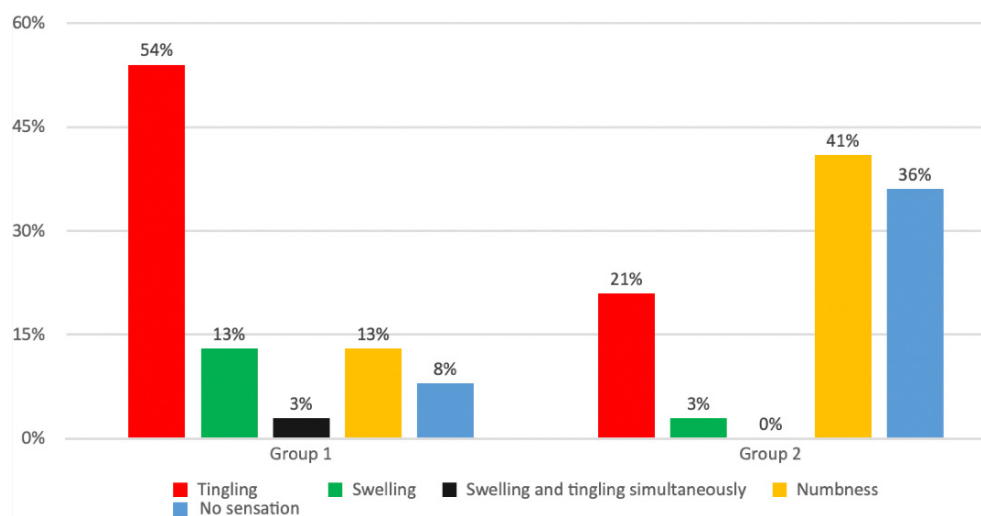


Fig. 5. Type of anesthetic sensation experienced with the two techniques

Regarding the increase in heart rate, the power of the sample was not enough to evaluate the significance of the difference between heart rate at T0 (baseline) and T1 (infiltration) in either of the two groups.

However, the difference between the heart rate of groups 1 and 2 was statistically significant in group 2. During infiltration, the heart rate increased by 5 ± 13 bpm (from 76 to 81 bpm) in group 1, while it increased by 22 ± 10 bpm (from 76 to 98 bpm) in group 2 ($P < 0.001$).

No statistically significant difference was observed in the comparison between immediate postoperative heart rates. Fig. 4 presents a graph illustrating the heart rhythm in blue in T0 and in red T1.

Regarding intraoperative anesthetic complications, no

case of lipothymia nor breakage of needles was reported. Six obstructions of the DHT[®] needle were recorded in group 2 after perforation of the cortical bone. The needle was replaced in these cases. No postoperative complications were reported.

The type of anesthetic sensation experienced by patients was also investigated. In group 1, a sensation of tingling (54%), swelling (13%), simultaneous swelling and tingling (13%), numbness (13%), and no sensation (8%) were recorded. In group 2, a sensation of only numbness was reported in 41% of cases, swelling in 3%, no type of anesthetic sensation in 36%, and only tingling in 21%, while no patient reported the feeling of simultaneous swelling and tingling (Fig. 5).

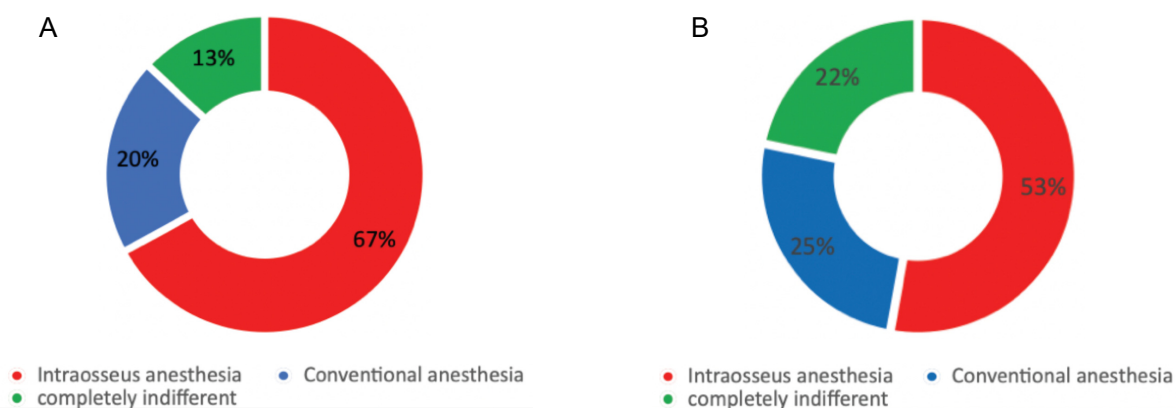


Fig. 6. Patient preference for tested techniques (A) and with a view to future interventions (B)

Patients demonstrated a preference of 67% for the alternative technique and 20% for the traditional, and 13% were indifferent. Finally, when questioned about which anesthesia they would prefer for future surgery, 56% of patients responded intraosseous anesthesia, 27% responded traditional IANB, and 23% were indifferent.

This may be because of the shorter duration of the anesthetic effect, which ended shortly after the end of the operation in most cases, exposing the patient to postoperative pain before analgesics could be administered (Fig. 6).

DISCUSSION

Our study results showed that the traditional technique was faster in execution than anesthesia delivered via the electronic syringe, which takes 3 min to be administered. However, considering the latency period, it was observed that for the onset of anesthesia with IANB, it was necessary to wait for an average of 6 ± 4 min from the execution, thus requiring 8 min to obtain the anesthetic effect. However, the latency of intraosseous anesthesia was virtually zero.

The amount of injected anesthetic is lower for the intraosseous technique according to the protocol elaborated by Cros [11], who emphasized the importance of bone structure for the success of intraosseous anesthesia. For his study, Cros injected half a vial of a

radiopaque contrast agent (a solution of methylene blue and barium sulfate) in cadaver jaws using a Quicksleeper[®] syringe. The researcher argued that the blue staining of the cortex demonstrated the diffusion of the solution through the cancellous bone canals. Furthermore, he suggested that increasing the quantity of the injected substance did not increase its diffusion. Contrarily, the excess dose escapes from the foramina. Consistent with the findings of his research, the protocol adopted in the present study limited the amount of anesthetic injected to three-fourths of a vial for intraosseous anesthesia.

The local extension of intraosseous anesthesia does not involve, except in limited cases, structures not involved in surgery, such as the lip and tongue. In cases where Vincent's sign manifested, patients reported a much milder anesthetic sensation mainly limited to the vermilion and upper third of the lip compared to the IANB effect. This greatly improves patients' comfort both during the operative and immediate post-surgical phases. In fact, 77% of patients treated with intraosseous anesthesia report not having felt the sensation of anesthesia except, to a small extent, a slight numbness of the operational area. On the contrary, 54% of patients treated with conventional anesthesia reported a tingling sensation of the lip and 13% reported both tingling and swelling, which was much more uncomfortable.

The duration of the anesthetic effect was greater with the traditional technique (average duration 3 h and 12 min vs. 2 h and 7 min with the alternative technique),

with the conventional technique lasting 1.5 times longer than the alternative. This is because of the increased vascularization of the mandibular bone. This limitation contraindicates the use of intraosseous anesthesia for long and complex surgical procedures, as there is a risk of loss of the anesthetic effect before surgery is concluded. Ozer et al. [7] indicated that it is not recommended to use intraosseous anesthesia for nonsurgical procedures that take more than 60 min. Furthermore, in case of surgical operations, the duration of the intervention should be further reduced to 20 min because of bleeding.

The anesthetic efficacy of the two techniques seems comparable, with some differences. The traditional technique was clearly more painful, while the alternative technique that uses a technologically more refined needle and a computerized injection system achieved better levels of comfort during execution.

The increase in heart rate from T0 to T1 under traditional anesthesia was generally very low. On average, there was an increase of 5 bpm, which seems to be attributable to the stress experienced by the patient. Moreover, the more the patient was constitutively anxious, the greater was the increase recorded. The factors related to the increase in heart rate under intraosseous anesthesia were instead identifiable both in increased stress and in dense vascular network of the bone exposed to the use of epinephrine, and a more pronounced increase in heart rate was observed. This peak, which averaged at 22 bpm, returned in each case to the normal level after approximately 1 min, with a statistically significant difference compared to that with conventional anesthesia.

Ozer et al. [7] did not observe significant differences in the increased heart rate caused by intraosseous injection and that by conventional anesthesia. Tolas et al. [12] in their study on the effects of epinephrine present in anesthetic solutions for dental use on the heart rhythm did not find significant differences between the basal heart rate and that recorded following the injection of 1.2 mL of 2% lidocaine with 1: 100000 vasoconstrictor. No signs of statistically significant increases in cardiac parameters

occurred even in the group of patients administered lidocaine without vasoconstrictor. Although some studies have reported statistically significant changes in heart rhythm [13], others claim the opposite [7-12]. No postoperative complications were reported for either technique in the present study.

This study confirms the findings of other studies regarding patient preference: 59% of 50 patients in the first study preferred intraosseous anesthesia, as did 69.7% of patients in the second study; the results of this work (67% preference for intraosseous anesthesia) are in line with those of the second study [14-15].

The intraosseous technique for is not recommended for cardiac patients as it may cause significant changes in heart rhythm. However, this technique has fewer collateral effects, the latency period is shorter, and the amount of injected anesthetic is lower than that in the conventional technique.

This study had some limitations, including the small sample size, limited study time, and recruitment of only young patients without pathologies. Future implications of this study may include extension of the use of the intraosseous technique to oral surgery in both healthy patients and patients with systemic disease.

Despite the advantages listed above, this method has some disadvantages. such as the small duration of the anesthetic effect and need for reinforcement of anesthesia linked to factors, such as variability in bone density, the duration of the operation, and bleeding. The use of this technique is not recommended in cardiac patients, except with the use of an anesthetic without vasoconstrictor, which may reduce the effectiveness of anesthesia. The results obtained in this study identify intraosseous anesthesia as a valid alternative to conventional anesthesia in the extraction treatment of impacted lower third molars.

In conclusion, intraosseous anesthesia delivered through a computerized system is a technique capable of ensuring less painful anesthesia than the traditional infiltrative techniques, with less numbness of soft tissue, greater patient comfort, and requirement of less anesthetic. It is a technique that can be used with

satisfaction not only to perform third molar extraction but also in restorative, endodontic, and simple extraction treatments.

AUTHOR ORCID*s*

Renato Pol: <https://orcid.org/0000-0001-7446-9897>

Tiziana Ruggiero: <https://orcid.org/0000-0003-3948-0243>

Marta Bezzi: <https://orcid.org/0000-0002-9256-0552>

Davide Camisassa: <https://orcid.org/0000-0002-9253-9112>

Stefano Carossa: <https://orcid.org/0000-0002-4986-1798>

AUTHOR CONTRIBUTIONS

Renato Pol: Conceptualization, Project administration, Supervision

Tiziana Ruggiero: Conceptualization, Data curation, Funding acquisition, Methodology

Marta Bezzi: Writing - original draft, Writing - review & editing

Davide Camisassa: Formal analysis, Methodology, Software

Stefano Carossa: Project administration, Supervision

DECLARATION OF INTERESTS: The authors have no conflicts of interest to declare.

REFERENCES

1. The glossary of prosthodontic terms: ninth edition. *J Prosthet Dent* 2017; 117: e1-105.
2. Khalil H. A basic review on the inferior alveolar nerve block techniques. *Anesth Essays Res* 2014; 8: 3-8.
3. Thangavelu K, Kannan R, Kumar NS, Rethish E, Sabitha S, Sayeeganes N. Significance of localization of mandibular foramen in an inferior alveolar nerve block. *J Nat Sci Biol Med* 2012; 3: 156-60.
4. Dental Hi Tec - QuickSleeper, l'expert de l'anesthésie. Dental Hi Tec. Available from <http://www.dentalthitec.com/2015en/products/quicksleeper/>
5. Deepak V, Challa RR, Kamatham R, Nuvvula S. Comparison of a new auto-controlled injection system with traditional syringe for mandibular infiltrations in children: a randomized clinical trial. *Anesth Essays Res* 2017; 11: 431-8.
6. Zhao X, Liu H, Qin M. Application of computer-controlled local anesthetic delivery system in children. *Hua Xi Kou Qiang Yi Xue Za Zhi* 2011; 29: 389-92.
7. Özer S, Yaltirik M, Kirli I, Yargic I. A comparative evaluation of pain and anxiety levels in 2 different anesthesia techniques: locoregional anesthesia using conventional syringe versus intraosseous anesthesia using a computer-controlled system (Quicksleeper). *Oral Surg Oral Med Oral Pathol Oral Radiol* 2012 ;114: S132-9.
8. Ghaderi F, Ahmadbeigi M. Pain perception due to dental injection by Smartject: split mouth design study. *J Dent* 2018; 19: 57-62.
9. Perugia C, Bartolino M, Docimo R. Comparison of single tooth anaesthesia by computer-controlled local anaesthetic delivery system (C-CLADS) with a supraperiosteal traditional syringe injection in paediatric dentistry. *Eur J Paediatr Dent* 2017; 18: 221-5.
10. Mozzati M, Pol R. *Chirurgia Stomatologica biologicamente guidata*. Vol. 2. 2018
11. Cros J. Transcortical anesthesia: experimental approach and importance in odontology. Available from http://www.dentalthitec.com/web2/upload_fich/bibliographie2007_07_tc_experimental_approach_and_importance_in_odontology.pdf.
12. Tolas AG, Pflug AE, Halter JB. Arterial plasma epinephrine concentrations and hemodynamic responses after dental injection of local anesthetic with epinephrine. *J Am Dent Assoc* 1982; 104: 41-3.
13. Kiyomitsu Y, Sugiyama K, Joh S. Effects of catecholamines added to lidocaine on cardiac function. *Anesth Prog* 1989; 36: 198-200.
14. Sixou JL, Marie-Cousin A, Huet A, Hingant B, Robert JC. Pain assessment by children and adolescents during intraosseous anaesthesia using a computerized system (QuickSleeper). *Int J Paediatr Dent* 2009; 19: 360-6.
15. Beneito-Brotos R, Peñarrocha-Oltra D, Ata-Ali J, Peñarrocha M. Intraosseous anesthesia with solution injection controlled by a computerized system versus conventional oral anesthesia: a preliminary study. *Med Oral Patol Oral Cir Bucal* 2012; 17: e426-9.