POLITECNICO DI TORINO
Repository ISTITUZIONALE

Combined orthograde 3D navigation microsurgical endodontic retreatment for the management of persistent apical periodontitis in a mandibular molar

Original
Combined orthograde 3D navigation microsurgical endodontic retreatment for the management of persistent apical periodontitis in a mandibular molar / Gibello, U., Cemenasco, A., Giordano, L., Alovisi, M., Cortese, L., Balocco, A., Berutti, E., Pasqualini, D.. - In: GIORNALE ITALIANO DI ENDODONZIA. - ISSN 1971-1425. - 37:1(2023), pp. 94-102. [10.32067/GIE.2023.37.01.07]

Availability:
This version is available at: 11583/2997571 since: 2025-02-18T06:49:45Z

Publisher:
Società Italiana di Endodonzia - Ariesdue

Published
DOI:10.32067/GIE.2023.37.01.07

Terms of use:

This article is made available under terms and conditions as specified in the corresponding bibliographic description in the repository

Publisher copyright

(Article begins on next page)

29 November 2026

Available online at www.giornaleitalianoendodonzia.it

Winner of Giorgio Lavagnoli Award IV SIE International Congress 2022

CASE REPORT

Combined orthograde 3D navigation microsurgical endodontic retreatment for the management of persistent apical periodontitis in a mandibular molar

Umberto Gibello[1*]
Andrea Cemenasco[2]
Lia Giordano[1]
Mario Alovisi[1]
Luca Cortese[1]
Alice Balocco[1]
Elio Berutti[1]
Damiano Pasqualini[1]

[1]Department of Surgical Sciences, Dental School, Endodontics, University of Turin, Turin, Italy.

[2]Department of Surgical Sciences, Radiology Institute, University of Turin, Italy.

ABSTRACT

Aim: *This case report shows a combined, orthograde and 3D navigation, microsurgical endodontic treatment of an element with persistent apical periodontitis (PAP), due to an inadequate endodontic treatment and a separated instrument beyond apical foramen of the mesio-buccal canal of the tooth 3.6. A targeted minimally invasive ostectomy with 3D navigation system was performed to localize the apex and remove the broken instrument, then completing the root end management and filling.*

Summary: *After previous renewal of the existing restoration and non-surgical retreatment, microsurgery was carried out using the Navident. CBCT dicom data and stl files obtained from intraoral scans were uploaded into the software and matched together. The preoperative digital planning defined the direction and depth of the ostectomy with 5.2 mm cilindrical bone mill drill. On the day of surgery an optic support was placed adhesively at the mandibular level, detected by the Navident camera.*

After the calibration of handpiece and the drill, a mucoperiosteal flap was performed. The bone mill drill was guided by the navigator, conducting a selective osteotomy. The removed bone block was stored in a Hank's buffered salt solution. The root end was resected and removed around the broken instrument. After the removal of the separated instrument, the retrocavity was prepared and filled with RRM fast set putty. A collagen sponge was placed to support the cortical block. The suture was made with 6.0 Vycril. Radiological images demonstrated the healing process. 3D navigation allowed to create a precise and targeted osteotomy. The 3D navigation seems to be predictable in complex cases, requiring accurate execution technique.

Key learning points

- *The use of 3D navigation is a valuable aid in complex cases, in which the proximity to anatomical structures.*
- *This technology allows a selective and rapid ostectomy, even by operators with less clinical experience*

Received 2022, December 22
Accepted 2023, January 25

KEYWORDS *Endodontics, microsurgical endodontics, Navident, persistent apical periodontitis*

Corresponding Author
Umberto Gibello | Department of Surgical Sciences, Dental School, Endodontics, University of Turin, via Nizza 230, 10126 Turin | Italy.
Phone: +39 3484369341 | Email umberto.gibello@gmail.com

Peer review under responsibility of Società Italiana di Endodonzia
10.32067/GIE.2023.37.01.07
Società Italiana di Endodonzia. Production and hosting by Ariesdue. This is an open access article under the CC BY-NC-ND license (http://creativecommons.org/licenses/by-nc-nd/4.0/).

Introduction

Persistent apical periodontitis (PAP) is a chronic inflammation of the periradicular tissues caused by etiological agents of endodontic origin. The main causes of PAP may include complex anatomy, reduced opening of the pulp chamber, forgotten or untreated canals, complications in instrumentation and extrusion of material beyond the apex (1).
The persistence of endodontic lesions after treatment may also be due to biological factors not directly related to the treatment: root infection due to the complexity of the root canal system, extraradicular infection due to actinomycosis, accumulation of cholesterol crystals, cystic lesions and wound healing with scar tissue (1).
Surgical micro-endodontics (EMS) is a highly predictable treatment option for the resolution of cases of endodontically treated teeth with persistent apical periodontitis (2). Retrograde surgical treatment is recommended when orthograde retreatment is not successful or demonstrates an increased risk than the microsurgical approach (3).
In recent years, thanks to the use of new technologies and the development of increasingly performing materials and equipment, we have witnessed a significant increase in the success rate of surgical micro-endodontics (4-6).
The Buffalo Study (5) showed a success rate after surgical micro-endodontic treatment of 94% with intraoral radiographs follow-up and 91% with cone beam CT (5).
Errors during the osteotomy and apicoectomy phases, that compromise the apical seal or the integrity of the support structures, are considered the first cause of failure of microsurgical treatment (5).
A study analyzed the causes of failure of surgical endodontic interventions, correlating the failures to a poor technique of preparation and filling of the retrograde cavity (7); on the contrary, the use of a microsurgical technique and the use of new biocompatible cements allows to obtain 92.9% of success in cases of reoperation (7).
Surgical micro-endodontics involves several phases including flap creation, ostectomy, apical root resection (RER), retrograde cavity preparation (RECP) and retrograde obturation (REF) (2, 3).
Ostectomy and apical resection can sometimes be complicated procedures because of the difficult access to the affected site due to an intact and thick cortex or to the high risk of damage the noble anatomical structures near the operative site.
The anatomical structures to pay particular attention to are the floor of the nasal cavity, the maxillary sinus, the mental foramen and the mandibular canal (2, 3).
Although CBCT allows the operator to identify the precise position of the root apex (8), freehand procedures (FH) are often linked to the operator's dexterity, experience, ability to interpret CBCT images (7).
The introduction of new guided technologies, through the use of digitally created and then 3D printed static guides (7-9) and 3D dynamic navigation (10) have improved the accuracy and efficiency of this therapeutic procedure.
Dynamic navigation systems (3D-DNS) represent an emerging technology that allows the implementation of minimally invasive procedures, increasing accuracy, safety and reducing the possibility of iatrogenic damage (11, 12).
The dynamic navigation system is a computer-based system similar to a satellite guidance system, which uses an optical stereo video camera and optical sensors to align the patient's real anatomical structures to the cone beam CT data, allowing to carry out an operation by navigating in time real through the monitor vision of the patient's CT images during the operating session.
The application protocol requires careful planning by the operator, starting from the CBCT images. This system makes use of optical cameras that track movement and CBCT images for immediate virtual feedback from the operator.
The match of these two technologies allows immediate intraoperative feedback of the surgical maneuvers.
The guided navigation system has found greater use in the implant field for the past



Figure 1
Orthograde retreatment: **A)** initial periapical x-ray, **B)** x-ray after the orthograde retreatment, **C)** long term restauration.

decade (12); this technology has allowed the planning and finalization of implant cases even in unfavorable anatomical conditions, allowing to highlight and avoid noble anatomical structures near the chosen rehabilitation site.
In orthograde endodontics, this system has been used for the localization of calcified canals (8-10), for access cavity planning (15, 16), for the removal of root canal posts (15), for orthograde retreatments (17) and for intraosseous anesthesia (18).
Recently 3D-DNS has been used for surgical micro-endodontics with excellent results, but the literature on this subject is still limited (10-18).
The advantages of this technology are mainly linked to the possibility of carrying out a correct apical resection and with a favorable bevel angle; operating times are shorter, reducing patient and operator discomfort; the operator can also modify his own operating strategy during the operation (17, 18-26).
The objective of this case report is to demonstrate how the use of dynamic navigation technologies in surgical micro-endodontics facilitates the operator in the ostectomy and apicectomy phases even in the vicinity of noble anatomical structures.

Case Report

A 32 years old female patient, with medical history of chemotherapy for breast cancer, was referred for consultation before antiresorptive therapy with oral bisphosphonates in order to reduce the risk of secondary osteoporosis. Chief complaint was pain in chewing and tenderness to percussion on tooth 3.6. Radiological periapical exam evidenced apical periodontitis, secondary caries and inadequate previous endodontic treatment with a separated instrument beyond the apical foramen in the mesial root (Figure 1).
The patient performed a cone beam computer tomography (CBCT) (Morita,Accuitomo) that highlighted the root anatomy, the buccal plate and the relationships with the inferior alveolar nerve.
First and foremost, the orthograde retreatment of the element 3.6 was performed. We carried out the removal of the gutta-percha with solvent (OGNA, Muggiò, Italy) and the canal system was re-shaped with Protaper Next System (Dentsply Maillefer, Baillagues, Switzerland).
The canal system was obtured with warm vertical condensation and the element was filled with a fuji long-term temporary filling (Figure 1).
Dicom data were uploaded on the Navident software to plan the navigated microsurgical endodontic procedures.
Since there are not yet commercially available software dedicated to navigated surgical micro-endodontics, we have planned the ostectomy in correspondence with the mesial root of the element 3.6. For the execution of this operation, we selected the cilindrical bone mill drill with diameter of 5.2 mm which in a single surgical act would have allowed to perform the ostectomy and the apicectomy (Figure 2).
We started with the planning of the surgical approach with the CBCT image data in order to verify the movement of the burs in the three levels of the space.
Trough the registration phase we matched the patient's CBCT images to the patient's anatomical structures.

Figure 2
Digital planning with Navident system.

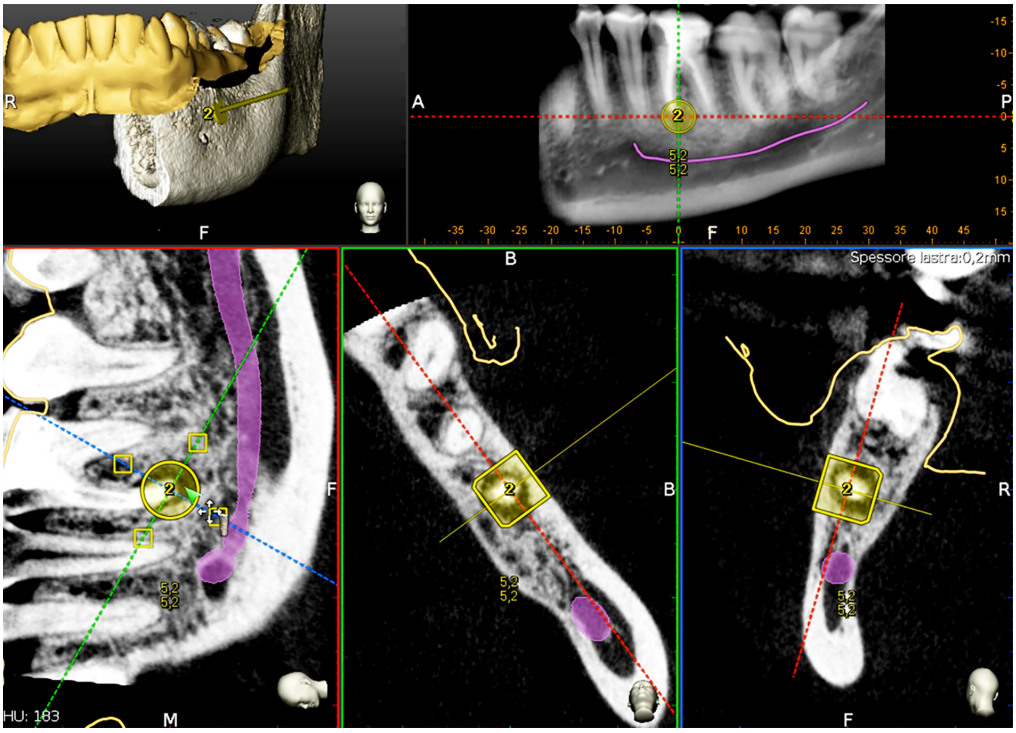

At the mandibular level we blocked a particular recognition tool called "butterfly" with silicone which allowed the stereovideocamera of the Navident system to identify the chosen anatomical site. Subsequently, thanks to the calibration phase, we verified the exact correspondence between the patient's six dental landmarks, chosen on the visualization software, and the same points in the patient's mouth.
The dental handpiece and the burs have been calibrated, through the optical recognition system.
Through the tracing phase we checked that the operator's movements in the three planes of space corresponded to what we were viewing on the screen, checking the degree of accuracy.
We checked that the previously fixed support did not move in any way to avoid losing the calibration.
Two percent mepivacaine with 1:100,000 epinephrine local anesthesia was administered for the inferior alveolar nerve block; a triangular papilla-based mucoperiosteal flap was made from the element 3.7 to the element 3.4 with a medial release incision (Figure 3).

The minimal invasive ostectomy (Ø 5.2 mm) was performed using a round bone-mill (Nobel Biocare, Yorba Linda, CA, USA) mounted on a high-speed handpiece surgical motor Kavo (Biberach, Germany) at 900 rpm. The removed bone block was stored in Hank's buffered salt solution.
Once the ostectomy phase was completed, it was possible to immediately visualize the mesiobuccal root with the fractured instrument beyond the apical foramen.
Hemostasis was obtained with an innovative hemostatic glue, utilized in general surgery (Ifabond™, Peters Surgical®).
We carried out the root resection by consuming the dental tissue around the instrument with a fine grain with a size #4 carbide round bur and a surgical length #702 carbide fissure bur (SS White Dental, Lakewood, NJ, USA) on a high-speed handpiece at 40,000 rpm.
The instrument was removed, after mobilization, with low-power angled ultrasonic tips (Acteon (Acteon Group, Olgiate Alona, Va, Italy).
A conventional 3 mm retrograde preparation was performed and the isthmus were prepared with low-power ultrasonic tips

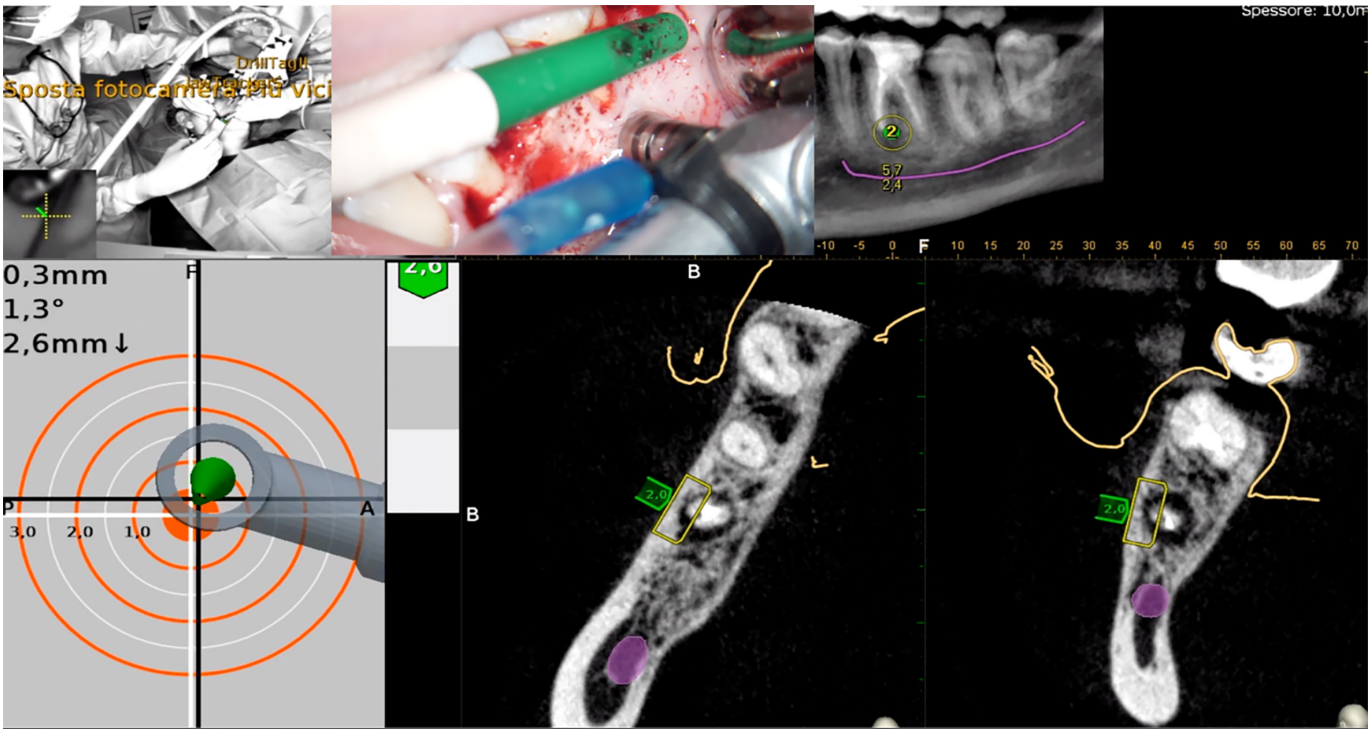

Figure 3
Ostectomy phase with bone mill drill.

(Acteon Group, Olgiate Alona, Va, Italy), using the microscope (ProErgo, Zeiss, Oberkochen, Germany).
The retrograde cavity was filled with Endosequence (Brasseler USA, Savannah, GA) and subsequently finished with diamond burs filled.
After positioning a fibrin sponge as a support, we repositioned the bone block; then the surgical wound was sutured with re-

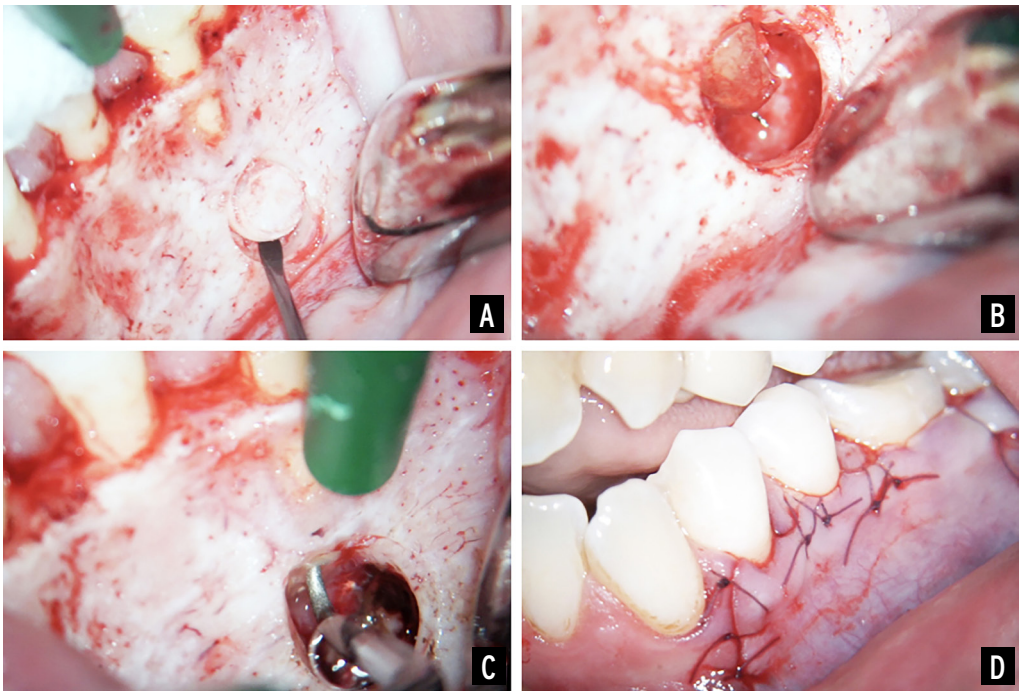

Figure 4
Dinamic microsurgical procedures: **A)** end of the ostectomy, **B)** bone after ostectomy, **C)** retrograde cavity preparation with ultrasound low power tip, **D)** suture with 6.0 Vycril.



Figure 5
Follow up: **A)** end of the microsurgical endodontics, **B)** 4 months follow up and **C)** 12 months follow up.

sorbable 6.0 Vicryl Plus (Ethicon, J&J Medical, Somerville, NJ) (Figure 4).
The suture at the mesial release incision was removed after 3 days, while the suture at the papillae was removed one week later.
The restorative build up was realized two weeks after surgery. Radiographic assessment was performed at the end of surgery, at 4 months and 12 months after surgery (Figure 5). It is possible to observe that there is a good healing of soft tissue; the lesion is in regression phase (Figure 6). The patient no longer has signs and symptoms.

Discussion

Surgical endodontics represents a valid and decisive technique in cases of teeth presenting persistent apical periodontitis, where the orthograde endodontic retreatment has not allowed to resolve the initial problem (2).
In recent decades, the concept of surgical endodontics has evolved further, through the use of increasingly performing operating techniques dedicated to a minimally invasive approach that respects the initial anatomical situation of the patient, to the point of defining this type of treatment as "microsurgical" (3, 12, 19).
The operating microscope, the micromirrors, the dedicated instrumentation, the ultrasonic tips for root canal preparation and the marketing of new cements for the filling of the retrograde cavity represent the foundations for the success of these interventions.
However, the indications for microsurgical endodontic retreatment have not changed: persistent apical periodontitis with or without symptoms in elements with adequate prosthetic restorations, correction of problems due to extrusion of material or fracture of root canal instruments and the need for histological analysis of the periradicular tissue (20).
However, in some clinical situations, surgical micro-endodontic treatment is complicated by proximity to noble anatomical structures that represent an obstacle for the

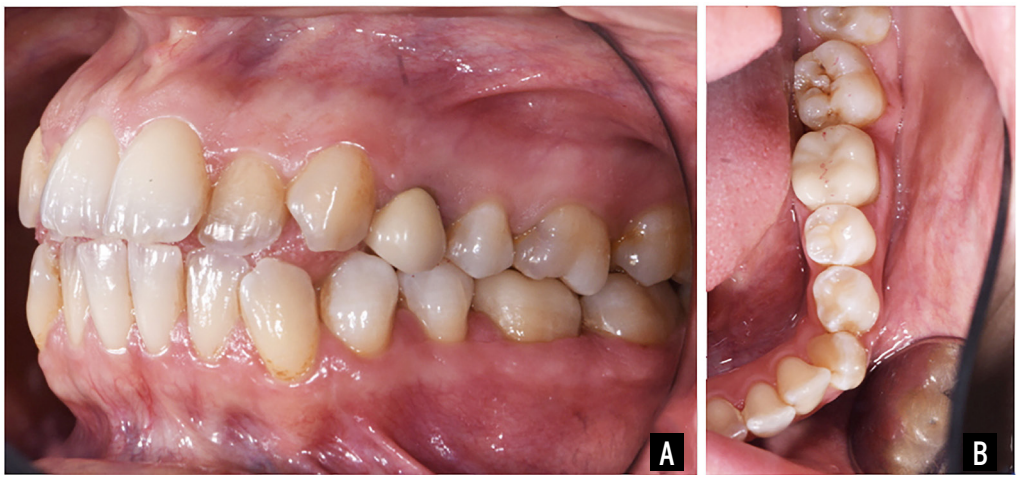

Figure 6
Clinical situation 12 months after surgery

clinician: the maxillary sinus, the inferior alveolar nerve, the mental foramen or the floor of the nose.
For this reason, in recent years the use of surgical procedures has spread, similar to those used in guided implantology for the creation of templates dedicated to osteotomic procedures. This procedure is called guided surgical micro-endodontics and has already been described in numerous scientific publications (19-22).
Guided surgical micro-endodontics involves several operating phases; through an intraoral scan of the patient and the execution of a level II radiographic investigation (CBCT), a template is created which presents a dedicated invitation to perform the osteotomy (22).
The operator, by positioning the surgical template, carries out the operation guided by the slot created during the digital planning of the operation (22). This technology, which allows a selective ostectomy, makes the operator's maneuvers safer, preserving the anatomical structures close to the site to be treated (22).
In the last 5 years, however, dynamic navigation systems have been presented and marketed on the dental market.
There are several dynamic navigation systems with decidedly different characteristics and costs; dedicated software often have different fields of application.
Dynamic navigation, through a system of tracking stereo cameras, allows you to perform surgical interventions by following the operator's movements in real time on a dedicated video. The doctor, after an accurate planning phase, can carry out the treatment and eventually modify his therapeutic strategy in progress (13).
These systems are already used in robotic surgery in medicine and find the greatest field of application in orthopedic surgery, otorhinolaryngology, ophthalmology, vascular surgery, neurosurgery and oncological surgery (13).
Their applications in odontostomatology are many and under study. Guided navigation systems are mainly used in implantology, for planning and carrying out operations in safety, in the vicinity of noble anatomical structures.
In orthograde endodontics, guided navigation systems have proved to be useful for finalizing treatment cases of dental elements with calcified canals (10) and for planning and performing intraosseous anesthesia (23). Our clinical experience is in agreement with the literature; dynamic navigation in orthograde endodontics has allowed us to finalize several cases of highly calcified teeth.
The navigation system was recently used for planning and fabricating the pulp chamber opening in a group of extracted maxillary and mandibular incisors previously scanned with a CBCT (REF nr Jain).
In half of the elements the pulp chamber was opened with the free hand method and in half with the 3D-DNS method; subsequently the teeth were subjected to a control CBCT.
The results showed that there are no differences between the two techniques as regards the mandibular incisors, while the openings made with dynamic navigation in the upper incisal group were decidedly more conservative than with the freehand method (15).
The creation of virtual models for the simulation of orthograde dental retreatments with this method has been proposed, defining it as optimal for the retreatments of elements restored with glass fiber posts (12).
The applicability of this system for surgical micro-endodontic operations has recently been applied.
In a case of persistent apical periodontitis in the frontal sector; the treatment was performed by an undergraduate student, under the supervision of an expert operator (17). However, this case was conducted in the frontal sector, where the traditional microsurgical approach could have been used in complete safety.
Some authors have used the dynamic navigation system on anatomical preparations to compare the skills of expert and non-expert operators in surgical micro-endodontic operations, hypothesizing that the method would allow the results to be equalized between operators;

the results obtained from this study refer to a comparison between the operators, highlighting in both groups a high accuracy in the execution of the osteotomy and apicectomy maneuvers, a greater speed of intervention, but highlights the need for a steeper learning curve long, especially for non-expert operators (24). Ex vivo cadaver study design applied this technology on anatomical preparations reaching the conclusion that this method allows an accurate, rapid ostectomy with a lower bone volume removed, defining it as safe and very useful in the posterior mandibular sector (11, 25).
To date, a dedicated software to perform endodontic ostectomies with this navigation system has not yet been patented.

Conclusion

Dynamic navigation technology can be used in areas close to noble anatomical structures, avoiding damage. A more conservative osteotomy allows for faster healing, fewer anesthesias, reduces bleeding; this technology reduces operator and patient fatigue.
Dynamic navigation systems still have a high cost and require a period of training to speed up the learning curve. Further studies are needed to deepen and validate this method.

Clinical Relevance

This new technology can be a valid resource to retreat persistent periapical lesions, allowing the maintenance of tooth in the oral cavity.

Conflict of Interest

The authors deny any conflicts of interest related to this study.

Acknowledgement

None.

References

1 Nair PN. On the causes of persistent apical periodontitis: a review. I.Endod J. 2006 Apr;39(4):249-81.
2 Nair PN. Pathogenesis of apical periodontitis and the causes of endodontic failures. Crit Rev Oral Biol Med. 2004;15:348-381.
3 Torabinejad M, White SN. Endodontic treatment options after unsuccessful initial root canal treatment: Alternatives to single-tooth implants. J Am Dent Assoc. 2016;147:214-20.
4 Kim S, Kratchman S. Modern endodontic surgery concepts and practice: a review. JEndod. 2006;32:601-23.
5 Azim AA, Albanyan H, Azim KA, et al. The Buffalo study: Outcome and associated predictors in endodontic microsurgery- a cohort study. Int Endod J. 2021;54:301-318.
6 Setzer FC, Kohli MR, Shah SB et al. Outcome of endodontic surgery: a meta-analysis of the literature-Part 2: Comparison of endodontic microsurgical techniques with and without the use of higher magnification. J Endod 2012;38:1-10.
7 Song M, Shin SJ, Kim E. Outcomes of endodontic micro-resurgery: a prospective clinical study. J Endod. 2011;37(3):316-320.
8 Lavasani SA, Tyler C, Roach SH et al. Cone beam Computed Tomography: Anatomic Analysis of Maxillary Posterior Teeth-Impact on Endodontic Microsurgery. J Endod. 2016;42:890-5.
9 Hawkins TK, Wealleans JA, Pratt AM et al. Targeted endodontic microsurgery and endodontic microsurgery: a surgical simulation comparison. Int Endod J. 2020;53:715-22.
10 Gambarini G, Galli M, Stefanelli LV, et al. Endodontic Microsurgery Using Dynamic Navigation System: A Case Report. J Endod. 2019;45:1397-1402.
11 Dianat O, Nosrat A, Tordik PA, et al. Accuracy and Efficiency of a Dynamic Navigation System for Locating Calcified Canals. J Endod. 2020;46:1719-1725.
12 Bardales-Alcocer J, Ram rez-Salom M, Vega-Lizama E, et al. Endodontic Retreatment Using Dynamic Navigation: A Case Report. J Endod. 2021;47:1007-1013.
13 Battista E, Gasparro R, Cacciola M et al. Dynamic Navigation System for Immediate Implant Placement in the Maxillary Aesthetic Region. Appl. Sci. 2022;12:5510.
14 Jain SD, Carrico CK, Bermanis I. 3-Dimensional Accuracy of Dynamic Navigation Technology in Locating Calcified Canals. J Endod. 2020;46:839-845.
15 Gambarini G, Galli M, Morese A, et al. Precision of Dynamic Navigation to Perform Endodontic Ultraconservative Access Cavities: A Preliminary In Vitro Analysis. J Endod. 2020;46:1286-1290.
16 Jain SD, Saunders MW, Carrico CK et al. Dynamically Navigated versus Freehand Access Cavity Preparation: A Comparative Study on Substance Loss Using Simulated Calcified Canals. J Endod. 2020;46:1745-1751.
17 Janabi A, Tordik Pa, Griffin I, et al. Accuracy and Efficiency of 3-dimensional Dynamic Navigation System for Removal of Fiber Post from Root Canal-Treated Teeth. J Endod. 2021; 47:1453-1460.
18 Lu Y-J, Chiu L-H, Tsai L-Y et al. Dynamic navigation optimizes endodontic microsurgery in an anatomically challenging area. J Dent Sci. 2021;17:580-582.
19 Syngcuk K, Samuel K. Modern Endodontic Surgery

Concepts and Practice: A Review. JOE. Volume 32, Number 7, July 2006

20 *Chong BS, Rhodes JS. Endodontic surgery. Br Dent J. 2014;216(6):281-290.*

21 *Lio F, Mampieri G, Mazzetti M et al. Guided endodontic microsurgery in apicoectomy: a review. Biol Regul Homeost Agents 2021 May-Jun;35(3 Suppl. 1):47-55.*

22 *Decurcio DA, Bueno MR, Silva JA et al. Digital Planning on Guided Endodontics Technology. Braz Dent J. 2021;32(5):23-33.*

23 *Jain SD, Carrico CK, Bermanis I et al. Intraosseous Anesthesia Using Dynamic Navigation Technology. J Endod. 2020;46:1894-1900.*

24 *Zubizarreta-Macho Á, Muñoz AP, Deglow ER, Agustín-Panadero R, Álvarez JM. Accuracy of Computer-Aided Dynamic Navigation Compared to Computer-Aided Static Procedure for Endodontic Access Cavities: An in Vitro Study. J Clin Med. 2020;9(1):129.*

25 *Aldahmash SA, Price JB, Mostoufi B et al. Real-time 3-dimensional Dynamic Navigation System in Endodontic Microsurgery: A. Cadaver Study. J Endod. 2022 Jul;48(7):922-929.*