

Novel complete-arch pillar system (CAPS) to register implant position and maxillomandibular relationship in one single visit: Complete-Arch Pillar System (CAPS)

*Original*

Novel complete-arch pillar system (CAPS) to register implant position and maxillomandibular relationship in one single visit: Complete-Arch Pillar System (CAPS) / Nuytens, P.; Grande, F.; D'Haese, R.; Salameh, Z.; Lepidi, L.. - In: JOURNAL OF DENTISTRY. - ISSN 0300-5712. - 143:(2024). [10.1016/j.jdent.2024.104885]

*Availability:*

This version is available at: 11583/2996272 since: 2025-01-06T22:52:53Z

*Publisher:*

Elsevier

*Published*

DOI:10.1016/j.jdent.2024.104885

*Terms of use:*


This article is made available under terms and conditions as specified in the corresponding bibliographic description in the repository

*Publisher copyright*

(Article begins on next page)

Contents lists available at [ScienceDirect](https://www.sciencedirect.com)

Journal of Dentistry

journal homepage: [www.elsevier.com/locate/jdent](http://www.elsevier.com/locate/jdent)

Short communication



# Novel complete-arch pillar system (CAPS) to register implant position and maxillomandibular relationship in one single visit

Philippe Nuytens<sup>a,\*</sup>, Francesco Grande<sup>b,c</sup>, Rani D'haese<sup>a</sup>, Ziad Salameh<sup>d</sup>, Luca Lepidi<sup>e</sup><sup>a</sup> Department of Reconstructive Dentistry, Faculty of Medicine and Health Sciences, Ghent University, C. Heymanslaan 10, 9000 Ghent, Belgium<sup>b</sup> Department of Prosthodontics, University of Ferrara, Ferrara, Italy<sup>c</sup> Department of Mechanical and Aerospace Engineering, Politecnico di Torino, Turin, Italy<sup>d</sup> Professor and Director, Research Center, Faculty of Dental Medicine, Lebanese University Beirut, Lebanon<sup>e</sup> Adjunct Professor, Department of Prosthodontics, University of Ferrara, Italy

## ARTICLE INFO

## Keywords:

Scan body  
Complete-arch  
Intraoral scanner  
Pillar  
Scan body attachment  
Occlusal pillar

## ABSTRACT

**Objectives:** This article presents a novel complete-arch pillar system (CAPS) to register implant position and maxillomandibular relationship in one single visit for implant-supported fixed complete dental prostheses (IFCDPs).

**Material and Methods:** The novel system presents a 3-unit toolset comprising intraoral scan bodies (ISBs), lateral pillar attachments (LPAs) and occlusal pillar attachments (OPAs). A 2-stage single visit workflow by an intraoral scanner (Trios 5) was introduced. The first stage "Screw-Scan-Done" was used to describe complete-arch intraoral implant scanning using LPAs. The second stage "Screw-Occlude-Done" involved virtual occlusal recording using OPAs. Two patients with one single edentulous arch were selected for this study. In the first patient, 6 bone level implants (Bone Level Tapered, Straumann) were placed in the edentulous maxilla at positions 12, 14, 16, 22, 24 and 26. In the second patient, 4 bone level implants (NobelActive CC, Nobel Biocare) were placed in the edentulous mandible at positions 32, 35, 42 and 45. A CAD-CAM procedure was initiated with the acquired IOS data to fabricate an interim IFCDP at the same day. Periapical radiographs were obtained of the implant-prosthetic connection of the definitive IFCDPs to verify the passive fit. Metrology software (Geomagic Qualify, 3D Systems – Matlab, Mathworks) was used to assess the implant analogs position in the 3D-printed casts used for fabricating the definitive IFCDPs. A quantitative occlusal relationship analysis was performed with IOS.

**Results:** Radiographic examination revealed no gaps at implant-prosthetic connection of the definitive IFCDPs. The 3D-printed casts showed an overall average distance deviation within the clinically acceptable range of errors of 150 µm. Quantitative occlusal relationship analysis with IOS showed well-distributed contacts.

**Conclusion:** Within the limitations of this study, the following conclusions can be drawn:

- (1) A 3-unit toolset with ISBs, LPAs and OPAs allows to register the implant position and maxillomandibular relationship in one single visit;
- (2) the 2-stage clinical workflow with the CAPS system facilitates the IOS data acquisition for fabrication of an interim IFCDP at the same day;
- (3) a passive fit was demonstrated for the interim and the definitive IFCDPs.

**Clinical significance:** The CAPS system can help clinicians to register the implant position and the maxillomandibular relationship in one single visit for the fabrication of an IFCDP.

## 1. Introduction

A fully digital workflow for a complete-arch fixed implant-supported

prosthesis is challenging for clinicians and dental technicians. For clinicians, complete-arch implant scanning using intraoral scanner (IOS) remains a critical aspect, especially in the mandibular arch [1]. Several

\* Corresponding author at: Department of Reconstructive Dentistry, Faculty of Medicine and Health Sciences, Ghent University, C. Heymanslaan 10, 9000 Ghent, BELGIUM.


E-mail address: [philippe.nuytens3@gmail.com](mailto:philippe.nuytens3@gmail.com) (P. Nuytens).

<https://doi.org/10.1016/j.jdent.2024.104885>

Received 11 November 2023; Received in revised form 28 January 2024; Accepted 7 February 2024

Available online 10 February 2024

0300-5712/© 2024 The Authors. Published by Elsevier Ltd. This is an open access article under the CC BY license (<http://creativecommons.org/licenses/by/4.0/>).

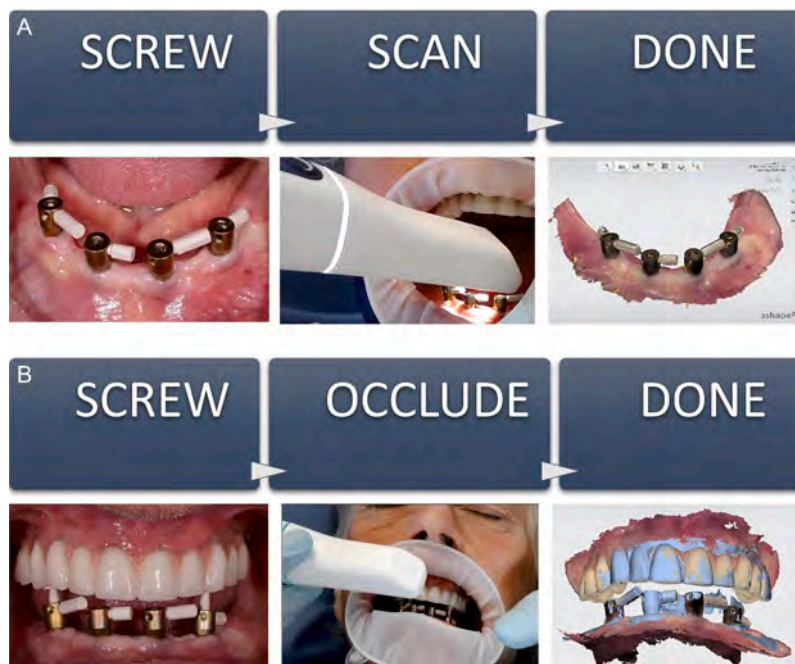

**Fig. 1.** Basic tools of novel scan body system (CAPS SYSTEM, Dynamic Abutment Solutions, Lleida, Spain). (A,B) Connection of the basic tools, (C) Assembling of LPAs to the ISB, (D) Mounting OPA to the ISB. ISB, intraoral scan body; LPA, lateral pillar attachment; OPA, occlusal pillar attachment.

factors influence the 3 dimensional (3 D) accuracy of a complete-arch implant scan: the interimplant distance, the implant angulation, the intraoral scan body (ISB) morphology, the IOS software and the scanning technique applied [1,2,3,4,5].

Most dental computer-assisted-design (CAD) software programs provide procedures for the alignment of various digital scans (meshes). The creation of a virtual implant master cast and the subsequent procedure of virtual tooth setup is widely applied in digital dentistry. The

mesh alignment process performed by the IOS is crucial because it is the starting point of the workflow. Therefore, the ISB system and the used scan protocol play an important role in this process and could enhance the accuracy and the speed of complete-arch implant scans [6,7,8]. However, the edentulous arch lacks anatomical landmarks, and thus poses a challenge for accurate direct intraoral scanning [4,9]. Oral environmental factors, patient movements, ambient lighting conditions, scanning strategy, use of artificial landmarks and operator expertise



**Fig. 2.** Two-stage single visit workflow. (A) The first stage “screw-scan-done”: complete-arch intraoral implant scanning using ISBs with LPAs, (B) The second stage “screw-occlude-done”: virtual occlusal recording using ISBs with OPAs. ISB, intraoral scan body; LPA, lateral pillar attachment; OPA, occlusal pillar attachment.

impact the IOS accuracy of complete edentulous arches with multiple implants [3,10,11].

Various ISB connecting techniques have been recently described to improve the accuracy of complete-arch implant scans [12], which include the use of additional materials and devices such as dental floss, orthodontic wire, acrylic resin, bis-acryl resin composite, self-cure polymethylmethacrylate resin or a calibrated splinting framework [13,14,15,16,17,18]. However, connecting ISBs can be challenging and time-consuming, depending on implant positions and interimplant distances. Fu et al. [19] examined the use of prefabricated aids mounted at the lateral side of ISBs and compared the accuracy of complete-arch scans with stereophotogrammetry (SPG). IOS scans with prefabricated aids mounted to ISBs revealed the same clinical accuracy results as SPG. Also, the most efficient workflow was demonstrated with an IOS device using prefabricated aids.

In edentulous patients, the absence of a tooth-related vertical dimension of occlusion (VDO) and centric relation (CR) is the main concern to establish a single visit approach for patients demanding a IFCDP. In this view, different techniques to register the maxillomandibular relationship have been previously described, which include the use of a surgical guide [20], a complete denture [21] or an implant-supported interim prosthesis [22]. Although these techniques have been successfully used in clinical studies, additional appliances or treatment steps are still required. In this regard, a novel clinical technique was described by Nuytens et al [23,24], in which occlusal pillars with different lengths were mounted to ISBs to obtain virtual occlusal records for a IFCDP. This short communication describes the use of a novel complete-arch pillar system (CAPS) to register implant position and maxillomandibular relationship in one single visit.

## 2. Materials and methods

### 2.1. Novel scan body system

The present digital system (CAPS SYSTEM, Dynamic Abutment Solutions, Lleida, Spain) includes 3 basic tools (Fig. 1):

1. ISBs (REFERENCE SCANBODY, Dynamic Abutment Solutions, Lleida, Spain) at multiunit abutment level with 3 screw thread entries at the ISB flank and one modified screw access channel on the ISB top side.
2. LPA in polyetheretherketone (PEEK PIN, Dynamic Abutment Solutions, Lleida, Spain) for the connection to the screw thread entries at the ISB flank. The LPAs used in the present article had 3 different lengths (6, 9 and 13 mm).
3. OPA (CAPS PILLAR, Dynamic Abutment Solutions, Lleida, Spain) to mount to the modified screw access channel on top of the ISB. The OPAs used in the present article are fabricated in PEEK and had 3 different lengths (3.8, 6 and 8 mm).

The first stage “Screw-Scan-Done” was used to describe complete-arch intraoral implant scanning using LPAs (Fig. 2A). The second stage “Screw-Occlude-Done” involved virtual occlusal recording using OPAs (Fig. 2B).

### 2.2. Patient selection

Two patients with a single edentulous arch were enrolled in this study. Inclusion criteria comprised good oral hygiene and systemic health (ASA class I and II), presence of a complete denture with clinically acceptable vertical dimension of occlusion (VDO) and occlusal relationship with the opposing teeth, absence of soft and hard tissue defects, mouth opening of at least 30 mm, and compliance with the novel 2-stage protocol. Exclusion criteria comprised uncontrolled systemic diseases, uncontrolled periodontitis, and mouth opening <30 mm. A written informed consent was obtained from the participants, following the

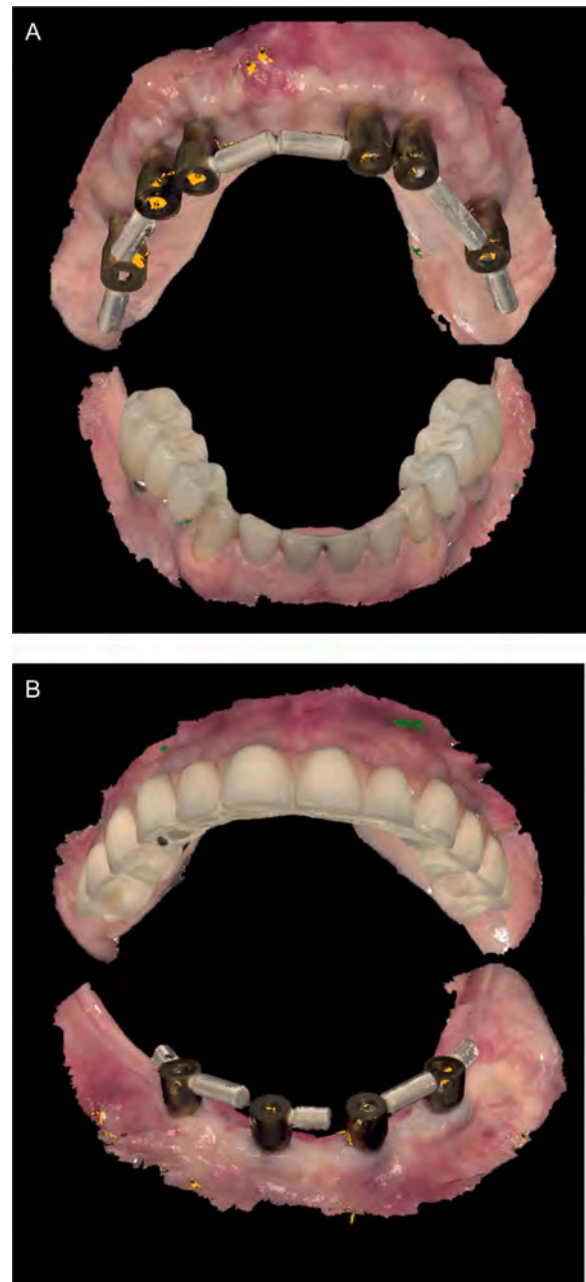
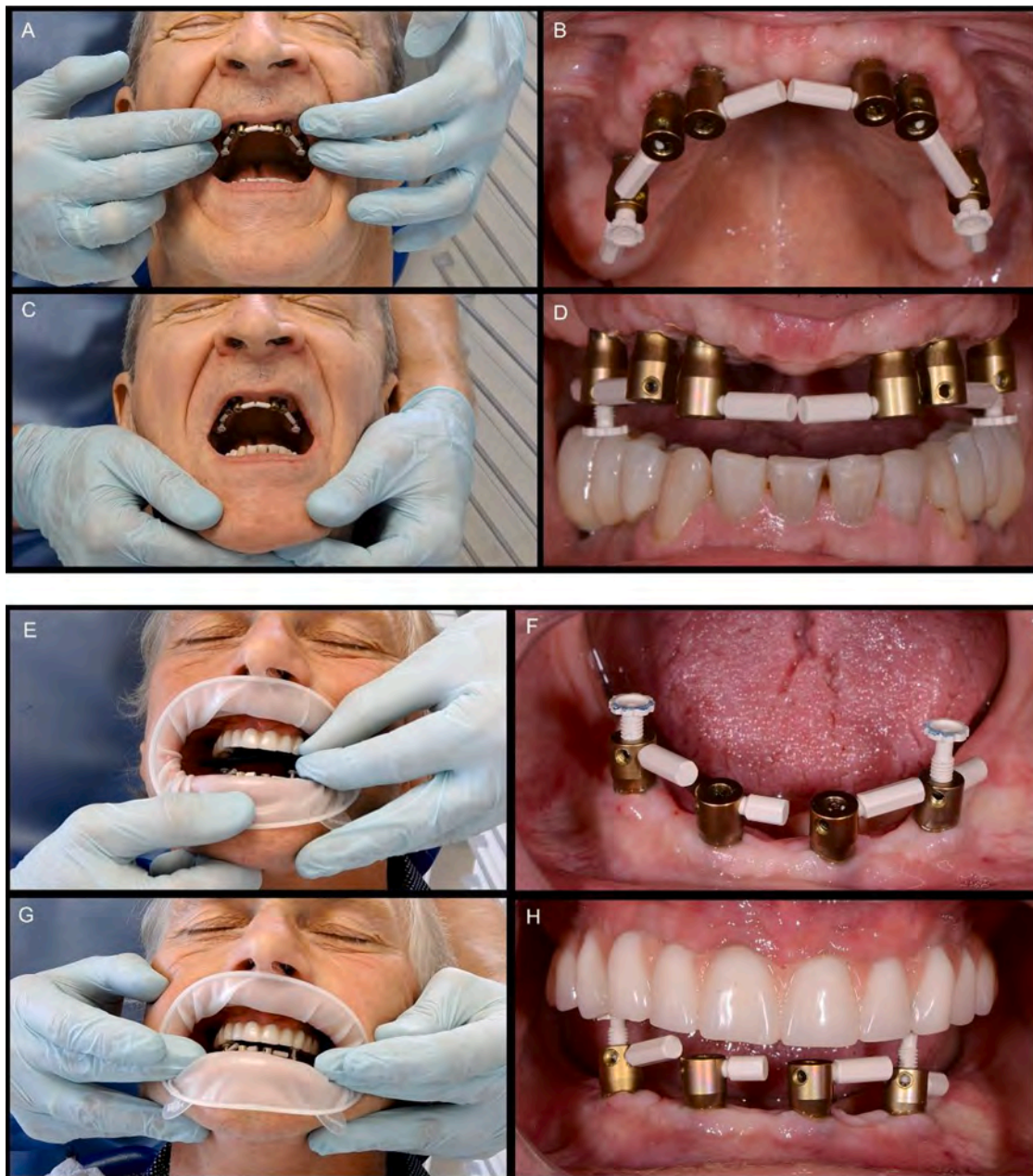

Fig. 3. Results of first stage “screw-scan-done”. (A) Intraoral scans in the first patient with an edentulous maxilla with 6 implants, (B) Intraoral scans in the second patient with an edentulous mandible with 4 implants.

guidelines of the Research Committee for data acquisition with the novel ISB system. Cone Beam Computed Tomography (CBCT) imaging (PaX-i3D, Vatech, Gyeonggi-do, South Korea) was performed and a mucosal supported implant guide was fabricated for both patients, based on the complete denture’s tooth arrangement. In the first patient, 6 bone level implants (Bone Level Tapered, Straumann, Villeret, Switzerland) were installed at positions 12, 14, 16, 22, 24 and 26. In the second patient, 4 bone level implants (NobelActive CC, Nobel Biocare, Zürich, Switzerland) were installed at positions 32, 35, 42 and 45. After the implant osseointegration period of 4 months, multiunit abutments (MULTI-UNIT DAS, Dynamic Abutment Solutions, Lleida, Spain) were mounted with a torque value of 25 Ncm following the company instructions.



**Fig. 4.** Second stage “screw-occlude-done”. Bimanual manipulation technique to guide the patient’s mandible into CR, with mounting and adjusting of the OPAs to ISBs. (A-D) Patient 1, (E-H) Patient 2. CR, centric relation; ISB, intraoral scan body; OPA, occlusal pillar attachment.

### 2.3. VDO determination

In both patients, the VDO with the existing complete denture worn during the implant osseointegration period, was measured extraorally [25]. To achieve this, 2 extraoral dots were placed at the nasal tip and chin with a black pencil and a digital caliper (DIN 862, Vogel GmbH & Co. KG, Kevelaer, Germany) was applied.

### 2.4. Two-stage workflow

#### Stage I: Screw-Scan-Done

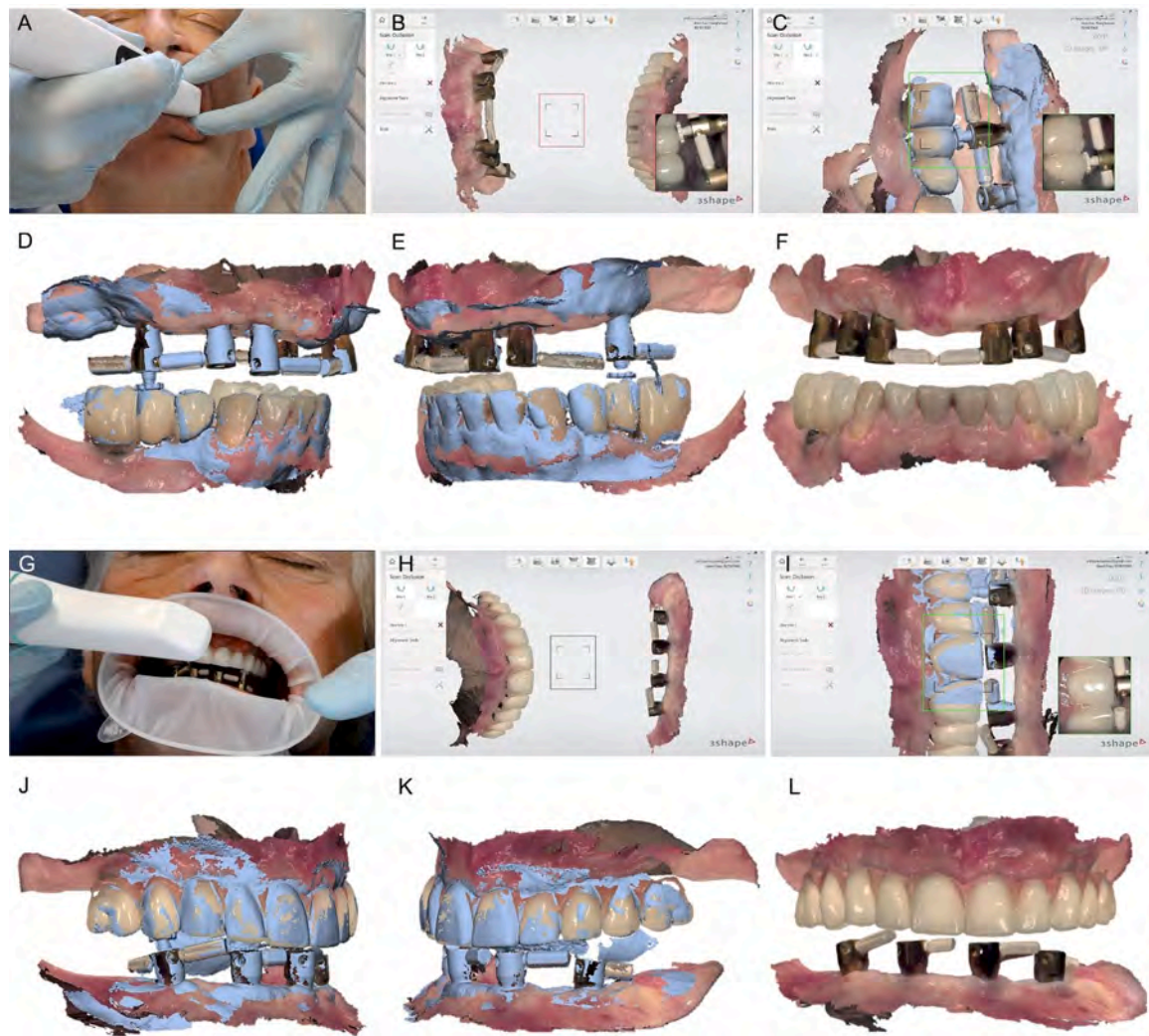
The first stage involved a complete-arch intraoral implant scan using ISBs and LPAs. First, assembled structures of ISBs with LPAs were constructed. Second, the assembled structures (ISBs + LPAs) were installed in a chain formation to the multiunit abutments. Finally, a complete-arch implant scan was obtained with a palatal-occlusal-buccal

scanning strategy [26] using an IOS (Trios 5 v22.1.6.0, 3 Shape A/S, Copenhagen, Denmark) combined with an antagonist scan. The scan conditions were: 1000 lux room light (no chair light), air dry mucosal condition, disabled color mode.

In the first patient, a complete-arch intraoral implant scan was obtained of the edentulous maxillary arch on multiunit abutments connected to 6 bone level implants. In the second patient, a complete-arch intraoral implant scan was obtained of the edentulous mandibular arch on multiunit abutments connected to 4 bone level implants (Fig. 3).

#### Stage II: Screw-Occlude-Done

The second stage involved virtual occlusal recording using OPAs. By screwing the OPAs in or out the screw access channel of the ISBs, the VDO was adjusted to the VDO obtained with the existing complete denture [25]. A digital caliper (DIN 862, Vogel GmbH & Co. KG, Kevelaer, Germany) was applied extraorally. The bimanual manipulation technique [27,28] was used to guide the patient’s mandible into CR



**Fig. 5.** Second stage “screw-occlude-done”. Obtaining virtual occlusal records with IOS. (A-F) Patient 1, (G-L) Patient 2. (Trios 5 v22.1.6.0, 3Shape A/S, Copenhagen, Denmark). IOS, intraoral scanner.

(Fig. 4). After obtaining a stabilized closure path, virtual occlusal records were acquired (Fig. 5).

### 2.5. Laboratory workflow for fabricating the interim IFCDP

After the 2-stage clinical workflow, the laboratory workflow initiated with the alignment of the ISB library file using a dental software program (DentalCAD 3.1 Rijeka, exocad, Darmstadt, Germany) (Fig. 6 A and E). Subsequently, the mesh of the LPAs was removed using the ‘lasso tool’ (Fig. 6 B and F). Finally, a virtual tooth setup for a IFCDP was created (Fig. 6 C and G).

For both patients, a PMMA interim prosthesis was fabricated with a milling machine (Compact line M1 Milling Unit, Zirkozahn, Gais, Italy). The milling rotary instruments were set to the smallest size of 0.6 mm, and wet processing was performed with a prefabricated resin block (Temp premium flexible, Zirkozahn, Gais, Italy). Additionally, 3 D-printed casts were fabricated using photopolymer resin (NextDent, Soesterberg, the Netherlands) with an industrial 3 D printer (Pro 4 K XL, Asiga, Erfurt, Germany). Multiunit abutment analogs (DAS Multi-Unit Digital Analog, Dynamic Abutment Solutions, Lleida, Spain) were inserted into the casts and tightened. With use of these 3 D-printed casts, titanium interfaces (Multi-Unit Non-Engaging Dynamic Ti-Base G0.5, Dynamic Abutment Solutions, Lleida, Spain) were adhesively bonded at the prosthetic connection with a self-adhesive resin luting cement

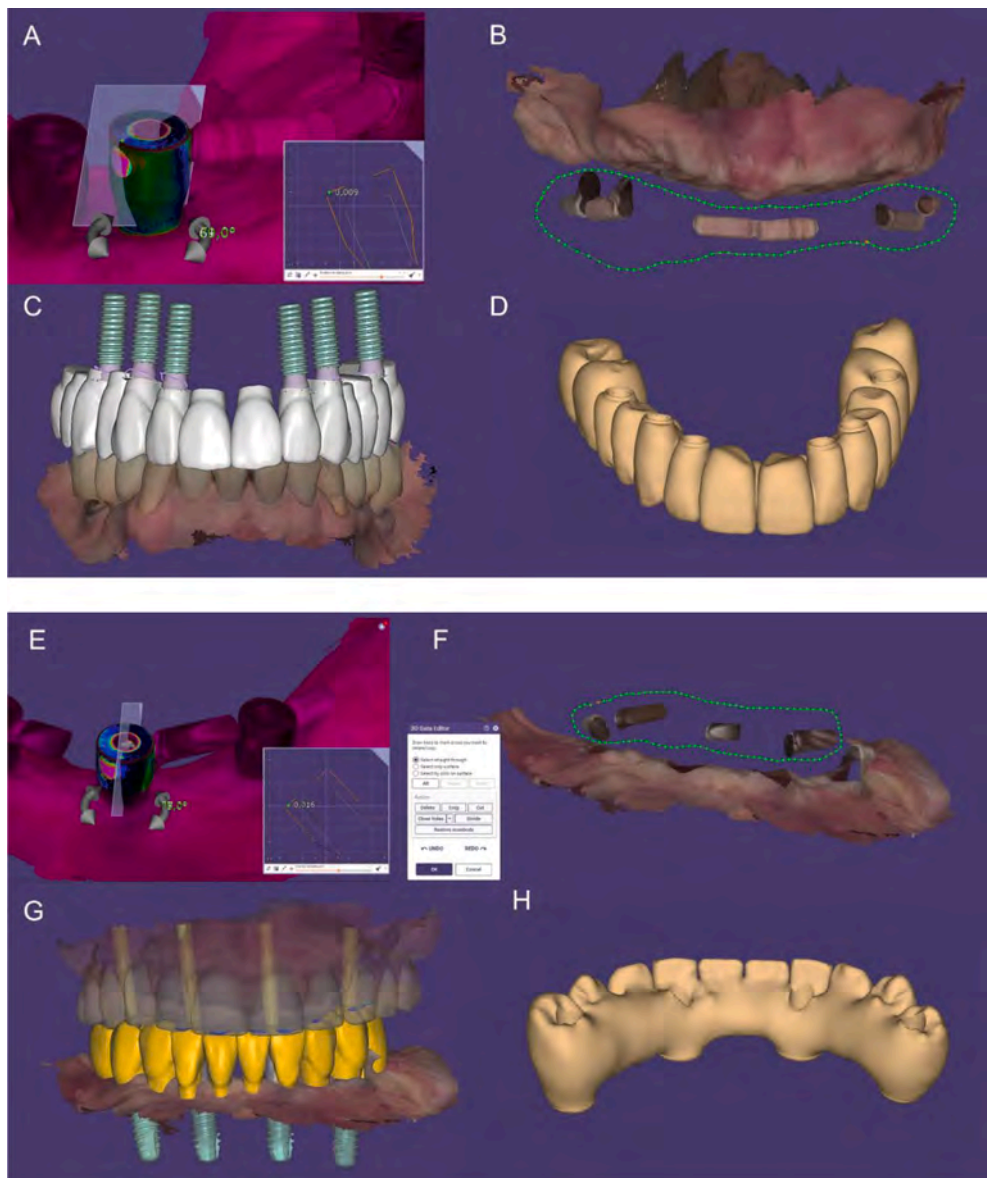
(Multilink Hybrid Abutment, Ivoclar, Zurich, Switzerland).

In both patients, a PMMA interim fixed prosthesis was delivered at the same day. The screw resistance test [29,30] was performed without detecting any resistance during manually screw tightening. The screws were tightened alternatively, starting with the implant closest to the midline. The screws were finally assured at the recommended torque level (25 Ncm) using a mechanical and digital torque gauge (OsseoSet 300, Nobel Biocare, Zürich, Switzerland). Marginal fit was examined clinically with the tip of an explorer and evaluation was also performed radiographically.

The interim prosthesis was used to evaluate the following occlusal parameters: 1. VDO, 2. CR and 3. occlusal contacts and occlusal guidance. Several aesthetic parameters were evaluated: 1. midline, 2. smile line, 3. tooth anatomy, 4. tooth shade and 5. gingival embrasures for optimal cleanability Fig 7.

### 2.6. Laboratory workflow for fabricating the definitive IFCDP

To verify positional and angular implant analogs displacement in the 3D-printed casts and to proceed with the fabrication of the definitive IFCDPs, corresponding ISBs were attached to the multiunit abutment analogs and hand-tightened. The casts were digitized using a laboratory desktop scanner (S600 ARTI SCANNER, Zirkozahn, Gais, Italy), exported as STL files and imported into a metrology software program



**Fig. 6.** Laboratory workflow for interim IFCDPs. (A-D) Maxillary interim IFCDP: (A) Digital scan body matching, (B) Elimination of LPAs with 'lasso tool', (C) Adjusting virtual tooth setup, (D) STL of maxillary interim IFCDP; (E-H) Mandibular interim IFCDP: (E) Digital scan body matching, (F) Elimination of LPAs with 'lasso tool', (G) Adjusting virtual tooth setup, (H) STL of mandibular interim IFCDP. (DentalCAD 3.1 Rijeka, exocad, Darmstadt, Germany). IFCDP, implant-supported fixed complete dental prosthesis; LPA, lateral pillar attachment; STL, standard tessellation language.

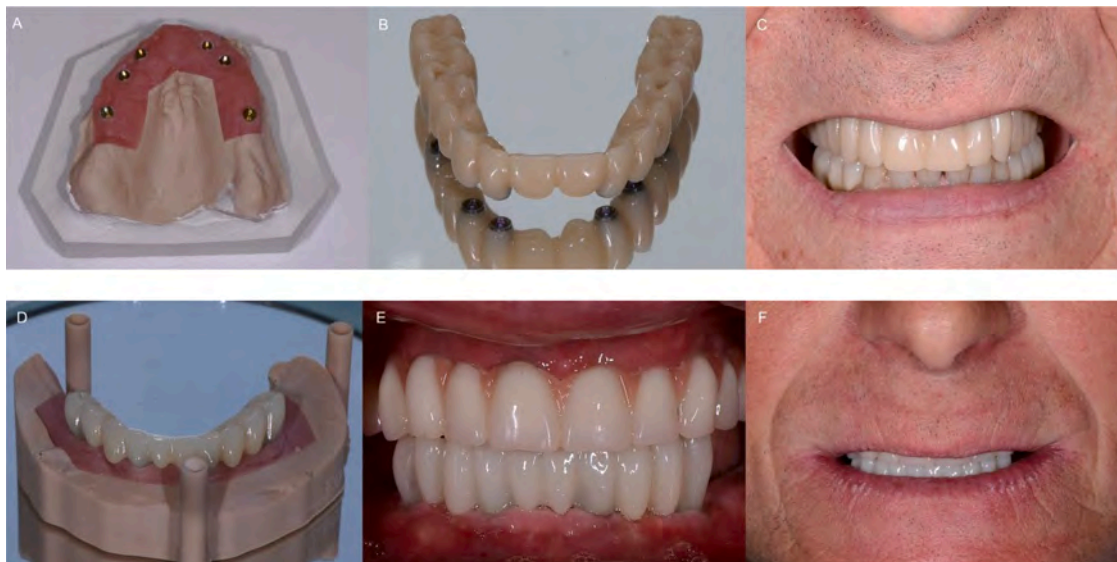
(Geomagic Qualify, 3D Systems, Rock Hill, SC, USA), together with the STL of the intraoral scans. Automatic detection of the ISB shape and replacement to the ISB library file at its site was performed. Subsequently, the STL files of the intraoral scans were aligned with the corresponding cast STL using a best-fit algorithm (MatLab, Mattworks) (Fig. 8A, B). The interimplant distances were measured and compared with the STL of the intraoral scan (mean values  $95 \pm 74 \mu\text{m}$  for patient 1 and  $81 \pm 26 \mu\text{m}$  for patient 2). The included angle was determined based on the central vertical axes of the ISB library file (Fig. 8C, D). Angular deviation at each ISB position was compared with the ISB position of the intraoral scan (mean values  $0.43 \pm 0.36^\circ$  for patient 1 and  $0.37 \pm 0.27^\circ$  for patient 2). For both patients, the clinical threshold of  $150 \mu\text{m}$  [31] was achieved and the laboratory workflow for the definitive IFCDP was proceeded.

After 4-weeks evaluation period with the interim IFCDP, both patients were recalled for prosthetic adjustments. Clinical examination of occlusal contacts was performed using micro-thin articulating paper ( $40 \mu\text{m}$  Arti-Check; Bausch, Nashua, USA). The first patient preferred a tooth

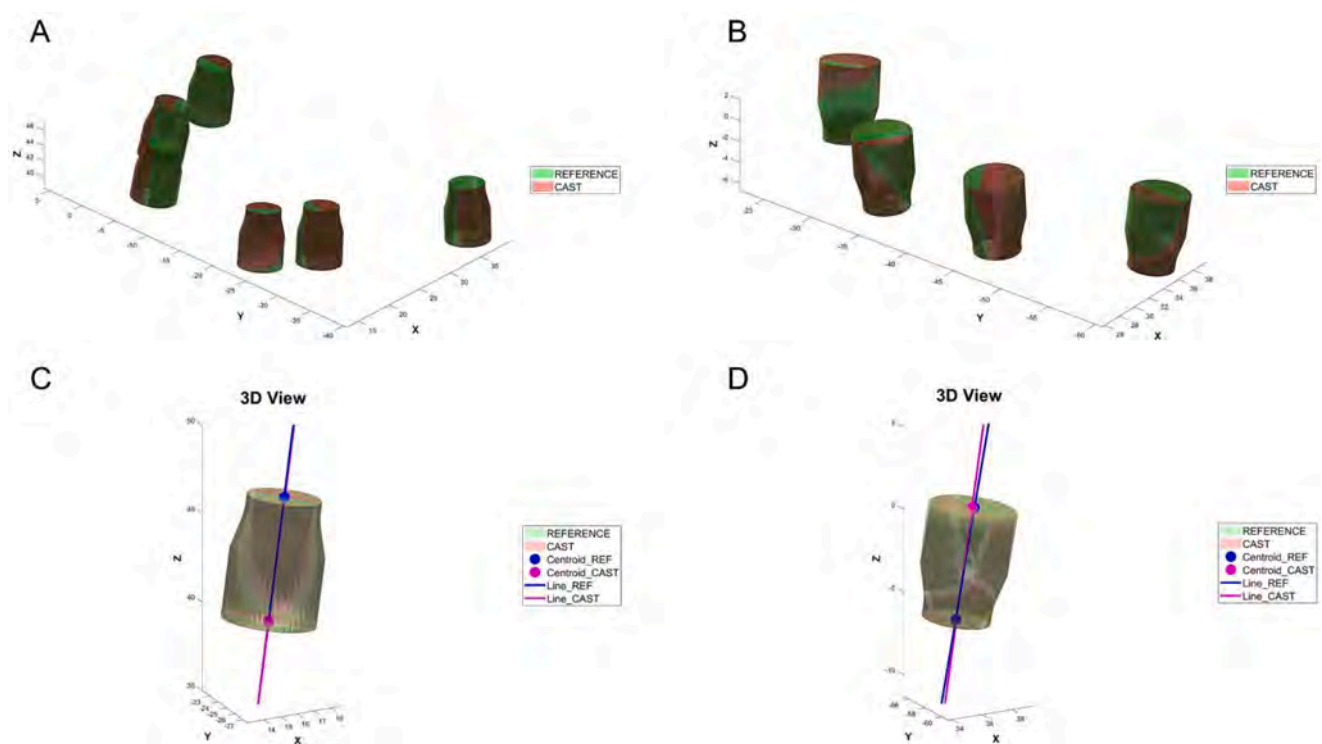
size modification by addition of a gum shade coating and a minor occlusal adjustment was needed to obtain optimal occlusal relationship with the opposing teeth. Accordingly, a complete-arch titanium framework by milling on 6 maxillary multiunit abutments (TITANIT 5 95H14, Zirkonzahn, Gais, Italy) was proposed with adhesively bonded composite teeth (Visio.lign, Bredent medical, Senden, Germany). This resulted in a hybrid IFCDP, finalized with gum shade composite (Gradia Plus Gum Shades, GC, Luzern, Switzerland) (Fig. 9A-C).

The second patient was satisfied with the aesthetic outcome of the PMMA interim IFCDP. There was no need for occlusal adjustments. As definitive restoration, an IFCDP was fabricated in zirconia by a copy-milling strategy on 4 mandibular multiunit abutments (Prettau 2 Dispersive, Zirkonzahn, Gais, Italy) (Fig. 9F-H).

Periapical radiographs were obtained of the implant-prosthetic connection to verify passive fit of the definitive IFCDPs (Fig. 9D-E, I-J). Furthermore, no resistance was detected with the definitive IFCDPs until the final recommended torque value ( $25 \text{ Ncm}$ ) was reached using a digital torque gauge (OsseoSet 300, Nobel Biocare, Zürich, Switzerland).



**Fig. 7.** Clinical delivery of interim IFCDPs. (A) Maxillary implant cast, (B) Maxillary interim IFCDP, (C) Maxillary interim IFCDP in occlusal relationship; (D) Mandibular interim IFCDP on implant cast, (E, F) Intraoral and extraoral view of mandibular interim IFCDP. (Temp premium flexible, Zirkozahn, Gais, Italy). IFCDP, implant-supported fixed complete dental prosthesis.



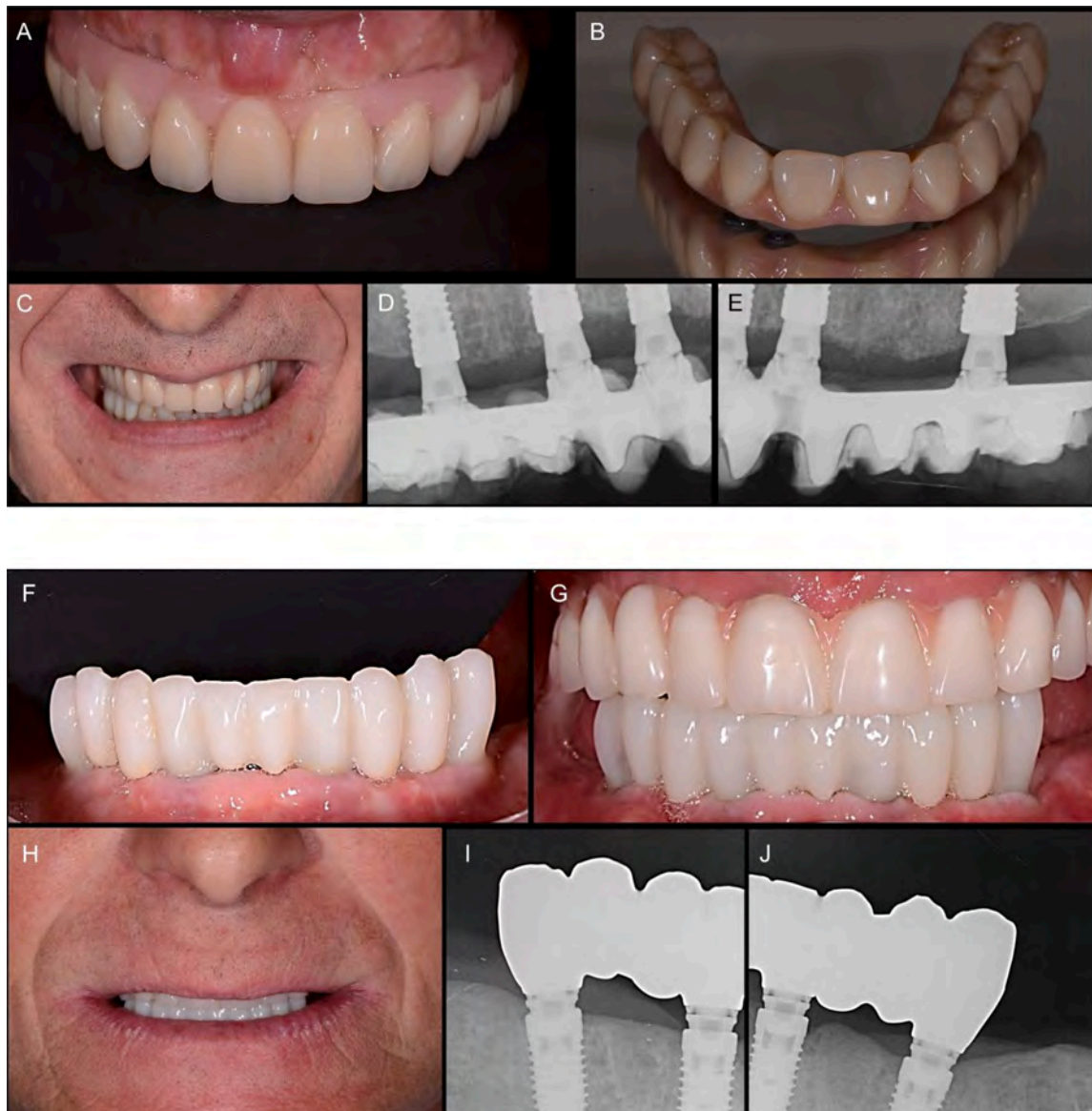**Fig. 8.** Verification of positional and angular implant displacement of the 3D-printed casts used for fabrication of definitive IFCDPs. (A-B) STL files of intraoral scans aligned with corresponding casts using best-fit algorithm. (C-D) Angular deviation measurement after identifying centroids at implant connection level and coronal level of each ISB. (Matlab, Mathworks). IFCDP, implant-supported fixed complete dental prosthesis; ISB, intraoral scan body; STL, standard tessellation language.

Screws were tightened alternatively starting with the implant closest to the midline.

To examine the occlusal parameters at CR with the definitive IFCDPs, myostabilisation with bimanual manipulation technique was used [27]. When the patients were guided into CR, two digital bite records were acquired and a quantitative occlusal relationship analysis was performed with IOS (Fig. 10A, B). The OVD of the definitive IFCDPs was measured using a digital caliper on extraoral facial reference marks and compared to the measurement with the complete denture.

### 3. Results

Radiographic examination revealed no gaps at implant-prosthetic connection of the definitive IFCDPs. The 3D-printed casts showed an overall average distance deviation within the clinically acceptable range of 150 µm. Analysis of the CR with the definitive IFCDPs revealed well-distributed occlusal contact points in both patients [32]. Analysis of the OVD on extraoral facial reference marks with the IFCDPs compared to the OVD with the complete denture revealed a deviation of 0.32 mm for



**Fig. 9.** Clinical delivery of definitive IFCDPs. (A) Diagnostic wax-up of definitive maxillary IFCDP on milled titanium framework with composite teeth (Visio.lign, Bredent medical, Senden, Germany). (B, C) Clinical delivery of definitive maxillary IFCDP. (D-E) Periapical radiograph using parallelization method. (F-H) Clinical delivery of definitive mandibular IFCDP (Prettau 2 Dispersive, Zirkonzahn, Gais, Italy). (I-J) Periapical radiograph using parallelization method. IFCDP, implant-supported fixed complete dental prosthesis.

the first patient and 0.41 mm for the second patient.

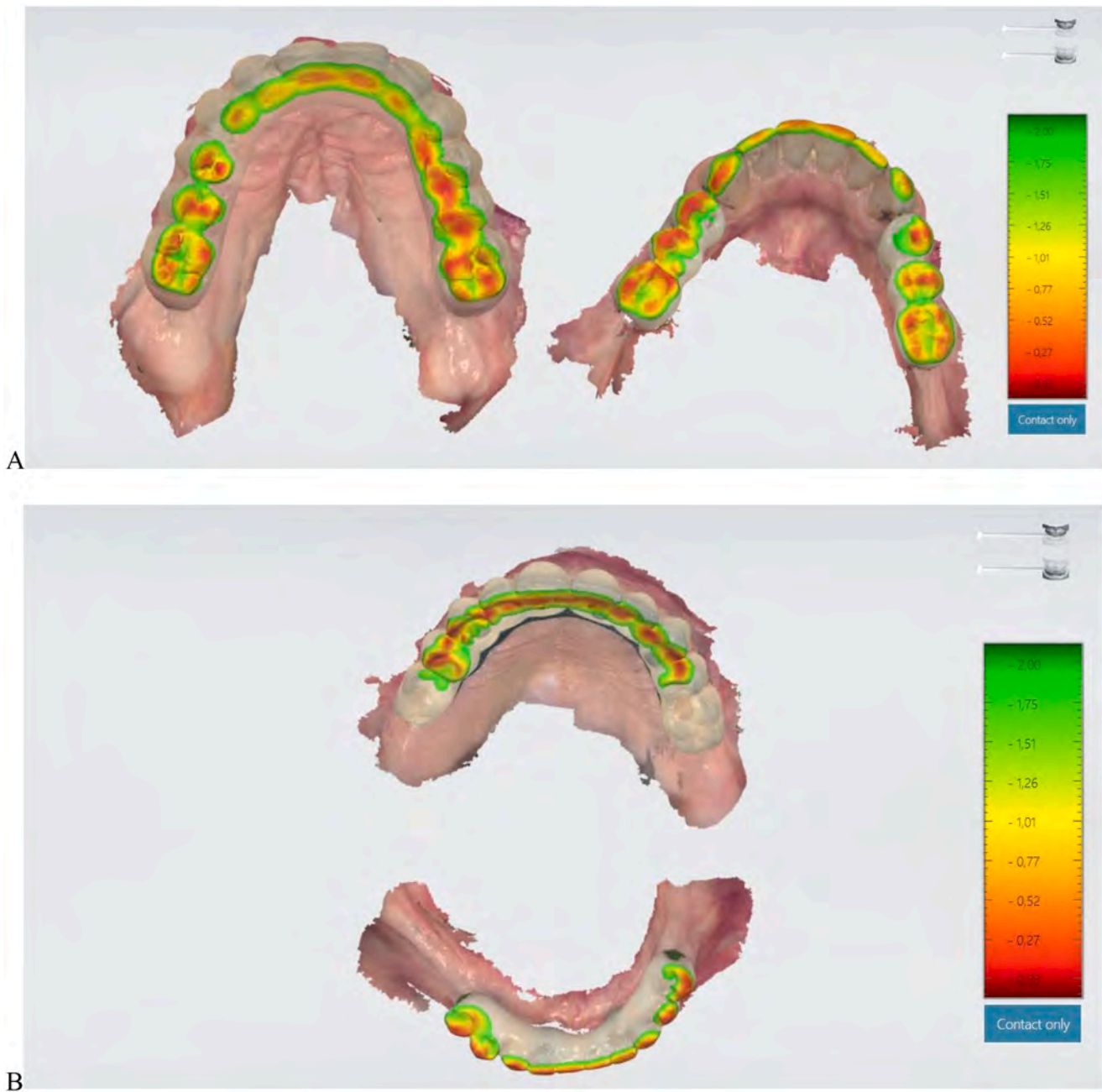
#### 4. Discussion

Digital workflows for complete arch implant rehabilitation has become routine to achieve excellent functional and esthetic outcomes [3,4,15]. Meanwhile, a precise maxillomandibular relationship record is the key to obtain good long-term outcomes for IFCDPs [32]. This short communication describes two complete arch implant rehabilitations, successfully delivered in two patients using a novel complete-arch pillar system (CAPS). The main advantage of this novel system is the integration of the maxillomandibular relationship into the intraorally acquired dataset during first prosthetic visit. Furthermore, the elimination of moldable material or wax rim and the simplicity of adjusting OVD with screw-retained OPAs contributes to a more complete digital prosthetic workflow. The maintenance of the OVD from the complete denture to the definitive IFCDP can be considered beneficial for implant-supported rehabilitation [33,34].

ISB connecting techniques can be challenging and time-consuming [12], depending on implant positions and interimplant distances. In the present study, a user friendly technique was described with screw-retained LPAs. Further research is needed to learn more about the accuracy and time efficiency.

However, these clinical improvements are associated with some limitations. The main limitation concerned the implant position in the edentulous arch (distribution, angulation, depth and interimplant distance). OPAs can only serve as an adjustable device to obtain virtual occlusal records when the implant position is favorable. Furthermore, LPAs can only serve as fixed landmarks when the interimplant distance and angle are conducive. A CBCT planning and/or a mucosal supported implant guide (based on a clinically approved teeth setup) might be necessary to overcome this limitation. Difficulties may also occur with an irregular antagonist arch. Hence, it is recommended to restore the antagonist arch before using the CAPS system.

Current diameter of occlusal pillar attachments is 4.8 mm. The screw thickness of OPAs is 2.5 mm. The fit at the inner screw thread of ISBs was



**Fig. 10.** Quantitative occlusal relationship analysis with IOS in terms of number, position, size and distribution of occlusal contacts. (A) Definitive maxillary IFCDP in patient 1, (B) Definitive mandibular IFCDP in patient 2. (Trios 5 v22.1.6.0, 3Shape A/S, Copenhagen, Denmark). IOS, intraoral scanner; IFCDP, implant-supported fixed complete dental prosthesis.

calculated to engage with a small level of resistance, which contributes to the capability of holding the screw at different occlusal heights and stabilize with the antagonist arch. OPAs were fabricated in PEEK material for its chemical resistance (corrosion resistance) and wear resistance. Further research is needed to investigate whether a wider occlusal platform could improve contact during occlusal record stabilization.

Another limitation of the presented CAPS system was the shiny titanium surface of current ISBs. In the present study, it did not affect intraoral scanning with IOS (Trios 5). Meanwhile, the ISB surface of the CAPS system was modified with a matte surface. Multiunit abutments used in this article (MULTI-UNIT DAS, Dynamic Abutment Solutions, Lleida, Spain) are available for 360 different implant types on the market. The digital workflow can be used in an open system without restrictions from dental CAD software programs. The CAPS system will

be available on Straumann Screw-retained Abutment (SRA) platform and Nobel Biocare Multi-unit Abutment platform in near future. In the present article, the height of the ISBs was 7 mm. Most scan bodies have a height of 10 mm and are not suitable for insertion of OPAs in patients with limited mouth opening. The protocol requires mouth closure at the correct VDO, without interference of ISBs. Therefore, the length of the scan bodies should be limited, and the variation of occlusal pillars should be wide.

Furthermore, this novel system can be used in a post-surgical setting; upon completing the implant placement an interim fixed prosthesis can be delivered at the same day, without additional preparation of a surgical guide, cast or appliance.

In the present study, the VDO of the existing denture was used for adjusting the OPAs [25]. However, it is not mandatory to start with a

predetermined VDO. Various techniques have been reported for measurement of the VDO in edentulous patients, ranging from use of swallowing [35], functionally acquired jaw positions associated with phonetics [36], or facial aesthetic appearance [37]. At this stage, the clinician's competent evaluation and clinical expertise play a major role [38]. There is no universally accepted or completely accurate method of determining the VDO in edentulous patients. Clinical research is required to validate the CAPS system with various patient criteria.

As shown in Fig 6, no library files were provided for LPAs and OPAs. The LPAs were eliminated with the 'lasso tool' prior to the virtual tooth setup (Fig. 6 B, E). In an in vitro study of Wu et al. [39], a portion of the ISB scan area was hindered when scan body clasps were mounted to ISBs. Mizumoto et al. demonstrated that ISB hindrance might worsen the scan result [40]. In the present article, the screw retained attachment of LPAs minimizes this potential impact of ISB hindrance on the IOS scan result and the ISB library file alignment. Because static virtual occlusal records are related to fixed recognition landmarks in both arches, LPAs could serve as fixed recognition landmarks during the registration of the maxillomandibular relationship [41,42].

A trueness analysis was performed to assess the accuracy of the 3D-printed casts used to fabricate the definitive IFCDPs. For both patients, results were within the clinically acceptable range of errors (150 µm) [31]. It was never the authors' intention to conduct a clinical study of fit accuracy. The novel single-visit workflow for edentulous patients could meet clinical requirements of trueness and contribute to a full digital workflow in which the maxillomandibular relationship was included.

## 5. Conclusions

Within the limitations of this study, the following conclusions can be drawn:

- (1) A 3-unit toolset with ISBs, LPAs and OPAs allows to register the implant position and maxillomandibular relationship in one single visit.
- (2) The 2-stage clinical workflow with the CAPS system facilitates the IOS data acquisition for fabrication of an interim IFCDP at the same day.
- (3) A passive fit was demonstrated for the interim and the definitive IFCDPs.

## Clinical significance

The CAPS system can help clinicians to register the implant position and the maxillomandibular relationship in one single visit for the fabrication of an IFCDP.

## CRedit authorship contribution statement

**Philippe Nuytens:** Writing – review & editing, Writing – original draft, Visualization, Validation, Supervision, Software, Project administration, Methodology, Investigation, Formal analysis, Data curation, Conceptualization. **Francesco Grande:** Writing – review & editing, Software, Formal analysis, Data curation. **Rani D'haese:** Writing – review & editing, Formal analysis, Data curation. **Ziad Salameh:** Writing – review & editing, Visualization. **Luca Lepidi:** Writing – review & editing, Visualization, Validation.

## Declaration of competing interest

The authors declare that there are no conflicts of interest in this study.

## Acknowledgements

The authors wish to acknowledge Alessandro Mosca Balma, M.Sc.

BME Research Fellow at Bone and Dental Bioengineering Laboratory CIR Dental School Department of Surgical Sciences University of Turin, for his technical support and data analysis.

## Funding

This research did not receive any specific grant from funding agencies in the public, commercial, or not-for-profit sectors.

## Institutional Review Board Statement

This study was approved by the Ethical Committee of Ghent University Hospital, Belgium.

## References

- [1] M. Revilla-León, D.E. Kois, J.C. Kois, A guide for maximizing the accuracy of intraoral digital scans: part 2—patient factors, *J. Esthet. Restor. Dent.* 35 (2022) 241–249, <https://doi.org/10.1111/jerd.12993>.
- [2] P. Papaspyridakos, K. Vazouras, Y.W. Chen, E. Kotina, Z. Natto, K. Kang, K. Chochlidakis, Digital vs conventional implant impressions: a systematic review and meta-analysis, *J. Prosthodont.* 29 (2020) 660–678, <https://doi.org/10.1111/jopr.13211>.
- [3] A.L. Carneiro Pereira, M.R. Souza Curinga, H.V. Melo Segundo, A. da Fonte Porto Carreiro, Factors that influence the accuracy of intraoral scanning of total edentulous arches rehabilitated with multiple implants: a systematic review, *J. Prosth. Dent.* 129 (2023) 855–862, <https://doi.org/10.1016/j.prosdent.2021.09.001>.
- [4] C. Wulfman, A. Naveau, C. Rignon-Bret, Digital scanning for complete-arch implant-supported restorations: a systematic review, *J. Prosth. Dent.* 124 (2020) 161–167, <https://doi.org/10.1016/j.prosdent.2019.06.014>.
- [5] M. Revilla-León, A. Lanis, B. Yilmaz, J.C. Kois, G.O. Gallucci, Intraoral digital implant scans: parameters to improve accuracy, *J. Prosthodont.* 32 (2023) 150–164, <https://doi.org/10.1111/jopr.13749>.
- [6] Z. Li, R. Huang, X. Wu, Z. Chen, B. Huang, Z. Chen, Effect of scan pattern on the accuracy of complete-arch digital implant impressions with two intraoral scanners, *Int. J. Oral Maxillofac. Implants* 37 (2022) 731–739, <https://doi.org/10.11607/jomi.9248>.
- [7] J. Latham, M. Ludlow, A. Mennito, A. Kelly, Z. Evans, W. Renne, Effect of scan pattern on complete-arch scans with 4 digital scanners, *J. Prosth. Dent.* 123 (2020) 85–95, <https://doi.org/10.1016/j.prosdent.2019.02.008>.
- [8] M. Gómez-Polo, M.B. Donmez, G. Çakmak, B. Yilmaz, M. Revilla-León, Influence of implant scan body design (height, diameter, geometry, material, and retention system) on intraoral scanning accuracy: a systematic review, *J. Prosthodont.* 32 (2023) 165–180, <https://doi.org/10.1111/jopr.13774>, [10.1111/jopr.13774](https://doi.org/10.1111/jopr.13774).
- [9] T. Flügge, W.J. van der Meer, B.G. Gonzalez, K. Vach, D. Wismeijer, P. Wang, The accuracy of different dental impression techniques for implant-supported dental prostheses: a systematic review and meta-analysis, *Clin. Oral Implants Res.* 29 (2018) 374–392, <https://doi.org/10.1111/clr.13273>.
- [10] M. Revilla-León, S.G. Subramanian, M. Özcan, V.R. Krishnamurthy, Clinical study of the influence of ambient light scanning conditions on the accuracy (trueness and precision) of an intraoral scanner, *J. Prosthodont.* 29 (2020) 107–113, <https://doi.org/10.1111/jopr.13135>.
- [11] Y. Chen, Z. Zhai, H. Li, S. Yamada, T. Matsuoka, S. Ono, T. Nakano, Influence of liquid on the tooth surface on the accuracy of intraoral scanners: an in vitro study, *J. Prosthodont.* 31 (2022) 59–64, <https://doi.org/10.1111/jopr.13358>.
- [12] A. Paratelli, S. Vania, C. Gómez-Polo, R. Ortega, M. Revilla-León, M. Gómez-Polo, Techniques to improve the accuracy of complete-arch implant intraoral digital scans: a systematic review, *J. Prosth. Dent.* 129 (2023) 844–854, <https://doi.org/10.1016/j.prosdent.2021.08.018>.
- [13] S. Guirao, F. Llansana, H. Button, B. Yilmaz, J.C. Kois, M. Revilla-León, Additively manufactured devices with varying designs and sizes for acquiring initial intraoral implant scans, *J. Prosthodont.* 32 (2023) 181–185, <https://doi.org/10.1111/jopr.13750>.
- [14] R. Huang, Y. Liu, B. Huang, C. Zhang, Z. Chen, Z. Li, Improved scanning accuracy with newly designed scan bodies: an in vitro study comparing digital versus conventional impression techniques for complete-arch implant rehabilitation, *Clin. Oral Implants Res.* 31 (2020) 625–633, <https://doi.org/10.1111/clr.13598>.
- [15] M. Imburgia, J. Kois, E. Marino, H. Lerner, F.G. Mangano, Continuous Scan Strategy (CSS): a novel technique to improve the accuracy of intraoral digital impressions, *Eur. J. Prosthodont. Restor. Dent.* 28 (2020) 128–141, [https://doi.org/10.1922/EJPRD\\_2105Imburgia14](https://doi.org/10.1922/EJPRD_2105Imburgia14).
- [16] Y. Ashraf, A. Abo El Fadl, A. Hamdy, K. Ebeid, Effect of different intraoral scanners and scanbody splinting on accuracy of scanning implant-supported full arch fixed prosthesis, *J. Esthet. Restor. Dent.* 35 (2023) 1257–1263, <https://doi.org/10.1111/jerd.13070>.
- [17] L. Retana, A.H. Nejat, A. Pozzi, Effect of splinting scan bodies on trueness of complete-arch implant impression using different intraoral scanners: an in vitro study, *Int. J. Comput. Dent.* 26 (2023) 19–28, <https://doi.org/10.3290/j.jcd.b2599297>.

- [18] F. Llansana, S. Guirao, J.C. Kois, M. Revilla-León, Calibrated splinting framework for complete-arch intraoral implant digital scans manufactured by combining milled and additively manufacturing technologies: a dental technique, *J. Prosthet. Dent.* (2022), <https://doi.org/10.1016/j.prosdent.2022.08.031>.
- [19] X.J. Fu, M. Liu, B.L. Liu, M.S. Tonetti, J.Y. Shi, H.C. Lai, Accuracy of intraoral scan with prefabricated aids and stereophotogrammetry compared with open tray impressions for complete-arch implant-supported prosthesis: a clinical study, *Clin. Oral Implants Res.* (2023), <https://doi.org/10.1111/clr.14183>.
- [20] R.E. Ramadan, M.M. Bahgat, A.M. Abdelhamid, M.M. Khamis, Registration of maxillomandibular relationship through a fully digital workflow for complete-mouth rehabilitation with screw-retained fixed implant-supported prostheses: a clinical report, *J. Prosthet. Dent.* (2023), <https://doi.org/10.1016/j.prosdent.2022.11.027>.
- [21] F. Parnia, E. Moslehifard, N. Motayagheni, A.A. Pournasrollah, A time-saving method for transferring occlusal vertical dimension and centric relation of complete denture to a full-arch implant prosthesis, *J. Contemp. Dent. Pract.* 15 (2014) 672–675, <https://doi.org/10.5005/jp-journals-10024-1597>.
- [22] N.T. Griseto, G.O. Gallucci, Digital maxillomandibular relationship registration for an edentulous maxilla: a dental technique, *J. Prosthet. Dent.* 125 (2021) 858–861, <https://doi.org/10.1016/j.prosdent.2020.04.008>.
- [23] P. Nuytens, R. D'haese, S. Vandeweghe, Reliability and time efficiency of digital vs. analog bite registration technique for the manufacture of full-arch fixed implant prostheses, *J. Clin. Med.* 11 (2022) 2882, <https://doi.org/10.3390/jcm11102882>.
- [24] P. Nuytens, J. Li, L. Lepidi, Face oriented digital workflow for transferring intraoral and extraoral data of edentulous arch rehabilitated with multiple implants: a clinical technique, *J. Prosthet. Dent.* (2023), <https://doi.org/10.1016/j.prosdent.2023.02.023>.
- [25] M. Bissasu, Use of a patient's old complete denture to determine vertical dimension of occlusion, *J. Prosthet. Dent.* 85 (2001) 413–414, <https://doi.org/10.1067/mpr.2001.114279>.
- [26] F.Z. Jamjoom, A. Aldghim, O. Aldibasi, B. Yilmaz, Impact of intraoral scanner, scanning strategy, and scanned arch on the scan accuracy of edentulous arches: an in vitro study, *J. Prosthet. Dent.* (2023), <https://doi.org/10.1016/j.prosdent.2023.01.027>.
- [27] J.D. Orthlieb, G. Hernandez, L. Darmouni, J.P. Ré, A. Girardeau, G. Slavicek, Myostabilized centric relation, *J. Stomat. Occ. Med.* 4 (2011) 87–94, <https://doi.org/10.1007/s12548-011-0014-7>.
- [28] J.R. McKee, Comparing condylar positions achieved through bimanual manipulation to condylar positions achieved through masticatory muscle contraction against an anterior deprogrammer: a pilot study, *J. Prosthet. Dent.* 94 (2005) 389–393, <https://doi.org/10.1016/j.prosdent.2005.06.012>.
- [29] V. Rutkunas, J. Dirse, D. Kules, I. Mischitz, C. Larsson, M. Janda, Misfit simulation on implant prostheses with different combinations of engaging and nonengaging titanium bases. Part 2: Screw resistance test, *J. Prosthet. Dent.* (2022), <https://doi.org/10.1016/j.prosdent.2022.04.027>.
- [30] J.Y. Kan, K. Rungcharassaeng, K. Bohsali, C.J. Goodacre, B.R. Lang, Clinical methods for evaluating implant framework fit, *J. Prosthet. Dent.* 81 (1999) 7–13, [https://doi.org/10.1016/s0022-3913\(99\)70229-5](https://doi.org/10.1016/s0022-3913(99)70229-5).
- [31] T. Jemt, A. Lie, Accuracy of implant-supported prostheses in the edentulous jaw: analysis of precision of fit between cast gold-alloy frameworks and master casts by means of a three-dimensional photogrammetric technique, *Clin. Oral Implants Res.* 6 (1995) 172–180, <https://doi.org/10.1034/j.1600-0501.1995.060306.x>.
- [32] D. Yoon, D. Pannu, M. Hunt, J. Londono, Occlusal considerations for full-arch implant-supported prostheses: a guideline, *Dent. Rev.* 2 (2022) 100042, <https://doi.org/10.11607/j.dentre.2022.100042>.
- [33] G. Fabbri, R. Sorrentino, G. Cannistraro, F. Mintrone, L. Bacherini, R. Turrini, T. Bombardelli, M. Nieri, M. Fradeani, Increasing the vertical dimension of occlusion: A multicenter retrospective clinical comparative study on 100 patients with fixed tooth-supported, mixed, and implant-supported full-arch rehabilitations, *Int. J. Periodontics Restorative Dent.* 38 (2018) 323–335, <https://doi.org/10.11607/prd.3295>.
- [34] Z. Ormianer, A. Palty, Altered vertical dimension of occlusion: a comparative retrospective pilot study of tooth- and implant-supported restorations, *Int. J. Oral Maxillofac. Implants* 24 (2009) 497–501.
- [35] Y.H. Ismail, W.A. George, The consistency of the swallowing technique in determining occlusal vertical relation in edentulous patients, *J. Prosthet. Dent.* 19 (1968) 230–236, [https://doi.org/10.1016/0022-3913\(68\)90083-8](https://doi.org/10.1016/0022-3913(68)90083-8).
- [36] I. Marko, K. Nebojsa, A. Ljiljana, M. Kostic, A. Igić, M.B. Petrovic, S. Dacić, S. Igić, A. Igić, Determination of vertical dimension of occlusion by using the phonetic vowel “O” and “E”, *Vojnosanit Pregl* 72 (2015) 123–131, <https://doi.org/10.2298/vsp1502123i>.
- [37] G.A. Zarb, G.E. Carlsson, C.L. Bolender, Boucher's prosthodontic treatment for edentulous patients, eleventh ed., Mosby, St. Louis, 1997.
- [38] F. Fayz, A. Eslami, Determination of occlusal vertical dimension: a literature review, *J. Prosthet. Dent.* 59 (1988) 321–323, [https://doi.org/10.1016/0022-3913\(88\)90182-5](https://doi.org/10.1016/0022-3913(88)90182-5).
- [39] H.K. Wu, J. Wang, G. Chen, X. Huang, F. Deng, Y. Li, Effect of novel prefabricated auxiliary devices attaching to scan bodies on the accuracy of intraoral scanning of complete-arch with multiple implants: an in-vitro study, *J. Dent.* 138 (2023) 104702, <https://doi.org/10.1016/j.jdent.2023.104702>.
- [40] R.M. Mizumoto, B. Yilmaz, E.A. McGlumphy Jr., J. Seidt, W.M. Johnston, Accuracy of different digital scanning techniques and scan bodies for complete-arch implant-supported prostheses, *J. Prosthet. Dent.* 123 (2020) 96–104, <https://doi.org/10.1016/j.prosdent.2019.01.003>.
- [41] J. Mei, L. Ma, J. Chao, F. Liu, J. Shen, Three-dimensional analysis of the outcome of different scanning strategies in virtual interocclusal registration, *J. Adv. Prosthodont.* 14 (2022) 369–378, <https://doi.org/10.4047/jap.2022.14.6.369>.
- [42] X. Garikano, X. Amezua, M. Iturrate, E. Solaberrieta, E. Evaluation of repeatability of different alignment methods to obtain digital interocclusal records: an in vitro study, *J. Prosthet. Dent.* (2022), <https://doi.org/10.1016/j.prosdent.2022.07.014>.