POLITECNICO DI TORINO
Repository ISTITUZIONALE

Evaluation of the root canal tridimensional filling with warm vertical condensation, carrier-based technique and single cone with bioceramic sealer: A micro-CT study

Original
Evaluation of the root canal tridimensional filling with warm vertical condensation, carrier-based technique and single cone with bioceramic sealer: A micro-CT study / Moccia, E., Carpegna, G., Dell'Acqua, A., Alovisi, M., Comba, A., Pasqualini, D., Berutti, E.. - In: GIORNALE ITALIANO DI ENDODONZIA. - ISSN 1121-4171. - 34:1(2020), pp. 55-62. [10.32067/GIE.2020.34.01.07]

Availability:
This version is available at: 11583/2983429 since: 2023-10-29T13:39:58Z

Publisher:
Ariesdue Srl

Published
DOI:10.32067/GIE.2020.34.01.07

Terms of use:

This article is made available under terms and conditions as specified in the corresponding bibliographic description in the repository

Publisher copyright

(Article begins on next page)

29 November 2026

Available online at www.giornaleitalianoendodonzia.it

Winner of Francesco Riitano Award 36th SIE National Congress 2019

ORIGINAL ARTICLE/**ARTICOLO ORIGINALE**

Evaluation of the root canal tridimensional filling with warm vertical condensation, carrier-based technique and single cone with bioceramic sealer: a micro-CT study

Valutazione della qualità del sigillo canalare mediante micro-CT: cono singolo con bioceramiche VS onda continua di condensazione VS guttaperca calda veicolata da carrier

KEYWORDS
Bioceramic Sealer, Micro-CT, Root Canal Obturation, Root Canal Sealers, Volumetric Distortion

PAROLE CHIAVE
Cemento bioceramico, Micro-CT, Otturazione canalare, Cementi canalari, Alterazione volumetrica

Edoardo Moccia[1*]
Giorgia Carpegna[1]
Alessandro Dell'Acqua[1]
Mario Alovisi[1]
Allegra Comba[1]
Damiano Pasqualini[1]
Elio Berutti[1]

[1]Università degli Studi di Torino, Italy

Received 2020, February 20

Accepted 2020, March 17

Abstract

Aim: *To compare the quality of the tridimensional (3D) filling and the presence of radiographic translucencies after root canal obturation with three different techniques: warm vertical condensation, carrier-based and single cone with bioceramic sealer.*
Methodology: *Thirty single-rooted human teeth extracted for periodontal reasons were selected. Glide path was performed with ProGlider and shaping with ProTaper Next (PTN) X1, X2 and X3 up to working length (WL). The specimens were randomly divided into three groups (N=10) for the final 3D filling step: Buchanan's continuous wave of condensation (Group 1, G1), Thermafil® (Group 2, G2) or TotalFill® BC Points™ combined with TotalFill® BC Sealer (Group 3, G3).*
Micro-CT scans were performed after the obturation step and the slices were 3D reconstructed with standardized parameters. Afterwards, the filled area and the associated radiographic translucencies were computer-isolated, and their volumes were calculated.
The statistical analysis was performed using one-way ANOVA and the post-hoc Student-Newmann-Keuls (P<0,05).

Scopo: *questo studio si pone come obiettivo la valutazione della qualità del sigillo, mediante analisi micro-tomografica computerizzata, in termini di presenza di difetti di riempimento del sistema canalare, dell'otturazione ottenuta con tre diverse metodiche: la tecnica dell'onda continua di condensazione, della guttaperca plasticizzata veicolata da carrier e la tecnica di otturazione con cono singolo di guttaperca abbinato al sealer bioceramico.*
Materiali e metodi: *sono stati selezionati trenta elementi dentari monoradicolati, estratti per motivi parodontali. Dopo aver eseguito l'accesso endodontico, la sagomatura è stata effettuata con sistema Protaper Next™, fino a X3, a lunghezza di lavoro (WL), irrigando con NaOCl 5% ed EDTA 10%.*
I campioni sono stati casualmente suddivisi in tre gruppi (N=10).
Il primo gruppo (G1) è stato otturato con la tecnica dell'onda continua di condensazione di Buchanan. Il secondo gruppo (G2) con guttaperca riscaldata veicolata da carrier (Thermafil®). Il terzo gruppo (G3) è stato infine otturato con cono singolo di guttaperca TotalFill® BC Points™ abbinato a sealer bioceramico TotalFill® BC Sealer™, secondo le specifiche della casa produttrice. Tutti i campioni sono stati analizzati tramite scansioni micro-tomografiche computerizzate (micro-CT), utilizzando parametri standardizzati. Dalle immagini ottenute sono stati calcolati tridimensionalmente i volumi dell'otturazione e delle aree di radiotrasparenza associate, tramite Materialise Mimics Medical™ e Geomagic Qualify®.

Corresponding author
Edoardo Moccia | Università degli Studi di Torino, Dental School, Via Nizza 230, 10126 Torino | Italy
Tel. +39 011 6331513 | edomcc@gmail.com

Peer review under responsibility of Società Italiana di Endodonzia
10.32067/GIE.2020.34.01.07
Società Italiana di Endodonzia. Production and hosting by Ariesdue. This is an open access article under the CC BY-NC-ND license (http://creativecommons.org/licenses/by-nc-nd/4.0/).

Abstract

Results: *The mean percentage of translucency areas in the warm vertical condensation group was 1,23%, whereas in the carrier-based group was 4,22% and in the single cone with bioceramic sealer group was 10,44%. The differences between the groups were statistically significant (P=0,029).*

Conclusions: *All the obturation techniques provided an adequate 3D root canal filling. However, the null hypothesis of a superimposable 3D filling quality between groups was refused. The single cone technique with bioceramic sealer represented a viable clinical alternative, although it seemed more operator-dependent than the others.*

Le analisi statistiche sono state effettuate utilizzando l'analisi one-way ANOVA ed il test post-hoc Student-Newmann-Keuls ad un livello di significatività di P<0,05.

Risultati: *la media della percentuale delle aree di minor radiodensità nel gruppo G1 è stata 1.23%, nel gruppo G2 4.22%, nel gruppo G3 10.44%. Le differenze tra i tre gruppi si sono dimostrate statisticamente significative (P=0,029).*

Conclusioni: *con le limitazioni di questo studio, possiamo affermare che in tutti i gruppi sia stata ottenuta un'otturazione tridimensionale soddisfacente, in linea con i dati dalla letteratura scientifica. Le tecniche dell'onda continua di condensazione e della guttaperca veicolata da carrier si sono dimostrate di maggiore predicibilità rispetto all'otturazione con sealer bioceramico. Tuttavia, quest'ultima rimane una valida alternativa in campo clinico, anche se è risultata essere ancora maggiormente operatore-dipendente.*

Introduction

During endodontic treatment, the obturation's quality is considered a main feature for a good prognosis: it aims to fill the entire root canal system and to seal it from any bacterial contamination (1). Anatomical variations such as isthmuses or bifurcations may be considered a challenge for the operator during this critical phase.

The perfect sealer and filling material have yet to be found. Its ideal characteristics have been described by Grossman in 1988 (2) and revised by Kaur in 2015 (3).

In modern endodontics, warm vertical condensation and thermo-plasticized carrier-based techniques are commonly used. Warm vertical condensation was described by Schilder in 1967 (4). In 1998, Buchanan proposed the continuous wave of condensation: it takes all the advantages of the Schilder's techniques achieving a 3D filling of the endodontic system and requiring a single heat compaction of 15 seconds (5, 6). Nowadays, thermo-plasticized carrier-based gutta-percha is taking hold solidly for its simplicity combined with high-performance (7).

Both of these techniques share the use of zinc oxide eugenol (ZOE) sealer, which is indicated as the obturation's weak link, so its volume percentage should be lower than the filling material (4, 8).

Bioceramics are a large family of root repairing cements and root canal sealers. Thanks to their high pH and ability to produce hydrated calcium silicate gel and calcium hydroxide, they have been proven highly biocompatible and nontoxic: these properties make them particularly suitable in dentistry (9, 10). One of the most well-known bioceramic-based material is mineral trioxide aggregate (MTA), a mixture of Portland cement and bismuth oxide (11). Through the years, bioceramic-based materials have been used mainly as retrograde filling materials, root repair cements or root canal sealers (12, 13, 14). Due to their capability to produce mineral tags, bioceramic sealers are supposed to bond chemically and mechanically dentinal tubules (15, 16). Nowadays, the clinical use of bioceramic-based materials endodontic sealer is widely documented (9, 17, 18). Radiopacity is an important characteristic for any filling material in order to assess the treatment's quality. Micro-computed tomography (micro-CT) is a modern highly accurate method proposed to assess the obturation quality through the three-dimensional analysis of the root canal volumes: it is widely documented as non-destructive, non-invasive, (19) repeatable and reliable, (20, 21) representing nowadays one of the best in vitro methods in the endodontics research field (22-25).

The aim of this micro-CT study is to evaluate the quality of the tridimensional fill-

ing and the presence of radiographic translucencies after the root canal obturation with three different techniques: warm vertical condensation, carrier-based technique and single cone with bioceramic sealer.

Materials and Methods

Specimen selection
For this study, intact single-rooted human teeth with closed apex, freshly extracted due to periodontal disease, were recruited and immediately stored in a NaCl 0.9% W/V solution after the extraction. Once the debridement of root's surface with a Gracey's curette was done, each tooth was restored in NaCl 0.9% W/V solution. The test tube was fixed on a customized support for low resolution scout scans (SS) (SkyScan 1172®: ©Bruker microCT, Kontich, Belgium) to obtain a general vision of the root canal system. Starting from the SS, thirty teeth with single roundish canal were selected.

Endodontic treatment
After performing a minimally invasive endodontic access, the canal was scouted with a #10 k-file (Dentsply Maillefer, Ballaigues, Switzerland). Working length (WL) was assessed with a microscope (OPMI Pro Ergo®, Carl Zeiss, Oberkochen, Germany) when the instrument's tip became just visible at the apex. The glide path and the shaping were achieved respectively with ProGlider (PG) (Dentsply Maillefer, Ballaigues, Switzerland) and with ProTaper Next (PTN) (Dentsply Maillefer) X1, X2 and X3 using the X-Smart plusTM motor according the manufacturer's instruction (300 rpm, 4 Ncm), always up to WL. Each instrument was used for a maximum of 3 cycles and then discarded. The irrigation between every instrument was performed with 5% NaOCl (Niclor 5; Ogna, Muggiò, Italy) alternated with 10% EDTA (Tubuliclean; Ogna) by using a 5 mL syringe and 30-gauge side-vented needle.
All specimens were randomly divided into three groups (N=10) for the final 3D filling step: continuous wave condensation (Group 1), carried-based obturation (Group 2) or bioceramic sealer (Group 3).

Continuous wave of condensation group (G1)
In Group 1 (G1) a dedicated gutta-percha X3 cone (Dentsply Maillefer) was selected and covered with a light coat of ZOE endodontic sealer, mixed according to manufacturer's instructions (Pulp Canal Sealer EWT; Kerr, Orange, CA). The cone was inserted up to 0.5 mm from the working length of each sample, checking the correct tug-back. An M plugger (EIE/Analytic, Redmond, WA) which penetrated within 5 mm from the working length was selected. A DownPak heat source (Hu-Friedy, Chicago, IL) heated the cone till 5 mm from working length and the plasticized gutta-percha was gently compacted with the plugger. Afterwards, backfilling step was performed with Obtura III (Analytic Technologies, Redmond, WA).

Carrier-based group (G2)
For the 3D filling step in Group 2 (G2), a small amount of ZOE endodontic sealer (Pulp Canal Sealer EWT; Kerr, Orange, CA), mixed according to manufacturer's instructions, was placed over the canal access, then a size .35 Thermafil plastic obturator (Dentsply, Tulsa Dental Products, Tulsa, OK) was heated in a Thermaprep oven (Dentsply Tulsa) for 30 seconds and inserted with firm apical pressure up to working length in the canal. The carrier was cut at the canal orefice.

Bioceramics group (G3)
In Group 3 (G3) a size .30 gutta-percha cone TotalFill® BC PointsTM (Brasseler U.S.A. Dental, LLC One Brasseler Boulevard Savannah, Georgia 31419, USA) was selected, in order to check its correct tug-back up to working length. A small amount of premixed TotalFill® BC SealerTM (Brasseler U.S.A. Dental, LLC One Brasseler Boulevard Savannah, Georgia 31419, USA) was placed in the canal through the intracanal tip of the pre-loaded syringe, and gently spreaded over the canal walls. The gutta-percha cone as well was covered with a light coat of sealer and finally placed in the canal up to working length. To guarantee better filling proprieties, the cone was clock-wise rotated in the final 3 mm of its insertion.

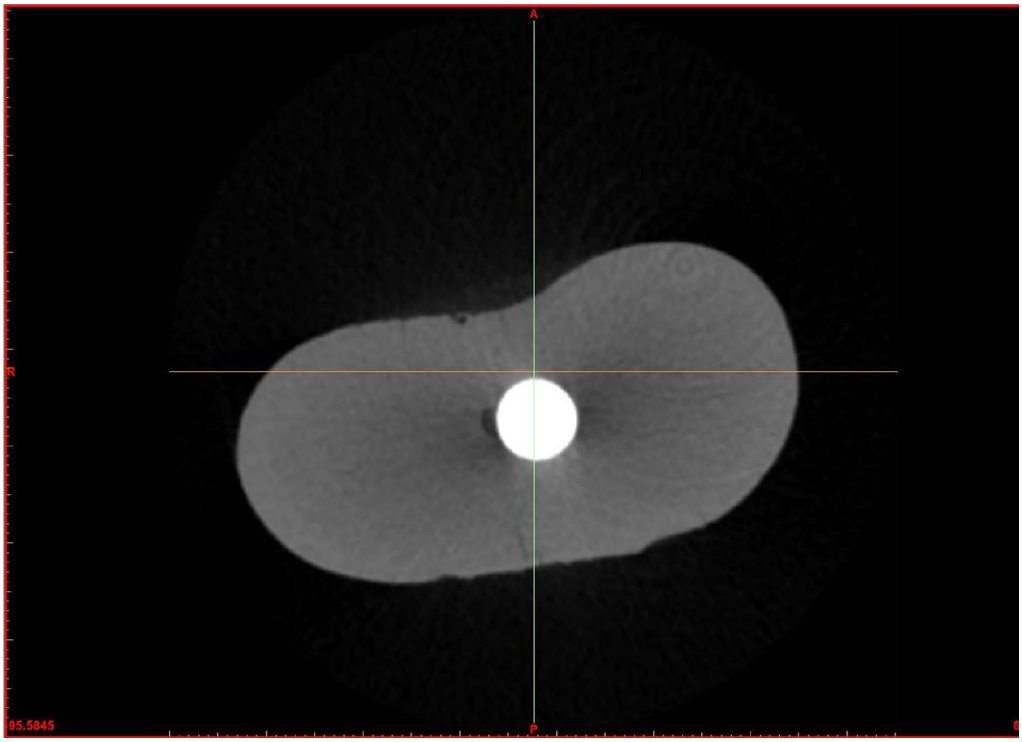

Figure 1
Example of a micro-CT G2 specimen slice.

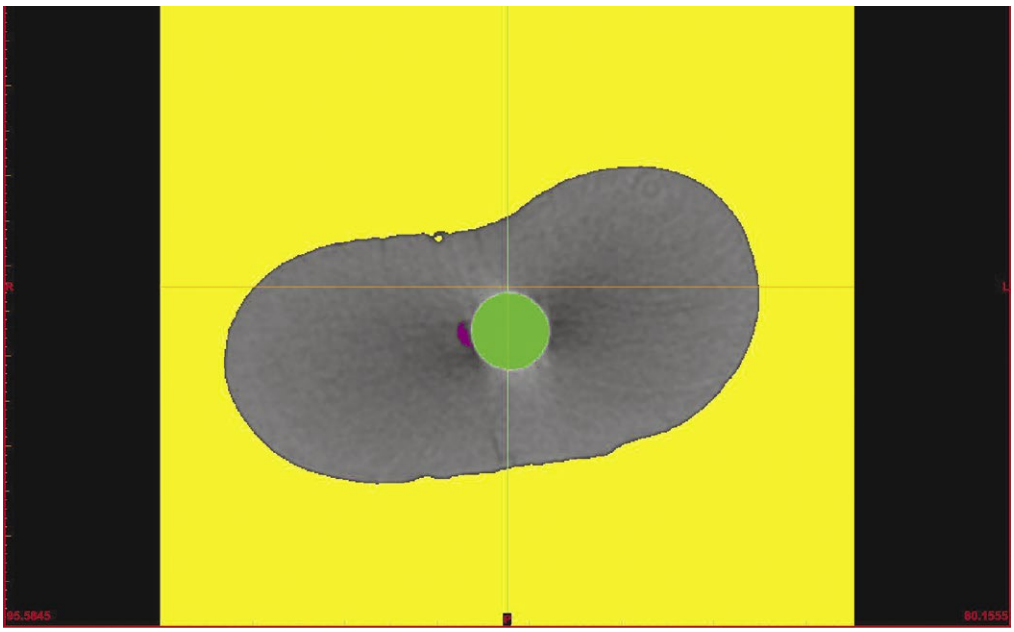

Figure 2
Masks selection: green for carrier-based gutta-percha obturation and ZOE sealer; yellow for space outside the specimen; purple for intra-canalar voids.

Endodontic access in all the specimens was sealed with a provisional sealer and then the teeth were stored again in a NaCl 0.9% W/V solution.

Micro-CT scans
Test tubes were fixed on the customized support for high resolution scans (100 kV, 100 µA) (SkyScan 1172®: ©Bruker microCT, Kontich, Belgium), with an isotropic resolution of 12.53 µm/pixel, in a 3 hours timeframe approximately for each specimen. Rotation step of the specimens was set at 0.4 degrees and averaging of 4 frames, through a physical 2 mm Copper and Aluminum filter. Once the scans were

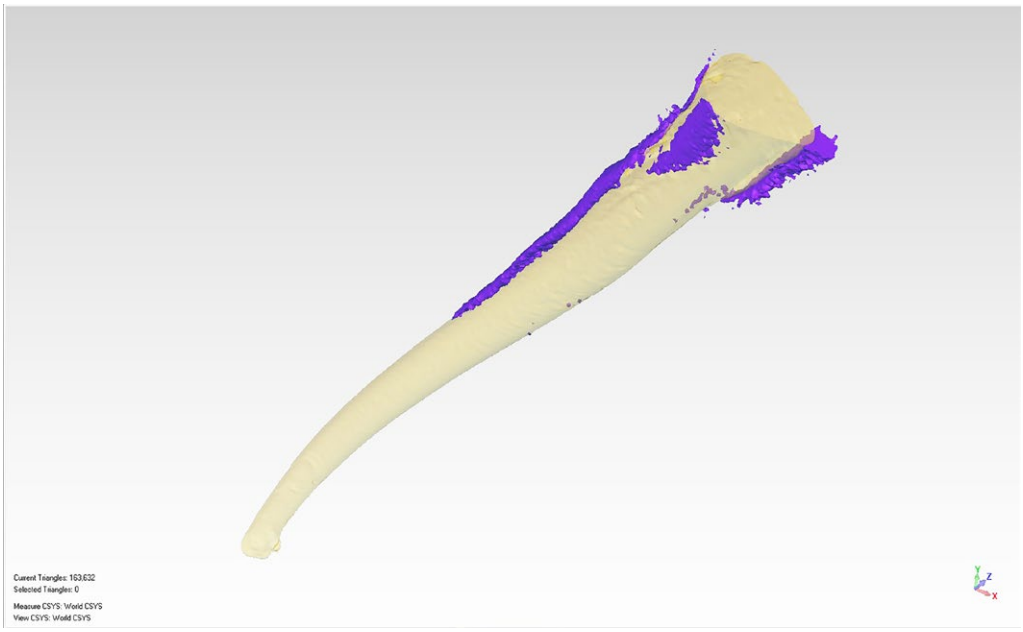

Figure 3
The 3D rendering of the previous G2 specimen with its obturation voids: ochre for carrier-based gutta-percha and ZOE sealer; purple for intra-canalar voids.

done, each acquisition was reconstructed with the software NRecon (©2012 Bruker) using standardized parameters for the whole study: 15% beam hardening; artifact correction between 4 and 8, depending on the specimen's artifact; smoothing between 3 and 5, depending on the specimen's radiodensity: Output histogram as well was standardized on the HU scale (min: 0; max: 0.064) (figure 1).

Digital analysis
Afterwards the software Materialise Mimics MedicalTM (Materialise NV) was used for processing the reconstructed files: region of interest (ROI) was selected starting from the cement-enamel junction (CEJ) up to the root apex.
Two different masks were selected over the ROI: obturation mask (Mobt) (lower threshold=1,624; higher threshold=3,194 on the HU scale) including areas with similar radiodensity to the gutta-percha and bioceramic sealer; voids mask (Mvds) (lower threshold= 1,024; higher threshold=-300 in the HU scale) including areas with similar radiodensity to the space outside the tooth. After this selection, Mobt was dilated of 30 pixels, assuming that eventual obturation voids extend no more for 375,9 µm from the radicular walls.
With an intersection between dilated Mobt and Mvds we obtained a pores mask (Mpor), as result of regions around for 0.3 mm and inside the obturation that have same radiodensity of the specimen's outside space (figure 2).
Mobt, Mvds and Mpor were exported in .stl files and renderized with the software Geomagic Qualify 12.0 (©2010 Geomagic), which also helped in the calculation (in µm3) of the obturation volume (Vobt) and pores volume (Vpor) (figure 3).

Results

To calculate the rate of the pores in the selected areas (Rpor) the following proportion was used:

(Vobt + Vpor) : 100 = Vpor : Rpor

Table 1 shows obturation volume, pores volume and pores rate for each sample and all the three groups mean values.
The statistical analysis was performed with one-way ANOVA test and the post-hoc Student-Newmann-Keuls test (P<0,05). The mean percentage of translucency areas in G1 was 1,23%, whereas in G2 was 4,22% and in G3 was 10,44%. The differences between the three groups were statistically significant (P=0,029). The null hypothesis of a superimposable 3D filling quality between the three groups was refused.

Table 1

Shows obturation volume, pores volume and pores rate for each sample and groups mean values

Group	Specimen	Obturation volume (μm³)	Pores volume (μm³)	Pores rate (%)
G1 (Continuous wave of condensation group)	WAV_01	13079.354794	67.012520	0.5
	WAV_02	8158.053783	19.798954	0.2
	WAV_03	6047.494961	4.322310	0.1
	WAV_04	18622.551407	107.023199	0.6
	WAV_05	9154.671449	326.944672	3.4
	WAV_06	10406.475035	44.739567	0.4
	WAV_07	7475.083765	20.232366	0.3
	WAV_08	12030.724405	691.364789	5.4
	WAV_09	6671.881436	5.616137	0.1
	WAV_10	14336.876706	195.714099	1.3
G1 MEAN VALUES		**10598.3**	**148.3**	**1.23**
G2 (Carrier-based gutta-percha group)	CAR_01	10944.11089	117.166773	1.1
	CAR_02	19517.0993	109.192633	0.5
	CAR_03	10329.0327	139.868864	1.3
	CAR_04	12477.193891	2651.3298	17.5
	CAR_05	10388.39338	414.6046	3.8
	CAR_06	9497.214289	8.524728	0.08
	CAR_07	9672.531468	475.833332	4.6
	CAR_08	9790.794203	143.298172	1.4
	CAR_09	9280.845704	1096.38577	10.5
	CAR_10	10944.11089	110.191466	1.0
G2 MEAN VALUES		**11284.1**	**526.6**	**4.22**
G3 (Single cone with bioceramic sealer group)	BIO_01	15161.606403	910.076029	5.7
	BIO_02	15883.825857	705.336862	4.3
	BIO_03	11490.327005	994.420567	8.0
	BIO_04	5075.217904	173.934894	3.3
	BIO_05	7810.608117	2869.873788	26.9
	BIO_06	20555.635418	2138.462997	9.4
	BIO_07	10045.453751	2149.309631	17.6
	BIO_08	15779.903813	715.423583	4.3
	BIO_09	15401.496286	2850.362639	15.6
	BIO_10	13228.770685	1363.863580	9.3
G3 MEAN VALUES		**13043.3**	**1487.1**	**10.44**

Discussion

In the present study micro-CT scans were used to compare the quality of the 3D filling and the presence of radiographic translucencies of three different root canal obturation techniques: warm vertical condensation, carrier-based technique and single cone with bioceramic sealer. The same parameters among the different group were analyzed: obturation volume, pores volume and pores rate. No obturation technique showed a completely filled canal system.

The obturation techniques used during this study presented similar characteristics: they are biocompatible, radiopaque and inert, (26) offering a stable apical and intra-canalar seal. The results of this study are comparable with previously published scientific data about the continuous wave of condensation and the carrier-based techniques and a good 3D filling of the root canal system was achieved (6, 27).

Both continuous wave and carried based techniques are based on minimum sealer interface concept, while the bioceramic sealer single cone technique starts from Grossman's concept of maximum sealer interface with the gutta-percha cone intended as a carrier. This difference probably makes this obturation technique more operator-dependent compared with the other two.

Eltair et al. reported that the use of different types of gutta-percha cones compositions doesn't affects significantly the quality of the endodontic seal (28).

Micro-CT have been validated as a viable method to tridimensionally evaluate the endodontic anatomy, that instrument shaping outcomes and the obturation quality (29). Moreover, it is accurate, reproducible, repeatable and non-destructive against the specimens (30, 31). In the present study, the areas of major radiolucency isolable in our scans (Mpo) represented a lack of filling of the tested obturation material.

These areas were frequently associated with a higher physical density of the bioceramic sealer which resulted in the formation of internal voids or in lacks of filling at the interface against the root canal walls. In conclusion, the standardization of the 3D root canal filling quality may be more operator dependent using the single cone bioceramic technique.

Conclusions

Within the limitations of this study, all the obturation techniques provided an adequate 3D root canal filling. The single cone technique with bioceramic sealer represented a viable clinical alternative, although it seemed more operator-dependent than the continuous wave of condensation and carrier-based gutta-percha techniques.

Clinical Relevance

3D filling is a key element for a successful endodontic treatment: continuous wave of condensation and carrier-based gutta-percha proved to be two more predictable techniques. The single cone with bioceramics, thanks to their biocompatibility proprieties, is a viable clinical alternative, although more operator-dependent.

Conflict of Interest

We affirm that we have no financial affiliation (e.g. employment, direct payment, stock holdings, retainers, consultantships, patent licensing arrangements or honoraria) or involvement with any commercial organization with direct financial interest in the subject or materials discussed in this manuscript, nor have any such arrangements existed in the past three years. The Authors declare no competing conflict of interests with the materials discussed in this manuscript.

Acknowledgements

Micro-CT scans were performed at C.I.R. Dental School (Via Nizza 230, 10100 Turin, Italy).

References

1. Sjögren U, Figdor D, Persson S, Sundqvist G. Influence of infection at the time of root filling on the outcome of endodontic treatment of teeth with apical periodontitis. Int Endod J 1997; 30:297.
2. Grossman, L. Endodontic practice 1988; ed 11, p 242, Philadelphia, Lea & Febiger.
3. Kaur A, Shah N, Logani A, Mishra N. Biotoxicity of commonly used root canal sealers: A meta-analysis. J Conserv Dent. 2015; 18: 83-88.
4. Schilder H. Filling root canals in three dimensions. Dental Clinics of North America, 1967; 11: 723-44.
5. Buchanan LS. Continuous wave of condensation technique. Endodontic Practice 1998; 1:7-10, 13-6, 18 passim.
6. Buchanan LS. Endodontic Obturation Techniques. The State of the Art in 2015. Dent Today, 2015; 34:90, 92, 94-5.
7. Greco K., Carmignani E., Cantatore G.: The Thermafill root canal obturation system. Giornale Italiano di Endodonzia 2011; 25: 97-109.
8. Malagnino VA, De Luca M, Altieri P, Goracci G. L'uso del cemento nella condensazione laterale della guttaperca. R.I.S. 1990; 59:5.
9. Wang Z. Bioceramic materials in endodontics. Endodontic Topics 2015; 32: 3-30.
10. Zhang H, Shen Y, Ruse ND, Haapasalo M. Antibacterial Activity of Endodontic Sealers by Modified Direct Contact Test Against Enterococcus faecalis. JOE 2009; 35:1051-5.
11. Witte. The filling of a root canal with Portland cement. German Quarterly for Dentistry. J Cent Assoc German Dent 1878; 18:153-4.
12. Torabinejad M, Watson TF, Pitt Ford TR. Sealing ability of a mineral trioxide aggregate when used as a root end filling material. J Endod 1993; 19: 591-5.
13. Atmeh AR, Chong EZ, Richard G et al. Dentin-cement interfacial interaction: calcium silicates and polyalkenoates. J Dent Res 2012; 91: 454-9.
14. Koch KA, Brave DG. Bioceramics, part I: the clinician's viewpoint. Dent Today 2012; 31:130–5.
15. Atmeh AR, Chong EZ, Richard G et al. Dentin-cement interfacial interaction: calcium silicates and polyalkenoates. J Dent Res. 2012; 9:454-9.
16. Han L, Okiji T. Uptake of calcium and silicon released from calcium silicate–based endodontic materials into root canal dentine. Int Endod J. 2011; 44:1081-7.
17. Haapasalo M, Parhar M, Huang X et al. Clinical use of bioceramic materials. Endodontic Topics 2015; 32: 97-117.
18. Trope M, Bunes A, Debellian G. Root filling materials and techniques: bioceramics a new hope? Endodontic Topics 2015; 32, 86-9.
19. Rengo C, Goracci C, Ametrano G et al. Marginal Leakage of Class V Composite Restorations Assessed Using Microcomputed Tomography and Scanning Electron Microscope. Oper Dent. 2015 40:440-8.
20. Spagnuolo G, Ametrano G, D'Antò V et al. Microcomputed Tomography Analysis of Mesiobuccal Orifices and Major Apical Foramen in First Maxillary Molars. Open Dent J. 2012; 6, 118-25.
21. Alovisi M, Cemenasco A, Mancini L et al. Micro-CT evaluation of several glide path techniques and ProTaper Next shaping outcomes in maxillary first molar curved canals. Int Endod J. 2017; 50:387-97.
22. Rengo C, Spagnuolo G, Ametrano G et al. Micro-computerized tomographic analysis of premolars restored with oval and circular posts. Clin Oral Investig. 2014; 18:571-8
23. Pasqualini D, Alovisi M, Cemenasco A et al. Micro-Computed Tomography Evaluation of ProTaper Next and BioRace Shaping Outcomes in Maxillary First Molar Curved Canals. J Endod. 2015; 41:1706-10.
24. Alovisi M, Pasqualini D, Musso E. Influence of Contracted Endodontic Access on Root Canal Geometry: An In Vitro Study. J Endod. 2018; 44:614-620.
25. Zogheib C, Hanna M, Pasqualini D. Quantitative volumetric analysis of cross-linked gutta-percha obturators. Ann Stomatol (Roma) 2017; 7:46-51
26. Candeiro GTDM, Correia FC, Duarte MAH et al. Evaluation of radiopacity, pH, release of calcium ions, and flow of a bioceramic root canal sealer. J Endod 2012; 38:842-5.
27. Torabinejad M, Skobe Z, Trombly PL et al. Scanning electron microscopic study of root canal obturation using thermoplasticized gutta-percha. JOE 1978; 4:245-250.
28. Eltair M, Pitchika V, Hickel R et al. Evaluation of the interface between gutta-percha and two types of sealers using scanning electron microscopy (SEM). Clin Oral Invest 2018; 22:1631-9.
29. Hammad M, Qualtrough A, Silikas N. Evaluation of root canal obturation: a three-dimensional in vitro study. J Endod 2009; 35:541-4.
30. Metzger Z, Zary R, Cohen R et al. The quality of root canal preparation and root canal obturation in canals treated with rotary versus self-adjusting files: a threedimensional micro-computed tomographic study. J Endod 2010; 36:1569-73.
31. Endal U, Shen Y, Knut Å, et al. A high-resolution computed tomographic study of changes in root canal isthmus area by instrumentation and root filling. J Endod 2011; 37:223-7.