

Mechanics of facial growth in young patients

*Original*

Mechanics of facial growth in young patients / Defabianis, P; Carli, E; Cogo, C; Ninivaggi, R. - In: EUROPEAN JOURNAL OF PAEDIATRIC DENTISTRY. - ISSN 1591-996X. - ELETTRONICO. - 23:4(2022), pp. 288-290. [10.23804/ejpd.2022.23.04.06]

*Availability:*

This version is available at: 11583/2982881 since: 2023-10-10T12:41:20Z

*Publisher:*

ARIESDUE SRL

*Published*

DOI:10.23804/ejpd.2022.23.04.06

*Terms of use:*

This article is made available under terms and conditions as specified in the corresponding bibliographic description in the repository

*Publisher copyright*

(Article begins on next page)

# Mechanics of facial growth in young patients



P. Defabianis, E. Carli\*, C. Cogo, R. Ninivaggi

Department of Surgical Sciences, C.I.R. Dental School –  
Section of Paediatric Dentistry, University of Turin, Turin, Italy  
\*Department of Surgical, Medical and Molecular Pathology  
and Critical Care Medicine, University of Pisa, Pisa Ital

e-mail: rossella.ninivaggi@unito.it

DOI 10.23804/ejpd.2022.23.04.06

## Abstract

**Aim** The aim of this work is to focus on the impact of occlusion on facial development.

**Methods** Literature was searched using Medline, Embase and Cochrane Library. The key words and mesh used were bone remodelling, facial growth, masticatory muscles, children. Only articles written in English were included in the study.

**Results** Mechanical forces shape biological tissues. They are the effectors of the developmental programmes that orchestrate morphogenesis. Much effort has been devoted to understanding morphogenetic processes in mechanical terms and in literature there is ample evidence of that. Normal development of the mandible as well as some portions of the upper jaw and face are related to good function of the masticatory apparatus. When the neuromuscular system is in harmony, the mandibular muscles collectively exert their effect on both position and movement of the jaw and the loading of forces on the TM joints is optimal and balanced; when the integrity and interaction of bony and soft-tissue structures is disturbed (i.e. by trauma or TMJ disorders or dysfunction) this may result in facial and occlusal disharmonies.

**Conclusion** Disturbances in the harmonious interplay of the masticatory muscles may result in facial alteration and asymmetries. If not treated, the dysplastic pattern of growth continues and worsens with time.

**KEYWORDS** Biomechanics, Bone remodelling, Facial growth, Masticatory muscles, Children.

## Introduction

The dynamics of the growth of bones is complicated: normal development of the mandible as well as of some portions of the upper jaw and face is related to good function of the masticatory apparatus. Maxilla, mandible and dental occlusion are considered parts of the postural alignment of the skeletal system. A change in any of them must be proportionately matched by appropriate growth changes and adjustment to sustain and progressively achieve functional and structural balance of the whole [Ghiabi and White, 1998]. Posture and movements of the mandible involve very complex regulation of all the masticatory muscles. From the earliest periods of embryonic growth, an intimate, functional relationship exists between muscles and the bones they are attached to. Obviously, as the bones grow, the muscles must change their size as adjustment between muscle and bone are to be

considered normal part of growth and development. The intimate relationships existing between bones and muscles are mediated through function and require constant adjustment of the attachment between muscle and skeleton.

The aim of this work is to focus on the impact of occlusion on facial development. Literature was searched in Medline, Embase and Cochrane Library, using as mesh keywords bone remodelling, facial growth, masticatory muscles, children. Only articles in English language were included in the study.

## Mechanics of growth

TMJs have many, important, structural functions: they provide stability of mandibular position during mastication and prevent dislocation from external or unusual forces. Furthermore, they provide a firm base for the mandible to prevent airway occlusion: the mandible forms a mechanical guard and serves as a muscle attachment to maintain the patency and forward position of most of the structures surrounding the airway [Giuca et al., 2021; Saccomanno et al., 2021; Gelb et al., 2021]. With regards to the growth and adaptative requirements for the mandible, the whole ramus—and not only the condyle—is directly involved thanks to the action of the muscles that collectively exert their effect on it. It is the ramus that places the mandibular arch in occlusal relation and position with the maxilla and its dimensions and morphology are directly involved in the attachment of the masticatory muscles [Gelb et al., 2021; Enlow and Hans, 1996]. In this situation the loading of forces on the TMJ(s) is optimal and balanced. It is a normal condition for the TMJ(s) to be loaded: the constant tension of the muscles of mastication on the mandible makes this so. Furthermore, the muscle tension forces the head of the condyles against the articular disks and slope of the articular eminences so that the forces created within the TM joints are transmitted to the temporal bones and to the rest of the cranium in a symmetrically balanced way. The forces are applied to the mandible by contraction of the masticatory muscles: although the lateral pterygoid muscles are the only ones inserting directly into the region of the joint, all mandibular muscles collectively exert their effect on both position and movement of the jaw [Schellas, 1989; Epker and Frost, 1966; Boyd et al., 2021]. In the stomatognathic system the maxilla is a fixed component and the hyoid bone is almost fixed: together they become the stable base to which the mandible—the mobile segment of the system—can be related to. Since the maxilla and the hyoid bone are fixed, the forces are applied to the mandible and directed towards the maxilla and the hyoid bone. The movements of the mandible

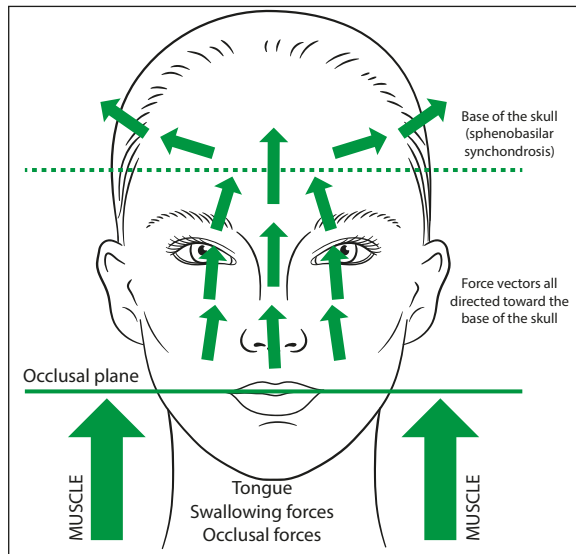


FIG. 1 The mandibular muscles affect position and movement of the jaw and the forces created within the TM joints and transmitted to the temporal bones and to the rest of the cranium are symmetrical.

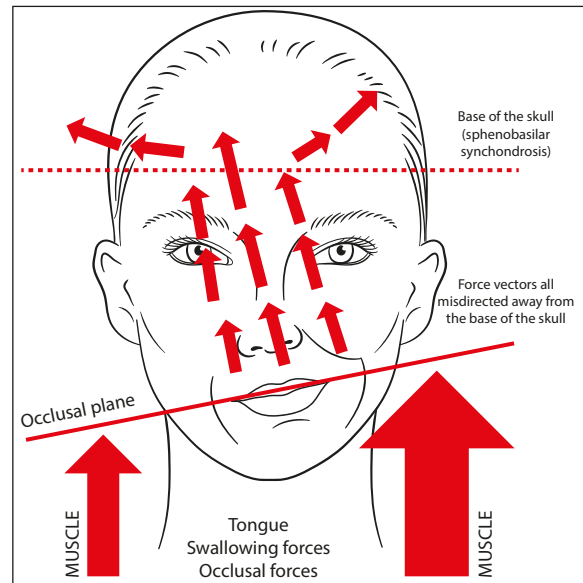


FIG. 2 Occlusal alterations and tilting of the occlusal plane in asymmetries.

are automatic and their patterns are engraved in the memory of neuromuscular mechanism: they obey a reflex command and are in synchrony with the movements of the tongue [Botzer et al., 2021].

Swallowing brings the maxillary and mandibular teeth into contact and the tongue is raised to the hard palate. In this way the vectors of forces generated by the closing muscles (mainly the masseter, the medial pterygoid and the temporalis muscles) are transmitted via the palatine, maxillae and vomer to the sphenoid in a symmetrically balanced way. Thus, the loading of forces on the temporomandibular joints is optimal and balanced. In normal-growing patients, the plane of occlusion is level, the mandible, articular disk, and head of the condyles are in good position, and the neuromuscular system is in harmony [Chinnappi and Getzoff, 1995]. The relative position of the plan of occlusion to the cranial base is strategic to determine the direction of the forces generated in the cranium during occlusal function. When the plane of occlusion is levelled, when mandible, articular disk, and head of the condyles are in good position, and when the neuromuscular system is in harmony, the loading of forces on the TM joints is optimal and balanced [Defabianis, 2002]. It is a normal condition for the TM joints to be loaded: the constant tension of the muscles of mastication on the mandible makes this so. The movements of the mandible are automatic and their patterns are engraved in the memory of neuromuscular mechanism: they obey a reflex command and are in synchrony with the movements of the tongue. Furthermore, the muscle tension of the TM joint forces the head of the condyles against the articular disks and slope of the articular eminences. In this way the mandibular muscles collectively exert their effect on both position and movement of the jaw and the forces created within the TM joints and transmitted to the temporal bones and to the rest of the cranium are symmetrical [Defabianis, 2002; Raadsheer et al., 1996; Gionhaku and Lowe, 1989; Ingervall and Helkimo, 1978; Katsaros, 2001; Rosenberg et al., 1997; Ingervall and Thilander, 1974] (Fig. 1). Without this proper alignment the forces of occlusion will not be directed toward the base of the skull and the vectors of forces will be directed away, resulting in pathological conditions within the

cranium. Unequal vertical forces generated on the teeth and hard palate during swallowing and chewing are greater on the low side as the muscles of the high side loose strength due to chronic hypertonicity [Rocabado et al., 1982]. The dentoalveolar compensation for abnormal jaw relationships causes the inclination of the teeth towards their opposites; this capability is provided by the moulding force of the tongue and cheeks and the responsiveness and adaptability of the alveolar bone. Since teeth erupt only until they achieve contact, the decreased vertical height of the affected side of the mandible causes interference with the vertical eruption of the maxillary posterior teeth as well as the mandibular ones [Rocabado et al., 1982]. Clinical expression of these asymmetries are occlusal alterations and the tilting of the occlusal plane when examined in the frontal view with supracontact between the molars on the affected side. This may compromise the biomechanical environment and result in a dysplastic pattern of growth [Bjork, 1955; Halperin, 1931; Waite, 1973] (Fig. 2).

Facial structures have been shown in humans and animals to be strongly dependent on muscular balance: the subsequent, asymmetric developing sequence acts as a stabilising factor on face development and osseous asymmetry [Raadsheer et al., 1996; Rosenberg et al., 1997]. Because the temporomandibular joints are compressible and subject to bone remodelling, TMJ loading becomes unbalanced and the forces transmitted to the temporal bones and to the rest of the cranium are misdirected away from the base of the skull. The stabilisation of this condition may compromise the biomechanical environment resulting then in facial asymmetries [Kiliaridis, 1995]. Disturbances in the harmonious interplay of the masticatory muscles may cause a misdirection of the vectors of forces away from the cranial base resulting in unbalanced TMJ loading and abnormal transmission of forces to the temporal bones and to the rest of the cranium. Abnormal muscle function can cause joint compression and bone remodelling and consequent pathological rotation of the occlusal plane: the subsequent, asymmetric developing sequence acts as a stabilising factor on face maldevelopment and osseous asymmetry [Boboc et al., 2022; Viscuso et al., 2020; Pawlaczyk-Kamienska et al., 2020; Thilander, 1995;

Gionhaku and Lowe, 1989; Ingervall and Helkimo, 1978; Ingervall and Thilander, 1974].

## Conclusion

A significant part of paediatric dentistry must be concerned with children's growth pattern. In a broad sense, although the basic blueprint of bone is inherent and genetic factors determine the development of bone structure mainly during the prenatal period, the form and architecture may be modified during prenatal and postnatal growth by local and systemic influences. Normal development of the mandible—as well as some portions of the maxilla and the face—is related to proper function of the masticatory apparatus. From numerous investigations it appears that many factors are responsible for controlling the craniofacial growth during childhood, function being one of the most important. For the cranio-facial-dental complex to function properly, teeth, jaws, masticatory muscles and cranial bones must be in harmony with each other: a change in any of them must be proportionally matched by appropriate growth adjustment to sustain and progressively achieve functional and structural balance of the whole.

Volumetric reconstruction of CT data (3D CT) and image analysis show a clear correlation between mandibular asymmetries, volume of the masticatory muscles and intensity and direction of the forces transmitted to the cranial base. These observations support the idea that the amount of skeletal growth of the face is strongly connected to a function equally balanced on both sides and regulated by the functional activation of muscles [Boyd et al., 2021; Botzer et al., 2021; Chinnappi and Getzoff, 1995; Raadsheer et al., 1996]. The concept by Ricketts [1975] of the mandible as being slung in a complex web of muscles more closely approximates reality than the concept of simple agonistic and antagonistic muscles. Diseases affecting cranio-facial structures, may involve and modify function in many ways. Congenital anomalies may seriously alter face symmetry, creating condition for altered muscular function and osseous development. They are both etiologically and pathogenetically heterogeneous, with autosomal or sporadic occurrence. Acquired pathologies like infection, trauma and/or tumours of the oro-facial region affecting salivary glands, bone and soft tissue may alter this balance as well as autoimmune and neurologic diseases involving the structure of the oro-facial area. Disorders of mandibular growth, therefore, lead to changes in the lower face. The common factor of both congenital and acquired forms is altered muscular balance leading to asymmetrical development of face structures.

After consolidation of mandibular disfunction and facial maldevelopment, even though the deformity may not be progressive, it is not self-correcting and there is no way to compensate for the loss or retarded growth [Brennan and Antonyshyn, 1996]. The persistent mandibular disfunction can also lead to disease of the joint, secondary to the changes in functional load: patients quite frequently develop an arthropathy with skeletal remodelling and alterations in the degree of TMJ loading which may add stress to one or both joints. Late symptoms may also appear on the uninjured side owing to changes brought about by alterations in biomechanical loading of this joint. As a result of the mechanical disfunction, disturbance of mandibular growth and TMJ disfunction may occur [Brennan and Antonyshyn,

1996]. Facial growth, in these cases, proceeds in close to normal fashion with the initial defect: if not treated, the dysplastic patterns of growth continues and worsens with time. Functional and cosmetic treatment of growth deficiencies is difficult. Orthodontic, prosthetic and surgical procedures may provide functional and aesthetic improvement [Giuca et al., 2020].

## References

- › Bjork A. Cranial base development. A follow-up X-ray study of the individual variation in growth occurring between ages 12 and 20 years and its relation to brain case and face development. *Am J Orthod* 1955;41:195-225.
- › Boboc AM, De Stefano A, Impellizzeri A, Barbato E, Galluccio G. Correlation between generalised joint hypermobility and temporomandibular joint disc displacement in adolescent patients: Magnetic Resonance Imaging study. *Eur J Paediatr Dent* 2022 Jun;23(2):106-110.
- › Botzer E, Quinzi V, Salvati SE, Coceani Paskay L, Saccomanno S. Myofunctional therapy Part 3: Tongue function and breastfeeding as precursor of oronasal functions. *Eur J Paediatr Dent* 2021 Sep;22(3):248-250.
- › Boyd K, Saccomanno S, Lewis CJ, Coceani Paskay L, Quinzi V, Marzo G. Myofunctional therapy. Part 1: Culture, industrialisation and the shrinking human face. *Eur J Paediatr Dent* 2021;22(1):80-81.
- › Brennan M, Antonyshyn O. The effects of temporalis muscle manipulation on skull growth: an experimental study. *Plast Reconstr Surg* 1996 Jan;97(1):13-24.
- › Chinappi AS Jr, Getzoff H. The dental-chiropractic cotreatment of structural disorders of the jaw and temporomandibular joint dysfunction. *J Manipulative Physiol Ther* 1995 Sep;18(7):476-81.
- › Defabianis P. Treatment of condylar fractures in children and youths: the clinical value of the occlusal plane orientation and correlation with facial development (case reports). *J Clin Pediatr Dent* 2002 Spring;26(3):243-50.
- › Enlow DH, Hans MG. *Essentials of facial growth*. W.B.Saunders Co: Philadelphia; 1996. p. 1-240.
- › Epker BN, Frost HM. Biomechanical control of bone growth and development: a histologic and tetracycline study. *J Dent Res* 1966 Mar-Apr;45(2):364-71.
- › Gelb M, Montrose J, Paglia L, Saccomanno S, Quinzi V, Marzo G. Myofunctional therapy Part 2: Prevention of dentofacial disorders. *Eur J Paediatr Dent* 2021 Jun;22(2):163-167.
- › Ghiabi N, White GE. Intraoral craniofacial manipulation. *J Clin Pediatr Dent* 1998 Fall;23(1):9-15.
- › Gionhaku N, Lowe AA. Relationship between jaw muscle volume and craniofacial form. *J Dent Res* 1989 May;68(5):805-9.
- › Giuca MR, Pasini M, Drago S, Del Corso L, Vanni A, Carli E, Manni A. Influence of Vertical facial growth pattern on herbst appliance effects in prepubertal patients: a retrospective controlled study. *Int J Dent* 2020 Jan 11;2020:1018793.
- › Giuca MR, Carli E, Lardani L, Pasini M, Miceli M, Fambrini E. Pediatric Obstructive Sleep Apnea Syndrome: Emerging Evidence and Treatment Approach. *Scientific World Journal* 2021 Apr 23;2021:5591251.
- › Halperin G. Normal asymmetry and unilateral hypertrophy. *Arch Int Med* 1931;49:676-682.
- › Ingervall B, Thilander B. Relation between facial morphology and activity of the masticatory muscles. *J Oral Rehabil* 1974 Apr;1(2):131-47.
- › Ingervall B, Helkimo E. Masticatory muscle force and facial morphology in man. *Arch Oral Biol* 1978;23(3):203-6.
- › Katsaros C. Masticatory muscle function and transverse dentofacial growth. *Swed Dent J* 2001;(151): Suppl. 1-47.
- › Kiliaridis S. Masticatory muscle influence on craniofacial growth. *Acta Odontol Scand* 1995 Jun;53(3):196-202.
- › Pawlaczyk-Kamienska T, Pawlaczyk-Wróblewska E, Borysewicz-Lewicka M. Early diagnosis of temporomandibular joint arthritis in children with juvenile idiopathic arthritis. A systematic review. *Eur J Paediatr Dent* 2020 Sep;21(3):219-226.
- › Raadsheer MC, Kiliaridis S, Van Eijden TM, Van Ginkel FC, Prah-Andersen B. Masseter muscle thickness in growing individuals and its relation to facial morphology. *Arch Oral Biol* 1996 Apr;41(4):323-32.
- › Ricketts RM. Mechanism of mandibular growth: a series of inquires on the growth of the mandible. in: McNamara JA. *Determinants of mandibular form and Growth*. Monogr. 4. Ann Arbor: Center for Human Growth and Development; 1975. p. 77.
- › Rocabado M, Johnston BE Jr, Blakney MG. Physical therapy and dentistry: an overview. *J Craniomandibular Pract* 1982 Dec-1983 Feb;1(1):46-9.
- › Rosenberg P, Arlis HR, Haworth RD, Heier L, Hoffman L, LaTrenta G. The role of the cranial base in facial growth: experimental craniofacial synostosis in the rabbit. *Plast Reconstr Surg* 1997 Apr;99(5):1396-407.
- › Saccomanno S, Berretin-Felix G, Coceani Paskay L, Manenti RJ, Quinzi V. Myofunctional Therapy Part 4: Prevention and treatment of dentofacial and oronasal disorders. *Eur J Paediatr Dent* 2021 Dec;22(4):332-334.
- › Schellas KP. MR of muscle of mastication. *AJNR* 1989;10:829-837.
- › Thilander B. Basic mechanisms in craniofacial growth. *Acta Odontol Scand* 1995 Jun;53(3):144-51.
- › Viscuso D, Storari M, Aprile M, Denotti G. Temporomandibular Disorders and Juvenile Idiopathic Arthritis: Scoping review with a case report. *Eur J Paediatr Dent* 2020 Dec;21(4):303-308.
- › Waite DE. Pediatric fractures of jaw and facial bones. *Pediatrics*.1973 Mar;51(3):551-9.