

The effect of ultrasonic access cavity preparation on dentinal inner walls: a micro-CT study on cadaveric samples

*Original*

The effect of ultrasonic access cavity preparation on dentinal inner walls: a micro-CT study on cadaveric samples / Zogheib, C.; Roumi, R.; Baldi, A.; Palopoli, P.; Pasqualini, D.; Berutti, E.; Alovise, M.. - In: ORAL RADIOLOGY. - ISSN 0911-6028. - (2023). [10.1007/s11282-023-00680-z]

*Availability:*

This version is available at: 11583/2980185 since: 2023-07-11T07:26:23Z

*Publisher:*

SPRINGER

*Published*

DOI:10.1007/s11282-023-00680-z

*Terms of use:*

This article is made available under terms and conditions as specified in the corresponding bibliographic description in the repository

*Publisher copyright*

(Article begins on next page)



# The effect of ultrasonic access cavity preparation on dentinal inner walls: a micro-CT study on cadaveric samples

C. Zogheib<sup>1</sup> · R. Roumi<sup>1</sup> · A. Baldi<sup>2</sup> · P. Palopoli<sup>3</sup> · D. Pasqualini<sup>2</sup> · E. Berutti<sup>2</sup> · M. Alovisi<sup>2</sup>

Received: 14 November 2022 / Accepted: 2 March 2023

© The Author(s) under exclusive licence to Japanese Society for Oral and Maxillofacial Radiology 2023

## Abstract

**Objective** The objective of this study is to evaluate the occurrence of coronal dentinal micro-cracks after access cavity refinement using high-speed burs and ultrasonic tips by means of micro-computed tomography (micro-CT) analysis.

**Methods** In this study, 18 mandibular cadaveric incisors were divided into two groups according to the protocol of the preparation of the conventional access cavity. The diamond bur 802 # 12 was used until the perforation of the pulp roof. Then, the Endo-Z bur was used for the group #1 and the ultrasonic tip Start-X # 1 for the group #2 to finish and refine the access cavity. The preparation time of each access cavity has been recorded. The teeth underwent a micro-CT scan before and after the preparation of the access cavity. Fisher's exact test, the Chi-square test, the Kolmogorov–Smirnov test, the Mann–Whitney test, and the Student's test were used for statistical evaluation.

**Results** The percentage of teeth with new micro-cracks is not significantly different between the two groups ( $-p$ -value < 0.5). The number of newly formed micro-cracks and extension size were not significantly different between the two groups. The direction of extension of the micro-cracks was occluso-apical. The average duration of the access cavity is significantly smaller with the Endo-Z system ( $-p$ -value < 0.001). The roughness of walls surfaces has no statistically difference between the two groups.

**Conclusion** The use of ultrasound, although slower, is considered safe in the creation of dentinal micro-cracks, in the preparation of the access cavity.

**Keywords** Endodontic access · Ultrasonic tip · Microcracks · Refinement bur · Micro-CT

## Introduction

The main purpose of endodontic treatment is the prevention and treatment of endodontic infection through the shaping, cleansing and three-dimensional obturation of the root canal system [1]. An appropriate access is required to successfully

achieve the above technical stages. An access cavity (AC) is defined as “the opening prepared in a tooth to gain entrance to the root canal system for the purpose of cleaning, shaping and obturating” [2]. Walton has described the access preparation as “the most important phase of the root canal treatment” since it maximizes cleaning, shaping and obturation. The control of the instruments and materials is difficult within the pulp system without a proper access [3].

Richman introduced the ultrasonic (US) instrumentation into endodontics which revolutionized the endodontic treatment [4]. Nowadays, the ultrasonic tips are a basic part of the endodontic equipment since they have multiple uses [5, 6]. They have many employments such as: access refinement, calcified canal location, pulp stone removal, management of intracanal obstruction, delivering energy to irrigating solutions, condensation of gutta-percha, root-end preparation during surgical procedures, and placement of mineral trioxide aggregate [5–7].

✉ P. Palopoli  
pietropalopoli@hotmail.it

C. Zogheib  
zogheibcarla@gmail.com

R. Roumi  
reina.roumi@gmail.com

<sup>1</sup> Department of Endodontics, Saint Joseph University of Beirut, Beirut, Lebanon

<sup>2</sup> Department of Surgical Sciences, Dental School, Endodontics, University of Turin, Turin, Italy

<sup>3</sup> Politecnico di Torino, Turin, Italy

Usually, the initial opening of the access cavity of anterior teeth is made with a round diamond bur [8]. The Endo-Z bur can be used after the perforation of the pulp chamber roof because it can safely rest on the pulp floor to eliminate the remaining pulp ceiling and its taper is very useful in the drafting and finishing of the cavity. In fact, burs driven in an air motor are more aggressive than ultrasonic tips driven in a piezo ultrasonic device. The ultrasonic tips eliminate small volumes of dentin and are more conservative with a greater longevity than the conventional high-speed diamond burs [4–9]. In addition, the water that runs over the entire length of the tip shaft provides effective cooling of the tooth with no risk of overheating during the AC preparation. Therefore, US tips could substitute the conventional high-speed diamond burs due to their conservative action and great longevity [9, 10]. Moreover, their use can be indicated also with operative microscope high magnification due to the higher visibility for the absence of the handpiece head [4].

In a previous study, Abedi et al. found a higher incidence of crack formation in correspondence of the walls of the retrograde cavities prepared by US tips compared with those made by burs [11]. In contrast, Rainwater et al. did not find any significant difference between conventional ultrasonic tips, diamond-coated ultrasonic tips, and high-speed stainless-steel burs for the number or type of cracks [12]. In a recent systematic review, John et al. concluded that ultrasonic root-end preparation resulted in higher crack formation than burs [13].

Despite many studies have investigated the correlation of dentinal defects formation in the root dentine during instrumentation, there are no studies investigating the correlation of dentinal defects formation after the preparation of the AC on cadaveric teeth where no crack related to tooth extraction

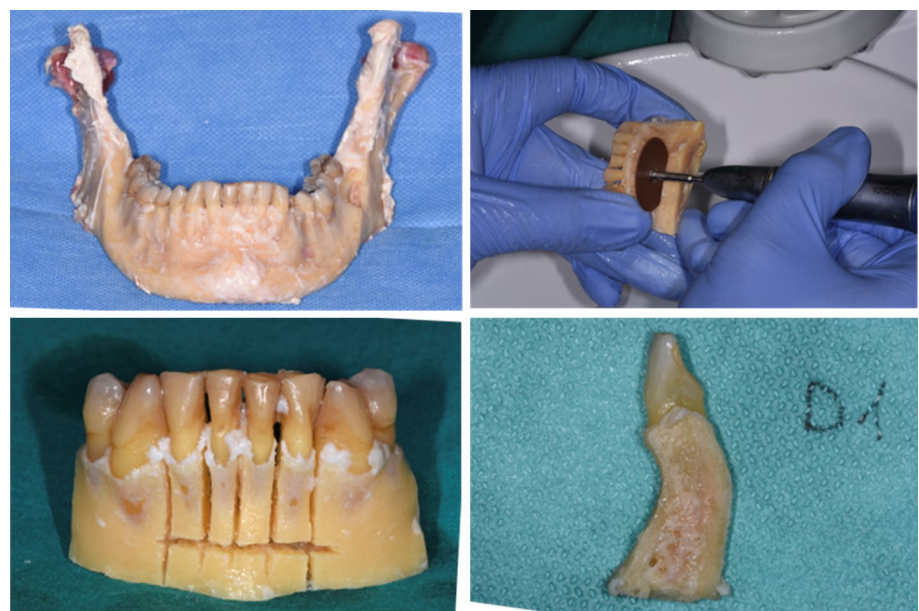is possible [14]. Thus, the purpose of this study is to evaluate the occurrence, location, and extension of dentinal defects (CEDD) after access cavity preparation with Endo-Z bur and Start-X ultrasonic device by means of a micro-computed tomography (micro-CT) imaging system and compare the final surface quality of dentinal cavity walls.

## Materials and methods

### Sample selection and specimen preparation

Five cadaveric jaws from donors ranging from 65 to 79 years old were collected in accordance with the local ethics committee (Protocol number EVS18/15). The samples were sectioned using a separator disk with abundant irrigation to obtain lower central and lateral incisors surrounded by alveolar bone (Fig. 1). Twenty intact teeth without caries, cracks and artificial alterations were included in the study. The specimens were stored in a 0.1% thymol solution then kept drying 24 h before micro-CT scanning. The samples were placed on a customized support to perform a preliminary low resolution micro-CT scan to obtain an overall outline of the canal anatomy and to select teeth that met the inclusion criteria (SkyScan 1172, Bruker micro-CT, Kontich, Belgium). Preliminary scans were conducted as follows: 450 projections through a 225° rotation (180° plus cone angle of the X-ray source) using a 1.0 mm thick aluminum filter, voltage = 100 kV, current = 80  $\mu$ A, source-to-object distance = 80 mm, source-to-detector distance = 220 mm, pixel binning = 8  $\times$  8, exposure time/projection = 0.2 s. The inclusion criteria were teeth with intact crowns and absence of significant abrasions or pulp calcifications. Samples

**Fig. 1** preparation of the samples



with average root length of  $12 \pm 2$  mm and one single root canal were included. Of twenty teeth assessed for inclusion, two were excluded due to anatomical features and 18 were included in the micro-CT study and stored in test tubes filled with isotonic solution. A single expert operator with over ten years of experience in endodontics and blinded to the objective of the study prepared the samples. The samples were randomly distributed into 2 groups ( $n=9$ ) according to the preparation protocol of the traditional access cavity: in the Endo-Z group the access opening was performed using an 802 #12 bur, followed by the endo Z bur (Dentsply-Maillefer, Ballaigues, Switzerland); while in the Start-X group, the pulp chamber was accessed using an 802 #12 bur, followed by Start-X #1 ultrasonic tip (Dentsply-Maillefer, Ballaigues, Switzerland) for access cavity refinement. The samples preparation was done under operative microscope (OPMI Pro Ergo, Carl Zeiss, Germany) following a geometrical pattern to remove the same tissues amount and the time required for access preparation was recorded.

### Microcomputed tomography analysis

The samples were scanned at a high spatial resolution before and after access creation (SkyScan, Bruker-microCT) to assess the extension of the cavity and the presence of enamel and dentin cracks. The micro-CT scanning parameters before and after access cavity creation were as follows: 2400 projections at 100 kV and 100  $\mu$ A, with a focus point of 8  $\mu$ m. The focus-object and object-detector distances were 98 mm and 218 mm, respectively. The total scan time was 4 h. High-resolution 16-bit TIFF images were acquired. This resulted in a volume of approximately  $1000 \times 1000 \times 1000$  isotropic voxels containing a length of 9.2  $\mu$ m. NRecon software was used to reconstruct the cross-sectional micro-CT images using the Feldkamp algorithm and standard parameters for *beam hardening* (60%) and *ring artifact correction* (7%). The native SkyScan data were automatically recognized, and the orthogonal cross sections were extrapolated using the DataViewer with the 3D recording function. The cross sections were imported in JPEG format and analyzed with ImageJ 1.43u 64-bit software (National Institute of Health, Bethesda, MD). An automatic threshold algorithm (MT-minimum threshold algorithm) was used to eliminate the possibility of manual errors [15]. All images from pre- and postoperative scans were analyzed by two blinded operators. Each access cavity was dynamically studied by observing the high-resolution 3D rendering and the orthogonal transverse sections. The cross sections were analyzed in relation to the cementum enamel junction (CEJ) through a plane perpendicular to the major axis of the canal, and coronally for the entire length of the crown. The following parameters were analyzed:

- Presence of CEDDs: the number of teeth with or without CEDDs and the number of CEDDs present in each tooth were calculated before and after the AC preparation, and percentages were also calculated.
- Location of CEDDs: the location of the CEDDs was registered as buccal, lingual, mesial, or distal in correspondence of the AC.
- Extension of CEDDs: the extension of the CEDDs was measured by multiplying the number of cross sections, in which each CEDD appeared by the thickness of the cross-Sect. (0.01 mm). The dimensions of the CEDDs were registered before and after the AC preparation for new and pre-existing cracks, thus registering a dimensional expansion for the pre-existing cracks. Linear measurements of the crack and their volume before and after preparation were registered to quantify the extension.

The teeth were allocated to each group to equally distribute specimens with preoperative presence or absence of CEDDs.

Furthermore, the three-dimensional (3D) reconstructed images of AC were used for the visual evaluation of the surface roughness of the dentinal walls. The surface roughness of the AC walls after the AC preparation procedures was observed for irregularities and striations. A quantitative scale classification containing four scores was used, as previously described [16]: Score 0 represented a very rough surface, score 1 rough surface, score 2 smooth surface, and score 3 very smooth surface. Roughness scoring was evaluated per tooth by two blinded evaluators. In case of discordance between them, both operators analyzed the images together until full agreement was reached.

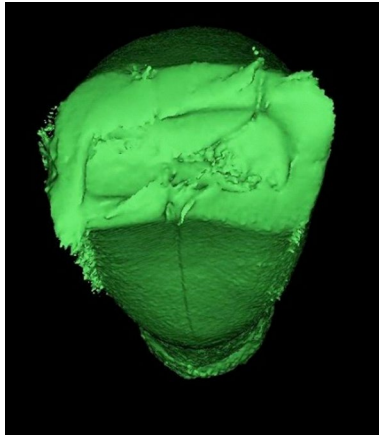
### Statistical analysis

Statistical analysis was performed using SPSS software (SPSS for Windows Version 20.0; IBM Corp, Armonk, NY) set at  $P < 0.05$ . The Fisher exact test compared the percentage of teeth with or without new CEDDs after AC. The Chi-square test and Fisher's exact test calculated the percentages of new CEDDs and pre-existing cracks postoperative expansion. The Kolmogorov–Smirnov test evaluated distribution normality of the dimensions and the duration of the AC preparation procedures between groups. Mann–Whitney test was applied to compare the size of the cracks between the two methods of AC preparation, and Student's t-test was conducted to compare the duration of the AC preparation procedures between the two groups, and to evaluate the effect of the two methods of AC refinement on roughness scoring and equality of the means, Levene's test was finally conducted for the equality of variances.

**Table 1** Sample baseline characteristics of the ten lower incisors included in the study<sup>a</sup>

	Endo-Z group ( <i>n</i> =9)	Start-X group ( <i>n</i> =9)	<i>P</i>
Canal volume (mm <sup>3</sup> )	4.18±0.69	3.99±0.45	0.33
Canal Surface area (mm <sup>2</sup> )	32.21±1.15	29.79±4.51	0.19

<sup>a</sup>Data are mean ± standard deviation. Statistical significance is indicated by *P* < 0.05



**Fig. 2** The direction and extension of the pre-existing CEDD in the preoperative Micro-CT high-resolution scans

## Results

Baseline pulp chamber volume and surface area displayed homogeneity between groups (*P* > 0.05) and are presented in Table 1.

In the preoperative scans, three of the eighteen teeth presented pre-existing cracks: one in the Endo-Z group and two in the Start-X group. In all cases, the pre-existing CEDDs extended from the incisal surface to the CEJ (Fig. 2).

A single new CEDDs was registered in Endo-Z group, while new CEDDs appeared in two teeth from Start-X group (Fig. 3). The percentage of teeth with new CEDDs was not significantly different between the two groups (*P* = 0.11). The new CEDDs extended from the incisal margin to the CEJ. All CEDDs were located on the buccal and lingual coronal walls.

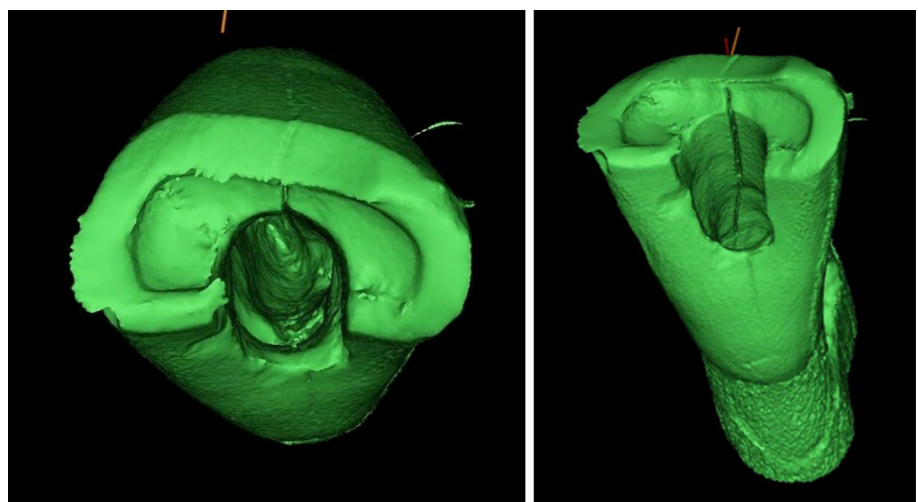
In 65% of the cases, an extension of pre-existing micro-cracks was observed with no statistically significant difference between groups (*P* = 0.21). The mean size and volume of the cracks were calculated (Figs. 4 and 5) and the results were not significantly different between groups (*P* = 0.33) (Table 2). The mean surface roughness of the inner walls of the access cavity was reported and there was no difference between groups (*P* = 0.42).

## Discussion

Tooth fracture, at any level, is one of the main factors leading to tooth loss [17]. The endodontic treatment includes several steps that may play an important role in the durability of teeth. Therefore, many studies evaluated the influence of different instruments and procedures on the formation of dentinal defects and tooth fracture strength [18–20].

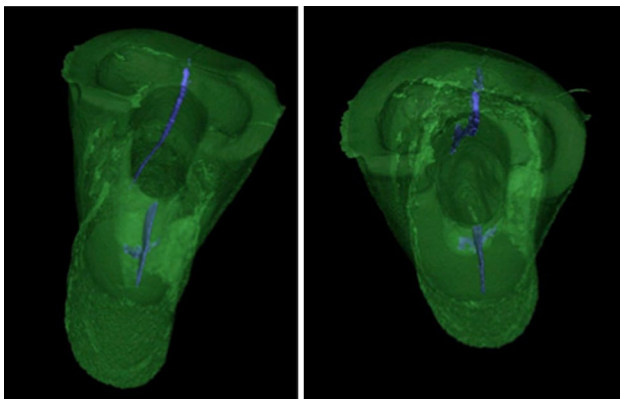
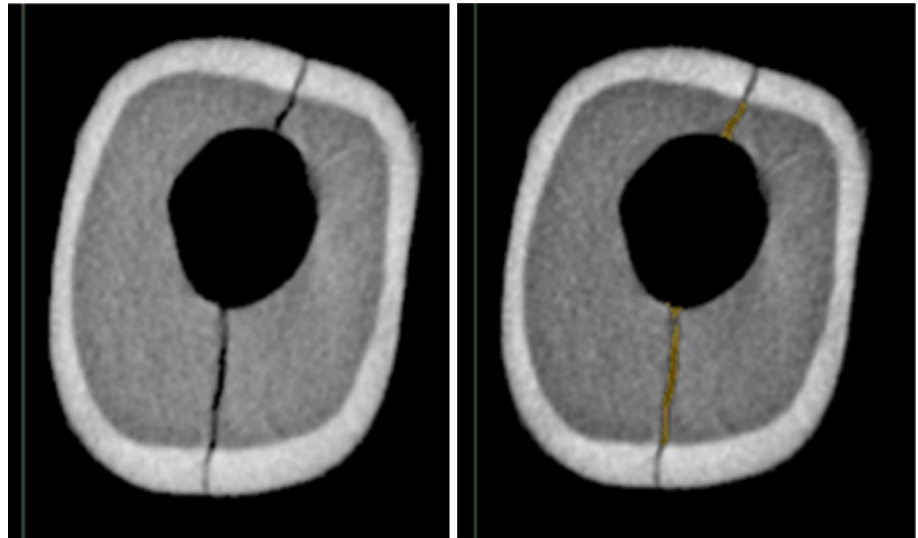
The current tendency is to preserve as much of the sound tooth structure as possible, starting from the AC preparation [21]. Nevertheless, no studies investigated the influence of this procedure on the integrity of the residual tooth

**Fig. 3** The direction and the extension of the new CEDDs from the incisal margin to the CEJ





**Fig. 4** The analysis of the dimension and pattern of CEDDs in the coronal portion through the evaluation of the cross-section images



**Fig. 5** The analysis of the fracture pattern and volume of the CEDDs through the evaluation of the three-dimensional micro-CT volumes

structure. In the present study, cadaveric human incisors were used to compare the effect of two different AC preparation procedures on the development of CEDDs by means of a micro-CT imaging system. Mandibular incisors were selected because they are more susceptible to cracks due to their low mesio-distal dentin thickness and anatomical position [22]. According to the present investigation, most

of the CEDDs observed after AC preparation were already detectable in the preoperative images, except for one newly CEDD formed in the Group 1 and 2 in one specimen of Group 2. However, this was not statistically significant and do not demonstrate the causality of USs in CEDDs formation. On the other hand, the extension of already existing CEDDs was detected in both groups with no statistically significant differences.

Generally, vertical root fractures develop due to a crack line initiated at the crown level [23]. This was already suggested in a similar study that found that CEDDs seemed directed occluso-apically [14]. Thus, vertical root fractures are to be considered as the extension of coronal micro-cracks. For both studies, the results are similar, except for the roughness of the AC which was smoother for the Endo-Z bur group [14]. This could be explained by the large AC surface

**Table 2** Percentage of new CEDDs; number of preoperative, new, and extended CEDDs; the mean dimension and volume of CEDDs and the mean surface roughness of the access cavity inner walls

Group	Preoperative CEDDs (%)	New CEDDs (%)	Dimension of CEDDs (mm) <sup>a</sup>	Volume of CEDDs <sup>a</sup> (mm <sup>3</sup> )	Roughness <sup>a</sup>
Bur (Endo-Z)	11.2	11.1	0.95 ± 0.39	0.55 ± 0.29	2.74 ± 0.88
Ultrasonic (Start-X)	22.2	22.3	1.07 ± 0.44	0.61 ± 0.12	1.97 ± 0.91

<sup>a</sup>Data are mean ± standard deviation. Statistical significance is indicated by  $P < 0.05$

The mean, standard deviation, minimum and maximum duration of the AC procedures are shown in Table 3. Endo-Z performed significantly faster than Start-X ( $P = 0.014$ )

**Table 3** Average access cavity procedure time (min:s) in both groups

Group	Mean ± SD	Minimum	Maximum
Endo-Z	4:21 ± 1:15	3:06	5:36
Start-X	10:28 ± 3:32	7:56	14:00

in molars compared to the small one in lower incisors. Other studies have shown that surfaces prepared with carbide burs are smoother than those prepared with diamond-coated US tips [24].

A previous micro-CT study showed that dentinal defects are more common in the endodontically treated teeth of older patients (40–70 years) [25]. Several studies highlighted the impact of US on the formation of dentinal defects in retrograde cavities. Peters et al. suggested that the incidence of cracks in retrograde cavities may be increased using US [26]. Likewise, Layton et al. demonstrated a significantly greater number of cracks after root resection and US retrograde preparation compared to teeth with only root resection [27]. In contrast, Beling et al. found no significant increase in the number of cracks after US preparation of the root [28]. This is in accordance with several other studies that found comparable number of cracks using stainless-steel, diamond-coated, or zirconium-coated tips [12, 29, 30].

The micro-CT analysis allows a 3D non-destructive evaluation of teeth before and after experimental procedures, and the detection of preoperative dentinal defects [30]. This explains the use of micro-CT in the current study for the evaluation of CEDDs before and after AC preparation. Therefore, samples can be examined by evaluating hundreds of sections to determine the location of the fracture, avoiding damage to the tooth structure, and obtaining reliable results [19, 31, 32]. Nevertheless, previous studies used destructive experimental models [31, 33]. For example, dentinal defects in retrograde cavities or after root canal shaping were evaluated by root sectioning and microscopic observation [11, 33]. These latter methods are biased since they do not allow preoperative visualization of the defects. Moreover, cutting procedures could initiate cracks themselves.

In the present study, the AC procedures were significantly shorter when performed with bur rather than with US. Nonetheless, generally, the use of US instead of high-speed burs, presents several advantages [34]. However, Tobón-Arroyave et al. suggested a positive association between dentinal defects and the longer time required for ultrasonic preparation of retrograde cavities [35]. However, dentinal defects occurred regardless of the dentinal walls thickness [35]. Thus, the extended time needed for ultrasonic preparation may have also influenced the results of the present study.

The use of cadaveric jaws, in the present study, better aligns with a clinical scenario. Moreover, the presence of the periodontal ligament allows the US energy to be absorbed leading to the formation of fewer CEDDs [36]. Furthermore, teeth were preserved from preoperative cracks due to extraction stress which may have influenced the results. However, dentinal defects appear to be mainly due to storage conditions, as dehydration, and not to extraction phenomena [23, 37]. Specimens of the present study were stored in a 0.1% thymol solution, as previously reported [19]. Moreover, as

it has been described that the spread of dentinal cracks may continue even during storage, although no stress is applied, the samples were kept moist along all experimental procedures [16, 38, 39]. In conclusion, within the limitations of this study, the access cavity preparation with ultrasonic tips did not significantly predispose the formation of dentinal defects and cracks of the tooth structure compared with high-speed burs.

**Acknowledgements** This work received a grant from the research committee of the University of Turin, financial support and sponsorship.

**Funding** Not applicable.

**Data Availability** Data and all materials related to this study is available by request to the corresponding author.

## Declarations

**Conflict of interest** There are no conflict of interest.

**Ethical approval** Ethics committee approval (Protocol number EVS18/15)

**Informed consent** This article does not contain any studies with human or animal subjects performed by the any of the authors.

## References

1. Tomson PL, Simon SR. Contemporary cleaning and shaping of the root canal system. *Prim Dent J*. 2016;5(2):46–53.
2. Glossary of endodontic terms. 9th ed. Chicago: American Association of Endodontists, 2016
3. Walton RE, Torabinejad M. In: Philadelphia WB, editor. *Principle and practice of endodontics* 3. Baltimore: Sanders Compagny; 2002.
4. Richman RJ. The use of ultrasonics in root canal therapy and root resection. *Med Dent J*. 1957;12:12–8.
5. Iqbal MK. Nonsurgical ultrasonic endodontic instruments. *Dent Clin N Am*. 2004;48:19–34.
6. Plotino G, Pameijer CH, Grande NM, Somma F. Ultrasonics in endodontics: a review of the literature. *J Endod*. 2007;33:81–95.
7. Nagendrababu V, Jayaraman J, Suresh A, Kalyanasundaram S, Neelakantan P. Effectiveness of ultrasonically activated irrigation on root canal disinfection: a systematic review of in vitro studies. *Clin Oral Investig*. 2018;22(2):655–70.
8. Adams N, Tomson PL. Access cavity preparation. *Br Dent J*. 2014;216(6):333–9.
9. Predebon JC, Lima LM, Flório FM, Santos-Pinto L, Basting RT. Micromorphologic assessment of CVD (Chemical Vapor Deposition) and conventional diamond tips and their cutting effectiveness. *J Mater Sci*. 2007;42:8454–60.
10. Predebon JC, Florio FM, Basting RT. Use of CVDentUS diamond tips for ultrasound cavity preparation. *J Contemp Dent Pract*. 2006;7:50–8.
11. Abedi HR, Van Mierlo BL, Wilder Smith P, Torabinejad M. Effects of ultrasonic root end cavity preparation on the root apex. *Oral Surg Oral Med Oral Pathol Oral Radiol Endod*. 1995;80:207–13.

12. Rainwater A, Jeanson BG. Effects of ultrasonic root-end preparation on microcrack formation and leakage. *J Endod.* 2000;26(2):72–5.
13. John J, Singh VPP, Karuveetil V, Subramanian D, Haridas K. Comparison of crack formation induced by ultrasonic tips and burs during root-end preparation: a systematic review and meta-analysis. *Evid Based Dent.* 2022. <https://doi.org/10.1038/s41432-022-0823-0>.
14. Zogheib C, Roumi R, Bourbouze G, Naaman A, Khalil I, Plotino G. Effects of ultrasonic refinement on endodontic access cavity walls: a microcomputed tomography analysis. *J Cons Dent.* 2021;24(1):29–35.
15. Neves AA, Silva EJ, Roter JM, et al. Exploiting the potential of free software to evaluate root canal biomechanical preparation outcomes through micro-CT images. *Int Endod J.* 2015;48:1033–42.
16. Vemisetty H, Priya NT, Singh B, Yenubary P, Agarwal AK, Surakanti JR. Synchrotron radiation-based micro-computed tomographic analysis of dentinal microcracks using rotary and reciprocating file systems: an in vitro study. *J Conserv Dent.* 2020;23:309–13.
17. Touré B, Faye B, Kane AW, Lo CM, Niang B, Boucher Y. Analysis of reasons for extraction of endodontically treated teeth: a prospective study. *J Endod.* 2011;37:1512–5.
18. Bayram HM, Bayram E, Ocak M, Uzuner MB, Geneci F, Celik HH. Micro computed tomographic evaluation of dentinal microcrack formation after using new heat treated nickel titanium systems. *J Endod.* 2017;43:1736–9.
19. De Deus G, Belladonna FG, Souza EM, Silva EJ, Neves Ade A, Alves H, et al. Micro computed tomographic assessment on the effect of ProTaper next and twisted file adaptive systems on dentinal cracks. *J Endod.* 2015;41:1116–9.
20. Zogheib C, Sfeir G, Plotino G, Deus G, Daou M, Khalil I. Impact of minimal root canal taper on the fracture resistance of endodontically treated bicuspid. *J Int Soc Prev Community Dent.* 2018;8:179–83.
21. Clark D, Khademi J. Modern molar endodontic access and directed dentin conservation. *Dent Clin North Am.* 2010;54:249–73.
22. Schatz D, Alfter G, Göz G. Fracture resistance of human incisors and premolars: morphological and patho-anatomical factors. *Dent Traumatol.* 2001;17(4):167–73.
23. De Deus G, Cavalcante DM, Belladonna FG, Carvalhal J, Souza EM, Lopes RT, et al. Root dentinal microcracks: a post extraction experimental phenomenon? *Int Endod J.* 2019;52:857–65.
24. Rosales Leal JI, Gaya V O, Vallecillo Capilla M, del Luna Castillo JD. Influence of cavity preparation technique (rotary vs ultrasonic) on microleakage and marginal fit of six end root filling materials. *Med Oral Patol Oral Cir Bucal.* 2011;16:e185-9.
25. PradeepKumar AR, Shemesh H, Chang JW, Bhowmik A, Sibi S, Gopikrishna V, et al. Preexisting dentinal microcracks in nonendodontically treated teeth: An ex vivo micro computed tomographic analysis. *J Endod.* 2017;43:896–900.
26. Peters CI, Peters OA, Barbakow F. An in vitro study comparing root-end cavities prepared by diamond-coated and stainless steel ultrasonic retrotips. *Int Endod J.* 2001;34(2):142–8.
27. Layton CA, Marshall JG, Morgan LA, Baumgartner JC. Evaluation of cracks associated with ultrasonic root end preparation. *J Endod.* 1996;22:157–60.
28. Beling KL, Marshall JG, Morgan LA, Baumgartner JC. Evaluation for cracks associated with ultrasonic root end preparation of gutta percha filled canals. *J Endod.* 1997;23:323–6.
29. Navarre SW, Steiman HR. Root end fracture during retropreparation: a comparison between zirconium nitride coated and stainless steel microsurgical ultrasonic instruments. *J Endod.* 2002;28:330–2.
30. Ishikawa H, Sawada N, Kobayashi C, Suda H. Evaluation of root end cavity preparation using ultrasonic retrotips. *Int Endod J.* 2003;36:586–90.
31. De Deus G, Silva EJ, Marins J, Souza E, Neves Ade A, Gonçalves Belladonna F, et al. Lack of causal relationship between dentinal microcracks and root canal preparation with reciprocation systems. *J Endod.* 2014;40:1447–50.
32. De Deus G, Belladonna FG, Silva EJ, Souza EM, Versiani MA. Critical appraisal of some methodological aspects of using micro CT technology in the study of dentinal microcracks in endodontics. *Int Endod J.* 2016;49:216–9.
33. Hin ES, Wu MK, Wesselink PR, Shemesh H. Effects of self adjusting file, Mtwo, and ProTaper on the root canal wall. *J Endod.* 2013;39:262–4.
34. von Arx T, Walker WA 3rd. Microsurgical instruments for root-end cavity preparation following apicoectomy: a literature review. *Endod Dent Traumatol.* 2000;16(2):47–62.
35. Tobón Arroyave SI, Restrepo Pérez MM, Arismendi Echavarría JA, Velásquez Restrepo Z, Marín Botero ML, García Dorado EC. Ex vivo microscopic assessment of factors affecting the quality of apical seal created by root end fillings. *Int Endod J.* 2007;40:590–602.
36. Calzonetti KJ, Iwanowski T, Komorowski R, Friedman S. Ultrasonic root end cavity preparation assessed by an in situ impression technique. *Oral Surg Oral Med Oral Pathol Oral Radiol Endod.* 1998;85:210–5.
37. Versiani MA, Souza E, De Deus G. Critical appraisal of studies on dentinal radicular microcracks in endodontics: methodological issues, contemporary concepts, and future perspectives. *Endod Top.* 2015;33:87–156.
38. Pedullà E, Genovesi F, Rapisarda S, La Rosa GR, Grande NM, Plotino G, et al. Effects of 6 single file systems on dentinal crack formation. *J Endod.* 2017;43:456–61.
39. Rödig T, Müller C, Hoch M, Haupt F, Schulz X, Wiegand A, et al. Moisture content of root canal dentine affects detection of micro cracks using micro computed tomography. *Int Endod J.* 2018;51:357–63.

**Publisher's Note** Springer Nature remains neutral with regard to jurisdictional claims in published maps and institutional affiliations.

Springer Nature or its licensor (e.g. a society or other partner) holds exclusive rights to this article under a publishing agreement with the author(s) or other rightsholder(s); author self-archiving of the accepted manuscript version of this article is solely governed by the terms of such publishing agreement and applicable law.