

IS PREVENTIVE CANAL THERAPY NECESSARY IN TEETH INVOLVED IN  
RADICULAR CYSTS? A CASE SERIES

*Original*

IS PREVENTIVE CANAL THERAPY NECESSARY IN TEETH INVOLVED IN  
RADICULAR CYSTS? A CASE SERIES / Bobba, I., Erovigni, F., Bosso, I., Dell'Acqua, A., Carossa, S.. - In: DENTAL  
CADMOS. - ISSN 2785-4248. - (2021), pp. 20-20.

*Availability:*

This version is available at: 11583/2976487 since: 2023-03-01T17:15:35Z

*Publisher:*

edra

*Published*

DOI:

*Terms of use:*

This article is made available under terms and conditions as specified in the corresponding bibliographic description in  
the repository

*Publisher copyright*

(Article begins on next page)



**28°  
CONGRESSO  
NAZIONALE**

COLLEGIO DEI DOCENTI UNIVERSITARI  
DI DISCIPLINE ODONTOSTOMATOLOGICHE

**L'ODONTOIATRIA  
per la salute in**

**SALUTE**

## COLLEGIO DEI DOCENTI UNIVERSITARI DI DISCIPLINE ODONTOSTOMATOLOGICHE ETS

### **PRESIDENTE**

Roberto Di Lenarda

### **PAST PRESIDENTE**

Enrico F. Gherlone

### **SEGRETARIO**

Filippo Graziani

### **TESORIERE**

Livia Ottolenghi

### **SEGRETERIA DOCENTI**

Giada Gonnelli | segreteria@cduo.it

### **SITO INTERNET**

www.cduo.it

### **DIRETTORE RESPONSABILE**

Giorgio Albonetti

### **RESPONSABILE EDITORIALE**

Ludovico Baldessin

### **COORDINAMENTO EDITORIALE**

Barbara Moret | b.moret@lswr.it | Tel. 02 88184.420

### **REDAZIONE**

Greta Schincaglia | g.schincaglia@lswr.it | Tel. 02 88184.512

### **PUBBLICITÀ**

Stefano Busconi (Responsabile commerciale) | s.busconi@lswr.it

### **TRAFFICO**

Elena Genitoni | e.genitoni@lswr.it | Tel. 02 89293962

© 2021 EDRA SpA

Tutti gli abstract pubblicati sono redatti sotto la responsabilità degli Autori. La pubblicazione o la ristampa degli articoli deve essere autorizzata per iscritto dall'editore. Ai sensi dell'art. 13 del D.Lgs. 196/03, i dati di tutti i lettori saranno trattati sia manualmente, sia con strumenti informatici e saranno utilizzati per l'invio di questa e di altre pubblicazioni e di materiale informativo e promozionale. Le modalità di trattamento saranno conformi a quanto previsto dall'art. 11 D.Lgs 196/03. I dati potranno essere comunicati a soggetti con i quali EDRA SpA intrattiene rapporti contrattuali necessari per l'invio delle copie della rivista. Il titolare del trattamento dei dati è EDRA SpA, G. Spadolini 7 - 20141 Milano, al quale il lettore si potrà rivolgere per chiedere l'aggiornamento, l'integrazione, la cancellazione e ogni altra operazione di cui all'art. 7 D.Lgs 196/03.

## SOMMARIO/SUMMARY

<b>Chirurgia maxillo facciale/Maxillofacial surgery</b>	<b>5</b>
<b>Chirurgia orale/Oral surgery</b>	<b>8</b>
<b>Conservativa/Conservative dentistry</b>	<b>42</b>
<b>Endodonzia/Endodontics</b>	<b>51</b>
<b>Gnatologia/Gnathology</b>	<b>70</b>
<b>Implantologia/Implantology</b>	<b>83</b>
<b>Laser in odontostomatologia/Laser odontostomalogy</b>	<b>110</b>
<b>Materiali dentari/Dental materials</b>	<b>118</b>
<b>Odontoiatria digitale/Digital dentistry</b>	<b>124</b>
<b>Odontoiatria pediatrica/Paediatric dentistry</b>	<b>133</b>
<b>Odontoiatria preventiva e di comunità/Preventive and community dentistry</b>	<b>158</b>
<b>Ortodonzia/Orthodontics</b>	<b>169</b>
<b>Parodontologia/Peridontology</b>	<b>241</b>
<b>Patologia e medicina orale/Pathology and oral medicine</b>	<b>258</b>
<b>Prevenzione ed igiene dentale/Dental prevention and hygiene</b>	<b>283</b>
<b>Protesi/Prosthetic dentistry</b>	<b>296</b>



## RESECTION OF A MUCOCUTANEOUS VERRUCOUS CARCINOMA AND SURGICAL RECONSTRUCTION: A CASE REPORT

Della Vella F.<sup>1</sup>, Sportelli P.<sup>2</sup>, Albanese G.<sup>1</sup>, Dell'Olio F.<sup>1</sup>, Mezzapesa P.<sup>1</sup>, Maiorano E.<sup>3</sup>

<sup>1</sup>Specialization School of Oral Surgery, Department of Interdisciplinary Medicine, University of Bari Aldo Moro, Bari, Italy

<sup>2</sup>Odontostomatology Unit, Department of Interdisciplinary Medicine, University of Bari Aldo Moro, Bari, Italy

<sup>3</sup>Department of Emergency and Organ Transplantation, Pathological Anatomy Unit, University of Bari Aldo Moro, Bari, Italy

**Aim:** this case report describes the excision of a commissural verrucous carcinoma and the simultaneous surgical reconstructions.

**Case report:** a male patient of 67 years old came to our attention at Policlinico of Bari presenting with a verrucous growth on the right labial commissure and a large hyperkeratotic area on the correspondent cheek mucosa. The patient referred that the lesions arose about a year before and that enlarged as months went by. Anamnestic data revealed arterial hypertension, benign prostatic hyperplasia, and extrasystole. He was regularly taking lorazepam, amitriptyline, irbesartan, terazosin and dutasteride. He reported smoking about 15 cigarettes per day and declared not to assume alcohol. EKG, OPT-RX, CBC and blood panel were normal.

The surgery was held under general anesthesia. The entire lesion was excised using a 15c scalpel and the bioptic sample was put in 10 buffered formalin. The commissural defect after the tumor resection was fixed by performing triangular cuta-

neous advancement flaps according to the Zisser technique. The oral surgical wound was closed with two transposition mucosal flaps.

Mucosal and intradermal suture was made with vicryl 3.0 e 4.0, while for the cutaneous stitches prolene 5.0 was employed. Antibiotic coverage with amoxicillin + clavulanic acid was prescribed together with an analgesic.

The patient carried out buccal muscular exercise to avoid scarring stenosis of the commissure.

The histopathology reported a verrucous squamous carcinoma, well-differentiated with an expansive growth into the superficial chorion. The biopsy's margins were free from neoplasia.

He underwent follow-up at 1 week, 4 weeks and each month till now. The aesthetic and mouth opening were completely restored, and no complications occurred.

**Conclusion:** the use of Zisser flaps technique allowed a complete and effective reconstruction of the commissure despite the wide and radical excision of the tumor.

## A COMBINED CLEAR ALIGNER - ORTHOGNATIC SURGERY APPROACH OF A CLASS III MALOCCLUSION

Macri M., Fiore V., Festa F.

Department of Medical, Oral and Biotechnological Sciences, University G. D'Annunzio of Chieti-Pescara, Chieti, Italy

**Aim:** the aim of this case report is to show the treatment of a 34 years old patient with skeletal Class III malocclusion treated using clear aligner before and after to an orthodontic-surgery approach.

**Methods:** clinical examination showed a dolichofacial-asymmetrical male patient with concave profile, Class III bilateral molar and canine malocclusion and crowding in the lower arch, midline deviation and signs of clenching. Objectives of treatment were: to correct soft tissues profile, skeletal discrepancies, functional and stable occlusion and the aesthetics pa-

tient's needs. A clear aligner-orthognatic surgery combined approach was performed in three phases: pre-surgical orthodontic phase, surgical phase and post-surgical orthodontic phase.

**Results:** the treatment objectives were achieved; the patient showed a more harmonious smile and a fine-balanced facial profile.

**Conclusion:** a combined clear aligner-orthognatic surgery approach showed a winning alternative for Class III malocclusion and skeletal discrepancies.

## SINUS FLOOR ELEVATION WITH DIFFERENT BONE SUBSTITUTES: A REVIEW

Inchingolo A.D.<sup>1</sup>, Hazballa D.<sup>1</sup>, Patano A.<sup>1</sup>, Laudadio C.<sup>1</sup>, Malcangi G.<sup>1</sup>, Colocchia G.<sup>1</sup>, Marinelli G.<sup>1</sup>, Limongelli L.<sup>1</sup>, Montenegro V.<sup>1</sup>, D'Oria M.T.<sup>1</sup>, Corsalini M.<sup>1</sup>, Dipalma G.<sup>1</sup>, Inchingolo F.<sup>1</sup>, Di Venere D.<sup>1</sup>, Cardarelli F.<sup>1</sup>, Farronato M.<sup>2</sup>, Tartaglia G.<sup>2</sup>

Complex Operative Unit of Odontostomatology Director: Prof. G. Favia

<sup>1</sup>Specialization School in Orthognatodontics, Director Prof. F. Inchingolo, Interdisciplinary Department of Medicine D.I.M. University of Bari Aldo Moro, Bari, Italy

<sup>2</sup>Department of Biomedical, Surgical and Dental Sciences, School of Dentistry, University of Milan. UOC Maxillo-Facial Surgery and Dentistry, Fondazione IRCCS Ca' Granda, Ospedale Maggiore Policlinico, Milan, Italy

**Aim:** sinus floor elevation procedures are routinely performed in dentistry. The sinus constitutes one of the most challenging regions to regenerate bone with higher complication/failure rates in comparison to other modalities. The aim of the present study was to investigate through a critical systematic overview the elevation of maxillary sinus with different bone substitutes, alloplastic, allograft, tooth matrix and bovine bone.

**Methods:** this systematic search was conducted by PubMed/Central, PubMed/Medline, Web of science and Google scholar according the PRISMA guidelines.

**Results:** calcium triphosphate (TCP) creates new bone faster than others biomaterials but exposed the apex of implants because loses its volume. Some authors believe that this resorption is connected to the length of the implant in the sinus. The bovine bone conserves its volume for a long time and keeps the apex of the implant covered. From the most used types of

allografts, DFDBA is considered more osteoinductive than FDBA. However, FDBA resorbs much slower, which brings the advantage of better space maintenance. Ground dentine instead is osteoinductive as DFDBA and maintains the volume as bovine bone. To ameliorate their properties the use of PRF is suggested, however PRF improve new blood flow to the grafted area and primary healing of soft tissues, does not give benefits in long-term on hard tissues. While the use of the BMP has give very promising results especially with collagen-based biomaterials.

**Conclusion:** an appropriate biomaterial in sinus floor elevation must maintain the volume until they are completely replaced by bone tissue and to resist over time. For better results these biomaterials can be used combined at each other because none fully meet the requirements needed in this procedure. Dental matrix seems to be promising in this field but further studies are required.

## QUALITATIVE AND QUANTITATIVE MORPHOMETRIC ANALYSIS IN ORTHOGNATHIC SURGERY: A PILOT STUDY

Muraca D.<sup>1</sup>, Averta F.<sup>1</sup>, Diodati F.<sup>1</sup>, Bennardo F.<sup>1</sup>, Antonelli A.<sup>1</sup>, Barone S.<sup>1</sup>, Cristofaro M.G.<sup>2</sup>, Giudice A.<sup>1</sup>

<sup>1</sup>Department of Health Sciences, University Magna Graecia of Catanzaro, Catanzaro, Italy

<sup>2</sup>Department of Experimental and Clinical Medicine, University Magna Graecia of Catanzaro, Catanzaro, Italy

**Aim:** this study aimed to evaluate the accuracy of virtual surgical planning (VPS) in patients undergoing orthognathic surgery, through the morphometric analysis.

**Methods:** this was a pilot retrospective study using existing CT scans of two orthognathic patients. Each patient underwent preoperative (T1) and postoperative (T2) scans. To perform a 3D comparative analysis, voxel-based superimposition of scans was made using 3DSlicer software. ITK-Snap allowed the segmentation of reliable 3D models of regions of interest. 3DSlicer was used to correlate the presurgical and postsurgical and to compare postsurgical movements with the VPS. The qualitative analysis was performed through semitransparent and colormaps overlays at T1 and T2. Quantitative assessments based on landmarks (Condilion, Gonion,

Menton, B point, Pogonion, Anterior Nasal Spine) placed on the 3D surface models were obtained and the mean distance was calculated in correspondence with the condylar region.

**Results:** a monomaxillary and a bimaxillary orthognathic surgery were performed to treat skeletal class III malocclusions. Comparison between T2-CT scans and VPS, for both patients, wasn't statistically significant ( $p > 0.05$ ). Condylar displacement showed a mean value of  $0.53 \pm 0.05$  mm for right condilion and  $1.9 \pm 0.05$  mm for left condilion. The mean difference of intercondylar position between T2 and T1 was  $1.16 \pm 0.37$  mm.

**Conclusion:** open-source software was a valid alternative for three-dimensional analysis of post-operative bone reduction and an effective tool for evaluating the accuracy of virtual surgical planning.

## A RARE CASE OF CLEIDOCRANIAL DYSPLASIA: CRANIOFACIAL FEATURES AND DENTAL ANOMALIES

Patano A.<sup>1</sup>, Laudadio C.<sup>1</sup>, Malcangi G.<sup>1</sup>, Coloccia G.<sup>1</sup>, Marinelli G.<sup>1</sup>, Limongelli L.<sup>1</sup>, Inchingolo A.D.<sup>1</sup>, Montenegro V.<sup>1</sup>, D'Oria M.T.<sup>1</sup>, Laforgia A.<sup>1</sup>, Dipalma G.<sup>1</sup>, Inchingolo F.<sup>1</sup>, Di Venere D.<sup>1</sup>, Cardarelli F.<sup>1</sup>, Farronato M.<sup>2</sup>, Tartaglia G.<sup>2</sup>

Complex Operative Unit of Odontostomatology Director: Prof. G. Favia

<sup>1</sup>Specialization School in Orthognatodontics Director Prof. F. Inchingolo, Interdisciplinary Department of Medicine D.I.M. University of Bari Aldo Moro, Bari, Italy

<sup>2</sup>Department of Biomedical, Surgical and Dental Sciences, School of Dentistry, University of Milan, Milan, Italy. UOC Maxillo-Facial Surgery and Dentistry. Fondazione IRCCS Ca' Granda, Ospedale Maggiore Policlinico, Milan, Italy

**Aim:** cleidocranial dysplasia (CCD) is a genetic disorder with autosomal dominant inheritance, characterized by a general dysplasia with various skeletal and dental deformities. The most prevalent features are aplastic or hypoplastic clavicles, supernumerary teeth, failed eruption of permanent teeth, and a hypoplastic maxilla. This case report describes surgical extractions of supernumerary teeth in a patient affected with CCD.

**Methods:** a 22 years old female affected with CCD referred to Oral Surgery Department for the avulsion of supernumerary teeth. The molecular genetic analysis identified an heterozygous missense mutation in the RUNX-2 gene (c.674G > A), resulting in the replacement of arginine with glutamine at residue 225 (p.Arg225Gln). Her father presented the same mutation.

Physical examination showed short stature, narrow shoulders, a brachycephalic head, hypoplastic maxillary and broad nasal bridge. Intraoral examination revealed an Angle class III

malocclusion, negative overjet and lower crowding. The patient was in treatment with a multibrackets straightwire fixed appliance.

The radiographic findings revealed the presence of supernumerary included teeth in the area of maxillary canines and mandibular premolars.

**Results:** the supernumerary teeth were surgically extracted under general anesthesia. A full thickness flap was raised and osteotomy was performed in order to expose the teeth. After extractions the flap was relocated and interrupted sutures were given; antibiotics and anti-inflammatory drugs were prescribed.

**Conclusion:** patients with cleidocranial dysostosis require a multidisciplinary team approach. A variety of diagnostic and treatment techniques and many surgeries might be required. It is important also the collaboration between dentists and clinical geneticists to produce early diagnosis.

## ANTIBIOTIC PROPHYLAXIS PROTOCOL IMPACT FOR DAY HOSPITAL ORAL SURGERY: PRELIMINARY DATA

Della Ferrera F., Basano L., Buttiglieri S., Chiarelli A., Gilardino M.O., Luciani M., Scatà E., Appendino P.

Department of Dentistry and Oral Surgery, Mauriziano Umberto I Hospital, Turin, Italy

**Aim:** observe impact of a new antibiotic prophylaxis (AP) protocol before day-hospital oral surgery procedures on prescription of prolonged post-operative antibiotic therapy (pAT) and incidence of surgical site infections (SSI).

**Methods:** random sample of patients who underwent oral surgery in day hospital setting were analyzed. Incidence of pAT, postoperative complications and SSI were calculated. Oral surgery procedures: extraction of impacted wisdom/unerupted teeth, tooth extractions in patients with systemic comorbidities, endodontic surgery, implant surgery, periodontal surgery, bone grafts. Systemic conditions requiring AP and AP regimens were identified according to international guidelines. AP regimens were classified upon duration. Extension of AT was considered according to systemic (eg. risk for osteonecrosis) and local (surgical site contamination, invasiveness) factors.

**Results:** 100 hospital records regarding 40♂, 6♀ mean age 40 years (90-16) were analyzed. Systemic conditions favour-

ing SSI were observed in 14 patients. Extraction of wisdom teeth (69) was the main intervention. Mean duration was 30 min (56-18).

Ostectomy was performed in 93% of cases. Incidence of pAT was 69%. Post-operative healing complications were observed in 4 patients. Three patients who underwent extraction of impacted wisdom teeth (2) and pre-prosthetic surgery (1) had no comorbidities, one patient submitted to tooth extraction was in therapy with antiresorptive drugs for oncologic reasons. SSI was diagnosed in two cases.

**Conclusion:** usefulness of antibiotic prophylaxis in oral surgery is a matter of debate.

Despite evidence of SSI prevention, specially following wisdom tooth extraction great concern arouses regarding antimicrobial resistance and AT side effects. With introduction of this AP protocol significant reduction of pAT employment was obtained without SSI/side effects increase.

## ADVANCED PLATELET-RICH FIBRIN IN THE TREATMENT OF DRY SOCKET

Eposito G., Gargiulo D., Quaraniello M., Giacoia A., Di Maro P., Rosiello N.

Department of Neurosciences, Reproductive Sciences and Oral Sciences, University of Naples Federico II, Naples, Italy

**Aim:** the aim of this study has been to evaluate the efficacy of A-PRF (Advanced Platelet-rich Fibrin) in the management of pain and the acceleration of wound healing in the treatment of dry socket.

**Methods:** consecutive patients who were diagnosed with alveolar osteitis (AO), recruited from Department of Oral Surgery of the University of Naples Federico II, were enrolled. After local anesthesia, the dry socket was curetted and irrigated with saline. The PRF clot was placed in the socket and then covered with an A-PRF membrane. The level of pain was assessed using a 10-point visual analogic scale. The rate of granulation tissue (GT) formation was clinically evaluated and recorded as follows. A complete absence of GT was recorded as 0. The formation of GT over one quarter or less of the socket was recorded as 1, over half of the socket as 2, over three quarters as 3, while a complete covering of granulation was recorded as 4. All the

measurements were carried out by a single masked examiner, before and after treatment, on the 1st, 3rd, 7th, 14th and 21st day. The Friedman test for multiple dependent samples was used to detect the treatment and time effect.

**Results:** over a six-month period, four patients with established AO were included. The pain scores statistically decrease from an average of 8.5 pre-operatively to 3.5 on the first day after PRF application, to 0.25 on the third day and subsequently to 0 at the following time points (Friedman test,  $p = .002$ ). The GT formation within the healing socket progressively improved statistically from an average of 0 before treatment to 0.25 on the first day, 1.75 on the third day, 3.25 on the seventh day and 4 on fourteenth and twenty-first days after the treatment (Friedman test,  $p = .002$ ).

**Conclusion:** the use of A-PRF in the treatment of AO significantly reduces pain levels and also improves the wound healing process.

## CONSCIOUS SEDATION WITH BENZODIAZEPINES: GENDER DIFFERENCES

Ezeddine F.<sup>1</sup>, Scibetta C.<sup>1</sup>, Brunello G.<sup>1,2</sup>, Sivoletta S.<sup>1</sup>, Zanette G.<sup>1</sup>

<sup>1</sup>Department of Neurosciences, Section of Dentistry, University of Padua, Padua, Italy

<sup>2</sup>Department of Oral Surgery, Universitätsklinikum Düsseldorf, Düsseldorf, Germany

**Aim:** benzodiazepines are commonly used to reduce patients' anxiety and discomfort in dentistry, in a technique known as conscious sedation. Aim of this review is to summarize the main findings on the influence of gender in the efficacy of benzodiazepine administration for conscious sedation.

**Methods:** a literature research was conducted in MEDLINE via OVID up to 10th March 2021 to assess potential gender-related differences in benzodiazepine efficacy.

Search was restricted to preclinical *in vivo* and clinical studies published in English.

A hand search was also performed. Routes of drug administration, types of benzodiazepines (e.g. midazolam, diazepam, temazepam) and related effects were recorded and summarized.

**Results:** 17 articles published between 1979 and 2020 were included in the present review (6 preclinical *in vivo* and 11 clinical studies). Overall, human studies demonstrate that females seem to be less sensitive to benzodiazepines and to require higher doses to reach the same efficacy compared to males. Benzodiazepine pharmacokinetics resulted to be affected by gender. The efficacy was influenced by sexual hormones, menstruation and oral contraceptive use.

**Conclusion:** while most researchers find that the administration of benzodiazepines is less efficacious and safe in women, some studies reach the opposite conclusion. This review highlights the necessity for further research to determine whether gender may be related to significant differences in benzodiazepine-based conscious sedation efficacy.

## DYNAMIC AND STATIC NAVIGATION VS FREEHAND DRILLING IN IMPLANTOLOGY: A LITERATURE REVIEW

Faben A., De Palma F., Bellantoni G., Agostinelli A., Rizzo S., Vinci R.

Department of Dentistry, IRCCS San Raffaele Hospital, Milan, Italy; Dental School, Vita-Salute San Raffaele University, Milan, Italy

Oral Surgery Postgraduate School, Department of Dentistry, Vita-Salute San Raffaele University, IRCCS San Raffaele Hospital, Milan, Italy

**Aim:** to evaluate the accuracy of implant placement by using the surgical guide, the navigation system or a freehand method. Aided implantology is based on a study of the case with a 3D software that reproduce the anatomy of hard and soft tissues. This method virtually guides the operator during implant placement and allows to minimize the possibility of anatomic complications.

**Methods:** 15 studies included case reports, *in-vitro* studies, prospective and retrospective studies and literature review. All the articles considered were searched using the following keywords: "dynamic navigation" AND "dental implants". They were published from 2015 to 2020 on scientific sites such as PubMed and MEDLINE.

**Results:** there is no statistically significant difference between implant surgery with a dynamic navigation and implant surgery

with the traditional method. Dynamic navigation is a technique that significantly improves the accuracy of the novice practitioner. Through dental navigation system, dental students can be introduced to dental implant surgery earlier.

Dental navigation system during implants placement represents a valid support for operators without experience and assists the dentists to achieve a significative level of accuracy without being affected by their own experience.

**Conclusion:** accuracy of computer-aided implant placement is more predictable than a freehand technique in operators without experience. This literature review suggests that computer-aided implantology does not reduce the effectiveness of the treatment and may even improve it in some cases. However, there are no articles totally in favour of one technique over the other.

## ADVANTAGES OF ERBIUM: YAG LASER IN OSTEOTOMY OF JAWS: AN OVERVIEW OF THE LITERATURE

Ferrari L., Pezzi M.E., Vescovi P., Meleti M.

University Center of Dentistry, Department of Medicine and Surgery, University of Parma, Parma, Italy

**Aim:** laser is one of the most used device for bone surgery. Here we present a critical overview of the relevant literature on the advantages of Erbium:YAG (Er:YAG) laser in osteotomy of jawbones with respect to other devices. Particularly, we focused on reduction of thermal damages, absence of temperature increasing and a better post-operative course.

**Methods:** we searched the Medline database, using 7 entry terms. Only studies published after 2010 and in English were included. Either studies on humans and on animal models were selected. We excluded studies performed in sites different from the oral cavity, on mucosal surgery and analyzing preparation of implant site. Review articles were not considered. Selected studies were classified into groups: Group A: studies evaluating osteotomy performed with Er:YAG laser only; Group B: studies comparing Er:YAG to other lasers; Group C: studies comparing Er:YAG laser to piezoelectric devices; Group D: studies comparing Er:YAG laser to surgical bur.

**Results:** seven studies met the inclusion and exclusion criteria. All studies in group A reported absence (using irrigation), or minimal (not using irrigation) thermal damage. The study of group B highlighted a slightly increased temperature and thermal damage in osteotomies performed with Er:YAG laser respect to those performed with picosecond infrared laser. The study in group C reported no differences between Er:YAG laser and piezoelectric device. In group D results were controversial: 1 article highlighted better results for laser and 1 for bur. Two out of 9 studies reported data on wound healing: results varied on the methodic used.

**Conclusion:** there is evidence that osteotomies performed with Er:YAG laser have minimal thermal damage, particularly when using irrigation. However, there are still controversies on the better performance of Er:YAG laser compared to conventional burs.

## AUTOTRANSPLANTATION OF MATURE APEX TOOTH WITHOUT ENDODONTIC TREATMENT: A CASE REPORT

Fornarelli G., Seliman E., Salerno C., Tagliatesta L.

Oral and Maxillofacial Department, University of Milan, Milan, Italy

**Aim:** in literature there are only two papers that avoid endodontic treatment of autotransplanted teeth with mature apex. Our work aims to evaluate this approach in a young patient.

**Methods:** in a 23-year-old patient with a decay of a second molar (4.7) that was no longer treatable have been checked: the presence of a healthy mandibular third molar (4.8) with mature apex, the absence of antagonist tooth contact, the young age of the patient and the absence of alternative treatments due to economic reasons. Then it was suggested the third molar (4.8) autotransplantation in 4.7 site. Element 4.7 was extracted atraumatically to preserve the walls of the alveolar socket, while the third molar (4.8), was extracted taking care not to damage the periodontal ligament and fitted carefully in the

socket prepared with a piezoelectric device. It was stabilized by sutures and composite splint.

**Results:** a one-week follow-up showed a great healing of soft tissues, then during a one-month follow-up dental pulp vitality test was performed: the tooth was responsive. After six months the wisdom tooth didn't show any pathological features in agreement with radiological exams: it suffered neither from tooth mobility nor from periodontal injuries.

**Conclusion:** this case presentation casts doubts upon performing immediate root canal treatment after transplantation of teeth, even with seemingly closed apices. Follow-up of transplanted tooth and initiation of root canal therapy only when pathological signs occur might be a sensible alternative to routine endodontic treatment.

## CLINICAL APPLICATION OF 3D STEREO LITHOGRAPHIC MODEL FOR THIRD MOLAR AUTOTRANSPLANTATION

Fornarelli G., Seliman E., Salerno C., Tagliatesta L.

Oral and Maxillofacial Department, University of Milan, Milan, Italy

**Aim:** the maintenance of vitality of periodontal ligament cells in the donor tooth is the most important factor for the success of autotransplantation: it is necessary to minimize the extra-alveolar time and to avoid multiple fitting attempts. These complications can be overcome using a 3D model of the donor tooth for planning and preparing an artificial socket.

**Methods:** a 22-years-old man with a decayed first molar (2.6) no longer treatable presented a healthy maxillary third molar (2.8) and the absence of antagonist tooth contact. It was then suggested the 2.8 autotransplantation. A CBCT was used to measure tooth dimension and to plan an artificial socket, as well as to create a stereolithographic model of the donor tooth using a CAD/CAM sy-

stem. Then the 3D guide tooth was fitted in the socket, prepared with a piezoelectric device, to evaluate its correct dimension. The tooth was finally stabilized in the socket by sutures.

**Results:** after 2 months vitality test was performed: the tooth was responsive. 5 months later it didn't show any pathological features: it suffered neither from tooth mobility nor from periodontal injuries.

**Conclusion:** this technique aims to minimize the extra-alveolar time of the tooth and to assure a correct socket preparation before the replantation. In conclusion, it may significantly simplify the autotransplantation procedure and contributes to increase the long-term success by shortening the time needed to fit the donor tooth and by reducing the trauma of the PDL.

## DEMINERALIZED *VERSUS* MINERALIZED TOOTH MATRIX IN BONE REGENERATION: A REVIEW

Inchingolo A.D.<sup>1</sup>, Hazballa D.<sup>1</sup>, Patano A.<sup>1</sup>, Laudadio C.<sup>1</sup>, Malcangi G.<sup>1</sup>, Colocchia G.<sup>1</sup>, Grazia Marinelli G.<sup>1</sup>, Limongelli L.<sup>1</sup>, Montenegro V.<sup>1</sup>, D'Oria M.T.<sup>1</sup>, Corsalini M.<sup>1</sup>, Dipalma G.<sup>1</sup>, Inchingolo F.<sup>1</sup>, Di Venere D.<sup>1</sup>, Cardarelli F.<sup>1</sup>, Farronato M.<sup>2</sup>, Tartaglia G.<sup>2</sup>

Complex Operative Unit of Odontostomatology, Director: Prof. G. Favia

<sup>1</sup>Specialization School in Orthognatodontics, Interdisciplinary Department of Medicine D.I.M. University of Bari Aldo Moro, Bari, Italy

<sup>2</sup>Department of Biomedical, Surgical and Dental Sciences, School of Dentistry, University of Milan. UOC Maxillo-Facial Surgery and Dentistry. Fondazione IRCCS Ca' Granda, Ospedale Maggiore Policlinico, Milan, Italy

**Aim:** the aim of this review is to discuss the use of tooth matrix in bone regeneration and a comparison of the properties this material offers when it is used demineralized versus mineralized. This material serves as a perfect scaffold because of its composition when 65% is the inorganic part, hydroxyapatite which is similar to that of bone. The organic part 35% consist mainly of type 1 collagen and non-collagenic proteins such as growth factors (BMPs). When tooth matrix is treated correctly BMPs offers osteoinductive properties to this material. BMPs have a strong osteoinductive potential, but used alone are very soluble and lose their properties. The combination of BMPs with biomaterials serves as a carrier for them.

**Methods:** a Boolean search was conducted by PubMed/Medline, Google scholar and Web of science to review the results based on the current scientific literature.

**Results:** some authors declare that mineralized tooth matrix takes longer time to re-absorb and fails to trigger the new bone regeneration instead the demineralization process can also lead to the complete destruction of dentinal tubules and a low osteogenic potential because eliminate the proteins. When dental matrix is partially demineralized has a greater regeneration potential. Partially demineralization process does not eliminate BMPs and collagen. In fact, the demineralized surfaces are the most adherent for osteoblasts and also decalcification serves to make the dentin matrix more accessible to collagenolytic enzymes.

**Conclusion:** from the physio-chemical side, the tooth matrix can be considered a material comparable to bone but with a higher mineralization. A total demineralization as well as a mineralized tooth matrix did not produce good results in bone regeneration. Partially demineralized dentine is a promising way to use tooth graft in bone regeneration.

## CORRELATION BETWEEN MANDIBULAR LINGULA POSITION AND SOME ANATOMICAL LANDMARKS IN CBCT

Landini J., Sassi A.N., Olivieri G., Vigorelli P., Lupi S.M.

Department of Clinical Surgical, Diagnostic and Pediatric Sciences, University of Pavia, Pavia, Italy

**Aim:** absence of appropriate bony landmarks and anatomical differences are a reason for failure of IAN (inferior alveolar nerve) block anesthesia. The aim of the present study is to assess the precise location of lingula in CBCT and to correlate this position to some anatomical measurement.

**Methods:** the location of the lingula was determined by distances from the lingular tip to the occlusal plane, the anterior and posterior borders of the mandibular ramus, the lower border of mandible, the distal surface of the mandibular second molar, the mandibular notch. We evaluated the antero-posterior diameter of the mandibular ramus, the vertical distance between condyle and mandibular angle, the mesial-distal diameter of the first, second and third mandibular molar, the intercanine distance, the

intermolar distance between the first, second and third mandibular molars, the distance between the intermolar line of first molars and midline and the length of the mandibular body.

**Results:** 200 hemi-mandibular CBCT model of 111 patients (43 male and 68 female patients; 12 to 88 years old) were evaluated. The results allowed us to localize the Spix's spine in relation to the anatomical structures considered. Some parameters are significantly correlated with the anatomical measurements taken into consideration.

**Conclusion:** this study provides new informations to the literature concerning the location of the lingula in an Italian population. Those findings may offer a valuable guideline for IAN block and could improve the success rate of mandibular blocks.

## DEXAMETHASONE INJECTION IN SURGERY OF LOWER THIRD MOLARS: A RETROSPECTIVE CLINICAL STUDY

Lenhardt M., Bevilacqua L., Porrelli D., Vasselli M., Maglione M.

Clinical Department of Medical Science, Surgery and Health, University of Trieste, Trieste, Italy

**Aim:** the aim of this study is to evaluate the efficacy of two different dosages of dexamethasone, i.e. 2 and 4 mg injected submucosally to reduce postoperative discomfort after mandibular third molar surgery.

**Methods:** the study was conducted on 150 patients subjected to surgical removal of an impacted third molar. Patients were randomly divided into three groups: G1 (n = 50) received 4 mg/1 ml dexamethasone submucosally; G2 (n = 50) received 2 mg/0,5 ml dexamethasone submucosally; G3 (n = 50) received saline submucosally. The drug was administered after wound closure through silk sutures. Pain, swelling, trismus, analgesic consumption and operation time were comparatively evaluated at

three different time point:  $T_0$  before surgery,  $T_1$  on 3<sup>rd</sup> and  $T_2$  on 7<sup>th</sup> day after surgery. The sutures were removed on the 7<sup>th</sup> day.

**Results:** G2 showed statistically significant reduction in swelling considering male gender. The differences between the time points where statistically significant in G2 under 25 years old when trismus was analyzed. Difference between G2 and G3 was statistically significant at  $T_1$  when compared in painkillers assumption.

**Conclusion:** it can be concluded that better post-operative values were obtained with 2 mg dexamethasone infiltration in order to reduce trismus in subjects under 25 years old. The statistical analysis showed positive effects in female patients with 4 mg dose of dexamethasone in the aperture evaluation and oedema.

## AN UNUSUAL CASE OF MANDIBULAR RADIOLUCENCY IN A YOUNG PATIENT

Lusardi S., Ruggeri K., Antonelli R., Manfredi M., Vescovi P., Meleti M.

University Center of Dentistry, Department of Medicine and Surgery, University of Parma, Parma, Italy

**Aim:** solitary bone cyst is a rare benign lesion which affects young people. It is generally asymptomatic and localized in the mandibular area. It has been hypothesized that its formation follows a traumatic event leading to intrabony bleeding. Here we report a case of an unusual mandibular radiolucency in a young patient, eventually diagnosed as a solitary bone cyst.

**Methods:** a 14-year-old female, was referred to the Department of Oral Surgery and Medicine of the University of Parma, for a radiolucent round lesion of about 1 cm with slightly irregular, well defined margins between the roots of 35 and 36, casually discovered on orthopantomography. At clinical examination there was no evidence of carious lesions, inflammation and infections. No swelling could be appreciated on palpation and the patient did not refer symptoms. CT scans showed the presence of well-defined cavity with some kind of microcystic spaces on the borders. Cortical bone was well preserved.

Clinical and radiographical appearances were suggestive for non-inflammatory cystic lesion (e.g. lateral periodontal cyst) or odontogenic tumour.

**Results:** surgery, included the execution of a mucoperiosteal, paramarginal flap followed by osteotomy on the vestibular side. No cystic wall was evident and fragments of fat-like material were collected after a curettage. The histological examination disclosed the presence of fragments of fibrous tissue incorporating pre-existing bone fragments with a significant typical histocyte component. A definitive diagnosis of solitary bone cyst was rendered.

**Conclusion:** solitary bone cyst is a rare lesion which should be taken into consideration when an asymptomatic radiolucency is highlighted in the jawbones of young patients. Differential diagnosis may include lateral periodontal cyst and odontogenic tumours. Explorative surgery and curettage of the cavity is usually curative.

## GROWTH FACTORS: INDICATIONS AND FIELDS OF APPLICATION

Mastroieni R.<sup>1</sup>, Fiorillo L.<sup>1,2</sup>, Gorassini F.<sup>1</sup>, Gambino D.<sup>1</sup>, Scoglio C.<sup>1</sup>, Russo D.<sup>2</sup>, D'Amico C.<sup>1</sup>, Cervino G.<sup>1</sup>, Cicciù M.<sup>1</sup>

<sup>1</sup>Department of Biomedical and Dental Sciences, Morphological and Functional Images, School of Dentistry, University of Messina, General Hospital G. Martino, Messina, Italy

<sup>2</sup>Multidisciplinary Department of Medical-Surgical and Odontostomatological Specialties, University of Campania Luigi Vanvitelli, Caserta, Italy

**Aim:** the main function of growth factors is the external control of the cell cycle. The present investigation is aimed at systematically analyzing recent literature about the innovative scaffold involved in the reconstructive surgeries by applying growth factors and tissue engineering.

**Methods:** an extensive review of the contemporary literature was conducted according to the PRISMA guidelines. Authors performed the manuscript research published from 2003 to 2020. The keywords used are as follows: “guided bone regeneration” and “growth factors”.

A total of 19 relevant studies with significant results about correlation between scaffold, molecular features of growth factors and reconstructive surgeries in oral maxillofacial district were included in the present review.

**Results:** the techniques currently in use involve the use of different materials like the group of fibroblast growth factor (FGF). As regards to the use in tissue engineering of the periodontium, FGF-2 seems to have a control activity on the differentiation of the cells of the periodontal ligament and, at the same time, stimulates cell proliferation. To date, technology has made it possible, by following the principles of PRP, to obtain concentrates such as CGF (concentrated growth factors), a valid aid in speeding up the processes of bone and soft-tissue regeneration.

**Conclusion:** growth factors can improve surgical outcomes, related to the operating field (improved height and bone thickness) compared to conventional techniques (without the use of growth factors) and the patient's systemic field (improving the quality of life, postoperative phases and self-reported measures by the patient).

## AUTOTRANSPLANTATION OF WISDOM TOOTH TO FIRST MOLAR: A CASE REPORT WITH 3-YEARS FOLLOW-UP

Oliveira A., Gaglione T., Seliman E., Vimercati I., Barbera E., Fornarelli G., Tagliatesta L.

Department of Biomedical, Surgical and Dental Sciences, University of Milan, Milan, Italy

**Aim:** this case report describes the management of the dental transplantation surgical technique.

**Methods:** a 18-years-old patient come for the treatment of her left first mandibular molar involved in decay process.

Periapical X-ray and ortopantomograhya evaluation showed an immature left mandibular third molar, suitable as donor tooth.

It was extracted in an atraumatic way, the intralveolar septum was modified with a piezoelectric device, the tooth was slightly depressible in the socket and remained in infraocclusion, stabilized by sutures and a metallic splint.

Then, the autotransplanted molar was fixed with a double splinting for 4 weeks.

Finally the autotransplantation was followed by endodontic treatment.

**Results:** six months later, on radiographic examination the tooth showed a radial contour similar to any other tooth; the periodontal line spacing and the bundle bone were well represented. The tooth didn't show pathological features at 12, 18, 24 and 36 months follow-up.

**Conclusion:** within the lack of studies related to this technique, autotransplantation seems to be a reliable alternative to dental implant placement for partially edentulous patients. When case selection and surgical procedures are properly performed, a survival rate of over 90% is described.

## POST-EXTRACTIVE SOCKET WITH EPITHELIAL-CONNECTIVE TISSUE GRAFT: A 3 MONTHS HEALING STUDY

Olivieri G., Todaro C., Torchia M., Lupi S.M.

Department of Clinical Surgical, Diagnostic and Pediatric Sciences, University of Pavia, Pavia, Italy

**Aim:** to evaluate the efficacy of healing, of a preservation technique for the post-extractive socket bone healing using an epithelial-connective tissue graft harvested from the palate. By the use of this technique we expect to get a better socket anatomy in order to position an implant in a second time.

**Methods:** 25 patients, requiring a single tooth extraction, were selected to enter the study and were randomly divided in two groups. In the first group, the socket healed spontaneously. In the second group, an epithelial-connective tissue graft harvested from the palate was sutured over the post-extractive socket. After surgery, an anti-inflammatory drug was prescribed to all patients. Patients were asked to return for a follow up immediately after the first surgery and after three months for implant positioning proce-

dures. At the implant surgery, a tissue sample was collected from the healed socket.

**Results:** at the third month after tooth extraction, in all cases the soft tissue appeared clinically healed, both in the tooth site and in the donor site, and the bone healed uneventfully. Implants obtained a good primary stability and they showed a physiological osteointegration during the follow up. Histological analysis of the bone samples revealed the presence of both woven and lamellar bone.

**Conclusion:** this technique demonstrates hopefully results aiming at the preservation of the post-extractive socket. Future studies should be run to understand more deeply the biological impact of this technique.

## ALL-ON FOUR REHABILITATIONS IN HIV+ PATIENTS: A THREE YEARS' FOLLOW-UP

Palmacci M., De Palma F., Ferraro C., Sertori F., Capelli O., Nagni M.

Department of Dentistry, IRCCS San Raffaele Hospital, Milan, Italy; Dental School, Vita-Salute San Raffaele University, Milan, Italy

**Aim:** this study was carried out to evaluate the expectation of implant-prosthetic rehabilitations in HIV+ patients under antiviral treatment, evaluating the marginal bone level change (MBLC) and the survival in relation to the implant surface and clinical parameters.

**Methods:** full-arch rehabilitations (according to All-on4 protocol) were performed on patients with controlled disease and an antiviral treatment. The implant surfaces were of two types: a group of implants with a greater surface roughness (micro-rough surface-MRS) and the other one with a reduced surface roughness (Full Contact Covering Surface-FCC). The survivals and the MBLC, analyzed over 36 months, were related to serological parameters such as CD4/CD8 ratio and HIV-RNA.

**Results:** implants were placed in 24 patients and the overall number of fixtures was 31 All-on4 (124 fixtures). After three ye-

ars of follow up, the rehabilitations showed a high survival rate (94.3%). The success rate for MRS implants was 84%, while for FCC implants the success rate was significantly higher (97.3%). Mean MBLC measured at T3 was 0.78 mm for FCC implant surface and 0.69 mm for MRS implant surface. Implant failures occurred in 5 patients (15 fixtures out of 124: 12%) due to primary infection (7 fixtures out of 124: 5.6%), fractures (2 fixtures out of 124: 1.6%) and periimplantitis (6 fixtures out of 124: 4.8%).

**Conclusion:** this study demonstrates that the All-on4 protocol turns out to be a predictable treatment with a high success rate and showed how the amount of MBLC is closely related to markers such as the HIV-RNA and the CD4 / CD8 ratio. Furthermore, FCC implant surfaces showed a reduced tendency to fail.

## ALVEOLAR RIDGE PRESERVATION EFFECTS ON BONE DENSITY: A SYSTEMATIC REVIEW AND META-ANALYSIS

Pettinari G., Conti R., Grieco M., Sani S., Andriuolo G., Tonelli P.

Department of Oral Surgery, University of Florence, Florence, Italy

**Aim:** this systematic review aims to analyze the available evidence on the effect of various alveolar ridge preservation (ARP) techniques as compared with spontaneous socket healing to understand whether these procedures can positively influence the bone density within the extraction socket.

**Methods:** an electronic and hand search directed at identifying relevant literature according to the PICOS method was conducted. The MEDLINE and the EMBASE databases were searched up starting from 2009. Only randomized clinical trials (RCTs) controlled clinical trials (CCTs) and prospective cohort studies that met the eligibility criteria were selected. The overall risk of bias was assessed for each included study. Bone density differences, measured in Hounsfield Unit values derived from cone-beam CT, were extracted to perform quantitative analysis.

**Results:** the initial search identified 133 papers. After the removal of duplicates and the screening process, 41 articles

were selected for the full-text evaluation, and 7 studies were included in the final selection (3 RCTs and 4 CCTs). Nine different ARP techniques were detected: (1) demineralized bone matrix + collagen membrane (CM), (2) hydroxyapatite bone substitute + CM, (3) beta-tricalcium phosphate, (4) autologous blood-derived products, (5) allogeneic dental material, (6) allogeneic bone graft, (7) deproteinized bovine bone, (8) synthetic bone with hydroxyapatite and silicon dioxide and (9) CM alone. Cone-beam CT acquisitions were performed after a 4 to 6 months healing period. The results of the random effect meta-analysis revealed an overall effect of 0,115 (95% CI = -0,694 - 0,924;  $I^2 = 90,9\%$ ). No statistical difference was found ( $p = 0,78$ ).

**Conclusion:** according to the selected papers, no differences in bone density become evident when alveolar ridge preservation procedures are compared to spontaneous socket healing.

## CONSERVATIVE SURGICAL APPROACH FOR THE REMOVAL OF AN ORAL LIPOMA OF THE GENIAN REGION

Pingitore G., Carrieri M., Serafini G., Mazzucchi G., Lollobrigida M., De Biase A.

Department of Oral and Maxillofacial Sciences, Sapienza University of Rome, Rome, Italy

**Aim:** oral lipoma is a benign neoplasm of connective tissue, rarely found in the oral cavity (1-4%). Given its non-invasive nature and low recurrence rate, conservative surgical treatment is the first treatment option. Oral lipoma mainly affects male patients and is more often found in the buccal mucosa, which has abundant adipose tissue due to the presence of the buccal fat pad (also called Bichat's fat pad). The purpose of the present case report is to describe the technique used to remove an oral lipoma in the genian region treated with a conservative surgical approach.

**Methods:** a patient of 69 years-old was referred to the UOC of Oral Surgery due to the presence of a neoformation in the oral cavity. The patient reported to have noticed the presence of the lesion since 4 years and that it has grown during the last months. On physical examination a swelling of 2 cm was observed in the right genian region with normal lining mucosa, no pain on palpation and soft-elastic consistency. Linear incision was made in the mucosa covering the neoformation using a monopolar electro-

surgical unit. A careful blunt dissection was then performed to separate the lining mucosa from the neoplasm capsule until the entire neoformation was excised. The sample collected was placed in a fixative solution and sent for histological examination. Sutures were placed to obtain primary wound closure. No antibiotics were prescribed.

**Results:** the pathologist report described a neoformation rich in mature dipocytes immersed in a fibrocellular connective stroma, compatible with the diagnosis of lipoma.

**Conclusion:** although it is a rare neoformation in the oral cavity, a conservative surgical approach has been shown to be effective on the treatment of the oral lipoma. With careful dissection, it was possible to completely excise the lesion without damaging the integrity of the fibrous capsule present. Given the nature of this neoformation and the low recurrence rate, a more invasive approach is not justified. However, follow-up is recommended to detect possible recurrence early.

## MANAGEMENT OF D-PTFE MEMBRANE EXPOSURE IN VERTICAL RIDGE AUGMENTATION USING L-PRF MEMBRANE

Pingitore G., Carrieri M., Serafini G., Mazzucchi G., Lollobrigida M., De Biase A.

Department of Oral and Maxillofacial Sciences, Sapienza University of Rome, Rome, Italy

**Aim:** membrane exposure is one possible complication that can occur after Guided Bone Regeneration (GBR) procedures. D-PTFE membranes have microporous < 1 µm therefore, even in case of exposure, its removal is not always necessary if the patient can maintain proper hygiene of the exposed surface. The purpose of the present case report is to describe the management with L-PRF of a case of membrane exposure after a GBR technique.

**Methods:** a patient of 46 years-old was referred to the UOC of Oral Surgery needing an implant supported rehabilitation of the mandibular left molar region. Considering a mild vertical bone deficiency, a GBR was performed with heterologous bone and reinforced d-PTFE membrane and three implants were placed. After 30 days membrane exposure was noted. It was decided not to remove the membrane prescribing local antiseptics (0.2% chlorhexidi-

ne). At 90 days, the d-PTFE membrane was removed and L-PRF membranes in triple layer, obtained by blood centrifugation, were placed above the underlying tissue and sutured.

**Results:** sutures were removed after 7 days. The patient reported no discomfort in the postoperative period and the healing process continued without complications. After complete tissue maturation, it was possible to proceed with the prosthetic phase. At the 5-years follow up, it was noted the stability of the soft tissue. In periapical RX it was possible to note a slight bone resorption at the distal implant. A debridement session was therefore scheduled.

**Conclusion:** membrane exposure is a possible complication of GBR techniques. The use of L-PRF membranes can be useful to minimize the risk of infection of the regenerative site after the membrane removal and during secondary intention wound healing.

## CORTICOTOMIES TO ACCELERATE ORTHODONTIC MOVEMENT IN LATE ADOLESCENTS

Pingitore G., Carrieri M., Serafini G., Mazzucchi G., Lollobrigida M., De Biase A.

Department of Oral and Maxillofacial Sciences, Sapienza University of Rome, Rome, Italy

**Aim:** given the growing number of patients asking for orthodontic treatment, techniques have been developed over the years to offer more aesthetic and faster therapies in this group of patients. In this context, corticotomies offer the opportunity to accelerate the orthodontic movements especially in oral-buccal direction. Corticotomies consist in bone incisions made at the level of the alveolar process, with or without mucosal flap elevation.

By exploiting the regional acceleratory phenomenon (RAP), it is then possible to obtain faster, more effective and efficient orthodontic movements. The purpose of this presentation is to describe the operative steps of corticotomies from a surgical perspective.

**Methods:** a late adolescent with bilateral posterior crossbite was referred to the UOC of Oral Surgery of Policlinico Umberto I to perform corticotomies before proceeding with orthodontic treatment. The surgery was performed 2 weeks after the oral hygiene session, with FMPS and FMBS values < 25%.

After local anesthesia, a full-thickness flap was elevated and linear 1.5 mm-deep incisions were made in the cortical bone using a piezoelectric device (Piezosurgery, Mectron, Carasco, Italy), on the buccal side of the upper arch. Vertical incisions were made at the interdental level, horizontal in the apical region and oblique incisions at the cervical level. Finally, the flap was sutured and, in the same session, the orthodontic therapy was started.

**Results:** sutures were removed after 7 days. The patient reported no discomfort in the postoperative period. It was possible to proceed with the orthodontic therapy with reduced side effects at the level of the periodontium of the involved teeth.

**Conclusion:** this orthodontic-surgical approach has proved effective and predictable in the treatment of a late adolescent, satisfying the expectations and needs of the patient. Variants of the reported technique have also been proposed without a surgical flap and using surgical guides.

## DIGITAL WORKFLOW IN EDENTULOUS AND ATROPHIC QUADRANT REHABILITATION

Poscolere A., De Santis D., Albanese M., Causarano G., Luciano U., Magi M., Modena N., Zarantonello M., Nocini P.F.

Section of Oral and Maxillofacial Surgery, Department of Surgical Sciences, Dentistry, Gynecology and Pediatrics, University of Verona, Verona, Italy

**Aim:** to investigate the reliability and the possibility of using a digital workflow in the rehabilitation of an atrophic ridge by combining custom made GBR techniques and implant placement using a Dynamic computer-aided implant surgery (d-CAIS) system.

**Methods:** a customized titanium mesh (YXOSS CBR, Re-Oss) is obtained from the CBCT performed after the removal of a large cystic lesion. The mesh, filled with a mixture of 50% autologous bone and 50% heterologous bone (Bio-Oss, Geistlich) is positioned and covered with a collagen membrane and mucoperiosteal flap. After 9 months, the mesh is removed and a control CBCT is performed. This CBCT is imported together with the digital diagnostic wax-up into a software (DTX Studio Implant, Nobel Biocare) where

the placement of 2 implants is planned. The planning is then exported to a d-CAIS system (X-Guide, X-Nav Technologies) with which the implants are positioned without a surgical template. After osteointegration, the prosthetic procedures were started.

**Results:** the use of a customized titanium mesh, pre-shaped on the bone volumes of the CBCT, allowed to reduce intraoperative times and to obtain an adequate bone volume while the use of a d-CAIS system allowed the insertion of the implants in a correct prosthetic position, previously determined and to manage the soft tissues without affecting the accuracy.

**Conclusion:** the use of digital technologies in the pre-surgical and intraoperative phases allow to optimize the rehabilitation results in atrophic sites.

## APICECTOMY WITH SUPEREBA IN TEETH ORTHODONTICALLY TREATED: A CASE REPORT

Saladino T., Ferraro C., Todaro M., Cusenza I., Tocchio A., Vinci R.

Oral Surgery Postgraduate School, Department of Dentistry, Vita-Salute San Raffaele University, IRCCS San Raffaele Hospital, Milan, Italy

**Aim:** the purpose of this study is to analyze a case of a traumatized teeth to evaluate the efficacy of apicectomy techniques in patients with periradicular lesions.

**Methods:** the clinical case presented is related to a young boy, who came to the attention of the Department of Odontostomatologic Surgery of the Dental Clinic, presenting clinical evidence of a fistula and radiographic evidence of periradicular lesion on the 1.1. The patient referred a trauma in that element. An endodontic access and medication with Calcium hydroxide were performed. The patient was given Amoxicillina + Clavulanic Acid (1g every 12 hours) for 6 days. Analyzing the apex diameter, the element was obturated using the apical plug technique with MTA.

After 3 years, the patient was involved in an orthodontic protocol, using fixed brackets. During the treatment the patient referred pain due to the arising of a fistula. At the periapical Rx was revealed the presence of a radicular reabsorption and a periapical lesion.

Among the possible treatment, apicectomy was selected. A flap was performed using a paramarginal incision between 1.1 and 1.2 zone and a relaxing incision in the distal tooth. The periosteum was dissected and an unicortical osteotomy, performed with piezoelectric handpiece, was shaped around the lesion. Then the lesion was excised and the apical 3mm of the root was removed with abrasion. Then, a retrograde cavity was performed using endosurgical piezoelectric devices; subsequently the cavity was filled using SuperEBA. Then the cavity review was performed, the clot was stabilized with fibrin sponge and the flap was sutured.

**Results:** after two weeks the fistula had disappeared. At 6 months follow up the patient didn't show clinical symptoms of periradicular infection anymore.

**Conclusion:** in case of difficult endodontic treatment or extendend periradicular lesion that can't heal, endodontic surgery could be the best choice, which guarantee right tissue healing and bone regeneration.

## ASSESSMENT OF THE BEHAVIOR OF DENTAL PULP STEM CELLS CULTURED ON PEEK AND TITANIUM SAMPLES

Ulian N., Porrelli D., Turco G., Bevilacqua L., Maglione M.

Department of Medicine, Surgery and Health Sciences, University of Trieste, Trieste, Italy

**Aim:** the following work assessed the behavior of human Dental Pulp Stem Cells (hDPSC) on PEEK and Titanium samples, in particular their ability to adhere, proliferate and differentiate into osteoblasts.

**Methods:** surface modifications were made to the samples by pre-established protocols of sandblasting and laser micropatterning, to modulate surface roughness. After roughening treatments, samples were divided into two groups: nontreated and treated with air-plasma cleaning process to modulate surface wettability. The hDPSCs were harvested from dental elements and, after expansion in the proper medium, were seeded on the samples to study their behavior. The analyses for the adhesion and the proliferation were performed by Scanning Electron Microscopy and Alamar Blue test, while the diffe-

rentiation in osteoblasts was evaluated by measuring AlkalinePhosphatase activity.

**Results:** all the samples tested are able to support hDPSCs adhesion, proliferation and differentiation in osteoblasts with differences depending on the material nature and surface. Laser micropatterned titanium samples, in particular, were the best performing in terms of cell differentiation.

Air-plasma treatment does not affect cell adhesion and proliferation but improves cell differentiation, in particular on Titanium samples.

**Conclusion:** PEEK and Titanium are confirmed as excellent materials to support the adhesion, the proliferation and the differentiation of the hDPSCs. The biological behavior is strongly dependent on material nature, roughness and wettability.

## CGF TO PROMOTE THE HEALING OF THE POST EXTRACTION SOCKET: A CASE REPORT IN AESTHETIC AREA

Morandi B.<sup>1,2</sup>, Corbella S.<sup>1,2,3</sup>, Vitelli C.<sup>1,2</sup>, Vimercati I.<sup>1,2</sup>, Taschieri S.<sup>1,2,3</sup>

<sup>1</sup>Department of Biomedical, Surgical and Dental Sciences, University of Milan, Milan, Italy

<sup>2</sup>IRCCS Galeazzi Orthopedic Institute, Milan, Italy

<sup>3</sup>Department of Oral Surgery, Institute of Dentistry, I.M Sechenov First Moscow State Medical University, Moscow, Russia

**Aim:** this case report aims to show the use of CGF (Concentrate Growth Factor) in socket preservation to promote the healing of the post extraction socket.

**Methods:** a 35-years-old female patient comes to IRRCS Istituto Ortopedico Galeazzi (Milano) for the treatment of her left central maxillary incisor (element 11). After clinical and radiographic evaluation we decide that the tooth cannot be saved.

The tooth in the esthetic area must be restored and, in agreement with the patient, we decide to perform the implant positioning after complete wound healing (6 months after extraction). So we operate in order to preserve the greatest possible bone volume. The tooth is extracted without trauma and flap elevation, the socket is curetted and rinsed with sterile saline solution. Immediately before the surgical procedure, CGF is

prepared using 20 mL of the patient's venous blood, centrifuged with Medifuge, Silfradent. After centrifugation we get 3 layers: plasma, fibrin buffy coat (CGF) and red blood cell layer.

The socket is filled with a bovine-derived xenograft (BiOss, Geistlich), mixed with patient's plasma and closed with a collagen membrane (Biogide, Geistlich). CGF is placed over the membrane and a suture is performed to allow secondary intention healing.

**Results:** after 14 days it was possible to observe an excellent healing of the site and mature gingival tissues, without gingival recession. As planned, after 6 months, it was possible to place one implant in the area.

**Conclusion:** the use of CGF membrane led to an improvement in terms of soft tissue healing time and patient's quality of life, especially postoperative pain.

## HISTOPATHOLOGICAL EVALUATION OF SEVERE SARS-COV2-RELATED ORAL LESION: STUDY ON 13 PATIENTS

Barile G.<sup>1</sup>, Acella V.<sup>2</sup>, Ciocia A.<sup>2</sup>, Dell'olio F.<sup>1</sup>, Mezzapesa P.<sup>1</sup>, Ingravallo G.<sup>3</sup>

<sup>1</sup>Specialization School of Oral Surgery, Department of Interdisciplinary Medicine, University of Bari Aldo Moro, Bari, Italy

<sup>2</sup>Department of Interdisciplinary Medicine, University of Bari Aldo Moro, Bari, Italy

<sup>3</sup>Pathological Anatomy Unit, Department of Emergency and Organ Transplantation, University of Bari, Bari, Italy

**Aim:** Sars-Cov-2 pathogenetic mechanism may be the binding of viral Spike protein to angiotensin-converting enzyme 2 (ACE-2) receptor which is ubiquitous and may cause a multiorgan involvement and multiorgan failure in severe cases. Moreover, activation of proinflammatory responses as cytokine, complement system, pro-coagulation dysfunction, and infiltration of inflammatory cells in Sars-Cov-2 infection can form microthrombi worsening the prognosis. Aim of this study is histopathological evaluation of ulcerative lesion appeared during Sars-Cov-2 infection.

**Materials:** patients with molecular swab positive to Sars-Cov-2, hospitalized in Emergency and Intensive Care therapy of Policlinic of Bari were evaluated with a clinical visit, after an accurate anamnesis. Excisional biopsy was performed on crater-like and/or aphthoid ulcers, appeared after Sars-Cov-2 infection. Histological samples were fixed in formalin, then embedded in paraffin, sectioned at 4 µm thickness and stained with haematoxylin-eosin.

**Results:** biopsy was performed in 13 patients: 8 males and 5 females, with a mean age of 72 years. Anamnesis was negative for pre-existent lesions and positive for anticoagulant and antibiotic therapy. Histologically, in the central parts of the ulcers were evaluated superficial layer of fibrin-enclosed basophilic debris and microorganisms on connective tissues formed by vascular hyperplasia, perivascular haemorrhage and lymphomonocytes infiltration. Thrombotic occlusion of small and medium size vessels is a frequent feature, especially in small vessels with total occlusion. From a histological point of view of ulcer border: epithelial lesions as oedema, spongiosis, leucocytosis and necrotic keratinocytes occurred.

**Conclusion:** this study showed presence of vascular microthrombi in histological sample of oral lesions during Sars-Cov-2 disease, probably due to multi-organ involvement of pathology. Further studies with larger samples may confirm this hypothesis.

## HOW TO REDUCE POST-EXTRACTIVE BLEEDING RISK IN DOAC AND VKA POPULATION?

Berton F.

Department of Maxillofacial Surgery Stomatology and Odontology, University Hospital "ASUGI" of Trieste, Clinical Department of Medical Sciences, Surgery and Health, University of Trieste, Trieste, Italy

**Aim:** the aim of this clinical study was to evaluate the use of L-PRF as hemostatic agent, evaluating post-operative bleeding events after dental extractions in patients under treatment with Vitamin K Antagonists (VKAs) or Direct Oral Anticoagulants (DOACs).

**Methods:** each enrolled patient underwent a single tooth extraction with a standardized technique. Participants were clustered in four different cohorts (VKA; DOAC; VKA+L-PRF and DOAC+L-PRF) and were evaluated pre-operatively, during surgery, thirty minutes after surgery and seven days after surgery. After extraction in VKA+L-PRF and DOAC+L-PRF groups, a L-PRF plug was positioned in the socket before suturing. Conversely, VKA and DOAC groups received only sutures. Biological complications were registered and post-extraction bleeding was described according to Iwabuchi classification. After checking data normality, statistical analysis has been performed using parametric tests (significance level  $\alpha = 0.05$ ).

**Results:** 242 patients were included in the final analysis: 65 VKA; 65 DOAC; 53 VKA+L-PRF and 59 DOAC+L-PRF. No post-extractive bleeding was recorded in 45 VKA patients (69.2%); 53 DOAC (81.5%); 44 VKA+L-PRF (83%) and 50 DOAC+L-PRF (84.7%). No significant differences were demonstrated in terms of bleeding events between VKA and DOAC groups, with or without the use of L-PRF use (chi-square test:  $p = 0.084$ ). Clinically significant bleeding events (score  $> 2$  according to Iwabuchi classification) were reported as follows: VKA 8 (12.3%); DOAC 5 (7.7%); VKA+L-PRF 2 (3.8%) and DOAC+L-PRF 0 (0%). Only non-PRF cohorts needed pharmacological or surgical interventions for post-extractive bleeding management (2 VKA patients; 1 DOAC).

**Conclusion:** L-PRF could be successfully used as an autogenous hemostatic agent for the prevention of bleeding events after dental extractions.

## IS PREVENTIVE CANAL THERAPY NECESSARY IN TEETH INVOLVED IN RADICULAR CYSTS? A CASE SERIES

Bobba I., Erovigni F., Bosso I., Dell'Acqua A., Carossa S.

Department of Surgical Sciences, Oral Surgery Section, CIR Dental School, University of Turin, Turin, Italy

**Aim:** radicular cysts are inflammatory odontogenic cyst lined by epithelial cells derived from rests of Malassez. Representing 60% of all odontogenic cysts, they are the most common of jaw cystic lesions.

Cyst expansion can interest the apex of adjacent teeth. Clinicians often decide to attend endodontic treatment of these teeth to prevent necrosis after cyst enucleation due to vascular /nervous lesions, but this decision is not supported by literature.

The aim of this study is to describe a case series of three patients who underwent cystectomy in the department of Oral Surgery in Dental School of Turin, from December 2017 to June 2018.

**Methods:** three patients with jaw cystic lesions were selected. Electric pulp test was performed on vital teeth with apex comprised into radicular cyst before surgery, 1 and 2 weeks after surgery and after 3 and 6 months, to point out differences in

pulp vitality responses. The test was repeated three times for each teeth and the mean value of evaluations was recorded.

**Results:** in all patients, responses to electrical stimulus tend to decrease in the first/second week after surgical treatment and to return approximately to the initial values after three/ six months. This trend is supported by literature related to other types of surgery (e. g. Le Fort I): teeth can fail responding to pulp tests right after treatment, due to surgical trauma on blood vessels and nerves, but it is possible to have a restitutio ad integrum after 3-8 months thanks to the formation of a collateral blood stream.

**Conclusion:** this data suggest that a good follow up is more effective than preventive endodontic treatment for an optimal healing. In addition, devitalized teeth undergo a lot of changes if compared with vital ones (e. g. a decrease in strength resistance) and endodontic treatment should be avoided in healthy vital teeth without indications for it.

## IS MARSUPIALIZATION THE OPTIMAL TREATMENT FOR AN ODONTOGENIC KERATOCYST?

Brancaccio Y., Antonelli A., Bennardo F., Buffone C., Vocaturo C., Barone S., Giudice A.

School of Dentistry, Division of Oral Surgery and Pathology, Department of Health Sciences, Magna Graecia University of Catanzaro, Catanzaro, Italy

**Aim:** odontogenic Keratocyst (OKC) represents a benign lesion of the maxillofacial region with a peak incidence of about 11%, affecting mostly the second and the third decades of life. In comparison to other cystic lesions, it is locally aggressive and infiltrative justifying the well-known high recurrence rate, probably due to an incomplete surgical removal. Aim of this study was to demonstrate the efficacy of a conservative surgical approach such as marsupialization on recurrence of OKC and reduction of the cystic cavity volume.

**Methods:** a 67-years-old patient underwent marsupialization of an OAK localized in the right branch of the mandibular arch. A biopsy examination of the lesion was performed to support diagnostic suspicion. In the marsupialization process, iodoform gauze was applied and then replaced weekly, in association with periodic washing of the injured area.

**Results:** after marsupialization, a clinical and radiographic healing was observed, with a significant reduction of the cystic cavity

volume. Clinical healing was confirmed with a second biopsy examination performed 14 months after marsupialization, which revealed the presence of healthy epithelial tissue. Radiographic healing was confirmed by evaluation of both orthopantomography and CT cone pre- and post- marsupialization beam.

**Conclusion:** our study suggests that marsupialization should be considered as the first approach in patients with OKC. Firstly, the moderate invasiveness of this conservative surgical approach led to a significant reduction of the volume of OAK and consequently of the risk of damage to adjacent structures, while preserving removal efficacy.

Second, marsupialization could be performed safely in any age group, although it is more suitable for pediatric and elderly patients. However, it is of fundamental importance that patients closely adhere to follow-up given the high incidence of recurrence.

## EVALUATION OF A NEW PORCINE COLLAGEN MATRIX FOR TREATMENT OF BUCCAL GINGIVAL RECESSIONS

Parma-Benfenati S.<sup>1</sup>, Cardo F.<sup>2</sup>, Quaresima R.<sup>3</sup>, Mastrangelo F.<sup>4</sup>

<sup>1</sup>Private Practice, Ferrara, Italy

<sup>2</sup>Dental student, University of Foggia, Foggia, Italy

<sup>3</sup>Department of Civil Engineering, Architecture and Environment, University of L'Aquila, L'Aquila, Italy

<sup>4</sup>Department of Clinical and Experimental Medicine, University of Foggia, Foggia, Italy

**Aim:** evaluation of the efficacy of a new NovoMatrix RTM porcine collagen matrix in the treatment of maxillary gingival recessions after 6 months of follow-up.

**Methods:** smokers, undergoing radio/chemotherapy patients, and patients in treatment with bisphosphonates were excluded and PD (probing depth) -RD (gingival recession depth) -RW (gingival recession width) -CAL (Clinical attachment level) -KTW (keratinized tissue width) and BL (Buccal bone level from CEJ to bone crest) clinical parameters were recorded. Patient S.B. (age 50yrs-sex F), in good general health with gingival recession depth of 4 mm on tooth 1.4 was selected in University of Foggia and treated in private dental office in Ferrara. The heterologous matrix NovoMatrix RTM was placed in the recession site at the CEJ point and then stabilized with suture techniques. The healing and soft tissue maturation process were monitored and all parameters were recorded at baseline, 3 and 6 months after surgery.

**Results:** baseline the soft tissue evaluation showed: REC 4 mm, RW 4 mm, PD 1 mm, CAL 5 mm, KTW 0 mm.

Significant improvements were found for gingival recession from baseline to 6 months post-operatively in all the parameters analyzed.

After 3 months were found REC 1 mm, RW 3 mm, PD 1 mm, CAL 2 mm, KTW 5 mm and after 6 months REC 1 mm, RW 3 mm, PD 1 mm, CAL 2 mm, KTW 6 mm.

**Conclusion:** further studies with a large number of case reports and a longer follow-up time could be conducted in order to understand the real impact of Novomatrix Heterologous graft materials in maxillary gingival recession.

However, the preliminary data recorded in this preclinical prospective pilot study encouraged novel researches to evaluate and compare Novomatrix with current biomaterials in soft tissue regeneration around teeth and dental implants.

## MANAGEMENT OF INVASIVE DENTAL PROCEDURES IN A PATIENT WITH HEREDITARY ANGIO-EDEMA TYPE I

Cinquini C., Marchio V., Santarelli S., Marianelli A., Nisi M., Barone A.

Department of Surgical, Medical, Molecular Pathology and of the Critical Area, University of Pisa, Pisa, Italy

**Aim:** hereditary angio-edema (HAE) is a rare autosomal dominant disease characterized by a deficiency of C1 esterase inhibitor (C1-INH). Patients with angio-edema have episodic swellings at hands, feet, face, genitals or gastro-intestinal tract, it can be life-threatening when the upper airways are involved. HAE attacks can be triggered by physical or psychological stress or can arise spontaneously; local trauma such as dental treatments and routine oral surgery procedures may increase the risk of HAE attacks within 4 - 48 hours from the intervention. This report describes the management of surgical dental procedures in a patient affected by HAE type I.

**Methods:** a 37-year-old man referred to our clinic because of episodic swellings in the inferior incisive area. The radiographic examination revealed a unilocular radiolucency adjacent to the apical area of mandibular incisors. The suspected diagnosis was periapical cyst and the surgical intervention

planned was the enucleation of the osteolytic lesion and the evaluation of the involved teeth. The patient had a diagnosis of HAE type I, with four episodes per year. His brother, diagnosed for HAE, died at young age for asphyxia after a dental extraction. The patient underwent the surgery with a prophylaxis with C1-INH concentrate. A mucoperiosteal flap was elevated in the central area of the mandible, the cyst was excised and three inferior incisive teeth were extracted due to the extensive bone loss.

**Results:** the patient was hospitalized for 36 hours to be monitored. No occurrence of HAE attack was observed, the patient was provided with an antagonist of Bradykinin B2 receptors to be administered subcutaneously in case of acute attack.

**Conclusion:** the administration of prophylactic C1-INH concentrate had been effective in preventing HAE attacks after surgical dental procedure.

## ENUCLEATION OF A CYSTIC LESION IN A PEDIATRIC PATIENT: A CASE REPORT

Cusenza I., Todaro M., Zizza A., Redi L., Cotticelli C., Vinci R.

Oral Surgery Postgraduate School, Department of Dentistry, Vita-Salute San Raffaele University, IRCCS San Raffaele Hospital, Milan, Italy

**Aim:** the purpose of this study is to present a clinical case about the removal of a cystic lesion with a 7 years follow-up.

**Methods:** a 9-year-old female patient presented to our attention at the Department of Dentistry of the IRCCS San Raffaele. An orthopantomography (OPT) was performed and it showed the presence of an apical osteolytic lesion at the 4.8 included element.

Following a careful preoperative evaluation, it was decided to proceed with the avulsion of element 4.8 and subsequent enucleation of the lesion. After loco-regional anesthesia, an intra-sulcular incision was made from element 4.6 to element 4.7 with preservation of the interproximal papilla. A vertical releasing incision angled at 45° toward the upright mandibular branch was performed to raise a subperiosteal flap. Using piezoelectric instruments, an osteotomy was performed opening a bone hatch leaving the cortical intact to expose the included

element. Subsequently, a dentotomy was performed to extract the element 4.8 and enucleate the lesion at the same time.

After careful revision of the cavity and after inducing bleeding to promote healing of the bony gap, fibrin sponges (spongostan) were placed and sutured with a double stitch distal to the 4.7 in keratinized gingiva and simple stitches on the vertical releasing incision. The papillae were also sutured.

**Results:** radiographic examination at 7 years after surgery shows proper reossification; in fact, a reduction of the radiotransparency is visible where the lesion was present. This is an indication of complete radiographic healing. Healing was also confirmed clinically by careful intraoral objective examination.

**Conclusion:** this study demonstrates that an adequate preoperative evaluation together with a correct surgical procedure can guarantee success in terms of bone remodeling following enucleation of a cystic lesion.

## EXTRACTION OF A SEMI-IMPACTED LOWER MOLAR IN A BRUGADA SYNDROME PATIENT: A CASE REPORT

Dell'Olio F.<sup>1</sup>, Siciliani R.A.<sup>2</sup>, Acella V.<sup>2</sup>, Barile G.<sup>1</sup>, Mezzapesa P.P.<sup>1</sup>, Massaro M.<sup>3</sup>, Lorusso P.<sup>2,3</sup>

<sup>1</sup>Specialization School of Oral Surgery, DIM, Interdisciplinary Department of Medicine, University of Bari Aldo Moro, Bari, Italy

<sup>2</sup>DIM, Interdisciplinary Department of Medicine, University of Bari Aldo Moro, Bari, Italy

<sup>3</sup>Unit of Anesthesiology, DAE, Emergency Department, University of Bari Aldo Moro, Bari, Italy

**Aim:** Brugada syndrome is a ventricular arrhythmic disease causing sudden cardiac death in patients with structurally healthy heart. Oral surgery may be risky in such patients since pain, anxiety, and local anesthetic drugs may trigger arrhythmic storms. The current report shows the multidisciplinary management adopted for the extraction of a semi-impacted lower right third molar in a Brugada syndrome patient referred to the Complex Unit of Odon-tostomatology of Aldo Moro University of Bari, Italy, in 2021.

**Case presentation:** the 38 years old, male patient had negative history for syncope, and no cases of sudden cardiac death in family; diagnosis of Brugada syndrome occurred after observation of spontaneous Brugada Type 1 ECG-pattern later confirmed by flecainide test. The assessment of intra- and post-operative risk of ventricular arrhythmia considered: oral surgical risk factors as patient's dental anxiety measured by Modified Dental

Anxiety Scale (7 points, range 5 – 25 points); anesthesiologic risk measured by American Society of Anesthesiologists Physical Status (III class, range I - VI); cardiologic risk according to hazard ratio stratification, which established intermediate risk (hazard ratio = 2.1) since the patient had spontaneous Brugada Type 1 pattern without syncope. After positioning external biphasic defibrillator pads, 12-leads continuous electrocardiogram, peripheral venous access, the extraction was performed with local anesthesia by lidocaine 2% with epinephrine 1:100000; ibuprofen 600 mg tablets were suggested for post-operative analgesia. No electrocardiographic changes occurred during both surgery and the following 3 hours of monitoring.

**Conclusion:** the current report showed the importance of a pre-operative multidisciplinary risk assessment to approach carefully to oral surgery in a Brugada syndrome patient.

## PATIENTS' SATISFACTION FOR RECEPTIVE MUSIC THERAPY DURING ORAL SURGERY: A CASE SERIES

Dell'Olio F.<sup>1</sup>, Giordano F.<sup>2</sup>, Siciliani R.A.<sup>3</sup>, Mezzapesa P.P.<sup>1</sup>, Barile G.<sup>1</sup>, Massaro M.<sup>4</sup>, Lorusso P.<sup>3,4</sup>

<sup>1</sup>Specialization School of Oral Surgery, DIM, Interdisciplinary Department of Medicine, University of Bari Aldo Moro, Bari, Italy

<sup>2</sup>School of Medicine, University of Bari Aldo Moro, Bari, Italy

<sup>3</sup>DIM, Interdisciplinary Department of Medicine, University of Bari Aldo Moro, Bari, Italy

<sup>4</sup>Unit of Anesthesiology, DAE, Emergency Department, University of Bari Aldo Moro, Bari, Italy

**Aim:** music therapy involves the systematic use of musical experiences to achieve therapeutic goals by a trained music therapist; it also implies the establishment of a relationship between patient, music, and music therapist. Such interventions may be appreciated by patients as intraoperative aid to oral surgery. The aim of the current study is to assess the patients' satisfaction for experiencing a receptive technique of music therapy during oral surgical procedures in local anesthesia.

**Methods:** authors studied consecutive volunteers,  $\geq 18$  years old, with negative history for auditory deficit, psychiatric diseases, and drug abuse, needing for a molar tooth extraction in local anesthesia (duration  $\leq 20$  minutes), between October and December 2020 as observational period. Each patient underwent standard blood tests, electrocardiogram, panoramic radiogram, and music assessment by a certified music therapist who tailored a playlist using an interactive relational

approach of receptive music therapy supplemented by Guided Imagery. During extractions, patients listened to their tailored playlists guided by the music therapist, using headphones (Bose QuietComfort 35II) or audio speakers (Bose SoundLink® Bluetooth® III), with standard volume 70 dB SPL, from iPod®. Authors assessed the patients' satisfaction for such experience using Patient Global Impression of Satisfaction questionnaire.

**Results:** 8 women and 7 men,  $45.57 \pm 16.79$  years old, accepted to join the study. 11 patients chose to listen to music by headphones, and 4 by speakers. According to Patient Global Impression of Satisfaction score, all patients were satisfied by such experience (1 "a little", 8 "much", 6 "very much" satisfied).

**Conclusion:** the current results seem to support intraoperative receptive music therapy as satisfying experience for patients during oral surgical procedures in local anesthesia.

## ODONTOGENIC MYXOMA: A CASE REPORT

Ferraro C., Ferri S., Saladino T., Faben A., Zizza A., Vinci R.

Oral Surgery Postgraduate School, Department of Dentistry, Vita-Salute San Raffaele University, IRCCS San Raffaele Hospital, Milan, Italy

**Aim:** the odontogenic myxoma is a lesion originated by the dental ectomesenchymal tissue. It is a benign odontogenic tumour with infiltrative character. The aim of this case report is to evaluate the healing after the complete excision of the osteolytic lesion.

**Methods:** a 65-year-old patient was referred to the attention of the Department of Odontostomatologic Surgery of the Dentistry Department of Università Vita-Salute San Raffaele. The patient presented mobility to the prosthetic restoration between 4.5 and 4.7, at the pillar elements. An orthopantomography (OPT) was performed which revealed a possible osteolytic lesion. Among the possible surgical treatments related to the osteolytic lesion, the complete excision was chosen. After signing the informed consent and under local anaesthesia, avulsion of elements 45-47 was carried out. Then a flap was performed using papilla preservation technique between 4.5 and 4.7 alveolus and a releasing incision in the

mesial zone. The flap was dissected through a bone-cleavage plane and the lesion was exposed. Subsequently a bone operculum was made using oxyvore. This allowed complete excision of the lesion, which was sent to the Histology and Pathology Department of San Raffaele Hospital for histopathological analysis. The lesion was 4X2 cm in size, soft and multilocular. The surgical site was washed and sutured. The patient was introduced into a maintenance program, considering the high rate of recurrences.

**Results:** histopathological examination confirmed the suspicion of an osteolytic lesion: myxoma. This is a tumour composed of acellular and myxomatous connective tissue, without capsule. At the 2 years follow-up the OPT presented the beginning of the reossification of the area.

**Conclusion:** considering the high rate of recurrences, the patient had to be followed up till 5 year from the surgical treatment, to guarantee the complete healing.

## INJECTABLE-PRF IN THE REDUCTION OF PAIN AND SWELLING AFTER LOWER THIRD MOLAR EXTRACTION

Gargiulo D., Lauro M., Bancale M., Rosiello N., Di Maro P., Esposito G.

Department of Neuroscience, Reproductive and Odontostomatological Sciences, School of Medicine and Surgery, Oral and Reconstructive Surgery Program, Director Prof. G.Sammartino, University of Naples Federico II, Naples, Italy

**Aim:** to clinically evaluate the reduction of complications related to the extraction of the lower impacted third molar, such as pain and swelling following submucosal infiltrations of injectable- platelet rich fibrin (i-PRF).

**Methods:** consecutive patients who needed the mandibular third molar extraction and referred to the Oral Surgery Department of the University of Naples Federico II, were enrolled. After dental extraction, the i-PRF was prepared as follows: 20 ml of venous blood was taken and collected in 2 plastic tubes without any anticoagulants or gelling agents. The tubes were placed in a centrifuge at 700 rpm for 3 minutes, to obtain the most superficial layer of liquid i-PRF. The i-PRF was taken from each tube using a sterile syringe and injected submucosal. Facial swelling was measured with silk thread using four reference points: tragus, pogonion (inferior most

point on the midline of the chin), gonion (angle of the mandible) and the corner of the mouth. It was calculated as the sum of the two diagonals made between these reference points after 3 and 7 days post-surgery. In addition, pain assessment was made by using VAS scale.

**Results:** 12 patients were enrolled in this study. At all the examination days the post-operative recovery was uneventful. Clinical evaluation on the 3<sup>rd</sup> and 7<sup>th</sup> postoperative day showed any reduction in the swelling differences over time while there was a progressively considerable pain decrease in the immediate post-operative.

**Conclusion:** the use of the autologous i-PRF seems to achieve important role to modulate the post-extraction pain of the lower impacted third molar's surgery. However, further studies are needed to confirm these results.

## GUIDED BONE REGENERATION USING OSSIX BONE COLLAGEN MATRIX: A HISTOLOGICAL CASE REPORT

Graziano D.<sup>1</sup>, Abundo R.<sup>2</sup>, Canciani E.<sup>1</sup>, Henin D.<sup>1</sup>, Pellegrini G.<sup>1</sup>, Cristofalo A.<sup>1</sup>, Meroni S.<sup>1</sup>, Dellavia C.<sup>1</sup>

<sup>1</sup>Department of Biomedical, Surgical and Dental Sciences, University of Milan, Milan, Italy

<sup>2</sup>Humanitas University, Rozzano, Milan, Italy

**Aim:** Ossix™ Bone (OB) (Datum Dental, Israel) is a spongy block made of a cross-linked collagen matrix (95%) and hydroxyapatite (5%) which contributes to bone proliferation and vascularization of the defect area to be regenerated, actively stimulating to the ossification process.

The tissue response to OB was tested in a patient needing a post-extraction socket preservation in the posterior mandible.

**Material and Methods:** after 7 months from socket preservation with OB, two biopsies were harvested from 3.6 and 4.6 sites in a 30-years old man. The samples were processed for undecalcified histological analysis by means of sawing and grinding technique. Two sections per specimen were stained with Toluidine Blue and Pyronine Yellow, observed under light-field optical microscope and digitally acquired with a high resolution scanner (Nanozoomer S60, Hamamatsu) for histometric evaluation.

**Results:** the clinical sites healed with a physiological filling of the socket with new bone, thus allowing the insertion of one dental implant per site for further prosthetic rehabilitation. Histologically, the matrix appeared ossifying with numerous osteoblasts lining the margins. No osteoclasts and no Howship's lacunae were visible, thus indicating the predominance of the anabolic phase of the ossification process over the catabolic one. There were no signs of fibrosis, inflammatory infiltrates or of necrotic areas. Newly formed tissue resulted highly mineralized, well-organized and formed by 7,85% ± 8,41 of new lamellar bone, 49,38% ± 18,42 of woven bone, 17,07% ± 6,63 of osteoid matrix, 13,49% ± 0,48 of grafted remnants and 12,22% ± 3,86 of medullary spaces.

**Conclusion:** this case report suggests that regeneration by Ossix™ Bone matrix may occur by direct ossification without remodelling of the biomaterial.

## MONOSTOTIC FIBROUS DYSPLASIA OF THE MAXILLARY SINUS: A CASE REPORT

Marsili F.<sup>1</sup>, Audino E.<sup>1</sup>, Subiaco S.<sup>1</sup>, Orlandi S.<sup>1</sup>, D'Ambrogio R.<sup>1</sup>, Borghesi A.<sup>2</sup>, Salgarello S.<sup>1</sup>

<sup>1</sup>Department of Medical-Surgical Specialties, Radiological Sciences and Public Health Dental School, School of Specialization in Oral Surgery, University of Brescia, Brescia, Italy

<sup>2</sup>Radiological Department, University of Brescia, Brescia, Italy

**Aim:** monostotic fibrous dysplasia is a benign, mass-forming lesion of bone composed of abnormal fibrous and osseous elements in which a single bone is involved. Lesions are discovered as a result of pain, physical deformity, pathologic fracture, or as an incidental finding on radiographic imaging. The aim of this study is to present a case of monostotic fibrous dysplasia of the maxillary sinus.

**Methods:** a 12-year-old boy, otherwise healthy, was referred to our service in 2014 from his dentist because, during the execution of a Cone Beam CT performed due to an orthodontic treatment difficulty of the right upper teeth, the incidental finding of an hyperdense, space-occupying bone lesion in the right maxillary sinus was found. The bone mass involves the maxillary sinus almost in its entirety but the sinus ostium was not obstructed by the mass. The contralateral maxillary sinus was not involved. The patient had no symptoms. The diagnosis was a monostotic fibrous dysplasia of

the maxillary bone. New Cone Beam CT exams were performed in 2015 and 2018 and the mass did not enlarge. The patient continues to have no symptoms other than a very slight eyelid closure on that facial side, not detected by the patient but detected on the medical examination. This symptom has not worsened over time.

**Results:** having had a stabilization of the symptoms and a non-growth of the mass in the radiographic examination, we decided to keep the patient in follow-up and to not intervene surgically.

**Conclusion:** monostotic fibrous dysplasia is a benign, sporadic disease of the bone. Malignant transformation is extremely rare. A long-term clinical and radiographic follow-up is required in patients with a diagnosis of monostotic fibrous dysplasia, even if the lesion is asymptomatic, to find the right moment to evaluate a surgical approach or to maintain the patient in follow-up.

## HISTOLOGICAL AND HISTOMORPHOMETRICAL EVALUATION OF INNOVATIVE BONE GRAFTS TOOTH DERIVED

Natale D.<sup>1</sup>, Minetti E.<sup>2</sup>, Giacometti E.<sup>3</sup>, Gambardella U.<sup>4</sup>, Contessi M.<sup>5</sup>, Ballini A.<sup>6,7</sup>, Marenzi G.<sup>8</sup>, Celko M.<sup>9</sup>, Bulzacchelli D.<sup>10</sup>, Mastrangelo F.<sup>11</sup>

<sup>1</sup>Private Practice, Trani, Italy

<sup>2</sup>Private Practice, Milan, Italy

<sup>3</sup>Private Practice, Torino, Italy

<sup>4</sup>Private Practice, Seriate, Italy

<sup>5</sup>Private Practice, Trieste, Italy

<sup>6</sup>Department of Biosciences, Biotechnologies and Biopharmaceutics, University of Bari Aldo Moro, Bari, Italy

<sup>7</sup>Department of Basic Medical Sciences, Neurosciences and Sense Organs, University of Bari Aldo Moro, Bari, Italy

<sup>8</sup>Department of Neurosciences, Reproductive and Odontostomatological Sciences, University of Naples Federico II, Naples, Italy

<sup>9</sup>Private Practice, Hradec Kralove, Czech Republic

<sup>10</sup>Private Practice, Bari, Italy

<sup>11</sup>Department of Clinical and Experimental Medicine, University of Foggia, Foggia, Italy

**Aim:** to evaluate the tooth derived graft biological behaviour in socket preservation.

**Methods:** 28 patients (avg. age  $51.79 \pm 5.97$  yr) with post-extractive defects were divided into two groups: with vital (G1) and with devitalized teeth (G2). Extracted teeth were treated by Tooth Transformer<sup>®</sup> to obtain demineralized grafts for socket preservation and covered with membrane. After 4 months 32 biopsies were obtained for histological, histomorphometric and statistical evaluation.

**Results:** histological analysis has not shown any inflammatory reaction in both groups. In G2, no endodontic material was

detected. High value of bone volume (avg. 36.6800 vs 39.1600%), new vital bone (avg. 20.7800 vs 22.8900%) surrounding graft granules were observed in all samples and, at higher magnification, partially resorbed dental tissues were detected. Non-statistically significant differences were found in both groups regarding total bone volume, autologous graft residual, and vital bone percentage.

**Conclusion:** further studies will allow to confirm promising results obtained and compare with biomaterials currently used in bone regeneration. Tooth derived grafts appear to be able to produce a high level of new vital bone in implant dentistry.

## LOWER THIRD MOLAR EXTRACTION AND LIFE-THREATENING COMPLICATION: LEMIERRE SYNDROME

Petrelli P.<sup>1</sup>, Rinaldi F.<sup>1</sup>, Bernardi S.<sup>1,2,3</sup>, Piattelli S.<sup>1</sup>, Varvara G.<sup>1</sup>

<sup>1</sup>Department of Innovative Technologies in Medicine and Dentistry, University G. D'Annunzio of Chieti-Pescara, Chieti, Italy

<sup>2</sup>Department of Clinical Medicine, Public Health, Life and Environmental Sciences, University of L'Aquila, L'Aquila, Italy

<sup>3</sup>Center for Microscopy, University of L'Aquila, L'Aquila, Italy

**Aim:** one of the complications that can follow infection of the oral-pharyngeal space is known as Lemierre's syndrome, characterized by thrombosis of the internal jugular vein and septic emboli metastasising in other organs. This condition includes anaerobic septicaemia, fever, dysphagia, neck pain, cervical lymphadenopathy and induration of the internal jugular vein.

**Case:** a 39-year-old woman, who underwent an attempt of extraction of 4.8, was referred from the E.R. suffering from a very large swelling of the submandibular cervical region on the right side together with fever and pain and headache on the occipital-parietal and temporal right side. Contrast-enhanced computed tomography performed on hospitalization revealed a wide area of abscess, measuring 3x3x 7 cm, communicating with jugular vein, appeared thrombosed with gaseous emboli

in the cervical direction. At the cranial level, the right sigmoid sinus was not opaque, and it was possible to detect a thrombosis of the vessel.

**Results:** pharmacological therapy, including the administration of clindamycin 1 g intravenously every 8 hours, imipenem 500 mg intravenously every 8 hours and parnaparin 0.6 ml every 12 hours. Surgical approach included draining the abscess to release the purulent material. The patient underwent anticoagulant therapy for six months, as warfarin 5 mg/day. After two months, the tooth was extracted.

**Conclusion:** Lemierre's syndrome is also known as the forgotten disease and is a rare but life-threatening complication that can arise after surgical extractions of infected mandibular third molars.

## ETHICAL, RELIGIOUS AND CULTURAL ASPECTS ON THE USE OF XENOGRAFTS IN DENTISTRY: A REVIEW

Pierobon C., Brunello G., Caione A., Perini A., Sivoletta S.

Department of Neurosciences, School of Dentistry, University of Padua, Padua, Italy

**Aim:** the purpose of this review is to describe ethical, religious and cultural aspects of the use of xenografts in dentistry, and how these aspects influence the clinical choices.

**Methods:** electronic databases were searched using specific search terms. A hand search was also undertaken. Only studies in the English language, published in peer-reviewed journals between 1998 and 2021 were considered.

**Results:** religiously active people seemed to be less in favor of animal organ transplantation than those who were not. Porcine

derived materials are associated to the lowest acceptance rate as compared to other biomaterials. In the general population, younger men and those with a better formal education had a more positive attitude to xenotransplantation, and the dietary habits seem to influence the attitude of patients.

**Conclusion:** the source of the graft may be objectionable to the patient due to many different factors, including religious, ethical or cultural ones. A culturally sensitive informed consent including these factors should be discussed with the patients.

## ETORICOXIB AND DICLOFENAC EFFECTS ON PAIN AFTER MANDIBULAR THIRD MOLARS AVULSIONS: RCT

Polizzi A., Santonocito S., Lo Giudice A., Ferlito S., Isola G.

Department of General Surgery and Surgical-Medical Specialties, School of Dentistry, University of Catania, Catania, Italy

**Aim:** the aim of the present study was to compare the effectiveness of etoricoxib and diclofenac on pain and perioperative sequelae after the surgical avulsion of impacted mandibular third molars.

**Methods:** 97 patients needing surgical avulsion of an impacted mandibular third molar were selected and randomly allocated to receive twice a day for 5 days after surgery one of these treatments: (P) placebo (n = 33), (D) diclofenac (n = 32), or (E) etoricoxib (n = 32). Postoperative pain (primary outcome) was evaluated in each patient with the Visual Analogue Scale (VAS) score, while the secondary outcomes consisted of changes in postoperative swelling and maximum mouth opening compared with preoperative ones.

**Results:** diclofenac and etoricoxib groups showed significantly reduced pain compared to placebo. Furthermore, eto-

ricoxib determined a significant median reduction in postoperative pain at 2 hours ( $P < 0.001$ ), 12 hours ( $P = 0.025$ ), and at 48 hours ( $P = 0.018$ ) after surgery, compared to diclofenac and placebo.

The linear regression analysis showed that a significant influence on VAS at 2, 6, 12, 24, 48 hours and at 10 days after surgery was determined by diclofenac and etoricoxib. No significant changes were reevaluated on the postoperative swelling and maximum mouth opening between groups.

**Conclusion:** both treatments were effective in pain reduction, but etoricoxib, compared to diclofenac and placebo, determined a greater reduction of postoperative pain incidence and severity after surgical avulsion of impacted mandibular third molars.

## MUCOCELE ON LOWER LIP: A CLINICAL CASE

Tocchio A., Saladino T., Palmacci M., Bellantoni G., Piro M., Vinci R.

Oral Surgery Postgraduate School, Department of Dentistry, Vita-Salute San Raffaele University, IRCCS San Raffaele Hospital, Milan, Italy

**Aim:** mucocele is a common salivary gland disorder that manifests as a mucus extravasation phenomenon or as a mucus retention cyst. Most of the time this lesion occurs due to mucus accumulation resulting from the alteration or the traumatic lesion of the minor salivary glands. Diagnosis is mainly clinical based on its pathognomonic presentation. The aim of this study is to describe a clinical case of mucocele.

**Methods:** a 27-year-old woman came to the attention of the Department of Odontostomatologic Surgery of the Dental Clinic, reporting a swelling on the lower lip; the patient referred that initially the lesion was small and, passing time, it was increasing gradually. During the intraoral examination, a round, solitary, swelling was detected on the inner surface of the lower lip in the left central incisor region. The lesion was 2–3 mm below the vermillion border and it extended inferiorly toward the lingual vesti-

bule, measuring approximately 10–12 mm. The color of the swelling was the same as that of the adjacent mucosa, without alteration. Considering the patient discomfort and the surgical choices to resolve the lesion, the mucocele was treated under local anesthesia with an excision, using scalpel by designing straight incision. The lesion was resected from its base and then sent for histological analysis. Then the surgical site was sutured.

**Results:** the lesion was presumptively diagnosed as a mucocele, based on the clinical features and history of lip biting habit. The histopathological report confirmed the diagnosis.

**Conclusion:** due to high chances of recurrence, management of mucocele is a challenging task. Surgical excision with dissection of surrounding zone is a successful approach with least recurrence. Simple surgical excision is the treatment of choice, and when done with care, is the best treatment alternative.

## ENUCLEATION OF A FOLLICULAR ODONTOGENIC CYST: A CASE REPORT

Todaro M., Cusenza I., Ferraro C., Soldati C., Zizza A., Vinci R.

Oral Surgery Postgraduate School, Department of Dentistry, Vita-Salute San Raffaele University, IRCCS San Raffaele Hospital, Milan, Italy

**Aim:** the purpose of this study is to present a clinical case of a follicular odontogenic cyst treated using a conservative surgical enucleation with a 12 months follow-up.

**Methods:** a 72-year-old male patient was referred to the Department of Dentistry of the IRCCS San Raffaele Hospital for a multilocular neoformation in the left mandible. The patient had a history of abscesses in the partially included and dystopic element 3.8. An orthopantomography (OPT) was performed and it showed the presence of a bilobed osteolytic lesion extending distally and apically to element 3.8. Possible rhizolysis of the distal root of element 3.7 was also observed in the OPT. A vitality test was performed on element 3.7 which was positive. The clinical and radiographic appearance of the lesion led the surgeon to a diagnosis of follicular odontogenic cyst to be confirmed by histological examination. The treatment plan consisted of a conservative surgical removal of the lesion and avulsion of element 3.8 under local anesthesia. A subperiosteal triangular flap was

elevated and a vestibular access has been created by osteotomy with a straight handpiece. Next tooth's extraction the enucleation of the lesion was carefully performed. After scrupulous revisions of the cavity, fibrin sponges were placed and suturing was performed with 4/0 suture thread. The removed neoformation was sent to the Histology and Pathology Department of San Raffaele Hospital for histopathological analysis.

**Results:** histopathological examination confirmed the diagnostic suspicion of odontogenic cyst.

At 1 year follow-up, the OPT showed the beginning of the reossification of the area and the maintenance of the distal peak bone.

**Conclusion:** considering the absence of relapses at 12 months, an accurate pre-surgical evaluation and a proper surgical procedure may allow for predictable enucleation of cystic lesions.

## PIEZOELECTRIC SURGERY OF AN ODONTOGENIC LESION: A CASE REPORT WITH AN 8-YEARS FOLLOW-UP

Viti S., Panerai F., Cardili M., Sertori F., Raimondi Lucchetti F.<sup>1</sup>, Vinci R.<sup>2</sup>

<sup>1</sup>Resident doctor, Oral Surgery Postgraduate School

<sup>2</sup>Director of Oral Surgery Postgraduate School, Associate Professor, Vita-Salute San Raffaele University

Oral Surgery Postgraduate School, Department of Dentistry, Vita-Salute San Raffaele University, IRCCS San Raffaele Hospital, Milan, Italy

**Aim:** the purpose of this clinical report is to present a mandibular root cyst, surgically treated with piezoelectric device in a 40 years old patient with an 8-years follow-up.

**Methods:** the patient was referred to the Dentistry department of San Raffaele Hospital for recurrent pain and swelling located in the lower jaw. From the medical history, associated systemic pathologies were excluded. After an accurate clinical and radiographic analysis, a large radiolucent lesion localized at the level of the left mandibular body with apparent erosion of the lingual cortical has been noticed. Therefore, a surgical exeresis of the neoformation under local anaesthesia was chosen. A mucoperiosteal incision was made in order to detach an envelope flap from element 3.5 to element 3.8, thus a full-thickness detachment and a crestal access hatch with piezoelectric technique were performed and the excision of the lesion was carried out. After a careful cavity revision, collagen spon-

ges were inserted into the neo-cavity, the bone block was repositioned and a 4/0 resorbable suture with everted stitches was placed to close the wound. Eventually the sample of 1,3 cm was sent to the Pathological Anatomy Department for histological analysis.

**Results:** the histological examination confirmed the diagnostic hypothesis of radicular cyst. At the two-week control visit, good tissue trophism was noted. At the 8-years follow-up both clinical and radiological analysis shown the wound healing and the complete disappearance of the lesion.

**Conclusion:** the use of the piezoelectric device allows to create a more conservative access even in the most complex cases, making sure to minimize complications related to neurological and vascular damage thanks to its features, and to obtain better healing, less post-operative swelling, less tissue edema and eventually avoiding the tearing of the lesion.

## USEFULNESS OF ELECTROMAGNETIC Mallet IN ORAL SURGERY AND IMPLANTOLOGY: A REVIEW

Bennardo F., Vocaturo C., Antonelli A., Brancaccio Y., Buffone C., Barone S., Giudice A.

School of Dentistry, Division of Oral Surgery and Pathology, Department of Health Sciences, University Magna Graecia of Catanzaro, Catanzaro, Italy

**Aim:** the aim of this study, through literature review, was to present clinical applications of electromagnetic mallet in oral surgery and implantology and outline its advantages and disadvantages compared with conventional surgical techniques.

**Methods:** PubMed/Medline, Scopus Preview and Web of Science databases were selected to search for articles published until 1<sup>st</sup> March 2021 that described clinical applications of electromagnetic mallet in oral and implant surgery. The key search terms included “magnetic mallet”, “electric mallet”, “oral surgery” and “dental implant.” Two independent reviewers assessed the relevance of the studies.

**Results:** after removal of duplicates the search yielded 260 records. After abstract analysis, 117 were selected for full text reading, then 29 articles were included in qualitative synthesis.

**Conclusion:** the analysis of the literature showed that the use of electromagnetic mallet was described by several authors both in oral and implant surgery; specifically, it was used for implant site preparation, fixture insertion, crestal sinus lift, ridge expansion, and for extractive surgery. The electromagnetic mallet proved to be a fast and accurate tool, but further studies are needed to prove its effectiveness in comparison with conventional surgical techniques.

## DENTAL AUTOTRANSPLANTATION ASSISTED BY COMPUTER-AIDED RAPID PROTOTYPING: A CASE SERIES

Stacchi C., Barlone L., Berton F., Rapani A., Zotti M., Perazzolo G., Di Lenarda R.

Department of Medical, Surgical and Health Sciences, University of Trieste, Trieste, Italy

**Aim:** this study evaluated the clinical outcomes of mature third molars autotransplanted to replace hopeless first or second molars with the aid of computer-aided rapid prototyping.

**Methods:** adult patients (> 18 years) with first or second molars scheduled for extraction and the presence of a mature third molar were included in this study. Cone-beam computed tomographies were used to produce 3-D replicas of the donor third molars.

After first and/or second molar extraction, the socket was carefully debrided and prepared with piezoelectric inserts until a suitable infraocclusal fit of the 3-D replica was reached. Duration of socket preparation was recorded. The third molar was then extracted, immediately placed in the recipient site and stabilized with a cross-stitch suture and a flexible splint to the adjacent teeth. Extra-alveolar time of manipulation of transplanted tooth was recorded. The fixation was removed after 21 days and root canal therapy was performed. Patients were

then followed both clinically (periodontal parameters) and radiographically (root resorption, ankylosis) for at least 12 months.

**Results:** seven autotrasplantations (4 maxilla; 3 mandible) in seven patients (5 male, 2 female; mean age  $29.7 \pm 7.3$  years) were performed. Mean duration of socket preparation was  $26.3 \pm 11.7$  minutes and mean extra-alveolar time of manipulation was  $7.4 \pm 3.7$  seconds. At 12-month follow up, all transplanted molars were successfully in function showing physiological periodontal parameters and no radiographic signs of root resorption or ankylosis.

**Conclusion:** the use of 3-D replicas in tooth transplantation allows for precise preparation of the recipient site, together with a very short extra-alveolar time of manipulation of the donor tooth. These factors could help in minimizing damage to the cells of the periodontal ligament and possibly contribute to positive clinical outcomes.

## SURGICAL REMOVAL OF THE LEFT UPPER MAXILLARY WISDOM TOOTH THROUGH SOLE HYPNOTIC ANALGESIA

Barjami A.<sup>1</sup>, Queirolo L.<sup>1</sup>, Facco E.<sup>1,2,3</sup>, Bacci C.<sup>1</sup>, Zanette G.<sup>1</sup>

<sup>1</sup>Department of Neurosciences, Dentistry Section, University of Padua, Padua, Italy

<sup>2</sup>Science of Consciousness Research Group, Department of General Psychology, University of Padua, Padua, Italy

<sup>3</sup>Institute Franco Granone, Italian Center of Clinical & Experimental Hypnosis, Turin, Italy

**Aim:** the aim of this case report is to highlight the importance of hypnosis, which is not only a valuable anesthetic tool, but in some selected clinical case it could be the best option available.

**Methods:** a 47 years old female patient affected by multiple chemical sensitivity (MCS) and Addison disease, referred an anaphylactoid reaction to all local anesthetics. Through the Stanford Susceptibility Scale Form C (SHSS-C) and a pain threshold test with a dental pulp stimulator, we evaluate her hypnotisability and her analgesic capability. We adopt the hypno-

tic focused analgesia protocol to get the patient to develop full hypnotic analgesia.

**Results:** the surgery was successfully performed, and the patient referred a total absence of pain. In this case, hypnosis was the only possible procedure, apart from general anesthesia which could have been potentially harmful considered the patient's clinical history.

**Conclusion:** therefore, the surgical removal of the left upper maxillary wisdom tooth in hypnosis proved to be safe, effective and the best available option.

## PARTIAL PALATAL OSTEOTOMY TECHNIQUE (PPOT): INDICATIONS AND TREATMENT

Bursomanno E., Di Bisceglie M., Arcuri L., Galli M.

Department of Oral and Maxillo-Facial Sciences, Sapienza University of Rome, Rome, Italy

**Aim:** transverse deficits, one of the most frequent problems in orthognatodontics, are treated in an effective and predictable way, with stable results over time, by means of a surgical-orthodontic approach, similar to SARME but with the peculiarity of performing the osteotomy at the middle palatine suture (MPS) by creating a palatal flap.

**Methods:** many patients diagnosed with transverse maxillary hypoplasia have undergone surgery using this technique. PPOT is reliable and highly predictable in its results due to the palatal approach that is added to the classic osteotomy technique of SARME on the vestibular side that extends from 1.6 from 2.6, after the incision and detachment of the paramarginal flap. Once the horizontal osteotomy is completed, 4-5 mm above the

root apices, the paramarginal palatal arch flap is performed from 1.4 to 2.4, a periosteal mucus flap, which considerably reduces the resistance of the fibromucosa, responsible for recurrences in the SARME technique, and thus performs the osteotomy of the median palatine suture in a safe and uniform way thanks to the complete visibility offered by the flap.

**Results:** the expansion was successfully achieved in all patients in a more than satisfactory manner, in the absence of post-treatment complications and relapses.

**Conclusion:** PPOT is affirmed for its significant advantages that millimetrically improve the outcome of the expansion compared to other techniques and for the certainty it gives the clinician and the patient in the consolidation of the result achieved.

## TOOTH-DERIVED BONE OBTAINED FROM TOOTH TRANSFORMER AS GRAFT MATERIAL: A LITERATURE REVIEW

Causarano G., De Santis D., Albanese M., Alberti C., Luciano U., Magi M., Modena N., Poscolere A., Zarantonello M., Nocini P.F.

Section of Oral and Maxillofacial Surgery, Department of Surgical Sciences, Dentistry, Gynecology and Pediatrics, University of Verona, Verona, Italy

**Aim:** the aim of the study is to perform a literature review on the use of demineralized dentin matrix obtained through the use of Tooth Transformer (BIOMAX S.p.A, Italy) in the treatment of alveolar bone defects. The TT can transform autologous teeth in suitable grafting material, increases BMP bioavailability that induces cell osteodifferentiation, osteoinduction and demonstrated signs of absence of inflammation were detected.

**Methods:** we performed an electronic search to identify relevant literature indexed by 2012 to 2020 using database (MEDLINE, PubMed). We used clinical study, histologic and histomorphometric analyses of clinical cases to perform a literature review. Many clinical studies on guided bone regeneration (GBR), socket preservation and ridge augmentation showed that new bone was obtained from TT.

**Results:** many authors demonstrated that demineralized dentin can maintain the intactness of the autogenous and could in-

duce bone formation. Histological analyzes reported percentages of new bone formation between 45% and 87%, a considerable range compared to other bone substitutes. Newly formed trabeculae incorporated tooth graft particles mixed with grafted granules fully and remodeling processes were observed. The regenerated tissue aspect was almost homogeneous and tooth particles or grains were not distinguishable.

**Conclusion:** the following study allows us to conclude that the use of the demineralized dentin matrix obtained from the use of TT leads to good bone healing in augmentation procedures. This technique could be a reasonable alternative to the more risky and morbid techniques for the patient, it offers the advantage of having a low cost for the clinician and exploiting the regenerative power that encloses one's tooth. Human dentin matrix could be considered an excellent alternative to autologous bone graft or heterologous.

## INFERIOR ALVEOLAR NERVE LACERATION DURING DENTAL IMPLANT INSERTION PHASE: A CASE REPORT

D'Antiochia S., Franceschini C., Santi G., Maldonado R., Sferlazza L., Galli M.

Department of Oral and Maxillo Facial Sciences, Sapienza University of Rome, Rome, Italy

**Aim:** an iatrogenic error during the insertion of a dental implant in the posterior mandible site caused the laceration of the inferior alveolar nerve.

**Methods:** a 71-year-old female patient came to our attention after dental implant placement treated by a colleague. She wanted to rehabilitate the posterior edentulous areas with a fixed implant-supported prosthesis. During osteotomy in region 46, the speed of the surgical motor was not changed; the implant was inserted with the last implant drill speed (1200 rpm) and entered into the mandibular canal, causing the laceration of the inferior alveolar nerve, with immediate and severe pain felt by the patient. The implant was immediately removed.

**Results:** after surgery, the patient was prescribed amoxicillin and clavulanic acid; a vitamin B complex, and oral dexamethasone. The patient, for unknown reasons, started the therapy with oral dexamethasone after 2 weeks from the prescription. During the first 2 weeks after surgery the patient complained pa-

resthesia in the mental and lower lip area, labial ptosis and drooling. After 14 days, the paresthesia reduced and mucosal and gingival normosensitivity was partially restored, but the patient had hyperesthesia in the lower inside lip. After 21 days, the lower lip tone and function were almost completely restored and the paresthesia was reduced; the hyperesthesia persisted.

**Conclusion:** this case shows that, even if it was planned properly, the damage is related to negligence, so it is clear that correct preoperative planning does not exclude neurological lesions. It is extremely important to pay attention through proper preoperative planning and careful execution of the surgical techniques. These damages can often imply a very unpleasant experience for the patient, both immediately and in the long term. It is important to note that in this instance, the clinical course during the first 2 weeks probably worsened because the patient forgot to take dexamethasone immediately after surgery; in this case the pharmacological therapy does not restore completely the sensitivity.

## EVALUTATION OF AN INNOVATIVE SCAFFOLD SOLUTION FOR BONE REGENERATION: COMPACT BIO BONE

De Giglio N.<sup>2</sup>, Dell'olio F.<sup>2</sup>, Barile G.<sup>2</sup>, D. Inchingolo A.<sup>2</sup>, Mezzapesa P.P.<sup>2</sup>, Patano A.<sup>1</sup>, Laudadio C.<sup>1</sup>, Malcangi G.<sup>1</sup>, Coloccia G.<sup>1</sup>, Marinelli G.<sup>1</sup>, Limongelli L.<sup>1</sup>, Montenegro V.<sup>1</sup>, D'Oría M.T.<sup>1</sup>, Dipalma G.<sup>1</sup>, Gargiulo Isacco C.<sup>1</sup>, Inchingolo F.<sup>1</sup>, Farronato M.<sup>2</sup>, Tartaglia G.<sup>2</sup>, Favia G.<sup>2</sup>

Complex Operative Unit of Odontostomatology Director: Prof. G. Favia

<sup>1</sup>Specialization School in Orthognatodontics, Director Prof. F. Inchingolo, Interdisciplinary Department of Medicine D.I.M. University of Bari Aldo Moro, Bari, Italy

<sup>2</sup>Specialization School in Oral Surgery, Director Prof. G. Favia, Interdisciplinary Department of Medicine D.I.M. University of Bari Aldo Moro, Bari, Italy

<sup>3</sup>Department of Biomedical, Surgical and Dental Sciences, School of Dentistry, University of Milan. UOC Maxillo-Facial Surgery and Dentistry. Fondazione IRCCS Ca' Granda, Ospedale Maggiore Policlinico, Milan, Italy

**Aim:** diseases, trauma, and surgical procedures can be the cause of bone paucity and defects. The main criteria of a biomaterials are: biocompatibility, osteoinduction, osteogenesis and osteoconduction. These properties allow the osteointegration of the biomaterial without causing inflammatory reactions, the differentiation of stem cells into osteoblasts and the formation of a new matrix. Furthermore, osteoconduction is an important property in order to provide a scaffold for cells activities. The aim of this study is to evaluate the activity of Compact Bio Bone cell (CBB) in bone regeneration.

**Materials:** CBB is a biomaterial made of periferical blood staminal cells (PB-SCs),  $\beta$ -TCP (Beta-Tricalcium-phosphate) and fibrin gel matrix. PB-SCs were directly transferred and inserted

into the previously constructed fibrin and  $\beta$ -TCP scaffolds. The  $\beta$ -TCP granules with diameters of 1 mm and 1-2.5 mm were embedded in a fibrin gel matrix and subsequently cultured with serum-free medium (SFM) for a period of 7-10 days.

**Results:** *in vitro* study showed that Compact Bio Bone Cells have a biodegradability rate comparable to the rate of bone regeneration, so cells resembling mature osteoblasts were detected at 7-12 days. The presence of stem cells induces the vascularization of the area.

*In vivo*, CBB induced both horizontal and vertical growth, but the most important aspect was the quality and compactness of the new bone which revealed a very similar solid and compact tissue formation to the structure of the original endogenous bo-

ne. The histological analysis carried out the presence and formation of new lamellar bone in good condition, osteocytic islets in lacunae, clusters of active osteoblasts and new matrix.

**Conclusion:** compact Bio Bone Cell seems to increase the osteoinductivity by using stem cells. Further studies may confirm this hypothesis.

## RESIDUAL ODONTOGENIC CYST: A CASE REPORT

Faben A., Massaglia M.M., Ferri S., Saladino T., Bellantoni G., Vinci R.

Oral Surgery Postgraduate School, Department of Dentistry, Vita-Salute San Raffaele University, IRCCS San Raffaele Hospital, Milan, Italy

**Aim:** the aim of this case is to describe the clinical-pathological features of residual odontogenic cyst. This is an inflammatory cyst composed by fibrous and granulation tissue, localized at the apex or in the periapical region of a tooth incorrectly removed or curetted at the time of dental extraction. If a residual cyst remains untreated, continued growth can cause significant bone resorption and weakening of the maxilla.

**Methods:** a 50-years-old male patient came to the attention of the Department of Dentistry of the IRCCS San Raffaele Hospital. During intraoral examination, a fistula was observed in the zone of element 13. A CBCT was performed to confirm the hypothesis of an osteolytic lesion of the maxilla. The radiological analysis showed a zone of radiolucency, extending from element 1.1 to element 1.3. It was decided to proceed with surgical excision of the lesion. A semi-lunar paramarginal incision was made and a full-thickness

flap was elevated. A piezoelectric device was used to perform an osteotomy to create a bone fenestration that permitted the isolation of the lesion. It was carefully identified, removed and then sent to the Histology and Pathology Department of San Raffaele Hospital for histopathological analysis. The cavity was subsequently revised, the clot was stabilized using fibrin sponge. The surgical site was sutured. The patient was introduced into a maintenance program, to avoid recurrences.

**Results:** after two weeks the fistula had disappeared. The OPT at 5-year follow-up showed a complete radiologically healing.

**Conclusion:** this case report shows that during the dental extraction the cavity has to be correctly revised, to avoid the uprising of a residual cyst. An accurate clinical and radiographical analysis of the case, a complete cyst excision and its histopathological diagnosis prevents recurrence of the lesion at 5 years.

## SOLITARY BONE CYST OF THE MANDIBLE: A CASE REPORT

Ferraro C., Ferri S., Saladino T., Todaro M., Franceschi L., Piro M.

Department of Dentistry, Vita-Salute San Raffaele University, IRCCS San Raffaele Hospital, Milan, Italy; Dental School Vita-Salute San Raffaele University, Milan, Italy

**Aim:** the aim of this case report is to present a clinical case of a Solitary Bone Cyst (SBC) and to describe the clinical, diagnostic and radiologic aspects as well as treatment. SBC is an intraosseous space that lacks of an epithelial lining. The pathogenesis of this lesion is unknown.

**Methods:** a 19-year-old patient was referred by a professional to the Dentistry Department of San Raffaele Hospital for an evaluation of an osteolytic lesion in the fourth quadrant. During the anamnesis the patient referred that the zone was affected by a trauma due to a car accident. On radiographic examinations (OPT, CBCT) the area of the lesion was well circumscribed, polycyclic, radiolucent and located in the posterior mandible, extending from 4.5 to the retromolar area. Dental elements didn't show mobility and responded positively to vitality tests. The presumptive diagnosis of SBC, and surgical exploration of the lesion was planned. Under local anesthesia, a parasulcular inci-

sion was designed for the creation of an envelope flap. Full-thickness flap was elevated, then an osteotomy was performed to create a bone fenestration. After a simple curettage of the walls of the bone cavity, the area is washed with sterile physiological solution and fibrin collagen is positioned in order to allow the organization of the blood clot, which will lead to spontaneous healing of the cavity through a process of bone regeneration. After the cavity review, the surgical site was sutured. The patient was introduced into a maintenance program of clinical and radiographic checks.

**Results:** a follow-up OPT and CBCT executed after 6 months revealed the resolution of the lesion, with starting ossification of the surgical site. Two years after surgical curettage, no recurrences were observed.

**Conclusion:** this clinical case demonstrates that surgical treatment of the site is not only curative, but also diagnostic.

## IDIOMATIC BONE CAVITY OF STAFNE: A CASE REPORT

Franceschi L., De Palma F., Ferraro C., Todaro M., Piro M., Vinci R.

Oral Surgery Postgraduate School, Department of Dentistry, Vita-Salute San Raffaele University, IRCCS San Raffaele Hospital, Milan, Italy

**Aim:** the aim of this case report is to present a clinical case of Stafne's Lacunae and to underline the importance of the radiographic diagnosis. Stafne's Lacunae was first described in 1942, by Stafne, as a depression of the mandibular surface on the lingual side.

It is a rare benign condition, a growth defect that appears on the radiography as a small and rounded area well circumscribed, with a sclerotic bead. Characteristic Stafne's Lacunae are occasionally encountered in clinical practice. Clinically it is an asymptomatic lesion.

Radiographically it is a unilocular radio-transparent lesion that can mimic cystic cavities or osteolytic areas, which is why a differential diagnosis is necessary.

**Methods:** a male patient of 55-years-old comes to our attention at the Department of Dentistry of the IRCCS San Raffaele Hospital, in January 2018. An Orthopantomography (OPT) was

performed, and it showed a radio-transparent area with clear margins in the context of the mandibular body, at the level of the 1st – 2nd molar, underneath the inferior alveolar canal.

The lesion was investigated by Cone Beam Computer Tomography (CBCT), which confirm the presumptive diagnosis. As reported in literature, Stafne's Lacunae does not require surgical excision treatment, but clinical and radiographic follow-up. The patient was introduced into a maintenance program of clinical and radiographic checks at 3, 6, 12 months and then annually.

**Results:** three years follow-up CBCT shows that the lesion has remained unchanged.

**Conclusion:** since the last CBCT, follow-up radiographic examination is recommended every year, in order to monitor any modification or change in the aspect of lesion and to avoid eventual degenerations.

## MANDIBULAR KERATOCYST: A RARE CASE OF RECURRENCE AFTER TWENTY YEARS

Lauro M., Bancale M., Gargiulo D., Esposito G., Di Maro P., Rosiello N.

Department of Neurosciences, Reproductive Sciences and Oral Sciences, University of Naples Federico II, Naples, Italy

**Aim:** this case report describes a rare case of a mandibular keratocyst recurrence after 20 years, highlighting the importance of long-term follow-up in diseases with a high rate of recurrence treated with a conservative surgical approach

**Methods:** a 48-year-old systemically healthy woman with a past history of enucleation performed at ages 28 years for an odontogenic mandibular tumor (keratocyst) was referred to the Department of Oral Surgery of the University of Naples Federico II. Radiographic (orthopantomography; OPG) examination revealed a well-defined homogeneously radiolucent lesion in correspondence with the lower right second molar while the previous OPG showed a large radiolucency extended from the first premolar distal to second molar of the same area, involving 4.4, 4.5, 4.6 and 4.7. The pre-operative Cone Beam Computed tomography (CBCT) revealed the osteolytic lesion without invasion of the mandibular lower border or vestibular and lingual

cortical plates. An incisional biopsy confirmed the diagnosis of keratocyst. The intervention was performed under local anesthesia and the second molar were extracted. The suspicion of keratocyst recurrence was confirmed by the histological exam after the total removal of the osteolytic lesion.

**Results:** the healing process and post-operative recovery was uneventful, lower second molar was extracted and patient was clinically and radiographically examined just after surgery. The patient was scheduled for follow-up appointments at six monthly intervals.

**Conclusion:** a rare case of keratocyst recurrence was reported, so the role of follow up remain fundamental, probably for entire life, in order to detect the recurrences as soon as possible. The teeth involved in the keratocysts probably may play a role in the occurrence of recurrence, so the extraction of the involved teeth can be recommended.

## RIDGE PRESERVATION WITH AUTOLOGOUS TOOTH: A REVIEW

Marinelli G.<sup>1</sup>, Patano A.<sup>1</sup>, Laudadio C.<sup>1</sup>, Malcangi G.<sup>1</sup>, Coloccia G.<sup>1</sup>, Limongelli L.<sup>1</sup>, Inchingolo A.D.<sup>1</sup>, Hazballa D.<sup>1</sup>, Montenegro V.<sup>1</sup>, D'Oria M.T.<sup>1</sup>, Corsalini M.<sup>1</sup>, Dipalma G.<sup>1</sup>, Inchingolo F.<sup>1</sup>, Di Venere D.<sup>1</sup>, Cardarelli F.<sup>1</sup>, Farronato M.<sup>2</sup>, Tartaglia G.<sup>2</sup>

Complex Operative Unit of Odontostomatology, Director: Prof. G. Favia

<sup>1</sup>Specialization School in Orthognatodontics, Director Prof. F. Inchingolo, Interdisciplinary Department of Medicine D.I.M. University of Bari Aldo Moro, Bari, Italy

<sup>2</sup>Department of Biomedical, Surgical and Dental Sciences, School of Dentistry, University of Milan. UOC Maxillo-Facial Surgery and Dentistry, Fondazione IRCCS Ca' Granda, Ospedale Maggiore Policlinico, Milan, Italy

**Aim:** after tooth extraction alveolar ridge resorbs approximately 50% in horizontal width the first six months the reason why dental implants placement and esthetic is often compromised. Alveolar ridge preservation is a common procedure in cranio-maxillofacial which has already become an indisputable need. This procedure is performed to prevent bone resorption for a prosthetically ideal position or simply to preserve the pontic site. Tooth matrix as autologous bone substituted material is free of antigenic reaction, poses osteoconduction and osteoinduction properties. This biomaterial permits the three-dimensional reconstruction of the bone, has a low cost and is easy to handle. The aim of this review is to sum up and denote the properties of tooth graft in alveolar ridge preservation.

**Methods:** to obtain the needed information we performed a quantitative inspection of the literature in the registers PubMed-Medline. To develop this systematic review the inclu-

sion criteria were study in cranio-maxillo facial, histological outcomes in human, publication of the last five years. Exclusion criteria were study in animal, ex vivo and *in vitro*.

**Results:** the results are obtained from a total of 95 patients with 119 sites treated in a period from 4-12 months. The average mean value for vertical dimension of bone loss was 0.61mm and for horizontal bone loss was 0.74mm. The average of new bone formation was  $33.96 \pm 11,38\%$ .

**Conclusion:** the data collected in this review demonstrate that autologous tooth matrix appears to be biologically and clinically a good alternative in ridge augmentation which support the implant immediate or delay placement. This biomaterial offers promising histological outcomes with an estimate rate of vital bone formed. Within its limitations we come to end that autologous tooth graft is a bioactive scaffold which unlock new frontiers in bone regeneration.

## KISSING MOLARS: DIAGNOSIS AND MANAGEMENT OF 3 RARE CASES

Mezzapesa P.<sup>1</sup>, Coloccia G.<sup>2</sup>, Casorelli A.<sup>3</sup>, Barile G.<sup>1</sup>, Dell'Olio F.<sup>1</sup>, Cantatore F.<sup>4</sup>

<sup>1</sup>Specialization School of Oral Surgery, Department of Interdisciplinary Medicine, University of Bari, Bari, Italy

<sup>2</sup>Specialization School of Orto-gnathology, Department of Interdisciplinary Medicine, University of Bari, Bari, Italy

<sup>3</sup>Department of Interdisciplinary Medicine, University of Bari, Bari, Italy

<sup>4</sup>Complex Operating Unit of Oral Pathology and Surgery, Department of Interdisciplinary Medicine, University of Bari, Bari, Italy

**Aim:** “kissing molars” or “rosette formation” are impacted permanent molars (mainly lower molars) that have occlusal surfaces contacting each other in a single follicular space. Gulses classified this condition in Class I (first and second lower molars), Class II (second and third lower molars) and Class III (third and a supernumerary fourth molar); class II is the most frequent. The aetiology remains unknown. The aim of this study was to describe the management of 3 patients affected by this rare condition.

**Methods:** between 2010 and 2021, 3 male patients were referred to the Complex Operating Unit of Oral pathology and Surgery, University of Bari Aldo Moro, complaining recurring oral pain radiated to the ear. In any case signs of inflammation or swelling were present. Medical history revealed good health patients.

The panoramic radiography showed in 2 cases the presence of impacted third and second lower molars facing with their occlusal surfaces (Class II of Gulses), and in 1 case impaction between third and fourth lower molars (Class III of Gulses). A high definition spiral multislice computer tomography was done. Patients underwent blood tests, elettrocardiogram and anesthetic counseling. During general anesthesia, after flap elevation and osteotomy, teeth were luxated and extracted. In 2 cases a radiolucent lesion was present therefore the cyst epithelium was removed, fixed in formalin and sent to the pathological anatomy department.

**Results:** a 3-months control x-rays showed in all 3 cases a good bone healing and absence of any recurrence. The histological analysis reported a follicular cyst diagnosis.

**Conclusion:** dental surgeon often deals with impacted teeth; kissing molars is a rare condition of impacted teeth. Dental practitioners must know kissing molars could be surrounded

by a follicular cyst, so periodic follow-ups are necessary to assess the need of surgery. If not treated these cysts can lead to bone destruction and/or histological changes.

## PRELIMINARY ANALYSIS OF THE CYTOKINE, CHEMOKINE AND GROWTH FACTOR PROFILE IN MRONJ LESIONS

Motta C.<sup>1</sup>, Genova T.<sup>2</sup>, Roato I.<sup>2</sup>, Erovigni F.<sup>1</sup>, Mussano F.<sup>1</sup>

<sup>1</sup>CIR Dental School, Department of Surgical Sciences, University of Turin, Turin, Italy

<sup>2</sup>Department of Life Sciences and Systems Biology, University of Turin, Turin, Italy

**Introduction:** the present study aims to analyze any difference in the biochemical markers' profile in patients with MRONJ treated with either bisphosphonates or denosumab. The purpose is to investigate the topic of biochemical markers of bone turnover, so as to evaluate the alterations of bone metabolism and the response of the patient to the different drug therapy.

**Methods:** the study included 19 patients diagnosed and treated for MRONJ related exclusively or with bisphosphonates or with denosumab. A sample of venous blood was taken from these patients and then centrifuged to obtain, for each patient, one sample of PRGF and one of PPGF. The flexible Bio-Plex system was employed to assess the concentration of a large range of biochemical markers.

**Results:** from the analysis of the samples, no statistically significant differences were found between the values of biofactors detected within the PRGF compared to those detectable within the PPGF. The concentration of IL-8 is important at the level of zoledronate samples. IFN- $\gamma$  appears particularly expressed within the PRGF of the group of oral bispho-

sphonates. There is a statistically significant difference in the concentration of IL-8, IFN- $\gamma$ , MCP-1 and MIP-1b in the comparison between patients in therapy with denosumab, zoledronate and alendronate respectively.

**Conclusion:** our study, highlighting that there are no significant differences between the concentration of biofactors between PRGF and PPGF, raises the question of the effective validity of this method of division between rich and poor and stresses the need for further studies, more in-depth, to validate the application of PRGF for the prevention and treatment of MRONJ. Also, statistically significant difference was found between the expression profile of IL-8, IFN- $\gamma$ , MCP-1 and MIP-1b, within the PRGF of zoledronate, denosumab and alendronate patients respectively. It would be interesting to investigate, in addition to the expression profile of cytokines, chemokines and growth factors, also gene expression profiling, in order to understand how cells respond to a given treatment in order to predict and prevent the possible development of adverse reactions such as MRONJ.

## TITANIUM INNOVATIVE LASER DENTAL MATERIALS: PHYSICAL AND CHEMICAL EVALUATION

Natale D.<sup>1</sup>, Quaresima R.<sup>2</sup>, Abundo R.<sup>3</sup>, Stacchi C.<sup>4</sup>, Troiano G.<sup>5</sup>, Lo Muzio L.<sup>5</sup>, Mastrangelo F.<sup>5</sup>

<sup>1</sup>Private Practice, Trani, Italy

<sup>2</sup>Department of Civil Engineering, Architecture and Environment, University of L'Aquila, L'Aquila, Italy

<sup>3</sup>Private Practice, Turin, Italy

<sup>4</sup>Department of Dentistry Medicine, University of Trieste, Trieste, Italy

<sup>5</sup>Department of Clinical and Experimental Medicine, University of Foggia, Foggia, Italy

**Aim:** evaluation of the esthetic and physical colored changes of titanium Grade 5 (Ti6Al4V) treated surfaces laser obtained for implant dentistry rehabilitations.

**Methods:** colored titanium surfaces were obtained with laser treatment. Physical and topographic properties were evaluated by stereo, light, and electron microscopy and profilome-

tric analyses. L\*a\*b\* colorimetric coordinates were estimated by spectrometry, and superficial chemical characteristics were evaluated by energy dispersive X-ray analysis.

**Results:** within the complete palette of titanium colors, 2 pinks (P1-P2), incarnadine (I), and white (W) laser obtained were selected. The topography, texture, hues, saturation, rou-

ghness, and porosity of the samples were evaluated and compared with machined (M) and sand-blasted and etched (SBAE) control implant surfaces. P1, P2, and I, similar in hue and roughness ( $R_a = 0.5$  mm), showed a microgroove spacing of 56  $\mu$ m and a decreasing porosity. The W sample with a “checkerboard” texture and a light color ( $L^* = 96.31$ ) showed similar characteristics to the M samples ( $R_a = 0.32$  mm), and great differences with SBAE ( $R_a = 1.41$  mm,  $L^* = 65.47$ ).

**Conclusion:** hard and soft tissues are crucial in an esthetic dental implant failure showing the grey color of implant fixture or abutment. The two different pinks and incarnadine surfaces showed favorable esthetic and physical features to promote dental implant success even in the maxillary anterior area (recession, asymmetry, or deficiency) suggesting that titanium colored laser surfaces could be representing potential perspectives in the management of esthetic edentulous maxillary areas and dental implant failures.

## SINUS LIFT WITH AUTOLOGOUS BONE AND CONTEXTUAL IMPLANT INSERTION: A CASE REPORT

Pensa V., Cusenza I., De Palma F., Tocchio A., Bellantoni G., Vinci R.

Oral Surgery Postgraduate School, Department of Dentistry, Vita-Salute San Raffaele University, IRCCS San Raffaele Hospital, Milan, Italy

**Aim:** the purpose of this study is to describe the surgical procedure used for the sinus lift, to explain its indications and to evaluate the healing through one year follow-up.

**Methods:** the clinical case presented is related to a 55-years-old patient who was evaluated at Department of Dentistry of the IRCCS San Raffaele Hospital. During the clinical exam was observed an extended edentulous zone in the first and in the third sextants. A CBCT was performed to observe the features of upper and lower residual bone. The radiological examination showed that the height of the residual alveolar crest in the area of 1.4 and 1.5 measured about 3 mm. Among the possible clinical options, it was selected sinus lift by a lateral approach with vestibular access, using autologous bone (obtained with bone scraper), and contextual implants insertion. One year after implant placement, an OPT and a CBCT were performed

to evaluate the healing of the bone and the osteointegration of the implants.

**Results:** using this protocol we have obtained an excellent primary implant stability due to the bone gain derived from the sinus lift, good tissue healing and adequate prosthetic stability, evaluated with a careful intraoral objective examination. The addition of autologous bone and contextual implant insertion showed good healing one year later without implant and surgical complications.

**Conclusion:** analyzing the results of this study, it is possible to affirm that the sinus lift and contextual insertion of implant fixture is a predictable procedure to rehabilitate edentulous zone in short time. For this reason it must be considered among the various alternatives for the implant-prosthetic rehabilitation of edentulous atrophic maxilla.

## INTRAVASCULAR PAPILLARY ENDOTHELIAL HYPERPLASIA OF THE MANDIBLE: A RARE ENTITY

Russo D., Mariani P., Laino G., Fiorillo L., Laino L.

Multidisciplinary Department of Medical and Dental Specialties, University of Campania Luigi Vanvitelli, Caserta, Italy

**Aim:** intravascular papillary endothelial hyperplasia (IPEH) is a rare benign vascular lesion that commonly occurs in the skin and subcutaneous tissue. Oral IPEH lesions are uncommon and mainly occur in the oral mucosa, only 4 cases in the jaws have been reported. The present is the fifth case of IPEH of the mandible.

**Methods:** a 65-year-old woman was referred to the Oral Surgery Division for the evaluation of osteolytic lesion. X-ray

examination revealed a multilocular radiolucent lesion in the mandibular region from 4.6 to the 3.4. Root resorption of the teeth 4.1 to 3.3 was present, but their vitality was preserved. The patient reports no story of painful symptoms. After a careful evaluation of the CT images, surgical removal of the lesion was planned.

**Results:** following local anesthesia, a mucoperiosteal flap was made from the dental element 4.6 to 3.5 to visualize the buccal

cortex where it was possible to appreciate the presence of multiple “point-like” areas of bone resorption. Through the osteotomy, access was made to a cavity containing tissue of probable vascular origin, which was excised. Besides, a bone sample was taken; the specimens were fixed in 10% formalin. Following a careful revision of the cavity, the flap was finally sutured. Microscopic examination revealed an anastomosing network of small caliber vessels, with papillary projections and tufting growth surrounded by a fibrous pseudo-capsule. Ba-

sed on clinical presentation and histopathological findings the diagnosis was of IPEH.

**Conclusion:** considering the variability of the clinical and symptomatological manifestations, it is necessary to perform a careful differential diagnosis: radiographically with multilobed osteolytic lesions (multicystic ameloblastoma, odontogenic keratocyst, giant cell bone tumor); histologically, with malignant tumors such as angiosarcoma and malignant endovascular papilloma.

## REHABILITATION OF ATROPHIC MAXILLA WITH ZYGOMATIC IMPLANTS: A CASE REPORT

Ferrigno R.<sup>1</sup>, Caggiano M.<sup>1</sup>, Sangiovanni G.<sup>1</sup>, Luongo G.<sup>2</sup>

<sup>1</sup>Department of Medicine, Surgery and Dentistry, Scuola Medica Salernitana, University of Salerno, Baronissi, Italy

<sup>2</sup>Private Practice, Salerno, Italy

**Aim:** the aim of this case report is to show if zygomatic implants are a valuable choice in case of severe atrophy of the jaws, without the application of bone augmentation techniques.

**Methods:** a 45 years old female patient, with a severe atrophy of the upper jaw (both vertically and horizontally), was treated by the placement of zygomatic implants, respectively two on the right and two on the left zygoma. After surgery, immediate loading was performed.

**Results:** after 9-years of observation period, at x-rays examination the implants showed optimum bone integration in the zygomatic process, no mucositis, periimplantitis or other soft tissue inflammation was detected.

These data are consistent with those reported in the literature in which it is noted that the survival rate varies from 95% up to 100% equal to or greater than 10 years.

**Conclusion:** several techniques to rehabilitate atrophic maxillae are described in the literature, such as maxillary sinus augmentation, short implants, bone grafting with intra and extra-oral donor sites, pterygoid implants. In particular, our experience and scientific evidences, although lacking in quantity, suggests that the quad zygoma approach offers a predictable solution for the challenge of severe maxillary atrophy; high implant survival rates are noted.

## JAW'S OSTEOMYELITIS DUE TO *CITROBACTER FREUNDII* IN A PATIENT RECEIVING BPS

Santi G., D' Antiochia S., Pagnoni A., Galli M.

Department of Odontostomatological and Maxillofacial Sciences, Sapienza University of Rome, Rome, Italy

**Aim:** osteonecrosis of the jaw is a rare but very serious complication of the therapy with bisphosphonates. In this case report we describe a 47-year-old woman affected by a metastatic adenocarcinoma of the breast on chemotherapy and bisphosphonate treatment, who first developed a dental abscess and one year after surgery an osteonecrosis and osteomyelitis (OM) with same localization.

**Methods:** after abscess's drainage and dental extraction a non contrast computed tomographic (CT) scan detected a lytic bone lesion with left-sided osteoradionecrosis of the jaw

and the path of skin fistula. The microbiology exam shows the presence of *Citrobacter freundii* described in only one case by Cirelli et al. as the cause of the OM of the jaw. The patient underwent surgery to remove the necrotic bone and realise curettage procedure using transcervical approach with the prompt resolution of the infection.

**Results:** in this case, several factors contributed to the development of osteonecrosis of the jaw: the patient's primary disease, dental history and ongoing treatment with bisphosphonates.

The latter is certainly the most important factor, although the dental abscess and the subsequent dental surgery are other important factors that contributed, in this case, to the development of this sequelae.

**Conclusion:** a correct oral hygiene is of utmost importance in patients undergoing therapy with BPs, as well as the collaboration between dentist, radiologists and otolaryngology specialists to correctly prevent and appropriately treat this rare condition.

## EFFECTIVENESS OF A PIEZOELECTRIC-ASSISTED PROCEDURE FOR THE TREATMENT OF ANKYLOSED TEETH

Santonocito S.<sup>1</sup>, Ramaglia L.<sup>2</sup>, Ciccù M.<sup>3</sup>, Polizzi A.<sup>1</sup>, Fiorentino E.<sup>2</sup>, Lo Giudice A.<sup>1</sup>, Isola G.<sup>1</sup>

<sup>1</sup>Department of General Surgery and Surgical-Medical Specialties, School of Dentistry, University of Catania, Catania, Italy

<sup>2</sup>Department of Neurosciences, Reproductive and Odontostomatological Sciences, School of Medicine, University of Naples Federico II, Naples, Italy

<sup>3</sup>Department of Biomedical and Dental Sciences and Morphofunctional Imaging, University of Messina, Messina, Italy

**Aim:** after traumatic tooth avulsion, the dental ankylosis is one of the most common complications of dental reimplantation inducing aesthetic and functional deficits of varying degrees of severity, especially in the frontal area. The aim of the study was to evaluate the effects of the repositioning procedure for ankylosed permanent anterior teeth using a distraction osteogenesis approach that combined piezoelectric surgery and orthodontic therapy.

**Methods:** five patients with an ankylosed permanent anterior tooth were enrolled in the present study. After pre-operative orthodontic preparation, each selected site underwent a dento-alveolar block osteotomy procedure. The osteotomy was performed with a piezoelectric surgery device using thin OT7 inserts or OT2 piezoelectric surgery tips. A customized distraction device was made for the patients, using a resin splint and a sector expansion screw. It was set to provide a force in the same direction in which the tooth

was expected to be repositioned after the osteotomy incision. After a latency period of 14 days, the distraction of the dento-alveolar block was initiated at a distraction rate of 0.8 mm per day.

**Results:** the mean displacement achieved by the ankylosed teeth was  $7.8 \pm 0.75$  mm (SD), and the ankylosed tooth was regularly positioned in occlusion in  $20.4 \pm 1.85$  days (SD), with a slight regression (0.5 mm) observed after 1 year follow-up. Post-treatment radiography after 5 years of follow-up showed that the ankylosed tooth had the same stable root resorption as the final active treatment.

**Conclusion:** this study indicated that the combined surgical-orthodontic approach, using osteotomy performed with piezoelectric surgery and segmental distraction of the alveolar bone, could be used for the treatment of the ankylosed tooth in the frontal area.

## THE FATE OF THE REPOSITIONED BONE LID IN LATERAL SINUS FLOOR ELEVATION: A REVIEW

Schiavon L., Ferrante G., Brunello G., Perini A., Sivoletta S.

Department of Neurosciences, Section of Dentistry, University of Padua, Padua, Italy

**Aim:** lateral sinus floor elevation consists in an inlay graft of the maxillary sinus through a bone window access. The purpose of this systematic review was to present the histological, clinical and radiographical outcomes of lateral maxillary sinus floor elevation associated to the repositioning of the bone lid.

**Methods:** animal and human studies involving the lateral maxillary sinus floor elevation associated to the bone lid repositioning were retrieved from the MEDLINE (PubMed) online library. The research was conducted using a combination of the following keywords: “bone lid”, “bony window”, “bone grafting”, “human

study”, “maxillary sinus lift”, “sinus floor augmentation”, “animal study” and limited to studies published in English between January 2000 and December 2020. A hand search was also performed to identify relevant articles. Reviews as well as single case reports were not included.

**Results:** a total of 5 animal and 15 human studies were included. In the former, histological analysis were obtained from rabbit (3), sheep (1), and monkey (1) models. In human studies, clinical, radiographical, and histological examinations were performed on a total of 495 lateral sinus lifts with bone lid re-

positioning. Both animal and human studies reported a good healing of the repositioned bony window, which acted as an autologous osteoconductive barrier, preventing soft tissue ingrowth and enhancing bone regeneration.

**Conclusion:** the repositioning of the bone lid after the lateral maxillary sinus augmentation seems to be a valid and safe technique, promoting the vascularization and integration of the graft.

## SURGICAL TREATMENT OF A PYOGENIC GRANULOMA IN A PREGNANT WOMAN: A CASE REPORT

Tocchio A., Cusenza I., Ferraro C., Saladino T., Todaro M., Vinci R.

Oral Surgery Postgraduate School, Department of Dentistry, Vita-Salute San Raffaele University, IRCCS San Raffaele Hospital, Milan, Italy

**Aim:** the aim of the study is to describe a clinical case of the surgical treatment of a pyogenic granuloma in a pregnant woman. The pyogenic granuloma represent an exuberant connective tissue proliferation to a initial known stimulus or a trauma.

**Methods:** during pregnancy, endocrine and immune changes can impact on the clinical course of various diseases. Due to the formation of a different biofilm, the inflammation of the periodontal tissues increases dramatically in severity during the course of a normal pregnancy, so this hormonal changes caused by puberty or pregnancy may modify the gingival reparation response to injury, producing a lesion. A 27-year-old pregnant woman at the third trimester came to the Department of Dentistry of the IRCCS San Raffaele Hospital with a sessile lesion. The patient was asymptomatic, but referred complaint in normal oral activities. The intraoral examination led the surgeon to a diagnosis of follicular odontogenic cyst to be confir-

med by histological analysis. The treatment plan consisted in a surgical excision of the lesion.

Local anesthesia was administered using 2% lidocaine conforming the other guidelines, then the excision was executed using a n° 15 B-P scalpel, through palatal approach.

As the lesion was sessile, the surgeon proceeded to the incision of the peduncle followed by a curettage of the gingival sulcus. The lesion was sent to the pathological anatomy laboratory for an histological examination. A compression suture was performed to control bleeding. One week after the suture was removed.

**Results:** the histological examination confirmed the presumptive diagnosis of pyogenic granuloma. One week later full healing aspect was found.

**Conclusion:** the surgical removal can be considered a predictable surgical option for pyogenic granuloma in pregnant women.

## THE ROLE OF CORTICAL BONE PERFORATIONS: A REVIEW OF THE LITERATURE

Vimercati I., Clauser T.

Department of Biomedical, Surgical and Dental Sciences, University of Milan, Milan, Italy; IRCCS Galeazzi Orthopedic Institute, Milan, Italy

**Aim:** the present review aims to investigate the role of cortical bone perforations in the different methods of bone regeneration in oral surgery.

**Methods:** the search was done using PubMed database, using words "cortical perforation bone regeneration". The search produced 24 results and, from reading the abstract, 7 were selected. A manual search was also done and produced 2 results.

**Results:** the studies come to conflicting conclusions. However, it is difficult to compare the studies with each other, both due to the diversity of the regeneration methods and the heterogeneity of the variables considered (quantity/quality of regenerated bone).

The role of cortical perforation may be different depending on the type of bone regeneration and the presence of non-uniform outcomes makes it difficult to integrate information from the various studies.

It is also necessary to consider the limit given by the fact that most of the studies are carried out on animals, in particular using the calvaria of rabbits or rats as a receiving bed, not comparable to the mandible and upper jaw.

Finally, many studies, considering different times and outcomes, agree that the variables taken into consideration to evaluate the effectiveness of the perforations are better in the short term in the test group than in the control, while in the

long term the differences between the two groups are no longer significant.

However, all studies are in agreement on the absence of negative effects of perforations.

**Conclusion:** the literature does not show strong evidence of the efficacy of cortical bone perforations, however since they do not bring any side effects, it is up to the surgeon to choose whether to use them or not, based on clinical preferences.

## SURGICAL EXCISION OF TWO MAXILLARY LESIONS CASE REPORT WITH A 3- YEARS FOLLOW-UP

Viti G., Cardilli M., Panerai F., Pensa V., Raimondi Lucchetti F.<sup>1</sup>, Vinci R.<sup>2</sup>

<sup>1</sup>Resident doctor, Oral Surgery Postgraduate School

<sup>2</sup>Director of Oral Surgery Postgraduate School, Associate Professor, Vita-Salute San Raffaele University

Oral Surgery Postgraduate School, Department of Dentistry, Vita-Salute San Raffaele University, IRCCS San Raffaele Hospital, Milan, Italy

**Aim:** the purpose of this clinical report is to present a calcifying cystic odontogenic tumor and a phlogosed root cyst in the maxilla, surgically treated by excisional biopsy in a 68 years old patient with a 3-years follow-up.

**Methods:** after a clinical and radiological examination, two osteolytic lesions (one located in the I quadrant from the element 12 to 13 and the second one located in the II quadrant from element 24 to the left maxillary tuber) have been noticed. Therefore, the surgical excision of both lesions consisted of a longitudinal incision with preservation of the papilla in I quadrant and a full-thickness triangular flap with mesial releasing incision in the II quadrant. The lesions were disconnected from the surrounding bony tissues and cautiously removed, to preserve as much bone tissues as possible. Together with the lesion of the first quadrant, the root of element 12, affected by a Miller class III mobility, was also extracted, since it was in-

involved in the lesion. Finally, we performed a review of the cavities noticing that the lesion of the II quadrant was located anterior to the maxillary sinus not into direct contact with it. Collagen sponges were inserted and a resorbable 4/0 suture was performed to close the wound. Eventually the sample was sent to the Pathological Anatomy Department for histological analysis.

**Results:** the histological examination indicated that the lesion in the I quadrant was a 1 cm phlogosed root cyst, while the one in II quadrant was a 2 cm calcifying cystic odontogenic tumor. At the 3-years follow-up visit complete soft tissues healing and a steady and significant reduction in radiolucency were observed, still without any lesion recurrence.

**Conclusion:** precise and accurate pre-surgical evaluation joined with timely intervention can lead to complete healing and optimal preservation of both soft and hard residual structures.

## ACCURACY OF INTERDENTAL CAVITY MEASUREMENTS PERFORMED ON DIGITAL RADIOGRAPHS

Malaguti F.<sup>1</sup>, Chinellato V.<sup>1,2</sup>, Miola J.<sup>1,3</sup>, Borella A.<sup>1,4</sup>, Farina R.<sup>1,5,6</sup>

<sup>1</sup>Degree Course in Dentistry and Dental Prosthetics, University of Ferrara, Ferrara, Italy

<sup>2</sup>Private Pratiche, Mestre, Italy

<sup>3</sup>Private Pratiche, Belluno, Italy

<sup>4</sup>Private Pratiche, Padua, Italy

<sup>5</sup>Interdepartmental Research Center for the Study of Periodontal and Peri-implant Diseases, University of Ferrara, Ferrara, Italy

<sup>6</sup>Operative Unit of Dentistry, Local Health Unit (AUSL), Ferrara, Italy

**Aim:** the aim of the present study was to evaluate the accuracy of linear radiographic measurements of artificial interdental cavities.

**Methods:** for the study, 9 posterior teeth extracted for periodontal reason were used. Each tooth was mounted in a plaster support. At the mesial and distal aspect of each crown, two artificial cavities were made using cylindrical burs of different diameters, which were mounted on a calibrated milling machine. For each tooth, radiographs were then taken with each of the following radiographic systems: analogic, PSP, and CCD. Two radiographs were taken with each system: one with the interposition of plexiglass between the X-ray tube and the radiographic device to simulate the presence of perioral soft tissues, the second without the interposition of plexiglass. Analogic radiographs were digitized. Each digitized analogic image as well as each radiographic

image obtained with either PSP or CCD systems was calibrated. On each image, a calibrated and blind operator measured the apico-coronal and mesio-distal dimensions of each cavity.

**Results:** the study showed that: 1) linear measurements of artificial interdental cavities of known size performed on radiographs taken with the three investigated systems are characterized by low average errors; 2) the magnitude of the variability of these errors may be clinically relevant, exceeding 0.5 mm and, therefore, representing a relevant aspect in identifying the most accurate system; 3) CCD system is characterized by a non-significant tendency to show higher accuracy than the other two systems.

**Conclusion:** similar accuracy was observed for linear measurements of artificial interdental cavities performed on radiographs taken with the three investigated systems.

## MECHANIC FRACTURE ON ENDODONTICALLY TREATED PREMOLARS UNDER CYCLIC FATIGUE LOADING

Lo dato V.<sup>1</sup>, Gallicchio V.<sup>1</sup>, Cafasso M.<sup>1</sup>, Cerner a M.<sup>1</sup>, Simeone M.<sup>1</sup>, De Santis R.<sup>2</sup>

<sup>1</sup>Department of Neurosciences, Reproductive and Odontostomatological Sciences, University of Naples Federico II, Naples, Italy

<sup>2</sup>Institute of Polymers, Composites and Biomaterials-National Research Council of Italy, Naples, Italy

**Aim:** endodontic treatment decreases the resistance of teeth under cyclic loading, leading to an increased risk of fracture. This chance is drastically reduced when respecting the anatomy of the root canals and using dental posts. The aim of this study is to compare the mechanical properties of teeth restored with different endodontic posts and a control group.

**Methods:** 15 maxillary premolars extracted for orthodontic treatment and with 2 distinct root canals and have been selected. Specimen were root canal treated and divided in 3 groups: group A treated with hollow posts TECHOLE, group

B with standard posts TECH21 and group C, the control group, treated without posts. Standardized MOD cavities were prepared and then restored with bulkfill composite SonicFill2. The samples were subjected to cyclic loading and to compression tests. Data were statistically analyzed.

**Results:** group A teeth bear higher loads than the group B teeth. Both the groups bear a much higher loads than group C.

**Conclusion:** no statistically significant difference was found between the use of hollow posts and standard post. Teeth treated with hollow or standard posts have an increased fracture resistance compared to the control group without posts.

## CLASS V RESTORATION ACCORDING TO BOPT TECHNIQUE: A CASE REPORT WITH A 36 MONTHS FOLLOW-UP

Certera M.<sup>1</sup>, Maglito M.<sup>1</sup>, Lodato V.<sup>1</sup>, Valletta A.<sup>1</sup>, Barbarulo F.<sup>2</sup>

<sup>1</sup>Department of Neurosciences, Reproductive and Odontostomatological Sciences, University of Naples Federico II, Naples, Italy

<sup>2</sup>Private Practice, Salerno, Italy

**Aim:** carious and non-carious Class V lesions represents an increasingly frequent issue affecting teeth. According to BOPT technique our case report describes a new skill used in the treatment of Class V non carious lesion.

**Methods:** a female patient referred to our Department affecting by a non-carious lesion on the right upper first premolar. The first step was the colours choice of restored tooth. After a gingival retraction cord was positioned. The next step was the cavity preparation. Later contour strip matrix and liquid dam were applied. We then proceeded by implementing the adhesive procedures using a 3-step system. Nano-filled composite (Clearfil majesty es-2 premium Kuraray) was added adjusting the proportions of the enamel and dentin masses according to the characteristics of the tooth. This technique allowed the restoration not simply filling the cavity, but creating a new dental morphology: the composite was

in fact overfilled. During the second therapeutic phase, a gingiva with coronal repositioning and suspended polyamide sutures were performed. Sutures were removed after 10 days.

**Results:** according to this new approach, the restoration should be intentionally overcontoured, in order to create a 60° angle between the restoration emergence profile and the tooth. Such emergence profile should allow a better gingival tissue adaptation while promoting soft tissue health. After 36 months of follow up, clinical examination showed a perfect fitting between restoration and periodontal tissue.

**Conclusion:** cervical restorations require a strict compliance of adhesive protocols, from surgical field isolation onwards. Moreover, periodontal tissues should never be neglected, and protecting their health must always be the primary focus of our efforts, since their conditions are indicative of treatment success.

## OPEN VS CLOSED SANDWICH IN CERVICAL MARGIN RELOCATION: A FEM STUDY

Ferrero G., Italia E., Baldi A., Comba A., Scattina A., Peroni L., Pasqualini D., Alovise M., Berutti E., Scotti N.

Department of Surgical Sciences, Dental School, University of Turin, Turin, Italy

**Objectives:** to study the influence of new highly-filled composite, nano-filled packable composite and lithium disilicate, in cervical margin relocation, using finite element method (FEM).

**Methods:** two standardized class II cavities, one mesial and one distal, were created on the specimen. The mesial cavity cervical margin was set 1 mm above the CEJ, while the distal one was set 1 mm below the CEJ. After it was scanned with microCT, reconstructed and imported into a FEM-analysis software. The specimen was segmented in the three parts, in order to simulate different material combinations: Model A: the entire restoration was simulated with lithium silicate; Model B: the entire restoration was simulated with nano-filled conventional packable composite; Model C: a 1.5mm thick horizontal layer of highly-filled flowable resin was simulated as a first layer, over the cervical margin; the remaining restoration was simulated with nano-filled traditional composite; Model D: same scenario of model B, but with 3mm of highly-filled flowable composite. The FEM simulation was made with a progressive load up to 50N.

**Results:** under interface normal pressure, in the distal box, model D has shown the less stress, while in distal box the Model A has shown the maximum stress. Under shear stresses, in the mesial box, appears to be higher in Model A, while in the mesial box, also the Model A has shown the maximum stress. In general, all the tested scenarios presented similar stress-distribution patterns of tensile and shear stresses. Maximum peaks of load, for what concern shear stresses, were found to be located mostly among dentin-enamel interface. On the other hand, tensile forces were most concentrated in the inner area of the cervical floor of the tooth-restoration interface.

**Significance:** this study shows that the FEM can be efficiently implemented with micro-CT in order to create realistic dental models. It can also be concluded that on dentinal margins the best restorative material is elastic highly-loaded flowable resin composite. On the other hand, when dealing with enamel margins ceramic can be used as well and has been proved to efficiently preserve cervical margin area.

## SURFACE ROUGHNESS AND HARDNESS EVALUATION OF TWO COMPOSITES AFTER AGING IN DRINK SOLUTIONS

Generali L.<sup>1</sup>, Franceschetti F.<sup>1</sup>, Mazzoni A.<sup>2</sup>, Breschi L.<sup>2</sup>, Giannetti L.<sup>1</sup>, Consolo U.<sup>1</sup>, Checchi V.<sup>1</sup>

<sup>1</sup>Department of Surgery, Medicine, Dentistry and Morphological Sciences with Transplant Surgery, Oncology and Regenerative Medicine Relevance, University of Modena and Reggio Emilia, Modena, Italy

<sup>2</sup>DIBINEM, University of Bologna, Bologna, Italy

**Aim:** the aim of this study was to investigate the effects of artificial saliva and drink solutions on surface roughness and hardness of 2 composites: Herculite XRV (HXRUV) and Harmonize (HZ) after one month aging.

**Methods:** fifty-four composite specimens were prepared in an oxygen-free environment and polymerized. Six specimens were immediately investigated (T0), while forty-eight specimens were soaked into different drink solutions (artificial saliva, cola, ethanol), sealed into PET bottles and incubated at 37°C. Control specimens were kept in air. Specimens evaluation was made at T0 (n = 6), after 1 week (T1) (n = 24) and 4 week (T2) (n=24). Twenty-four samples (HXRUV = 12, HZ = 12) were analyzed with an optical microscope equipped with a Confovis-structured-light camera used as profilometer. This system digitally elaborates a known size grid projected on the surface

to be analyzed in order to evaluate the differential interference contrast. Twenty-four samples (HXRUV = 12, HZ = 12) underwent instrumented (depth-sensing) indentation test to evaluate the hardness at room temperature.

**Results:** concerning surface roughness analysis, statistically significant differences were observed in HZ group after aging in ethanol between T0, T1 and T2. Statistically significant differences were observed in HXRUV group after aging in cola between T0 and T2, while in ethanol cola between T1 and T2. Concerning surface hardness analysis, HZ group showed a decrease in all the tested drink solutions, while HXRUV showed a significant decrease after soaking in ethanol.

**Conclusion:** this study showed that HZ is more subject to surface roughness and hardness after aging in ethanol if compared to HXRUV.

## EFFECT OF DIFFERENT PRISMLESS ENAMEL TREATMENTS ON BOND STRENGTH AND SURFACE MODIFICATION

Garavelli M.<sup>1</sup>, Comba A.<sup>1</sup>, Mazzitelli C.<sup>2</sup>, Baldi A.<sup>1</sup>, Maravic T.<sup>2</sup>, Breschi L.<sup>2</sup>, Mazzoni A.<sup>2</sup>, Scotti N.<sup>1</sup>

<sup>1</sup>Department of Surgical Science, University of Turin, Turin, Italy

<sup>2</sup>DIBINEM, University of Bologna, Bologna, Italy

**Aim:** several pretreatment has been identified as a method to increase the adhesive bond strength in intact aprismatic enamel. The purposes of this study were to evaluate the effect of different powders and bonding systems on shear bond strength of prismless enamel and to evaluate the effect of pretreatments on the surface. The null hypothesis tested were that there were no differences in bond strength regardless 1) to the surface pretreatment; 2) to the adhesive system employed.

**Methods:** hundred-twenty human upper incisors were assigned to five different groups and pretreated with: no treatment, glycine, sodium bicarbonate, aluminum oxide and extra fine bur. Then teeth were divided into three subgroups, according to the adhesive system applied: 3-step ER (etch-and-rinse), universal adhesive in ER mode and universal adhesive in SE mode. Shear bond strength (SBS) test was performed with a

universal testing machine. For SEM observation, fifteen human molars were collected and analyzed after pretreatment and after pretreatment and etching with 37% H<sub>3</sub>PO<sub>4</sub> for 30s.

**Results:** aluminum oxide showed higher MPa than all other groups considered. Comparable SBS values were obtained for other pretreatments. Universal adhesive in ER mode performed better than 3-step ER and universal adhesive in SE mode. The SEM observation showed visible differences on enamel surface roughness.

**Conclusion:** sandblasting with aluminum oxide followed by etching with H<sub>3</sub>PO<sub>4</sub> increased SBS on aprismatic enamel. The combination of sandblasting with alumina powder followed by 15s of H<sub>3</sub>PO<sub>4</sub> etching and application of a universal adhesive in ER mode revealed to be the more effective protocol for adhesion.

## POST-ORTHODONTIC RECONTOURING USING THE INJECTION RESIN TECHNIQUE

Geretti G., Di Lenarda R., Contardo L., Marchesi G.

Department of Medical Science, Surgery and Health, University of Trieste, Trieste, Italy

**Aim:** to present a versatile, rapid and effective technique for post-orthodontic recontouring of lateral upper incisors using flowable composite and a PVS matrix.

**Methods:** a 15-years old female patient presented at the end of the orthodontic treatment with microdontia of the lateral upper incisors. The integrity of the enamel suggested a minimally invasive adhesive technique with a “no prep” approach and the “Injection Resin Technique” was chosen. Alginate impressions of both arches were recorded for the realization of the diagnostic wax-up. A clear PVS impression material was used to replicate the wax-up, thus obtaining a clear matrix and two small openings were made to allow insertion of the composite tip.

The unprepared teeth were submitted to the adhesive protocol, the clear matrix was positioned and an A2-shade flowable resin composite was injected in a controlled manner, taking care to avoid bubbles formation. The resin was light-cured through the PVS matrix for 2 minutes, then without it for 2 more minutes. Composite excesses were removed using a #12 scalpel blade and the restorations were finished and polished.

**Results:** one week after treatment, the patient was called back for a subsequent polishing session and was extremely satisfied with the treatment.

**Conclusion:** sst and minimally invasive solution to complete the aesthetic result of the orthodontic treatment.

## SPLIT-MOUTH CLINICAL TRIAL AND WEAR ANALYSIS IN DIRECT POSTERIOR RESTORATIONS

Italia E., Ferrero G., Baldi A., Comba A., Pasqualini D., Alovisi M., Berutti E., Scotti N.

Department of Surgical Sciences, Dental School, University of Turin, Turin, Italy

**Aim:** the aim of this study was to compare clinical performances and wear pattern of two different nanohybrid resin-based composite materials used, Admira Fusion a ormocer and Tetric Evo-Ceram, for restoring class II posterior restorations during a 3-years follow-up period.

**Methods:** a total of twenty-five patients ( $n = 25$ ). Overall, 15 females and 10 males were selected for a total of 50 restorations performed (equally divided among Admira Fusion and Tetric Evo-Ceram). 23 restorations were performed on premolars and 27 on molars. At 3 years follow-up, all patients were recalled and visited by two blinded calibrated operators, who recorded SQUACE and FDI criteria. Moreover, impressions were taken and then scanned for the evaluation of occlusal wear.

**Results:** as regards the FDI AND SQUACE criteria, slight yellowing effect was observed in Admira Fusion group after

3-years even if the material maintained a good superficial texture. On the other side, Tetric Evo Ceram showed a worse surface texture which led to an increased superficial discoloration due to extrinsic pigment absorption which could eventually be removed with composite re-polishing. For the wear analysis, two-way ANOVA test showed a significant influence of the factor subgroup, with molars showing greater wear compared to premolars ( $p < 0.001$ ). On the other hand, no significant differences were reported among tested groups. Obtained values for each group and subgroup, expressed in  $\text{mm}^3$ .

**Conclusion:** clinical performances with a three-year follow-up is worse in restorations with TetricEvoCeram compared to Admira Fusion, while there is no statistically significant difference in the wear of the occlusal surfaces.

## LONG-TERM MANAGEMENT OF DENTAL TRAUMA INVOLVING UPPER CENTRAL INCISORS: A CASE REPORT

Lipari F.<sup>1</sup>, Bruno G.<sup>2</sup>, Lussi C.<sup>1</sup>, Lo Giudice R.<sup>3</sup>

<sup>1</sup>Department of Biomedical, Dental Sciences, Morphofunctional Imaging, University of Messina, Messina, Italy

<sup>2</sup>Private Practice, Messina, Italy

<sup>3</sup>Department of Biomedical, Clinical and Experimental Sciences, University of Messina, Messina, Italy

**Aim:** dental traumas frequently occur among school-age children and they often involve upper central incisors. This case report shows the long-term management and multidisciplinary treatment of a complicated crown-root fracture on a tooth 2.1 and an uncomplicated crown-root fracture on a 1.1.

**Methods:** in 2011, a 7 y.o. female patient was affected by a trauma involving the upper central incisors. The clinical and radiographic examinations showed an uncomplicated crown-root fracture on the upper right central incisor and a complicated crown-root fracture on the upper left central incisor. Pulpotomy and direct pulp capping with MTA was performed in 2.1, followed by temporary resin-modified glass-ionomer restorations on 2.1 and 1.1. The tooth fragments were available and they were stored. Eight months later the fragments were reattached. Periodical vitality tests were positive. In 2013 a ceramic veneer was realized on 2.1. A 2-years follow-up showed

no loss of vitality. In 2015 the patient started orthodontic treatment, including slow orthodontic extrusion of 2.1, which ended in 2017. In 2019 a gingivectomy and gingivoplasty treatment was performed. In 2021 the tooth 2.1 was rehabilitated with a full ceramic crown.

**Results:** the multidisciplinary treatment approach and the long-term management reported in this clinical case showed to be effective. Pulp vitality of 2.1 was successfully preserved and complete root formation was achieved. Over 9 years post-treatment, the tooth displayed no adverse signs or symptoms clinically or radiographically.

**Conclusion:** the approach of dental traumas in children should consider the age and the development of the patient. Whenever the tooth fragment is available, it is a valuable choice to reattach it. Preserving pulp vitality is important. Necrosis may occur, so the pulp vitality follow-up must be made.

## RETREATMENT OF POSTERIOR ELEMENTS INADEQUATE RESTORATION: A CASE REPORT

Cernera M.<sup>1</sup>, Maglito .<sup>1</sup>, Cafasso M.<sup>1</sup>, Barbarulo F.<sup>2</sup>

<sup>1</sup>Department of Neurosciences, Reproductive and Odontostomatological Sciences, University of Naples Federico II, Naples, Italy

<sup>2</sup>Private Practice, Salerno, Italy

**Aim:** tooth anatomy is essential for the mechanical food breakdown, but also for the preservation of periodontal tissues. The aim of this case report is to demonstrate how a functionally and aesthetically composite restorations can improve gingival health.

**Methods:** a Caucasian male patient who came to our Department, referred pain and gingival swelling due to inadequate previous restorations. The fillings were removed along with demineralized enamel and decalcified dentin. At the bottom of the cavity Teflon was placed. Light-curing composite resin system (Quicks Flow, Dentkist) was used as temporary filling. After 2 weeks gingival health was restored, allowing the clinicians to continue the treatment. Rubber dam was placed and sectional Matrix System Palodent V3 along with wedges (Palodent Plus) and Teflon pellets were used to create ideal contacts. Selective enamel etching was performed and adhesive system Prime-

Bond Active (DENTSPLY) was applied. Marginal ridges were restored with incremental layering technique and flow composite (SDR) was applied keeping the tip close to the cavity floor in order to minimize air entrapment. Dentinal structures were restored with Ceram.X® Universal D3 Dentin Shade. E3 high translucency composite was finally used to repair the external enamel layer.

**Results:** at the end of the treatment, correct dental anatomy was achieved. After 3 months follow up, the clinical examination showed no signs of gingival inflammation.

**Conclusion:** the treatment plan required a healing time of 2 weeks to obtain the ideal condition for a proper restoration able to solve the problems referred by the patient. This case report demonstrates how the improvement of gingival health can be achieved through the correct and functional anatomy of the restorations.

## THE ENDOCROWN BIOMECHANICS: INFLUENCE OF AXIAL DIVERGENCE AND FILLING MATERIAL

Lo Giudice R.<sup>1</sup>, Tribst J.P.M.<sup>2</sup>, Souto Borges A. L.<sup>3</sup>, Silva-Concilio L. R.<sup>2</sup>, Amaral M.<sup>2</sup>, Puleio F.<sup>4</sup>

<sup>1</sup>Department of Human Pathology in Adulthood and Childhood G. Barresi, University Hospital G. Martino of Messina, Messina, Italy

<sup>2</sup>Postgraduate Program, School of Dentistry, University of Taubaté, Taubaté, São Paulo, Brazil

<sup>3</sup>Institute of Science and Technology, São Paulo State University (Unesp), São José dos Campos, São Paulo, Brazil

<sup>4</sup>Department of Biomedical and Dental Sciences and Morphofunctional Imaging, University of Messina, Messina, Italy

**Aim:** endocrown restorations have been reported as promising treatments to rehabilitate extensively damaged endodontically treated teeth. The aim of this study is to evaluate the effect of pulp chamber angle and filling material in the endocrown biomechanical behavior.

**Methods:** a model of maxillary molar with endodontically treatment was selected in the CAD software to perform the 3D- finite element analysis (FEA). The endocrown received different pulp chamber angles (right angle; 6, 12 and 18 degrees of axial divergence). The geometries were imported to the analysis software and nine different filling materials were simulated to seal the orifice of root canal system. The bone has been fixed and 300 N axial load applied at the occlusal surface. Results were determined by stress maps using von-Mises criterion (VMS) and Maximum Principal Stress (MPS) on tooth, cement layer, and endocrown restoration.

**Results:** VMS results showed a similar pattern regardless the models, with high stress at the loaded region for the right-angled endocrowns. The MPS showed that the cement layer and endocrown intaglio surface can present a different biomechanical behavior according to the different filling materials and pulp chamber angle. The stress peaks showed that the filling material elastic modulus is proportional to the stress magnitude in the adhesive interface. Therefore, 6 and 12 degrees pulp-chamber angles showed a balance between the stresses of the analyzed regions.

**Conclusion:** when an endocrown restoration is planned, the dentist should prefer a flexible filling material to seal the orifice of root canal system. In addition, the pulp chamber axial walls should be limited to 6 and 12 degrees of divergence to avoid unwanted stress concentration in the adhesive interface.

## A MINIMALLY INVASIVE MULTIDISCIPLINARY APPROACH TO THE ESTHETIC REHABILITATION OF MAXILLA

Sawadogo V., Drago G., Venuleo A., Stellini E.

Department of Neuroscience, U.O.C. of the Odontostomatological Clinic, University of Padua, Padua, Italy

**Aim:** the patient, a 52 years old woman, comes to our attention for dental evaluation in order to rehabilitate the front teeth from the aesthetic point of view. After physical and radiographic examination are found agenesis of elements 12 and 22 and dentoalveolar discrepancy with multiple diastemas.

**Methods:** the patient desire is to improve smile's aesthetics but requires not to perform any orthodontic therapy. After the case study we have chosen to treat the specific case with direct restorations using composite layers with the adhesive technique, so it was possible to close the diastemas. The diagnostic wax-up and the silicone key are made in the laboratory and will be used to recreate the correct dimensions of the direct restorations with the use of the Bolton index and a correct evaluation and realization of the transition lines. Element 13 is located in position 12 and will be transformed into a lateral incisor while in position 22 the missing lateral incisor will be re-

placed with a Maryland Bridge made with direct technique starting from the metal structure built by the technician in the laboratory.

**Results:** with a quick and minimally invasive intervention, we were able to achieve the harmony of the patient's smile and satisfy the patient's aesthetic requests without excessive financial commitment. The patient could not sustain an implant supported prosthetic rehabilitation as she had neither sufficient space / bone nor the financial possibility.

**Conclusion:** only orthodontic therapy is not the optimal solution to improve the smile's aesthetics in cases where the presence of diastemas is caused by a dentoalveolar discrepancy as can be found by analyzing the Bolton index, in these cases it is useful to use a multidisciplinary treatment. To improve the result it is possible to use minimally invasive restorative techniques with which we can improve a lot the smile's aesthetics.

## TELEDIAGNOSIS FOR DETECTING CAVITIES: AN OBSERVATIONAL TRASVERSAL STUDY

Simoncelli F., Rosolin L., Poscolere A., Zotti F.

Department of Surgical Science, Dentistry, Paediatrics and Gynecology, University of Verona, Verona, Italy

**Aim:** the primary aim of this study is to assess the feasibility of telediagnosis in detecting dental caries and compare it with clinical diagnosis. Secondary aim is to evaluate the sensitivity of telediagnosis on detecting the different location of cavities.

**Methods:** 10 patients, aged 23 to 30, were recruited for the study. Participation consisted in two phases: 1) they had to send photographs of their teeth according to the protocol we administered and 2) they had to undergo a clinical visit performed by an experienced clinician.

Photographs required had to be taken as follows: in a lit room, using a smartphone with a camera (least 10mpx), 5 different perspectives (frontal, upper occlusal, lower occlusal, right vestibule and left vestibule), with and without flash, so 10 photos overall were received by e-mail from each patient, of which the best 5 were selected for the study.

Cavities of the same patient were diagnosed based on photographs and on clinical visit. ICDAS score was used to evaluate

the severity of the cavities, the lesions location were also noticed both in the pictures and in the clinical visit. Spearman's correlation coefficient was run to evaluate the availability of two different methods in assessing dental caries.

**Results:** 100 photos were sent from 10 patients, telediagnosis was performed on 50 photographs and 10 patients were visited. The overall number of analyzed teeth was 280. The Spearman's correlation was 0,668, indicating a good association between telediagnosis and clinical diagnosis of dental caries. Lesions better detected on the photographs were found those located on occlusal surfaces together with those located on the vestibular surfaces of anterior teeth.

**Conclusion:** telediagnosis of dental caries seems to be a valuable way of diagnosis, especially for advanced cavities and sound teeth. It could improved and a better way to take photographs might be developed.

## DIRECT ANTERIOR RESTORATION: A STEP BY STEP GUIDE LOOKING TO MIMETIC AIM

Solimena A., Salucci A., Di Giorgio G.

Department of Odontostomatological and Maxillofacial Sciences, School of Specialization in Pediatric Dentistry, Master in Odontostomatology in the Evolutionary Age, Sapienza University of Rome, Rome, Italy

**Aim:** the aim of this case report is to illustrate how it is possible to obtain an optimal mimesi of composite restorations in the anterior teeth, following standard techniques and knowingly using new universal composites.

**Methods:** a male patient had a trauma on element 1.1 resulted in the fracture of the incisal third. An old restoration was on 1.1 incisal margin. The case was set up taking care of optimal rubber dam field isolation. At the baseline, a wax up and a silicon key index were done. After preparing the teeth and removing

the old restoration, we put on few layers of universal composites on the enamel palatal shell, modelling anatomy. Finishing and polishing were the last steps.

**Results:** excellent mimesi was reached, just using few standard steps and selected equipment.

**Conclusion:** contemporary materials, like the latest universal composites, are imposing new standards to the possibilities of anterior restoration successful rate. Less steps, less time on chair, more predictability of mimesi.

## X-RAY MICRO-COMPUTED TOMOGRAPHY IN RESTORATIVE DENTISTRY: A MINI-REVIEW

Tosco V., Monterubbianesi R., Vitiello F., Furlani M., Procaccini M., Giuliani A., Orsini G., Putignano A.

Department of Clinical Sciences and Stomatology, Polytechnic University of Marche, Ancona, Italy

**Aim:** this mini-review describes the possible applications of micro-computed tomography ( $\mu$ -CT) in restorative dentistry, especially for the evaluation of novel bulk-fill resin-based composites (BFCs).

**Methods:** the present review was conducted using the following databases: PubMed, Web of Science, the Cochrane Library, Scopus, Google Scholar.

**Results:** nowadays, BFCs became increasingly popular due their superior physical and chemical characteristics. BFCs allow to place and sculpt the composite in one single layer up to the occlusal surface, restoring the cavity by a more time-efficient bulk fill technique. Despite these excellent properties, the polymerization shrinkage stress and the marginal gap formation or microleakage still represent an important concern. Current methods to determine the polymerization shrinkage stress and the microleakage at the tooth-composite interface are qualitative

or semi-quantitative. To overcome these problems, several previous studies have introduced 3D imaging technique by means of  $\mu$ -CT. The  $\mu$ -CT allows to determine and visualize polymerization shrinkage stress and marginal adaptation and its distribution at the interface of cavity wall and composite restoration in model cavities. Due to the penetrating capacity of x-rays,  $\mu$ -CT represents a reliable device for a non-destructive acquisition of precise information of the internal restoration features regardless sample's shape or dimensions. The high-resolution 3D imaging lets to define small objects with a high level of spatial resolution as it corrects the artefacts caused by air bubbles and provides accurate images similar to those obtained by dye penetration.

**Conclusion:** although further studies are needed, there is consistent new scientific literature that supports the validity of  $\mu$ -CT approach for a non-destructive evaluation of the modern resin-based composites.

## TEETH RECONTOURING AFTER ORTHODONTIC TREATMENT TO ACHIEVE A PLEASANT SMILE: A CASE REPORT

Venuleo A., Drago G., Caburlotto A., Bressan E., Stellini E.

Department of Neurosciences, University of Padua, Padua, Italy

**Aim:** the aim of this paper is to introduce a case report about the usage of direct composite resin restorations to improve anterior aesthetics after orthodontic treatment.

**Methods:** a 32 years old patient asked for the alignment of the upper arch in order to improve the aesthetics of the anterior teeth.

After the diagnosis was made, invisible aligners were chosen, in order to meet the aesthetic needs of the patient. Once the orthodontic treatment was completed, the patient was sent for the restoration in order to improve aesthetic results. A diagnostic wax-up and a silicon index were made in order to aid

the clinician in carrying out the direct composite resin restorations. Function, shape and aesthetics were adequately restored following non-invasive principles.

**Results:** the patient was pleased with the final results and thankful for high aesthetic standards obtained, without sacrificing the structural and biological aspects of her dentition.

**Conclusion:** when Bolton discrepancies and bad shape are detected, orthodontic intervention alone can't establish a satisfactory aesthetic result. Progress in composite technology has made it possible to reshape teeth with aesthetically pleasing results almost imperceptible to the human eye.

## FAILURE LOAD OF HEAT-PRESSED LDG TABLE-TOP RESTORATIONS WITH TWO PREPARATION DESIGNS

Angerame D.<sup>1</sup>, Zanin R.<sup>1</sup>, Turco G.<sup>1</sup>, Porrelli D.<sup>1</sup>, Zarone F.<sup>2</sup>, Sorrentino R.<sup>2</sup>, Marchesi G<sup>1</sup>.

<sup>1</sup>Clinical Department of Medical Science, Surgery and Health, University of Trieste, Trieste, Italy

<sup>2</sup>Department of Neurosciences, Reproductive and Odontostomatological Sciences, University of Naples Federico II, Naples, Italy

**Aim:** to assess the fracture resistance of maxillary molars restored using heat-pressed lithium disilicate glass-ceramic (LDG) table-top restorations with two preparation designs.

**Methods:** sixteen maxillary molars were randomly assigned to two groups (n = 8): Group 1 (G1) occlusal preparation for a 1 mm full-coverage table-top restoration with a 90° rounded shoulder margin; Group 2 (G2) 1 mm occlusal reduction with a marginal chamfer. Restorations were obtained by heat-pressed lithium disilicate glass-ceramic (LDG) and luted with Variolink II cement. The specimens were loaded to fracture after thermomechanical aging (1 250 000 cycles). A qualitative

analysis on the type of fracture and a SEM analysis of marginal seal were conducted. Collected data were statistically analyzed (Mann Whitney U-test).

**Results:** the mean load to fracture was  $1796.58 \pm 307.27$  N in G1 and  $1892.77 \pm 379.40$  N in G2. No statistical difference was found. Six specimens showed restorable fractures in G1, 4 specimens in G2. Thermomechanical aging did not produce marginal seal degradation.

**Conclusion:** the two preparations designs for LDG table-top restorations exhibited a similar load resistance, type of fracture and marginal adaptation.

## CLINICAL STRATEGIES TO MANAGE EXTERNAL INVASIVE CERVICAL RESORPTION: A SYSTEMATIC REVIEW

Bardini G., Orrù C., Musu D., Mezzena S., Cotti E.

Department of Conservative Dentistry and Endodontics, University of Cagliari, Cagliari, Italy

**Aim:** an increasing number of cases of external cervical resorption (ECR), are being constantly diagnosed. Given the variety of ECR defects, the purpose of this review is to evaluate the therapeutic approaches reported in the literature to assess if there is a prevalent treatment plan.

**Methods:** an electronic systematic search, using a set of mesh terms, was conducted in PubMed, Scopus and Web of Science. Two reviewers independently performed data extraction and quality assessment. Disagreement were resolved by a third reviewer.

**Results:** based on the inclusion criteria, 88 of 815 articles obtained, that were of moderate to high quality, were selected. Available scientific evidence shows that the approach most

frequently used to treat ECR was surgical external (38%), (Heithersay class 3) followed by internal treatment (27%), (class 4), and by a combination of both (17%). The defects were prevalently treated by excavation (manual, ultrasonic, rotary), alone or in combination with inactivating chemicals. In most cases the defect was seal with a sandwich technique, followed by composite resins, bioactive and glass-ionomer cements. According to the follow-up (mean of 31,73 months), available in most cases, failure was > 10%.

**Conclusion:** thanks to a better understanding of the condition and to the new technologies, most cases of ECR are successfully treated in clinical practice.

## CYTOTOXIC AND ANTIMICROBIAL EFFECTS OF PHYTIC ACID AND BIOAKT®: AN *IN VITRO* STUDY

Bertoletti P.<sup>1</sup>, Tonini R.<sup>1</sup>, Forgione D.<sup>1</sup>, Salvadori M.<sup>1</sup>, Lin S.<sup>2</sup>, Salgarello S.<sup>1</sup>

<sup>1</sup>Department of Medical and Surgery Specialities, Radiological Sciences and Public Health, Dental School, University of Brescia, Brescia, Italy

<sup>2</sup>Department of Endodontics, School of Graduate Dentistry, Rambam Health Care Campus, Haifa, Israel

**Aim:** the aim of this study is to compare Phytic acid (IP6) and BioAkt® with Sodium Hypochlorite, evaluating cytotoxicity and antimicrobial capacity, in order to find an alternative endodontic irrigant in the field of regenerative endodontics.

**Methods:** murine macrophages cell line J774A.1 and *Enterococcus faecalis* HH22 were used in the present study and five types of solutions were prepared for the tests: IP6 1%, IP6 3%, IP6 5%, BioAkt® (pure, 100%), Sodium Hypochlorite 1,5%. Two different cell viability tests were performed: Crystal violet assay, CellTiter-Glo® 2.0 Assay, and three different antimicrobial tests: disk diffusion test, effect of 1h treatment on *Enterococcus faecalis* and minimum inhibitory concentration (MIC).

**Results:** many statistical significances were registered in the comparison between the two considered exposures: 4h and

24h. Mean values decreased significantly in all groups, except for sodium hypochlorite.

The first antimicrobial test showed a statistical significance between BioAkt and 1% IP6 and between 3% IP6 and NaOCl. In the second antimicrobial test, control mean value was higher than 5% IP6 mean value with a statistical significance at level of 5%. BioAkt and NaOCl showed a statistical significance in comparison with control group. The third antimicrobial test was used to calculate the minimal inhibitory concentration (MIC) of the three materials.

**Conclusion:** the preliminary results suggest that both Phytic Acid and BioAkt were statistically more biocompatible than Sodium Hypochlorite even though they were effective in all three antimicrobial tests.

## THE MANAGEMENT OF TYPE II CORONAL *DENS INVAGINATUS*: A CASE REPORT

Lizio A. S.<sup>1</sup>, Lo Giudice G.<sup>1</sup>, Bruno G.<sup>2</sup>, Lo Giudice R.<sup>3</sup>

<sup>1</sup>Department of Biomedical, Dental Sciences, Morphofunctional Imaging, University of Messina, Messina, Italy

<sup>2</sup>Private Practice, Messina, Italy

<sup>3</sup>Department of Biomedical, Clinical and Experimental Sciences, University of Messina, Messina, Italy

**Aim:** *Dens Invaginatus* (DI) is a development anomaly of the tooth. In this Case Report we show the management (diagnosis and endodontic treatment) of a clinical case of Type II Coronal *Dens Invaginatus* (CDI), with one-year follow-up.

**Methods:** a male 18 years old patient is referred to our Department complaining pain in upper anterior right maxillary region. The periapical radiograph shows a Type II *Dens Invaginatus* (Oehlers classification), with a wide periapical radiolucency. CBCT has been performed, confirming the presence of a Type II CDI. The clinical and radiological diagnosis of pulpal necrosis and periapical pathology requires an endodontic treatment after the intussusception complete removal. Endo-

dontic treatment has been performed; MTA was used to obturate the canal.

**Results:** the clinical and radiographic follow-up after 3 months underlines the absence of symptomatology and the initial healing of the periapical radiolucency area. The clinical and radiographic one-year follow-up underlines the absence of symptomatology and the almost complete healing of the periapical radiolucency area.

**Conclusion:** the *Dens Invaginatus* treatment requires rigorous planning based on clinical and radiological examination. The analysis of the long-term results reported in this case report shows the effectiveness of the therapy.

## DENTAL TISSUE CHARACTERIZATION BY FINITE ELEMENT ANALYSIS: A LITERATURE REVIEW

Carpegna G.<sup>1</sup>, Alovisi A.<sup>1</sup>, Scattina A.<sup>2</sup>, Chiandussi G.<sup>2</sup>, Scotti N.<sup>1</sup>, Pasqualini D.<sup>1</sup>, Berutti E.<sup>1</sup>

<sup>1</sup>Department of Surgical Science, Dental School Department of Endodontic and Restorative Dentistry, University of Turin, Turin, Italy

<sup>2</sup>Department of Mechanical and Aerospace Engineering, Polytechnic of Turin, Turin, Italy

**Aim:** finite Element Analysis (FEA) in dentistry is focused on simulation of realistic intra-oral conditions such as nonlinear stress strain relationship. The substrates' characteristics are crucial for the reliability of the virtual analysis. Enamel has the highest values of elastic modulus especially closer to the crown outer surface. Dentin is composed for the 70% of mineral structure, 20% organic material and 10% water. It has different modulus between intertubular and peritubular zone and its mechanical properties are affected to microstructural alteration due to ageing, carious lesions and restorative procedures. A review of the literature was conducted in order to characterize the dental tissue applied in FEA.

**Methods:** PubMed library was used and papers from 2017 to 2020 were analyzed. The articles presented at least one of word

combination in title, abstract or keywords. For papers selection, the studies met the pre-established inclusion/exclusion criteria.

**Results:** 65 articles were selected: 8 records were excluded for duplication, 35 articles were elided after searching for explicit value while 21 papers were included. The mean value for young modulus for enamel and dentin resulted 78,27GPa and 18,19GPa.

**Conclusion:** the tooth microstructure causes considerable variations in the results of experimental measurement of the tooth properties. It is relatively difficult to simplify the material properties without changing the tooth natural behavior. In order to simplify the future biomedical FEA applications, it might be considered to create a specific data library containing the main biomedical tissues' properties.

## INTENTIONAL REPLANTATION OF A MAXILLARY SECOND PREMOLAR: A 6-MONTHS FOLLOW-UP CASE REPORT

Galeano P.<sup>1,2</sup>, Cordaro M.<sup>1,2</sup>, Castagnola R.<sup>1,2</sup>, Zacccone R.<sup>1,2</sup>, Grande N. M.<sup>1,2</sup>, Marigo L.<sup>1,2</sup>

<sup>1</sup>Department of Conservation and Endodontics, A. Gemelli University Hospital Foundation – IRCCS, Rome, Italy

<sup>2</sup>Institute of Dentistry and Maxillofacial Surgery, Catholic University of the Sacred Heart, Rome, Italy

**Aim:** intentional replantation is the deliberate extraction of a tooth that, after evaluation of root surfaces, endodontic manipulation and repair, is reinserted into its original position. This technique can be used in several clinical scenarios when conventional treatment, such as primary root canal treatments, nonsurgical endodontic retreatments or apical microsurgery, cannot be performed. Aim of this work is to describe step by step the procedures applied in a case of intentional replantation performed to treat a tooth with an obliterated root canal.

**Methods:** a 42-year-old patient came to our attention for an abscess of tooth 2.5. After a first failed attempt of primary endodontic therapy and informed patient consent, the intentional replantation was performed. The tooth was extracted with for-

ceps using solely rotary movements. Apicoectomy and retrograde preparation using ultrasonic inserts were performed while holding the tooth firmly. The retrograde filling was carried out using bioceramic material. The tooth was reinserted into the dental alveolus and splinted. The total extra-oral handling time was approximately 14 minutes.

**Results:** clinical and radiological follow-up at 6-month showed a good healing both of the endodontic lesion and extraction site. Our clinical success can be associated with the atraumatic extraction and the rapid and cautious management of the tooth during the extraoral phase.

**Conclusion:** intentional replantation can be a viable way to treat teeth that cannot be predictably treated using conventional endodontic procedures.

## DIFFERENT BUILD-UP PROCEDURES OF ENDODONTICALLY TREATED ANTERIOR TEETH

Corsentino G., Ferrari Cagidiaco E., Pontoriero K.I.D., Ferrari M.

Department of Medical Biotechnologies, Division of Prosthodontics, University of Siena, Siena, Italy

**Objectives:** the aim was to investigate the clinical behavior of endodontically treated (ET) upper anterior teeth (incisors and canines) restored by various fiber-reinforced post-core composites (FRCs) or fiber posts (FP).

**Methods:** 80 ET anteriors, with 50% or less of coronal residual structure, were selected and randomly divided into four groups (n = 20). Group 1: FP GC FIBER POST, GC (FP) luted with GRADIA CORE, GC (GC) + Initial LiSi Press, GC crown luted with G-CEM LinkForce, GC (LF) (as control); Group 2: everX Flow, GC (EXF) core build up + Initial LiSi Press crown luted with LF; Group 3: EXF + G-ænial Universal Injectable, GC (GUI); Group 4: FP + EXF + GUI. Natural teeth were as opposing dentition and patients were free from parafunctions. Patients were recalled at six months and 1 year from baseline. Mechanical and biological parameters were evaluated accordingly with Functional Index of Teeth (Ferrari Cagidiaco et al., 2020). FIT was

used for the objective assessment of outcomes including clinical and radiographic examinations. FIT is made up of 7 variables (Interproximal, Occlusion, Design, Mucosa, Bone, Biology and Margins), each of them to be evaluated using a 0-1-2 score. The Mann-Whitney U test was applied for statistical analysis and the level of significance was set at  $p < 0.05$ .

**Results:** at one year recall all the restorations were in place without any biological or mechanical complication. FIT scores for each restoration ranged between 13.5 and 14. No statistically significant differences were found among groups.

**Conclusion:** under the limitations of this study, anterior ET showed no difference when restored with or without a fiber post, and when occlusal surface was covered by a crown or not.

Longer observation time of this study is needed to confirm these findings. Also, similar studies on patients with different degree of parafunctions are desirable.

## IN VITRO OPERATIVE TORQUE STUDY AND MECHANICAL PROPERTIES OF EDGEGLIDEPATH AND PROGLIDER

Del Bove G., Bellanova V., De Vietro S., Seracchiani M., Zingarelli L., Donfrancesco O., Gambarini G., Testarelli L.

Department of Oral and Maxillo-Facial Sciences, Sapienza University of Rome, Rome, Italy

**Aim:** aim of this study was to evaluate cyclic fatigue resistance, torsional resistance, bending properties in a conventional way and compare the cutting efficacy of two different NiTi rotary instruments for Glide Path by a new methodology: the operative torque (torque and time needed to progress toward the apex).

**Methods:** seventy ProGlider NiTi and 70 EdgeGlidePath rotary instruments have been randomly divided into 3 groups of 20 instruments each and 1 group of 10 instruments. Each group was tested to analyze four different properties: cyclic fatigue and torsional resistance, flexibility and cutting efficiency. The first three were analyzed with conventional tests found in literature. Moreover, ten fresh extracted upper first premolars with two canals were instrumented at 300 rpm with maximum torque set at 2 Ncm. One canal was instrumented with ProGlider NiTi and the other one with EdgeGlidePath. Mean instrumentation time, mean torque values, and maxi-

um torque values were evaluated. All the collected data were statistically analyzed.

**Results:** a significant difference in cyclic fatigue resistance, torsional resistance, and flexibility between EdgeGlidePath and ProGlider was found ( $p < 0.05$ ). EdgeGlidePath instruments reached the working length in significantly less time with a smaller amount of torque when compared to ProGlider ( $p > 0.05$ ). No instruments exhibited flute deformation or underwent intracanal separation.

**Conclusion:** operative torque is related to the capability to cut dentin and progress toward the apex: the smaller the torque values, the higher the cutting ability (and safety). Moreover, EdgeGlidePath better resists to flexural and torsional stresses and seemed to be more flexible in conventional mechanical tests. Operative torque during endodontic instrumentation helps understanding the overall performance in terms of both cutting efficiency and safety.

## EPOXY RESIN VS BIOCERAMIC: SYSTEMATIC REVIEW WITH META-ANALYSIS

Sovereto D.<sup>1</sup>, La Neve E.<sup>1</sup>, Quarta C.<sup>1</sup>, Iurato Carbone M.<sup>2</sup>, Mascitti M.<sup>3</sup>, Santarelli A.<sup>3</sup>, Togni L.<sup>3</sup>, Lo Muzio E.<sup>4</sup>, Dioguardi M.<sup>1</sup>

<sup>1</sup>Department of Clinical and Experimental Medicine, University of Foggia, Foggia, Italy

<sup>2</sup>Sector of Oral Medicine, Department of Surgical, Oncological, and Oral Sciences (DiChirOnS), University of Palermo, Palermo, Italy

<sup>3</sup>Department of Clinical Specialistic and Dental Sciences, Marche Polytechnic, Ancona, Italy

<sup>4</sup>School of Orthodontics, University of Ferrara, Ferrara, Italy

**Aim:** the purpose of this systematic review of the literature is to investigate which of the epoxy-based cements and those based on Tricalciumsilicate (MTA, Bioceramic) have the best sealing capacity through the analysis of studies that have provided a survey model *in vitro* of bacteria leakage.

**Methods:** the articles were identified using electronic databases such as PubMed, Scopus, the search was conducted between 81.2.2020 and 31.12.2020 and a last search was conducted on 2.12.2021.

**Results:** 678 records were identified and after removing the overlaps we obtain 481 records, with the first phase of screening and selection of records we reached 204 and with the application of the inclusion and exclusion criteria we selected 31 articles, only 9 studies made a direct comparison between the two endodontic cement categories and presented data that

could be included in the meta-analysis Data: The meta-analysis of first outcome shows an odds ratio of 2.70 C.I. [1.54, 4.73], the test for overall effect has a p value = 0.0005 with a heterogeneity index of 12.9%; The second outcome meta-analysis shows an Odds Ratio of 1.50 C.I. (Confidence Interval) [0.92, 2.46] with a p value of 0.10 with an I2 of 79%.

**Conclusion:** we can conclude that the sealing ability, studying with a bacterial micro-infiltration model, is higher for epoxy resins than for tricalcium silicate-based cements for observation periods longer than 90 days. The knowledge of the cement that determines the best sealing ability and resistance to microbial leakage, can be of help for the dentist who has to face clinical situations such as endodontic retreatments whose failure is determined by the persistence of bacteria in the endodontic canals.

## CONSERVATIVE SHAPING COMBINED WITH 3D CLEANING CAN BE A POWERFUL TOOL: A CASE SERIES

Iandolo A.<sup>1</sup>, Abdellatif D.<sup>2</sup>, Frucci E.<sup>1</sup>, Cecere L.<sup>1</sup>, Pisano M.<sup>1</sup>, Sammartino P.<sup>1</sup>, Scelza G.<sup>1</sup>, Amato M.<sup>1</sup>

<sup>1</sup>Department of Medicine, Surgery and Dentistry, Scuola Medica Salernitana, University of Salerno, Baronissi, Italy

<sup>2</sup>Department of Endodontics, Faculty of Dentistry, University of Alexandria, Alexandria, Egypt

**Aim:** the purpose of this case series was to report on the outcome of root canal treatments following a conservative canal preparation, followed by three-dimensional cleaning technique (intracanal heating and ultrasonic activation of NaOCl).

**Methods:** three endodontic treatments of infected root canals associated with apical disease are reported.

Conservative canal preparations were done using a NiTi rotary instrument with a diameter of 0.20 mm at the tip and a constant taper of 0.05 mm/mm.

A final 3D cleaning was performed in all three cases following a modern protocol of irrigant activation: internal heating of NaOCl associated with ultrasonic activation.

**Results:** the follow up of the three cases showed healing and resolution of clinical signs and symptoms.

**Conclusion:** the new protocol is safe and effective. Healing of periapical disease was achieved in the above reported cases following conservative root canal preparation, irrigation with 17% EDTA, and intracanal heating and ultrasonic activation of NaOCl.

## ENTEROCOCCUS FAECALIS IN ENDODONTIC INFECTIONS AND THE ROLE OF SALIVA IN ITS TRANSMISSION

Gaeta C.<sup>1</sup>, Marruganti C.<sup>1,2</sup>, Santoro F.<sup>3</sup>, Franciosi G.<sup>1</sup>, Ferrari M.<sup>4</sup>, Grandini S.<sup>1</sup>

<sup>1</sup>Unit of Endodontics and Restorative Dentistry, School of Dentistry and Dental Prosthodontics, Department of Medical Biotechnologies, University of Siena, Siena, Italy

<sup>2</sup>Unit of Periodontology, School of Dentistry and Dental Prosthodontics, Department of Medical Biotechnologies, University of Siena, Siena, Italy

<sup>3</sup>Lamb, Laboratory of Molecular Microbiology and Biotechnology, University of Siena, Siena, Italy

<sup>4</sup>Unit of Prosthodontics, School of Dentistry and Dental Prosthodontics, Department of Medical Biotechnologies, University of Siena, Siena, Italy

**Aim:** the purpose of the present study is to investigate the prevalence of *Enterococcus faecalis* in primary and secondary endodontic infections and its presence in saliva.

**Methods:** fifty-one patients were recruited and divided in 5 Groups based on different pulpal and peri-apical conditions: vital tooth (CVT), treated teeth without lesion (CTR), necrosis (N), retreatment (R), irreversible pulpitis (PI).

Microbiological sampling was processed by culture and molecular methods. Fisher exact test ( $P < 0.05$ ) was used to assess the correlation between single group and the presence of *Enterococcus faecalis* and its association with saliva samples.

**Results:** *Enterococcus faecalis* were found in 7 cases in pre-treatment canal samples (16%) and its presence was associated with endodontic infections ( $P = 0.014$ /Fisher's exact test). The saliva was the principal source of infection (83%) and was strongly associated with endodontic contamination ( $P = 0.000$ /Fisher's exact test).

**Conclusion:** although not statically significant, *Enterococcus faecalis* remain one of the most important etiological factors of secondary endodontic infections. Our study demonstrate that the saliva is the main source of contamination of root canal system, underlining the importance of rubber dam isolation.

## ECTOPIC DENTIN-LIKE TISSUE RELATED TO CHRONIC APICAL PERIODONTITIS: 4 YEARS CBCT FOLLOW UP

Giordano L., Gibello U., Carpegna G., Costamagna P., Alovise M., Pasqualini D., Berutti E.

Department of Surgical Science, Dental School Department of Endodontic and Restorative Dentistry, University of Turin, Turin, Italy

**Aim:** cone beam CT is essential in clinical cases with challenging differential diagnosis of dental-alveolar lesions of uncertain origin.

**Methods:** a 36 years-old female reported moderate spontaneous pain referred to the maxillary left lateral incisor and canine. No dental history of trauma, caries, periodontitis or previous endodontic or orthodontic treatment were reported. Normal periodontal probing and soft tissue aspect were evidenced, no clinical sign of caries. Sensitivity thermal and electric pulp testing on tooth 2.2 and 2.3 demonstrated a negative response. Intraoral x-rays showed peri-apical radiolucency on teeth 2.2 and 2.3 and a radiopaque irregular neof ormation close to 2.3 root apex. CBCT confirmed previous findings, also showing apical root re-

sorption of 2.3; the location of the unknown dense material was at the periphery of the lesion. Root canal treatment was performed on both teeth then a microsurgical apical resection and biopsy were made on tooth 2.3.

**Results:** the histology evidenced the dentin-like origin of the dense material and periapical granuloma. The CBCT follow up of the area evidenced complete healing and no symptoms at 4 years.

**Conclusion:** CBCT was fundamental for the differential diagnosis of the lesion and decision making process, although the etiopathogenesis of the pulp necrosis, the peri-radicular chronic lesion and the ectopic dental hard tissue formation remains unclear.

## APICAL EXTRUSION DEBRIS: A COMPARATIVE *EX VIVO* STUDY OF TWO RETREATMENT TECHNIQUES

Generali L.<sup>1</sup>, Ingrosso A.<sup>1</sup>, Cavani F.<sup>1</sup>, Pedullà E.<sup>2</sup>, La Rosa G.R.M.<sup>2</sup>, Bertoldi C.<sup>1</sup>, Consolo U.<sup>1</sup>, Checchi V.<sup>1</sup>

<sup>1</sup>Department of Surgery, Medicine, Dentistry and Morphological Sciences with Transplant Surgery, Oncology and Regenerative Medicine Relevance, University of Modena and Reggio Emilia, Modena, Italy

<sup>2</sup>Department of General Surgery and Surgical-Medical Specialties, University of Catania, Catania, Italy

**Aim:** to compare the amount of apically extruded debris using two rotary NiTi retreatment instruments.

**Methods:** twenty extracted single-root permanent human teeth were selected. The root canals were prepared to size 30 using the ProTaper Next system (Dentsply Sirona, Ballaigues, Switzerland), filled with gutta-percha and AH Plus sealer (Dentsply De Trey, Konstanz, Germany) using the continuous wave of condensation technique and, after a storage period of thirty days, randomly divided into two retreatment groups (n = 10). The root fillings were removed with one of the following instruments: ProTaper Universal Retreatment (Dentsply Sirona, Ballaigues, Switzerland) or

VDW. Rotate Retreatment (VDW, Munich, Germany). Apically extruded debris was collected in Eppendorf tubes which were weighed with a microbalance (10<sup>-5</sup> g) before and after the retreatment. These data were analysed statistically using the Mann Whitney test with the significance level set at 5%.

**Results:** no significant differences were detected amongst the two retreatment techniques concerning apically extruded debris (P > .05).

**Conclusion:** both retreatment systems were associated with apical extrusion of debris, with no significant differences between the two techniques.

## EFFECTS OF CORONAL FLARING ON SHAPING ABILITY OF TWO NITI FILES: A MICRO-CT STUDY

La Rosa G.R.M.<sup>1</sup>, Hawi N.<sup>2</sup>, Palazzo G.<sup>1</sup>, Generali L.<sup>3</sup>, Nehme W.<sup>2</sup>, Pedullà E.<sup>1</sup>

<sup>1</sup>Department of General Surgery and Medical-Surgical Specialties, University of Catania, Catania, Italy

<sup>2</sup>Department of Endodontics, Faculty of Dentistry, Saint Joseph University, Beirut, Lebanon

<sup>3</sup>Endodontic Section, Department of Surgery, Medicine, Dentistry and Morphological Sciences with Transplant Surgery, Oncology and Regenerative Medicine Relevance (CHIMOMO), School of Dentistry, University of Modena and Reggio Emilia, Modena, Italy

**Aim:** to evaluate through micro-computed tomography the effects of coronal flaring on the canal transportation and centering ability of two heat treated nickel-titanium (NiTi) rotary instruments, 2Shape (Micro Mega, Besançon, France) and Hyflex CM (Coltène Whaledent, Switzerland).

**Methods:** thirty extracted mandibular molars with two independent mesial canals were selected and randomly assigned into the following groups ( $n = 15$ ): One Flare (Micro Mega) before Hyflex CM (the OFCM group), Hyflex CM (the CM group), One Flare before 2Shape (the OF2S group) and 2Shape (the 2S group). Pre- and post-preparation micro computed tomographic images were obtained to measure mesial and distal dentin walls thickness variation, and calculate root canal transportation (%) and centralization. Repeated measures analysis

of variance followed by multiple comparisons of Bonferroni were performed to compare the different groups and the root thirds in each group ( $P < 0.05$ ).

**Results:** the 2S-OF2S groups exhibited significantly lower values compared to CM-OCM ones in the cervical thirds with no difference at middle and apical parts, both for canal transportation and centralization. Moreover, in the apical section, OF2S was significantly associated with minor canal transportation and major centralization compared to 2S while no significant difference emerged between CM and OFCM.

**Conclusion:** within the limits of this *in vitro* study, coronal flaring reduced canal transportation and improved centralization of the 2Shape files in the apical section while had no significant influence on the HyFlex CM instruments.

## INFLUENCE OF SHAFT LENGTH ON TORSIONAL AND CYCLIC FATIGUE RESISTANCE OF NI-TI INSTRUMENTS

Leone C., Bramucci C., Tosti I., Mazza F., Obino F.V., Di Nardo D., Gambarini G., Testarelli L.

Department of Oral and Maxillo-Facial Sciences, Sapienza University of Rome, Rome, Italy

**Aim:** the aim of this study was to evaluate the influence of shaft length on torsional stiffness and cyclic fatigue resistance of endodontic instruments.

**Methods:** the experiment was performed using Twisted File Adaptive S-M2 (SybronEndo, Orange, CA, USA). Sample size was calculated using G\*Power software (version 3.1.9.6, Kiel University, Germany) with  $\alpha$  value and test power respectively set to 0.05 and 0.80. Regarding this, 100 instruments were submitted to static torsional and cyclic fatigue tests. Four groups were individuated ( $n = 25$ ), two for both tests according to different instruments length: group A<sup>1-2</sup> (23 mm) and group B<sup>1-2</sup> (27 mm).

Static torsional test was achieved with a 1:1 handpiece connected to an electric motor (Kavo, Biberach, Germany) able to record torque values. Each instrument was constrained at 3 mm from the tip and was rotated until fracture and torque at fracture (TtF) was detected.

Cyclic fatigue test was performed rotating each instrument in an artificial canal (angle curvature of 90° with curvature radius of 3 mm) until fracture occurred. Rotational speed was set to 300 rpm and torque limit to 2.0 Ncm, according to manufacturer's instructions. Time to fracture (seconds) was registered and number of cycles (NCF) was calculated multiplying time to fracture and rpm.

All data were statistically analyzed. One-way analysis of variance and t tests with Bonferroni correction were used at a 5% significance level ( $p < 0.05$ ).

**Results:** group B<sup>1</sup> showed higher TtF than group A<sup>1</sup> with statistically significant difference ( $p$  value  $< 0.05$ ), whilst in terms of cyclic fatigue resistance, no statistically significant difference was observed between group A<sup>2</sup> and B<sup>2</sup> ( $p$  value  $> 0.05$ ).

**Conclusion:** according to results and statistical analysis, shaft length positively affects the torsional stiffness, while cyclic fatigue seems to be not affected by instrument length.

## INFLUENCE OF TEMPERATURE AND RADIUS OF CURVATURE ON CYCLIC FATIGUE OF NITI SINGLE FILES

Leotta M.L., La Rosa G.R.M., Indelicato F., Lo Giudice A., Isola G., Pedullà E.

Department of General Surgery and Medical-Surgical Specialties, University of Catania, Catania, Italy

**Aim:** the objective of this study was to determine the influence of different temperatures and curvature radii on the cyclic fatigue resistance of F6 SkyTaper (F6ST, Komet, Brasseler GmbH & Co., Lemgo, Germany) and One Curve (OC, Micro-Mega, Besançon, France) single file nickel-titanium rotary instruments.

**Methods:** a total of 120 instruments of F6ST and OC #25.06 were evaluated in two curvature radii (5-mm and 3-mm) at two temperatures ( $20^{\circ}\text{C} \pm 1^{\circ}\text{C}$  and  $37^{\circ}\text{C} \pm 1^{\circ}\text{C}$ ) in 16-mm stainless steel artificial canals with a  $60^{\circ}$  curvature. Instruments were tested in continuous rotation at 300 rpm and 4.1 Ncm in a customized testing device. Cyclic fatigue resistance was expressed by the times to fracture (TtF). Data were analyzed statistically using 2-way analysis of variance and the Bonferroni multiple comparison post hoc test with the significance level established at 95%.

**Results:** all instruments reduced their TtF at  $37^{\circ}\text{C}$  ( $P < 0.05$ ) except for OC in the 3-mm radius, in which no significant difference was detected between  $20^{\circ}\text{C}$  and  $37^{\circ}\text{C}$ . The 3-mm curvature radius negatively affected TtF of all tested instruments ( $P < 0.05$ ), except for F6ST at  $20^{\circ}\text{C}$  ( $P > 0.05$ ). F6ST reported higher TtF than OC in the 3-mm radius at  $20^{\circ}\text{C}$  ( $P < 0.05$ ), with no significant differences between them in the other tested conditions.

**Conclusion:** within the limitations of the present *in vitro* study, body temperature negatively influenced cyclic fatigue resistance of all tested files, except for OC in the 3-mm curvature radius.

All instruments showed lower times to fracture in the 3-mm radius excluding F6ST at  $20^{\circ}\text{C}$ .

## A NEW DEVICE TO TEST THE BENDING RESISTANCE OF ENDODONTIC INSTRUMENTS

Mazzoni A., Del Giudice A., Zanza A., Reda R., Di Nardo D., D'Angelo M., Testarelli L., Gambarini G.

Department of Oral and Maxillo Facial Sciences, Sapienza University of Rome, Rome, Italy

**Aim:** the aim of the present study was to propose a new machine for testing the bending behavior of Nickel Titanium (NiTi) Rotary instruments. Moreover, the aim was twofold to test multiple points along the cutting surface and to compare the influence of proprietary heat treatment on the bending ability of EdgeTaper (ET), Protaper Universal (PTU), EdgeTaper Platinum (ETP), and Protaper Gold (PTG).

**Methods:** a total of 320 instruments were examined in the present study: 80 ET, 80 PTU, 80 ETP, and 80 PTG. The bending ability of all instruments was tested at a  $45^{\circ}$  angle and on three different portions of the instrument at 3, 6, and 9 mm from the tip. The new device used was customized as follow: a main platform made of a stainless-steel alloy, a load cell linked to a digital display, a mobile device that allowed the repeatable position of the file on the load cell, and an analog protractor. The mobile device made it possible to measure the bending resi-

stance at different portions of the instrument. All measurements, shown on the display attached to the load cell, were recorded on a spreadsheet and statistically analyzed using the Mann-Whitney U-test.

**Results:** statistical analysis showed significant differences among each single instrument of the series and between ET and PTU as well as ETP and PTG. The bending behavior of a NiTi instrument is the ability of the file to bend without any plastic deformation. This feature, according to the results of the present study, is variable along the cutting surface.

**Conclusion:** the present testing machine should be considered as a useful device to better describe the bending ability of NTR instruments rather than the ISO 3630-1 and could permit to precisely investigate the bending behavior of the whole rotary instrument, providing more reliable and realistic information about the flexibility of the instrument.

## MACRO- AND HISTOLOGICAL DATA OF COPPER SULFIDE PENETRATION IN THE FRONTAL MANDIBULAR TEETH

Meto A.<sup>1</sup>, Spinelli A.<sup>1,2</sup>, Tragaj E.<sup>3</sup>, Meto A.<sup>3</sup>

<sup>1</sup>Endodontic Clinical Section, School of Dentistry, Department of Biomedical and Neuromotor Sciences, University of Bologna, Bologna, Italy

<sup>2</sup>Laboratory of Biomaterials and Oral Pathology, School of Dentistry, Department of Biomedical and Neuromotor Sciences, University of Bologna, Bologna, Italy

<sup>3</sup>Department of Therapy, Faculty of Dentistry, University of Aldent, Tirana, Albania

**Aim:** to evaluate the dynamic of copper sulfide penetration during electrophoresis in the root canal system of frontal mandibular teeth.

**Methods:** in this study, 14 extracted intact frontal mandibular teeth were taken into consideration. These latter were extracted for prosthetic purposes, with an age of patients ranged from 50 to 65 years. The study was conducted in two phases, in macroscopic and histological analysis. In the first group, consisting of 5 teeth, copper-calcium hydroxide-based (Cupral, Humanchemie GmbH, Alfeld, Germany) compound was applied by the help of electrophoresis. The treatment was performed in two sessions, in a 7-day time interval from one another. In the second group, consisting from other 5 teeth, was applied a combination-paste by a portion of Cupral and 9 portions of Ca(OH)<sub>2</sub>-highly dispersed paste. Then, the third group was the comparison one consisting of 4 teeth, not treated. The tooth with opened endodontic cavity was immersed in the plastic container filled with 0.9% saline up to the level of the tooth neck, in order to conduct the electrophoresis session. The exploration of each canal entrances was performed using a hand K-file size 10 until its tip could reach. Here, we used the crown-down technique up to 2/3 of the canal length. After drying the canal with paper points, we applied the corresponding paste for each group, thus creating an endodontic reservoir. Next,

the current was applied by switching the apparatus KOMFORT II, where the intensity of the electrophoretic current was 5 mA x min for each canal. According to the groups, the teeth were inserted into labeled containers with 10% neutral buffered formalin for fixation and then delivered for histological examination.

**Results:** macroscopically, in the first group, a turquoise blue staining of the crown and root was observed; not aesthetically acceptable for the frontal teeth. While in the second group, no staining of this intensity was observed. During the histological observation of the first group, we noticed the penetration of copper sulfide into predentin and dentinal tubules. The intertubular dentinal matrix was not stained, due to the presence of inorganic substances. Although in the second group, areas of predentin slightly impregnated with copper sulfide were observed. Interestingly, the penetration of copper particles into the dentinal tubules was not uniformly distributed in this group. Meanwhile, in the third group, only a normal structure of the dentin was observed in the dentinal walls of the root canal.

**Conclusion:** it can be emphasized that the use of electrophoresis with Cupral and/or Ca(OH)<sub>2</sub>-highly dispersed can be an effective alternative for the endodontist in the treatment of difficult or impassable root canals.

## A NEW TECHNIQUE TO SAFELY PERFORM ACTIVE CLEANING IN TEETH WITH OPEN APICES: CAB TECHNIQUE

Iandolo A.<sup>1</sup>, Amato A.<sup>1</sup>, Scelza G.<sup>1</sup>, Pisano M.<sup>1</sup>, Sammartino P.<sup>1</sup>, Abdellatif D.<sup>2</sup>, Amato M.<sup>1</sup>

<sup>1</sup>Department of Medicine, Surgery and Dentistry Scuola Medica Salernitana, University of Salerno, Baronissi, Italy

<sup>2</sup>Department of Endodontics, Faculty of Dentistry, University of Alexandria, Alexandria, Egypt

**Aim:** this study aims to evaluate *in vitro* the extrusion of NaOCl, using an artificial root canal with an open apex, using different canal irrigation protocols.

**Methods:** for this study, a transparent artificial root canal was used. The apex was shaped to be large and irregular in form. After root canal mechanical shaping, the artificial cylindrical chamber, which was made below the large apical foramen, was filled with fuchsine-stained bovine pulp tissue. Afterward, irrigation protocols were carried out and compared regarding their safety with regards to irrigant extrusion. Subsequently,

two groups were created, Group A: Internal heating associated with ultrasonic activation and Group B: Internal heating associated with ultrasonic activation by using the CAB technique. In both groups, 5.25 % sodium hypochlorite solution was used as the irrigant. Regarding the assessment of the presence or absence of the extrusion, photographs at 20x were taken and analyzed.

**Results:** for the statistical analysis, a T-test for paired samples was used. Extrusion of irrigant beyond the apex was present only in group A.

**Conclusion:** the main goal of endodontic treatment is the removal of damaged tissues and bacteria. For this reason, active cleaning is crucial in all endodontic treatment cases. In-

ternal heating followed with ultrasonic activation while using the CAB technique was an effective and safe technique to ensure no irrigant extrusion beyond the open apex.

## TORSIONAL RESISTANCE OF TWO NEW HEAT TREATED NI-TI ROTARY INSTRUMENTS

Abbagnale R., Salomone L., Stepan B., Picari F., Savo F., Galli M., Testarelli L., Gambarini G.

Department of Oral and Maxillo-Facial Sciences, Sapienza University of Rome, Rome, Italy

**Aim:** the aim of the present study was to estimate the difference in torsional resistance between two new heat treated rotary instruments: AF Blue S4 and S-One (Fanta Dental CO., Ltd, Shanghai, China).

**Methods:** a total of 40 new Nickel-Titanium instruments were tested in this *in vitro* study. 20 AF Blue S4 25/06 (Group A) and 20 S-One 25/06 (Group B). The torsional test was performed using an endodontic motor able to record torque values during the instrumentation (KaVo, Biberac, Germany). All instruments were rotated at 300rpm with torque limit set to 5.5 Ncm with their tip firmly secured at 3 mm thanks to an auto-polymerizing resin mold (DuraLay; Reliance Dental Mfg Co, Worth, IL). Torque to Fracture (TtF), Angular Deflection (AD) and Fragment Length (FL) were re-

corded. Data were statistically analysed using the SPSS 17.0 software (IBM SPSS inc., Chicago, IL, USA). In order to evaluate differences among groups, the t-student test was performed and the significance level was set at 0.05.

**Results:** group A showed higher TtF mean values ( $1.268 \pm 0.259$  Ncm) and AD mean values ( $515 \pm 36.5^\circ$ ) than Group B; TtF ( $1.712 \pm 0.150$  Ncm); AD ( $664 \pm 48^\circ$ ). Statistical significant differences were to be found between the two groups ( $p < 0.05$ ).

**Conclusion:** the two instruments differed only for their cross-sectional design, respectively convex triangular for AF Blue S4 and Italic S-Shaped for S-One. Therefore, since AF Blue S4 showed a higher TtF and AD, it could be stated that they are safer in terms of torsional resistance than S-One.

## ROLE OF PERIAPICAL LESION IN MRONJ: A RETROSPECTIVE STUDY

Audino E., Salvadori M., Marsili F., Venturi G., Visconti L., Salgarello S.

Department of Medical and Surgery Specialties, Radiological Sciences and Public Health Dental School, University of Brescia, Brescia, Italy

**Aim:** case reports of MRONJ caused by endodontic treatments are limited in number and the association with ONJ is often questionable. The position statement of several scientific societies recommended endodontic treatment to prevent foci of infection or replace surgery treatment. The role of the periapical lesion has not yet been clear in the progress of MRONJ. The purpose of this study is to overview the implications of endodontic disease in patients who developed MRONJ.

**Methods:** twenty-two orthopantomograms of patients with MRONJ 2019-2020 were analyzed to identified teeth with: endodontic treatment and no periapical lesion (A); endodontic treatment and periapical lesion (B); endodontic treatment and poor coronal seal (C); endodontic treatment and periodontal disease (D); periapical lesion and no endodontic treatment (E).

**Results:** a total of 210 teeth detected, ninety-one elements were endodontically involved. Sixty-two teeth had endodontic treatment (A-B-C-D), fifty-five teeth had periapical lesion (B-E); of these twenty-six elements had endodontic treatment (B) and twenty-nine elements were without treatment (E). Despite the presence of fifty-five possible infectious foci none all of twenty-two MRONJ had endodontic origin. According with literature MRONJ occurred in prosthetic trauma (9); dental implants (4); periodontal disease (4); tooth extraction (7).

**Conclusion:** MRONJ rarely occurs from periapical lesion. If the coronal seal is adequate, evaluation of symptomatology in teeth with periapical lesion is diriment to suggest necessity of endodontic retreatment. Instead, in case of asymptomatic apical periodontitis, it can be useful monitoring the element without intervening.

## ENDOGENOUS MMPs ACTIVITY OF RADICULAR DENTIN EXPOSED TO BIOCERAMIC SEALERS

Dirutigliano A., Comba A., Pasqualini D., Alovisi M., Scotti N., Mazzoni A., Breschi L., Berutti E.

Department of Surgical Sciences, Dental School, University of Turin, Turin, Italy

**Aim:** evaluation of MMPs activity after the use of endodontic sealers (traditional vs bioceramic), filling techniques (warm vs cold) and adhesive techniques (self etch SE vs etch and rinse ER).

**Methods:** multirooted teeth were shaped with Proglider, Pro-Taper Next X1-X2 and divided into 4 groups (G): warm filling with ZoE sealer (G1); cold filling with resin based sealer (G2); cold filling with bioceramic sealer (G3); warm filling with bioceramic sealer (G4).

The post-space was prepared, each group was divided into 2 subgroups of adhesive procedure (SE vs ER) and the posts were cemented with dual resin cement. *In situ* zymography with fluorescein-conjugated gelatin was performed.

A 3-way ANOVA, post-hoc Tukey were used to test the three factors and one-way ANOVA to evaluate the differences within each variable ( $\alpha = 0.05$ ).

**Results:** the adhesive method (ER vs SE) and obturation technique (Warm vs Cold) demonstrated a significant impact ( $P < 0.05$ ), while no differences were found for endodontic sealers ( $P = 0.53$ ). The ER groups produced higher enzymatic activity than the SE groups ( $P = 0.01$ ), regardless of the sealers and obturation technique. A decrease in fluorescence in the hybrid layer was identified in the warm obturation group ( $P = 0.03$ ).

**Conclusion:** the results showed that bioceramic sealers should not alter the radicular dentin endogenous enzymatic activity. The heat produced during the root canal obturation might modify the internal enzymatic activity, however this aspect requires further investigation. The ER adhesive system produced an increase in collagenolytic activity. Nonetheless, this elevation is not evident when the ER system is used in conjunction with a warm obturation technique.

## RETREATMENTS OF OVAL-SHAPED CANALS WITH RECIPROC BLUE: DIGITAL X-RAY AND CBCT EVALUATION

Spinelli A.<sup>1</sup>, Gentilini E.<sup>1</sup>, Zamparini F.<sup>1</sup>, Gandolfi M.G.<sup>2</sup>, Prati C.<sup>1</sup>

<sup>1</sup>Endodontic Clinical Section, School of Dentistry, Department of Biomedical and Neuromotor Sciences, University of Bologna, Bologna, Italy

<sup>2</sup>Laboratory of Green Biomaterials and Oral Pathology, School of Dentistry, Department of Biomedical and Neuromotor Sciences, University of Bologna, Bologna, Italy

**Aim:** to evaluate the efficacy of a reciprocating system in removing filling material from oval-shaped root canals. The remnants and the variation of root canal morphology were assessed by digital periapical X-ray and Cone Beam Computed Tomography (CBCT).

**Methods:** twenty human single-rooted teeth with an oval-shaped canal were selected for the study. The teeth were prepared and obturated with AH Plus and Single Cone 25 (Dentsply Maillefer, Ballaigues, Swiss). After 7 days, retreatment procedures were performed with Reciproc Blue (RB) (Dentsply Maillefer, Ballaigues, Swiss) using a Silver Reciproc Endomotor (VDW, GmbH, Munich, Germany) under profuse irrigation. The root canals were retreated with crown-down technique using Gates Glidden burs #2- #3 in the coronal third and then RB #25 and #40 until the working length.

Digital periapical X-ray (Dürr Dental VistaScan Plus, Bietigheim-Bissingen, Germany) and CBCT (NewTom VGi, Verona, Italy) were performed on each specimen before and after retreatment to measure the residual fillings and the variation of canal area compared with the initial pre instrumented morphology.

**Results:** the increment of the canal area measured on Rx after retreatment with RB #40 compared to preoperative was 17%. The remnants detected on Rx were 12% of the root canal filling area. The remnants detected on CBCT were 7% of the root canal filling volume.

**Conclusion:** digital X-ray and CBCT provided detection of residual root filling material in retreatment of oval-shaped root canals. The residual fillings were more frequently detected at medium third of the root canal.

## MINERAL TYRIOXIDE AGGREGATE: CURRENT USE IN DENTISTRY AND FUTURE PERSPECTIVES

Gorassini F.<sup>1</sup>, Fiorillo L.<sup>1,2</sup>, Scoglio C.<sup>1</sup>, Gambino D.<sup>1</sup>, Mastroieni R.<sup>1</sup>, D'Amico C.<sup>1</sup>, Cervino G.<sup>1</sup>, Cicciù M.<sup>1</sup>

<sup>1</sup>Department of Biomedical and Dental Sciences, Morphological and Functional Images, School of Dentistry University of Messina, Messina, Italy

<sup>2</sup>Multidisciplinary Department of Medical-Surgical and Odontostomatological Specialties, University of Campania Luigi Vanvitelli, Caserta, Italy

**Aim:** one of the main requirements in endodontia, to ensure the success of the treatment, is the isolation of the operating field from humidity. Mineral Tyrioxide Aggregate (MTA) is one of the most accepted biomaterials by clinicians due to its biocompatibility property. The aim of this study is to highlight the advantages and versatility of the material in different clinical applications.

**Methods:** MTA is an endodontic cement that comes in the form of a powder to be mixed with a solution (physiological, water or anesthetic) giving rise to a colloidal gel. It is a highly biocompatible material that determines the healing of inflammatory phenomena with the formation of new cement on the reconstructed root surface, thus activating cementogenesis. It is a highly hydro-

philic biomaterial, it is not sensitive to humidity (in particular to saliva and blood) and in fact it hardens in the presence of the latter. In particular, literature of the last 10 years has been analyzed.

**Results:** there are many indications for the use of the MTA such as retrograde fillings, direct pulp capping, repairs of endo-periodontal perforations, treatment of internal resorptions, treatment of the open apex.

**Conclusion:** the results obtained thanks to clinical, histological and radiographic tests highlight the predictability of success of the MTA both in the endodontic and conservative fields and certainly represent promising and predictable biomaterials to be considered as a starting point for future developments.

## SYSTEMIC ADMINISTRATION OF STATINS AND APICAL PERIODONTITIS: A SYSTEMATIC REVIEW

Ideo F., Manca M.F., Cotti E.

Department of Conservative Dentistry and Endodontics, University of Cagliari, Cagliari, Italy

**Aim:** the response to endodontic treatment of apical periodontitis (AP) in patients under immunomodulators is of great interest. Statins, medications prescribed to reduce the levels of cholesterol in patients at risk for cardiovascular diseases, regulate many anti-inflammatory pathways. The purpose of this systematic review was to evaluate the potential influence of statins in the development and treatment outcome of endodontic infection.

**Methods:** two reviewers independently conducted a literature search, using a set of search terms in PubMed, Scopus and Web of Science. The bibliographies and gray literature of all relevant articles and textbooks were manually searched. Data extraction, quality assessment and risk of bias were performed,

using different tools, according to the type of study. Disagreements were resolved by a third reviewer.

**Results:** nine out of 364 articles respected the inclusion criteria. All studies showed a moderate to high value for quality assessment and risk of bias. Available scientific evidence shows that statins reduce the pro-inflammatory status of the individual and play a crucial role in the modulation of bone resorption during the pathogenesis of AP.

**Conclusion:** statins may exert a contentive effect on the development of AP and may improve the healing of periapical lesions thanks to their anti-inflammatory potential. The results strongly underline that conventional endodontic therapy may be helped from the modulation of the immune system of the patient.

## MICRO-CT EVALUATION OF TWO SHAPING ROTARY SYSTEMS IN MANDIBULAR FIRST MOLAR MESIAL CANALS

Lavino S., Alovisi M., Moccia E., Multari S., Carpegna G., Pasqualini D., Scotti N., Berutti E.

Department of Surgical Sciences, Dental School, Endodontics, University of Turin, Turin, Italy

**Aim:** to evaluate the shaping ability of a modified ProTaper Next technique (PTNm) and the TruNatomy (TN) rotary system using Micro-CT.

**Methods:** forty mesiobuccal and mesiolingual canals of permanent first mandibular molars extracted for periodontal disease were randomly assigned into 2 groups (n = 20): (A) modified ProTaper Next technique and (B) TruNatomy system. The specimens were randomly selected, and the inclusion criteria were a primary root canal curvature less than 40°, a mean radius of 4° - 8° and the absence of calcifications. The modified ProTaper Next technique (encoded by Professor Elio Berutti) consists in: ProGlider, ProTaper Next X1 and apical finishing with a K-file NiTiFlex #25. The shaping instruments were changed every canal. The irrigation was achieved with 5% NaOCl and 10% EDTA solutions. The samples were scanned using micro-CT (SkyScan 1172®: ©Bruker microCT, Kontich,

Belgium). Matched volumes were evaluated and analysed for: volume of removed dentin, difference of canal surface, centroid shift, minimum and maximum diameters, cross-sectional areas and canal geometry variations through the ratio of diameter ratios (RDR) and the ratio of cross-sectional areas (RA). The measurements were assessed at 2 mm from the apex, in middle coronal and medium third of the root canal. The data were statistically analysed using ANOVA with the level of significance set at  $\alpha = 0.05$ .

**Results:** the PTNm group showed a higher volume of removed dentin and a less centroid shift at apical level while the TN sequence demonstrated a better centring ability at coronal level. The only significant difference between the two groups is represented by the RA at coronal level.

**Conclusion:** both shaping techniques demonstrated the ability to maintain the original root canal anatomy.

## THE RELATIONSHIP BETWEEN ROOT CANAL SHAPING TAPER AND ROOT FRACTURE: A SYSTEMATIC REVIEW

**Aim:** the objective of this systematic review is to evaluate if the root canal shaping with low taper instruments decreases the risk of root fracture compared to high conicity shaping.

**Methods:** A comprehensive search was carried out on electronic databases, including: Ovid MEDLINE, PubMed and Web of Science. Inclusion criteria were: "Root fracture" and "Instrument taper", studies published between 01/2011 and 04/2020. The exclusion criteria were: patients with dental diseases, only one type of taper used, case report/series, review, meta-analysis, papers without full text available. The methodological quality and risk of biases of included papers were assessed using CONSORT criteria for non-randomized comparative studies.

**Results:** from 283 articles, 16 *in vitro* studies evaluated:

- presence/variations in the number of micro cracks observable;
- fracture resistance to the fracture load test;
- variation in the stress distribution with Finite Element Analysis.

The studies analyzed does not concord among them and the results varied as follows:

1. Increasing the root canal taper does not produce a decrease of root resistance.
2. Increasing the root canal taper after the shaping, decreases the root resistance.
3. Increasing the root canal taper increases the resistance of the root itselfes.

The differences in the studies could be related to:

- differences in the preparation motion;
- cross-sectional and cutting blade design;
- type of alloy of the instrument used.

**Conclusion:** it is not clear whether a taper difference can determine differences in root fracture resistance. The studies do not agree in the results, probably because it is not possible to standardize endodontic procedures using files with the same characteristics and only with different taper.

## PERIAPICAL STATUS IN PATIENTS WITH INFLAMMATORY BOWEL DISEASE: A META-ANALYSIS

Marruganti C.<sup>1,2</sup>, Discepoli N.<sup>2</sup>, Gaeta C.<sup>1</sup>, Franciosi G.<sup>1</sup>, Ferrari M.<sup>3</sup>, Grandini S.<sup>1</sup>

<sup>1</sup>Department of Medical Biotechnology, Endodontic and Restorative Unit, University of Siena, Siena, Italy

<sup>2</sup>Department of Medical Biotechnology, Unit of Periodontology, University of Siena, Siena, Italy

<sup>3</sup>Department of Medical Biotechnology, Prosthetics Unit, University of Siena, Siena, Italy

**Aim:** a poorer oral health status in patients with Inflammatory Bowel Diseases (IBD) was reported in many studies. Therefore, the present review aims to systematically evaluate the occurrence of caries and Apical Periodontitis (AP) in patients with IBD, either Crohn's Disease (CD) or Ulcerative Colitis (UC), compared to IBD-free controls.

**Methods:** MEDLINE (PubMed), Embase, Google Scholar, LILACS and Cochrane Library electronic databases were screened. Caries experience was measured through the Decayed, Missing, Filled Teeth (DMFT) index. Weighted Mean Difference (WMD) with 95% CI was calculated between IBD subjects and IBD-free controls. Odds Ratio (OR) with 95% CI was used to evaluate the association between AP and IBD.

**Results:** 9 studies were selected for the inclusion in the systematic review, 8 of which were also included in the quantitative

synthesis of data. WMD between IBD (no distinction between CD and UC) and IBD-free subjects (3 studies) was 1.92 (95% CI, 0.39-4.23,  $P = 0.10$ ; heterogeneity:  $I^2 = 91\%$ ,  $P < 0.001$ ). Patients diagnosed with either CD (5 studies, WMD = 2.53, 95% CI, 0.38-4.68,  $P < 0.05$ ; heterogeneity:  $I^2 = 84.54\%$ ,  $P < 0.001$ ) or UC (3 studies, WMD = 4.01, 95% CI, 1.91-6.11,  $P < 0.001$ ; heterogeneity:  $I^2 = 53.20\%$ ,  $P = 0.12$ ) presented significantly higher DMFT scores than IBD-free controls. No significant association was found between AP and IBD (2 studies, OR = 0.51, 95% CI, -0.26-1.28; heterogeneity:  $I^2 = 55.21\%$ ,  $P = 0.14$ ).

**Conclusion:** there is a remarkably higher past and present caries experience in patients with IBD compared to IBD-free controls. This result should encourage clinicians to include oral health preventive programs in the overall treatment plan of IBD patients.

## PREVALENCE OF APICAL PERIODONTITIS IN PATIENTS AFFECTED BY RHEUMATOID ARTHRITIS

Mezzena S., Bardini G., Ideo F., Cadoni E., Musu D., Cotti E.

Department of Conservative Dentistry and Endodontics, University of Cagliari, Cagliari, Italy

**Aim:** the aim of this study was to evaluate the periapical status of patients with Rheumatoid Arthritis (RA) to assess a possible association between the two conditions.

**Methods:** the medical, dental and endodontic records of 41 patients with RA, and 41 healthy patients matched for age ( $54.2 \pm 12.3$ ) and gender (Control), who presented to the dental clinic for a visit, were retrospectively examined for: DMFT, presence of apical periodontitis (AP), periapical index score (PAI) and medications used. Statistical analysis was conducted at 5% significance level ( $\alpha = 0.05$ ).

**Results:** prevalence of AP was higher in RAs than in Controls at patient level (63.4% vs 43.9%,  $p = 0.078$ ), and at a tooth level (4.6% vs 2.8%,  $p = 0.083$ ). When the multi-level logistic regression was conducted using generalized estimation equations

(GEE) to assess the risk of AP in a tooth, the analysis showed a stronger association of RA diagnosis on presence of AP, close to statistical significance (OR = 1.69;  $p = 0.055$ ). The age of patients influenced significantly the probability of AP ( $p = 0.042$ ). Each one additional year implied +2% risk of AP at tooth-level. A RA patient increased the risk of AP diagnosis by 2.22 times, and a tooth hosted in RAs increases 1.66 times the same risk. Teeth in RA patients treated with glucocorticoids had the highest AP ( $p = 0.043$ ) and teeth hosted in female patients showed significantly lower risk of AP compared to reference male (OR = 0.46;  $p = 0.014$ ).

The mean DMFT was similar for both groups as the PAI.

**Conclusion:** based on these findings there seems to be an association between AP and RA.

## OPTIMIZATION OF A FULL DIGITAL TARGETED ENDODONTIC MICROSURGERY PROTOCOL: A CASE REPORT

Moccia E.<sup>1</sup>, Sanseverino F.<sup>2</sup>, Multari S.<sup>1</sup>, Carpegna G.<sup>1</sup>, Pasqualini D.<sup>1</sup>, Alovivi M.<sup>1</sup>, Berutti E.<sup>1</sup>

<sup>1</sup>Department of Endodontics, Dental School Lingotto, University of Turin, Turin, Italy

<sup>2</sup>R&D Team New Ancorvis srl, Bargellino di Calderara di Reno, Bologna, Italy

**Aim:** the aim of this case report is to propose an optimized, fully digital workflow for targeted endodontic microsurgery (FDTEMS) with a minimum degree of freedom of the operator during check surgical stages.

**Methods:** a 35-year-old female patient presented with a persistent apical periodontitis around the apex of tooth 1.5. The related symptoms were recurrent sensitivity and moderate pain. A CBCT imaging was prescribed (Morita Accuitomo 170, Morita Co., Japan). Teeth, bone and neurovascular structures were rendered with the Real Guide 5.0 (3DIEMME, Italy) software. Next, soft tissues and teeth crowns were rendered with an intraoral optical scan (IOS) (Omniscan Scan, Dentsply Sirona, UK). CBCT and IOS files were merged together using the same software, which also allowed to: delimitate the bone window area, identify the apical resection plane and depth, and bevel angle. Finally, the guide design was created on the virtual model, ready for Polyjet 3D printing.

After the anesthesia, the surgical procedure was performed by preparing the flap with a papilla-based incision with one vertical releasing incision. The guide, which also functioned as a tissue

retractor, was placed in position. A surgical bur with constant external irrigation was used for the osteotomy and apical resection, following guiding planes and lines. Next, the retrograde cavity was prepared using ultrasonic tips (Pro Ultra, Dentsply Maillefer, Switzerland), and root-end filling (Fast set putty RRM Bio-ceramic cement, FKG, Switzerland) was placed. The site was sutured with GORE-TEX® 5-0. After 6 months, periapical inflammation showed no signs of recurrence with symptoms resolution.

**Results:** in a freehand surgery, clinicians may overextend the osteotomy and perform a non-ideal root resection as a result from errors in perforation site, angulation, depth and poor visibility. The FDTEMS provides the operator the benefit of a previously planned surgical path and depth of bone and tooth-tissue management, saving operation time and decreasing the stress of the clinician in complex sites.

**Conclusion:** FDTEMS is a further development of the latest TEM techniques. A full digital workflow improves the 3D reproduction accuracy of all the anatomical structures involved, giving this protocol remarkable advantages during surgery and post-operative healing.

## SODIUM HYPOCHLORITE ACCIDENT: REPORT OF TWO CASES DOCUMENTED ACCORDING TO NEW STANDARDS

Salvadori M., Audino E., Venturi G., Garo M.L., Salgarello S.

School of Dentistry, Department of Medical and Surgery Specialties, Radiological Sciences and Public Health, University of Brescia, Brescia, Italy

**Aim:** reporting NaOCl accidents should be detailed and complete given the sporadicity of these events and their potentially severe complications. This work aimed to report two hypochlorite accidents using new guidelines for documenting.

**Methods:** the 2020 Guidelines and Guivarch's template were used to register clinical information, irrigation and extrusion data, post-extrusion management, and legal consequences.

**Results:** a 59-year-old female patient presented to the Dental Clinic of Brescia complaining of pain and discomforts, probably consequences of endodontic treatment. Examination revealed a diffuse swelling and ecchymosis at the right side of the face and ulcerative lesions on the internal mucosa of the lip. The hypochlorite accident, not immediately diagnosed by her dentist, had

occurred on teeth #12 the day before. Another case occurred in a 43-year-old female with liver cirrhosis and depression. Sudden moderate pain and intracanal bleeding were reported during a non-surgical endodontic treatment on teeth #13. Hypochlorite extrusion was immediately diagnosed, and saline solution was injected. The severity level was classified low for both accidents, although the high NaOCl concentration (5%). Pain and swelling lasted for a short period: antibiotics, corticosteroids, and NSAID were used to improve symptomatology. Only the first patient required her case sheet for legal evaluation.

**Conclusion:** NaOCl accident is a rare event. Reporting hypochlorite accidents following standardized indication is necessary to gather homogenous and useful data for future studies.

## AN *EX VIVO* EVALUATION OF TORQUE GENERATED DURING INSTRUMENTATION WITH DIFFERENT LUBRICANTS

Seracchiani C., Pietrangeli C., Vannetelli E., D'Angelo M., Marsella G., Miccoli G., Testarelli L., Gambarini G.

Department of Oral and Maxillo Facial Science, Sapienza University of Rome, Rome, Italy

**Aim:** the aim of the present study was to assess *ex vivo* the role of different lubricants on real-time torque generated during intracanal instrumentation. Furthermore, this study evaluates two different type of torque parameters, operative torque (OT) and average peak torque (APT), to demonstrate if similar results could be reached.

**Methods:** four equal groups (n = 15) of extracted single-rooted teeth were selected for the present study. Each group was treated with different lubricants: Group A with NaCl 0.2%, Group B with NaOCl 5%, Group C with ethylenediaminetetraacetate (EDTA) and Group D with EDTA and hydrogen peroxide (RC PREP). Furthermore, an endodontic motor was used with a clockwise motion (300 rpm and 3 Ncm maximum torque) using a Nickel-Titanium (Ni-Ti) rotary instrument, F-One Blue (Fanta Dental, Shanghai, China). This peculiar endodontic motor (Kavo, Biberach, Germany) could record, during intracanal instrumentation, the gene-

rated torque every 1/10s. For this reason, it could be possible to record Mean OT and APT in each sample. Data were analyzed, and statistical analysis were performed using one-way ANOVA and post-hoc Bonferroni between groups ( $p < 0.05$ ).

**Results:** regarding OT, the statistical analysis relieved a significant difference ( $p < 0.05$ ) between EDTA and both saline solution and sodium hypochlorite. On the other hand, statistical analysis found no significant differences between EDTA ( $p > 0.05$ ) and RC PREP. Moreover, the mean APT generated using EDTA was significant lower ( $p < 0.05$ ) compared with the others irrigants evaluated.

**Conclusion:** according to the results of the present study, the *ex vivo* torque generated during instrumentation could be influenced by different lubricants. Moreover, the study demonstrates that the mean APT could be a reliable evaluation method to estimate torsional stress during root canal treatments.

## ANALYSIS OF PULP DISSOLUTION INSIDE AN ISTHMUS USING DIFFERENT CANAL IRRIGATION METHODS

Iandolo A.<sup>1</sup>, Amato A.<sup>1</sup>, Amato M.<sup>1</sup>, Spirito F.<sup>1</sup>, Abdellatif D.<sup>2</sup>

<sup>1</sup>Department of Medicine, Surgery and Dentistry Scuola Medica Salernitana, University of Salerno, Baronissi, Italy

<sup>2</sup>Department of Endodontics, Faculty of Dentistry, University of Alexandria, Alexandria, Egypt

**Aim:** this *ex vivo* study investigated *in vitro* the effect of different canal irrigation methods on the pulp tissue dissolution inside an isthmus.

**Methods:** in the current research a single rooted premolar with two root canals and an isthmus was selected. For each experiment, a calibrated pulp tissue was inserted inside the isthmus. Six groups were created and 20 experiments were performed in each group. The dissolution of the pulp tissue in the isthmus was tested using six different irrigation methods and the efficacy of each was calculated and compared. The techniques tested in

the current study were, in sequence, (group A) traditional irrigation using endodontic needle, (group B) Subsonic activation (endoactivator), (group C) Sonic activation (Eddy tip), (group D) Internal heating followed by sonic activation, (group E) Ultrasonic activation (Endoultra) and (group F) Internal heating followed by ultrasonic activation.

**Results:** the tests by Kruskal Wallis and Mann-Whitney showed statistically significant differences among the six groups.

**Conclusion:** the activation of NaOCl allows a greater dissolution of the pulp tissue in areas like the isthmus.

## MANAGEMENT OF *DENS INVAGINATUS* THROUGH THE PRINT&TRY TECHNIQUE: A CASE REPORT

Tonini R., Boschi G., Signorini G.

School of Dentistry, Department of Medical and Surgery Specialties, Radiological Sciences and Public Health, University of Brescia, Brescia, Italy

**Aim:** the main objective of the work is to show how to treat *dens invaginatus* type3a introducing the *Print&Try* technique into the clinical practice.

**Methods:** a 40-years-old female was referred because of apical periodontitis on her upper right maxillary lateral incisor. The crown wider mesially and the periapical X-ray were pathognomonic of a *dens invaginatus* type3a. A small-FOV CBCT followed, showing also that periapical lesion had perforated both buccal and palatal bone plate. From CBCT it was obtained a file that was transformed into an STL and printed with a high definition 3D-printer. Clinician tried to find the best approach working on the 3D-printed tooth and chose a double approach: a non-surgical endodontic therapy for the main canal, combined with surgical endodontics to achieve an adequate

sealing of the invagination. Therefore, the patient underwent a selective access cavity preparation with ultrasonic tips to achieve obturation of the main canal with warm gutta-percha under an operating microscope. Subsequently, the apical inflammatory lesion was surgically cleaned and invagination filled with a bioceramic material, always under an operating microscope. A palatal membrane and a buccal one were located before flap repositioning.

**Results:** a positive outcome was assessed based on clinical findings and radiographic controls after a week and overtime.

**Conclusion:** in complex cases, patient-specific 3D-models can facilitate treatment planning and subsequently make the real therapy extremely precise, positively influencing the outcome and reducing the operating time.

## NONSURGICAL RETREATMENT USING REGENERATIVE ENDODONTIC PROTOCOLS (REPS): A CASE REPORT

Vannettelli E., Reda R., Zanza A., Mazzoni A., Del Giudice A., Di Nardo D., Gambarini G., Testarelli L.

Department of Oral and Maxillo-Facial Sciences, Sapienza University of Rome, Rome, Italy

**Aim:** the aim of this case report was to describe regenerative endodontic procedures (REPs) on a previously treated mature teeth, after having verified the success on immature teeth with long-term results.

**Methods:** regenerative endodontic procedures are aimed to treat apical periodontitis and regenerate the pulp-dentin complex in necrotic teeth. Consensus in the treatment of immature teeth with this technique is wide, however, there is no consensus in using REPs in the previously treated mature teeth. The aim of this case report was to describe REPs of the previously treated mature teeth with long-term results. A 25-years-old woman presented swelling and pain on chewing on 15 (WHO numbering system). The tooth had been endodontically treated and restored 4 years ago. After removing the old root canal filling, the roots were irrigated with 2.5% sodium hypochlorite and 17% EDTA using sonic activation.

Calcium hydroxide (CH) was used as medicament for 3 weeks. At the second visit, CH was removed, and canals were irrigated as like as the first visit, and a decision was made to complete a cell-free revascularization treatment. Apical bleeding was induced, and concentrated growth factors (CGFs) were placed inside the root canal. The tooth has been followed up to 3 years.

**Results:** the tooth was functional and asymptomatic at follow-up visits. Since the first-year follow-up, the tooth responded to the thermal and electric pulp test. Radiological exams revealed healing of apical lesion and hard tissue densification.

**Conclusion:** the clinical significance of regenerative endodontic procedures can offer an advantage over traditional endodontic procedures in immature, also for mature teeth treatments, in terms of tertiary healing, with a predictable, user-friendly procedure also for complex retreatment cases.

## PUSH-OUT BOND STRENGTH OF A NEW TWO STEPS ADHESIVE

Verniani G., Karafili D., Zucca G., Ferrari M.

Department of Medical Biotechnology, University of Siena, Siena, Italy

**Objectives:** adhesion of fiber posts luted with simplified adhesive systems has been a matter of great interest over the past years. Aim of this study was to assess the post retentive potential of new two steps self-etching system (G2-BOND Universal: GB2) when used alone and in modality etch and rinse.

**Methods:** as luting material Gradia Core (GC) and everX Flow (EXF) were used. Fiber posts (GC) were placed in endodontically treated teeth and divided into four groups ( $n = 6$ ) according the adhesive-luting material: group 1 (GB2+GC self-etch mode); group 2 (GB2+GC etch and rinse mode); group 3 (GB2+EXF self-etch mode); and group 4 (GB2+EXF etch and rinse mode). The retentive strength of fiber posts (MPa) was assessed by push-out test. Specimens were analyzed under a stereomicroscope to determine failure mode. Adhesive interface between the cement and root canal dentin for each group was evaluated using scanning electron microscopy. As push-out strength data were not normally distributed (Normality test

failed,  $P < 0.05$ ), the Kruskal–Wallis analysis of variance was applied. Dunn's multiple range test was used for post hoc comparison among the groups. The chi-square test determined if the failure mode distribution differed significantly among the groups ( $P < 0.05$ ). Bonferroni correction was applied in post hoc comparisons of failure modes (Sig- maPlot 11.0 software, Systat Software, San Jose, CA, USA).

**Results:** the post retentive potential of group 3 ( $14.71 \pm 4.25$  MPa) was higher than the other three groups, but not statistically significant difference from Group 1 ( $13.52 \pm 3.68$  MPa) and Group 4 ( $13.84 \pm 2.91$  MPa). Group 2 showed the statistically significant lowest push-out bond-strength values when compared to other groups.

**Conclusion:** G2-BOND Universal showed high values of push-out bond-strength when used with Gradia Core and everX Flow. Two steps procedure showed better results than three steps etch and rinse.

## TORSIONAL RESISTANCE OF AUSTENITIC AND MARTENSITIC INSTRUMENTS DURING FLEXURAL STRESS

Zanza A., Reda R., Mazzoni A., Del Giudice A., Di Nardo D., Seracchiani M., Gambarini G., Testarelli L.

Department of Oral and Maxillo-Facial Sciences, Sapienza University of Rome, Rome, Italy

**Aim:** to evaluate the effect of flexural stress on the torsional resistance of austenitic and martensitic instruments subjected to bending moment.

**Methods:** 60 instruments were selected for the research, 30 F1 Protaper Gold (PTG) and 30 F1 Protaper Universal (PTU). PTG and PTU instruments share all features, except for different alloy (respectively martensite and austenite). To evaluate influence of flexural stress on torsional resistance of those instruments, a static torsional test was carried out with a device composed by three components: an endodontic motor able to record torque values (Ncm); a vise used to constrain the instruments at 3mm from the tip; an interchangeable artificial canal (90° and 2-mm radius curvature), which allows instruments to remain flexed during test procedures. Each instrument was rotated at 300 rpm with a torque limit set to 5.5 Ncm until tip fracture and Torque at Fracture (TF) was recorded. This experiment was then repeated

with a straight canal, to compare torsional resistance of bended instrument with straight one. According to this, four groups were established: group A and B (respectively composed by PTG and PTU inserted in curved artificial canal) and the control groups A° and B° (straight canal).

All data were statistically analysed using one-way analysis of variance and t tests with Bonferroni correction at a 5% significance level ( $p < 0.05$ ).

**Results:** group A and Group B showed higher value of TtF compared to control groups, with a statistically significant difference ( $p$  value  $< 0.05$ ). Moreover, PTU showed higher TtF values than PTG in both experiments ( $p < 0.05$ ).

**Conclusion:** flexural stress positively affects torsional resistance of austenitic and martensitic instruments. Moreover, austenitic instruments seem to be more positively influenced in terms of torsional resistance than martensitic instruments.

## INTRACANAL HEATING OF SODIUM HYPOCHLORITE: SEM EVALUATION OF ROOT CANAL WALLS

Iandolo A.<sup>1</sup>, Cecere L.<sup>1</sup>, Scelza G.<sup>1</sup>, Pisano M.<sup>1</sup>, Frucci E.<sup>1</sup>, Abdellatif D.<sup>2</sup>, Amato M.<sup>1</sup>

<sup>1</sup>Department of Medicine, Surgery and Dentistry Scuola Medica Salernitana, University of Salerno, Baronissi, Italy

<sup>2</sup>Department of Endodontics, Faculty of Dentistry, University of Alexandria, Alexandria, Egypt

**Aim:** the aim of this study is to evaluate the surface of root canal dentine using scanning electron microscope after using two different protocols of activation of sodium hypochlorite (NaOCl) (extracanal heating at 50°C and intracanal heating at 180°C).

**Methods:** 36 single-rooted teeth were selected, divided into three groups and shaped with ProTaper Universal instruments following irrigation protocols with 5.25% NaOCl. At the end of the preparation, three different protocols of activation were used: non heated NaOCl in Group A, extra-canal heated NaOCl at 50°C for Group B and intracanal heated NaOCl at 180°C for Group C. Specimens were cut longitudinally and analyzed by SEM at standard magnification of  $\times 1000$ . The presence/

absence of the smear layer as well as the presence/absence of open tubules at the coronal, middle, and apical third of each canal were estimated using a five-step scale for scores.

**Results:** Kruskal-Wallis analysis of variance (ANOVA) for debris score showed significant differences among the Ni-Ti systems ( $P < 0.05$ ). Mann-Whitney test confirmed that Group A presented significantly higher score values than other Ni-Ti systems. The same results were assessed considering the smear layer scores. ANOVA confirmed that the apical third of the canal maintained a higher quantity of debris and smear layer after preparation of all the samples.

**Conclusion:** intra canal heating of NaOCl at 180°C proved to be more effective in obtaining clean canal walls.

## TEMPORO-MANDIBULAR DISORDERS VARIATION IN SLEEP APNEA PATIENTS FOLLOWING TREATMENT

Alessandri-Bonetti A., Mangino G., Laureti A., Gallenzi P.

Orthodontics Residency Program, Director Prof. M. Cordaro, A. Gemelli Foundation, IRCCS Catholic University of Sacred Heart, Rome, Italy

**Aim:** patients suffering from obstructive sleep apnea (OSA) prior to undergo any treatment, present a higher prevalence of temporo-mandibular disorder (TMD) signs and symptoms compared to healthy controls. The aim of this research was to detect if a reduction in TMD prevalence can be expected after 18 months of OSA treatment.

**Methods:** we prospectively recruited adult OSA patients which had been examined according to the Diagnostic Criteria for Temporomandibular Disorders (DC/TMD) protocol prior to start any treatment for OSA. Patients underwent a second TMD examination after at least 18 months of OSA treatment, independently of the treatment option chosen. Data obtained during follow-up visit were compared to the ones obtained pri-

or to treatment beginning. Chi-squared test was used to compare data.

**Results:** a total of 22 patients were recruited. Six patients did not undergo any treatment for OSA and no variation in TMD was observed in this sample. Nine patients presented some kind of TMD prior to starting OSA treatment and 7 of those (78%) were TMD-free at the follow up visit. Seven patients were TMD-free prior to starting OSA treatment and 5 patients (71%) did not develop TMD during therapy. A statistically significant difference was observed in TMD prevalence before and after OSA therapy.

**Conclusion:** a reduction in TMD signs and symptoms is observed in OSA patients after sleep apnea therapy.

## ORAL DEVICES AND IMPACT ON ATHLETIC PERFORMANCE

Baldassin D.<sup>1</sup>, Tepedino M.<sup>1</sup>, Chimenti C.<sup>1</sup>, Illuzzi G.<sup>2</sup>, Campobasso A.<sup>2</sup>

<sup>1</sup>Department of Applied Clinical Sciences and Biotechnology, University of L'Aquila, L'Aquila, Italy

<sup>2</sup>Department of Clinical and Experimental Medicine, University of Foggia, Foggia, Italy

**Aim:** many studies demonstrate that the presence of an oral device modifies neuromuscular function of stomatognathic system. In the last forty years, several authors have investigated on the possibility that oral devices could affect not only stomatognathic system, but also athletic performance. The debate on this issue is still open. The purpose of this systematic review is to understand if oral devices can improve performance (especially power) in young-adult athletes.

**Methods:** this research is designed according to the Cochrane Handbook guidelines for systematic reviews. PubMed, Web of Science, Scopus and Cochrane were searched without time and language restriction. Risk of bias in individual studies was assessed with the Cochrane Collaboration's Tool for randomized studies, and the New castle Ottawa Scale for no-randomized studies.

**Results:** twenty-three studies were included in qualitative synthesis. The great heterogeneity didn't allow to conduct a meta-analysis. Results are not unanimous. Eleven authors affirm that using mouthguards can slightly improve athletic performance in young-adult athlete. However, this affirmation regards especially power parameters. In most studies that investigated the relationship between oral devices and isometric/isokinetic strength, results are negative.

**Conclusion:** power is really important in sports. Especially for professional athletes can be decisive to use something like occlusal splints which enhances power. It needs to be said that scientific research is still poor for this topic. There is a great variability in tools used and outcome measures. Further studies with close cooperation between specialists in dentistry and sport science are needed.

## CRANIOFACIAL MORPHOLOGY IN PATIENTS WITH OBSTRUCTIVE SLEEP APNEA

Bertuzzi F., Campagnoli G., Corna E., Pollis M., Santagostini A., Segù M.

Degree course in Dentistry and Dental Prosthetics, Department of Clinical-Surgical, Diagnostic and Pediatric Sciences, University of Pavia, Pavia, Italy

**Aim:** the aim of the study is to assess the relationship between cranio-facial morphology and the severity of OSA.

**Methods:** a sample of 14 adult patients (8 males and 6 females, mean  $\pm$  SD age =  $58 \pm 16.9$  years), with a polysomnography confirmed diagnosis of OSA (i.e., AHI over 5 events/h), was recruited from the Department of Clinical-Surgical, Diagnostic and Pediatric Sciences, Section of Dentistry (Pavia) and underwent a cephalometric evaluation. The cephalometric tracing was performed with Tweed analysis and using the Delta-Dent CE software.

Sleep parameters such as AHI, AHI supine, ODI and mean desaturation (%) were assessed. Correlation analysis between cephalometric features and AHI was performed by means of Pearson test.

**Results:** five of the OSA patients were diagnosed with mild OSA, 3 with moderate OSA, and 6 with severe OSA.

Mean AHI was  $24,3 \pm 19.3/h$ , mean AHI supine  $56,9/h$ , mean Oxygen Desaturation Index (ODI)  $18,95/h$ , mean desaturation  $93,55\%$ . Cephalometric variables were FMA  $19,3 \pm 1,4$ ; SNB  $78,8 \pm 0,8$ ; ANB  $1,25 \pm 3,4$ ; Occl Plane  $12,35 \pm 9,1$ ; PFH  $50,8 \pm 11$ . Pearson test showed a lack of correlation with any of the assessed cephalometric variables ( $p > .05$ ).

**Conclusion:** this investigation showed that apnea severity is not correlated to craniofacial parameters. However, most of the patients in the sample showed a reduced FMA, a tendency to skeletal class III, an anterotation of the occlusal plane.

Furthermore, prosthetic rehabilitations of the posterior sectors were found in many patients.

## DIGITAL WORKFLOW FOR CLINICAL MANAGEMENT OF PATIENTS WITH TEMPOROMANDIBULAR JOINT DISORDER

Bosco F.<sup>1</sup>, Gaydchuck M.<sup>1</sup>, Clerici C.<sup>1</sup>, Nota A.<sup>2</sup>, Tecco S.<sup>1</sup>

Department of Dentistry, Director Prof. E. Gherlone, University Vita-Salute San Raffaele, Milan, Italy

<sup>1</sup>School of Specialization in Orthodontics, Director: Prof. G. Gastaldi, Vita-Salute San Raffaele University, Milan, Italy

<sup>2</sup>Master's Degree Course in Dentistry and Dental Prosthetics, President: Prof. O. Cremona, Vita-Salute San Raffaele University, Milan, Italy

**Aim:** in a patient with temporomandibular joint disorders (TMD) symptoms, the use of a splint is often suggested.

Evaluation of TMD begins with a thorough patient history and clinical examination. In some cases, the clinical examination findings are sufficient to allow the dentist to arrive at a preliminary diagnosis and begin conservative treatment. However, other patients will require diagnostic imaging of the TMJs in order to provide information, which is not available from the clinical examination.

Today, new technology allows the computerized analysis of TMJs images and movements, improving diagnosis and manufacturing of a splint through a digital workflow. The results of these software must be correlated with the patient history and clinical findings in order to arrive at a diagnosis and plan treatment. In this clinical case, the procedure is described.

**Methods:** after anamnestic interview and a proper clinical examination, 3D models of the patient's arches are taken with an intraoral scanner. The .stl files are then transferred on the software (ModJaw®). This device works thanks to an optical camera that records the patients movements and reproduces them on a monitor. Additional images can be then imported into the software, such as a CT scan of the mandible, allowing the clinician to analyze the movements of the arches and of the TMJ at the same time.

**Results:** in the rehabilitation of the patient, digital records helped the clinician to make diagnosis and a treatment plant, improving the collaboration among dentist and technician.

**Conclusion:** digital techniques and 3D visualization can help the clinician to explore mandibular cinematics and improve clinical management of TMD patients.

## EVALUATION OF A CUSTOM-MADE, TITRATABLE MAD (ORTHOAPNEA NOA®) FOR TREATMENT OF OSAS

Campagnoli G., Bertuzzi F., Corna E., Santagostini A., Segù M.

Degree in Dentistry and Dental Prosthetics, Department of Clinical-Surgical, Diagnostic and Pediatric Sciences, University of Pavia, Pavia, Italy

**Aim:** the purpose of this study is to determine the effectiveness of ORTHOAPNEA NOA® MAD in the treatment of OSAS patients. Noa® is a two-piece MAD, the first worldwide one customized according to the mandibular kinematic of each patient.

**Methods:** the study is carried out on a sample recruited from the Department of Department of Clinical-Surgical, Diagnostic and Pediatric Sciences, Section of Dentistry of Pavia. The sample meets the following inclusion criteria: AHI > 5, age between 18 and 75 years old, initial PSG supplied.

PSG is repeated both at the baseline (T0) and 3 months after the start of therapy with NOA® (T1). Sleep parameters, such as AHI, supine AHI, ODI, SpO2 < 90% time, mean desaturation (%), are analyzed and compared between T0 and T1.

**Results:** the evaluation of the effectiveness of the NOA device® is based on a sample of 7 patients, 3 males and 4 females (mean age 57.4±10.72). T0 indexes were AHI 19.41 ± 8.74, supine AHI 34.58 ± 14.46, ODI 13.25 ± 9.87, SpO2 < 90% time 55.2 ± 93.64 minutes, mean desaturation 92,74 ± 2,23.

This sample includes 4 patients with mild OSAS (5 < AHI < 15), one with moderate OSAS (15 < AHI < 30) and 2 with severe OSAS (AHI > 30).

After treatment with NOA®, a relevant decrease of AHI (8.5 ± 1,55), supine AHI 9.95 ± 0,77, ODI (10,05 ± 0,9) and SpO2 < 90% (0,35 ± 0,49min) was observed.

**Conclusion:** MAD NOA® could be an effective alternative in the treatment of OSAS; the device has obtained significant results with the improvement of the PSG parameters.

## DIGITAL PLANNING OF ALIGNERS ORTHODONTIC TREATMENT IN PATIENT WITH PREVIOUS TMJ TRAUMA

Cavallaro M.<sup>1</sup>, Pittari L.<sup>2</sup>, Bosco F.<sup>2</sup>, Clerici C.<sup>2</sup>, Nota A.<sup>1</sup>, Tecco S.<sup>1</sup>

Department of Dentistry, Director Prof. E. Gherlone, Vita-Salute San Raffaele University, Milan, Italy

<sup>1</sup>School of Specialization in Orthodontics, Director: Prof. G. Gastaldi, Vita-Salute San Raffaele University, Milan, Italy

<sup>2</sup>Master's Degree Course in Dentistry and Dental Prosthetics, President: Prof. O. Cremona, Vita-Salute San Raffaele University, Milan, Italy

**Aim:** even if the gnathological treatment with occlusal splint is the reversible treatment most approved by the scientific literature, a prosthetic or orthodontic finalization can be performed after resolving the TMD symptomatology. The purpose of this case report is to show a digital planning of orthodontic treatment to achieve mandibular repositioning and occlusal stability after gnathological treatment in a young subject with previous temporomandibular and mandibular angle fracture.

**Methods:** a 20-year-old boy suffered of TMD after previous jaw trauma in 2017. Clinical examination showed occlusal instability with head to head anterior relationship and absence of posterior contacts. A gnathological treatment with occlusal splints was performed achieving the absence painful symptomatology. After 9 months an orthodontic treatment with clear aligners (Invisalign, Align Technology Inc. San Jose, CA, USA) was planned to achieve occlusal stability and mandibular repositioning according with the previous gnathological treatment.

**Results:** after 9 months of occlusal splints, the orthodontic treatment with clear aligners was planned in the first part with active aligners on the lower arch and maintaining the night splint on the upper arch to prevent the representation of TMD symptomatology. Then, passive aligners and/or the occlusal splint were positioned on the lower arch and active aligners started on the upper arch. Interocclusal elastics were applied to perform extrusion of the lateral-posterior sectors during the treatment.

**Conclusion:** this case report shows in a young subject with previous mandibular fracture how, after solving TMD symptomatology with gnathological treatment with occlusal splints, digital planning of orthodontic treatment with clear aligners is able to achieve a new occlusal and mandibular relationship in accordance with the previously achieved articular position with occlusal splints, allowing to continue the occlusal splints wearing during the treatment in order to prevent a possible exacerbation of previous TMD symptomatology.

## IMPACT OF PSYCHOLOGICAL TRAITS ON THE OCCLUSAL TACTILE ACUITY OF HEALTHY INDIVIDUALS

Coppola G.<sup>1</sup>, Lenci F.<sup>1</sup>, Lembo D.<sup>2</sup>, De Rosa F.<sup>3</sup>, Bucci R.<sup>1</sup>

<sup>1</sup>School of Orthodontics, Department of Neurosciences and Oral Sciences, University of Naples Federico II, Naples, Italy

<sup>2</sup>Department of Medical, Oral and Biotechnological Sciences, University G. D'Annunzio of Chieti-Pescara, Chieti, Italy

<sup>3</sup>Multidisciplinary Department of Medical-Surgical and Dental Specialties, University of Campania Luigi Vanvitelli, Caserta, Italy

**Aim:** to determine the effect of psychological traits on the ability to detect small thickness changes among antagonist teeth (occlusal tactile acuity, OTA) in subjects with natural dentition.

**Methods:** sixty-three (63) volunteers (32 males, 31 females; mean age  $24.6 \pm 2.7$ ) were enrolled. Standardized written questionnaires were used to measure different psychological characteristics: somatosensory amplification, general anxiety, depression, physical symptoms and catastrophizing. The OTA was tested with 9 aluminum foils (from  $8 \mu\text{m}$  to  $72 \mu\text{m}$ ) and 1 sham test (without foil); each thickness was tested 10 times randomly (100 tests in total). Participants were instructed to close their mouth and report whether they felt the foil or not. Considering the repetition of the measurements, mean percentage of correct answers was calculated for each thickness tested. Also, the minimum interdental threshold (MIT) was calculated, as the thickness that was correctly detected at least in

5 out of 10 tests. ANOVA for repeated measurement was computed to determine the effect of psychological traits on the detection thresholds. After Bonferroni correction, statistically significant differences were set at  $P < 0.005$ .

**Results:** a significant decrease in OTA was observed in subjects with moderate and severe anxiety, as compared to mild anxiety ( $p = 0.003$ ), and in subjects with severe catastrophizing as compared to mild catastrophizing ( $p = 0.008$ ). On the other hand, non-significant differences were found for somatosensory amplification, depression and physical symptoms ( $p = 0.276$ ;  $p = 0.195$  and  $p = 0.452$ , respectively). All the psychological variables presented significantly higher scores in individuals with greater MIT (all  $p < 0.005$ ).

**Conclusion:** individuals with increased anxiety and catastrophizing tend to have decreased perception of small thicknesses between antagonist teeth during maximum intercuspation.

## EVALUATION OF A PREFABRICATED ADJUSTABLE THERMOPLASTIC MAD (MYTAP™) FOR TREATMENT OF OSAS

Corna E., Cosi A., Bertuzzi F., Campagnoli G., Santagostini A., Scribante A., Segù M.

Degree in Dentistry and Dental Prosthetics, Department of Clinical-Surgical, Diagnostic and Pediatric Sciences, University of Pavia, Pavia, Italy

**Aim:** to assess the effectiveness of a prefabricated adjustable thermoplastic mandibular advancement device (PAT-MAD; MyTAP™) in the treatment of OSAS.

**Methods:** sixteen adult patients (13 men and 3 women) with a mean age of  $53.88 \pm 12.88$ , with diagnosed mild, moderate or severe OSAS on polysomnography (PSG) were recruited. Respiratory parameters included apnea-hypopnea index (AHI), oxygen desaturation index (ODI) and the lowest O<sub>2</sub> saturation (Low SpO<sub>2</sub>) were measured before (T<sub>0</sub>) and after 6 months (T<sub>1</sub>) of treatment.

**Results:** AHI index decreased from  $29.9 \pm 19.97$  to  $9.59 \pm 8.94$  after treatment ( $p$ -value = 0,0023), ODI index also decreased from  $21.06 \pm 16.05$  to  $8.20 \pm 9.67$  after treatment ( $p$ -value = 0,0129). No statistically relevant decrease of Low SpO<sub>2</sub> was observed ( $p$ -value = 0,8374) after treatment.

Significance for all statistical tests was set at  $p$ -value  $< 0.05$ . An additional study compared the AHI  $> 30$  sub-population with the AHI  $< 30$  sub-population. The AHI  $> 30$  sub-population consisted of 5 patients, all males, mean age  $47.6 \pm 14.04$  and initial AHI  $56.02 \pm 3.60$ . The AHI  $< 30$  consisted of 11 patients, 8 males and 3 females, mean age  $56.73 \pm 11.88$  and initial AHI  $18.03 \pm 5.28$ . ANOVA test and Tukey test proved a statistically relevant decrease in the AHI index from T<sub>0</sub> to T<sub>1</sub> in the sub-population AHI  $> 30$  with  $p$ -value  $< 0.05$ . Other comparison showed no statistically significant difference.

**Conclusion:** MyTAP™ is a device for trial use, but it appears also to be an effective and economical option for OSAS treatment, improving the polysomnographic parameters.

## CLINICAL AND INSTRUMENTAL TMJ EVALUATION IN CHILDREN WITH JUVENILE IDIOPATHIC ARTHRITIS

Di Carlo B., Caroccia F., Moscagiuri F., Breda L., D'Attilio M.

Department of Innovative Technologies in Medicine & Dentistry, University G. D'Annunzio of Chieti-Pescara, Chieti, Italy

**Aim:** to investigate muscle pain, mouth opening width and jaw deviation during mouth opening in Juvenile Idiopathic Arthritis (JIA) subjects.

**Methods:** a group of 32 subjects with JIA and a control group of 32 healthy subjects were evaluated. Muscle pain was registered through muscle palpation (masseters, anterior temporalis, and sternocleidomastoids), while mouth opening width and jaw deviation during mouth opening were assessed by kinesiography. Data were compared using Mann U Whitney test ( $p < 0.05$ ).

**Results:** higher pain was registered in the masseter and sternocleidomastoid muscles on both sides and in the right

anterior temporalis in the JIA group compared to control group ( $p < 0.05$ ).

Kinesiography showed a statistically significant difference in mouth opening width and jaw deviation during mouth opening between the groups ( $p < 0.05$ ): JIA subjects showed lower mouth opening values and wider deviation on mouth opening; 29 out of 32 JIA subjects showed jaw deviation on the right side.

**Conclusion:** JIA affects the TMJ causing myalgia in head and neck muscle, reduction of mouth opening width and increase in jaw deviation during mouth opening.

## THE EFFECT OF TELECONSULTATION ON OROFACIAL PAIN PATIENTS DURING PANDEMIC COVID-19

Diodati F., Averta F., Muraca D., Barone S., Giudice A.

School of Dentistry, Department of Health Sciences, University Magna Graecia of Catanzaro, Catanzaro, Italy

**Aim:** both physical and psychological factors can cause orofacial pain. Stressful events can worsen the intensity of pain and parafunctions. This study aimed to investigate, through teleconsultation, any modification in symptoms of patients with orofacial pain during the stressful period of the Coronavirus pandemic.

**Methods:** a retrospective study was conducted recording data of diagnostic criteria for temporomandibular disorder, VAS Temporomandibular joint (TMJ) scale, VAS headache scale, VAS myofascial pain scale and Perceived Stress Score (PSS). Each patient underwent a first medical evaluation (T0), a clinical check-up (T1), a telemedical consultation (T2) and finally subsequent checks (T3-T4). All patient at T2 was subjected to an online survey in which any modification in symptoms was investigated and instructions were provided until the next check-up. Statistical analysis was performed with  $\alpha = 0.05$  as level of significance.

**Results:** the study sample included 30 patients (mean age: 34.43 years). For myofascial pain, headache, and TMJ pain, an increase of VAS values at T2 was recorded in patients with higher pain intensity at T0 ( $p < 0.05$ ). This upward trend was significantly observed also analyzing pain intensity at T4 compared to VAS values at T2 ( $p < 0.05$ ). Myofascial pain VAS value was significantly associated with higher PSS at T0 and T2 ( $p < 0.05$ ). A significant correlation was recorded between myofascial pain intensity and functional limitation of the jaw at T2 and T4 ( $p < 0.01$ ).

**Conclusion:** higher stress level negatively influenced myofascial pain intensity during Covid-19 pandemic, favoring greater functional limitation of the jaw. Teleconsultations allowed to follow the patients during lockdown period, improving their conditions.

## TREATMENT OF BILATERAL TMJ ARTHROSIS PAIN WITH HYALURONIC ACID INFILTRATION: A CASE REPORT

Fornarelli G., Rizzi A., Marchesi A.

Department of Gnathology and Temporomandibular Disorders, University of Milan, Milan, Italy

**Aim:** the aim of the treatment is to reduce the pain symptoms in a patient suffering from bilateral arthrosis of the Temporomandibular joint by infiltration with hyaluronic acid.

**Methods:** the patient complained night headache and facial soreness, while at the oral examination we found left deflection in opening and contracture of the masticatory muscles. A nuclear magnetic resonance shows problems in the Temporomandibular joint: worn meniscus on the right side and irreducible dislocation on the left side. We proceed with three sessions of treatment of the right TMJ with a distance of two weeks from each other. Each session includes: anesthesia with 3% carboicain without adrenaline, joint washing with physiological 1-needle, infiltration of hyaluronic acid (20 mg/2 ml) to lubricate

the joint heads. At the end of the sessions we proceed with the remaking of the gnathological bite plate.

**Results:** there was reduction of joint noise, reduction of pain and improvement in opening. Symptoms are further diminished by the use of a new bite which partially contrasts the muscle tension.

**Conclusion:** according to scientific literature, infiltrations with hyaluronic acid are an option in the treatment of joint with arthrosis.

In this case infiltrations, associated with a bite plate, have proved to be a valid therapy for the decrease of painful symptoms in a patient suffering from bilateral TMJ arthrosis.

## RELATIONSHIP BETWEEN TMJ DISORDERS AND MALOCCLUSIONS

Fornarelli G., Rizzi A., Deleonardis M., Braga Ablondi E., La Mura G., Marchesi A.

Department of Gnathology and Temporomandibular Disorders, University of Milan, Milan, Italy

**Aim:** the aim of this study is to investigate the existence of an association between Temporomandibular disorders and malocclusions. Molar class, dental bite and midline deviation were considered; then also the association between DTM and orthodontic treatment was evaluated.

**Methods:** an observational study was conducted for 2 years on patients in their first gnathological visit. The subjects were divided into TMD and non-TMD and subjected to an extraoral, intraoral and functional clinical examination. The associations were evaluated by the chi-square test or the Kruskal-Wallis test when needed. Values of p level less than 0.05 were considered statistically significant.

**Results:** there was a statistically significant association between DTM and sex ( $p = 0,023$ ), but not between DTM and

previous orthodontic treatment ( $p = 0,918$ ). The prevalence of TMD is much higher in subjects with sagittal malocclusion ( $p < 0,0001$ ), as well as in those with open or deepbite ( $p = 0,003$ ). Finally, the association between midline deviation and the presence of DTM was statistically significant ( $p < 0,0001$ ) and the prevalence of TMD resulted twice as high in subjects with deviation  $> 3$  mm as in those with  $< 3$ mm.

**Conclusion:** the study found a 2-fold increased risk in women of suffering from TMD, as well as an association between TMD and malocclusion related to class, dental bite and midline deviation, although the existing results in literature are controversial on this association. No correlation was found between DTM and previous orthodontic treatment.

## THE USE OF BOTULINUM TOXIN TYPE A IN PATIENTS WITH TEMPOROMANDIBULAR DISORDERS

Fortunati C., Musto F., Vella M., Rosati R., Pellegrini G., Canciani E., Henin D., Dellavia C.

Department of Biomedical, Surgical and Dental Sciences, University of Milan, Milan, Italy

**Aim:** temporomandibular disorders (TMD) are a group of conditions that affect the temporomandibular joint and masticatory muscles, causing myofascial pain and restricted jaw opening capacity. Botulinum toxin (BTX) is a neurotoxin produced by *Clostridium Botulinum*, that interferes with the impulse of neuromuscular junction producing analgesic and muscle relaxing effects. This review of literature aimed at evaluating the efficacy of BTX-type A injection for TMD treatment.

**Methods:** randomized trials and systematic reviews were searched in PubMed database between 2011 and 2021, using “Botulinum toxin and temporomandibular disorders” as keywords. Among the 21 articles, we identified 6 that dealt with both topics. The systematic review by Patel et al. 2019 included all the resulting articles.

**Results:** Patel’s review analyzed articles lasting from 2001 to 2018 including 15 to 90 patients, mostly mid-aged women. TMD

patients treated with BTX-A were compared with control subjects treated with saline injection, conservative treatment, low level laser therapy or manipulations. Test patients suffered from 1-to-6-month muscular diseases and/or bruxism, non-responding to previous treatment; only one study analyzed articular patients. In all studies, the primary outcome was pain reduction measured by VAS or questionnaire with a follow-up ranging from 1 to 12 months. Injections were performed in masseters alone or also in temporalis muscle with variable dosage. Controversial data about pain reduction were obtained. After an initial improvement in the BTX-A group with not negligible side effects, no significant differences were found between groups over time.

**Conclusion:** conservative approach is the recommended TMD management but BTX-A injections may represent an option in non-responders and for bruxism. Consensus is lacking and more studies are needed to identify all possible benefits.

## EVALUATION OF CERVICAL MOVEMENTS DURING GNATHOLOGICAL SCREENING

Nota A., Gamba L., Bosco F., Beraldi A., Tecco S.

Dental School, Vita-Salute San Raffaele University and IRCCS San Raffaele Hospital, Milan, Italy

**Aim:** during the gnathological examination, the dentist often evaluates the tract of the cervical spine, for example through the palpation of the cervical and sternocleidomastoid muscles, or through the electromyographic evaluation of the neck muscles. The 9-axis accelerometer is an electromedical device that allows the evaluation of the cervical range of motion and speed of execution of the main movements of the head on the neck (rotation, flexion-extension, and lateroflexion). Even though it is a rather simple instrument to use, the correct execution of the examination requires attention from the clinician to check that all the movements of the head are performed correctly and without unwanted movements of the shoulders. No literature studies have analyzed the repeatability of the tests when performed by dentists. Therefore, this pilot study aimed to evaluate the repeatability of the data.

**Methods:** healthy volunteers (mainly dentistry students) were included in the sample.

An accurate protocol based on a review of the existing literature was prepared for the standardized execution of the exams. The test was performed twice for each volunteer and the interval between the tests was 2 weeks, both in the university dental clinic (by a non-expert operator) and in a private practice (by an expert operator).

**Results:** the results demonstrate the importance of correct execution of the test and the control of the operator to obtain data reliability.

**Conclusion:** the accelerometer is a medical device that seems promising for a standardized examination of cervical spine kinematics during gnathological screening.

## COMPARISON BETWEEN QUESTIONNAIRE AND EMA FOR AWAKE BRUXISM ASSESSMENT

Lenci F.<sup>1</sup>, Coppola G.<sup>1</sup>, Lembo D.<sup>2</sup>, Michelotti A.<sup>1</sup>.

<sup>1</sup>School of Orthodontics, Department of Neurosciences, Reproductive Sciences and Oral Sciences, University of Naples Federico II, Naples, Italy

<sup>2</sup>Department of Medical, Oral and Biotechnological Sciences, University G. D'Annunzio of Chieti-Pescara, Chieti, Italy

**Aim:** several tools have been proposed to assess awake bruxism (AB). Recently, a smartphone-based application for ecological momentary assessment (EMA) has been introduced to collect data on AB. The aim of this study was to compare the self-report of AB by means of a standardised questionnaire, with the EMA recording.

**Methods:** one-hundred fifty-one (N = 151) individuals (mean age  $27.2 \pm 8.1$  years) were recruited from the general population of the city of Naples (Italy). Participants were invited to fill-in the Oral Behaviour Checklist (OBC), and scores of 4 individual questions concerning clenching, grinding, tooth contact, and mandible bracing were computed. Afterwards, participants were provided with a dedicated smartphone application to report in real time their condition among five possible options: relaxed jaw muscles, teeth contact, clenching, grinding, and mandible bracing. One-way Analysis of Variance (ANOVA) was used to compare the different responses

of each individual OBC question, with the mean frequencies of the same condition recorded with the EMA, over a 7-days period. Statistical significance was set at  $P < 0.05$ .

**Results:** within each OBC question, significantly different frequencies were reported for the respective condition recorded with the EMA (*question-3 vs. grinding*:  $F(3,147) = 56.21$ ;  $P < 0.001$ ; *question-4 vs. clenching*:  $F(3,147) = 11.84$ ;  $P < 0.001$ ; *question-5 vs. teeth contact*:  $F(4,146) = 5.60$ ;  $P < 0.001$ ; *question-6 vs. bracing*:  $F(4,146) = 4.13$ ;  $P = 0.003$ ). In particular, increased frequencies of clenching, grinding, and teeth contact were recorded by individuals who provided high OBC scores, while inconsistent findings were observed for the condition "mandible bracing".

**Conclusion:** good overlapping of responses was observed between OBC and EMA in the recording of AB. However, difficulties were pointed out in the comprehension of the condition "mandible bracing".

## A PRELIMINARY CASE-CONTROL STUDY OF THE SSEMGM PATTERN IN PATIENTS TREATED WITH INVISALIGN

Nardi N., Nucci F., Bica E., Maspero C., Gianni A., Spadari F.

Department of Dentistry, IRCCS Ca' Granda Maggiore Policlinico Hospital, Milan, Italy; University of Milan, Milan, Italy

**Aim:** the use of braces, ligatures, archwires and other elements of conventional orthodontic treatment make dental hygiene difficult; this interferes with aesthetics and causes patient discomfort.

With the significant recent improvements in computer-aided design/computer-aided manufacturing (CAD/CAM) and dental materials, we have seen an increase in the demand for customized aesthetic systems. Subsequently, plastic orthodontics, specially designed for adult patients, have been developed.

On the other hand, this treatment provides for a prolonged absence of contact between the dental arches, thus preventing the gain of intercuspation during therapy. The aim of this study was to evaluate by standardized surface electromyographic analysis (ssEMG) whether patients treated with aligners presented a difference in the activity of the masseter (MM) and temporal (TA) muscles from patients treated with a fixed appliance or not.

**Methods:** 18 patients (average age  $20.2 \pm 8.4$ ) with class I or class II molar relation, ANB angle between  $1^\circ$  and  $5^\circ$ , cranio-mandibular angle between  $28^\circ$  and  $38^\circ$ , space discrepancy  $<4$  mm, overjet and overbite between 1 and 4 mm and no transverse skeletal deficits were recruited. 8 patients were treated with traditional MBT prescription-brackets (ORTO group), while 10 patients were treated with Invisalign® (ALIGN group). SsEMG (Easymyo, Udine, Italy) was the instrumental investigation used to evaluate the activity of masticatory muscles before (T1), at the end (T2) and 3 months (T3) after the treatment. Functional parameters including symmetry (POC), intensity (IMPACT) of MM and TA, antero-posterior balance (ACTIVITY) and torsion (TORQUE) were detected. A descriptive analysis was performed.

**Results:** as for the duration of the therapy, ORTO treatments took  $20.3 \pm 4.3$  months while ALIGN treatments took  $14.2 \pm 5.9$  months to end. At T1, records showed good ssEMG

indexes without significant differences between groups. At T2, ORTHO group showed a slight decrease in POC and AC-TIVITY indexes and a mild increase in IMPACT index. All the indexes were normalized at T3. In align group, no changes were observed between each time points.

**Conclusion:** ORTHO group showed a moderate electromyographic indexes alteration at T2. However, standard deviations at T3 were much higher in the ALIGN group compared to ORTHO group, thus indicating a higher degree of variability in response to such treatment.

## MASTICATORY MUSCLES MYALGIA AND MYOTATIC REFLEX ACTIVATION IN SLEEP APNEA PATIENTS

Ossani F., Alessandri-Bonetti A., Mangino G., Gallenzi P.

Orthodontics Residency Program, Director Prof M. Cordaro, A. Gemelli Foundation, IRCCS-Catholic University of Sacred Heart, Rome, Italy

**Aim:** in patients suffering from obstructive sleep apnea (OSA), a temporo-mandibular disorder (TMD) evaluation should be performed prior to starting any treatment. The aim of this research was to detect if myotatic reflex activation of masticatory muscles during drug-induced sleep endoscopy (DISE) can be an indirect marker for masticatory muscle pain in OSA patients.

**Methods:** we prospectively recruited adult OSA patients with indication to DISE from the Otolaryngology department of A. Gemelli Hospital. Prior to starting DISE procedure, patients were evaluated according to the DC/TMD protocol, which represents the gold standard for TMD diagnose. Patients later underwent DISE with the addition of electrodes applied over masseter, temporalis and digastric muscles. A positive activation of myotatic reflex was

considered in case of an increase in muscles tone of at least 50%. The ethical approval was obtained prior to the study beginning.

**Results:** a total of 41 patients were included in the study and 20 of those, presented activation of myotatic reflex. When observing patients which presented myotatic reflex activation during mandibular advancement, 7 patients (35%) presented a positive diagnose of TMD, 9 patients (45%) presented pain at masticatory muscles palpation and 3 patients (15%) did not report pain during clinical examination. Myotatic reflex activation test presents a sensibility of 0.67 and a specificity of 0.82.

**Conclusion:** myotatic reflex activation during mandibular advancement during DISE is a useful test to detect patients at risk of suffering from masticatory muscle pain.

## STUDY OF THE RELATIONSHIP BETWEEN TEMPOROMANDIBULAR DISORDERS AND ORAL BEHAVIORS

Pancari C., Soares T., Sardinha J., Barbosa C.

Mestre Integrado de Medicina Dentária, Universidade Fernando Pessoa, Porto, Portugal

**Aim:** epidemiological cross-sectional study to determine the relationship between Temporomandibular Disorders and Oral Behaviors in students of the Integrated Master of Dental Medicine - University Fernando Pessoa.

**Methods:** 106 students were assessed based on self-completion of the *Oral Behavior Checklist* and clinical examination of the *Diagnostic Criteria for Temporomandibular Disorders* to assess the prevalence of Temporomandibular Disorders and Oral Behaviors as well as their relationship. The results of the *Oral Behavior Checklist* were evaluated by the sum of 21 items (0-4 points for each item) ranging from 0-84. The Oral Behaviors sum was categorized into tertiles considering 0-16 normal behavior, 17-24 low parafunction risk and 25-84 high parafunction risk.

The statistical analysis was performed with the SPSS v.25.0 program considering a significance level of 0.05.

**Results:** it was found that only the habit of clenching teeth during the day has a statistically significant relationship with the appearance of Temporomandibular Disorders ( $p = 0.012$ ). However, with regard to the relationship between Temporomandibular Disorders and the Oral Behaviors sum, only category 25-84 presents a 3.5 times greater risk of developing Temporomandibular Disorders ( $p = 0.013$ ).

**Conclusion:** among the limitations of the study it was observed that there is a relationship between Temporomandibular Disorder and Oral Behaviors in university students.

## EVALUATION OF THE ACCURACY OF IMAGING SOFTWARE FOR 3D ANALYSIS OF THE CONDYLE FROM CBCT

Peters A., Palazzo G., Deodato L., Venticinque V., Ronsivalle V., Lo Giudice A.

Department of Orthodontics, University of Catania, Catania, Italy

**Aim:** the present study evaluates the accuracy of four software for semi-automatic segmentation of the condyle, compared with manual segmentation approach. We referred to a specific 3D digital diagnostic technology involving the surface-to-surface matching and deviation analysis of 3D rendered condylar models. The null hypothesis was the absence of significant differences in the accuracy of semi-automatic segmentation software compared to manual segmentation.

**Methods:** 10 CBCT were selected to perform semi-automatic segmentation of the condyles by using three free software (Invesalius, ITK-Snap and Slicer 3D) and one commercially available software (Dolphin 3D). The same models were also manually segmented (Mimics) and set as ground truth. The accuracy of semi-automatic segmentation was evaluated by: 1) comparing the volume of each semi-automatic 3D rendered condylar model to that one obtained with manual segmentation, 2) deviation analysis of

each 3D rendered mandibular models with those obtained from manual segmentation. Kruskal-Wallis test, Signed-Rank Test and Intraclass correlation coefficient (ICC) were used to assess.

**Results:** no significant differences were found in the volumetric dimensions of the condylar models among the tested software ( $p > 0.05$ ). The color-coded map showed underestimation of the condylar models obtained with ITK-Snap and Slicer 3D, and overestimation with Dolphin 3D and Invesalius. The ICC values ranged from 0.993 to 0.997 for intra-observer reliability and from 0.996 to 0.998 for inter-observer reliability. Only manual segmentation showed a statistical significance between first and second readings.

**Conclusion:** despite the excellent reliability, data of condylar morphology obtained with semi-automatic segmentation should be taken with caution when an accurate definition of condylar boundaries is required.

## CORRELATION BETWEEN BRUXISM AND GERD AND THEIR EFFECTS ON TOOTH WEAR: A SYSTEMATIC REVIEW

Pittari L., Gaydchuck M., Cavallaro M., Nota A., Tecco S.

Department of Dentistry, Director Prof. E. Gherlone, Vita-Salute San Raffaele University, Milan, Italy; Vita-Salute San Raffaele University, Milan, School of Specialization in Orthodontics, Director: Prof. G. Gastaldi, Milan, Italy

**Aim:** bruxism and gastroesophageal reflux can lead to wear of the dental tissues. Wear has mechanical or chemical origin and it is of extrinsic or intrinsic type. Bruxism and gastroesophageal reflux are two aetiological factors of dental wear. The intrinsic mechanical wear (abfraction) of Bruxism and intrinsic chemical wear (erosion) of gastroesophageal reflux are both involved in sleep disorders; indeed, they could have associations and act in synergy in dental wear. The purpose of this review was to find out the possible associations between bruxism and gastroesophageal reflux and their effects on tooth wear.

**Methods:** the research was conducted on PubMed and the Cochrane Library using the following Keywords/Mesh Terms: Tooth wear, Bruxism, Sleep Bruxism, Sleep Disorders or Gastroesophageal Reflux. Only systematic reviews and clinical

studies performed exclusively on human subjects were included in the review.

**Results:** the research gave more than 800 publications on dental wear, bruxism and gastroesophageal reflux and after application of the inclusion criteria irrelevant studies and any duplicates were excluded. It was possible to observe the presence of some associations between the two problems and hypothesize negative effects on tooth wear.

**Conclusion:** the research revealed the presence of an interconnection between these three problems that can further act in synergy by attacking the hard dental tissues both from a chemical (reflux) and mechanical (bruxism) point of view. The dentist could play a role of “sentinel” in a multidisciplinary team, intercepting these problems early in order to be able to treat them in the most appropriate way.

## TREATMENT OF TMJ ARTHROSIS PAIN WITH HYALURONIC ACID INFILTRATION: A CASE REPORT

Rizzi A.<sup>1</sup>, Marchesi A.<sup>2</sup>, Fornarelli G.<sup>1</sup>, La Mura G.<sup>1</sup>

<sup>1</sup>Student, Department of Gnathology, University of Milan, Milan, Italy

<sup>2</sup>Guest professor, Department of Gnathology, University of Milan, Milan, Italy

**Aim:** the aim of the treatment is to reduce pain symptoms in a patient with temporomandibular joint osteoarthritis by infiltration with hyaluronic acid.

**Methods:** the patient, who was already using bite, complained of difficulty opening her mouth and pain in the right periauricular area.

Oral examination revealed reduced mouth opening, left deflection and contracture of the masticatory muscles. Pending magnetic resonance imaging (RMN) results, Diazepam 5mg/ml and paracetamol 1000 mg were prescribed to reduce the symptoms. The RMN showed thinning of the meniscus, arthrosis

and joint effusion on the right side. We proceeded with three treatment sessions of treatment of the right TMJ one week apart from each other. Each session included: anesthesia with 3% carbocaine without adrenaline, joint irrigation with physiological 1-needle, infiltration of hyaluronic acid (HYALGAN, 20 mg/2 ml) to lubricate the joint heads.

**Results:** the intra-articular infiltrations reduced pain and there was a marked improvement in mouth opening mouth.

**Conclusion:** infiltrations with hyaluronic acid have been shown to be a valid therapy for resolving pain symptoms in patients suffering from TMJ arthrosis.

## PREVALENCE OF TEMPOROMANDIBULAR DISORDERS IN RHEUMATOID ARTHRITIS: RELATION WITH SEROLOGY

Rotolo R. P.<sup>1</sup>, Monsurrò A.<sup>1</sup>, Olivieri Alma N.<sup>2</sup>, Piancino M. G.<sup>3</sup>, Minervini G.<sup>1</sup>, d'Apuzzo F.<sup>1</sup>

<sup>1</sup>Multidisciplinary Department of Medical-Surgical and Dental Specialties, Orthodontics Program, University of Campania Luigi Vanvitelli, Caserta, Italy

<sup>2</sup>Department of Women, Children and General and Specialized Surgery, University of Campania Luigi Vanvitelli, Caserta, Italy

<sup>3</sup>Department of Surgical Sciences, University of Turin, Turin, Italy

**Aim:** Rheumatoid Arthritis (RA) is a systemic and chronic autoimmune disease with persistent inflammation at the synovial joints causing morphological deformities and pain. RA may severely affect the normal functions of temporomandibular joints (TMJ) in a range from 45% to 92.8% of adults. The main clinical signs of the TMJ involvement with RA are arthralgia, stiffness during mouth opening and, upon waking, joint noises and limited functions. Early diagnosis, treatment and monitoring of TMJ disturbances should be extremely important for quality of life. The aim of this study was to evaluate the prevalence of TMJ disorders (TMD) in patients with RA and their eventual correlation with serology.

**Methods:** the study group consisted of 17 patients (2 males and 15 females) aged between 36 and 76 years. Patients were excluded if they had incomplete medical records, congenital or acquired facial anomalies, previous maxillofacial surgery or orthodontics. Patients were asked if they suffered of any TMD (joint sound, locking, or functional limitations). A clinical eva-

luation was performed and dental casts, panoramic x-rays and serological analysis were collected. In particular, rheumatoid factor (RF), C-reactive protein (CRP), erythrocyte sedimentation rate (ESR), immunoglobulin M-RF, anti-CCP antibody and anti-nuclear antibody (ANA) were evaluated.

**Results:** the symptoms at the TMJ reported in patients with RA were tenderness/pain in the joint area (arthralgia) in 64,7%, joint sounds in 47,0% and myofascial pain in 64,7%. High positive RF showed a significant correlation with the presence of TMD (60%). The anti-CCP antibody and ANA were positive in 40% while CRP and ESR showed high levels in 46,7% of patients with TMJ derangements.

**Conclusion:** RA seems to play a role in TMD, with a higher frequency of patients' complaints.

Moreover, all the serological tests, in particular the RF, showed a strong correlation with the presence of TMJ disorders. Further investigations should be performed in a wider sample.

## NANOTECHNOLOGICAL SUPPORTS (TAOPATCH®) IN DIFFERENTLY ABLE ENTITIES

Sedran A., Sindici E., Rizzi R., Sedran A.

Department of Surgical Sciences, Director Prof. S. Carossa, Dental School, University of Turin, Turin, Italy

**Aim:** dental therapies in people with disabilities must be provided with the same principles used for the rest of the population. The complexity of the treatment is influenced by the severity of the disability itself. The “Taopatch®” informational nanotechnology, which promotes positive interaction with biological systems, supports a more comfortable dental therapy for the patient and the operator.

**Methods:** anamnesis and physical examination of patients who refer to the clinic for the disabled are collected, assessing the degree of collaboration and autonomy. 14 patients with difficulty opening the oral cavity and little resistance to maintaining it, not otherwise managed, were selected. The “Taopatch® TMJ” devices apply. The maximum opening of the mouth is measured at the time T0 start, T1 after the preparation, and T2 at the

end of therapy. The VAS scale is evaluated at times T0, T1, and T2 and the comfort test at T0 and T2.

**Results:** the different dental treatments with and without the use of “Taopatch® TMJ” were compared. Their use made it possible to complete the therapeutic session, optimizing patient collaboration and consequently reducing operator stress.

**Conclusion:** the use of “Taopatch® TMJ” in this study highlighted better proprioception, greater resistance to fatigue in keeping the mouth open and accepting therapy. Short- and medium-term dental therapies could be carried out with less discomfort for patients and better comfort for the operator. The promising study highlighted unexpected clinical facilitation. Future research is desirable to define standardized criteria.

## ELECTROMAGNETISM AS ADD-ON THERAPY FOR CHRONIC CERVICO-FACIAL PAIN

Storari M., Vaccaro R., Spinis E.

Department of Surgical Science, Institute of Dentistry, University of Cagliari, Cagliari, Italy

**Aim:** chronic pain is responsible for widespread disabling consequences. Often it requires the use of medications which may additionally impact the quality of life with their side effects. Electromagnetism is investigated as add-on therapy for the treatment of chronic musculoskeletal cervical and facial pain.

**Methods:** an observational trial was conducted including 15 individuals, all females, aged between 28 and 65. All patients were diagnosed with chronic musculoskeletal cervico-facial pain. Recruited patients continued the appropriate pharmacological treatment and those who respond adequately to appropriate medications were excluded. The electromagnetic field was provided via a small and flexible plastic patch, 2x3cm in size, which is comfortably wearable in the neck area. The device emits low- and very low-frequency electromagnetic waves aimed to promote a direct regularization of the calcium transmembrane flow and to

reduce the pro-nociceptive changes induced in calcium channels in a non-specific way, both voltage- and ligand-dependent.

**Results:** quantitative analysis revealed an important decrease in pain levels in the overall sample during the observational period. Median VAS scale values at each periodic check appeared notably lower than T0 (6,55), respectively 4,40 (1 month later), 4,03 (3 months later), 2,95 (6 months later), and 4,00 (12 months later). Clinical reports suggested that most of the patients revealed improvements in pain intensity already the day after the application. Benefits concerning other symptoms were also reported, such as decreased morning shoulder joint stiffness, headaches and masticatory fatigue. Similarly, daily mood and sleep improved.

**Conclusion:** electromagnetism-based therapy appeared effective in treating chronic musculoskeletal cervico-facial pain, with broader improvements and no side effects.

## ALTERED MASTICATION IMPACTS MORPHO-FUNCTIONAL FEATURES OF HIPPOCAMPUS: A SYSTEMATIC REVIEW

Tortarolo A., Matacena G., di Benedetto L., Piacino M.G.

Department of Surgical Sciences, Dental School C.I.R., Division of Orthodontics, University of Turin, Turin, Italy

**Aim:** recent results have established that masticatory function plays a role not only in the balance of the stomatognathic system and in the central motor control, but also in the trophism of the hippocampus and in the cognitive activity. These implications have been shown in clinical studies and animal researches as well, by means of histological, biochemical and behavioural techniques.

**Methods:** this systematic review describes the effects of three forms of experimentally altered mastication, namely soft-diet feeding, molar extraction and bite-raising, on trophism and function of hippocampus in animal models. Through a systematic search of PubMed, Embase, Web of Science, Scopus, OpenGray and GrayMatters, 645 articles were identified, 33 full text articles were assessed for eligibility and 28 articles were included in the review process. The comprehensiveness of reporting was evaluated with ARRIVE guidelines and the risk of bias with SYRCLE RoB tool.

**Results:** the literature reviewed agrees that a disturbed mastication is significantly associated with a reduced number of hippocampal pyramidal neurons in Cornu Ammonis CA1 and CA3, downregulation of Brain Derived Neurotrophic Factor, reduced synaptic activity, reduced neurogenesis in the Dentate Gyrus, glial proliferation, and reduced performances in behavioural tests indicating memory impairment and reduced spatial orientation. Moreover, while the bite-raised condition, characterized by occlusal instability, is known to be a source of stress, soft-diet feeding and molar extractions were not consistently associated with a stress response. More research is needed to clarify this topic.

**Conclusion:** the role of chewing in the preservation of hippocampal trophism, neurogenesis and synaptic activity is worthy of interest and may contribute to the study of neurodegenerative diseases in new and potentially relevant ways.

## SSEMG OF THE MASTICATORY MUSCLES MONITORING IN TMD PATIENTS MANAGED WITH OCCLUSAL SPLINT

Vella M., Musto F., Fortunati C., Rosati R., Pellegrini G., Henin C., Sirello R., Dellavia C.

Department of Biomedical, Surgical and Dental Sciences, University of Milan, Milan, Italy

**Aim:** to monitor the neuromuscular balance of occlusion in a group of patients with temporomandibular disorders (TMD) managed with occlusal splint, by means of standardized surface electromyography (ssEMG).

**Methods:** five patients with a muscular TMD, according to diagnostic criteria for temporomandibular disorders (DC/TMD) were recruited.

At T0, all subjects reported myalgia, familiar pain on palpation of masseter (MM) and anterior temporalis (TA) and underwent to ssEMG of MM and TA activity during maximum teeth clenching. Indexes of symmetry (POC-percentage overlapping coefficient), localization of the occlusal forces center (activation, ratio between TA and MM potentials), torsional effect (torque) and global electrical activity (impact, average of muscular activity) were computed.

An inferior stabilization splint with only posterior contacts was prescribed and patients were followed-up with ssEMG after three (T1) and six months (T2).

**Results:** at T0, T1, T2 indexes were respectively: POC (82,75%, 85,10%, 85,23%), activation (-14,33%, -6,61%, -0,13%), torque (-1,07%, -0,95%, -2,15%), impact (101,66%, 115,08%, 90,11%). At T2, all patients experienced relief of symptoms. All EMG indexes improved from T0 to T2, showing a progressive attainment of a physiological neuromuscular balance of occlusion.

**Conclusion:** SsEMG helps to quantify the benefits of conservative treatments such as occlusal splint, thus implementing the standard qualitative assessment and self-reporting data (questionnaire, VAS) and allowing early detection of eventual muscular impairment.

## THE ACCURACY AND MINIMAL INVASIVENESS OF COMPUTER GUIDED IMPLANT SURGERY IN AESTHETIC AREA

Caggiano M., Acerra A., Iandolo A., Scognamiglio B., Argentino S.

Department of Medicine, Surgery and Dentistry, Scuola Medica Salernitana, University of Salerno, Baronissi, Italy

**Aim:** the aim of this study was to evaluate diagnostic-therapeutic accuracy of computer-guided implant placement with flapless procedure with digital measurements on computed-tomography Cone Beam (CTCB).

**Methods:** we recruited patients who received tooth extraction in aesthetic area. To preserve post extractive bone resorption the socket was grafted with a biomaterial. A CTCB scan and intraoral digital impression were revealed and implant insertion was planned with computer guided implant software. After 3 months from surgery, a control CTCB was performed to analyze the congruence of implant placement compared to pre-operative digital planning. For the analysis 3 digital measurements were detected: the variation of implant axis in degrees, mesiodistal implant deviation both at the apex and at the implant head level.

**Results:** 30 implants were placed in patients ranged in age from 27 to 45 years with tooth-supported digital design 3D printed guided. After 7 days from implant surgery an advanced soft tissue healing, absence of edema and postoperative pain were detected in 100% of treated cases. The mean deviation of implant axis was  $2,1^{\circ} \pm 0,7^{\circ}$  in sagittal projection, the mean mesiodistal implant deviation between adjacent teeth was  $0,2 \text{ mm} \pm 0,1 \text{ mm}$  at implant head level and  $0,8 \text{ mm} \pm 0,3 \text{ mm}$  at the apex in axial projection.

**Conclusion:** our finding show that computer-guided implant placement is extremely accurate. In particular when combined with post-extractive socket preservations technique, it allows a simplified and predictable implant placement with a minimal surgical trauma.

## UP TO 5 YEARS FOLLOW-UP OF FEATHER EDGE CROWNS ON TISSUE- VS BONE-LEVEL SINGLE IMPLANTS

Bagnasco F.<sup>1</sup>, Menini M.<sup>1</sup>, Di Tullio N., Pesce P.<sup>1</sup>, Canullo L.<sup>2</sup>

<sup>1</sup>Department of Surgical Sciences and Integrated Diagnostics, University of Genoa, Genoa, Italy

<sup>2</sup>Private Practice, Rome, Italy

**Aim:** the purpose of this retrospective study was to assess the outcomes of crowns designed according to the biologically oriented preparation technique (BOPT) cemented on conical titanium abutments on tissue level and bone level implants.

**Methods:** patients consecutively rehabilitated with a delayed loading protocol with anterior implant-supported single crowns with a feather edge margin, in function for at least 4 years, were recruited and divided in 2 groups based on the implant type they had received: tissue level implants with a conical transmucosal portion or bone level implants rehabilitated with a conical abutment by following the platform switching concept. Bone resorption, pink esthetic score (PES), and white esthetic score (WES) were collected and analyzed. The non-

parametric Mann-Whitney test was performed to analyze all parameters ( $\alpha=.05$  for all tests).

**Results:** a total of 43 participants (48 implants) were included in the present study. The mean follow-up period was 4.5 years (range 52-64 months). A statistically significant difference ( $P = .004$ ) was found in the mean  $\pm$  standard deviation bone resorption between tissue level implants ( $0.38 \pm 0.46 \text{ mm}$ ) and bone level implants ( $0.83 \pm 0.58 \text{ mm}$ ). Higher values for both PES and WES were obtained in the tissue level implant group.

**Conclusion:** within the limitations of the present retrospective study, tissue level implants with a conical transmucosal portion seem to provide a suitable alternative to bone level implants in the anterior area.

## VITAMIN D AND OSSEOINTEGRATION: A SYSTEMATIC REVIEW

Bertini G., Prezioso D., Di Maggio I., Borgoli C., De Cesaris E., Duvina M., Tonelli P.

School of Specialization in Odontostomatological Surgery, Director Prof. P. Tonelli, University of Florence, Florence, Italy

**Aim:** the role of vitamin D and its efficacy in implant osseointegration is currently unclear.

The aim of this study was to make a systematic review of the literature on the influence of vitamin D in osseointegration process.

**Methods:** this review was done with the PRISMA statement tools. For studies identification to include in our analysis, an electronic search was carried out on the databases of PubMed, Cochrane Central Register of Controlled Trials and Embase (last access on 02/14/2021).

Furthermore, the following sector journals were browsed for the last 10 years: Clinical Oral Implants Res, J Oral Maxillofacial Res and Oral Surg Oral Med Pathol Oral Radiol. Finally we have read the bibliography of the included works.

The keywords used were: Vitamin D, Vit. D, Vitamin D3, Vit. D3, osseointegration, dental implant, 1.25 dihydroxyvitamin D3. Only studies written in English before 02/02/2021 were included.

**Results:** electronic and print research identified 231 articles and, after the screening, 14 articles were included. The heterogeneity of the criteria and parameters used in the studies makes it impossible to perform a meta-analysis. Six main topics were found in the studies: effects of vitD deficiency on osseointegration in the rats, effects of vitD administration on osseointegration in ovariectomized rats, effects of vitD supplementation in the diabetic rat model, effect of vitD coating of the implant surface in dogs and rabbits, effects of vitD gene polymorphism on the osseointegration of implants in human and rat model, effects of vitD deficiency on osseointegration in human model.

**Conclusion:** the administration of vitD in the majority of the studies analyzed in this systematic review seems to give a moderately positive result on the osteointegration of dental implants and to show that the effectiveness of vitD is proportional to its level of deficiency. However, at this time of research there isn't an efficacy protocol of vitD administration.

## WIDE-DIAMETER IMMEDIATE POST-EXTRACTIVE IMPLANTS VS SOCKET PRESERVATION: 5-YEARS RCT

Bonifazi L.<sup>1,2</sup>, Barausse C.<sup>1,3</sup>, Montebugnoli A.<sup>1</sup>, Di Simone S.<sup>1</sup>, Karaban M.<sup>1</sup>, Felice P.<sup>1</sup>

<sup>1</sup>Oral Surgery, Department of Biomedical and Neuromotor Sciences, University of Bologna, Bologna, Italy

<sup>2</sup>Department of Basic Medical Sciences, Neurosciences and Sense Organs, University of Bari Aldo Moro, Bari, Italy

<sup>3</sup>Postgraduate school of Oral Surgery, University of Modena and Reggio Emilia, Modena, Italy

**Aim:** to compare the effectiveness of 6- to 8-mm-wide diameter implants placed immediately after tooth extraction with conventional diameter implants placed in preserved sockets.

**Methods:** just after extraction of one or two molar teeth, and in the presence of no vertical loss of buccal bone in relation to the palatal wall, 100 patients were randomly allocated to either immediate placement of one to two 6- to 8-mm-wide diameter implants or one or two 4.0- or 5.0-mm-wide delayed implants to be placed four months after socket preservation using a porcine bone substitute covered by a resorbable collagen barrier.

Bone-to-implant gaps at immediate implants were filled with autogenous bone. Implants were loaded 4 months after placement with provisional prostheses. After 4 months, definitive restorations were delivered.

**Results:** five years after loading, 7 patients from the immediate group and 8 from the delayed group dropped out. Ten

out of 43 patients in the immediate group (23.3%) experienced one implant failure versus 2 out of 42 (4.8%) in the delayed group, the difference being statistically significant. Sixteen patients in the immediate group were affected by 21 complications, and 4 patients by 4 complications in the delayed group, a statistically significant difference.

Five years after loading, patients in the immediate group lost on average  $1.82 \pm 0.72$  mm of peri-implant marginal bone, and those in the delayed group lost  $0.84 \pm 0.33$  mm, the difference being statistically significant. All patients were fully or partially satisfied with both function and aesthetics, and would undergo the same procedure again.

**Conclusion:** the findings indicate that immediate placement of 6- to 8-mm-wide diameter implants in molar extraction sockets yielded unacceptable outcomes when compared to ridge preservation and delayed placement of conventional 4- or 5-mm diameter implants.

## POST EXTRACTIVE IMPLANT AND USE OF BIOMATERIALS: A CASE REPORT

Butti A., Guerrieri P., Vella M., Rossi F., Calò A., Porro A.

Department of Biomedical, Surgical and Dental Sciences, University of Milan, Milan, Italy

**Aim:** this work reports the post-extractive implant surgery of a single dental element. The possibility of immediately rehabilitating an edentulous patient offers significant advantages today because it satisfies the patient's needs in terms of comfort, aesthetics and functionality and reduces the surgical phases for the clinician. In particular, the concept of post-extractive implantology was developed to avoid bone resorption after dental extraction.

**Methods:** it's considered a case of an adult male patient with a fractured tooth (46). Therefore it's decided to extract it and to place a post-extractive implant. The implant chosen is AnyRidge from Megagen with a diameter of 4.5 mm and a length of 8.5 mm. To regenerate the bone site used of THE Graft™ produced by

Purgo. It is a natural and porous bone mineral matrix. The implant site was closed with a 4/0 monofilament suture. At the end of the surgery, some general warnings were given to the patient in order to promote optimal tissue healing. The sutures were removed after 8 days and the patient was visited every 10 days.

**Results:** a month and a half after the operation, positive data can be observed such as the presence of the implant in the surgical site, the absence of infection, the absence of micro-movements and optimal healing of the peri-implant tissues.

**Conclusion:** recent works that appeared in literature and our clinical experience allows us to declare that post-extractive implants are today a reliable alternative to traditional implantology.

## SOCKET PRESERVATION: PDT WITHOUT DYE AND PBM FOR BONE AND KERATINIZED TISSUE REGENERATION

Caccianiga G., Caccianiga P., Porcaro G., Baldoni M., Ceraulo S.

School of Medicine and Surgery, University of Milano-Bicocca, Monza, Italy

**Aim:** our aim was to evaluate the regenerative potential of porcine bone graft, PRF and collagen membranes combined with Oxygen High Level Laser Therapy in alveolar ridge preservation, implant survival in regenerated bone and wound closure during the 2/3 weeks following surgery.

**Methods:** we selected 15 patients that underwent alveolar ridge preservation.

A clinical and radiographic examination was performed at baseline. In this study sockets were treated with porcine bone (Osteobiol, granulometry 25), PRF and collagen membranes (Biogide/Geistlich), combined with photodynamic laser-therapy (Oxygen High Level Laser Therapy/SiOxyL+ protocol). PBM sessions with ATP38 were made for the first 4 months each 2 weeks.

Evaluations were performed at 14, 21, 90 and 240 days. 9 months after the first surgical procedure a reentry surgery was performed using the same approach to place implants.

**Results:** all socket preservation surgeries were successful, without having any complication and not showing significant differences in the results. No sockets showed bone graft exfoliation during the healing of wounds or alveolitis, with minimal bone contraction after 9 months. 53 implants were placed. Only in 1 patient 2 of 4 implants placed did not have a proper osseointegration. After 5 years of follow up all 51 of 53 implants placed met all implant survival criteria with a percentage of 96,2%. Closure of gingival tissue healed by secondary intention was achieved after 14 days for all patients except one who showed wound closure after 21 days.

**Conclusion:** this technique enabled to obtain a great bone and keratinized tissue regeneration in treated sites and to place implants in all patients without other bone augmentation techniques, thanks to ECM induced by photodynamic laser-therapy on grafts materials used and to PBM made each 2 weeks for the first 4 months post-surgery.

## IMMEDIATE LOADED SUPER SHORT DENTAL IMPLANTS: A RETROSPECTIVE STUDY

Caione A.<sup>1</sup>, Giovannini S.<sup>2</sup>, Pierobon C.<sup>1</sup>, Di Fiore A.<sup>1</sup>, Sivoletta S.<sup>1</sup>

<sup>1</sup>Department of Neurosciences, University of Padua, Padua, Italy

<sup>2</sup>Department of Biomedical, Surgical and Dental Sciences, University of Milan, Milan, Italy

**Aim:** the purpose of the present retrospective study is to describe the results of immediate loaded super short dental implants in terms of implant survival and marginal bone loss.

**Methods:** eleven patients were consecutively treated with super short implants (T3 Super Short 3i, Biomet 3i Implants, Vicenza, Italy). Fifteen super short implants (5 or 6 mm length) were positioned subcrestal (0,5/1 mm) and were immediately loaded with a non-functionalized screwed provisional crown. Periapical radiographs were taken with a long cone paralleling technique after implant placement (baseline). Clinical and radiographic follow-up was then scheduled at annual intervals up to 5-years. Each radio-

graphic image was evaluated using the known implant diameter (5 or 6 mm) to calibrate the radiographs. Implant survival and marginal bone loss (MBL) levels were considered.

**Results:** at five years follow-up 1 implant failed and implant survival rate was at 93%. Marginal bone loss was 0,41 mm average (0,55 SD).

**Conclusion:** within the limits of the study, implant survival and bone loss of super short immediate loaded implants can be considered comparable to standard length implant (eg 10 mm or more). A larger sample is needed to have more statistically significant data.

## TREATMENT OF A ONE WALL DEFECT IN THE MANDIBLE BY GBR WITH A NON-RESORBABLE MEMBRANE

Cino R., Arletti A., Armogida N.G., Lubrano M.R., Cuzzo A., Mauriello L., Vaia E.

Department of Neuroscience and Reproductive and Odontostomatological Sciences, University of Naples Federico II, Naples, Italy

**Aim:** alveolar ridge deficiency is the most common impediment in implant dentistry. Guided Bone Regeneration (GBR) with the use of E-PTFE Titanium reinforced membranes has been proven a valid technique to perform local bone augmentation thanks to the optimal mechanical performance and biocompatibility.

**Methods:** a 45 y.o. woman in good general health came to our attention asking for an implant-prosthetic rehabilitation of the edentulous site of a 3.1 presenting a severe ridge defect. The full thickness flap elevation could highlight the esiguity of the ridge as the lingual wall alone was present. Therefore, implant positioning was followed by GBR with non-resorbable membrane (Gore TR6Y, Gore Tex) stabilized by titanium fixation pins and supported by a mixture of autologous bone and DBBM

(Bio oss, Geistlich). After 7 months of submerged healing, a surgical re-entry was performed in order to remove the membrane and pins. Healing abutment was contextually connected and, after 2 weeks, the implant was loaded with a provisional restoration. Two months later, an optimal soft tissue condition was assessed, hence the final restoration could be delivered.

**Results:** at 5 years, peri-implant health and clinical success can be appreciated. The correct prosthetic profile leaving adequate interdental spaces allowed the patient to obtain a good interdental hygiene with the use of interdental toothbrushes.

**Conclusion:** the use of GBR technique with an E-PTFE Titanium reinforced membrane and a mixture of autologous bone and DBBM has shown to be very effective in order to achieve the treatment goals, even in presence of a severe ridge deficiency.

## EFFECT OF LASER-ABLATED MICRON-SCALE MODIFICATION OF FIXTURES COLLAR ON PERI-IMPLANT BONE

Del Giudice A., Mazzoni A., Zanza A., Reda R., D'Angelo M., Seracchiani M., Guarnieri R., Testarelli L.

Department of Oral and Maxillo-Facial Sciences, Sapienza University of Rome, Rome, Italy

**Aim:** the purpose of the present evaluation is to compare radiographic modifications of the fractal, mesial and distal vertical dimensions of peri-implant trabecular bone of dental implants either with a laser-ablated micron-scale modification (LAM) of collar surface, either without any collar surface modifications, after a 5-year follow-up period.

**Methods:** the implants were divided in two groups: Test Group (TG) 34 implants with LAM collar surface (BioHorizons Laser-Lok™; Internal Implants, Birmingham, AL, USA); Control Group (CG): 31 implants without LAM collar surface (BioHorizons RBT; Internal Implants, Birmingham, AL, USA) placed in 45 non-smoking, periodontally healthy patients. Fractal and verti-

cal dimensions of peri-implant trabecular bone were measured by comparing radiographs taken in three different times: right after the implant placement, after 3 year of loading and after 5 years of loading.

**Results:** in the fifth year the marginal bone loss (MBL) in the TG was  $0.85 \pm 0.19$  at the mesial aspect and  $0.72 \pm 0.23$  mm at distal one, while a MBL of  $2.10 \pm 0.28$  mm at the mesial site and  $2.06 \pm 0.37$  mm at the distal one was registered in the CG.

**Conclusion:** the increased fractal dimension and the decreased MBL around TG implants after 5 years follow-up, highlights a positive effect of LAM collar surface on peri-implant trabecular bone remodeling.

## THE PERI-IMPLANT SOFT TISSUE INTEGRATION OF IMMEDIATELY LOADED IMPLANTS: THE BIOLOGICAL

Figliuzzi M. M., Iovane C., Altilia M., Aiello D.

Department of Periodontics and Oral Sciences, University Magna Graecia of Catanzaro, Catanzaro, Italy

**Aim:** the aim of this research was to assess peri-implant bone remodeling of post-extractive implants over 2 years. 60 patients who met the pre-established inclusion criteria were enrolled for the study. an implant for each patient was inserted into the post-extraction sockets according to a defined surgical protocol (atrophy extraction, implant insertion, respecting the biological width, suture). the assessment of resorption was radiographic with a customized resin check. The measurements were taken from the edge of the implant to the most coronal bone peak. the values obtained were analyzed using the t-student test. Our results showed that after 2 years 98% of patients had 0 mm of bone resorption, 2% of patients had  $0.5 \text{ mm} \leq x \leq 2 \text{ mm}$  of bone resorption. after 5 years, on the other hand, all 60 patients showed a resorption equal to 0. this is most likely due to the stabilization that occurs over time, both of the soft tissues and of the bone tissue, which occurred around the implant, due to the positioning of the implant in the three spatial dimensions respecting the biological width.

**Methods:** trial design.

Selected patients for the study meet the following inclusion criteria:

1. good health conditions (no systemic diseases including diabetes, rheumatic diseases, neoplasia);
2. non smokers or smokers less of 15 cigarettes a day;

3. presence of adequate cortical bone at vestibular and palatal plates (at least 2 mm);
4. presence of adjacent teeth;
5. sufficient vertical amount of bone (at least 3 mm of residual bone evaluated thorough CT dental scan) to insert a stable post-extractive implant.

Exclusion criteria were:

1. pregnancy and lactation;
2. assumption of drugs such as biphosphonates which could negatively influence bone healing;
3. active periodontitis. All patients required teeth extractions due to root fractures, destructive caries, endodontic failures. Each patients signed an informative approval form before acceptance of treatment. The research was conducted with the approval of local ethical committee nr. 926 of October 2010 and in accordance with the Helsinki Declaration. Our results showed that after 2 years 98% of patients had 0 mm of bone resorption, 2% of patients had  $0.5 \text{ mm} \leq x \leq 2 \text{ mm}$  of bone resorption. After 5 years, on the other hand, all 60 patients showed a resorption equal to 0. This is most likely due to the stabilization that occurs in the time, both of the soft tissues and of the bone tissue, which occurred around the implant, due to its positioning of the implant in the three spatial dimensions respecting the biological width.

## THE REHABILITATION OF THE ATROPHIC MAXILLA BY ZYGOMATIC IMPLANTS: A RETROSPECTIVE STUDY

Gamalero M., Tealdo T., Pesce P., Pera F., Bagnasco F., Menini M., Pera P.

School of Medical and Pharmaceutical Sciences Prosthetics and Implant Prosthetics Service (DISC Department), Responsible: Prof. M. Menini, University of Genoa, Genoa, Italy

**Aim:** the purpose of this observational study was to evaluate implant survival and the incidence of complications of rehabilitations using zygomatic implants and the satisfaction of patients rehabilitated through this procedure.

**Methods:** the study was developed retrospectively by collecting the clinical data of 36 patients treated with the ZAGA protocol for a total of 75 zygomatic implants (phase 1).

5 patients were rehabilitated by 4 zygomatic implants following the QUAD protocol, while the others had 1 to 3 zygomatic implants and a number of 1 to 4 standard dental implants.

For each patient pre- and post-operative X-rays were analyzed, the ZAGA class was defined, and implant failures and complications reported in medical records were recorded. Among the 36 patients, 13 were clinically examined to assess implant stability, peri-implant tissue condition, and prosthetic

design (phase 2). These 13 patients also answered a questionnaire regarding their satisfaction towards the rehabilitation.

**Results:** the mean follow-up period for the patients analysed was 18 months (range: 12-24 months). Implant failure rates were similar to those reported in the literature. In fact, 2 out of 75 implants failed during the follow-up. Implant stability values, sinusitis incidence (2.8%), peri-implant tissue conditions and prosthetic assessment were satisfactory and comparable to those reported in the literature for this type of rehabilitation. All the patients reported an improvement in their quality of life thanks to the rehabilitation compared to their previous condition.

**Conclusion:** zygomatic implants are reliable devices with implant survival rate comparable to that of conventional dental implants. This technique, however, requires careful planning of the surgical and prosthetic phases to have an adequate predictability of the clinical outcome.

## ANALYSIS OF TWO TYPES OF IMPLANT CONNECTION: 5° CONOMETRIC CONNECTION VS 45° CONNECTION

Gemma E.<sup>1</sup>, Fantini M.<sup>1</sup>, Cangelosi D.<sup>2</sup>, Cosi R.<sup>1</sup>, Giboli I.<sup>2</sup>, Laveglia L.<sup>1</sup>

<sup>1</sup>Private Practice, Varese, Italy

<sup>2</sup>Department of Health Sciences, School of Dentistry, University of Insubria, Varese, Italy

**Aim:** understand how the use of a different type of connection will maintain or modify the hard and soft tissues adjacent to the implant.

**Methods:** a group of 182 intraoral radiograph imaging implants were analyzed, and two created. *First* dealt with connection 0, patients treated with a 5° conometric internal hexagonal connection, *second* connection 1, patients treated with a 45° internal hexagonal connection. Marginal bone resorption was calculated as the distance between the most apical bone-implant contact point (i-FBIC) and the implant-abutment connection level. The measurement of crown height and contact point as the midpoint of the overlap of the two adjacent crowns was added and the results were reported on 32 implants. This allowed to evaluate the relationships between the connection and the distance between the contact point (CP) and the bone peak (BP). The I-TH distance indicates the height of the pros-

thetic crown and was calculated between the distance from the shoulder of the implant to the perpendicular point corresponding to the apex of the crown.

**Results:** more group 1 implants with connection 0 have average I-fbic values greater than 0, group 2 implants with connection 1 have more average I-fbic values less than 0. Over time, the I-fbic values of implants with 5° connection are more stable, while those with 45° connection show a considerable drop after 1000 days from insertion. The use of a 5° connection allows for an average distance between the bone peak and the contact point of approximately 5.6mm, very close to Tarnow's 5mm for papilla maintenance in contrast to the 45° connection which brings this average measurement to 7mm due to greater bone resorption.

**Conclusion:** the use of a 5° conometric connection allows for better stability and predictability of the result reducing the risk of aesthetic and functional problems.

## SUB-MICRO PATTERN INFLUENCE ON BONE CELLS

Matera B.<sup>1,2</sup>, Ghezzi B.<sup>2</sup>, Toffoli A.<sup>2</sup>, Lagonegro P.<sup>3</sup>, Fukata N.<sup>4,5</sup>, Parisi L.<sup>2,6</sup>, Rossi F.<sup>7</sup>, Macaluso G.M.<sup>2,7</sup>

<sup>1</sup>Department of Chemical, Life and Environmental Sustainability Sciences, University of Parma, Parma, Italy

<sup>2</sup>University Center of Dentistry, Department of Medicine and Surgery, University of Parma, Parma, Italy

<sup>3</sup>SCITEC-CNR Institute Giulio Natta, Milan, Italy

<sup>4</sup>International Center for Materials Nanoarchitectonics, National Institute for Materials Science, Namiki Tsukuba, Ibaraki, Japan

<sup>5</sup>Institute of Applied Physics, University of Tsukuba, Tsukuba, Japan

<sup>6</sup>Laboratory Oral Molecular Biology, Department Orthodontics and Dentofacial Orthopedics, School of Dental Medicine, University of Bern, Bern, Switzerland

<sup>7</sup>IMEM-CNR Institute, Parma, Italy

**Aim:** it is widely known that substrate topography can affect cell responses as adhesion, proliferation and differentiation, key events to allow the deposition of new extracellular matrix, thus resulting in implant osseointegration. In this study we analyzed how sub-micropatterned surfaces (SMPS) could influence the behavior of osteoblasts.

**Methods:** SMPS with pillars disposed in specific layouts have been developed through Nanoimprint Lithography. Osteoblastic adhesion, proliferation and morphology have been studied and specific dimensional parameters (e.g. cell perimeter, area, elongation factor) have been analyzed.

**Results:** cells adhered and proliferated well on both the SMPS. Interestingly, they appeared to mainly follow the alignment

of the pillars which influenced the cytoskeletal structure accordingly to their geometries, maximizing cell-biomaterial contacts and minimizing the gaps within the irregularities. These results are consistent with the amount of observed focal adhesions, underlining the close relationship between cell shape and pillars disposition.

**Conclusion:** results underlined how substrate topography can affect cell adhesion and morphology, leading cells to minimize the gaps between irregularities. To design innovative biomaterials with geometric nano/micro-topographies able to alter the inner cytoskeletal organization and consequently cell behavior might play a pivotal role in new tissue deposition and osseointegration of dental implants.

## THE USE OF CERAMIC IMPLANTS (PURE CERAMIC) WITH IMMEDIATE LOADING IN THE AESTHETIC AREA AS

Pometti O. S., Di Murro B., Rosella D., Bonavena C., Papi P., Baldinetti F.

Oral Surgery Unit, Director: Prof. G. Pompa, Department of Oral and Maxillo-Facial Sciences, Sapienza University of Rome, Rome, Italy

**Objectives:** the use of a ceramic implant, which has an integrated prosthetic component for the definitive restoration, has been proposed as a valid substitute to conventional titanium implants in the aesthetic sector in order to guarantee high aesthetics avoiding the gray coloring of the abutment, transpiring from the peri-implant soft tissue in case of mucosal recessions. The aim of this research is to analyze the clinical and radiographic response of single-component ceramic implants inserted with an immediate loading protocol, associated with horizontal GBR.

**Methods:** a zirconia dental implant was placed to replace a missing central upper incisor with the aid of a surgical template, following proper manufacturer instructions. Then, a simultaneous GBR was performed using deproteinized bovine bone and a resorbable porcine-derived collagen membrane. The day after surgery, a temporary restoration was placed in infra-occlusion. Definitive prosthetic restorations were cemented 3

months after surgical procedure. The parameters evaluated were implant success rate, implant survival, marginal bone loss (MBL) levels through standard periapical x-rays at implant insertion and after 3 months, 1 and 3 years.

**Results:** a total of 15 patients, either males or females, with a mean age of  $50.80 \pm 15.44$  years were enrolled in this study. After 36 months of observation, no implant was lost, with implant survival and success rates of 100%. No symptoms such as pain, suppuration or GBR complications were reported after implant placement and throughout the observation period. Mean MBL levels were: T1 –  $0.42 \pm 0.34$  mm, T2 –  $0.68 \pm 0.36$  mm, T3 –  $0.88 \pm 0.32$  mm, T4 –  $1.02 \pm 0.28$  mm.

**Conclusion:** our study showed that zirconia dental implants can guarantee an excellent osseointegration, optimal aesthetic results and can be successfully used with an immediate loading protocol.

## ULTRA-SHORT IMPLANTS: CLINICAL STUDY AT FIVE-YEARS FOLLOW UP

Rinaldi F.<sup>1</sup>, Petrelli P.<sup>1</sup>, Bernardi S.<sup>1,2,3</sup>, Varvara G.<sup>1</sup>, Piattelli M.<sup>1</sup>

<sup>1</sup>Department of Innovative Technologies in Medicine & Dentistry, University G. D'Annunzio of Chieti-Pescara, Chieti, Italy

<sup>2</sup>Department of Clinical Medicine, Public Health, Life and Environmental Sciences, University of L'Aquila, L'Aquila, Italy

<sup>3</sup>Center of Microscopy, University of L'Aquila, L'Aquila, Italy

**Aim:** this study aimed to evaluate retrospectively the use of ultrashort implants in the rehabilitation of patients with atrophic jaws (I and II classes according to Kennedy's classification). In particular the study evaluated the adequacy of single crowns rehabilitation on ultrashort implants, measuring 4mm in length and 4mm in diameter, in terms of survival and complications' occurrence.

**Methods:** patients requiring a fixed crown implant supported but with a low availability of adequate bone volume between 2015 and 2020 were selected. Among them, those who received ultrashort-implants were finally selected (N = 7, Implants = 21). Primary outcome was defined as the number of implants survived after five years. Secondary outcomes were eventual

complications related to the implant site and the prosthetic structure (crown fractures etc.).

**Results:** the majority of the patients at the 5 years follow-up (T5) still had the implants integrated in the jawbone (N = 6). Regarding the primary outcome, the implant survival was high (Implant survived = 19). The data regarding the secondary outcomes were also promising with no complications in the survived implants and the related crowns.

**Conclusion:** within the limits of the study, the reported data confirm combining innovative implant surfaces with a performing prosthetic project, allows to use implants with no-conventional lengths (short and ultrashort) in atrophic jaws offering a good compromise in critical situations.

## SHORT AND ULTRASHORT IMPLANTS IN ASSOCIATION WITH INTERNAL SINUS LIFT: A 5-YEARS STUDY

Romagna B.<sup>1</sup>, Signoriello A.<sup>1</sup>, Tomizioli N.<sup>1</sup>, Hernandez Gonzalez D.<sup>2</sup>, Marincola M.<sup>2</sup>, Lombardo G.<sup>1</sup>

<sup>1</sup>Dentistry and Maxillo-facial Surgery Section, Department of Surgery, Dentistry, Paediatrics and Gynaecology (DIPSCOMI), University of Verona, Verona, Italy

<sup>2</sup>School of Dentistry-Dental Implant Unit, University of Cartagena, Cartagena, Colombia

**Aim:** the aim of this 5-year study was to retrospectively evaluate implant survival rate, bone levels stability and peri-implant soft tissues conditions of 8 mm, 6 mm and 5 mm-length plateau-design locking-taper implants placed in conjunction with internal sinus lift technique (ISL).

**Methods:** 107 implants were placed in the atrophic posterior maxilla of 48 patients and rehabilitated with single-crown restorations. Clinical and radiographic examinations were performed at 5-year follow-up.

**Results:** 22 implants were 5 mm-length, 71 6 mm-length and 14 8 mm-length. As one early failure was registered, 106 implants were loaded. Overall implant survival after 5 years was 97.2%. Soft tissues conditions were stable after 60 months.

Average bone loss ( $\Delta$ CBL) and average apical shift of the first bone-to-implant contact point position ( $\Delta$ F-BIC) were recorded:  $0.17 \pm 0.76$  mm and  $-0.19 \pm 0.71$  mm. Mean residual crestal bone height (RCBH) was  $4.67 \pm 2.02$  mm before implant placement,  $9.39 \pm 1.87$  mm after implant placement,  $7.74 \pm 2.04$  mm after loading and  $6.64 \pm 2.02$  mm at the recall examination. Mean intra-sinus bone height gain (IBHG) was  $2.01 \pm 1.78$  mm after implant placement,  $0.85 \pm 1.92$  mm after loading and  $0.25 \pm 1.44$  mm at follow-up.

**Conclusion:** short and ultrashort implants, placed in conjunction with ISL technique, can be considered a predictable treatment for the rehabilitation of the atrophic posterior maxilla at mid-term follow-up.

## SPIRAL DENTAL IMPLANTS: A CASE REPORT OF A POST-EXTRACTIVE SITES

Rossi F., Butti A., Porro A., Calò A., Guerrieri P., Tripicchio C.

Department of Biomedical, Surgical and Dental Sciences, University of Milan, Milan, Italy

**Aim:** the Noris Medical cortical implant is a spiral dental implant (SDI) with a conical internal helix that provides the characteristics of self-drilling, self-threading and self-bone condensing. These properties offer better control during insertion. Immediate dental implants have reduced treatment and healing time.

**Methods:** in this clinical case, a 47-year-old patient reported to our clinic with an upper right second molar with poor prognosis. The tooth was extracted atraumatically and a SDI was inserted. The defect was closed with synthetic bone and then sutured. The implant was left in place and loaded after three months.

**Results:** SDIs are reliable tools for difficult oral rehabilitation cases. They have a higher success and survival rate. Immediate implant therapy has many advantages such as reduced treatment time, preservation of soft and hard tissues surrounding the implant and reduced number of operations. No complications occurred one month after loading.

**Conclusion:** for SDI osseointegration, not only adequate quantity of bone is needed, but also adequate density. The initial bone density provides the mechanical immobilization of the SDI and allows the distribution and transmission of stresses from the prosthesis to the implant-bone interface. No differences were found between the SDI lengths and the implant to crown ratio.

## RE-OSSEOINTEGRATION OF IMPLANTS AFTER ACCIDENTAL BREAKING OF THE BONE-IMPLANT INTERFACE

Vimercati I., Clauser T.

Department of Biomedical, Surgical and Dental Sciences, University of Milano, Milan, Italy; IRCCS Galeazzi Orthopedic Institute, Milan, Italy

**Aim:** this review of the literature aims to explain how the clinician should behave in the event of breaking of the interface between bone and implant after mechanical unscrewing of the healing screw or prosthetic components.

**Methods:** the search was done using PubMed database.

**Results:** first of all, it is important to exclude a diagnosis of fibrointegration: in this case the only option is to remove the implant. On the other hand, in the event that implant mobility occurs only after mechanical unscrewing of the healing screw or prosthetic components, the studies by Kim et al. 2013 and by Jang et al. 2010 on animals can address the clinician. It has been seen that if the implant is unloaded, tightened again in the site and submerged, a faster and more consistent re-osseointegration can occur.

It has been histologically observed how bone residues still in contact with the implant re-establish a connection with the bone of the implant site; in addition to this component already adhered to the implant, there would be a new apposition of bone on the free implant surface, resulting in an increase in the contact area between bone and implant thanks to the phenomenon of regional acceleration.

However, it remains essential to pay attention and avoid using high torques when screwing implant components, especially in the earliest stages of osseointegration.

**Conclusion:** after accidental breaking of the bone-implant interface, the best choice is to maintain the implant, screwed in, submerged and not subjected to functional load. This choice has biological, economic and time-related advantages.

## REHABILITATION OF AN ATROPHIC MAXILLA USING 4-MM-ULTRASHORT IMPLANTS: A CASE REPORT

Angelescu C.<sup>1</sup>, Carlo Barausse <sup>1,2</sup>, Montebugnoli A.<sup>1</sup>, Karaban M.<sup>1</sup>, Bonifazi L.<sup>1,3</sup>, Felice P.<sup>1</sup>

<sup>1</sup>Oral Surgery, Department of Biomedical and Neuromotor Sciences, University of Bologna, Bologna, Italy

<sup>2</sup>Postgraduate school of Oral Surgery, University of Modena and Reggio Emilia, Modena, Italy

<sup>3</sup>Department of Basic Medical Sciences, Neurosciences and Sense Organs, University of Bari Aldo Moro, Bari, Italy

**Aim:** this case report describes an alternative minimally invasive treatment option using 4-mm-long ultrashort implants placed to rehabilitate a severely atrophic edentulous maxilla.

**Methods:** the patient, coming from a full removable denture, asked for an implant prosthesis avoiding reconstructive surgeries and expensive procedures. Considering that the mean available bone was about 4.8 mm in height on Cone Beam Computed Tomography (CBCT) scans, 6 implants were placed where bone volumes were sufficient to receive 4-mm-ultrashort implants. Six months after implant placement an implant-supported bar-retained overdenture prosthesis was delivered.

**Results:** the healing process was uneventful and 1 year after loading the result appears clinically and radiographically stable and the patient is fully satisfied.

**Conclusion:** the described approach, despite some prosthetic compromises, within all the limitations of this case report, might be applied in selected cases, reducing rehabilitative times, possible complications and costs. However, longer follow-ups on large number of patients coming from Randomized Controlled clinical Trials (RCTs) are necessary before making more reliable recommendations.

## MINIMALLY INVASIVE TECHNIQUE FOR CRESTAL SINUS LIFT: A PRELIMINARY STUDY

Antonelli A., Attanasio F., Bennardo F. Brancaccio Y., Buffone C., Barone S., Giudice A.

School of Dentistry, Division of Oral Surgery and Pathology, Department of Health Sciences, University Magna Graecia of Catanzaro, Catanzaro, Italy

**Aim:** this study aimed to evaluate a minimally invasive protocol for crestal sinus lift, through the bone compaction technique.

**Methods:** a preliminary cohort study was conducted including patients with a residual bone height (between 3 and 5 mm) evaluated by preoperative CT scans. Crestal sinus lift was performed with a pilot drill followed by manual bone compactors ( $\varnothing 2 - \varnothing 3 - \varnothing 3.5$  and  $\varnothing 4$  mm) with a stop at 1 mm beyond the sinus floor. Bone graft (0.25 g) were inserted with a carrier and pushed into the implant site with a push-pin stopped 2 mm beyond the sinus floor. Before the implant placement, a push screw was used to condense the bone graft. Implant stability quotient (ISQ) values were recorded after implant placement (T0), at 7 (T7), 14 (T14), 28 (T28), 60 (T60) and 90 (T90) days after the surgical procedures. A follow-up CT was performed 6 months after surgery to evaluate the residual bone height. Sta-

tistical analysis was performed, setting  $\alpha = 0.05$  as level of significance.

**Results:** five patients were enrolled in this study ( $59 \pm 4.18$  age) and 5 tapered implants ( $\varnothing 4 \times 8$  mm) were inserted. ISQ showed the following values:  $68.6 \pm 2.9$  at T0,  $69 \pm 2.44$  at T7,  $68 \pm 2.82$  at T14,  $71.6 \pm 2.7$  at T28,  $76.8 \pm 1.92$  at T60, and  $81 \pm 2$  at T90. A statistical significant difference was recorded between T0 and T90 ( $p = 0.0003$ ). The mean bone height augmentation at 6 months follow-up was  $4 \pm 0.7$  mm, significantly different from the initial bone level ( $p = 0.0002$ ). No Schneiderian's membrane perforations, infections and graft migrations were observed in these cases.

**Conclusion:** this minimally invasive procedure seems to be an effective alternative to the more traumatic Summer's osteotomes technique allowing to gain a good residual bone height at 6 months follow-up with good implant stability values.

## MULTIDISCIPLINARY DIGITAL APPROACH OF A COMPLEX ANTERIOR SINGLE GAP: A CASE REPORT

Arcuri L.<sup>1</sup>, De Vico G.<sup>2</sup>, Lio F.<sup>2</sup>, Barlattani A. Jr<sup>2</sup>

<sup>1</sup>Department of odontostomatological and maxillofacial sciences, Sapienza University, Rome, Italy

<sup>2</sup>Department of Clinical Sciences and Translational Medicine, Tor Vergata University, Rome, Italy

**Aim:** to describe a complex esthetic case finalized by means of computer guided implant surgery, bone expansion, peri-implant soft tissue thickening and conditioning.

**Methods:** a 19-year-old patient needed to rehabilitate the missing right upper central incisor (FDI 1.1). Cone beam computed tomography and intraoral scanning (IOS) were acquired and merged into a dedicated planning software. A tooth supported surgical guide was digitally created and 3D printed. The day of the surgery the patient received 2 g of amoxicillin 1 h before surgery and rinsed with chlorhexidine 0.2% for 1 min prior surgery. After local anesthesia was executed, a full thickness flap was raised, and the 2 mm pilot drill was passed through the surgical template to the planned depth. Then the surgical guide was removed and an osteotome was used to deal with the reduced bone thickness. After the repositioning of the surgical guide, a 3.5 X 13 mm implant was placed and

closed with a cover screw. A roll-flap was then performed on the vestibular aspect to increase the soft tissue thickness and a Maryland bridge was cemented. After a healing period of 2 months, the implant was loaded with a screw-retained temporary restoration. Definitive impression was taken by means of IOS after 3 months, and a zirconia-ceramic crown was cemented on a zirconia abutment. To match the contralateral tooth proportion, a ceramic addition was cemented on the lateral incisor.

**Results:** at 1 year follow-up no biological nor mechanical complications were recorded, and the patient was fully satisfied about the esthetic result.

**Conclusion:** the computer guided approach was fundamental in a comprehensive analysis of the clinical scenario, leading the clinician to deal with possible criticalities and complications previously on the planning software.

## LONG TERM FOLLOW-UP OF TISSUE LEVEL IMPLANTS IN THE ESTHETIC AREA: A RETROSPECTIVE STUDY

Baldinetti F., Di Murro B., Pometti S., Papi P., Solimena A.

Department of Oral and Maxillo-Facial Sciences, Sapienza University of Rome, Rome, Italy

**Aim:** the aim of this retrospective cohort study was to evaluate the clinical and radiographic outcomes of tissue level dental implants in the aesthetic sector after a minimum of 10 years of functional loading.

**Methods:** only patients presenting at a regular maintenance visit in a private practice, who had one or more Tissue Level implant (Institut Straumann, Basel, Switzerland) in the aesthetic sector with >10 years of functional loading and complete radiographic and clinical documentation at baseline, were enrolled. Primary outcome variable was mean marginal bone loss (MBL) levels measured on standardized periapical x-rays. Peri-implant health and peri-implantitis were defined based on the 2017 World Workshop on the Classification of Periodontal and Peri-Implant Diseases and Conditions. Chi-square and Fi-

sher tests were performed to evaluate the statistical association between peri-implantitis and secondary variables.

**Results:** a total of 100 patients were enrolled in this study, either males or females, with a mean age of XY and a mean functional time of  $13.14 \pm 3.298$  years (range = 10-20 years). Mean MBL level was  $-1.25 \pm 0.79$  mm (range: 0.2 -3 mm), 22% of implants was affected by peri-implantitis and only smoking and presence of periodontitis were statistically significant ( $p < 0.05$ ) among variables evaluated.

**Conclusion:** tissue level implants in the esthetic sector exhibited low MBL values after at least 10 years of functional loading, with a low prevalence of peri-implant diseases. Our results are in agreement with current literature, even if a direct comparison is challenging since our study has the longest follow-up currently available.

## MANAGEMENT OF ANTICOAGULATED PATIENTS IN IMPLANT THERAPY: A 1-YEAR FOLLOW-UP

Bellantoni G., Franceschi L., Massaglia M., Montemezzi P., Ruscica C., Capparè P.

Department of Dentistry, IRCCS San Raffaele Hospital, Milan, Italy; Dental School, Vita-Salute University, Milan, Italy

**Aim:** the purpose of this study was to evaluate the incidence of bleeding complications following surgical implant therapy in 28 patients where oral anticoagulant therapy was not modified.

**Methods:** all patients suffered from controlled cardiovascular disease and were evaluated by their cardiologist which gave consent to the surgery. Patients included in this study had to be under Warfarin therapy and with an International Normalized Ratio (INR) between 2 and 3. Hemorrhagic events were reported for each patient according to a classification that ranged from mild, moderate and severe. A total amount of 44 teeth in premolar and molar area were atraumatically extracted, and implants (CSR, Sweden & Martina, Due Carrare, Padova, Italy) were immediately placed in fresh sockets and loaded after 3 months. All patients were evaluated at the time of the procedure (baseline) for bleeding complications and at 3 (T1), 6 (T2) and 12 months (T3) for clinical periodontal parameters and marginal bone loss.

**Results:** intra-operative bleeding was mild in all patients. Moderate postoperative bleeding occurred in 5 of them and a mild bleeding was reported in 11 patients: almost all of them within 6 hours (only 3 patients within 24 hours) from the surgical procedure. Local agents, such as collagen sponge application and sterile gauze with tranexamic acid compression, accomplished to stop all hemorrhagic complications. At 1-year follow-up there were no implants lost, with a survival rate of 100%. Radiographic evaluation showed mean bone loss equal to  $0.12 \pm 0.05$  mm.

**Conclusion:** within the limitations of this study, it can be concluded that implant surgery in patients taking oral anticoagulant drugs seems to be a predictable and safety procedure if minimally invasive approach and hemostatic measures to reduce postoperative risks and bleeding complications are set in place.

## IMMEDIATE IMPLANT PLACEMENT IN HIV POSITIVE PATIENTS: A PROSPECTIVE CLINICAL STUDY

Bellantoni G., Cusenza I., Franceschi L., Palmacci M., Ruscica C.<sup>1</sup>, Vinci R.<sup>2</sup>

Oral Surgery Postgraduate School, Department of Dentistry, Vita-Salute San Raffaele University, IRCCS San Raffaele Hospital, Milan, Italy

<sup>1</sup>Resident doctor, Oral Surgery Postgraduate School, Department of Dentistry, Vita-Salute San Raffaele University, IRCCS San Raffaele Hospital, Milan, Italy

<sup>2</sup>Director of Oral Surgery Postgraduate School, Associate Professor, Vita-Salute San Raffaele University, IRCCS San Raffaele Hospital, Milan, Italy

**Aim:** this prospective study aims to compare immediate loading protocol in post-extractive implants versus delayed loading protocol in implants placement into healed sites on controlled HIV-positive patients.

**Methods:** after a single-tooth extraction in the maxillary or mandibular anterior or premolar areas, patients were assigned by randomization into two group: group T, in which implants were placed immediately following tooth's extraction and immediate loading protocol was applied, and group C, in which implants were placed 3 months after extraction and delayed loading protocol was adopted.

The definitive ceramic-fused-to-metal restorations were cemented 3 months after implant placement. Clinical periodontal parameters, marginal bone loss and biological complications (peri-implantitis, pus, pain) were recorded at 3 (T1), 6 (T2), 12 (T3) and 24 (T4) months follow-up.

**Results:** a total of 38 implants were placed in 32 patients. Among them, 22 patients were smokers. At 24-month, a survival rate of 100% was reported. In group T mPI and mBI were  $1.18 \pm 0.12$  and  $0.71 \pm 0.54$ , while in group C were  $1.33 \pm 0.09$  and  $0.54 \pm 0.36$ , respectively. There were no statistically significant differences between the two groups. No statistically significant differences were found in the mean values of probing depth (PD) between test ( $2.71 \pm 0.67$ ) and control ( $2.92 \pm 0.49$ ) groups. At the 24-month radiographic evaluation, perimplant crestal bone loss averaged  $0.11 \pm 0.07$  mm for group T and  $0.13 \pm 0.06$  mm for group C. No statistically significant difference in the marginal bone loss between groups was found ( $p > .05$ ).

**Conclusion:** within its limitations, the present study showed that immediately loaded implants placement into fresh socket can be done successfully in HIV-positive patients as long as who HIV-viremia and immune cell counts are controlled.

## TISSUE-LEVEL IMPLANTS WITH CONVERGENT COLLAR IN IMMEDIATE LOADING FULL-ARCH REHABILITATION

Carossa M., Crupi A., Ambrogio G., Mussano F., Pera F.

Department of Surgical Sciences, C.I.R Dental School, University of Turin, Turin, Italy

**Aim:** tissue-level implants with a convergent collar have been recently introduced. While different studies investigated the outcome of this implant in the rehabilitation of single teeth, its use in full-arch rehabilitations has not yet been investigated. The aim of the present case report is to describe the clinical outcomes of a full-arch immediate loading rehabilitation using four upright tissue-level implants with a convergent collar with 1 year of follow-up.

**Methods:** a male patient, 59 years old, systemically healthy and partially edentulous with all the remaining teeth with unfavorable prognosis was found eligible for an implant-supported fixed full-arch rehabilitation. After the extraction of the remaining hopeless teeth, the patient was rehabilitated with four post extractive tissue level implants with a convergent collar. All the implants were pla-

ced upright to the bone. Full-arch resin prosthesis supported with metal framework, connecting all the implants, according to Columbus Bridge Protocol® was screwed following immediate loading protocol (24 to 48 h from the surgery). Bone loss, peri-implant probing depth (PPD), Plaque index, and bleeding on probing (BOP) were evaluated after one year of follow up.

**Results:** implants success rate was 100% after 12 months from the loading. Mean bone loss was  $0.2 \pm 0.23$  mm. Peri-implant soft tissue was healthy and stable at all the implant sites.

**Conclusion:** tissue-level implants with a convergent collar seem to be a viable alternative to traditional implants. A larger number of patients and a longer period of follow-up are required to confirm the preliminary results of the present case report.

## PHOTO AND PLASMA ACTIVATION OF DENTAL IMPLANT TITANIUM SURFACES: A SYSTEMATIC REVIEW

De Giovanni E., Pesce P., Menini M., Santori G., Bagnasco F., Canullo L.

Department of Surgical Sciences and Integrated Diagnostics, University of Genoa, Genoa, Italy

**Aim:** the aim of this systematic review and meta-analysis is to assess the effect of ultraviolet (UV) and non-thermal plasma functionalization as surface treatment modalities to improve osseointegration.

**Methods:** the systematic research of pre-clinical animal studies was conducted up to May 2020 in the databases PubMed/Medline, Scopus and the Cochrane Library. A meta-analysis was performed by using the DerSimonian-Laird estimator in random-effects models.

**Results:** through the digital search, 518 articles were identified; after duplicate removal and screening process 10 papers were included. Four studies evaluating UV treatment in rabbits were included in the meta-analysis. The qualitative evaluation of the included studies showed that both UV photofunctionali-

zation and non-thermal plasma argon functionalization of titanium implant surfaces might be effective *in vivo* to improve the osseointegration. The meta-analysis on four studies evaluating UV treatment in rabbits showed that bone to implant contact values (expressed as standardized mean differences and raw mean differences) were significantly increased in the bio-activated groups when follow-up times were relatively homogeneous, although a high heterogeneity ( $I^2 > 75\%$ ) was found in all models.

**Conclusion:** the present systematic review and meta-analysis on pre-clinical studies demonstrated that chair-side treatment of implants with UV or non-thermal plasma appear to be effective for improving osseointegration. This systematic review supports further clinical trials on this topic.

## MICRORNA IN IMPLANT DENTISTRY: FROM BASIC SCIENCE TO CLINICAL APPLICATION

Delucchi F.<sup>1</sup>, Dellepiane E.<sup>1</sup>, Pera F.<sup>2</sup>, Izzotti A.<sup>3,4</sup>, Baldi D.<sup>1</sup>, Bagnasco F.<sup>1</sup>, Pesce P.<sup>1</sup>, Pera P.<sup>1</sup>, Menini M.<sup>1</sup>

<sup>1</sup>Division of Prosthodontics and Implant Prosthodontics, Department of Surgical Sciences (DISC), University of Genoa, Genoa, Italy

<sup>2</sup>Department of Surgical Sciences, CIR-Dental School, University of Turin, Turin, Italy

<sup>3</sup>Department of Health Sciences, University of Genoa, Genoa, Italy

<sup>4</sup>IRCCS Ospedale Policlinico San Martino, Genoa, Italy

The use of dental implants is widespread and represents a predictable treatment option. However, the occurrence of biological complications is not rare and is widely debated in the dental scientific community. Moreover, current clinical criteria to evaluate peri-implant tissue health are not able to determine the risk rate and progression of peri-implant disease. Specific microRNA (miRNA) expression profiles have been reported to be predictive of specific clinical outcomes of dental implants and

might be used as biomarkers in Implant Dentistry with diagnostic and prognostic purposes. The aim of the present narrative review was to summarize current knowledge regarding the use of miRNAs in Implant Dentistry. The authors attempt was to identify all available evidence on the topic and to critically appraise it in order to lay the foundation for the development of further research oriented towards the clinical application of miRNAs in Implant Dentistry.

## INSERTION TORQUE AND IMPLANT STABILITY QUOTIENT CORRELATION: A PROSPECTIVE CLINICAL STUDY

Marchio V., Cinquini C., Derchi G., Izzetti R., Nisi M., Barone A.

Department of Surgical, Medical, Molecular Pathology and of the Critical Area, University of Pisa, Pisa, Italy

**Aim:** to estimate implant stability, insertion torque measurement (IT) is used at insertion while the Implant Stability Quotient (ISQ), obtained by Resonance Frequency Analysis, is used to determine implant stability over time. The correlation between ISQ, IT and Marginal Bone Level (MBL) is unclear. The aims of this monocentric prospective clinical study on immediate implants are to investigate the correlation between ISQ and IT at T0 (as primary aim) and that between ISQ and MBL at T0 and at 2, 4 and 12 months (as secondary aim).

**Methods:** a total of 23 patients included in this trial received 32 immediate implants (10 mandibular, 22 maxillary), placed with the platform at the level of the buccal bone plate in 23 type I and 9 type II fresh extraction sockets. The peri-implant bone defects were grafted with cortico-cancellous porcine bone particles, a resorbable membrane was used to avoid graft particles loss. IT was measured using a manual torque wrench

at implant insertion, ISQ values were recorded using the Osstel device at implant insertion and at 2, 4 and 12 months from 4 different directions (M-D, D-M, B-L, L-B); MBL was measured at 2, 4 and 12 months radiographically as the distance from the reference point (implant-abutment interface) to the most apical contact between implant and bone.

**Results:** survival rate for implants at 1 year was 100%. Mean IT value at insertion was  $46.875 \pm 9.66$  (range: 25 to 65 Ncm), while ISQ mean value at insertion was  $71.438 \pm 4.31$  (range: 63 to 78) and  $74.594 \pm 2.75$  (range: 70 to 90) at 1 year. Correlation values between IT and ISQ showed a statistically significant strong correlation at T0, 2 months, 4 months and 1 year, while ISQ and MBL did not.

**Conclusion:** there is a positive correlation between IT values between 25 and 65 Ncm and ISQ, while implant stability expressed by ISQ has no correlation to MBL at different time points.

## PROSTHETIC IMPLANT REHABILITATION OF A C.I.M.D.L.: A CASE REPORT

Palumbo L., Pensa V., Cardili M., Ferri S., Gastaldi G., Vinci R.

Oral Surgery Postgraduate School, Department of Dentistry, Vita-Salute San Raffaele University and IRCCS San Raffaele Hospital, Milan, Italy

**Aim:** one of the most important dental complications related to the use of cocaine is an extensive destruction of the osteo-cartilaginous midline structure of the palate, nose and sinuses. The aim is to describe an oronasal defect caused by cocaine use and the management of the defect.

**Methods:** a 45-years-old woman was evaluated by the department of Dentistry and Dental Prosthesis of "Vita-Salute S. Raffaele" University, complaining of the ability to eat and speak properly because of an ill-fitting obturator. The patient had an history of intranasal cocaine abuse with erosion of her palate, nasal septum and inferior nasal turbinates. The patient's teeth were absent and the pre-existing prosthesis was incongruous, so we decided to create a new obturator prosthesis with exclusive mucous support by evaluating the possibility of inserting implants in the upper arch. An alginate impression

was performed and four implants fixture were placed in the residual maxillary bone. After a healing period of 6 months, the implants are uncovering and it is evaluated that there is no mobility, bone loss or clinical signs of infection. The anchoring of the obturator prosthesis to the implants is carried out by applying ball attachment (Locator) on the implant fixtures.

**Results:** after two years of rehabilitation the prosthesis is well tolerated and the implants are perfectly osteointegrated. The prosthetic implant rehabilitation is useful, not only to give to the patient a better aesthetic aspect but also a better chewing function.

**Conclusion:** the prosthetic implant rehabilitation in cocaine patients is a valid alternative to traditional prosthesis with an exclusive mucous support. The use of osteointegrated implants has allowed a great stability and retention of prostheses, making it more acceptable and comfortable for the patient.

## INFLUENCE OF NANO, MICRO AND MACRO TOPOGRAPHY OF IMPLANT SURFACES ON GINGIVAL FIBROBLASTS

Pierfelice T.V.<sup>1</sup>, D'Amico E.<sup>1</sup>, Pignatelli P.<sup>1</sup>, Piattelli A.<sup>1,2</sup>, Iezzi G.<sup>1</sup>, Lepore S.<sup>1</sup>, Petrini M.<sup>1</sup>

<sup>1</sup>Department of Medical Oral and Biotechnological Science, University G. D'Annunzio of Chieti-Pescara, Chieti, Italy

<sup>2</sup>Villa Serena Foundation for Research, Città Sant'Angelo, Italy

**Aim:** the purpose of this study was to evaluate the human gingival fibroblast (HGF) response to commercially pure titanium (ASTM F67) implant discs (Implacil De Bortoli, Brazil) having different micro and nano-topography: Machined versus sandblasted double acid-etched (SDAE). The secondary aim was to investigate the additional effect of the macrogeometry of discs on cells: SDAE surfaces versus SDAE+linear macrogeometry (LSDAE), and SDAE+wave macrogeometry (WSDAE).

**Methods:** nano-topographies of Machined and SDAE surfaces have been characterized using the atomic force microscopy (AFM), whereas the micro- and macrogeometry by scanning electron microscopy (SEM). Then, HGF cells were seeded onto titanium discs in 24-well plates at density of 10,000 cells per Ti-surface. Samples were analyzed at three time points (1, 3 and 5 days), by using Cell Counting kit-8 for viability, SEM for adhesion and morphology of cells, and MTT assay to evaluate the proliferation.

**Results:** the AFM and SEM observations have shown that the SDAE surfaces were characterized by a significant higher micro and nano roughness. Moreover, LSDAE and WSDAE were characterized by 3D macrotopography. The viability study showed that any tested surfaces did not seem to be cytotoxic to HGFs. Cellular analysis showed that the superficial treatment (SDAE) positively affected the proliferation of HGFs in time-dependent manner. The proliferation and adhesion study showed that the 3D macrogeometry of implant discs favor the growth of cells and improved their adhesion. At 3 and 5 days the number of cells on LSDAE was higher than other surfaces included the WSDAE.

**Conclusion:** in conclusion, the SDAE surfaces significantly favored the HGFs adhesion and proliferation. The superficial macrogeometry, in particular the LSDAE, increased the cell interaction with the surfaces.

## EXPERIMENTAL EVALUATION OF INTRAORAL SCANNERS IN EDENTULOUS MANDIBLES

Pietrantonio M., Bonifacio A., Epifania E.

Department of Neuroscience, Reproductive and Odontostomatological Sciences, University of Naples Federico II, Naples, Italy

**Aim:** the main difficulties for intraoral scanners (IOS) are found in the edentulous mandibles. The reduced bucco-lingual surface, the limited height of the bone crest and the mobility of the soft tissues generate criticalities for the acquisition of the digital impression. The purpose of this study is to evaluate the comparison between digital and analog impressions in these particular conditions.

**Methods:** two scans were obtained for the 11 subjects. The first intraoral scan was carried out with intraoral scan (Omnicam DentsplySirona) and the second was acquired by digitizing a plaster model, obtained from an impression taken with an analogue method, the best choice in these cases. All scans were converted to standard tessellation language (STL). The STL files obtained for each patient were superimposed by means of the GEOMAGIC Control X software, to evaluate the comparison.

The average distance values obtained through the Geomagic 3D software constitute our primary outcome measure. 1 sample t-test was used to prove the hypothesis that the average distances of the points obtained between the two files are relevant ( $\alpha = .05$ ).

**Results:** concerning the scans ability to reproduce the analog impression the intraoral scans carried out with a intraoral scan generated files with single measurements in terms of minimal distance between objects far from scans obtained with analogue methods ( $t = -7.29, P < .001$ ).

**Conclusion:** regarding the results obtained, it was possible to conclude that the STL files deriving from digital impressions are significantly different from those deriving from analog impressions, highlighting a difference between the two methods.

## PERI-IMPLANT TISSUES AFTER 10-15 YEARS IN PATIENTS WITH TREATED CHRONIC PERIODONTITIS

Reda R., Zanza A., Mazzoni A., Del Giudice A., Miccoli G., Di Nardo D., Guarnieri R., Testarelli L.

Department of Oral and Maxillo-Facial Sciences, Sapienza University of Rome, Rome, Italy

**Aim:** aim of this study was to retrospectively evaluate the peri-implant tissues conditions in treated patients with chronic periodontitis (CP) and in patients without chronic periodontitis (noCP).

**Methods:** a chart review was used to evaluate 267 implants, 134 placed in 42 CP treated patients and 133 placed in 46 noCP patients. The primary outcome was to evaluate peri-implant tissues condition (health, peri-mucositis, and peri-implantitis). The secondary outcome was to evaluate the possible association of some variables, such as, Plaque Index (PI), Bleeding Index (BI), probing pocket depth (PD), bleeding on probing (BoP), bone level (BL), loading time, type of implant placement and loading protocol, type of prosthesis, type of bone, implant manufacturer, implant diameter and length, with the implant health condition.

**Results:** the analysis of patient files revealed that after 10-15 years of loading (mean loading time  $13.4 \pm 2.07$  years), six

noCP patients (13%) experienced implant loss with a total of nine implants (6.7%) lost. The remaining 124 implants were classified: 54 (43.5%) as healthy, 45 (36.3%) with peri-implant mucositis, and 25 (20.2%) with peri-implantitis. Twelve CP subjects (28.5%) experienced implant loss with a total of 19 implants (14.1%) lost. The remaining 115 implants were classified: 34 (29.5%) as healthy, 40 (34.7%) with peri-implant mucositis and 41 (35.6%) with peri-implantitis. Compared with noCP subjects, only treated CP subjects with recurrent periodontal disease (RPD) showed differences statistically significant ( $p < .05$ ).

**Conclusion:** after 10–15 years of loading, in CP patients treated in a private practice setting, most implants (70.1%) were classified with some type of peri-implant inflammation. In patients with RPD, a higher tendency for implant loss and peri-implant biologic complications was found.

## OSSEODENSIFICATION DRILLING PROTOCOL FOR ALVEOLAR SITE PREPARATION IN IMPLANT SURGERY

Romeo M.<sup>1</sup>, Patano A.<sup>1</sup>, Laudadio C.<sup>1</sup>, Malcangi G.<sup>1</sup>, Colocchia G.<sup>1</sup>, Marinelli G.<sup>1</sup>, Limongelli L.<sup>1</sup>, Inchingolo A. D.<sup>1</sup>, Montenegro V.<sup>1</sup>, D'Oria M. T.<sup>1</sup>, Laforgia A.<sup>1</sup>, Dipalma G.<sup>1</sup>, Inchingolo F.<sup>1</sup>, Di Venere D.<sup>1</sup>, Cardarelli F.<sup>1</sup>, Farronato M.<sup>2</sup>, Tartaglia G.<sup>2</sup>

Complex Operative Unit of Odontostomatology Director: Prof. G. Favia

<sup>1</sup>Specialization School in Orthognatodontics Director Prof. F. Inchingolo, Interdisciplinary Department of Medicine D.I.M. University of Bari Aldo Moro, Bari, Italy

<sup>2</sup>Department of Biomedical, Surgical and Dental Sciences, School of Dentistry, University of Milan, Milan, Italy. UOC Maxillo-Facial Surgery and Dentistry. Fondazione IRCCS Ca' Granda, Ospedale Maggiore Policlinico, Milan, Italy

**Aim:** the Osseodensification Drilling Protocol is an innovative technique in the field of alveolar site preparation for implant surgery, characterized by the use of special designed burst with alternative use of combined clockwise and anticlockwise rotation. The aim of this work is to demonstrate the effectiveness of the Osseodensification Drilling Protocol in alveolar site preparation to obtain an higher insertion torque and an higher implant primary stability compared to the conventional alveolar preparation technique, especially in that cases where this two values are negatively affected.

**Methods:** a research in the archives of PubMed-Medline and Google Scholar was performed, a total of 8 studies analysed was on animal subjects: 6 on ovine, 2 on suine, 3 studies have been performed on human model, 1 in areas with poor bone density, 1 in health alveolar crest and 1 in the portion of the upper maxillary.

**Results:** as resulting from an analysis of the quoted papers, the alveolar preparation performed with osseodensification special drills allows to increase the contact between the surface of the titanium dental implant and autologous bone of prepared alveolar site compared to the conventional alveolar preparation technique and also obtained an higher BIC index compared to Summers osteotome technique.

**Conclusion:** the obtained results reveal the promising nature of the Osseodensification Drilling Protocol especially in that cases in which the primary stability of titanium implant is hard to reach for the poor bone density, as the burst used in this technique and the mix of clockwise and anticlockwise rotation movements compact and respect the autologous bone that surround the implant site. In a practical point of view we notice the need for courses of training for the use of the special drills used in the osseodensification technique as it requires an expert surgeon and skills.

## LONG-TERM OUTCOMES OF FULL-ARCH IMMEDIATE FIXED PROSTHESES: PROSPECTIVE CLINICAL STUDY

Sacchi L., Romeo D., Agliardi E.

Department of Dentistry, IRCCS San Raffaele Hospital, Milan, Italy; Dental School, Vita-Salute University, Milan, Italy

**Aim:** nowadays immediately loaded full-arch implant supported prostheses with axial and tilted implants represents a well established procedure with surgical and prosthetic advantages. However, long term-clinical data are still lacking. The aim of this prospective study was to report implant and prosthetic survival rates of immediate fixed prostheses supported by two axial and two tilted implants and to assess patients' quality of life after at least 10 years of function.

**Methods:** from April 2004 to January 2009, 173 patients (92 male and 81 female, 62 smokers) received an immediate full prostheses supported by two tilted implants that engages the anterior sinus wall and two axial anterior implants. Acrylic resin provisional prostheses were delivered within 4 hours of implant placement and definitive restorations were placed 4 to 6 months later. During follow-up appointments, plaque and bleeding indexes were sco-

red, periapical radiographs were obtained and patient satisfaction was recorded. Cumulative implant survival rate was assessed using the Kaplan-Meier statistics.

**Results:** a total of 692 implants was inserted (404 in the mandible and 288 in the maxilla). One-hundred and one prostheses were immediately loaded in the mandible with a follow-up range of 138-195 months (mean value  $159 \pm 14$  months). Eleven implants failed in 4 patients (3 male, 1 female, 4 no smokers) leading to an implant cumulative survival rate (CSR) of 97.12%. Seventy-two prostheses were delivered in the maxilla with a follow-up range of 138-195 months (mean value  $161 \pm 15$  months). Eight failures occurred in seven patients (1 male, 6 females, 3 smokers) with an implant CSR of 97.13%. No significant difference in survival were reported in the mandible and maxilla (Pearson's chi square) per implant ( $P = 1.00$ ) and per patient ( $P = 0.13$ ). No effect on gender (males vs fe-

males) (maxilla using Fisher's exact test  $P = 0.055$  and mandible  $P = 0.32$ ) or smoking habits (smokers vs NS) (maxilla  $P = 0.29$  and mandible  $P = 0.18$ ) were reported. Patients' satisfaction in terms of function and esthetics was very high thought the study.

**Conclusion:** these long-term clinical data from a relatively large sample size suggest that the present technique can be considered a viable treatment option for the immediate rehabilitation of both mandible and maxilla.

## PERI-IMPLANT CONDITIONS AT 3 YEARS FOLLOWING TRANSCRESTAL VERSUS LATERAL SINUS LIFT

Severi M.<sup>1</sup>, Farina R.<sup>1,2</sup>, Simonelli A.<sup>1</sup>, Franceschetti G.<sup>1</sup>, Minenna L.<sup>1</sup>, Schincaglia G.P.<sup>1,3</sup>, Riccardi O.<sup>1,4</sup>, Trombelli L.<sup>1,2</sup>

<sup>1</sup>Research Centre for the Study of Periodontal and Peri-implant Diseases, University of Ferrara, Ferrara, Italy

<sup>2</sup>Operative Unit of Dentistry, University-Hospital of Ferrara, Ferrara, Italy

<sup>3</sup>Department of Periodontics, School of Dentistry, West Virginia University, Morgantown WV, USA

<sup>4</sup>Private Practice, Torre Pedrera, Rimini, Italy

**Aim:** to comparatively evaluate the peri-implant bone support and conditions of marginal tissues at 3 years following transcres- tal and lateral sinus floor elevation (tSFE and ISFE, respectively).

**Methods:** patients included in a parallel-arm randomized trial comparatively evaluating tSFE and ISFE at sites with a residual bone height of 3-6 mm were recalled at 3 years post-surgery. Twenty-one and 24 patients in tSFE and ISFE group, respectively, participated in the follow-up visit. Each patient contributed the analysis with one implant. The percentage proportion of the entire implant surface in direct contact with the radiopaque area (totCON%) was evaluated on 3-year periapical radiographs. The conditions of the peri-implant tissues at 3-year visit were classified according to the case definitions proposed in the 2017 World Workshop.

**Results:** at 3 years, both groups showed an implant survival rate of 100%. totCON% was 100% (IR: 84.6% - 100%) in tSFE group and 100% (IR: 100% - 100%) in ISFE group ( $p = 0.124$ ). Exposure of the implant apex to the sinus cavity accounted for most tSFE and ISFE cases with suboptimal (< 100%) 3-year totCON% values. Peri-implant health and mucositis were diagnosed in 10 (47.6%) and 11 (52.4%) patients, respectively, in tSFE group, and in 8 (33.3%) and 16 (66.7%) subjects, respectively, in ISFE group ( $p = 0.502$ ).

**Conclusion:** implants placed concomitantly with tSFE and ISFE may similarly maintain complete peri-implant bone support at 3 years following surgery, and must be carefully considered for a similarly high occurrence of peri-implant mucositis.

## LATERAL SINUS LIFT AND IMPLANT REHABILITATION IN PATIENT AFFECTED BY SINUS MUCOCELE

Solimena A., Papi P., Baldinetti F., Pompa G., Bianco G.

Department of Odontostomatological and Maxillofacial Sciences, Sapienza University of Rome, Rome, Italy

**Aim:** the aim of this case report is to describe feasibility of sinus lift with lateral access to rehabilitate missing posterior elements using dental implants also in a clinical case complicated by a benign cystic lesion.

**Methods:** a female patient lost elements 2.6 and 2.7 due to periodontitis. After accurate non-surgical periodontal treatment and pre-operative analysis of cone beam computer tomography scans, a standard sinus lift with lateral access and placement of two implants were planned. The access was made using piezo-surgery instruments, the sinus cystic lesion was removed and sent for histological analysis. The sinus graft was realized using large particles of deproteinized bovine bone substitute (Geistlich Bio-

Oss®). After six months, two Biomet 3i OSSEOTITE® Tapered Implant were placed using a resin surgical template. After five months, prosthetic restoration was delivered to patient.

**Results:** after twenty-four months of follow-up, the clinical outcome was optimal, either radiographically and prosthetically. The pathologist report confirmed that the radiopaque lesion in the sinus had the pattern of a sinus mucocele.

**Conclusion:** pre-operative analysis is the most important step to deal with surgical complications, especially if pathological lesions are involved. Biological-guided criteria and established surgical protocols are supposed to be the best way to achieve predictable results.

## GBR AND CONNECTIVE TISSUE GRAFT AT ADJACENT SITES WITH BUCCAL WALL DEFICIENCIES

Arletti A., Cino R., Armogida N.G., Lubrano M.R., Vaia E., Cuzzo A., Mauriello L.

Department of Neuroscience and Reproductive and Odontostomatological Sciences, University of Naples Federico II, Naples, Italy

**Aim:** GBR is the most common approach to manage the lack of buccal bone around dental implants.

When such defects are associated with soft tissue recession, CTG might be a valid alternative.

In this clinical case, we could observe the efficacy of both treatments at adjacent sites.

**Methods:** a 52 y.o. male in good general health presented a 1.5 with an endodontic failure with a hopeless prognosis: thus, it was extracted. After 2 months of spontaneous healing, a full thickness flap was elevated and an implant positioned. A lateral ridge augmentation by means of a resorbable collagen membrane (Bio Gide, Geistlich) fixed with a pin and supported by DBBM (Bio Oss, Geistlich) was performed to treat the severe dehiscence defect. After six months of submerged healing, a surgical re-entry was performed and a healing abutment was

placed. Contextually, an epithelial-connective tissue was harvested from the palate, de-epithelized with the surgical blade and then stabilized at the vestibular aspect of element 1.4 which showed a buccal wall dehiscence.

Implant loading was performed two weeks after the healing abutment connection and, after four months, the final restoration was delivered.

**Results:** after 5 years, peri-implant health and optimal esthetics can be appreciated and the patient feels very satisfied with the treatment outcome.

**Conclusion:** GBR proved to be a reliable treatment to fully correct a severe dehiscence defect, while the connective tissue graft proved to be a successful treatment to significantly improve esthetics at an implant site presenting a buccal bone deficiency.

## GBR AROUND DENTAL IMPLANTS: ONE STAGE AUGMENTATION PROCEDURE IN THE ANTERIOR MAXILLA

Arletti A., Cino R., Lubrano M.R., Armogida N.G., Mauriello L., Vaia E., Cuzzo A.

Department of Neuroscience and Reproductive and Odontostomatological Sciences, University of Naples Federico II, Naples, Italy

**Aim:** in this clinical case, we face one of the most challenging task that comes to mind when talking of implant supported prosthesis as we manage an atrophic ridge in the esthetic area.

**Methods:** a 48 y.o. woman, in good general health, refers pain and discomfort in the upper jaw. Elements 1.2, 1.1, 2.1 and 2.2 were extracted due to failure of pre-existing therapies. After spontaneous healing of the extraction sites, a full thickness flap was elevated and implants were placed in a prosthetically driven position with the aid of a customized surgical guide. Both implants threads were exposed on the vestibular aspect due to severe ridge deficiency, thus a GBR was performed around the implants by means of resorbable collagen membranes (Bio Gide, Geistlich) supported by DBBM (Bio Oss, Geistlich).

After 6 months of submerged healing, implants were loaded with a provisional restoration: elements 1.2 and 2.2 served as abutments, while 1.1 and 2.1 were pontics. Such restoration, was gradually adapted in the pontic area to obtain optimal soft tissues conditioning before the final restoration could be delivered.

**Results:** after 7 years, peri-implant health with minimal alterations of marginal bone levels can be appreciated. Even though slight soft tissue recessions are present at both sites the patient couldn't notice it herself, hence she did not perceive it as an impairment of her smile esthetics.

**Conclusion:** on the long term, the treatment proved to be reliable in terms of implant survival, clinical success and patient satisfaction.

## SINGLE-CROWN LOCKING-TAPER IMPLANTS IN THE ANTERIOR MAXILLA: AESTHETIC RESULTS

Binotto S.<sup>1</sup>, Corrocher G.<sup>1</sup>, Portelli F.<sup>1</sup>, Signoriello A.<sup>1</sup>, Gonzalez Hernandez D.<sup>2</sup>, Marincola M.<sup>2</sup>, Lombardo G.<sup>1</sup>

<sup>1</sup>Dentistry and Maxillo-facial Surgery Section, Department of Surgery, Dentistry, Paediatrics and Gynaecology (DIPSCOMI), University of Verona, Verona, Italy

<sup>2</sup>School of Dentistry-Dental Implant Unit, University of Cartagena, Cartagena, Colombia

**Aim:** the present retrospective study aimed at evaluating the variations in soft tissues levels which occurred from the time before the extraction to at least one year after the prosthetic loading of locking-taper implants. Furthermore, the aesthetics of single crowns and the quantitative modifications of the anatomical and prosthetic parameters at baseline (T0, with the tooth still in place), and at the subsequent follow-up (T1), were assessed.

**Methods:** 22 implants were evaluated. The Pink Esthetic Score (PES), proposed by Furhauser, was used to evaluate the aesthetics of soft tissues, while a modified version of the Crown-Implant Aesthetic Score, proposed by Meijer, was used to evaluate the prosthetic crowns. The dimensional changes of the anatomical

and prosthetic parameters were measured with standardized photos, both at the dental site at T0 and at T1. These measurements were also put in relation to the gingival biotype and to the use of connective tissue graft (CTG), if present.

**Results:** the average value of the PES was 9.2 and 9.5, respectively at T0 and at T1. The gingival margin and the width of keratinized tissue were maintained between T0 and T1, while the mesial and the distal papillae underwent a decrease in height.

**Conclusion:** the use of locking-taper implants reveals outcomes comparable with those in literature after 1 and 5 years of follow-up. The use of CTG in patients with a thin biotype limits the recession of the gingival margin, while it does not give any additional value to the procedure in patients with thick biotype.

## TREATMENT OF THE IMPLANT SURFACE AND OSTEOINTEGRATION

Calò A., Porro A., Butti A., Guerrieri P., Vella M., Rossi F., Tripicchio C.

Department of Biomedical, Surgical and Dental Sciences, University of Milan, Milan, Italy

**Aim:** the aim of this study is to show the current state of knowledge concerning the different types of surfaces and topographies of dental implants linked to their ability to produce osseointegration, with reference to zirconia and treated laser surfaces.

**Methods:** this study was conducted by analyzing literature articles on the last 10 years consulting PubMed and Cochrane Library databases.

**Results:** all titanium and zirconia implants achieved the osseointegration with excellent bone-implant contact, especially those with titanium SLA surface. According to a systematic review, the survival rate and marginal bone loss of zirconium oxide dental implants stabilized with yttrium oxide, supporting SCs and FDPs after 1 year are increasing and comparable to

data on two-pieces titanium implants. Furthermore, short-term cumulative survival rates and marginal bone loss of zirconia implants are promising and improving. Few significant results have been found on laser treated surfaces. It seems that they show a superior roughness to the ones created by subtraction.

**Conclusion:** the results confirm the titanium implant and the SLA surfaces are the gold standards in implant rehabilitations, but should be considered the use of zirconia implants. The zirconia implants have several good qualities such as biocompatibility, aesthetic and low percentage of bacteria colonization. They seem to have only a flaw: the low fracture resistance, but with new materials and manufacturing processes this can be improved, becoming a real alternative to titanium implants as a non-metallic implant solution.

## EVALUATION OF BONE REMODELING IN ALVEOLAR RIDGES: A LITERATURE REVIEW

Calò A., Porro A., Butti A., Guerrieri P., Rossi F., Tripicchio C.

Department of Biomedical, Surgical and Dental Sciences, University of Milan, Milan, Italy

**Aim:** the aim of this review is to evaluate dental literature to assess the medium dimension changes of the hard tissues of the alveolar ridge, both vertical and horizontal, following tooth extraction.

**Methods:** a search on the main databases as PubMed, Cochrane library, Medline was performed. The bibliographies of review articles were checked. The searching was made to identify randomised controlled clinical trials and prospective cohort studies that evaluate just human bone healing. Only studies reporting on undisturbed post-extraction dimensional changes were included, articles reporting socket preservation healing were not included. Another inclusion criteria used was the observation time of the healing, that must be more than 3 months.

**Results:** in human hard tissue, horizontal dimensional reduction ( $3.54 \pm 0.8$  mm) was more than vertical reduction at 3 months ( $1.37 \pm 0.96$  mm) took on buccal plate and after 6 months of healing. Percentage of vertical dimensional change is believe to be 11–22% at 3 months and between 29 and 63% at 6–7 months.

**Conclusion:** the studies show rapid reductions in the first 3–6 months, followed by gradual reductions in dimensions. The horizontal reduction in the coronal area of the alveolar ridge is much more prominent than in the apical part that keeps unaffected dimension, the horizontal changes are also more emphasized than the vertical ones, that are still mostly concentrated on the buccal plate. Even if the lingual plate undergoes unavoidable modifications, this area of the ridge seems to be much more preserved than the buccal area.

## MULTICENTRE SPLIT-MOUTH STUDY ON EXTRA-SHORT IMPLANTS: ONE- VS TWO-STAGE TECHNIQUE

Canepa C., Delucchi F., Pera F., Pesce P., Carossa M., Ambrogio G., Menini M.

Division of Prosthodontics and Implant Prosthodontics, Department of Surgical Sciences (DISC), University of Genoa, Genoa, Italy; CIR-Dental School, Department of Surgical Sciences, University of Turin, Turin, Italy

**Aim:** the aim was to compare the clinical outcome of extra-short implants placed with one-stage or two-stage technique through a split-mouth study.

**Methods:** 19 healthy adult patients without contraindications to surgery were included: 9 at the University of Genoa and 10 at the University of Turin. Before surgery, bone quality was evaluated by the Hounsfield scale with the BTI Scan® program. In each patient we inserted two adjacent distal implants (BTI extra-short implants with a 5.5 mm or 6.5 mm length) with a split-mouth approach: one randomly selected implant was submerged (two-stage technique – “2ST”), the other was immediately connected to the multim abutment (one stage technique – 1ST). After 3 months, second stage surgery was performed, and the implants were rehabilitated with splinted screw-retained prostheses. Intraoral radiographs were taken to assess bone resorption, and periodontal indexes (Plaque in-

dex-PI, Bleeding on probing-BOP, Probing depth-PD) were recorded at the time of implant placement (T0), after 3 months (T3), after 6 months (T6) and after 12 months (T12) of healing. Implant stability (ISQ) was recorded by Osstell at T0 and T3.

**Results:** at 12 months of follow-up there were no drop-outs and none of the implants failed resulting in a 100% implant CSR. No significant difference between the two techniques was found in the mean increase in implant stability from T0 to T3 (T0: 1ST:67,81; 2ST:66,23;T3: 1ST:78,92; 2ST:78,60). Mean bone resorption was not significantly different between the two groups at any time point (T0: 1ST: 0.15mm 2ST:0.12mm; T3: 1ST:0.52 mm 2ST:0.41 mmm;T6: 1ST:0.85 mm 2ST:0.63 mm; T12: 1ST:0.68 mm 2ST:0.67 mm).

**Conclusion:** according to our preliminary results, the type of surgical technique (one-stage vs. two-stage) does not significantly affect the clinical outcomes of extra-short implants.

## ANALYSIS OF PERI-IMPLANT HARD TISSUE CHANGES IN RELATION TO IMPLANT CONNECTION TYPE

Fantini M.<sup>1</sup>, Gemma E.<sup>1</sup>, Cangelosi D.<sup>2</sup>, Cosi R.<sup>1</sup>, Giboli L.<sup>2</sup>, Laveglia L.<sup>1</sup>

<sup>1</sup>Private Practice, Varese, Italy

<sup>2</sup>School of Dentistry, Department of Health Sciences, University of Insubria, Varese, Italy

**Aim:** investigate the correlation between increase in coronal height and variation of interproximal bone peaks.

**Methods:** this is a retrospective observational study of intraoral radiograph imaging of two types of implants placed in edentulous sites. 182 intraoral radiograph imaging implants were analyzed and reduced to 77. The two groups samples were: first connection 0, patients treated with a 5° conometric internal hexagonal connection; second connection 1, patients treated with a 45° internal hexagonal connection. Analog and digital periapical radiograph imaging were taken for each implant with tailored centering to determine the marginal bone level position at T<sub>0</sub> and after 1 year implant placement. A provisional prosthesis was placed after the osseointegration period and left for 1 year to allow tissue maturation. After 1 year, measuring was taken for definitive prosthesis. Marginal bone resorption was calculated as the distance between the most

apical bone-implant contacts points (I-Fbic) and the implant-abutment connection level. The measurement of crown height and contact point was added to evaluate the relation of the connection with distance between contact point (CP) and the bone peak (BP). Prosthetic crown height (I-TH) was calculated as the distance from the shoulder of the implant to the perpendicular point corresponding to the apex of the crown. IBM SPSS 24.0 software.

**Results:** the relation between I-Fbic and I-TH (lever arm) showed that as the lever arm increases there is a reduction in the I-Fbic value which could indicate an increase in bone resorption.

**Conclusion:** as coronal height increases interproximal bone peaks decrease. This explained by a grow in the lever arm which leads to increased stress at the implant level or by the pumping effect. Studies with a larger and more specific sample is needed to confirm these hypotheses.

## INTERNAL VS EXTERNAL CONNECTION IN FULL-ARCH REHABILITATION: THREE YEARS SPLIT-MOUTH STUDY

Crupi A., Carossa M., Ambrogio G., Mussano F., Pera F.

Department of Surgical Sciences, C.I.R Dental School, University of Turin, Turin, Italy

**Aim:** the aim of this split-mouth study was to evaluate the difference between peri-implant tissue behaviour using internal and external connection on immediately loaded-full-arch implant rehabilitations.

**Methods:** 10 subjects, 7 males and 3 females, have been enrolled. They were all partially edentulous, eight in the upper jaw and two in the lower jaw, with high levels of bone resorption. After extraction of the remaining hopeless teeth, patients were rehabilitated with four post extractive implants according to the All on 4 Protocol<sup>®</sup> with the variance of using two implants with external connection in one emijaw and two with internal connection in the other one. The mesial ones were placed up-right while the distal ones were inserted tilted in order to avoid the anatomical limits. Full-arch resin prosthesis supported with a metal framework, connecting all the implants, according to Columbus Bridge Protocol<sup>®</sup> was screwed following immediate loading protocol. Peri-

implant bone loss was chosen as the primary studied parameter. In each patient, peri-implant bone levels were evaluated on intraoral radiographs. The distance from implant/abutment junction (IA) to marginal bone level was evaluated. Implant probing and implant survival rate were chosen as secondary parameters to study. Peri-implant probing depth (PPD), Plaque index, bleeding on probing (BOP), mobility and pain were evaluated.

**Results:** no significant differences ( $p > 0,05$ ) between the two types of implant connection were evidenced at 36 months. No difference was evidenced in peri-implant probing. Implant success rate was 100% at 9 months and 95% at 36 months.

**Conclusion:** external connection bone loss at 36 months was higher, but not significant compared to the internal connection. The two types of connections didn't show any difference in peri-implant probing. A larger number of patients is required to confirm the result of the present study.

## THE “ALL-ON-FOUR” REHABILITATION IN DIABETIC PATIENTS: A 3-YEARS FOLLOW-UP

Cusenza I., Bellantoni G., Franceschi L., Ruscica C., Piro M., Capparè P.

Department of Dentistry, IRCCS San Raffaele Hospital, Milan, Italy; Dental School, Vita- Salute San Raffaele University, Milan, Italy

**Aim:** the aim of the present study was to evaluate the survival rate of “All-on-four” rehabilitation in diabetic patients with 3-years follow-up.

**Methods:** thirty-eight patients with completely edentulous jaws or with a severely compromised natural dentition were selected for an implant supported rehabilitation of one or both the jaws. After teeth’s avulsion, four post-extraction immediate implants with a minimum torque of 35 N/cm were placed at the same time according to the “All on four” concept treatment and immediate loading protocol was achieved. After a 6-month healing period definitive prosthesis were delivered.

**Results:** a total amount of 200 implants were placed in 38 patients. 12 patients received rehabilitation of both jaws, 9 patients only in the mandible and 17 patients in the maxilla. At 12 months follow-up, overall survival rate was 94.5% with 11 implant failures. At 3-years follow-up a patient rehabilitated only

in the mandible died for cardiovascular problems, then we excluded him from this study. With a total amount of 196 implants, we saw 5 more failures with a global survival rate of 91.83%.

Considering the full arch rehabilitation group (12 patients), at 1 year follow-up survival rate was high, with a 96,87% with 3 implant failure out of 96. At 3-years, only one more failure we observed, with a survival rate of 95.83%.

At 1 year follow-up, intraoral X-rays analysis revealed a mean marginal bone loss of  $0,86 \pm 0,45$  mm at 12 months follow-up. At 3-years it was only slightly higher, equal to  $0,79 \pm 0,37$  mm.

**Conclusion:** within the limitations of this study, it suggests that the “All-on-four” treatment concept can be considered a safety and predictable procedure for full-arch rehabilitation in diabetic patients. It’s crucial to include them in a strict follow-up protocol and monitoring modifiable risk factors for implant failure.

## EFFECTIVENESS OF THE MACROGEOMETRY AND THREADS PROFILE ON DENTAL IMPLANT PRIMARY STABILITY

Di Cosola M.<sup>1,2</sup>, Comuzzi L.<sup>3</sup>, Tumedei M.<sup>4</sup>, De Angelis F.<sup>4</sup>, Lorusso F.<sup>4</sup>, Piattelli A.<sup>4,5,6</sup>, Iezzi G.<sup>4</sup>

<sup>1</sup>University of Foggia, Foggia, Italy

<sup>2</sup>Villa Pompea, Bari, Italy

<sup>3</sup>Private Practice, San Vendemiano-Conegliano, Treviso, Italy

<sup>4</sup>Department of Medical, Oral and Biotechnological Sciences, University G. D’Annunzio of Chieti-Pescara, Chieti, Italy

<sup>5</sup>Biomaterials Engineering, Catholic University of San Antonio de Murcia (UCAM), Guadalupe, Murcia, Spain

<sup>6</sup>Villaserena Foundation for Research, Città Sant’Angelo, Pesaro, Italy

**Aim:** the aim of the present investigation was to evaluate the insertion torque (IT), removal torque (RT) and Implant stability Quotient (ISQ) of two different implant macrogeometry and thread profile on solid rigid polyurethane model.

**Methods:** two different implants macrogeometries were tested: K2 (Group I) with 11° angle, 1.17mm pitch and self-cutting V thread profile and K3 (Group II) implants with 30° angle, 0.71 mm pitch and spiryal thread profile. A total of 120 specimens (n 1/4 60 for each group) were positioned into different conditions of solid rigid polyurethane blocks. The insertion torque (IT), removal tor-

que (RT) and ISQ were measured for each specimen. All specimens achieved the positioning into solid rigid polyurethane blocks for both of groups with no loss of stability.

**Results:** a significantly higher IT, RT and ISQ were detected in Group II ( $p < 0.05$ ). In both groups the mean values for IT, RT and ISQ appeared promising from a clinical point of view.

**Conclusion:** in spite of different macrogeometry and thread profile, both implant types achieved high primary stability on solid rigid polyurethane block to support the functional loading for a clinical application.

## IMPLANT-PROSTHETIC REHABILITATION IN THE GERIATRIC PATIENT: A REVIEW

Franceschi L., Bellantoni G., Cusenza I., Todaro M., Carinci G., Capparè P.

Department of Dentistry of the IRCCS San Raffaele Hospital, Milan, Italy; Dental School, Vita-Salute San Raffaele University, Milan, Italy

**Aim:** the purpose of this study is to evaluate implant successful rate in geriatric patients ( $\geq 75$  years) to investigate if age represents a risk factor in implant rehabilitation.

**Methods:** this systematic review includes all human clinical studies referred to geriatric patients with and without particular systemic conditions, undergoing an implant rehabilitation.

Inclusion criteria are:

1. Implant placement in fully and partially edentulous patients.
2. Implant-supported fixed or removable prostheses.
3. Studies must specify the type of research carried out, the number of participants, placed and failed implants, the time elapsed since the loading of the implants and the patients' follow-up.
4. Participants must have been clinically examined during the recall appointments.

Exclusion criteria are:

- Age <75 years.

- One-component, zygomatic and pterygoid implants.
- Post-load follow-up < 12 months.
- Narrow diameter implants or mini-implants.
- Implants with machined/minimally rough surfaces.

The databases used were MEDLINE (PubMed), EMBASE and CENTRAL. The search terms used were included in the MeSH (Medical Subject Headings) system. They were combined with "OR" and "AND" conjunctions to generate the PICO model.

**Results:** a total of 6,893 studies were included. Analyzing title and abstract to eliminate duplicates and irrelevant articles, 680 studies were selected for full-text analysis. A total of 62 articles were included for data extraction and only 7 were about geriatric patients. The overall post-load survival of the implant was estimated to be 97.5%. There were no statistically significant differences compared to the young cohort studies.

**Conclusion:** implant therapy can be considered a predictable treatment option even for geriatric patients.

## BIOMECHANICAL BEHAVIOR OF IN-KONE® CONICAL IMPLANT CONNECTION: FEM AND VON MISES ANALYSES

Gambino D., Fiorillo L., Gorassini F., Scoglio C.M.R., Mastroieni R., D'Amico C., Cervino G., Cicciù M.

Department of Biomedical and Dental Sciences and Morphological and Functional Imaging, University of Messina, Messina, Italy

**Aim:** several simulations and studies in silica evaluate conical implant-abutment connections and their excellent connection stability. The purpose of this study is to obtain data about the force distribution on the In-Kone® dental implant components and on the peri-implant tissues, subjected to mandibular force during chewing cycles. The hypothesis was assumed that there are no clinical differences between in silica studies and *in vivo* conditions.

**Methods:** by applying engineering systems of investigations like Finite Element Method and Von Mises analyses, it was possible to evaluate the distribution of forces and dental implant material resistance against the dynamic masticatory loads. The study conducted on this novel dental implant connection therefore includes an investigation of the forces with a load of 800N at 0 and 30 degrees of angulation. The research was divided into three

steps: (i) reverse engineering of the prosthesis, which allowed the transformation of a STL scan into a three-dimensional CAD model, (ii) creation of the mechanical model with applications of the boundary conditions of loads and constraints, (iii) results on mechanical behavior are obtained, on the distribution of stresses on the three prosthodontics.

**Results:** by analyzing the data, it's possible to assume that there are no clinical differences between in silica studies and *in vivo* conditions. These new connections guarantee a correct distribution of forces both on the implant components and on the peri-implant tissues.

**Conclusion:** the tested connection shows how studies of this type are able to improve dental implants even before they are fabricated. The continuous evolution in the bioengineering field will certainly lead to obtaining ever more performing dental implants.

## DECISION CRITERIA FOR THE TREATMENT OF VERTICAL BONE ATROPHIES IN THE POSTERIOR MANDIBLE

Karaban M.<sup>1</sup>, Barausse C.<sup>1,2</sup>, Montebugnoli A.<sup>1</sup>, Berti C., Bonifazi L.<sup>1,4</sup>, Felice P.<sup>1</sup>

<sup>1</sup>Oral Surgery, Department of Biomedical and Neuromotor Sciences, University of Bologna, Bologna, Italy

<sup>2</sup>Postgraduate school of Oral Surgery, University of Modena and Reggio Emilia, Modena, Italy

<sup>3</sup>Department of Neuroscience, Reproductive Sciences and Dentistry, University of Naples Federico II, Naples, Italy

<sup>4</sup>Department of Basic Medical Sciences, Neurosciences and Sense Organs, University of Bari Aldo Moro, Bari, Italy

**Aim:** nowadays, to deal with bone atrophy is a quite common situation for surgeons.

In this complex rehabilitations, especially in the posterior mandible, it is still unclear in literature which fixed treatment option is the best. The aim of this article was to help clinicians in the choice of an adequate treatment for the posterior atrophic mandible.

**Methods:** posterior mandible bone atrophies were divided into four main groups depending on the bone height measured above the inferior alveolar nerve: (1)  $\leq 4$  mm; (2)  $> 4$  mm  $\leq 5$  mm; (3)  $> 5$  mm  $\leq 6$  mm; (4)  $> 6$  mm  $< 7$  mm.

**Results:** different approaches were proposed for each group, considering patient expectations. If  $\leq 4$  mm of bone height was available, guided bone regeneration was used as the adequate approach. For bone heights  $> 4$  mm and  $\leq 6$  mm, the “sandwich” technique and/or short implants were used, depending on esthetics. In cases with  $> 6$  mm and  $< 7$  mm above the mandibular canal, short implants might be the proper option.

**Conclusion:** every time the clinician faces vertical bone atrophies of the posterior mandible, the proper treatment plan should be chosen depending on the residual bone height, in conjunction with patient’s expectations of the upcoming rehabilitation.

## 6 MM VS 11 MM IMPLANTS FOR THE REHABILITATION OF THE EDENTULOUS MANDIBLE: 5-YEARS RESULTS

Guida L.<sup>1</sup>, Annunziata M.<sup>1</sup>, Esposito U.<sup>2</sup>, Sirignano M.<sup>2</sup>, Torrisi P.<sup>3</sup>, Piccirillo A.<sup>1</sup>, Cecchinato D.<sup>4</sup>

<sup>1</sup>Multidisciplinary Department of Medical-Surgical and Dental Specialties, University of Campania Luigi Vanvitelli, Caserta, Italy

<sup>2</sup>Antonio Cardarelli Hospital, Naples, Italy

<sup>3</sup>Private Practice, Catania, Italy

<sup>4</sup>Institute Franci, Padua, Italy

**Aim:** short dental implants represent today a well-documented clinical option to rehabilitate edentulous atrophic sites in order to avoid bone augmentation procedures. This is a 5-year ad-interim report of a multicenter randomized controlled trial aimed to assess the efficacy of short (6 mm) implants vs longer (11 mm) implants supporting fixed full-arch mandibular prostheses (ethical committee approval N. 13/2010; registration on clinicaltrials.gov NCT03509402).

**Methods:** patients with an edentulous mandible, able to receive five 4 mm-wide and 11 mm-long implants in the interforaminal area, were selected in three study centers and randomly allocated to the test group (6 mm-implants) or to the control group (11 mm-implants). No bone augmentation procedure was performed. Implants (Osseospeed, Dentsply Sirona Implants, Mölndal, Sweden) were exposed after 3 months, and a screw-retained metal-resin full-arch prosthesis with distal can-

tilevers was positioned. Clinical and radiographic data for up to 5 years were analyzed.

**Results:** 150 implants in 30 patients were inserted. 20 patients were controlled at 5 years. No implant or prosthesis loss occurred. No significant inter-group difference for biological/technical complications was registered. No significant intra-group or inter-group differences in the mean peri-implant marginal bone level change were registered at any follow-up. At 5 years, the mean MBLc values were  $-0.02 \pm 0.18$  mm and  $-0.10 \pm 0.37$  mm for the test and control group, respectively.

**Conclusion:** 6-mm implants may be considered, basing on the clinical and radiographic outcomes found, a reliable option for the rehabilitation of total edentulous mandibles. Such promising results support the hypothesis of the use of short implants, in selected cases, even in non-atrophic sites, in the wake of increasingly simplified, low-stress and minimally invasive implant therapies.

## 1-STAGE GBR WITH RESORBABLE MEMBRANES IN HORIZONTALLY ATROPHIC JAWS: A RETROSPECTIVE STUDY

Remitti C.<sup>1</sup>, Carlo Barausse C.<sup>1,2</sup>, Montebugnoli A.<sup>1</sup>, Bonifazi L.<sup>1,3</sup>, Karaban M.<sup>1</sup>, Felice P.<sup>1</sup>

<sup>1</sup>Oral Surgery, Department of Biomedical and Neuromotor Sciences, University of Bologna, Bologna, Italy

<sup>2</sup>Postgraduate School of Oral Surgery, University of Modena and Reggio Emilia, Modena, Italy

<sup>3</sup>Department of Basic Medical Sciences, Neurosciences and Sense Organs, University of Bari Aldo Moro, Bari, Italy

**Aim:** the aim of this retrospective study was to evaluate clinical and radiographic outcomes of one-stage Guided Bone Regeneration (GBR) procedures in the rehabilitation of partially edentulous and horizontally atrophic jaws using resorbable membranes.

**Methods:** a retrospective single cohort study was conducted. Patients were treated by two expert surgeons. The inclusion criteria were the following: previously partially edentulism, horizontal bone atrophy treated with GBR (1-stage implant positioning approach) performed with resorbable membranes and with at least 3 years of follow-up. Clinical and radiographic data were collected by examining clinical charts.

**Results:** a total of 49 patients were included and 97 dental implants were placed. Twenty-six (53.06%) of the GBRs were performed in the upper jaw and 23 (46.94%) in the posterior mandible. The follow-up is between 3 to 7 years after loading. The healing was uneventful and no complications occurred in

the majority of the patients (43 patients, 87.76%). Two temporary paresthesia lasting 7 and 21 days respectively and 5 incomplete bone augmentations occurred. No membrane exposures were reported. The amount of horizontally augmented bone was  $2.76 \pm 0.74$  mm. The mean percentage of bone filling was 93.21%. When a complete regeneration was obtained, the mean planned horizontal augmentation was  $2.81 \pm 0.67$  mm, while when the regeneration was incomplete, the mean planned horizontal augmentation was  $3.12 \pm 0.76$  mm. The 7-year follow-up resulted in a  $0.99 \pm 0.63$  mm of peri-implant bone loss.

**Conclusion:** data seem to indicate that one-stage GBR with resorbable membranes can be a good clinical choice, and suggest that it could be better to reconstruct horizontally no more than 3 mm of bone in order to reduce the number of complications and to obtain stable results. However, this technique remains difficult and requires expert surgeons.

## BIOCHEMICAL MODIFICATION OF TITANIUM ORAL IMPLANTS SURFACES

Torchia M., Landini J., Sassi A. N., Lupi S.M.

Department of Clinical-Surgical, Diagnostic and Pediatric Sciences, Section of Dentistry, University of Pavia, Pavia, Italy

**Aim:** the evolution of the implant-prosthetic technique and the consequent need to expand the indications for implant treatment require an improvement of the osseointegration features of titanium surfaces, thus reducing the healing time and increasing the possibility to perform implant surgery even in patients suffering from bone metabolism disorders. Biochemical Modification of Titanium Surfaces (BMTiS) currently represents in this regard a fascinating and promising area of research. BMTiS allows to immobilize biomolecules on dental implant surfaces to increase implant-host interactions, with a possible improvement of osseointegration. The aim of the study is to present the evidences from literature about the main biomolecules employed in *in vivo* studies to obtain biochemically-modified titanium oral implants.

**Methods:** through a complete review of the literature on the *in vivo* use of BMTiS, the possible applications of this technology

are illustrated and possible future fields of scientific research are identified.

**Results:** bone-Implant Contact parameter showed the most significant improvements due to the immobilization of biomolecules on titanium implant surfaces. In particular, the immobilization of extracellular matrix components such as type-I collagen - alone or in combination with growth factors and/or glycosaminoglycans - appears to positively influence new bone apposition around implant surfaces, thus accelerating the osseointegration process. Further, promising results have been reported in terms of newly formed bone density values, RTQ and ISQ.

**Conclusion:** biochemical modification of titanium oral implants surfaces can improve osseointegration. Nevertheless, given the lack of human applications, more studies are required to confirm the evidences obtained from animal models.

## A COMPARATIVE EVALUATION OF OSSEODENSIFICATION VS STANDARD DRILLING PROTOCOL: AN *IN VITRO* INVESTIGATION

Tumedei M.<sup>1</sup>, Comuzzi L.<sup>2</sup>, Piattelli A.<sup>1,3,4</sup>, Iezzi G.<sup>1</sup>

<sup>1</sup>Department of Medical, Oral and Biotechnological Sciences, University G. D'Annunzio of Chieti-Pescara, Chieti, Italy

<sup>2</sup>Private Practice, San Vendemiano-Conegliano, Treviso, Italy

<sup>3</sup>Biomaterials Engineering, Catholic University of San Antonio de Murcia (UCAM), Murcia, Spain

<sup>4</sup>Villaserena Foundation for Research, Città Sant'Angelo, Pescara, Italy

**Aim:** the aim of the present *in vitro* investigation was to evaluate, on polyurethane sheets, two different drilling techniques for dental implant positioning using osteocondensing burs compared to a standard type protocol.

**Methods:** three different implant designs (Implacil De Bortoli UN III 4 × 10 mm, Restore RBM 4 (HEX) × 10 mm; Implacil De Bortoli UN II 4 × 10 mm) were evaluated (test implant (osteocondensing drills) and control implant (standard drills)). The insertion torque (IT), the removal torque (RT) and the resonance frequency analysis (RFA) values of test and control implants inserted in different size and different density polyurethane foam models were compared for 120 experimental sites. Accordingly, 120 experimental holes were produced in different PCF polyurethane foams: 60 sites we-

re produced in 10 PCF sheets and 60 sites in 10 PCF sheets with an additional 1 mm layer of 30 PCF.

**Results:** the IT, removal torque and RFA values were significantly higher for both of the evaluated implants, in the sites prepared with the osteocondenser drills when compared to sites prepared with standard drills ( $p < 0.05$ ). The UNII and UN III showed significantly higher stability compared to the HEX implant; these differences increased drastically in the 10 PCF Polyurethane Block with the additional 1 mm cortical layer ( $p < 0.05$ ).

**Conclusion:** the outcome of this investigation suggested a possible clinical application of osteocondensing burs in case of reduced bone quality and quantity in the posterior maxilla.

## COST-EFFECTIVENESS ANALYSIS OF ANTIBIOTIC USE IN DENTAL IMPLANT THERAPY

Zhurakivska K.<sup>1</sup>, Dioguardi M.<sup>1</sup>, Caponio V. C. A.<sup>1</sup>, Arena C.<sup>1</sup>, Campisi G.<sup>2</sup>, Mascitti M.<sup>3</sup>, Lo Muzio E.<sup>4</sup>, Mauceri R.<sup>2</sup>, Troiano G.<sup>1</sup>

<sup>1</sup>Department of Clinical and Experimental Medicine, University of Foggia, Foggia, Italy

<sup>2</sup>Sector of Oral Medicine, Department of Surgical, Oncological, and Oral Sciences (DiChirOnS), University of Palermo, Palermo, Italy

<sup>3</sup>Department of Clinical Specialistic and Dental Sciences, Marche Polytechnic, Ancona, Italy

<sup>4</sup>School of Orthodontics, University of Ferrara, Ferrara, Italy

**Aim:** use of antibiotic prophylaxis during implant placement seems to improve implant short term survival. Nevertheless, the use of antibiotics carries a risk of adverse effects, as well as an ever increasing resistance to antibiotics. Aim of the present study is to compare in terms of costs and health outcomes the implant rehabilitation procedures with and without use of antibiotic prophylaxis.

**Methods:** a decision-tree model with a short time horizon of 1 year has been developed using TreeAge Pro Healthcare software. Two strategies have been compared: Antibiotic use and No antibiotic prophylaxis in implant placement procedures. The costs were calculated considering direct costs for implant placement, antibiotic costs, and costs for implant replacement in case of failure. Effectiveness was defined in terms of Quality

Adjusted Life Years (QALYs) and data were obtained from scientific papers available in literature. Transition probabilities were also obtained from scientific papers. Monte Carlo Simulation was performed for sensitivity analysis. The analysis was conducted from patient's perspective.

**Results:** cost-effectiveness analysis revealed that Antibiotic strategy leads to a greater final net monetary benefit, making the strategy more effective in terms of Incremental Cost Effectiveness Ratio (ICER) compared to No Antibiotic alternative.

**Conclusion:** adoption of antibiotic prophylaxis during implant placement procedures may be considered an effective strategy, since the incremental cost is compensated by final incremental QALYs and a reduced need of implant replacement.

## TREATMENT OF MELANIN GINGIVAL PIGMENTATION WITH Q-SWITCHED ND:YAG LASER

Armogida N.G., Lubrano M.R., Arletti A., Cino R., Cuzzo A., Mauriello L., Vaia E.

Department of Neuroscience and Reproductive and Odontostomatological Sciences, University of Naples Federico II, Naples, Italy

**Aim:** gingival pigmentations (GP) are purplish discolorations or irregularly shaped brown streaks or spots. These common and probably hereditary conditions are determined by the accumulation of melanin due to the hyperactivity of melanocytes in the basal and supra-basal epithelial layers. Gingivoplasty is considered the conventional treatment for these lesions and allows the direct removal of pigmentations but is associated to the common side effects of surgeries. In order to provide for a more conservative approach, the off-label application of the Q-switched Nd:YAG laser (wavelength 532-1064 nm) has been tested with its selective photothermolysis.

**Methods:** four patients were treated with the Q-switched Nd:YAG laser. The selected parameters allowed laser pulse to

act directly on the melanocyte layer. The so produced melanocytes photothermolysis determines a tissue reaction with the destruction of melanin granules. Depending on the degree of pigmentation, from 1 to 3 applications were carried out at 3-week intervals, without the need of any anesthesia.

**Results:** in all the cases pigmentations were completely removed, only one patient referred a slight discomfort during normal oral hygiene procedures. No complications or major discomforts have been reported.

**Conclusion:** the treatment was proved effective in treating GP and reducing the side effects of the conventional surgeries, thus laser treatment could be a valid alternative. However, further studies are needed.

## TREATMENT OF TONGUE ARTERIO-VEIN MALFORMATION (AVM) WITH DYE-LASER: 24 MONTHS FOLLOW-UP

Armogida N.G., Lubrano M.R., Cino R., Arletti A., Mauriello L., Cuzzo A., Vaia E.

Department of Neuroscience and Reproductive and Odontostomatological Sciences, University of Naples Federico II, Naples, Italy

**Aim:** AVMs are abnormal communications among vessels, which bypass the normal capillary bed. To avoid the invasiveness of the gold standard surgical exeresis, dye-laser has been used to coagulate both capillaries and red vascular malformations, without involving the superficial epithelial layers.

**Methods:** a 53 years old man with a good systemic health presented a voluminous bluish-red nodular neoformation on the left hemi-tongue covered by intact mucosa, with hard-elastic consistency and no pain on palpation and referred difficulties in chewing and phonation. The TUI technique and the Color/Power Doppler and 3D Angio showed a capsulated neoformation diagnosed as AVM subsequently classified as stage 2 (Schobinger, 1996). The patient was treated with two applications 2 months apart of rhodamine dye-laser with the following

parameters: fluence at 12 J/cm<sup>2</sup>, handpiece with 6 mm spot, single pulse with repetition up to 1.0 Hz and pulse duration of 3.0 ms.

**Results:** one month after the first application, the lesion was reduced in volume but stable in colour, thus a second application was provided in order to improve its colour and size. At 24 months follow-up, the lesion showed a size reduction with non-anarchic vessels arborization but a fibrotic structure persisted, requiring a peri-structural injection of cortisone.

**Conclusion:** with the limits of a case report, the application of dye-laser to treat AVMs was successful. Further studies are needed to better understand the efficacy and morbidity of dye-laser in the treatment of AVMs compared to the traditional therapeutic options.

## FLUORESCENCE VISUALIZATION WITH 405NM LASER OF ORAL SQUAMOUS CELL CARCINOMA: A CASE REPORT

Di Petto L.F., Lissoni A., Abati S., Polizzi E.M.

Department of Dentistry, Vita-Salute San Raffaele University, IRCCS San Raffaele Hospital, Milan, Italy

**Aim:** oral and oropharyngeal cancer represent a worldwide health burden, with an estimated incidence of more than 650,000 diagnosed cases. Oral squamous cell carcinoma (OSCC) represents 90% of the cases. A delayed diagnosis leads to poor quality of life and a higher mortality rate, and almost 50% of SCC cases receive a proper diagnosis when they are already at an advanced stage. Oral screening plays a vital role to detect any precancerous lesion or suspect of malignancy, thus reducing the mortality of SCC. Although the surgical biopsy represents the “gold standard” for an unquestionable diagnosis, the optical technologies of the last decade helped the health care providers with sophisticated devices the interception of suspect lesions.

**Methods:** a 33 years old female patient, during her appointment for oral hygiene, complained about a sore ulcer on the left border of the tongue, thinking it was due to an accidental traumatism that wasn't healing properly. The dental hygienist performed

an examination of the oral cavity and inspected the lesion with a 405nm wavelength laser device (Lasotronix). The positivity of the fluorescence visualization (FV), due to the excitement of the tissues showed how the area had a loss of fluorescence due to the decrease of fluorescence caused by a different absorption of light wave-lengths for the breakdown of collagen cross-links of flavin adenine dinucleotide (FAD) and nicotinamide adenine dinucleotide (NADH). The patient was immediately referred to the oral medicine specialist that performed a punch biopsy.

**Results:** surgical punch biopsy confirmed the lesion as a keratinized squamous cell carcinoma G2. The patient underwent to surgical excision, and at the 18-month follow-up, she has completely recovered.

**Conclusion:** early detection of OSCC is crucial to reduce the mortality rate of the patient, affecting minimally her QoL and guaranteeing a complete recovery.

## THE EFFICACY OF DIODE LASER AS AN AID IN PERIODONTITIS' TREATMENT: A REVIEW OF LITERATURE

Tetè G.<sup>1</sup>, Ferrante L.<sup>2</sup>, Moretto M.<sup>2</sup>, Rellandini G.<sup>2</sup>, Polizzi E.<sup>3</sup>

<sup>1</sup>Department of Dentistry, Vita-Salute San Raffaele University, IRCCS San Raffaele, Milan, Italy

<sup>2</sup>Student CLID, Vita-Salute San Raffaele University, IRCCS San Raffaele Hospital, Milan, Italy

<sup>3</sup>Coordinator CLID, Vita-Salute San Raffaele University, Center for Oral Hygiene and Prevention, Department: Dentistry, IRCCS San Raffaele Hospital, Milan, Italy

**Aim:** the objective of this study is to evaluate the effectiveness of the diode laser at 800-980 nm in addition to non-surgical periodontal therapy for the periodontitis treatment.

**Methods:** the authors performed an electronic research on PubMed inserting as keywords: (laser OR laser therapy OR diode laser) and (periodontitis OR periodontal disease). The field has been narrowed to select only Randomized controlled clinical trials (RCT) performed from 2010 to 2020.

**Results:** the result of this research was 84 articles, of which eight were included in the review because they met the inclusion criteria. The clinical, microbiological and immunological parameters obtained from the various studies included were compared. It has been shown that four of eight studies have

achieved greater benefits, in terms of clinical parameters, with the use of diode laser compared to only scaling and root planing (SRP). However, the greater increase in clinical parameters in diode laser-treated patients compared to the control group was mainly detected in the short term rather than in the long term. In terms of microbiological parameters no improvement was detected after six months. Only one study reported six-month improvements in immunological parameters in patients treated with DL compared to the SRP-only group.

**Conclusion:** in conclusion, taking into account the limitations of this review of literature, there is no evidence that the diode laser at 800-980 nm in addition to non-surgical periodontal therapy is more effective than SRP alone in the long term.

## LED PHOTOBIMODULATION FOR MANAGING THE PAIN PERCEIVED DURING RAPID MAXILLARY EXPANSION

Lacagnina C.<sup>1</sup>, Caccianiga P.<sup>2</sup>, Caccianiga G.<sup>2</sup>, Moretti N.<sup>2</sup>, Peters A.<sup>1</sup>, Palazzo G.<sup>1</sup>, Isola G.<sup>1</sup>, Lo Giudice A.<sup>1</sup>

<sup>1</sup>Department of Orthodontics, University of Catania, Catania, Italy

<sup>2</sup>Department of Orthodontics, University of Milano-Bicocca, Monza, Italy

**Aim:** the aim of this study is to evaluate the effectiveness of LLLT (low level laser therapy) in the reduction of pain reported by young patients during rapid palatal expansion therapy.

**Methods:** thirty subjects with diagnosis of skeletal transverse maxillary deficiency were included and randomly assigned to tested group (RPE and LLLT) and control group (RPE only). Inclusion criteria were: skeletal age between 10 and 13 years old, skeletal maturation from CVS1 to CVS3, completed eruption of upper first molar. Exclusion criteria were: bone systemic or metabolic diseases, chronic pain, neurological or psychiatric disorders, use of pharmacological agents interfering with pain perception, previous orthodontic treatment or simultaneous presence of other devices in the patient's mouth. The final sample included 14 males and 16 females with a mean age of 11,5 years old. Subjects in the tested group were irradiated at the time of the positioning of

the RPE with ATP38® (Biotech Dental, Allée de Craaponne, Salon De Provence, France). For the purposes of this investigation, the biostimulation scheme included 3 consecutive irradiation cycles of 48 J/cm<sup>2</sup>, with 1 minute rest time between each cycle for a total fluency of 144 J/cm<sup>2</sup>. Patients reported the pain experienced by using a Numerical Scale Rate, ranging from 0 to 10, at specific time intervals, that are, 6 hours, 12 hours, 24 hours, and from day 2 to 7. Wilcoxon-Mann-Whitney test was used to assess differences in NRS reported values among the two groups.

**Results:** pain experienced at each time interval and the maximum pain score were significantly lower in tested group ( $p < 0.05$ ) and decrease faster in tested group with score test near to 0 after 2/3 days.

**Conclusion:** LED photobiomodulation procedure alleviates the intensity and the duration of pain experienced by young patients undergoing rapid palatal expansion.

## LOW-LEVEL LASER THERAPY BIOSTIMULATION IN BONE REGENERATION: A REVIEW

Laudadio C.<sup>1</sup>, Hazballa D.<sup>1</sup>, Patano A.<sup>1</sup>, Malcangi G.<sup>1</sup>, Coloccia G.<sup>1</sup>, Marinelli G.<sup>1</sup>, Limongelli L.<sup>1</sup>, Inchingolo A.D.<sup>1</sup>, Montenegro V.<sup>1</sup>, D'Oria M.T.<sup>1</sup>, Corsalini M.<sup>1</sup>, Dipalma G.<sup>1</sup>, Inchingolo F.<sup>1</sup>, Di Venere D.<sup>1</sup>, Cardarelli C.<sup>1</sup>, Farronato M.<sup>2</sup>, Tartaglia G.<sup>2</sup>

Complex Operative Unit of Odontostomatology, Director: Prof. G. Favia

<sup>1</sup>Specialization School in Orthognatodontics, Director Prof. F. Inchingolo, Interdisciplinary Department of Medicine D.I.M. University of Bari Aldo Moro, Bari, Italy

<sup>2</sup>Department of Biomedical, Surgical and Dental Sciences, School of Dentistry, University of Milan, Milan, Italy. UOC Maxillo-Facial Surgery and Dentistry. Fondazione IRCCS Ca' Granda, Ospedale Maggiore Policlinico, Milan, Italy

**Aim:** nowadays the use of laser (Light Amplification by Stimulated Emission of Radiation) is finding ground in many fields of medicine. At the very beginning the use of laser was strictly employed in scientific laboratories but today its use has widespread in health care and diagnosis. The LLLT (Low-Level Laser Therapy) also known as photobiomodulation encourages the healing process by interfering in bone cell metabolism and in factors involved in inflammation and pain. The aim of this study is to point out the efficiency of the LLLT in tissue regeneration with a special focus in hard tissues and bone biomaterials, also to review evidence for the effect of different wave lengths in the cells differentiation and proliferation.

**Methods:** in order to access relevant articles, an electronic search is performed in Web of science, PubMed/Medline and Google Scholar. This study is focussed on the last ten year pa-

pers in English language only to review the use of the LLLT in bone regeneration.

**Results:** this study has analysed LLLT which uses a red light (600-700)nm and infrared light (770-1200)nm with an energy density from 2 J/cm<sup>2</sup> to 140 J/cm<sup>2</sup> in bone regeneration and its capacity to improve the properties of biomaterials used as bone substitutes. The photobiomodulation seems also to get involved with the osseointegration of implants offering a better adherence on the bone-implant surfaces. Most of the evidences point to the fact that LLLT influences the differentiation and the proliferation of osteoblastic lineage and encourage the deposition of Ca<sup>2+</sup>.

**Conclusion:** the LLLT is a promising therapy in the field of bone regeneration, but despite the fact that many research has been conducted in different cell lines and animal for the efficiency of LLLT further studies are needed to determine the standard protocol.

## TREATMENT OF VENOUS LAKES OF THE ORAL CAVITY WITH ND:YAG LASER: A CASE SERIES

Lubrano M.R., Armogida N.G., Arletti A., Cino R., Mauriello L., Vaia E., Cuzzo A.

Department of Neuroscience and Reproductive and Odontostomatological Sciences, University of Naples Federico II, Naples, Italy

**Aim:** venous lakes (VL) or phlebectasias are benign venous ectasias of the superficial dermal layers of a tissue damaged by prolonged sunlight exposure. They appear as solitary, soft, compressible, bluish-red papules, sized 0.2-1.0 cm, mostly localized on lower lip, face, ears and oral mucosa. Conventional treatments are excision, sclerotherapy and cryotherapy but for the treatment of the 25 venous lakes of this case series Nd:YAG laser has been chosen for its high penetration up to 5-6 mm into the tissue and its coagulative potential.

**Methods:** a dermatoscope was used to confirm the diagnosis of VL. Except for one on hard palate, the lesions affected the lower lip. Anesthesia was not needed in 24 cases, but one required lidocaine gel as topical anesthetic. The following operating para-

eters were used: energy density between 80-100 J/cm<sup>2</sup>; absolute energy parameters (4.9-10.0 J) and spot size (2.5-4 mm) were set according each lesion size; single pulse frequency.

**Results:** follow-ups were performed at 1 week, 1 month and 3 months. Patients did not report any discomfort in the days following treatment. After 1 week the tissue was almost completely intact, only a small eschar persisted, while after 1 month the recovery was complete and the lesions were totally absent.

**Conclusion:** the use of Nd:YAG laser in the treatment of VL could represent an excellent alternative to conventional therapies. Furthermore, the patient's compliance is high for the absence of major postoperative sequelae. Further studies are needed to analyze the effectiveness and morbidity of this treatment.

## OROPHARYNGEAL TERATO-CORISTOMA IN A NEWBORN: DIAGNOSIS AND DIODE LASER-ASSISTED SURGERY

Mezzapesa P.<sup>1</sup>, Casorelli A.<sup>2</sup>, Albanese G.<sup>1</sup>, Barile G.<sup>1</sup>, Dell'Olivo F.<sup>1</sup>, Limongelli L.<sup>3</sup>

<sup>1</sup>Specialization School of Oral Surgery, Department of Interdisciplinary Medicine, University of Bari, Bari, Italy

<sup>2</sup>Department of Interdisciplinary Medicine, University of Bari, Bari, Italy

<sup>3</sup>Specialization School of Oral Surgery, University of Chieti, Chieti, Italy

**Aim:** teratomas are benign neoplasms derived from all three germinal layers. The rare oropharyngeal involvement can lead to potentially lethal airway obstruction and respiratory distress. The management of such patients comprises the immediate postpartum secure airway and the surgical resection of the mass. The aim of this study was to report a case of a newborn affected by oropharyngeal teratoma treated by laser-assisted surgical excision.

**Case presentation:** in January 2020 a two-months old male infant, born to a 19-years old mother after 40 weeks gestation, was referred to Complex Operating Unit of Oral pathology and Surgery, University of Bari Aldo Moro, for respiratory distress because of a protruding mass involving the mouth's floor. The lesion was not intercepted during pregnancy ultrasonography. No mother's risk factors or wrong habits were pointed out from her medical history. Magnetic resonance imaging showed an enhanced un-homogenous ovalar 2cm lesion involving the spa-

ce between the mylohyoid muscle and the tongue. During general anesthesia, intra-operative Fine Needle Aspiration revealed a whitish-yellowish gelatinous amorphous material. Afterwards laser-assisted surgical enucleation was performed (diode laser in CW- 320µm fiber; output 7 W) via an intraoral approach. Histological examination reported a "mature terato-coristomatous nodule, with skin and adnexal type structures, fibro-adipose tissue and skeletal muscle, without malignant signs". 1 year follow-up revealed no sign of recurrence and complete healing and resolution of the respiratory distress.

**Conclusion:** congenital sublingual masses are rare and life-threatening infant neoplasms. Surgical excision with histopathological analysis is essential to secure the airway and to exclude malignancy. In our experience laser-assisted enucleation allows to reduce intra-operative bleeding and improves post-operative outcome.

## APDT FOR THE TREATMENT OF PERIODONTITIS: AN EVALUATION OF LITERATURE QUALITY AND METHODS

Modolo D., Stellini E., Sbricoli L.

Department of Neuroscience, University of Padua, Padua, Italy

**Aim:** a critical evaluation of the quality of literature concerning antimicrobial photodynamic therapy.

**Methods:** full-text studies concerning a PDT in periodontal treatment were extracted from PubMed, using the key-words *photodynamic therapy, periodontitis, gingivitis, laser*. The randomized controlled trial was chosen as the study type to be analyzed as it was the most frequent, and CONSORT Statement was used to evaluate the quality of literature.

**Results:** 81 studies were analyzed. CONSORT items were classified as completely/partially/not at all satisfied; they could have been considered not applicable as well. None out of the 81 RCTs respected all the 37 items. If this trend lasts, the pro-

bability to find a study in PubMed adhering to 80-100% of items will be equal to 9,18%; a study adhering to 90-100% of items will have 4,18% probability to be found.

**Conclusion:** aiming the CONSORT Statement to guarantee greater transparency and accuracy of reporting, it is undeniable that the more its requirements are respected, the higher the quality is. The probability to find a study adhering to the Statement needs to be increased. We consider right and useful to spread the knowledge of CONSORT and of other guidelines for reporting, encouraging its employment as well, in order to get an increased quality and comparability among the growing number of studies in the scientific research on this new oral treatment approach.

## THE USE OF LOW-LEVEL LASER THERAPY IN DENTISTRY

Patano A.<sup>1</sup>, Laudadio C.<sup>1</sup>, Malcangi G.<sup>1</sup>, Hazballa D.<sup>1</sup>, Coloccia G.<sup>1</sup>, Marinelli G.<sup>1</sup>, Limongelli L.<sup>1</sup>, Inchingolo A.D.<sup>1</sup>, Montenegro V.<sup>1</sup>, D'Oria M.T.<sup>1</sup>, Laforgia A.<sup>1</sup>, Dipalma G.<sup>1</sup>, Inchingolo F.<sup>1</sup>, Di Venere D.<sup>1</sup>, Inchingolo A.M.<sup>1</sup>, Farronato M.<sup>2</sup>, Tartaglia G.<sup>2</sup>

Complex Operative Unit of Odontostomatology, Director: Prof. G. Favia

<sup>1</sup>Specialization School in Orthognatodontics Director Prof. F. Inchingolo, Interdisciplinary Department of Medicine D.I.M. University of Bari Aldo Moro, Bari, Italy

<sup>2</sup>Department of Biomedical, Surgical and Dental Sciences, School of Dentistry, University of Milan, Milan, Italy. UOC Maxillo-Facial Surgery and Dentistry. Fondazione IRCCS Ca' Granda, Ospedale Maggiore Policlinico, Milan, Italy

**Aim:** in recent years, laser therapy has gained popularity in the fields of medicine and dentistry. Low-level laser therapy (LLLT), also known as photobiostimulation (PMB) is widely used in dentistry since it offers numerous benefits to patients such as inflammation and edema reduction, accelerated wound healing and pain relief. The aim of this study is to examine the use of LLLT in oral medicine and dentistry.

**Methods:** an electronic search on PubMed and Google Scholar databases was conducted and the following keywords were used: low-level laser therapy, photobiomodulation, photobiostimulation, oral medicine and dentistry.

**Results:** LLLT has positive effects on the healing of ulcerative lesions, recurrent aphthous stomatitis, herpes simplex and oral mucositis in oncologic patients. It is also used in periodontal thera-

pies and perimplantitis with positive effects on soft and hard tissues. Furthermore, the use of LLLT seems able to reduce symptoms of trigeminal neuralgia and burning mouth syndrome and to enhance salivary flow in patients with xerostomia. Many studies reported that LLLT can stimulate the proliferation and differentiation of osteogenetics cell. Biostimulation improves the osteogenetic properties of biomaterials and increases implant osteointegration improving cellular adhesion on implant surface. LLLT is useful also in orthodontics accelerating tooth movement and decreasing the inflammation and pain caused from the pressure on the teeth.

**Conclusion:** the results of this study show that LLLT has a wide range of applications in dentistry. However, the utilization parameters are still controversial and further researches are needed to develop optimal clinical protocols.

## LASER PARAMETERS FOR PHOTOBIO-MODULATION IN ORAL LICHEN PLANUS: EVIDENCE OR EXPERIENCE?

Roccon A., Schiazzano C., Tomasin M., Bacci C.

Department of Neurosciences, Head Prof. R. De Caro, Section of Clinical Dentistry, Head Prof. E. Stellini, Unit of Oral Pathology and Medicine, University of Padua, Padua, Italy

**Aim:** the aim of this study is to find in the scientific literature the laser parameters used to perform successfully Laser Photobiomodulation in order to manage symptomatology and clinical manifestations of Oral Lichen Planus.

**Methods:** clinical Trials, Studies and Randomized Clinical Trials were searched in electronic databases (PubMed, Scopus, Google Scholar) using the key words: “LLLT” OR “PBM” OR “low level laser therapy “ OR “photobiomodulation” OR “low level laser” AND “oral lichen planus” OR “OLP”. Among these studies, the following laser parameters were examined: active medium, wavelength, spot area, time of exposure, output power, power density (irradiance), fluency (energy density), time exposure and application technique.

**Results:** ten studies were found. Authors did not always report all the laser parameters searched. In most cases a diode laser with continuous wave emitting mode was used. Wave-

lengths ranged from 630nm to 1064nm. Output power varied from 10 mW to 3 W, while spot areas from 0,00283 cm<sup>2</sup> to 1cm<sup>2</sup>. Then, the values of power density and fluency administered were 10mW/cm<sup>2</sup> to 1W/cm<sup>2</sup> and 0.3 J/cm<sup>2</sup> to 177 J/cm<sup>2</sup>, respectively. Laser Photobiomodulation was found to be effective in all the studies. No adverse effect was reported.

**Conclusion:** laser Photobiomodulation proved to be effective in the management of Oral Lichen Planus symptoms and clinical manifestations with different laser settings. The remarkable advantage of this therapy is the absence of side effects. The heterogeneity of the laser doses administered can be explained by the lack of a universally accepted definition of Photobiomodulation. Further RCTs that compare the effectiveness of the different laser parameters and a standardization of the measurement of the parameters are necessary to establish the best settings for Photobiomodulation.

## ERBIUM:YAG LASER AND ENDODONTIC SURGERY: A CRITICAL REVIEW OF THE LITERATURE

Ruggeri K., Lusardi S., Viani M.V., Vescovi P., Meleti M.

University Center of Dentistry, Department of Medicine and Surgery, University of Parma, Parma, Italy

**Aim:** laser technologies and applications are rapidly spreading in all fields of dentistry, particularly in oral surgery. Among surgical procedures endodontic surgery, including osteotomy, apex removal and canal preparation could have a significant benefit from lasers properties. The aim of the present review is to summarize the relevant knowledge on the advantages and possible disadvantages of the use of Erbium:YAG (Er:YAG) laser in endodontic surgery.

**Methods:** we searched the Medline database, using as entry terms the combination of “Er:YAG laser and endodontic surgery”, “Erbium:YAG laser and apicoectomy”, “Er:YAG laser and endodontics”, “Er:YAG laser and apicoectomy” and “Erbium:YAG laser and endodontics”. Only literature in English, published after 2000, was taken into consideration. Duplicates resulting from the initial database querying were discarded through End Note X9©, Clarivate Analytics, software aid. After exclusion of repetitions, 437 records were screened for titles and abstracts and after full text evaluation 27 studies qualified for final inclusion in the review.

**Results:** the summarization of the results of the studies included in the present review highlighted that the usefulness of Er:Yag La-

ser in endodontic surgery is somewhat debated. The majority of studies (20) emphasize that Er:YAG laser surgery is very useful in achieving a good intra-operative haemostasis, in reducing post-surgical pain, and in decreasing discomfort associated to bur vibration. It is worthy to mention here that the use of Er:YAG laser can be useful for obtaining a smooth surface of the root surface and the canal which can promote the sealing with the material used for retro-cavity filling. On the other hand, few studies (7) demonstrated that there were no significant differences in endodontic surgery procedures performed with ultrasonic tools and burs and that the cut with Er:YAG laser is slower.

**Conclusion:** even if there is some controversy, the result of the present review highlighted that Er:YAG laser can be safely used for endodontic surgery, replacing traditional instruments. Advantages reported include, among others, a good haemostasis (when the laser is used without water irrigation) and reduction of post-surgical pain. Further studies are needed in order to clarify peculiar aspects such as the possible better retention of filling materials.

## LASER THERAPY IN THE TREATMENT OF PERI-IMPLANTITIS: STATE OF ART

Pisano M., Caggiano M., Iandolo A., Sammartino P., Sangiovanni G., Frucci E., Amato M.

Department of Medicine, Surgery and Dentistry, Scuola Medica Salernitana, University of Salerno, Baronissi, Italy

**Aim:** the treatment of the peri-implantitis is still challenging and no consensus was found in the literature on which is the best treatment protocol. In recent years, numerous Authors have proposed the use of the dental laser as an alternative and effective method for decontaminating the surface of infected implants. Therefore, the aim of this work was to examine the state of the art on the use of lasers in the treatment of peri-implantitis through the literature.

**Methods:** a literature search was carried out through the PubMed database (<http://www.ncbi.nlm.nih.gov/pubmed/>), selecting and reviewing articles that evaluate the effects of laser therapy in the treatment of peri-implantitis.

**Results:** among the various decontamination protocols proposed, those that involve the use of lasers seem to provide en-

couraging results. The included studies were subsequently divided into 3 groups based on the active medium of the laser used for the treatments being tested. Erbium: Yttrium Aluminum Garnet (Er:YAG) laser were included in group 1, CO<sub>2</sub> laser in group 2 and Diode laser in group 3.

**Conclusion:** the lasers showed positive results on average after 6 months of follow-up. The longer follow-up periods revealed that initial results were unstable and cases of reinfection were described. Comparative *in vivo* studies on the efficiency of laser and photodynamic therapy in addition to conventional therapy, indicate that this technique can induce a significantly higher decontamination of anaerobic bacterial species compared to that obtained with conventional therapy alone.

## PHOTOBIMODULATION WITH LASER DIODE ON MEDICATION RELATED OSTEONECROSIS OF THE JAW (MRONJ)

Santomauro N., Erovigni F., Todaro D., Ruggiero T., Dell'Acqua A.

Department of Surgical Sciences, Oral Surgery Section, CIR Dental School, University of Turin, Turin, Italy

**Aim:** biostimulation therapy is one of the most promising therapies for the treatment of medication-related osteonecrosis of the jaw (MRONJ) due to its biostimulatory potential. The objective of the study was to evaluate the clinical laser diode biostimulation therapy efficacy as MRONJ treatment.

**Methods:** this is a prospective single-sample study. 11 subjects with MRONJ, referred to the Oral Surgery Department of the Dental School, were included in the study. Collection of lesion data were evaluated before and after treatment and included: perceived pain expressed by a numerical rating scale (NSR), soft tissue quality using the Healing Scale of Masse et al., exposure area in mm<sup>2</sup> and probing depth in mm. 4 laser sessions, twice a week, was performed, with at least one day off between each session.

**Results:** the results, before and after the therapy, did not show statistically significant differences. Although a positive trend

could be seen in all parameters evaluated after treatment: probing depth decreased in 7 patients, two patients improved pain in NSR, the lesion area decreased in one patient and there is a difference in Healing Scale near statistic significant level ( $p = 0,06$ ). The improvement was minimal but present.

**Conclusion:** in literature, to date, there are no treating protocols, no definite approaches or long-term therapy for MRONJ. This study suggests that Biostimulation therapy might improve wound healing and reduce pain in some patient, but further studies with a wider sample are needed. Biostimulation therapy is easy to perform, does not increase morbidity and has no side effects. For this reason, it can be a critical adjuvant therapy for patients who cannot access invasive treatments because of their poor health. In these patients, a conservative approaches, such as laser biostimulation therapy, could be a valid, if not the only, alternative.

## PHOTODYNAMIC THERAPY EFFECTS ON MEDICATION-RELATED OSTEONECROSIS OF THE JAWS (MRONJ)

Vettori T., Erovigni F., Todaro D., Carossa M., Dell'Acqua A.

Department of Surgical Sciences, Oral Surgery Section, CIR Dental School, University of Turin, Turin, Italy

**Aim:** medication-related osteonecrosis of the jaw (MRONJ) is a drug-adverse reaction associated with antiresorptive and antiangiogenic therapy. MRONJ management have medical and surgical approaches. Photodynamic therapy (PT) is used, as adjuvant treatment, to improve healing applying topic photosensitizer in pair with low level laser diode light. The aim of this study is to evaluate the effects of diode laser PT (Oralia d-lux, Konstanz, Germany) as MRONJ treatment.

**Methods:** 9 patients with MRONJ were selected, 53 to 87 years old. Professional oral hygiene was performed first, immediately after was applied methylene blue/violet dye (Photolase, Hamburg, Germany) and the PT with GaAIs at 810nm up to 1 cm from lesion using photodynamic setting (600 mW, 0 Hz, 24000 mJ) for 40 s/cm<sup>2</sup>, 4 times in 2 weeks with final check a week later.

Before and after the therapy, clinic status was evaluated using: Healing Scale of Masse et al. for mucosal healing, Numerical

Rating Scale for patient pain, probe depth in mm and lesion area in mm<sup>2</sup>.

**Results:** the difference of probe depth and lesion area, before and after the therapy, don't show a statistically significant difference ( $p = 0,0643$ ). No significant difference in score of pain scale, even if near the 0.05 statistic significant level ( $p = 0,0104$ ). There is a significant difference in Healing Scale: soft tissue's clinical appearance improved.

**Conclusion:** the use of adjuvant PT enhances oral mucosa healing decreasing inflammation, bleeding, suppuration.

This study suggests that PT might decrease pain, but the outcome should be interpreted cautiously because of the narrow group of patients. PT may be an adjuvant treatment of the standard surgical and medical approaches offering an advantage to reduce infection and inflammation of soft tissues or improve the patient's health and quality of life when surgery is not possible.

## LLLT LASER THERAPY IN SUPPORT OF AESTHETIC PROSTHETIC REHABILITATIONS: A CASE REPORT

Ferri S., Sertori F., Pensa V., Massaglia M.M., Rebba B., Cattoni F.

Department of Dentistry, IRCCS San Raffaele Hospital, Milan, Italy; Dental School, Vita Salute San Raffaele University, Milan, Italy

**Aim:** in dental practice, low-level laser therapy (LLLT) is considered a predictable technique to reduce the inflammation and pain and improve the tissue healing. The aim of this study is to evaluate the effect of Diode laser (EG Laser, DMT srl, Lissone, Italy) to stimulate the tissue healing.

**Methods:** a 32-year-old healthy male patient was referred to the Dentistry Department of San Raffaele Hospital (Milan). He came demanding an aesthetic improvement of his upper anterior arch, refusing any orthodontic treatment. After clinical and radiological evaluation, a treatment plan was proposed through a digital design; then an optical impression was taken. A case study was made using a CAD wax-up and mock-up based on the digital analysis of photos of the patient, made by using 3D LYNX Software (Smile Lynx, 3D LYNX srl, Varese). A dental minimally invasive preparation was performed. After that, a laser gingivectomy was performed in the vestibular side

of the elements 1.2 and 2.2. In this case LLLT was used to achieve an optimization of soft tissue healing, using Diode Laser (EG Laser, DMT, Lissone, Italy). The adhesive cementation of CAD-CAM lithium disilicate veneers was performed. The patient was introduced into a maintenance program.

**Results:** the bio-stimulation protocol allowed us to obtain an excellent management of the pain symptomatology in the post-operative phase, to improve the tissue healing and it is a minimally invasive treatment for the patient. After 3 years of follow-up, it is possible to observe that the prosthetic rehabilitation is well-accepted and integrated with oral and facial structure of the patient.

**Conclusion:** the laser is a predictable tool in clinical dental practice, it is very precise and atraumatic. Laser can modulate biological tissue processes. It represents an optimal treatment option for minimally invasive aesthetic rehabilitation.

## FATIGUE RESISTANCE OF INTERIM RESTORATIONS: COMPARISON OF CAD/CAM AND 3D-PRINTING

Marchesi G.<sup>1</sup>, Furlan D.<sup>1</sup>, Buda M.<sup>2</sup>, Di Lenarda R.<sup>1</sup>, Cadenaro M.<sup>1</sup>, Turco G.<sup>1</sup>

<sup>1</sup>Department of Medical Sciences, University of Trieste, Trieste, Italy

<sup>2</sup>Private Practice, Treviso, Italy

**Aim:** additive manufacturing (AM) technologies can be used to fabricate 3D-printed interim restorations in dentistry. However, evidence of their performance is lacking. The purpose of this study was to compare the fatigue resistance of 3-teeth interim resin restorations made by 3D printing with those obtained from polymethylmethacrylate (PMMA) blocks using a CAD/CAM system.

**Methods:** a titanium master model for 3-teeth fixed dental prostheses (FDPs) (abutment teeth 45 and 47) was manufactured. The master model was scanned and 14 FDPs were fabricated using respectively: group 1 (N = 7): CAD/CAM + BreCAM HIPC-Bredent (BH); group 2 (N = 7): 3D printing + Temporis-DWS (T). The FDPs were cemented on the titanium ma-

ster model with a provisional cement (Temp Bond, Kerr) and submitted to a 5-step incremental cyclic isometric loading: step 1: 5.000 cycles at 10 Hz with 200 N compressive load; steps 2 to 5: 30.000 cycles at 3Hz with a compressive load respectively of 400 N, 600 N, 800 N and 950 N. The 2 groups were compared using the life table survival analysis and t-test.

**Results:** only 5 specimens of group 1 (BH) survived the entire fatigue process and two specimens failed during step 5 (i.e. 950 N). Four specimens of group 2 (T) failed during step 3 (600 N) and three specimens failed during step 4 (800 N).

**Conclusion:** PMMA CAD/CAM fabricated interim restorations showed higher mechanical resistance if compared to the ones produced *via* 3D printing.

## HYDROPHILIC SILICON CARBIDE NANOWIRES AS A BONE TISSUE ENGINEERING CANDIDATE BIOMATERIAL

Ghezzi B.<sup>1,2</sup>, Toffoli A.<sup>1,2</sup>, Attolini G.<sup>3</sup>, Parisi L.<sup>1,2,4</sup>, Rossi F.<sup>3</sup>, Lagonegro P.<sup>5</sup>, Meglioli M.<sup>1,2</sup>, Macaluso G.M.<sup>1,2,3</sup>

<sup>1</sup>University Center of Dentistry, University of Parma, Parma, Italy

<sup>2</sup>Department of Medicine and Surgery, University of Parma, Parma, Italy

<sup>3</sup>MEM-CNR Institute, Parma, Italy

<sup>4</sup>Laboratory for Oral Molecular Biology, Department of Orthodontics and Dentofacial Orthopedics, School of Dental Medicine, University of Bern, Bern, Switzerland

<sup>5</sup>SCITEC-CNR, Giulio Natta Institute of Chemical Sciences and Technologies, Milan, Italy

**Aim:** many evidences show the importance of biomaterial micro- and nano-topography on cellular adhesion, proliferation and differentiation, and hence, tissue regeneration. In this context, nanomaterials play a pivotal role, due to their peculiar biological properties they reach at the nanometric size. Literature shows that nanowires (NWs) can mimic many different tissues as a result of their shape and their surface characteristics. Moreover, surface hydrophilicity affects the early stage of protein adsorption and consequently cell adhesion. Therefore, the objective of this study is to design a biomaterial by combining optimal surface topography and hydrophilicity, in order to favour bone regeneration.

**Methods:** silicon carbide (SiC) and core/shell silicon carbide/silicon dioxide (SiC/SiO<sub>x</sub>) nanowires have been synthesized by CVD and their wettability has been enhanced through a hydrogen plasma treatment (PT). Osteoblastic cell behavior has been

evaluated in terms of cell metabolic activity, viability, morphology and focal adhesions formation.

**Results:** hydrogen plasma treatment drastically enhanced SiC NWs hydrophilicity. Osteoblasts appeared to be healthy on all the tested samples. Interestingly, both SiC NWs and SiC/SiO<sub>x</sub> NWs after PT favor the formation of more elongated focal adhesions with a more homogeneous localization around the cell body, if compared to samples without PT. Moreover, osteoblasts grown on hydrogen plasma treated SiC/SiO<sub>x</sub> NWs showed an increased metabolic activity testified by a significantly higher cell number.

**Conclusion:** taken together our data underline how hydrogen PT of SiC and SiC/SiO<sub>x</sub> NWs favor osteoblasts adhesion through the enhancement of NWs wettability. We are therefore suggesting that hydrogen plasma treatment of SiC/SiO<sub>x</sub> can offer a suitable method to develop scaffolds for bone tissue engineering applications.

## NANOTECHNOLOGY IN CLINICAL DENTISTRY: A MINI REVIEW

Monterubbianesi R., Tosco V., Orilisi G., Vitiello F., Catellani A., Procaccini M., Putignano A., Orsini G.

Department of Clinical Sciences and Stomatology, Polytechnic University of Marche, Ancona, Italy

**Aim:** this mini review describes nanotechnological application in clinical dentistry, highlighting its role in preventive, restorative and regenerative procedures.

**Methods:** the review was conducted using PubMed, Web of Science, Cochrane Library, Scopus, Google Scholar databases.

**Results:** modern nanotools may improve preventive strategies and implement diagnosis of dental diseases. Possible tricks include biochips attached to tooth surface: small devices made of innovative materials like graphene, are able to release active substances and to have miniaturized test sites (microarrays), investigating a variety of bacteria colonizing the oral cavity. They may predict caries formation and patient's risk of periodontal disease, personalizing treatment plans. In restorative dentistry, nanogels can improve longevity of adhesive resin-dentin interface, protecting the collagen fibers against the degradation exerted by endogenous matrix metalloproteinases.

The incorporation of new nanofillers and nanoparticles (based on zinc oxide, silver, graphene and polyethyleneimine) into resin-based materials may improve their physical and bioactive properties (including antibacterial and remineralization activities). The nanotechnology also allows a significant improvement in regenerative dentistry. For instance, it can provide unique 3D matrix conditions for cells and tissues and may produce novel nanoengineered scaffolds with enhanced intrinsic mechanical properties. Furthermore, biological proteins and active molecules can be integrated within the biomaterials at nanoscale level to exert therapeutic efficacy and to spatially control the cellular behaviour.

**Conclusion:** while research studies and extensive clinical validation are needed, the recent and ongoing development of nanoinnovations can be a valuable tool for improving all types of dental treatments in the near future.

## CYTOTOXIC EFFECTS OF COMPOSITE RESINS ON GINGIVAL FIBROBLASTS

Nardi M.G., Beltrami R., Rizzo K., Viola M., Spinelli A., Pellegrini M.

Department of Clinical-Surgical, Diagnostic and Pediatric Sciences, Section of Dentistry, University of Pavia, Pavia, Italy

**Aim:** this study aims to evaluate and compare the cytotoxic effects of eight composite resins on immortalized human gingival fibroblasts over a period of 48 and 72 hours.

**Methods:** immortalized human gingival fibroblast-1 HGF-1 (ATCC CRL-2014) were incubated. Composites were placed into sterile, cylindrical Teflon molds. The extraction was made eluting the composites in cell culture medium. Cells ( $1 \times 10^4$ ) were seeded in each well of a 96-well plate and incubated for 24 hours at 37°C, then exposed to 100  $\mu$ L of the extracts medium to calculate the percentage of viable cells relative to control cells set to 100%. Data observed were not normally distributed and non-parametric statistical methods were used for statistical analysis. Wilcoxon test was used for intragroup

comparison while Kruskal Wallis for intergroup multiple comparisons ( $p$ -value  $< 0.05$ ).

**Results:** Omnichroma, Omnichroma blocker, Admira Fusion x-tra and Enamel Plus HRI Bio function Enamel resulted non or mildly cytotoxic. The other ones resulted moderately cytotoxic, except for Enamel Plus HRI that resulted severely cytotoxic after 48 and 72 hours.

**Conclusion:** composite resins contain monomers with cytotoxic properties.

BisGMA, TEGDMA and UDMA have inhibitory effects and induce apoptotic proteins in pulp fibroblast. Composite resins with fewer unbound free monomers and that release less ions show higher biocompatibility *in vitro*.

## A MODERN ANALYTICAL APPROACH TO EVALUATE HUMAN DENTAL ENAMEL AFTER BLEACHING TREATMENT

Orlissi G.<sup>1</sup>, Tosco V.<sup>1</sup>, Monterubbiansi R.<sup>1</sup>, Notarstefano V.<sup>2</sup>, Procaccini M.<sup>1</sup>, Özcan M.<sup>3</sup>, Putignano A.<sup>1</sup>, Orsini G.<sup>1</sup>

<sup>1</sup>Department of Clinical Sciences and Stomatology, Polytechnic University of Marche, Ancona, Italy

<sup>2</sup>Department of Life and Environmental Sciences, Polytechnic University of Marche, Ancona, Italy

<sup>3</sup>Division of Dental Biomaterials, Center for Dental and Oral Medicine, Clinic for Reconstructive Dentistry, University of Zurich, Zurich, Switzerland

**Aim:** this study evaluates the chemical, elemental and morphological changes on human dental enamel after treatment using different bleaching agents, containing hydrogen peroxide with nanohydroxyapatite or carbamide peroxide.

**Methods:** the bleaching agents (BioWhiten, Biodent Ltd., Turkey), loaded with nano-hydroxyapatite (nHA) and containing either 6%, or 12% or 18% of hydrogen peroxide (HP), and a whitening gel (White Dental Beauty, Novon, West Yorkshire, UK) containing 10% of carbamide peroxide (CP), were tested. Fifteen sound human third molars were divided into the five following groups (n = 3): CTRL (untreated samples); G1 (6% HP for 50 min/day for 7 days); G2 (12% HP for 10 mins/5 times); G3 (18% HP for 10 mins/5 times); G4 (10% CP 2 h/day for 7 days). Enamel microstructure was evaluated by Attenua-

ted Total Reflectance-Fourier Transform Infrared Spectroscopy (ATR-FTIR), Scanning Electron Microscopy (SEM) and Energy Dispersive X-ray Spectroscopy (EDS).

**Results:** no significant differences were detected in the spectral profile of CTRL, G1 and G2; an increased amount of organic matter was found in G3, while G4 displayed an intermediate behavior. SE micrographs revealed a slight increase of enamel irregularities in G2, while G3 displayed a partial removal of the aprismatic layer; G1, G4 and CTRL showed a similar pattern. In all groups, EDS identified slight changes in O and Ca concentrations, while Ca/P ratio was similar to CTRL.

**Conclusion:** the use of the tested bleaching agents, containing HP up to 12% and CP at 10%, does not alter the morphological and chemical composition of the enamel surface.

## DIGITAL ANALYSIS OF THE APPROPRIATE OFFSET FOR 3D PRINTED OCCLUSAL SPLINTS (CAD-CAM)

Peters A.<sup>1</sup>, Ronsivalle V.<sup>1</sup>, Isola G.<sup>1</sup>, Lacagnina C.<sup>1</sup>, Lo Giudice A.<sup>1</sup>, Fichera G.<sup>1</sup>

Department of Orthodontics, University of Catania, Catania, Italy

**Aim:** the aim of the present study was to assess the fitting of prototyped splints digitally designed with different offset and generated with two different bio-compatible resins.

**Methods:** the sample consisted of ten dental digital models, on which occlusal splint designed with different offset values (0.0-mm, 0.05-mm, 0.10-mm, 0.15-mm, 0.20-mm and 0.25-mm). Each splint was 3d printed using two different bio-compatible resins and the airspace between the splint and the teeth was recorded by placing impression material. A specific 3d technology was used to assess the volume of the airspace between the splint and the teeth and to calculate the euclidean distance between the surface points of two digital models, with and without the airspace volume. The one-way analysis of variance (ANOVA) was used to assess if the volumetric values of airspace and deviation analysis were different among the tested splints (different offsets), in both groups of resins used.

Independent Student's t tests was also performed to compare the same outcomes between the splints printed with different resins, for each offset tested.

**Results:** the splints with 0.20-mm offset showed lower values of airspace and deviation analysis compared with the 0.15-mm and 0.25-mm splints, being these results consistent with both types of biocompatible resins used. The values of airspace and deviation analysis did not significantly differ between the splints printed with two different resins, for each offset tested. Excellent correlation was found between the two intra-operator readings with values of ICC ranging from 0,921 to 0,974 for volumetric data and from 0,943 to 0,982 for data of deviation analysis.

**Conclusion:** according to the present findings, the 0.20-mm offset would be the best choice when digitally designing occlusal appliances.

## BIOLOGICAL AND MECHANICAL BEHAVIORS OF ZLS IN CAD-CAM SYSTEMS: A SCOPING REVIEW

Ruggiero G., Sorrentino R., Zarone F.

Department of Neurosciences, Reproductive and Odontostomatological Sciences, Division of Prosthodontics and Digital Dentistry, University Federico II, Naples, Italy

**Aim:** to provide a scoping review of the mechanical and biological properties of zirconia-reinforced lithium silicate glass-ceramics (ZLS) in CAD-CAM systems.

**Methods:** a literature search for papers related to ZLS was made on the databases of PubMed/Medline, Scopus, Embase, Google Scholar, Dynamed, and Open Grey. The literature search was performed using combinations of the keywords “zirconia-reinforced lithium silicate” OR “ZLS”.

**Results:** 71 papers were included. After reviewing the included records, it was found that two types of ZLS are nowadays available on the market for CAD-CAM systems, similar in their chemical composition, microstructure, and biological-mechanical

properties. ZLS is reported to be a biocompatible material, whose fracture resistance can withstand physiological chewing loads. The firing process influences the improvements of strength and fatigue failure load, with a volumetric shrinkage. To date, ZLS can be considered a viable alternative to other glass-ceramics for fixed single restorations.

**Conclusion:** as to biocompatibility and mechanical behaviors of ZLS, data are still limited, often controversial and limited to short-term observational periods. These promising ceramics require further studies to define mechanical and biological behaviors, particularly in the long-term performance of restorations produced with such materials.

## WEAR, OPTICAL PROPERTIES, ADHESION AND CLINICAL INDICATIONS OF ZLS: A SCOPING REVIEW

Ruggiero G., Sorrentino R., Zarone F.

Department of Neurosciences, Reproductive and Odontostomatological Sciences, Division of Prosthodontics and Digital Dentistry, University of Naples Federico II, Naples, Italy

**Aim:** the present scoping review aimed to shed light on optical properties, wear, adhesion, and clinical indications concerning the use of zirconia-reinforced lithium silicate glass-ceramics (ZLS) in CAD-CAM systems.

**Methods:** an extensive search of the literature for papers related to ZLS was made on the databases of PubMed/Medline, Scopus, Embase, Google Scholar, and Dynamed. The literature search was performed using combinations of the keywords: “zirconia-reinforced lithium silicate” OR “ZLS”. 98 papers were included after the deletion of duplicates and the removal of records that did not meet the inclusion criteria.

**Results:** despite the promising microstructure characteristics of ZLS, improved optical properties and increased translucency compared to lithium-disilicate (LS<sub>2</sub>) have not proven, although acceptable color changes were reported. Machinability and

handling were reported to be harder and less advantageous for ZLS than LS<sub>2</sub>; mechanical polishing was the most effective method to reduce surface roughness. Conventional acid etching procedures were reported to be effective in conditioning ZLS surface but no univocal protocol has been established yet; silane-coupling and dual-curing resin cements were strongly recommended. The mechanical and esthetic characteristics allow treating ZLS as a promising material for single-unit fixed CAD-CAM-based restorations onto both natural teeth and implants.

**Conclusion:** as to translucency, adhesion systems, wear and clinical performance of ZLS, data are still limited, often controversial and related to short-term observational periods. Further *in vitro* and *in vivo* studies are needed to define the optical and wear behaviors, adhesion and clinical performance of these ceramics.

## STUDY ON THE BIOCOMPATIBILITY AND ANTIBIOFILM PROPERTIES OF CALCIUM SILICATE-BASED CEMENTS

Salucci A., Silvestri S., Perrone A., Battaglia E., Iaculli F., Di Giorgio G.

Department of Oral and Maxillo-Facial Sciences, "Sapienza" University of Rome, Rome, Italy; Unit of Pediatric Dentistry, Director: Prof.ssa A. Polimeni, Postgraduate School of Pediatric Dentistry, Director: Prof. M. Bossù

**Aim:** the aim of this study was to evaluate *in vitro* the biocompatibility and antibiofilm properties of two bioactive cements mostly used in dentistry, especially in the endodontic field.

**Methods:** samples of two cements, ProRoot MTA (Dentsply Sirona, York, PA, USA) and Biodentine (Septodont, Saint-Maur-des-Fossés, Francia), were produced according to the instructions of the manufacturers. Human osteosarcoma cells (Saos-2) were cultured on both cements' specimens or in the presence of their extracts. To assess biocompatibility and cell viability MTT assay was performed. Moreover, ROS production was investigated and immunofluorescence analysis and morphological evaluations through VP-SEM imaging were conducted. The antibiofilm capacity of the two cements was also evaluated using *S. mutans* strains.

**Results:** the biocompatibility investigation obtained by MTT assay demonstrated that ProRoot MTA exhibited a greater cell viability than Biodentine. Both materials were responsible for a dose-dependent increase in oxidative stress in Saos-2 cells, although this appeared to be greater for cells exposed to Biodentine than to ProRoot MTA. The immunofluorescence analysis showed improvement of cytoskeletal status and focal adhesions in a better way for the ProRoot MTA samples. The VP-SEM analysis of Saos-2 cells revealed that they were more adherent to the ProRoot MTA disc surfaces than to Biodentine ones. In addition, ProRoot MTA demonstrated improved antibiofilm properties.

**Conclusion:** both materials showed biocompatibility and exhibited similar antibacterial activity, although the ProRoot MTA seemed to demonstrate superior performances.

## STANNOUS FLUORIDE EFFECTS ON ENAMEL: A SYSTEMATIC REVIEW

Scoglio C.M.R.<sup>1</sup>, Fiorillo L.<sup>1,2</sup>, Gorassini F.<sup>1</sup>, Gambino D.<sup>1</sup>, Mastroieni R.<sup>1</sup>, D'Amico C.<sup>1</sup>, Cervino G.<sup>1</sup>, Cicciù M.<sup>1</sup>

<sup>1</sup>Department of Biomedical and Dental Sciences, Morphological and Functional Images, School of Dentistry, University of Messina, Messina, Italy

<sup>2</sup>Multidisciplinary Department of Medical-Surgical and Odontostomatological Specialties, University of Campania Luigi Vanvitelli, Caserta, Italy

Toothpaste is used in maintaining oral and tooth health and aesthetics. Its functions concern: food removal from teeth, halitosis elimination or masking, gum and dental disease prevention. Toothpaste could be a vehicle of active molecules that are applied to dental surfaces, so as to enhance their effect. Fluoride, in various forms, is the most popular active ingredient for the prevention of tooth decay in toothpastes. Stannous fluoride adheres to the surface of tooth enamel and form a protective layer that is able to shield from the effects of erosive acids. The aim of this review is to highlight all the clinical features concerning stannous fluoride reported in literature. The literature analysis of the last 10 years shows more than 800 results,

but applying the inclusion/exclusion criteria, and following a manual analysis of the results, 26 manuscripts have been included in this review. From results analysis, it could be shown that stannous fluoride does not present important contraindications, if not those commonly reported for fluorine. A meta-analysis conducted on enamel loss shows that SnF<sub>2</sub> products provide better results with a  $p < 0.05$  value than product with the absence of SnF<sub>2</sub>. This compound has demonstrated different functions; it could have significant effects in favour of the enamel erosion and recalcification, on the biofilm formation, gum inflammation and might be an important aid in tooth stains and halitosis removal.

## MICROLEAKAGE STUDY OF THREE DIFFERENT ADHESIVE-RESIN COMPOSITE COMBINATIONS

Zucca G., Karafili D., Verniani G., Ferrari M.

Department of Medical Biotechnology, University of Siena, Siena, Italy

**Objectives:** the aim was to evaluate the influence of several adhesive systems on the microleakage of direct composite restorations with one proximal margin located below the cemento-enamel junction (CEJ) and the other above in the enamel.

**Methods:** standardized MOD cavities with proximal margins located 1mm below CEJ were prepared in 30 human molars and randomly divided into 3 groups. Three adhesive systems were combined with an injectable resin composite (G-aenial Universal Injectable). An incremental technique was followed to restore the cavities. In Group 1 G2-BOND Universal (GC), in Group 2 Clearfil SE Bond 2 (Kuraray) and in Group 3 OptiBond FL (Kerr) were used. Sample teeth were tested for microleakage scoring the amount of tracer (Silver nitrate) along the marginal interfaces in 5 degrees.

**Results:** at the dentin interfaces Group 1 scored 1,3, Group 2 2,3 and Group 3 1,3.

At the enamel site Group 1 scored 0, Group 2 0,2 and Group 3 0,1. Differences in leakage at dentin and enamel adhesive interfaces were also evaluated for statistical significance ( $P < 0.05$ ). At the dentin interface statistically significant differences emerged in microleakage scores between Group 2 and the other two groups whilst no difference was found at the enamel interface.

**Conclusion:** the G2-BOND Universal showed the best marginal seal, similarly to OptiBond FL in both dentin and enamel interfaces.

The enamel interfaces showed an extremely good seal whilst the dentin interfaces always showed leakage.

## IMMEDIATE LOADING OF A POSTEXTRACTIVE IMPLANT WITH A FULL DIGITAL WORKFLOW: A CASE REPORT

Arcuri L.<sup>1</sup>, De Vico G.<sup>2</sup>, Refoni G.<sup>3</sup>, Galli M.<sup>4</sup>, Barlattani A.<sup>5</sup>

<sup>1</sup>Oral Surgery School Resident Sapienza University of Rome, Rome, Italy

<sup>2</sup>Private Practice, Rome, Italy

<sup>3</sup>Master Dental Technician, Rome, Italy

<sup>4</sup>Sapienza University of Rome, Rome, Italy

<sup>5</sup>Tor Vergata University of Rome, Rome, Italy

**Aim:** to show a clinical case of anterior single gap implant-prosthetic rehabilitation managed by means of a full digital workflow from implant planning to prosthetic finalization.

**Methods:** a 60 years old patient came to our attention to replace the right upper central incisor (FDI 1.1) because of the fracture of the residual root. Cone beam computed tomography and intraoral scanning (IOS) were acquired and merged together into a dedicated planning software. A tooth supported surgical guide was digitally created and 3D printed. The day of the surgery the patient received 2 g of amoxicillin 1 h before the intervention and rinsed with chlorhexidine 0.2% for 1 min prior to the intervention. After local anesthesia was executed, tooth 2.1 was atraumatically extracted and the drilling sequence (pilot drill 2 mm, twist step drills 2.4/2.8, 2.8/3.2, 3.2/3.6, mm) was performed through the surgical template performing implant site underpreparation. A

4.3 X 13 mm self-tapping implant was placed with a torque > 45 N/cm and loaded with a screw-retained temporary restoration. After 3 months of soft tissue conditioning definitive impression was taken by means of IOS, including the shape of the temporary restoration and the transmucosal path. A screw-retained Cobalt-Chrome Cad-Cam structure was ceramic layered on a 3D printed model and placed intraorally (Odt. Donati C.- Minelli T.).

**Results:** at 1 year follow-up no biological nor mechanical complications were noticed and the patient was fully satisfied about the esthetic result.

**Conclusion:** the application of cutting edge technologies of digital dentistry both in the surgical and prosthetic field made it possible to manage a complex esthetic case with less time spent chairside, less morbidity for the patient and with a fast and detailed communication between clinician and dental technician.

## DIGITAL FLASH FREE BONDING: EVALUATION OF THE TRANSFER TRAY ACCURACY ON A CASE REPORT

Caldara G.<sup>1</sup>, Mandelli A.<sup>2</sup>, Mandelli G.<sup>2</sup>, Fiorillo G.<sup>2</sup>, Gastaldi G.<sup>2</sup>

Department of Dentistry, Director Prof. E. Gherlone, Vita Salute San Raffaele University, Milan, Italy

<sup>1</sup>Master's Degree Course in Dentistry and Dental Prosthetics, President: Prof. O. Cremona, Vita-Salute San Raffaele University of Milan, Milan, Italy

<sup>2</sup>School of Specialization in Orthodontics, Director: Prof. G. Gastaldi, Vita-Salute San Raffaele University of Milan, Milan, Italy

**Aim:** the aim of the present study was to assess the precision of a digitally planned indirect bonding procedure based on the use of a cad-cam 3D printed individual transfer tray.

**Methods:** a single patient was enrolled in the study and served as reference model for the evaluation. Both upper and lower arches were scanned with intraoral scanner (Trios 3 Shape) by the orthodontist. Digital flash free bonding was then planned by positioning brackets on digital models using Ortho Analyzer (3Shape) software. The tray for the indirect bonding was 3D printed using a biocompatible resin and adhesive pre-coated (APC) flash free brackets (3M) were placed into it. Superimpositions were made between the digital model obtained after indirect bonding and the STL file obtained from the original virtual setup. To analyze the differences in bracket positions a colorimetric evaluation with a corresponding quantitative value was made using Ortho Analyzer (3Shape) software.

**Results:** the colorimetric evaluation showed a 0 +/- 0.3 mm precision outcome (yellow range of the colorimetric evaluation). The only exception was in the pin areas of the brackets where the precision was in the red range, with a discrepancy of 2 mm or more. The reason why it happened is that the virtual setup showed brackets without undercuts, therefore the shape is not perfectly the same as bonded brackets detected with the intraoral scanner.

**Conclusion:** the reproducibility of digital flash free bonding was confirmed in terms of brackets positions using an individual 3D printed transfer tray because each bracket showed accuracy in both the vertical, horizontal and axial planes. APC flash free brackets without excesses of composite prevent the clinician from moving the bracket from the position virtually planned so they are suitable for digital bonding.

## RESTORATIONS WITH DIGITAL CAD/CAM COMPOSITE CHAIRSIDE WORKFLOW: A CLINICAL CASE

Del Bianco F.<sup>1</sup>, Florenzano F.<sup>1</sup>, Josic U.<sup>1</sup>, Mancuso E.<sup>1</sup>, Maravic T.<sup>1</sup>, Comba A.<sup>2</sup>, Mazzitelli C.<sup>1</sup>, Mazzoni A.<sup>1</sup>, Breschi L.<sup>1</sup>

<sup>1</sup>DIBINEM, University of Bologna Alma Mater Studiorum, Bologna, Italy

<sup>2</sup>Department of Surgical Sciences, Dental School, Cariology and Operative Dentistry, University of Turin, Turin, Italy

**Aim:** semi-indirect CAD/CAM composite restorations are presented and documented step-by-step.

**Methods:** a 47-yr woman was visited due to strong sensitivity in the IV sextant with 3.6 suffering pain on percussion. Medical history was negative. Radiographic and clinical inspection revealed previous dental treatments with secondary caries of 3.5-3.7 and pulpitis of 3.6. After the endodontic treatment of 3.6, indirect CAD/CAM composite restorations (Bredent) were proposed. Teeth were prepared and finished with diamond burs (medium- and fine-grit, respectively). Intraoral scans of the upper and lower dental arches and of the occlusion were taken. The internal surface of the composite restorations was sandblasted with 50 µm AL<sub>2</sub>O<sub>3</sub> (5 cm distant for 10s), cleaned in alcohol solution in an ultrasonic bath for 1 min, a silane coupling agent was applied (5

min) and the adhesive (Optibond FL, Kerr) was applied and left unpolymerized. After rubber dam isolation, the teeth were cleaned with water-pumice, sandblasted and the adhesive was applied and polymerized for 20s. Luting procedures were performed with a pre-heated resin composite (Filtek Supreme, 3M). After finishing and polishing, occlusal, and radiographic checks were made.

**Results:** after 16 months, no fractures, discoloration, secondary caries, or pain were reported. Rx showed no signs of periapical inflammatory processes.

**Conclusion:** semi-direct composite restorations are a valid option in cases where cuspal coverage is needed. Digital CAD/CAM chairside workflow makes restorative procedures faster, predictable, and easier than traditional protocols.

## DIGITAL TECHNOLOGIES IN COMPLETE REMOVABLE DENTURE: A CASE SERIES

Evangelisti S., Pietrantonio M., Ausiello P., Epifania E.

Department of Neuroscience, Reproductive and Odontostomatological Sciences, University of Naples Federico II, Naples, Italy

**Aim:** complete removable denture has been the last prosthetic procedure to follow the digitization because of drawbacks into the intraoral scans of edentulous arches; in addition, it is impossible to record muco-compressive impressions through IOS. So, a full digital procedure is not yet conceivable.

We considered the possibility of an “hybrid” protocol thanks to a specific software. The hybrid protocol requires traditional techniques for the anatomical impression followed by laboratory scan of casts and wax.

**Methods:** the software consists in two synergic programs:

- Ruthinium Digital Preview allows to have a picture of the prosthetic project and change it previously, thanks to two calibrated photographs.

- Ruthinium Denture Guide is a 3D software that helps laboratory work into denture production, particularly to a correct setting of acrylic teeth. The planned dental setting is printed in a template. Template and base plate, both 3D printed, are connected thanks to a structure that ensures the designed occlusal scheme.

**Results:** the collected clinical cases did not allow a statistic analysis about patient and clinical satisfaction through evaluation questionnaires.

**Conclusion:** it looks like that patients appreciate the prosthetic rehabilitation previsualization and in particular being actively involved in aesthetic choices. Clinically, it appears to be a shorter need for touch-ups at the last appointment; probably because of the 3D tooth position planning.

## OCCUSAL PLANE VARIATION WITH CLEAR ALIGNERS AND CORRELATION WITH PATIENT DIVERGENCE

Fanelli C., Guida L., Cazzolla A.P., Illuzzi G., Laurenziello M., Suriano C., Ciavarella D.

Department of Clinical and Experimental Medicine, University of Foggia, Foggia, Italy

**Aim:** the aim of this study is to analyze the variation of the occlusal plane after orthodontic therapy with clear aligners and the possible correlation between this variation and the degree of divergence of a patient.

**Methods:** twenty-two patients were treated with clear aligners for approximately 12 months. Intraoral scans were taken at the beginning and the end of treatment. Using Autodesk Fusion 360 software, a palatine plane and an occlusal plane were drawn on STL files of the maxillary arches. The bisector of the angle formed by the above planes was delineated. At a standardized point on the bisector, a perpendicular was passed and intersected both the palatine and occlusal planes to define the linear distance of the study. The divergence angles were measured: SN-GoMe, PP-PM, PP-PO, PO-PM. The Spearman correlation coefficient ( $\rho$ ) existing between the variation of the distance and the divergence angles was calculated.

**Results:** the difference in the estimated averages of the occlusal and palatine planes distances before and after treatment with clear aligners is:

- 1.062 mm in hyperdivergent patients;

- 1.627 mm in hypodivergent patients.

In hyperdivergent patients  $\rho$  is:

- 0.5 between  $\Delta$ hyper and SN-GoMe;

- -0.5 between  $\Delta$ hyper and PP-PO and between hyper and PP-PM;

- 0.866 between  $\Delta$ hyper and PO-PM.

In hypodivergent patients  $\rho$  is:

- -0.4 between  $\Delta$ hypo and SN-GoMe and between hypo and PO-PM;

- 0.4 between  $\Delta$ hypo and PP-PO;

- -0.2 between  $\Delta$ hypo and PP-PM.

**Conclusion:** the distance between the occlusal and palatine planes increases in both hyperdivergent and hypodivergent patients, especially in the latter.

The correlation with Go-Me divergence angle is low. In hyperdivergent patients, there is a strong correlation between the variation of the occlusal plane related to the palatine plane and the angle between PO-PM.

## A DIGITAL WORK-FLOW FOR THE CONSTRUCTION OF MAXILLARY SKELETAL EXPANDER FROM CBCT SCANS

Lacagnina C., Ronsivalle V., Fichera G., Venticinquè V., Bennici O., Leonardi R., Lo Giudice A.

Department of Orthodontics, University of Catania, Catania, Italy

**Aim:** maxillary Skeletal Expander (MSE) is a particular device characterized by the engagement of four miniscrews in the palatal and nasal cortical bone layers to achieve the skeletal opening of the midpalatal suture in late adolescents and adults. In this manuscript, we described a user-friendly digital workflow which can provide the predictable placement of maxillary skeletal expander (MSE) appliance according to the patient's anatomical characteristics and the construction of a positional template of the MSE that allows technician to realize the MSE according to the virtual project planned by the orthodontist on the CBCT DICOM file. We also described a case report of an adult female patient affected by skeletal transversal maxillary deficiency treated with MSE appliance that was projected according to the described workflow.

**Methods:** a 25 years old female featured maxillary transversal deficiency with mandibular shift toward cross-bite side (right).

The digital workflow included the CBCT examination, the construction of positional template of the MSE using TINKERCAD software, the virtual placement of MSE (negative template) using Dolphin 3D software and the construction of the final prototyped lab template.

**Results:** evaluation of the effectiveness of the skeletal maxillary expansion procedure was performed two weeks later. Intraoral inspection showed resolution of the posterior cross-bite at the right side and the appearance of the diastema between maxillary central incisors, which confirmed a skeletal opening of the midpalatal suture.

**Conclusion:** the present user-friendly digital workflow can provide a predictable placement of the MSE appliance, according to bone characteristics of the palate region. It can be also an interesting tool to enhance the communication between the orthodontists and lab technicians for the construction of the MSE.

## ACCURACY OF INTRAORAL SCANNERS: ARE SCANNING STRATEGIES OPERATOR-SENSITIVE?

Aquilanti L.<sup>1</sup>, Mascitti M.<sup>1</sup>, Santarelli A.<sup>1,2</sup>, Lattanzi F.<sup>1</sup>, Rappelli G.<sup>1,2</sup>

<sup>1</sup>Department of Clinical Specialistic and Dental Sciences, Polytechnic University of Marche, Ancona, Italy

<sup>2</sup>Dentistry Clinic, National Institute of Health and Science of Ageing, IRCCS INRCA, Ancona, Italy

**Aim:** the aims of the study were to evaluate the accuracy of different scanning techniques and to verify if scanning techniques are operator sensitive.

**Methods:** a custom upper maxillary dental arch model was scanned by an industrial high-resolution scanner and used as reference cast. Two intraoral scanner setups were used: Omnicam (OC) and Primescan (PS). Complete dental arch (CDA) was scanned 10 times per group, using two scanning techniques: manufacturer suggested scanning strategy and a clinically used technique. Scans were performed by an expert operator (EO) and a no-experienced (NE) one, using the manufacturer suggested scanning strategy. A chronometer was used to assess scanning time. All the scans were digitally compared to the reference.

**Results:** statistically significant differences were found between scans performed using OC and PS, PS scans using manufacturer suggested scanning strategy and clinically used technique and scanning time between EO and NE ( $p < 0.01$ ). Accuracy values ranged from  $6 \pm 7 \mu\text{m}$  (PS-EO) to  $19 \pm 17 \mu\text{m}$  (PS-NE) and from  $31 \pm 25 \mu\text{m}$  (OC-EO) to  $21 \pm 24 \mu\text{m}$  (OC-NE). Using the clinical technique, accuracy ranged from  $28 \pm 28 \mu\text{m}$  (OC-EO) to  $-12 \pm 11 \mu\text{m}$  (PS-EO). Scanning times varied from  $206.4 \pm 18.9 \text{ s}$  (OC-EO) to  $268.1 \pm 22.1 \text{ s}$  (OC-NE) and from  $176.6 \pm 26.1 \text{ s}$  (PS-EO) to  $215.0 \pm 11.8 \text{ s}$  (PS-NE).

**Conclusion:** PS was more accurate than OC in scanning CDA. Manufacturer scanning strategy was more accurate than the clinical used one. NE spent more time in scanning CDA than EO, but scans accuracy did not differ statistically from the ones of EO.

## ROLE OF TELEMEDICINE IN ORAL PREVENTION: ROLE OF THE DENTAL HYGIENIST

Leocov R.A., Guaragna M., Preite C., Luzzi V.

Department of Odontostomatological and Maxillofacial, Sciences Unit of Pediatric Dentistry, Director: Prof. A. Polimeni, Sapienza University of Rome, Rome, Italy

**Aim:** nowadays technology accompanies the daily life of people in all its facets, being used also in the field of medicine, under the name of telemedicine. Teledentistry, a branch of telemedicine, is the use of various technological tools in dentistry by dental professionals, such as the dental hygienist, the professional figure in the dental field that deals with the prevention of oral-dental pathologies of the individual or of a community.

**Methods:** a review of the literature on pediatric dentistry, oral prevention and the usefulness of the use of teledentistry by the dental hygienist was carried out, through a bibliographic search of articles and studies, carried out in PubMed and Google scholar.

**Results:** studies have shown that teledentistry can be useful for the dental hygienist in providing remote health services or communication with the patient, can be used for prevention in patients of various ages, having a major impact in pediatric

age, the essential period of learning of oral habits. Furthermore, the effectiveness of teledentistry is also observed in cases of health emergencies, as in the case of the COVID-19 pandemic of 2020, since the technology can facilitate the maintenance of the social distance, necessary for the elimination of the risk of infections, and remote monitoring of the dental patient by dental professionals.

**Conclusion:** from the analyzes carried out, it emerged that the use of telemedicine in the dental field can lead to facilitation and progress in the interaction between dental professionals, including the dental hygienist, and patients. The provision of oral and preventive health services can take place remotely for the dental professional, communicating “digitally” himself with the patients of any age, and for example in cases of health emergencies.

## ORTHODONTIC PATIENTS ATTITUDE TOWARDS DENTAL MONITORING® DURING COVID-19 PANDEMIC

Massetti F., Dalessandri D., Scazzero N., Laffranchi L., Bonetti S., Visconti L., Paganelli C.

School of Dentistry, Department of Medical and Surgical Specialties, Radiological Sciences, and Public Health, University of Brescia, Brescia, Italy

**Aim:** the COVID-19 pandemic has markedly influenced all dental health professionals and orthodontists. Due to nature of the COVID-19 pandemic the recommendations of numerous health government officials were to restrict in-clinic visits to only emergency patients, postpone appointments and monitor patients virtually. Specific telemonitoring systems are progressively gaining more diffusion in dentistry, together with the improvement of general population skills in new technologies utilization. Therefore the aim of this study was to analyze patients attitude towards the use of Dental Monitoring®, an app based system for orthodontic patients remote monitoring, during Covid 19 pandemic.

**Methods:** 30 patients looking for orthodontic treatment were enrolled in this cross-sectional study. Patients aged between 14 and 50 years, with absence of difficulties in Italian language and ownership of a smartphone were included. After a presentation explaining the use of Dental Monitoring system participants were asked to fill a questionnaire investigating their attitude towards remote monitoring and their opinion regarding its usefulness. Sociodemographic data were recorded and the Mann-Whitney U test and chi-square contingency tables were

utilized to analyze the effect of sex, age and smartphone ownership on telemonitoring attitude; next, a multiple regression analysis was used to estimate this effect.

**Results:** 93% of patients were not aware of the possibility to use a smartphone based monitoring system, whereas 7% had a friend using one of these systems during the orthodontic treatment. 89% of patients declared their availability to take pictures of their teeth every 2 weeks, 74% declared their availability to take pictures of their teeth every week, 97% positively judged the possibility to reduce the number of in office visits, 50% declared their availability to pay an extra fee to use Dental Monitoring® and 100% considered the use of remote monitoring systems indicative of high tech and high quality treatment. Sex and age did not influence attitude towards telemonitoring.

**Conclusion:** this study showed a positive patients' attitude towards telemonitoring, proportionally with their "digitalization" degree. A stronger patient motivation is needed if weekly monitoring is required. The reduction in visits number is especially appreciated by patients, even if they are not always oriented to pay for this extra service.

## RSS: A DIGITAL TECHNIQUE TO DETECT THE INTRASULCULAR FINISH LINE

Meglioli M.<sup>1</sup>, Zingari F.<sup>1</sup>, Gallo F.<sup>2</sup>, Lumetti S.<sup>1</sup>, Macaluso G.M.<sup>1,3</sup>, Toffoli A.<sup>1</sup>

<sup>1</sup>Center of Dental Medicine, Department of Medicine and Surgery, University of Parma, Parma, Italy

<sup>2</sup>Private Practice, Milan, Italy

<sup>3</sup>MEM-CNR, Parma, Italy

**Aim:** the Intraoral Scanners (IOS) present difficulties in reading the subgingival area, especially when a vertical preparation is present.

We introduce a novel protocol, the Reverse Subgingival Scan (RSS), to deeply read the sulcus anatomy and to obtain a master model that precisely shows the stump finish line and the transmucosal zone as conditioned by the provisional. Two software workflows are possible to perform a RSS, and we present them applied to the same clinical case.

**Methods:** RSS is possible via two different CAD software workflows (A and B), both starting from: a full arch scan of the stumps, a full arch scan with the provisional inserted and a scan of the provisional restoration. "A" involves MeshMixer

(Autodesk, USA) and Exocad (Align Technology, USA) software, while "B" uses OpticadRevenge 5.0 (Open Technologies, Italy), Plasticad (3Diemme, Italy) and Exocad. Both methods allow to refine the meshes, to align them through the "best-fit" algorithm, and to obtain the master model. We tested the workflows by producing two zirconia crowns from the master models obtained through both the workflows "A" and "B" with the same digital impressions. An *in vitro* fit test on physical model, as well as a radiological and clinical fit test were performed.

**Results:** RSS proved an adequate digital master model that allowed to produce crowns with a good fitting level, and the two methods performed equally well. A key-point of this ap-

proach is the use of the stumps as landmarks to fuse the digital datasets.

**Conclusion:** the RSS technique allows to image the gingival sulcus anatomy without the use of retraction cords, but it

should be noted that it is strictly dependent on the quality of the provisional restoration and that its application is limited to the cases in which the finish line of the final crown is at the same level or more coronal than the one of the provisional.

## ACCURACY OF PHOTOGRAMMETRY IN ACQUIRING DIGITAL DENTAL MODELS

Poscolore A., Rosolin L., Pappalardo D., Bersani M., Zotti F.

Department of Surgical Science, Pediatrics and Gynecology, University of Verona, Verona, Italy

**Aim:** purpose was to test the accuracy of photogrammetry used to obtain a digital dental model from a dental plaster model.

**Methods:** 50 photographs of a dental upper plaster model with a single butt-joint preparation were taken. The photographs were taken by a single operator using room light. Camera configuration was set at ISO 100, f32 with an exposure time of about 2.5 seconds. The images were processed using 3DF Zephir Free® software (3D Flow®, Italy). Height and width of the six anterior elements were measured as well as the transversal widths between the canines' cusp and the palatal cusps of the first premolars. Height and width of the prepared tooth were also assessed. Measurements were taken on plaster model using a caliper and on the digital models using Blender®

(Blender Foundation®, The Netherlands) by the same trained operator. Mean values from all measurements were evaluated in order to simplify calculation.

**Results:** mean difference between measurements taken on the plaster model and those taken on the digital model was  $-0,16\text{mm} \pm 0,36\text{mm}$ . There were no significant differences between plaster model measurements and digital model distances (T test:  $p > 0.05$ , Normal distribution tested by Kolgorov-Smirinov).

**Conclusion:** the photogrammetry was found to be a good method for acquiring digital dental models, although further studies are required to better evaluate its effectiveness and usability in daily clinical practice.

## DENTIST, HAVE YOU CHECKED YOUR STRESS LEVELS? MANAGEMENT OF STRESS THROUGH HRV BIOFEEDBACK

Queirolo L.<sup>1</sup>, Barjami A.<sup>1</sup>, Stellini E.<sup>1</sup>, Facco E.<sup>1,2,3</sup>, Bacci C.<sup>1</sup>, Zanette G.<sup>1</sup>

<sup>1</sup>Department of Neuroscience, Dentistry Section, University of Padua, Padua, Italy

<sup>2</sup>Science of Consciousness Research Group, Department of General Psychology, University of Padua, Padua, Italy

<sup>3</sup>Institute Franco Granone, Italian Center of Clinical & Experimental Hypnosis, Turin, Italy

**Aim:** literature demonstrates the connection between stress and dentist's profession, but it completely lacks when it comes to the use of technology in dentist's stress management. The goal of the present study is to address the efficacy of Heart Rate Variability (HRV) biofeedback in stress management.

**Methods:** single case report and analysis of literature through a narrative overview.

**Results:** wearable devices and apps allow an HRV evaluation, based on the HRV index that reflects the ability of the Central Nervous System to adapt to environmental requests through cingulo-frontal-insular vagally mediated activity. A crucial component of HRV biofeedback is the HRV index; the variation in interval between heartbeats. HRV is largely affected by re-

spiratory sinus arrhythmia that represents heart rate accelerating during inhalation and decelerating during exhalation. Thus, uniting the feedback from heartbeats intervals and breath cycle, HRV biofeedback allows the creation of a bridge between stress response and its management in dentistry profession. Voluntarily changing the breathing rate allows to modify sympathovagal balance. This theoretical perspective has met for the first time evidence in this single case study on a dentist referring being stressed.

**Conclusion:** combining the evidences from biofeedback literature with this single case report, the present work underlines the relevance of HRV biofeedback in dentist's stress evaluation and management.

## EVALUATION OF THE ACCURACY OF CNN-BASED METHOD FOR SEGMENTING THE MANDIBULAR JAW

Ronsivalle V.<sup>1</sup>, Spampinato C.<sup>1</sup>, Isola G.<sup>1</sup>, Leonardi R.<sup>1</sup>, Lo Giudice A.<sup>1</sup>

Department of Orthodontics, University of Catania, Catania, Italy

**Aim:** the aim of this study was to test the accuracy of a new automatic deep learning-based approach for fully mandible automatic segmentation from CBCTs.

**Methods:** 40 CBCT scans from healthy patients (20 females and 20 males, mean age  $23,37 \pm 3,34$ ) were collected and a manual mandible segmentation were carried out by using Mimics software. Twenty CBCT scans out of the total sample were randomly selected and used for training the artificial intelligence model file. The remaining 20 CBCT segmentation masks were used to test the accuracy of the CNN fully automatic method by comparing the segmentation volumes of the 3D models obtained with automatic and manual segmentations. The accuracy of the CNN-based method was also assessed by using the DICE Score coefficient (DSC) and by the surface-to-surface matching technique. The Intraclass correlation coefficient (ICC) and Dahlberg's formula were used respectively

to test the intra-observer reliability and method error. Independent Student's t-test was used for between-groups volumetric comparison.

**Results:** measurements were highly correlated with an ICC value of 0.937 while the method error was  $0.24 \text{ mm}^3$ . A difference of  $0.71 (\pm 0.49) \text{ cm}^3$  was found between the methodologies but it was not statistically significant ( $p > 0.05$ ). The matching percentage detected was  $90.35\% \pm 1.88\%$  (tolerance 0.5 mm) and  $96.32\% \pm 1.97\%$  (tolerance 1.0 mm). The differences, measured as DSC in percentage, between the assessments done with both methods were, respectively, 2.8% and 3.1%.

**Conclusion:** the tested deep learning CNN-based technology provided a fast and accurate fully automated segmentation of the mandible from CBCT scans. Also, it performs as well as an experienced image reader but at much higher speed, which is of significant clinical relevance.

## COMPARISON OF DIFFERENT ACQUISITION METHODS FOR DIGITAL DENTAL MODELS

Rosolin L., Pappalardo D., Bersani M., Poscolere A., Zotti F.

Department of Surgical Science, Pediatrics and Gynecology, University of Verona, Verona, Italy

**Aim:** the aim of this study was to compare different techniques of data acquisition to create three digital dental models from the same plaster model.

**Methods:** an upper plaster model (PM) was converted into a digital model using three different techniques: photogrammetry (PH), CT scan (CT) and with a lab scan (LS). PM was chosen as the reference object and measurements were taken on it by using a caliper. Following measurements were taken on the three digital models using Blender® (Blender Foundation®, The Netherlands) and compared with those obtained from PM. Height and width of each tooth were measured, as well as the transverse widths between the canines cusps and the mesio-palatal cusps of first molars. Distance between the midline and the cusps of canines were also assessed. Mean values from all measurements were evaluated in order to simplify calculation.

All meshes were superimposed to view differences between digital models and obtain sound data.

**Results:** mean values obtained by sources of acquisition were: PM: 9,39mm; PH: 9,39mm; CT: 9,38mm; LS: 9,41mm. Differences between PM and digital models were shown as mean  $\pm$  SD in mm: PM-PH:  $0 \pm 0,12$ ; PM-TC:  $0,03 \pm 0,14$ ; PM-SC:  $-0,03 \pm 0,11$ . No statistically significant differences were found between values from different acquisition methods (ANOVA test  $p > 0.05$ ). Mean distance  $\pm$  SD in mm between landmarks of the two overlapped meshes where: LS-PH:  $0,006 \pm 0,129$ ; CT-LS:  $0,003 \pm 0,067$ ; CT-PH:  $0,006 \pm 0,129$ .

**Conclusion:** the study showed a good viability of the acquisition methods in obtaining digital dental models. It seems they could be useful in designing accurate and faithful digital models.

## THE ROLE OF CBCT IN DENTISTRY: A CRITICAL REVIEW

Sertori F., Bellantoni G., Ferri S., Palmacci M., Palumbo L., Manacorda M.

Department of dentistry, IRCCS San Raffaele Hospital, Milan, Italy; Dental School, Vita-Salute San Raffaele University, Milan, Italy

**Aim:** cone beam computed tomography (CBCT) is a valuable imaging modality in oral and maxillofacial (WHO) surgery. A 3D analysis of the anatomy of the head and neck allows the doctor to operate with confidence and evaluate the results after surgery. CBCT imaging has clear indications and limitations. In addition, CBCT overcomes some limitations of 2D imaging, such as distortion, magnification, and overlap. This review evaluates the use of CBCT in the various fields of oral and maxillofacial surgery and the worth of CBCT in preoperative assessment, surgical planning, and postoperative analysis. In addition, the main limitations of CBCT are discussed.

**Methods:** a critical review was conducted separately for different fields of oral and maxillofacial surgery.

Using PubMed as the primary database the emphasis has been on systematic reviews, meta-analyses and large randomized controlled trials.

The keywords used for the research were: CBCT, Cone Beam Computed Tomography and NEWTOM.

**Results:** this review confirms that the NEWTOM CBCT provides valid information to the doctor in a variety of clinical cases. Bone volume and linear measurements can be accurately calculated with CBCT, which is useful during pre-surgical evaluations. CBCT can also show bone infections but does not allow for soft tissue visualization. While some studies support the use of CBCT for orthognathic surgery or TMJ, systematic reviews have failed to support its application universally.

**Conclusion:** the NewTom is used for many purposes, such as WHO procedures, the removal of teeth and the placement of dental implants. The quality of the literature supporting its use is quite varied. Although CBCT has been available for several decades, there are many significant opportunities to expand the existing literature and support new applications of this imaging technology.

## ACCURACY AND RELIABILITY OF A DIGITAL PLANNING FOR COMPOSITE VENEERS MANUFACTURING

Sigari G.<sup>1</sup>, La Rosa G.R.M.<sup>1</sup>, Ferri A.<sup>2</sup>, Grande F.<sup>2</sup>, Pedullà E.<sup>1</sup>, Ortensi L.<sup>1</sup>

<sup>1</sup>Department of General Surgery and Medical-Surgical Specialties, University of Catania, Catania, Italy

<sup>2</sup>Oral and Maxillofacial Surgery, University of Bologna, Bologna, Italy

**Aim:** purpose of this study was to evaluate the production of customized composite veneers starting from a 2D digital diagnostic wax up, through the use of the Digital Smile System (DSS).

**Methods:** a total of thirty patients requesting restoration treatment to improve the aesthetics of maxillary anterior section were included. Phonetic tests were done to detect the proper position of maxillary incisors. Then, the photographic exam was performed taking two digital pictures of the face and digital preview through the DSS. In addition, optical scans of the antagonistic arches were obtained and the data were put into a 3D software to make a virtual wax up. The STL files were sent for production using CAD-CAM technology. The Friedman test for matched groups with Bonferroni and Dunn post-hoc tests were applied to

compare the various measurements of the 2D plan, the 3D plan, and the veneers made ( $\alpha = .05$ ).

**Results:** significant differences resulted between the pictures and digital scans on the mesial-distal widths of the lateral incisors and canine. Linear measurements in 2D plan were significantly different from those of the 3D plan except for the height measures of incisors for which no significant difference was found. No significant changes emerged comparing the parameters of the 2D and 3D plans with those of the final prosthetic pieces.

**Conclusion:** the customized veneers were clinically adequate and similar to 2D and 3D plans even if significant differences emerged between the linear measurements on the picture and the digital scans as well as between the 2D and 3D plans.

## 3D SURGICAL PLANNING FOR SUPERNUMERARY TEETH: CLINICAL EXPERIENCE

Todaro C., Torchia M., Landini J., Lupi S.M.

Department of Clinical Surgical, Diagnostic and Pediatric Sciences, University of Pavia, Pavia, Italy

**Aim:** the purpose of this study was to investigate the impacted supernumerary teeth which were initially detected on panoramic radiographs by using Cone Beam Computer Tomography (CBCT) and 3D rendering. Through CBCT scan the surgeon can visualize the supernumerary teeth on all spatial planes during the pre-surgical examination.

**Methods:** a 9-years-old girl was referred to our Orthodontic Clinic, because of the eruptive delay of the maxillary incisors. The orthopantomography revealed the presence of a supernumerary tooth precluding eruption of the permanent maxillary left incisors. A CBCT scan was taken and the examination of both 3D rendering and cross-sectional images confirmed the position and the morphology of the supernumerary tooth in relation with the surrounding noble structure.

**Results:** according to the Literature, the presence of supernumerary teeth is a condition that most commonly occurs in permanent maxillary lateral incisors.

Being the anatomy of supernumerary teeth extremely variable, the clinician needs to know the exact position and morphology of the elements to be extracted in order to plan the surgery.

CBCT and 3D rendering provide more information about the shape and the spatial collocation of supernumerary teeth, reducing the incidence of complication and enabling a more accurate diagnosis and treatment plan.

**Conclusion:** CBCT volume rendering is an efficient and effective method to detect and plan the surgical treatment of supernumerary teeth.

## EARLY ROOT RESORPTION OF PRIMARY INCISORS IN CONGENITAL NEMALINE MYOPATHY: A CASE REPORT

Almonte E., Carrara I., D'Avola V., Viola N., Cagetti M.G.

Department of Biomedical, Surgical and Dental Sciences, School of Specialization in Pediatric Dentistry, University of Milan, Milan, Italy

**Aim:** a 3-year-old patient affected by Congenital Nemaline Myopathy (CNM), required a visit at the Pediatric Dentistry Department of the University of Milan, showing severe mobility of all primary incisors. The aim of this study is to present this rare case of early root resorption and to investigate if other similar cases are reported in young patient with this myopathy.

**Methods:** L.R. is the second born son of Italian healthy parents. No similar cases are reported in the family. At birth, due to severe conditions, he was transferred to a Neonatal ICU and, using electromyography and muscle biopsy, the diagnosis of CNM was made. CNM incidence is estimated to be 1 in 50,000 live births. The child presents severe muscle weakness, hypoventilation, swallowing dysfunction, and none speech ability.

The patient came to our attention in February 2021. Severe root resorption with no clear etiology was found in all primary

incisors through periapical radiography. With parent consent, the extraction of 51 and 61, to avoid risk of swallowing, was performed. A research was made using Orphanet and PubMed database to investigate if similar findings were present in the literature.

**Results:** no similar cases were found and no guidelines to treat these patients, except for a Consensus paper published in 2012, were available, making the management of these patients very difficult.

**Conclusion:** no studies reporting root alteration associated with CNM were found. This case report is the first describing early root resorption of primary teeth in a patient with CNM. This case underlines the importance of a multidisciplinary approach in the diagnosis and treatment of young patients with rare diseases.

## PEDIATRIC AUTISM PATIENTS: A STUDY ON APPROACHES TO DENTAL CARE

Amenduni B., Ligori A., Quercia E., Ricci A., Tempesta A., Prof. Corsalini M.

Specialization School of Paediatric Dentistry, Department of Interdisciplinary Medicine, University of Bari Aldo Moro, Bari, Italy

**Aim:** the aim of the work is to find the most suitable methods for the treatment of pediatric special needs patients, and in particular autistic children.

**Methods:** we performed a review of literature using Medline for consultation of the articles of interest published until January 2021. We analyzed the methodologies and protocols that have proved valid.

**Results:** research shows that it is necessary to associate cognitive-behavioral techniques with pharmacological protocols. It is necessary to modulate between basic and advanced be-

havioral techniques in combination with pharmacological therapies, such as benzodiazepine administration and the use of nitrous oxide. For the most severe forms, in the absence of collaboration, deep sedation or general anesthesia should be used. The dentist must adopt a diversified, flexible and adaptable approach to each individual case.

**Conclusion:** it is necessary to expand the contents of behavioral management techniques with pre and post treatment strategies and to investigate more suitable and safe pharmacological protocols even in an out of hospital environment.

## ART TECHNIQUE AND HIGH VISCOSITY GLASS IONOMER CEMENT: A SYSTEMATIC REVIEW

Angelino E., Zaffarano L., Romeo S.A., Cagetti M.G.

School of Specialization in Pediatric Dentistry, Department of Biomedical, Surgical and Dental Sciences, University of Milan, Milan, Italy

**Aim:** two aims are selected for this study. The first aim is to evaluate the effectiveness of atraumatic restorative treatment of carious lesions in primary teeth with glass ionomer cements with at least one year of follow up. The second aim is to evaluate if traditional ART technique is more effective by placing an adhesive resin over the restoration with glass ionomer cement (coating), with at least one year of follow up.

**Methods:** electronic search strategy was performed by five search engines. Using the PICOS system, the included studies had to comply the following inclusion criteria: (P) children between 2 and 14 years with occluso-proximal cavities in posterior primary teeth, (I) treatment of carious lesions with ART technique restored with high viscosity glass ionomer cements (HVGIC), (C) comparison between high viscosity glass ionomer cements and conventional glass ionomer cements, (O1) to evaluate if high viscosity glass ionomer cement is more effectiveness compared to conventional glass ionomer cement in primary teeth treated with ART technique with at least one year of follow up, (O2) to evaluate is the placement of a light cured adhesive resin based protector on the surface of the restoration helps to improve the prognosis with a follow up at least of one year, (S) randomized controlled clinical trial. The risk of bi-

as was evaluated with Cochrane instrument RoB 2.0. The GRADE method was evaluated using GRADE-pro software. Two authors E.A and L.Z assessed the certainty of evidence.

**Results:** the PRISMA flowchart resume the study selection process, 670 studies were selected by reading title and abstract. After this search 30 studies were selected for the final reading of the full text, the reading of this articles led to a selection of 6 articles. In total, the analyzed elements among all the includes studies were 699. To answer the first outcome, we used tree studies in which only one has statistically significant differences ( $p = 0.03$ ) in favour of HVGIC. To answer the second outcome we used four studies, in three studies the authors used a resin adhesive coating while one author used a transparent nail coating. For this outcome two results were statistically significant.

**Conclusion:** few studies have compared GIC and HVGIC. There is a little evidence regarding a greater efficacy of high viscosity glass ionomer cements compared to conventional ones with a one year follow up. Basically, both materials work well, with a slight superiority of HVGIC. The application of a light-cured protective adhesive resin on the surface of the cavities selected for the study did not affect the survival rate of the restorations.

## EVALUATION OF TMJ INVOLVEMENT IN CHILDREN AFFECTED BY JUVENILE IDIOPATHIC ARTHRITIS (JIA)

Defabianis P., Caserta G., Cricenti L., Crupi D., Bello L.

Department of Surgical Science, C.I.R Dental School, Section of Paediatric Dentistry, University of Turin, Turin, Italy

**Aim:** temporomandibular joint (TMJ) involvement in children with juvenile idiopathic arthritis (JIA) can cause severe craniofacial growth disturbances if not treated in the early stage. We investigated correlations between findings from the clinical examination with ultrasound (US) imaging of the TMJ.

**Methods:** sixty-two children (mean age 10.4 yrs) with newly diagnosed JIA were examined clinically and imaged with US. All imaging studies were interpreted by radiologists experienced in TMJ imaging. Clinical and imaging findings were scored.

**Results:** a total of 124 joints were examined: 5% of them showed condylar remodelling, 15% unilateral and 3% bilateral enhance-

ment of the synovial membrane. All children showing mild to severe findings by clinical examination also had pathological signs on US, but not all patients without clinical findings had a normal imaging of the TMJ. Eighteen children (29%) showed clinical findings with no imaging evidence. The sensitivity of the clinical examination was 21.43% with a specificity of 95.83%.

**Conclusion:** symptoms can be considered good predictors of TMJ involvement, but their absence does not exclude it. The clinical examination combined with screening US evaluation could be used as a filter to plan the follow-up of patients and to select children for enhanced MRI.

## IS GENERAL ANAESTHESIA A GOOD STRATEGY FOR YOUNG NON-COOPERATING PATIENTS?

Cirio S., Balian A., Carrara I., Salerno C., Mbanefo S., Cagetti M.G.

Department of Biomedical, Surgical and Dental Sciences, University of Milan, Milan, Italy

**Aim:** to present a case-report of a non-cooperating 10-years-old girl with enamel defects treated in general anaesthesia and discuss strengths and limits of this therapeutic choose.

**Methods:** at the first examination parents reported that the child undergone extractions of all primary molars and first permanent molars under general anaesthesia (GA) 3 years before. No further dental check-ups were planned.

A poor cooperation level (Frankel scale 2) was offered by the child during the visit. The intraoral examination revealed enamel defects on permanent incisors and premolars. Second permanent molars showed a serious hypomineralized enamel with post-eruptive breakdown.

Parents reported to be not informed about their daughter's enamel defects condition.

**Results:** the possible etiological factors of the defects were inquired with parents and the child's paediatrician was consulted in order to investigate any systemic disorder that could be linked to the enamel defects. A minimally invasive approach was planned and carried out in order to prevent further breakdown of second molars and increase patient's cooperation. Fluoride varnish was regularly applied on all dental surfaces.

**Conclusion:** this case shows how dental treatments under GA can be not follow by long-term benefits, if the degree of patient's cooperation and the parents' awareness about their child's oral status are not addressed. Patients who had undergone dental treatment under GA should always be included in a dental follow-up protocol to prevent further problems and increase cooperation via behavioural approach.

## ELASTODONTIC THERAPY OF OPEN BITE MALOCCLUSION OF A 3 YEARS OLD PATIENT: A CASE REPORT

Coloccia G.<sup>1</sup>, Patano A.<sup>1</sup>, Laudadio C.<sup>1</sup>, Malcangi G.<sup>1</sup>, Marinelli G.<sup>1</sup>, Limongelli L.<sup>1</sup>, Inchingolo A.D.<sup>1</sup>, Montenegro V.<sup>1</sup>, D'Oria M.T.<sup>1</sup>, Laforgia A.<sup>1</sup>, Dipalma G.<sup>1</sup>, Inchingolo F.<sup>1</sup>, Di Venere D.<sup>1</sup>, Cardarelli F.<sup>1</sup>, Farronato M.<sup>2</sup>, Tartaglia G.<sup>2</sup>

Complex Operative Unit of Odontostomatology Director: Prof. G. Favia

<sup>1</sup>Specialization School in Orthognatodontics Director Prof. F. Inchingolo, Interdisciplinary Department of Medicine D.I.M. University of Bari Aldo Moro, Bari, Italy

<sup>2</sup>Department of Biomedical, Surgical and Dental Sciences, School of Dentistry, University of Milan, Milan, Italy. UOC Maxillo-Facial Surgery and Dentistry. Fondazione IRCCS Ca' Granda, Ospedale Maggiore Policlinico, Milan, Italy

**Aim:** this works wants to describe the resolution of a 3 years old patient anterior open bite malocclusion caused by non-nutritive sucking habit, altered swallowing and breathing. Usually orthodontic malocclusion like open bite are associated with bad habit and oral disfunction of breathing, swallowing and chewing that cause abnormal growth of the jaws and teeth.

**Methods and results:** in this patient at first the pacifier was replaced by a modified pacifier made of buccal and lingual shield, an occlusal pad and an extraoral ring, called "ciuccio bite". The patient was asked to wear the modified pacifier for 6 months. After that, the modified pacifier was replaced by an

"AMCOP Open" appliance for other 6 months. This appliance was wearred by the patient for 1 hour during the day and all the night. After 12 months the open bite was corrected and the upper and lower anterior teeth had the right occlusion and the same last appliance was wearred as retention for about 8 months.

**Conclusion:** in a 3 years old patient it was possible to correct the malocclusion caused by bad habit of non-nutritive sucking first with a well-accepted modified pacifier that had similar shape of old pacifier, and then with a more performing appliance AMCOP elastodontic for anterior open bite treatment.

## ORAL LOCALIZATION OF BEHCET DISEASE IN A 12 YEARS OLD FEMALE PATIENT: DIAGNOSTIC FRAMEWORK

Cutrupi S.<sup>1,2</sup>, Petrocelli M.<sup>1</sup>, Baietti A.M.<sup>1</sup>

<sup>1</sup>Dental and Maxillofacial Unit, Maggiore and Bellaria Hospital, Bologna, Italy

<sup>2</sup>School of Specialization in Pediatric Dentistry, University of Milan, Milan, Italy

**Aim:** the diagnosis of Behcet disease (BD) in a female young patient with oral aphthosis is discussed. BD is an autoinflammatory systemic vasculitis characterized by oral and genital mucocutaneous recurrent ulcerations, uveitis and systemic vasculitis involving arteries and veins of all sizes. The etiology is still unclear although genetics and environmental factors have been a role. The association of carriers of HLA-B51/B5 with exposure to infectious agents, hypersensitivity to Streptococcus, Staphylococcus Aureus, Prevotella, Herpes Simplex type 1 antigenes have been suggested as potential culprits.

**Methods:** we report a case of a 12-years old female patient presented a chronic recurrent aphthosis of oral cavity and pharynx, intestinal disease, previous genital condylomas, labial Herpes Simplex type 1. Under local anesthesia we per-

formed biopsy of right oral floor, right inferior labial fornix and left superior labial fornix lesions.

**Results:** histopathological analysis shows a neutrophil-predominant reaction with endothelial swelling, extravasation of RBCs, and leukocytoclastic vasculitis with fibrinoid necrosis of the blood vessel walls.

**Conclusion:** the neutrophilic vascular reaction oriented for BD therefore the patient was referred for a gastrointestinal, ocular, cardiological and neurological evaluations to exclude further localizations with involvement of great vessels.

After rheumatology prescription the patient began a systemic therapy with corticosteroid, sucralfate suspension for orogenital lesions and immunosuppressor drugs to prevent intestinal recurrences.

## PREGNANTS' ORAL HEALTH: WHAT GYNECOLOGISTS/OBSTETRICIANS KNOW?

D'Avola V., Maspero C., Cagetti M.G.

Department of Biomedical, Surgical and Dental Sciences, School of Specialization in Pediatric Dentistry, University of Milan, Milan, Italy

**Aim:** the aim of this study is to evaluate the knowledge of gynecologists and obstetricians about the importance of the oral health maintenance during pregnancy and the correlation between women's oral health conditions and their general health, the childbirth and the future health of the babies.

**Methods:** health professionals working in the Gynecology and Obstetrics Unit of Policlinico of Milan, were asked to participate in a survey, filling in an anonymous questionnaire. The questionnaire was also posted on various obstetricians' groups on a social network. One-hundred-thirty-three between gynecologists and obstetricians participated.

**Results:** the results showed that the majority (70,0%) of the medical staff involved did not have a satisfying knowledge on the importance of the oral health during pregnancy, in particu-

lar 63,3% of participants stated they are not able to recognize signs and symptoms of periodontal disorders and only less than 50% of obstetricians and gynecologists recommend a dental visit during pregnancy. Almost all of the participants (92,5%) declared an interest in taking courses on this topic.

**Conclusion:** disinformation is the first cause of poor early diagnosis and prevention of gestational and neonatal complications as well as systemic health of the woman herself. Gynecologists and obstetricians could play an important role in increasing awareness and spreading the importance of oral health during pregnancy. Healthcare professionals should be instructed to recognize signs and symptoms of oral disorders during pregnancy, give adequate advices and recommend a dental visit.

## MIH-AFFECTED TEETH: WHICH TREATMENT IS SUGGESTED?

De Grazia M.T., Oberti L., Paniura L., Mbanefo S., Cagetti M.G.

School of Specialization in Pediatric Dentistry, Department of Biomedical, Surgical and Dental Sciences, University of Milan, Milan, Italy

**Aim:** MIH is a qualitative developmental defect of the enamel involving from 1 to 4 permanent molars with or without incisors involvement. This review aims to investigate which treatments are effective in treating MIH-affected teeth.

**Methods:** PubMed and Scopus database were searched from 1991 to 2020. Forty articles were evaluated and fourteen were included. The inclusion criteria were: scientific articles in English published in impact journals, systematic reviews and clinical studies on human subjects having at least a permanent molar with MIH.

**Results:** four papers dealt with incisors' treatment modalities and ten with molars' cares. Early diagnosis resulted essential for an immediate intervention, avoiding the onset of pulp inflammation. Both patient and parents must be informed about the consequences of untreated MIH. Hypersensitivity

should be treated, since it leads to avoid toothbrushing increasing the risk of caries. CPP-APC paste seems to reduce mild and moderate hypersensitivity in MIH affected teeth. Sealants have some benefits in molars with mild MIH to prevent caries and enamel breakdown. In molars with enamel loss, direct and indirect composite restorations have proven to be effective. For molars with severe MIH, extraction should be considered. In the incisors, aesthetics is often the most important aspect to consider. Invasive restorative interventions, such as veneers, should be avoided or postponed in favor of less invasive strategies.

**Conclusion:** dentists need to consider the specific condition of each MIH-affected tooth and the patient's needs and expectations when deciding how to manage MIH. Strong recommendations are not possible based on current evidence.

## ANKYLOSIS OF THE SECOND PRIMARY MOLARS: FOCUS ON DIAGNOSIS AND TREATMENT

Del Vecchio S., Semprini Pironi F., Guaragna M., Preite C., Vodola E., Titone A., Ierardo G., Luzzi V.

Department of Oral and Maxillofacial Science, Unit of Pediatric Dentistry, Director: Prof. A. Polimeni, Sapienza University of Rome, Rome, Italy

**Aim:** the purpose of this study was to re-elaborate the data present in the literature regarding the diagnosis and subsequent different strategies to treat second primary molars ankylosis. We focused on the presence or the absence of the permanent substitute element to evaluate the best therapeutic approach.

**Methods:** were searched on PubMed® papers published about this topic from 1980 to 2020. The advanced research was carried out by entering the following keywords 'dental ankylosis', 'infraocclusion of primary molars' and 'treatment of infraocclusion'. All case reports were excluded.

**Results:** the diagnosis of ankylosis is still unclear. However, the association of clinical data (dental mobility, percussion sound and infraocclusion), radiographic data (CT and OPT) and study models can be sufficient to make diagnosis. The

absence of the permanent tooth represents the most important condition to guide the therapeutic approach. Indeed, if it is present, the surgical-orthodontic approach with space maintenance could be used, waiting for the eruption. Contrarily, in case of agenesis of the permanent tooth, we can keep the ankylotic element to preserve the space for a dental implant or, considering the type of malocclusion and the unilateralism or bilateralism of ankylosis, to extract the element and close the spaces.

**Conclusion:** regarding ankylosis treatment, it is essential to make an early diagnosis in order to set the most correct approach. A late diagnosis could lead to severe consequences such as the tipping of adjacent teeth and lower predictability of the treatment.

## FACIAL GROWTH AND MORPHOLOGY OF CLEFT LIP AND/OR PALATE PATIENTS AFTER CORRECTIVE SURGERY

Giuca M.R.<sup>1</sup>, Fambrini E.<sup>1</sup>, Pasini M.<sup>1</sup>, Giacomina A.<sup>2</sup>, Fortini G.<sup>2</sup>, Gatti G.<sup>2</sup>

<sup>1</sup>Department of Surgical, Medical, Molecular and Critical Area Pathology, Unit of Pediatric Dentistry, University of Pisa, Pisa, Italy

<sup>2</sup>Cleft Lip and Palate Center, Plastic and Reconstructive Surgery Unit, Santa Chiara Hospital, Pisa, Italy

**Aim:** cleft lip and/or palate patients (CLP) undergo corrective surgery that can affect facial growth. The aim of this study was to analyze facial growth and maxillary development of CLP subjects after surgery according to P.I.S.A. technique (Peri osteoplasty Improves Symmetry and Aesthetic).

**Methods:** cephalometric tracings of 55 patients were performed, thirty-three of which belonged to the test group, while the lasting twenty subjects were part of the control group. The test group was formed by cleft lip and/or palate patients after surgical repair according to P.I.S.A. technique. The control group included patients unaffected by this malformation, with an Angle's first class, selected from the Michigan Growth Study sample. Facial growth and upper maxilla development

analysis was carried out by comparing the data obtained from the cephalometric traces of cleft patients who performed an early surgery, with the values of the same parameters measured in non-cleft subjects, providing the normal values.

**Results:** the results of this study showed, in the test group, a maxillary and mandibular bi-retrusion, a more negative facial convexity, the absence of a marked discrepancy in the skeletal relationships, a slight tendency towards hyper-divergence.

**Conclusion:** data interpretation makes it necessary to evaluate different factors, including the presence of a basal intrinsic deficit of bone growth in CLP patients and the presence of scar tissue, due to the palate surgical repair, which inhibits the bone growth by the phenomenon of scar retraction.

## PEDIATRIC PROCEDURAL ANALGOSEDATION IN THE DENTAL EMERGENCY ROOM: A PILOT STUDY

Baietti A.M.<sup>1</sup>, Ghizzi C.<sup>2</sup>, Alberghini V.<sup>3</sup>, Balsamo C.<sup>3</sup>, Francavilla R.<sup>3</sup>, Salvago P.<sup>3</sup>, Florio R.<sup>4</sup>

<sup>1</sup>Operative Unit for Face Surgery and Dentistry, Bellaria and Maggiore Hospital, Bologna, Italy

<sup>2</sup>Complex Operating Unit of Pediatrics, Bellaria and Maggiore Hospital, Bologna, Italy

<sup>3</sup>Pediatricians of Bellaria and Maggiore Hospital, Bologna, Italy

<sup>4</sup>School of Specialization in Pediatric Dentistry, University of Milan, Milan, Italy

**Aim:** to investigate effectiveness and safety of IV Ketamine plus Midazolam administration to uncooperative children undergoing dental surgical therapies.

**Methods:** 95 children aged 1-7 years (51 males) treated at Maggiore Hospital (Bologna) in a period of 12 months were included. Children with the following inclusion criteria were enrolled: presence of severe infections due to Type 3 ECC and Frankl's grade 0 and 1; traumatized teeth needed extractions and sutures; children whose parents refused general anesthesia. All included patients were ASA I and II.

Special needs children were also included. After acquiring an informed consent IV Midazolam (0,1-0,2mg/kg) and Ketamin (1-2mg/kg) were administered. Patients were monitored with oximetry, capnography and through a cardiac monitoring device. For each patient were evaluated: a) depth of sedation (modified Ramsey Scale); b) events (Word SIVA Scale); c) am-

nesia and parents' satisfaction (questionnaire); d) pain and anxiety (modified FLACC Scale); e) discharge (modified Aldrete Scale).

**Results:** a) All patients received good moderate sedation for 15-20 minutes; b) vomiting occurred in 2 patients; agitation in the recovery phase in 3 patients; mild desaturation in 2 patients; c) all children reported amnesia and all caregivers, except one, expressed high satisfaction; d) all children with "special needs" (5 patients) reported score 0 of modified FLACC Scale; e) at discharge all patients had score 2 of the modified Aldrete Scale.

**Conclusion:** a low dose of Midazolam and Ketamine produced quick onset of satisfactory moderate sedation without significant side-effects, it can certainly be a valid alternative to general anesthesia for short term surgical procedures in deciduous dentition.

## MUSIC THERAPY IN PEDIATRIC DENTISTRY

Greco A.<sup>1</sup>, Menozzi G.<sup>1</sup>, Rey L.<sup>1</sup>, Mauri M.<sup>2</sup>, De Bortoli G.<sup>2</sup>, Zanarello S.<sup>2</sup>, Andreoni C.<sup>2</sup>, Leonforte L.<sup>2</sup>, Ventimiglia R.<sup>2</sup>, Cagetti M.G.<sup>2</sup>

<sup>1</sup>Department of Biomedical, Surgical and Dental Sciences, School of Specialization in Pediatric Dentistry, University of Milan, Milan, Italy

<sup>2</sup>Department of Biomedical, Surgical and Dental Sciences, University of Milan, Milan, Italy

**Aim:** uncooperative pediatric patients are difficult to treat. Recently the anxiolytic effects of music has been studied, and especially during dental treatments could help to reduce other noises, decreasing the patient's perception of pain. The aim of the study is therefore to evaluate whether music therapy actually reduces the level of anxiety in dental patient performing a literature review.

**Methods:** using PubMed, a literature search was performed with the following key words: "Music therapy", "Effect music therapy", "Music dentistry", "Dental anxiety children". Clinical trials, systematic reviews and meta-analysis, published within 10 years, were the types of studies included. Only studies focused on the effect of the music on patient's anxiety in the clinical setting were included. The research identified 26 documents, 5 papers met the inclusion criteria.

The studies employed different methods to measure dental anxiety including the Venham's Picture Test, the Venham's clinical anxiety rating scale and pulse oximetry. Singh *et al* (2014) examined the effects of listening to patient-selected music vs standard dental care on anxiety in pediatric dental patients.

**Results:** the results showed that music listening significantly decreased anxiety in the test group, compared to the control group. Statistically significant reductions were also reported for systolic blood pressure and pulse rate in the test group. Also Di Nasso L. *et al* (2016) showed that all the measured vital signs decreased in the group of patients listening to music, considering the overall period, during endodontic treatments ( $P < .05$ ).

**Conclusion:** findings shows a substantial agreement in favour of the use of music to reduce and moderate anxiety of patient, especially children, during dental treatments.

## CONNECTION BETWEEN THE USE OF ANTI-COVID-19 PROTOCOL AND ANXIETY IN PEDIATRIC PATIENTS

Guaragna M., Semprini Pironi F., Preite C., Luzzi V.

Department of Oral and Maxillofacial Science, Unit of Pediatric Dentistry, Director: Prof. A. Polimeni, Sapienza University of Rome, Rome, Italy

**Aim:** due to COVID-19 pandemic, the use of some additional protective measures were necessary, for the protection of the dentist and the patients. The aim of this work is to define if the use of personal protective equipment (PPE) increases children's anxiety related with dental treatment and the figure of the dentist.

**Methods:** systematic review of the literature was conducted using PubMed. 25 studies were selected and included in which different strategies were used to reduce dental anxiety in the child during dental treatment and 5 studies concerning the change in the management of the pediatric patient in the covid period. The data were then analyzed descriptively.

**Results:** the association between the use of the new anti COVID-19 safety protocols in the dental field and the increase in dental anxiety in the pediatric patient has not yet been evaluated in the literature.

**Conclusion:** considering the importance of anxiety management in the pediatric patient, it would be interesting to start a study evaluating the effect that the dentist, equipped with anti-COVID-19 devices, has on the anxiety of the pediatric patient, and if there is an increase in the incidence of this phenomenon, identify the methods to be implemented to manage it.

## INTERCEPTIVE THERAPY WITH A.M.C.O.P. DURING THE DECIDUOUS DENTITION: A CASE REPORT

Laudadio C.<sup>1</sup>, Patano A.<sup>1</sup>, Malcangi G.<sup>1</sup>, Colocchia G.<sup>1</sup>, Marinelli G.<sup>1</sup>, Limongelli L.<sup>1</sup>, Inchingolo A.D.<sup>1</sup>, Montenegro V.<sup>1</sup>, D'Oria M.T.<sup>1</sup>, Laforgia A.<sup>1</sup>, Dipalma G.<sup>1</sup>, Inchingolo F.<sup>1</sup>, Di Venere D.<sup>1</sup>, Cardarelli C.<sup>1</sup>, Farronato M.<sup>2</sup>, Tartaglia G.<sup>2</sup>

Complex Operative Unit of Odontostomatology Director: Prof. G. Favia

<sup>1</sup>Specialization School in Orthognatodontics, Director: Prof. F. Inchingolo, Interdisciplinary Department of Medicine D.I.M. University of Bari Aldo Moro, Bari, Italy

<sup>2</sup>Department of Biomedical, Surgical and Dental Sciences, School of Dentistry, University of Milan, Milan, Italy. UOC Maxillo-Facial Surgery and Dentistry. Fondazione IRCCS Ca' Granda, Ospedale Maggiore Policlinico, Milan, Italy

**Aim:** elastodontic therapy represents a new frontier of orthodontics in young patients. A.M.C.O.P. bio-activators are individualized elastodontic devices indicated for a-traumatic therapies of the dysfunctional problems. A.M.C.O.P. for deciduous teeth are signed in D and DC types, respectively without and with Pacifier grip. The DC model is equipped with a shield and a support for grip, which make it like pacifier to facilitate the use of the device from the psycho-emotional point of view, where the orthodontic correction acts adequately. The aim of this case report was to describe the use of the A.M.C.O.P. DC in a patient during the deciduous dentition with dental anterior open bite malocclusion due to sucking habits and tongue thrust.

**Methods:** a 2-year-old female patient showed a transverse maxillary deficit and anterior open bite sucking habits and atypical swallowing related. Treatment plan included A.M.C.O.P. DC appliance. No dental impressions were needed. The device was placed at night and one-hour daily. The active phase of therapy was conducted in six months and the retention time was six months.

**Results:** at six months anterior open bite was closed and canines were placed in I class. Quick results of this therapy have been due to the plasticity of skeletal structures at this stage.

**Conclusion:** early intervention with elastodontic therapy in primary dentition offers to clinicians the possibility to solve easy the anterior open bite and to prevent future severe malocclusion.

## ORAL MANAGEMENT OF PAEDIATRIC PATIENTS AFFECTED BY AUTISTIC SPECTRUM DISORDER

Ligori A., Amenduni B., Quercia E., Ricci A., Tempesta A., Prof. Corsalini M.

Specialization School of Paediatric Dentistry, Department of Interdisciplinary Medicine, University of Bari Aldo Moro, Bari, Italy

**Aim:** autism Spectrum Disorder (ASD) is characterized by impairments in communication and social relationship, and by repetitive repertoire of activities, behaviours and interests. As reported in literature, children with ASD are at higher risk of caries, severe gingivitis and alteration of periodontal status; moreover, treatment of these conditions is difficult due to limited patients' collaboration to dental procedures. The aim of this study is to report the experience of the University of Bari in the oral treatment of paediatric ASD patients.

**Methods:** forty-six paediatric patients with ASD were enrolled in this study (age range 4-15 years, 19 females, 27 males). They were referred to Complex Operating Unit of Odontostomatology of Policlinic of Bari between January 2020 and January 2021 because of oral pain. If it was possible, according to grade of collaboration, each patient underwent clinical examination and radiological exams. Then, patients received

oral treatments under general anaesthesia with nasotracheal intubation technique. Clinical follow-up was performed 7 days, 1 month and 6 months after treatment.

**Results:** all patients required treatment for gum diseases, due to plaque and tartar buildup, and for dental cavities. They all underwent full mouth disinfection; moreover, 124 dental extractions, 12 root treatments, 160 fillings of dental decays, 68 fissure sealing were performed. Each patient showed a good response to the general anaesthesia, without post-operative complications.

**Conclusion:** although difficult due to poor patients' collaboration, oral treatments are mandatory for paediatric patients affected by ASD to avoid serious infective complications. Individualized anaesthetic plan and oral management by a multidisciplinary team of dentists and anesthesiologists are key points to allow safe and effective oral management for ASD patients.

## ELASTODONTIC THERAPY WITH AMCOP TC: A CASE REPORT

Malcangi G.<sup>1</sup>, Patano A.<sup>1</sup>, Hazballa D.<sup>1</sup>, Laudadio C.<sup>1</sup>, Coloccia G.<sup>1</sup>, Marinelli G.<sup>1</sup>, Limongelli L.<sup>1</sup>, Inchingolo A.D.<sup>1</sup>, Montenegro V.<sup>1</sup>, D'Oria M.T.<sup>1</sup>, Dipalma G.<sup>1</sup>, Inchingolo F.<sup>1</sup>, Di Venere D.<sup>1</sup>, Farronato M.<sup>2</sup>, Tartaglia G.<sup>2</sup>, Cardarelli F.<sup>1</sup>

Complex Operative Unit of Odontostomatology Director: Prof. G. Favia

<sup>1</sup>Specialization School in Orthognatodontics, Director: Prof. F. Inchingolo, Interdisciplinary Department of Medicine D.I.M. University of Bari Aldo Moro, Bari, Italy

<sup>2</sup>Department of Biomedical, Surgical and Dental Sciences, School of Dentistry, University of Milan. UOC Maxillo-Facial Surgery and Dentistry. Fondazione IRCCS Ca' Granda, Ospedale Maggiore Policlinico, Milan, Italy

**Aim:** to show the ability of elastodontic devices and eliminate the factors responsible for dental malocclusions, restore the regular dental-skeletal growth, by obtaining a correct dental alignment. The myofunctional regulators rehabilitate the tongue posture, correct the deglutition, stimulate a correct respiration.

**Methods:** B.P., female, 3 y.o., malocclusion of class 3 skeletal and dental, complete crossbite. AMCOP TC is used for the first 6 months, 1 hour during the day and all the nights, in passive way, and then for other 10 months, only during the night, to obtain a class 1 molar and bilateral canine, through the maxillary advancement, by inhibiting the excessive mandibular bone. Once obtained the correct dental relation, patient will wear the device only during the night to the restrain and guide the eruption

of the permanent dental elements. After the resolution of the skeletal problem, the case is monitored each six months.

**Results:** the results obtained highlight as the elastodontic therapy may restore the regular occlusion, for the plasticity of the skeletal structures at the age of 3 years. The early therapy of malocclusions of dental and skeletal class 3 impedes the formation of irreversible bone atrophies or classes 3, by obtaining orthopaedic effects when the sutures are in active phase of proliferation.

**Conclusion:** the preventive orthodontics through elastodontic devices represent an important evolution in the field of orthodontics in developmental age as it is able to resolve most of the orthodontic problems by converting many of these cases in ideal occlusions from the aesthetic and functional point of view.

## THE USE OF VIDEO-MODELLING IN INCREASING ORAL HYGIENE IN CHILDREN WITH ASD

Mancini G.<sup>1</sup>, Salerno C.<sup>1,2</sup>, Cetraro F.<sup>1</sup>, Bontà G.<sup>1</sup>, Fornarelli G.<sup>1</sup>, Cagetti M.G.<sup>1,2</sup>

<sup>1</sup>G. Vogel Dental Clinic, Department of Biomedical, Surgical and Dental Sciences, University of Milan, Milan, Italy

<sup>2</sup>School of Specialization in Pediatric Dentistry, Department of Biomedical, Surgical and Dental Sciences, University of Milan, Milan, Italy

**Aim:** the aim was to evaluate the use of a cartoon in improving daily oral hygiene routine in children with autism spectrum disorder (ASD).

**Methods:** 255 parents of children with ASD, aged from 4 to 18 years, attending the Pediatric Dentistry Department for special needs patients of the G. Vogel Dental Clinic of Milan were contacted. A questionnaire, investigating the oral hygiene habits and the degree of collaboration during hygiene procedures, and the video were sent via email (t0). The video shows a correct brushing technique and the time required to perform it; the cartoon was designed by creating simple images, focusing on the mouth. After 4 weeks (t1), the parents were re-contacted asking to fill in a new questionnaire to evaluate changes in oral hygiene procedures.

**Results:** toothpaste was used by 93% of subjects at t0, while at t1, 96% of parents declared to use it. At t0, a brushing frequency of 1 time/day was reported by 27% of parents, while at

t1 this percentage decreased to 11%; a frequency of 2 times/day increased from 52% at t0 to 61% at t1. Finally, a frequency of 3 or more times/day increased from 21% at t0 to 28% at t1. Regarding brushing time, less than 1 minute of brushing was reported at t0 by 16% of the sample, while at t1 it decreased to 5% of the sample. One minute of brushing was reported by 38% of subjects at t0, while, at t1 it decreased to 35%; finally, a correct time of 2 minutes or more, increased from 46% at t0 to 60% at t1. More than one-third of the parents (38%) stated that the collaboration of their children during oral hygiene procedures remained unchanged after the use of the cartoon, 39% considered it improved, 20% declared an increased autonomy in toothbrushing performance, while 3% still consider it very difficult to perform.

**Conclusion:** the use of video modeling in children with ASD can improve oral hygiene routine.

## ORAL FEATURES IN CHILDREN AFFECTED BY PRADER-WILLI SYNDROME

Defabianis P., Maschio M., Bocca N., Bello L.

Department of Surgical Science, C.I.R Dental School, Section of Paediatric Dentistry, University of Turin, Turin, Italy

**Aim:** papers on Prader-Willi Syndrome (PWS) report evidence of enamel hypoplasia, dental erosion and rampant caries; thick and sticky salivary flow and mild dryness of lips and oral mucosa have also been described. Even if no systematic investigations of salivary flow rate and saliva buffering capacity has ever been reported. The aim of this work is to perform a systematic assessment of salivary secretion and oral manifestations to give some suggestion for the management and follow-up of these patients.

**Method:** eleven children (6 males, 5 females), aging from 4 to 18 years (mean age 12.2 yrs) were included in the study. Medical information including age, therapy, carbohydrate and acid drinks intake, presence of gastro-oesophageal reflux or frequent vomiting were collected. All patients were examined to evaluate dental caries prevalence using dmft and DMFT indices, dental plaque and gingival inflammation using plaque and

bleeding indices and dental erosion scored by BEWE index. In each patient salivary tests were performed to evaluate basal flux, stimulated flux, and salivary pH.

**Results:** in most of the patients oral hygiene was very poor. The mean dmft index was 2.8 and the mean DMFT one was 2.5. All the patients showed extremely low salivary flow rates, and the salivary pH ranged from 5.4 to 6.4 resulting in a low buffering capacity. In 5/11 (45.5 %) patients dental erosions were observed, but none of them complained vomiting or sour taste in the mouth.

**Conclusion:** dental erosions and caries observed in these patients could be caused by a low salivary flow rate and a low salivary buffering capacity combined with a high acid intake and poor tooth brushing habits. Paediatric dentists must be aware of these problems to perform correct preventive programs in these patients.

## IS THE ADMINISTRATION OF PROBIOTICS ABLE TO CONTROL CARIES INCREMENT IN PRIMARY TEETH?

Mbanefo S., Paniura L., Preatoni S. M., Cirio S., Salerno C., Oberti L., De Grazia M., Bontà G., Cagetti M.G.

School of Specialization in Paediatric Dentistry, Department of Biomedical, Surgical and Dental Sciences, University of Milan, Milan, Italy

**Aim:** the aim of this review is to investigate the effectiveness of probiotics in controlling caries increment in primary dentition.

**Methods:** research question was formulated based on the PICO. A comprehensive literature search was conducted across PubMed, Scopus and Embase without publication date limit, using search strings. The following criteria were considered: randomized clinical trials written in English, investigating the administration of probiotics in children with primary dentition compared to placebo using as outcome a caries index (dmft, ICDAS, Nyvad criteria) to calculate caries increment.

**Result:** twelve studies met the inclusion criteria and were included. In ten studies the administration from  $10^5$  to  $10^8$  CFU/ml of *Lactobacillus* (*paracasei*, *rhannosus*, *reuteri*), *Bifidobacterium* (*longum*, *animalis*, *lactis*) or *Streptococcus* (*uberis*, *oralis*, *rattus*) through milk powder, tablets or drops for at least 3 months was investigated. In eight out of ten, a statistically significant higher

caries increment was found in the placebo group compared to the probiotic group ( $p \leq 0.05$ ). In one of them, a combined administration for 21 months of fluoride and probiotics showed a statistically significant decrease in caries increment compared to placebo ( $p < 0.01$ ). Two studies reported that the early administration of probiotics in infants did not affect the occurrence of caries in primary teeth after 4 and 9 years follow ups, respectively. Nevertheless, in one study the administration of probiotics to mothers during the last month of pregnancy and to their children through the first year of life reduced caries prevalence measured at 9 years of age, compared to placebo ( $p = 0.01$ ).

**Conclusion:** a regular intake of probiotics seems to reduce caries increment in the primary dentition. Further studies are needed to clarify the mechanisms of action of probiotics within the oral cavity and to evaluate the cost-effectiveness of the probiotic administration.

## ORAL MANIFESTATIONS OF CORNELIA DE LANGE SYNDROME: A CASE REPORT

Oberti L., De Grazia M.T., Paniura L., Mbanefo S., Cagetti M.G.

School of Pediatric Dentistry, Department of Biomedical, Surgical and Dental Sciences, University of Milan, Milan, Italy

**Aim:** to present the oral findings of a child affected by Cornelia De Lange syndrome (CdLS). CdLS is a multisystemic syndrome characterized by growth retardation, intellectual and psychomotor impairment, abnormalities of the hands, facial dysmorphism with marked and arched eyebrows fused in the midline, thin lips, and micrognathia. The prevalence is about 1 in 50.000 cases. Most cases are sporadic, although NIPBL gene is often mutated.

**Method:** S.V. is a 12-year-old girl with CdLS, who attends the Dental Clinic of S. Paolo Hospital, Milan for dental treatment.

**Results:** the clinical examination shows a typical facial dysmorphism, bilateral conductive hearing loss, minor hand anomalies and eyelid ptosis. She also manifests significant growth retardation, severe mental retardation, and speech dis-

orders; collaboration during dental visits is poor. The inspection of the oral cavity revealed micrognathia, narrow upper jaw, dental crowding, tooth malposition and suspected agenesis of premolars. The patient also presented cleft palate surgically corrected with palatoplasty at 2 years. Dental caries, enamel defects and gingivitis are also detected. The treatment plan will include oral hygiene sessions and topical applications of fluoride varnish for caries control and prevention, restorative therapies, and primary teeth extractions to guide the eruption of permanent teeth and reduce dental crowding.

**Conclusion:** patients with rare diseases known to involve different intraoral structures should be included early in a program of regular follow-up visits with a multidisciplinary dental team.

## MANAGEMENT OF SEVERE MOLAR INCISOR HYPOMINERALIZATION: EXTRACTION PROTOCOL

Preatoni S.M., Cagetti M.G., Bazzini E., Bogni V., Mbanefo S.

Department of Biomedical, Surgical and Dental Sciences, University of Milan, Milan, Italy

**Aim:** the purpose of this review is to identify a protocol regarding the treatment of severe Molar Incisor Hypomineralization (MIH) form, investigating if first permanent molars (FPM) extraction and the management of the potential subsequent orthodontic treatment is an effective clinical choice.

**Methods:** the research was performed on PubMed using the following keywords: molar incisor hypomineralization, orthodontic treatment, tooth extraction.

**Result:** five papers were selected. All of them support the possibility of FPM extractions in severe MIH form in order to avoid complex and not long-lasting conservative care. Papers highlight the importance of assessing the patient's age, the

presence of the third molar germs, the orthodontic conditions and the possibility of using less invasive treatments. Two papers underline the importance of extracting FPM within 8-10 years of the child in order to increase the chance of second permanent molars mesialization with spontaneous space closure; one article shows the possibility of extracting FPM at a later age (15-16 years old) using it as a solution of dental crowding, when present.

**Conclusion:** protocols to manage severe form of MIH does exist. The extraction of molars MIH-affected may represent the therapy of choice for severe form of MIH in terms of cost-efficacy and result's stability.

## MOLAR INCISOR HYPOMINERALIZATION (MIH) AND PRACTICAL TREATMENT APPROACH IN LITERATURE

Ricci A., Amenduni B., Ligori A., Quercia E., Tempesta A., Corsalini M.

Specialization School of Paediatric Dentistry, Department of Interdisciplinary Medicine, University of Bari Aldo Moro, Bari, Italy

**Aim:** molar Incisor Hypomineralization (MIH) is a qualitative developmental defect of systemic origin of the enamel of one or more permanent first molar, with or without the affection of incisors, commonly seen in dental daily practice. The objective of the current study was to illustrate the available literature regarding the treatment options for MIH.

**Methods:** PubMed was screened up February 01, 2021. The keywords used were “Molar Incisor Hypomineralization” and “treatment” and “systematic review”. The research was limited to systematic review published in English.

**Results:** of 11 references initially found, 5 papers were included. Lygidaki illustrated a treatment approach according to the level of defect severity, suggesting that the individual preventive programs might postpone the initiation of the restorative treat-

ment. Elhennawy et al published the treatment for MIH molar and incisor, separately; the indication for which should be based on the severity of MIH and hypersensitivity. Coelho et al reported several effective treatments for MIH teeth using arginine pastes or fluoride varnishes to treat hypersensitivity. Elhennawy et al described the outcomes of restoration success and management of pain and hypersensitivity associated with MIH. Lagarde et al reviewed the bonding of adhesive materials to MIH-affected enamel, that was not significantly different when using self-etch compared with etch-and-rinse adhesives.

**Conclusion:** long-term clinical trials should be conducted to facilitate the clinical management of this dental defect. To date, it remains the necessity of specific clinical guidelines worldwide recognised.

## LASER FRENOTOMY FOR ANKYLOGLOSSIA IN NEWBORNS: THE EXPERIENCE OF THE UNIVERSITY OF BARI

Tempesta A.<sup>1</sup>, Dell’Olio F.<sup>2</sup>, Limongelli L.<sup>3</sup>, Siciliani A.<sup>4</sup>, Mezzapesa P.P.<sup>2</sup>, Massaro M.<sup>4</sup>, Sportelli P.<sup>4</sup>, Corsalini M.<sup>1</sup>, Favia G.<sup>2</sup>

<sup>1</sup>Specialization School of Paediatric Dentistry, Department of Interdisciplinary Medicine, University of Bari Aldo Moro, Bari, Italy

<sup>2</sup>Specialization School of Oral Surgery, Department of Interdisciplinary Medicine, University of Bari Aldo Moro, Bari, Italy

<sup>3</sup>Specialization School of Oral Surgery, University of Chieti, Chieti, Italy

<sup>4</sup>Department of Interdisciplinary Medicine, University of Bari Aldo Moro, Bari, Italy

**Aim:** ankyloglossia, also known as tongue-tie, is a congenital anomaly in which newborns present an abnormally short and/or thick lingual frenulum that limits the movement of the tongue. It has been associated with difficult breastfeeding due to ineffective sucking, that could cause breast pain to the mother, poor weight gain to the newborn, and excessively long feeds. WHO recommends mothers breastfeeding exclusively up to 6 months of age, so quick recognition of any obstacles in the suction mechanism should be a priority. English literature is controversial about the necessity of surgical treatment of these conditions, and about treatment outcomes. This study was aimed to describing the treatment protocol used in The Complex Operating Unit of Odontostomatology of the Policlinic of Bari.

**Methods:** ten newborns (age range 0-2 months, 4 females and 6 males) came to our attention due to breastfeeding difficulties. They all presented tongue-tie classified as anterior or

posterior; the Hazelbaker Assessment Tool for Lingual Frenulum Function (HATLFF) was employed to evaluate surgical treatment need. During vital signs monitoring and after topical anesthetic application, all the patients underwent laser frenotomy which was performed with diode laser (c.w., power of 4-5 W). After laser sessions, each patient received immediate mother breastfeeding. Clinical follow-up was performed 7, 14 and 30 days after treatment.

**Results:** totally, all treated patient showed anterior ankyloglossia that required surgical therapy according to HATLFF. After laser treatment, all patients healed without adverse events, as bleeding, pain or swelling. In each case, mother reported subjective breastfeeding improvement.

**Conclusion:** to date, laser frenotomy could be considered really effective for the treatment of ankyloglossia in newborns, allowing improvement of patients breastfeeding without risks.

## IMPACT OF COVID-19 PANDEMIC IN MANAGING ORAL HEALTH OF AUTISTIC SPECTRUM DISORDER PATIENTS

Zumbo G., Corridore D., Corvino I., Guaragna M., Perrone A., Battaglia E., Bossù M.

UOC of Pediatric Dentistry Polyclinic Umberto I Sapienza University of Rome, Director Prof. A. Polimeni, Director of the School of Specialization in Pediatric Dentistry Prof. M. Bossù; Department of Odontostomatological and Maxillofacial Sciences, Sapienza University of Rome, Rome, Italy

**Aim:** due to Covid-19 pandemic, in March 2020 assistance in the Pediatric Dentistry and Special Needs Department of Policlinico Umberto I was suspended without notice. Domestic oral health management and support to caregivers was monitored thanks to channels like emails and WhatsApp. Our aim is to evaluate the perception and approval rating of parents and the impact of Covid-19 emergency related to remote oral care management.

**Methods:** parents of children affected by ASD treated in the Department were included; patients' age was between 3 and 18 at their first exam (January 2020); mean age was of 9 ½ y.o. In June 2020, an anonymous online survey was administered to parents through email and WhatsApp channel. Informed consent was taken. Incomplete questionnaires were excluded.

**Results:** 120 questionnaires were analysed. Appointments were: postponed to an undefined date (86.4%), cancelled (10.7%), postponed to a precise date (2.9%), unchanged

(4.1%). Dental urgencies were reported by 19.2%: 41.2% due to difficulty in performing daily oral hygiene, 41.1% due to pain, 11.8% due to abscess and 5.9% due to caries. Among them, 64.3% turned to the referral person in the Department and 14.3% to their doctor. Among the ones not reporting dental urgencies, 50% states that would not know who to turn to in case of need. During pandemic, 30.1% of the parents sought help of the dental team through Telemedicine.

**Conclusion:** covid-19 pandemic caused worsening of public dental service, with consequences on oral health of ASD patients. Telemedicine still struggles to be effective having half of the sample difficulties in using it. This result is not satisfactory yet. Nowadays, Telemedicine is mainly constituted by WhatsApp, emails, and Skype, as instrument to communicate with the doctor, but it is more than this and it can state the difference even when this sanitary emergency will be over.

## LINGUISTIC VALIDATION OF A QUESTIONNAIRE FOR THE DIAGNOSIS OF OSAS IN CHILDREN WITH DS

Agostini L., Mezzofranco L., Bruno G., De Stefani A., Gracco A., Stellini E.

Department of Neuroscience, School of Dentistry, University of Padua, Padua, Italy

**Aim:** obstructive sleep apnoea syndrome (OSAS) is a common clinical condition in which the throat collapses repeatedly during sleep. Down Syndrome (DS) is associated with intellectual disability and characterized by further clinical manifestations. Most of the craniofacial features typical of down syndrome represent a risk factor for OSAS. The aim of this study is the Italian linguistic validation of a questionnaire for the diagnosis of OSAS in children with DS.

**Methods:** a specific questionnaire for the diagnosis of OSAS in children with DS was selected and subjected to translation and adaptation to the Italian version through a process of forward/backward translation. The questionnaire was administered to 110 parents of children with DS, through an online compilation. The last section of the questionnaire was spent on questions on understanding the questionnaire.

**Results:** the understanding of the questionnaire was defined as excellent in 41.8% of the interviewees, good in 56.4%, clarity was excellent in 41.8% and good in 54.5% and precision was excellent in 26.4% and good in 69.1%. Furthermore, 72.7% of the interviewees had no difficulty in filling out the questionnaire.

**Conclusion:** the Italian translation of the questionnaire is considered understandable.

## DENTAL ANOMALIES AND LIFE QUALITY IN CLEFT PALATE PATIENTS: AN OBSERVATIONAL STUDY

Cagidiaco I.<sup>1,2</sup>, Fambrini E.<sup>1,2</sup>, Carli E.<sup>1</sup>, Lardani L.<sup>1</sup>

<sup>1</sup>Department of Surgical, Medical, Molecular and Critical Area Pathology, Unit of Pediatric Dentistry, University of Pisa, Pisa, Italy

<sup>2</sup>Cleft Lip and Palate Center, Plastic and Reconstructive Surgery Unit, Santa Chiara Hospital, Pisa, Italy

**Aim:** to investigate the presence of dental anomalies and the life quality in patients affected by cleft lip/palate.

**Methods:** forty-five patients aged from 6 to 26 years and affected by different types of cleft were included. The presence of dental anomalies was detected by clinical and radiological examination. The OHIP-14 questionnaire was applied for evaluating the life quality of cleft palate patients compared. Patients not affected by cleft, but requiring treatments for various oral health problems were selected as control group. The Chi-Square test was used to evaluate whether the patient's sex or the type of cleft significantly influenced the presence of anomalies. The U Mann-Whitney test was used to evaluate whether there were significant differences between the test group and

the control group in the scores detected by the OHIP-14 questionnaire.

**Results:** agenesis was the most frequent dental anomaly. Microdontia was significantly more represented in males than in females ( $p = 0.02$ ). Significant differences in the recorded scores were detected in 6 out of 14 questions of the OHIP-14 questionnaire. Scores of cleft palate patients were lower of those recorded in the control group.

**Conclusion:** males presented dental anomalies more frequently than females. Mono and bilateral CGPS are more frequently associated with the presence of dental anomalies compared to other cleft types. The life quality associated with oral health problems is better in cleft patients than in the control group.

## OBSTRUCTIVE SLEEP APNEA SYNDROME IN CHILDREN WITH DOWN SYNDROME: A REVIEW OF THE LITERATURE

Chirieleison G., Costa S., Battista M., Nucera R., Portelli M., Militi A.

Department of Biomedical, Dental and Morphological and Functional Imaging Sciences, University of Messina, Messina, Italy

The purpose of this study is to present a thorough overview of the literature regarding obstructive sleep apnea syndrome (OSAS) in the pediatric patient with Down syndrome (DS).

A computer-assisted search was performed in the medical database MEDLINE (from 2009 to 2020). A combination of the following medical subject headings (MESH) were used in the search: "Sleep Apnea, Obstructive," "Down syndrome", "child", "sleep-disordered breathing

Our search yielded a total of 749 articles but only 9 studies were included after exclusion of non-relevant, duplicate, non-English or non-Italian publications and studies about adults with DS, because the risk factors, diagnosis and treatment are different.

The review shows that OSAS manifests itself with higher rates and greater severity in children with DS. OSAS in these patients is associated with complications such as obesity and cardiovascular risk in patients with DS but without congenital cardiovascular diseases. The literature review shows that an

early diagnosis is essential and for this purpose the gold standard is represented by polysomnography. Children with mild to moderate DS and OSAS can benefit from adenotonsillectomy, with OSAS symptoms that should improve after surgery. In most patients (19-73%) this procedure is unable to resolve OSAS, for this reason CPAP can be used. In children with mono or bilateral maxillary contraction, rapid palatal expansion is an effective treatment for OSAS.

This review shows the need for more in-depth studies to further explore the scope of OSAS in patients with DS, including improved screening models that optimize the identification of individuals with OSAS and continued efforts to analyze the results in order to better match the individual patients with personalized treatment plans. Nowadays there are no reliable clinical predictors of sleep respiratory disorders for children with DS and a screening polysomnography from the age of 4 is recommended for these children.

## INCIDENTAL SINUS AND NASAL FINDINGS ON CBCTS OF A PAEDIATRIC ORTHODONTIC POPULATION

Giaccaglia F., Bruno G., De Stefani A., Gracco A.L., Stellini E.

Department of Neuroscience, School of Dentistry, University of Padua, Padua, Italy

**Aim:** nowadays, it's becoming more frequent for an orthodontist to prescribe, for a paediatric patient, a Cone Beam Computed Tomography (CBCT) of the head for orthodontic purposes, such as evaluating impacted teeth or planning a bone-borne palatal expansion procedure.

Despite that, these examinations are often carried out in private dental clinics and evaluated only by the dentist, without consulting a radiologist or an otolaryngologist.

Our aim is to study the prevalence of sinuses and nasal septum abnormalities in a paediatric orthodontic population.

**Methods:** 200 CBCTs were considered, but only 61 respected the inclusion criteria: age of the patient under 15 years old; scans showing all paranasal sinuses and the entire nasal septum; DICOM format.

The following findings were considered: sinus mucosal thickening (defined as any thickening of more than 1 mm and further

categorized into more or less than 4mm); underdevelopment of sinuses; anatomical variations of the ethmoid sinus morphology (Onodi cells, Haller cells); nasal septum deformities.

The included CBCTs were evaluated twice by two different orthodontists and findings were compared and statistically analyzed.

**Results:** the mean age of the patients was 10.7 years old.

More than half of the patients presented a Schneiderian membrane thickening, involving usually both maxillary sinuses.

The most frequent finding was the nasal septum deformity, along with mucosal thickening of the left maxillary sinus. No findings were observed in only 4 CBCTs out of the 61 examined.

**Conclusion:** considered the high prevalence of paranasal sinus and nasal septum abnormalities observed in this study, it appears necessary, for an orthodontist prescribing a CBCT for a paediatric patient, to carefully analyze that exam, in order to identify all those situations that require referral to a specialist.

## SURGICAL TREATMENT OF FRENULECTOMY IN PAEDIATRIC PATIENT WITH ELECTRO SURGICAL UNIT

La Mura G.<sup>1</sup>, Macrì A.<sup>2</sup>, Angileri C.M.<sup>4</sup>, Madeo E.<sup>3</sup>, Caizzi M.<sup>3</sup>, Bagatta S.<sup>3</sup>, Fornarelli G.<sup>1</sup>, Malerba A.<sup>5</sup>

<sup>1</sup>Student - University of Milan, Milan, Italy

<sup>2</sup>Guest Professor - University of Milan, Milan, Italy

<sup>3</sup>Postgraduate Student - University of Milan, Milan, Italy

<sup>4</sup>First level medical director - A.O. Santi Paolo e Carlo, Milan, Italy

<sup>5</sup>Department Head Paediatric Dentistry - A.O. Santi Paolo e Carlo, Milan, Italy

**Aim:** the aim of this report is to show the effectiveness of the electrosurgical unit in the treatment and resolution of tecto labial frenulum (4° class in the classification of Plaket).

**Methods:** a 12-year-old male patient presented with: a tecto labial frenulum (4° class of Plaket, 3° type Sewerin), an incisor diastema of 3 mm and inflammation due to impacted food. The patient demonstrated a poor compliance.

The patient underwent frenulectomy with an electrosurgical device. It was performed under local anaesthesia in an ambulatory setting. One week after the procedure, the tissue was al-

most completely healed and the patient reported very little discomfort after the procedure.

**Results:** thanks to the frenulectomy surgery with the use of the electrosurgical device, the postoperative discomfort and care were significantly improved compared to the traditional approach, with shorter operative time, and the surgical management was easier.

**Conclusion:** according to the international literature, this clinical case demonstrates the effectiveness of the use of the electrosurgical device in the correction of a tecto labial frenulum.

## MARSUPIALIZATION OF ODONTOGENIC CYSTIS IN PEDIATRIC PATIENT

La Mura G.<sup>1</sup>, Macri A.<sup>2</sup>, Angileri C.M.<sup>4</sup>, Madeo E.<sup>3</sup>, Caizzi M.<sup>3</sup>, Bagatta S.<sup>3</sup>, Malerba A.<sup>5</sup>

<sup>1</sup>Student - University of Milan, Milan, Italy

<sup>2</sup>Guest Professor - University of Milan, Milan, Italy

<sup>3</sup>Postgraduate Student - University of Milan, Milan, Italy

<sup>4</sup>First level medical director- A.O. Santi Paolo e Carlo, Milan, Italy

<sup>5</sup>Department Head Pediatric Dentistry - A.O. Santi Paolo e Carlo, Milan, Italy

**Aim:** the aim of this report is to show the combined surgical and orthodontic treatment of dislocated elements due to the pressure of an odontogenic radicular cyst.

**Methods:** a 10-year-old female patient presented at the initial examination: mixed dentition, odontogenic abscess due to a deep carious lesion in the first and second quadrants, and presence of chromogenic bacteria.

On the tac cone beam image appeared a radiotransparent lesion that dislocated elements 23 and 24 from the eruptive pattern, and an absence of 12 due to agenesis and supernumerarity instead of 12. We extracted the elements 54 and 64. Marsu-

pialization of the cyst was performed, intraoperative irrigation with a solution of rifampicin. A drain was left in place for 6 weeks, with instructions to perform daily washes with fisiologic and clorexidine solution. Healing and repositioning of the dental elements were monitored weekly with intraoral radiographs.

**Results:** thanks to the marsupialization of the odontogenic cyst, after 6 weeks we can appreciate a reduction in the diameter of the cyst and a normalization of the eruption pattern of elements 23 was achieved.

**Conclusion:** marsupialization is a viable option in the treatment of radiopaque lesions in the pediatric population.

## A COMPLICATED FACIAL TRAUMA IN A YOUNG PATIENT DURING COVID-19 PANDEMIC

La Mura G.<sup>1</sup>, Angileri C.M.<sup>2</sup>, Macri A.<sup>3</sup>, Madeo E.<sup>4</sup>, Caneva M.<sup>4</sup>, Bagatta S.<sup>4</sup>, Fornarelli G.<sup>1</sup>, Malerba A.<sup>5</sup>

<sup>1</sup>Student - University of Milan, Milan, Italy

<sup>2</sup>First level medical director- A.O. Santi Paolo e Carlo, Milan, Italy

<sup>3</sup>Guest Professor - University of Milan, Milan, Italy

<sup>4</sup>Postgraduate Student - University of Milan, Milan, Italy

<sup>5</sup>Department Head Paediatric Dentistry - A.O. Santi Paolo e Carlo, Milan, Italy

**Aim:** the aim of this report is to present the treatment of a complicated dental-facial trauma during the covid pandemic.

**Methods:** a 17-year-old female patient was sent from our conjunt hospital with facial trauma that had occurred a week earlier. She reported multiple fractures of the nasal bones that required surgery. She was sent to us by our maxillofacial surgery department to treat the dislocation of the 21 11 12. The 21 had a root fracture, the 11 a fracture of the apical third, and the 12 had an infraction compatible with concussion. The elements were repositioned and splinted with a semi-flexible passive splint. Vitality was assessed for all elements with cold test. The patient was

advised to follow a soft diet and to use a clorexidine spray. The patient was monitored with check-ups at weeks 1, 2, 4, and 8, continuously checking pulp vitality and possible signs of infection. The split was removed after 3 months. This length is due to the instability of the fragments and the late intervention after the trauma. Xrays were performed at the 4° and 8° week.

**Results:** elemental vitality was preserved, semistability was achieved, and there is evidence of radiographic healing of the fracture third.

**Conclusion:** in cases of late intervention longer splint are advisable to maintain pulp vitality.

## COMPLICATION OF AN ABSCESS RESULTING IN HOSPITALIZATION DURING COVID-19 LOCKDOWN

La Mura G.<sup>1</sup>, Macrì A.<sup>2</sup>, Angileri C.M.<sup>4</sup>, Romeo S.<sup>3</sup>, Malerba A.<sup>5</sup>

<sup>1</sup>Student - University of Milan, Milan, Italy

<sup>2</sup>Guest Professor - University of Milan, Milan, Italy

<sup>3</sup>Postgraduate Student - University of Milan, Milan, Italy

<sup>4</sup>First level medical director - A.O. Santi Paolo e Carlo, Milan, Italy

<sup>5</sup>Department Head Pediatric Dentistry - A.O. Santi Paolo e Carlo, Milan, Italy

**Aim:** the aim of this report is to present and share the events that led to the hospitalization and surgery of a 10-year-old boy for a complicated odontogenic abscess.

**Methods:** the patient presented to us after several cycles of antibiotic therapy prescribed by the pediatrician with different classes of antibiotics; he had significant swelling of the right region with redness of the antegonial region due to a possible fistula tract of the abscess; he presented with fever and difficulty swallowing; he was not taken to the dentist for several days due to the pandemic situation. The patient had no relevant medical history or known allergies. The patient was not cooperative.

A CT scan of the facial mass with and without contrast was performed, which showed a fistulous path starting from the distal lingual root of element 46, and involvement of the submandibular lodge. It was decided to hospitalize him and dental avulsion. He was sent to the pediatric department for hospitalization and urgent surgery.

**Results:** thanks to urgent surgery, which resulted in extraction of the element and extraoral drainage of the abscess, the patient was discharged from the hospital after one week.

**Conclusion:** when treating pediatric patients, it is essential to keep in mind the serious consequences of untreated dental caries in the pediatric population.

## OZONE THERAPY FOR EARLY CHILDHOOD CARIES (ECC) TREATMENT: A PROSPECTIVE STUDY

Mantoan C.<sup>1</sup>, Manfra A.<sup>1</sup>, Luppi V.<sup>1</sup>, Chermetz M.<sup>1,2</sup>, Cadenaro M.<sup>1,2</sup>

<sup>1</sup>Department of Medical Sciences, Pediatric Dentistry Postgraduate Program, University of Trieste, Trieste, Italy

<sup>2</sup>Institute for Maternal and Child Health, IRCCS Burlo Garofolo, Trieste, Italy

**Aim:** evaluate the effect of ozone therapy on the consistency of decayed dentin in ECC-affected teeth in uncooperative patients and on salivary bacterial count, tooth hypersensitivity and patients' quality of life.

**Methods:** 20 children (3-5 years) uncooperative for conventional restorative treatments were enrolled and treated with weekly 60-s ozone applications for 4 weeks (OzoneDTA, Sweden&Martina). Patients were assessed at baseline (T0), after 4 ozone applications (T1) and 1, 2 and 3 months after treatment (T2, T3, T4). At T0 and T1 dentin was classified according to the Affect-ed Dentine Scale (ADS), salivary bacteria counted using the Saliva Check Mutans Test (GC), hypersensitivity recorded with the Visual Analogue Scale (VAS) and patients' quality of life evaluated with the ECOHIS questionnaire submitted to patients' par-

ents. ADS and VAS were registered also at T2, T3, T4. ADS and salivary tests results were analyzed using non-parametric tests.

**Results:** both ADS score and salivary bacteria count showed statistically significant differences between T0 and T1 ( $p < 0.01$ ). ADS increased from  $3.2 \pm 0.3$  at T0 to  $2.1 \pm 0.6$  at T1. Bacteria count decreased from positive results in 82% cases at T0 to 9% at T1. At T1 tooth hypersensitivity was completely solved and did not reappear over time. A reduction of ECOHIS scores was found at T1 compared to T0.

**Conclusion:** ozone therapy was an effective tool for ECC treatment. By reducing salivary bacteria and improving dentin's consistency it may prevent caries progression, decrease hypersensitivity and improve patients' quality of life in uncooperative children.

## ORAL HYGIENE KNOWLEDGE OF FAMILY MEMBERS AND CARE GIVERS OF PEOPLE WITH DISABILITIES

Ludovichetti F.S., Pillon C., Gobbato E.A., Zuccon A., Stellini E., Mazzoleni S.

Department of Neuroscience, Pediatric Dentistry, University of Padua, Padua, Italy

**Aim:** over a billion people in the world live with some form of disability and this figure is growing due to the increase in life expectancy; with it the caregiver takes on an increasingly important role, being able to promptly identify any need for medical and/or dental treatment. However, in some cases, caregivers can represent an obstacle if they lack of adequate knowledge and commitment. Finally, the aim of this study is to evaluate the level of oral education of family members and operators dedicated to people with disabilities.

**Methods:** the data were collected by means of completely anonymous paper questionnaires, completed by hand. The questionnaires were distributed in the disability service centers in the mu-

nicipalities of the Treviso province and 250 questionnaires were collected, of which 100 were filled in by family members and 150 by operators. The data were analyzed by applying the Chi-square ( $\chi^2$ ) independence test and the Pairwise method for missing data.

**Results:** in the analyzes of tables 7 and 8 there are no significant differences between the responses of the family members and those of the operators ( $P > 0.05$ ) while in all the other analyzes it can be seen that the level of oral education of the family members is generally statistically better.

**Conclusion:** the level of oral education of the family member is better than that of the operator for: brushing frequency, toothbrush replacement and check-ups.

## PARENTAL SATISFACTION OF PBMT IN RECURRENT APHTHOUS STOMATITIS IN CHILDREN

Rosselli L., Bardellini E., Amadori F., Albini G., Majorana A.

Department of Oral Medicine, Dental Clinic, University of Brescia, Brescia, Italy

**Aim:** this study aims to evaluate the effectiveness of the photobiomodulation therapy (PBMT) in the treatment of minor recurrent aphthous stomatitis (MiRAS) in children, in terms of pain relief, lesion size reduction and the parental satisfaction of the therapy.

**Methods:** this randomized controlled study was carried out on 60 children with clinical diagnosis of MiRAS. Patients were randomized into two groups: group A receiving laser therapy and group B receiving sham therapy (placebo). Laser therapy (diode laser,  $\lambda$ : 645 nm) was administered on day 1 (T0) for three consecutive days. Patients were evaluated also on day 4 (T1), on day 7 (T2) and on day 10 (T3). Oral aphthous lesions size was assessed through a periodontal probe to measure the

diameter length (mm); pain was evaluated through the Visual Analogue Scale (VAS); parental satisfaction was assessed through a questionnaire.

**Results:** the difference in the reduction of ulcers diameters between the two groups resulted statistically significant at T1 and at T2 ( $p < 0.05$ ). A statistically significant difference in pain reduction between two groups was found at T1 ( $p < 0.05$ ). No statistically significant difference between the two groups of parents was found as concerns the parental acceptance of the procedure and the discomfort for the need of multiple appointments.

**Conclusion:** PBMT is to be considered effective in the treatment of MiRAS in children and well-accepted by the parents of the children themselves.

## TELEDENTISTRY: AN EFFECTIVE TOOL IN PAEDIATRIC DENTISTRY DURING COVID-19 PANDEMIC

Salerno C., Cirio S., Carrara I., Mbanefo S., Cagetti M.G.

Department of Biomedical, Surgical and Dental Sciences, School of Specialization in Pediatric Dentistry, University of Milan, Milan, Italy

**Aim:** during the COVID-19 pandemic in Italy, especially in the lockdown period, most dental treatments were postponed, except for emergencies, and many private dental offices were closed. This situation led patients with non-urgent oral problems to enlist the help of mobile dental consultations by sending pictures or videos to their dentist or physician. This approach to diagnose and “treat” oral problems is called teledentistry, this method is already validated in literature. The aim of this case report is to present an unusual manifestation of oral candidiasis infection in a 9 years-old child solved through teledentistry.

**Methods:** the patient’s mother sent pictures of her child’s mouth to the clinician via whatsapp, starting from time zero up to 1-month follow-up. This diagnostic and therapeutic strategy

led the clinician to follow the clinical evolution until the resolution of the child’s oral lesion, avoiding face to face visit during Covid-19 pandemic.

**Results:** this case report shows how, in the era of COVID 19 pandemic, teledentistry is an effective tool available to clinicians, that allowed the resolution of an unconventional case of oral pathology.

**Conclusion:** social platforms and modern technology, through the use of high-resolution pictures now available even if at an amateur level, have made possible the anamnestic investigation, the diagnostic framework and the follow-up of a case of oral pathology in a child, when conventional examinations were difficult to perform.

## THE EFFECT OF NUTRACEUTICALS ON ORAL HEALTH IN CHILDREN: A REVIEW

Salerno C., Cirio S., Carrara I., Fornarelli G., Mbanefo S., Cagetti M.G.

Department of Biomedical, Surgical and Dental Sciences, School of Specialization in Pediatric Dentistry, University of Milan, Milan, Italy

**Aim:** nutraceuticals are substances derived from plants, microbial agents and foods that can be integrated into diet with health benefits in addition to the basic nutritional values of foods through the intake of functional foods enriched with nutraceutical substances or in the form of supplements. The integration of these substances into a balanced diet affects oral health of children and adults in different ways: controlling caries development, decreasing enamel defects development, reducing gum inflammation and alterations of the oral mucous membranes.

**Methods:** a review of the literature was conducted aiming to evaluate the impact of nutraceutical substances on oral health of children. PubMed was searched with no time limits using the following key words: “nutraceutical”, “probiotics”, “oral health”, “caries”, “children”, “polyols”, “polyphenols”. Observational studies, RCTs, meta-analysis, reviews, and clinical trial were considered.

**Results:** seventy-two studies were included. Results show that a caries prevention effect is reported for polyols, intensive sweeteners, mineral salts such as fluoride and its compounds, prevention mainstays, universally approved by the literature and by international guidelines, probiotics, vitamins and polyphenols. Polyols, probiotics, vitamins, polyphenols of tea, turmeric, honey, and glycoproteins such as lactoferrin are effective nutraceuticals in increasing periodontal health. A protective effect on oral mucous membranes is played by carotenoids, omega-3 polyunsaturated fatty acids, isoprenoids, probiotics, vitamins and lactoferrin when included in the diet.

**Conclusion:** even if the findings of the present review seem to highlight a role of nutraceuticals in improving oral health, however the effects of these substances in human, especially in children, need to be further studied since a clear evidence of their role is still lacking.

## THE ORAL MICROBIOTA IN OBESE PEDIATRIC PATIENT

Saporito I., Costa S., Bellocchio A., Ciralo L., Portelli M., Nucera R., Militi A.

Department of Biomedical, Dental and Morphological and Functional Imaging Sciences, University of Messina, Messina, Italy

**Aim:** in this systematic review several studies were examined to show an association between the of the oral microbiota composition and obesity in childhood patients.

**Methods:** the search was carried out on several databases, such as PubMed, google scholar, researchgate and were considered both cross-sectional studies and systematic reviews from 2010 to 2018. Sample volumes were characterized by subjects aged between 6 and 17 years, affected by obesity with significant differences in salivary composition or with altered supra- or sub-gingival microbiota, together with the coexisting presence of caries and periodontitis. Study exclusion criteria were age and systemic diseases.

**Results:** a total of 23 bacterial species were present in amounts approximately three times higher in obese subjects than in normal weight controls. In addition, significant changes were observed in salivary concentrations of phosphate, free sialic acid and protein, and peroxidase activity, all favorable

conditions to dental caries. The bacterial flora into the oral cavity seems to have a relevant role in determining obesity during the growth phase. Moreover the amount of free sialic acid, total protein, phosphate and increased peroxidase may promote and increase the dental caries incidence.

**Conclusion:** the data obtained so far show that in these subjects the subgingival microbiota is altered and closely related to a higher incidence of gingivitis or periodontitis. In addition, in overweight patients have been shown alterations in the concentration of sialic acid, phosphorus, peroxidase activity and a lower flow rate of saliva, factors that favor the development of dental caries compared to normal weight individuals. The available data on the pathogenetic mechanism of obesity encourage further studies involving larger populations of obese boys, using saliva as an easily accessible diagnostic medium obtained in a non-invasive manner.

## CLINICAL SUCCESS OF PREFABRICATED PEDIATRIC CROWN: A LITERATURE REVIEW

Ludovichetti F.S., Scatigna M., Piovan S., Menin M., Stellini E., Mazzoleni S.

Neurosciences Department, Dentistry Section, University of Padua, Padua, Italy

**Aim:** the aim of this study is to compare clinical success of pediatric preformed metal crown with pre-veneered metal crowns and pediatric zirconia crowns.

**Methods:** review of studies through searches of keywords "pediatric zirconia crown", "pediatric metal crown", "pediatric crown".

**Results:** analysis of different factors linked to clinical success. The fracture resistance is tested in metal and zirconia crowns and the best results are from the first, but both the crowns are resistant to the children chewing force. Gingival inflammation and bacterial adhesion are more represented in metal crowns. Other complications like decementation or secondary caries

have different results. Esthetic factor is negative for metal crown while have good answers for the zirconia crowns.

**Conclusion:** today traditional metal crowns are still functionally the best for fracture resistance. The necessity of more finishing cause major roughness of the surface respect to zirconia crowns. This change in the surface cause more bacterial adhesion and so more gingival inflammation in metal crowns. Complications like decementation and secondary caries depend on many different factors that make difficult the attribution of the cause only on the material of the crowns. The growing interest in the esthetics has made less acceptable metal crowns, finding in zirconia crowns a new possible valid alternative, that needs more studies.

## CORRELATION BETWEEN ACUTE OTITIS MEDIA AND MALOCCLUSION IN CHILDREN: A PILOT STUDY

Semprini Pironi F., Preite C., Guaragna M., Del Vecchio S., Titone A., Vodola E., Ierardo G., Luzzi V.

Department of Oral and Maxillofacial Science, Unit of Pediatric Dentistry, Director: Prof. A. Polimeni, Sapienza University of Rome, Rome, Italy

**Aim:** this work is a pilot study aimed at highlighting the effects of orthodontic treatment upon acute otitis media.

An interdisciplinary approach with otorhinolaryngologist to solve otitis media should be a main concern for pediatric dentists and orthodontists since AOM is one of the most common childhood infections.

**Methods:** this study examined 15 children with an age range of 3-9 years, who were referred from the Department of Otolaryngology of Policlinico Umberto I Hospital with diagnosis of AOM. The examination used to investigate the auditory problem was impedenzometry. Dental occlusion was analyzed through physical examination, dental models and radiographic exams (orthopantomography and latero-lateral radiograph with cephalometric evaluation). Vertical, sagittal and transver-

sal problems were evaluated so that the most adequate treatment could be conducted.

**Results:** after 8 months of therapy, the patients underwent a second otolaryngologist's examination. The results showed a reduction of the number of type B tympanograms and an increase of type A tympanograms. Furthermore, despite all children at the beginning had positive anamnesis for AOM, after treatment no episodes of AOM were referred by 12 patients.

**Conclusion:** the data of this study demonstrated a significance statistical correlation between orthodontic treatment and the improvement of impedenzometry results, meaning a positive effect on AOM. However, no statistical correlation was found between the correction of the skeletal class, deep bite and cross bite and impedenzometry results, this may be due to the small sample size.

## THE ROLE OF INFORMATION IN DENTAL TRAUMATOLOGY IN CHILDREN AND ADOLESCENTS

Signoriello A.G., Piova S., Di Fiore A., Fioretti A., Zuccon A., Ludovichetti F.S.

Neurosciences Department, Dentistry Section, University of Padua, Padua, Italy

**Aim:** a dental trauma is the consequence of an accidental event damaging the hard and supporting structures of the tooth. It can cause both aesthetic and functional problems, with a possible impact on the patient's quality of life. The aim of this study is to investigate the knowledge and preparation of parents, guardians, teachers, sports coaches regarding dental trauma in children and adolescents between 0 and 16 years.

**Methods:** this study is based on the online publication, from 24 January 2020 to 3 September 2020, of an anonymous questionnaire consisting of 17 multiple choice questions, to which a sample consisting of 993 subjects answered. The data were analyzed individually and by crossing several variables for the purpose of statistical analysis. The investigation was supported by the search for scientific material in the literature on PubMed-Medline.

**Results:** 76.6% of the sample claims to have already heard of "dental trauma", but this is not enough to possess adequate knowledge about it, as can be seen from the fact that 63.3% of the same sample is not a knowledge of the existence of predisposing factors and the majority do not know the correct methods of conservation of a fragment (64.4%) / tooth (67.77%) and the importance of timing in the treatment of this emergency. On the other hand, there is a greater awareness in the management of nutrition and hygiene following a trauma.

**Conclusion:** the study reveals a lack of knowledge in the management of this dental emergency and, therefore, there is the need for a spread for information purposes targeted and aimed at those who, on a daily basis, interact with children and adolescents in these age groups, in order to preserve their oral and psycho-physical health.

## TREATMENT AND FOLLOW UP OF AN AVULSED PERMANENT TOOTH WITH OPEN APEX: A CASE REPORT

Sperelli F., Silvestri S., Battaglia E., Iaculli F., Di Giorgio G., Salucci A.

Department of Oral and Maxillo-Facial Sciences, Unit of Pediatric Dentistry, Director: Prof. A. Polimeni, Postgraduate School of Pediatric Dentistry, Director: Prof. M. Bossù, Sapienza University of Rome, Rome, Italy

**Aim:** nowadays, as evidenced by the scientific literature in pediatric dentistry, dental trauma is the second cause of urgency after caries. Dental avulsion, i.e. the complete falling out of the tooth from its cavity due to a trauma, is a common event among children.

**Methods:** our study was based on the analysis of the clinical case of an eight-year-old boy, who reported a trauma causing the complete avulsion of element 1.1 and the crown-root fracture of dentin and enamel of element 2.1. The patients underwent a quick replanting intervention, 30 minutes post-trauma, and a subsequent orthodontic splint.

Both elements resulted negative upon vitality examination. Moreover, the periapical radiographic analysis showed a slight area of radiolucency on the vestibular bone layer of the root of element 1.1. A month later, due to an aggressive external root resorption showed by x-ray analysis, the patient underwent an endodontic

treatment with a calcium-hydroxide-based dressing and a temporary IRM filling. Three weeks after, apical plug with bioactive cements (MTA), according to international protocols, was carried out. Then, a week later, once the material was completely hardened, the root canal was backfilled with thermoplastic gutta-percha and the crown was restored with composite resins.

**Results:** six months later, the periapical radiograph showed a good adaptability of the used materials and the absence of periapical lesions. Two years after the trauma, the dental elements did not show any mobility or periapical abscess. However, element 1.1 displayed a slight root resorption and a decreased coronal height probably due to ankylosis.

**Conclusion:** the diagnosis, the type of treatment and the timeliness of intervention would define the prognosis, that, as in our case, was also strictly related to the maturity of the root and to the condition of the periodontal ligament.

## REVISION OF DENTAL TRAUMATOLOGY DURING SARS-COV-19 EPIDEMIC IN MARCHE REGIONAL HOSPITAL

Tesei A.<sup>1</sup>, Morini M.<sup>1</sup>, Berlin R.S.<sup>1</sup>, Di Bari R.<sup>1</sup>, Mascitti M.<sup>2</sup>, Nori A.<sup>1</sup>

<sup>1</sup>Department of Surgical and Special Odontostomatology, Umberto I General Hospital, Ancona, Italy

<sup>2</sup>Department of Clinical Specialistic and Dental Sciences, Marche Polytechnic University, Ancona, Italy

**Aim:** dental traumatology in children is a topic of great importance due to the spread and frequency of episodes. The main localization concerns the upper frontal group, whose involvement increases in the presence of increased overjet, which in the event of a direct hit facilitates the exposure of the upper power plants; conversely, a deep bite can increase the risk in the event of an indirect blow. Trauma in deciduous dentition can have consequences on the underlying permanent element such as small abrasions, up to real injuries, and laceration. The Sars-Cov-19 epidemic has radically changed the daily habits of the younger age groups, more present in the home setting resulting in a distance from school and sports activities with a consequent decrease in the prevalence of dental trauma, especially in children in these contexts.

**Methods:** this retrospective study analyzes the cases of access to the dental emergency room at the "Ospedali Riuniti" hospital,

Ancona, from March to December 2020. The records of the department for access to the emergency room of pediatric patients for dental trauma were examined. A qualitative analysis was conducted on the characteristics of the patients, the elements involved and the type of trauma. The extrapolated data were then compared to the available literature prior to the analysis.

**Results:** in the period under review, 37 accesses for dental trauma in pediatric age were recorded. The mean age of the patients at the time of the visit was 122.5 months with a majority of the male gender (63%) over the female one (37%). Element 5.1 was involved in 51% of patients and 6.1 in 37%. Dislocation was diagnosed in 52% of cases (18), fracture in 23%, avulsion and intrusion in 14% and 11% respectively.

**Conclusion:** the management of pediatric dental trauma can be difficult to implement in this period. Guidelines remain the reference for clinical practice.

## COST-EFFECTIVENESS ANALYSIS OF DENTAL TREATMENTS ON PEDIATRIC PATIENTS IN M.A.C. AND G.A.

Tesei A.<sup>1</sup>, Luconi E.<sup>2</sup>, Mascitti M.<sup>2</sup>, Togni L.<sup>2</sup>, Barlattani A.<sup>3</sup>, Panzarella V.<sup>4</sup>, Tozzo P.<sup>4</sup>, Zhurakivska K.<sup>5</sup>, Nori A.<sup>1</sup>

<sup>1</sup>Department of Surgical and Special Odontostomatology, Umberto I General Hospital, Ancona, Italy

<sup>2</sup>Department of Clinical Specialistic and Dental Sciences, Marche Polytechnic University, Ancona, Italy

<sup>3</sup>Department of Clinical Sciences and Translational Medicine, Tor Vergata University, Rome, Italy

<sup>4</sup>Department of Surgical, Oncological and Oral Sciences (DiChirOnS), University of Palermo, Palermo, Italy

<sup>5</sup>Department of Clinical and Experimental Medicine, University of Foggia, Foggia, Italy

**Aim:** patient behavioral control has always been the most critical point in pediatric dentistry. The aim of this study was to perform a cost-effectiveness analysis of dental therapies in pediatric patients in monitored anesthesia care (MAC) and general anesthesia (GA) at the regional hospital “Ospedali Riuniti” of Ancona.

**Methods:** data from patients treated under GA at the hospital were collected between 2018 and 2020. Only those patients who received dental treatments codified according to ICD9CM 23.19 (dental extraction) and 23.2 (dental restoration) were included. The treatment plan was normalized using Relative Based Value Units (RBVU). The data related to the social costs of the treatments were estimated based on the average per capita income in the municipality of residence of the patient, ac-

ording to the Italian National Institute of Statistics (ISTAT). Using a cost-minimization model, we calculated the direct and social costs of GA and simulated the same costs of MAC; subsequently, the results were compared with regression analyses.

**Results:** the sample under examination included 37 patients. The mean cost of a GA treatment was € 1317.97. In the MAC model, social costs were influenced by the RBVU value by more than 80% ( $R^2 = 0.84$ ). The cut-off beyond which MAC exceeds GA in total costs was € 1393.60, corresponding to 2.14 operating room sessions.

**Conclusion:** there is a need to study new analysis models to be adapted to our reality, to optimize the means available to public health and to rationalize the current provision of services of public dentistry in the pediatric field.

## ORTHODONTIC CONSEQUENCES OF TRAUMAS IN DEVELOPMENT AGE

Titone A., Del Vecchio S., Semprini Pironi F., Guaragna M., Preite C., Vodola E., Ierardo G., Luzzi V.

Department of Oral and Maxillofacial Science, Unit of Pediatric Dentistry, Director: Prof. A. Polimeni, Sapienza University of Rome, Rome, Italy

**Aim:** the study proposes an overall view on orthodontic consequences deriving from traumatic injuries in pediatric patients in order to identify an optimal therapeutic approach for each possible disorder.

**Methods:** through the review of PubMed® articles, we classified the traumatic injuries and determined their consequences on the stomatognathic system; subsequently we identified – among the various options of treatment – the ones which could bring greater benefit to the patient.

**Results:** the skeletal consequences, essentially related to mandibular condyle fractures, are in most cases treated with conservative therapy and early mobilization of the mandible to minimize any limitation of movement; cases of asymmetric deficit involve the distraction of the hypoplastic condyle from the glenoid fossa to stimulate its growth through asymmetric

functional devices. The repercussions on the alveolar-dental system are mainly manifested by ankylosis, or early loss of the element; an intrusive dislocation on deciduous elements can lead to inclusions and ectopias.

From an orthodontic point of view, all these conditions lead to inclusions with a space reduction in the arch, therefore alterations in occlusion and skeletal development.

The therapy aims to achieve a regular development of jaws by proposing the use of devices like Maryland, palatal bars or expanders, lingual arches or lip bumpers, that allow the maintenance or recovery of space without ignoring the aesthetic factor.

**Conclusion:** identifying and preventing the possible consequences of a trauma in the pediatric age allows us to minimize functional and aesthetic late complications.

## MOLAR INCISOR HYPOMINERALIZATION: PERCEPTION AND OPERATIONAL STRATEGIES OF TUSCAN DENTISTS

Vitale S., Lardani L., Pasini M., Giuca M.R.

Department of Surgical, Medical, Molecular and Critical Area Pathology, Unit of Pediatric Dentistry, University of Pisa, Pisa, Italy

**Aim:** to investigate the knowledge and operational strategies of Tuscan dentists and compare any differences in the responses between pediatric dentists and general dentists, and the differences between expert dentists and young dentists.

**Methods:** a questionnaire was sent by email to Tuscan dentists.

The answers were collected anonymously and were statistically analyzed.

The questionnaire was divided into a first part in which general information on the participants was requested, a second part in which 4 different clinical cases with various treatment options were presented, a third part where the aetiological factors and different diagnosis of MIH was investigated and finally the difficulties encountered in managing the disease

**Results:** pediatric dentists and young dentists claimed to prefer prophylaxis therapy, remineralizing substances, and they were very careful to the aesthetic requests of the patients. Instead, general dentists, especially those who have been practicing for many years, if possible, they did not intervene, or they relied on traditional composite materials.

Pediatric dentists demonstrated a greater preparation regarding the aetiology and differential diagnosis of MIH, although dentists with less than 10 years' work experience admitted a certain difficulty in performing a correct differential diagnosis.

**Conclusion:** dentists involved in the study considered MIH a very complex pathology for clinical and therapeutic management. Significant differences were observed between pediatric and general dentists and between expert and young operators.

## INDIRECT PULP TREATMENT IN A NON-ERUPTED FIRST PERMANENT MOLAR: A 7 YEARS FOLLOW-UP

Zaffarano L.<sup>1</sup>, Angelino E.<sup>1</sup>, Romeo S.<sup>1</sup>, Campus G.<sup>2</sup>, Cagetti M.G.<sup>1</sup>

<sup>1</sup>Paediatric Dentistry, University of Milan, Milan, Italy

<sup>2</sup>Restorative Dentistry, University of Bern, Bern, Switzerland

**Aim:** the aim of an indirect pulp treatment (IPT) is to preserve pulp vitality. More conservative pulp management has the potential to reduce the need of a more invasive endodontic treatment. In case of carious pulp exposure, the successful outcome of a direct pulp capping will be substantially reduced. In case of an immature permanent tooth the endodontic management will be substantially more complex.

**Methods:** a 7 year old female patient reported discomfort associated with thermal stimulation on the permanent maxillary left first molar. The clinical inspection revealed a deep occlusal lesion with dentine exposure in cavity greater than half of the

dental surfaces. The tooth was not erupted with occlusal surface under the gingival level. A relative isolation with retraction cord and cotton rolls was obtained. A selective caries removal until leathery dentine and a restoration with a bulk flow composite and a bulk packable composite was performed.

**Results:** after 7 years, no radiographic or clinical signs and symptoms of endodontic involvement are present.

**Conclusion:** with the proper indications, indirect pulp treatment, especially in case of immature permanent teeth, could be considered a great opportunity to perform a "child-oriented" clinical decision.

## SILVER DIAMINE FLUORIDE (SDF) IN PRIMARY POSTERIOR TEETH: A SYSTEMATIC REVIEW

Zaffarano L.<sup>1</sup>, Angelino E.<sup>1</sup>, Romeo S.<sup>1</sup>, Campus G.<sup>2</sup>, Cagetti M.G.<sup>1</sup>

<sup>1</sup>Paediatric Dentistry, University of Milan, Milan, Italy

<sup>2</sup>Restorative Dentistry, University of Bern, Bern, Switzerland

**Aim:** to evaluate whether Silver Diamine Fluoride (SDF) is effective in arresting dentine caries lesion in posterior primary teeth when compared to other non-restorative treatments.

**Methods:** this is a systematic review of randomized controlled trials. Searches were performed in 4 electronic databases, 1 register of ongoing trials, 1 register of “grey literature”, reference lists of identified review articles. Two researchers carried out data extraction and quality appraisal. Disagreements were resolved by a third reviewer or a consensus/based discussion. The primary outcome was the arrest of caries lesions comparing different cariostatic agents and different protocols.

**Results:** researchers find 843 records. Only 5 R.C.T were included. One trial compared SDF 38% every 6 month to Sodium Fluoride (NaF) varnish 5% every 6 month. One trial compared

SDF 25% every 6 month with NaF 5% to SDF 25% every 6 month with NaF 5% containing tricalcium phosphate (tTCP). One trial compared Nano Silver Fluoride (NSF) once a year to control. One trial compared different concentration of SDF (12% vs 38%) and different frequency of application (every 6 months vs every 12 months). The last trial compared SDF 38% every month for 4 times to every three months for 3 times, to every six months for 2 times. After 12 months of follow-up, in comparison to placebo and fluoride varnish, SDF applications significantly reduces the mean active caries surfaces (OR 3.51).

**Conclusion:** when applied to caries lesions in posterior primary teeth, SDF compared to no treatment or FV appears to effectively arrest active dentine caries in posterior primary teeth. However, more homogeneity of protocols are needed.

## COMPLEX ELECTROMAGNETIC FIELDS AND CANDIDA ALBICANS: AN *IN VITRO* STUDY

Petrini M.<sup>1</sup>, Biferi V.<sup>1</sup>, Iezzi G.<sup>1</sup>, Cipollina A.<sup>2</sup>, Di Campli E.<sup>2</sup>, Piattelli A.<sup>1</sup>, D'Ercole S.<sup>1</sup>

<sup>1</sup>Department of Medical, Oral and Biotechnological Sciences, University of Chieti, Chieti, Italy

<sup>2</sup>Department of Pharmacy, University of Chieti, Chieti, Italy

**Aim:** *Candida albicans* is a common member of the human microbiota but a variety of predisposing local and systemic factors lead its transition from the commensal to the pathogenic forms. Local factors include the use of dentures, periodontal disease and xerostomia, whereas systemic factors include immunosuppressed states, endocrine dysfunction such as diabetes and broad-spectrum antimicrobials. Due to the problem of antifungal resistance rising, which is threatening our ability to treat common mycotic diseases, the aim of this study is to investigate the effects of C.M.F antibacterial program on the *Candida Albicans* count (CFU) and metabolism.

**Methods:** *Candida albicans* was cultured and incubated under aerobic conditions. A positive control and two test groups were established. The application of multi-frequency magnetic fields of variable intensity, frequency and wave form (C.M.F

slim version, Medicina Fisica Integrata, Italy) was administered once on the first test group of planktonic yeasts and twice on the second test group respectively. At the end of each treatment, the samples were checked, diluted and plated on Sabourad-Agar plates and the number of colonies forming units per milliliter CFU/ml was determined. In addition, the spectrophotometric quantification of INT formazan concentration in each sample was performed to assess the metabolic activity.

**Results:** microbiological analysis showed that C.M.F promoted a significant reduction of *Candida* CFUs and metabolism, independently by the number of repetitions of the antibacterial program applied.

**Conclusion:** C.M.F seems to have antifungal action against *Candida albicans* and could be a promising technology for treating candidiasis infections.

## AWARENESS OF DRUG-RELATED ONJ RISK: A PRELIMINARY LITERATURE REVIEW

Botta A., Capocci M., Corridore D., Ndokaj A., Pasqualotto D., Ripari F., Guerra F., Ottolenghi L.

Department of Oral and Maxillofacial Sciences, Sapienza University of Rome, Rome, Italy

**Aim:** antiresorptive drugs (AR) use has grown considerably during the last 30 years. BP are among the 20 most prescribed drugs in the world. Because of their peculiar mechanism of action, BP result often concentrate in the bone tissue such as jaws. In presence of concomitant conditions, they can induce a septic osteonecrosis named Medication Related Osteonecrosis of the Jaws (MRONJ). As per today, the level of incidence of the disease remains still not fully clarified. Aim of the study is to elucidate the level of awareness of MRONJ among General Medical Practitioners, Medical Doctor Specialists, General Dental Practitioners, Medical and Dental Students and Patients.

**Methods:** a literature review of the last 10 years conducted on the following sources: PubMed, Medline, Scopus, Cochrane Library, SICMF-SIPMO 2020 guidelines, AIFA and EMA pharmacovigilance sections and CIOMS website.

**Results:** in the considered whole medical population the level of knowledge of BP therapy and awareness of the potential related problems resulted not adequate. Patients correctly referred to the dental visit by prescribers was around 30%, indicating an unsatisfactory knowledge of MRONJ primary and secondary prevention guidelines. Students' group showed limited and unsatisfying level of knowledge for both class of drugs and risk factors. However, an increase of knowledge through the 10-years' time period considered has been registered. Patient information leaflet resulted in 38% the only source of patients' information.

**Conclusion:** main objective to adequately contrast MRONJ is an appropriate prevention program mostly based on specific increase of the adequate level of knowledge. This could be achieved by specific training commitment during the dentist and doctor's education period and thereafter, and appropriate time dedicated to doctor-patient dialogue for an adequate transfer of information.

## DIGITAL TECHNOLOGY SUPPORTING PATIENTS WITH AUTISM SPECTRUM DISORDER

Capotosti I., Lardani L., Pardossi F., Pasini M., Giuca M.R.

Department of Surgical, Medical, Molecular and Critical Area Pathology, Unit of Pediatric Dentistry, University of Pisa, Pisa, Italy

**Aim:** this study aims to evaluate the domiciliary and the professional oral care, the frequency of tooth brushing and the level of compliance of each patient affected by ASDs during the dedicated dental pathway that includes the use of the application “Il mio Dentista” as a support from the evaluation (T1) to the re-evaluation (T5) dates.

**Methods:** after establish inclusion and exclusion criteria, 100 patients (78 male and 22 females) with diagnosed Autism Spectrum Disorder (ASDs) have been recruited into the study with age ranging from 7 to 22 years related to the University by Pisa. We evaluated the plaque index (IP), gingival index (IG), the dmft/DMFT, the frequency of tooth brushing, the frequency of snack of each patient. We evaluated the Frankl Scale, a behavioral scale based on a classification. Based on specific pa-

rameters, each patient has been individually reassessed after five visits from the first one.

The T test was used to compare the parameters before and after the inclusion in the dedicated dental pathway.

**Results:** from T1 to T5 we found a significant improvement of the IP, IG and of the frequency of tooth brushing. Concerning the frequency of snack and the parameter dmft/DMFT the difference in the observed averages were not significant. The difference in collaboration between T1 and T5 evaluated by the Frankl scale was statistically significant.

**Conclusion:** we have shown that the personalized digital supports can have a key role for success in familiarization and desensitization process of the patient affected by ASDs, leading an increase in his/her collaboration.

## DRUGS AND ORAL HEALTH IN INSTITUTIONALIZED ELDERLY

Carossa M.<sup>1</sup>, Ceruti P.<sup>1</sup>, Gassino L.<sup>2</sup>, Bassi F.<sup>1</sup>

<sup>1</sup>C.I.R Dental School, Department of Surgical Sciences, University of Turin, Turin, Italy

<sup>2</sup>University of Fernando Pessoa, Oporto, Portugal

**Aim:** the aim of the present study was to evaluate the influence of pharmacological treatment on oral health in institutionalized elderly people.

**Methods:** 403 residents of eight nursing homes in the city of Turin underwent the following procedures: 1) recording of past and present health history and pharmacological treatment using questionnaires and, when available, examining clinical records: 2) assessment of oral condition by administration of questionnaires of feeding, mastication, saliva, dental status (A.M.S.P), of mental status (S.P.M.S.Q.), and of nutrition (MNA= Mini Nutritional Assessment); 3) clinical examination: evaluation of oral hygiene, residual elements, dentures conditions, palpation of masticatory muscles and assessment of TMJ status.

**Results:** oral condition of the subjects were very poor, with high prevalence of decreased salivation, changes in taste, decreased denture stability, poor oral hygiene. Over 95% of the

subjects was under pharmacological treatment. The most significant effect of drugs on oral health was decreased salivary flow, with consequent dentures instability. Changes of taste were strongly associated with treatment with sedatives, anti-diabetic and angiotensin converting enzyme inhibitors. Taste was also influenced by wearing or not dentures. Since nearly all of the subjects had poor oral hygiene, the influence of specific drugs on the development of dental plaque or calculus could not be assessed. A significant association was found between poor nutritional status and anti-diabetic and antihypertensive drugs.

**Conclusion:** when prescribing pharmacological treatments to elderly patients, physician should account for the possible adverse effects of drugs on oral health. Public health services should be alerted on the poor oral conditions of the institutionalized elderly and should organize a close odontoiatric surveillance.

## ORAL HEALTH AND SLEEP DISEASES IN INSTITUTIONALIZED ELDERLY

Carossa M.<sup>1</sup>, Ceruti P.<sup>1</sup>, Gassino L.<sup>2</sup>, Bassi F.<sup>1</sup>

<sup>1</sup>C.I.R Dental School, Department of Surgical Sciences, University of Turin, Turin, Italy

<sup>2</sup>University of Fernando Pessoa, Oporto, Portugal

**Aim:** respiratory disorders during sleep, particularly obstructive sleep apnea (OSA), are increasingly recognised. These disorders are favoured by age and by conditions that decrease the retropharyngeal spaces such as micrognathia. A recent observation suggests that edentulism, by decreasing the vertical dimension, is a risk factor for OSA. The aim of this study was to evaluate the prevalence of respiratory sleep disturbances, assessed by questionnaires, in relation to edentulism in institutionalized elderly people.

**Methods:** to this aim, 403 residents in eight nursing homes in the city of Turin, 307 woman and 96 men, underwent clinical oral examination and recording of a sleep questionnaire. This allowed to assess the presence of snoring, sleep disturbances and their influence on daily activities and to calculate a score that expressed total sleep disturbances (SDS). To evaluate the

influence of oral status on sleep disturbances, the SDS was related to dental conditions.

**Results:** most of the subjects (71%) were completely edentulous and 34% of them did not wear any dentures. These subjects had significantly greater prevalence of dyspnea on awakening. Decreased occlusal vertical dimension was significantly associated with high SDS ( $p < 0,005$ ). These findings support the hypothesis that edentulism contributes to the development of respiratory disturbances during sleep, probably by decreasing the occlusal vertical dimension and thus favouring OSAS.

**Conclusion:** considering the high prevalence of edentulism among elderly people and the increased morbidity and mortality associated with OSA, It seems important to promote a careful odontoiatric surveillance in the geriatric population.

## AN ALTERNATIVE “TROJAN HORSE” HYPOTHESIS FOR COVID-19

Laudadio C.<sup>1</sup>, Patano A.<sup>1</sup>, Malcangi G.<sup>1</sup>, Colocchia G.<sup>1</sup>, Marinelli G.<sup>1</sup>, Limongelli L.<sup>1</sup>, Inchingolo A.D.<sup>1</sup>, Montenegro V.<sup>1</sup>, D’Oria M.T.<sup>1</sup>, Hazballa D.<sup>1</sup>, Corsalini M.<sup>1</sup>, Dipalma G.<sup>1</sup>, Inchingolo F.<sup>1</sup>, Di Venere D.<sup>1</sup>, Balzanelli M.G.<sup>2</sup>, Distratis P.<sup>2</sup>, Kieu Nguyen C.D.<sup>1,2</sup>, Gargiulo Isacco C.<sup>1,2</sup>, Farronato M.<sup>3</sup>, Tartaglia G.<sup>3</sup>.

Complex Operative Unit of Odontostomatology Director: Prof. G. Favia

<sup>1</sup>Specialization School in Orthognatodontics Director: Prof. F. Inchingolo, Interdisciplinary Department of Medicine D.I.M. University of Bari Aldo Moro, Bari, Italy

<sup>2</sup>SET-118, Department of Pre-hospital and Emergency, SG Giuseppe Moscati Hospital, Taranto, Italy

<sup>3</sup>Department of Biomedical, Surgical and Dental Sciences, School of Dentistry, University of Milan. UOC Maxillo-Facial Surgery and Dentistry. Fondazione IRCCS Ca’ Granda, Ospedale Maggiore Policlinico, Milan, Italy

**Aim:** the coronavirus disease 2019 (COVID-19) pandemic was a challenge for emergency care units worldwide. The severe thromboembolism often described as systemic complications contradistinguished by a blend of severe inflammatory-infectious patterns often concluded into a multi-organ failure (MOF) and death.

**Methods:** we proposed an atypical scenario that involves two co-existing possible events, the virus-bacteria/fungi co-infection based on the “Trojan horse” hypothesis and the down-regulation of IL-10 as the reasons of acute massive inflammation and uncontrolled cytokine storm. Bacteria and virus crosstalk has been confirmed and might happen in different ways becoming a topic of great interest.

**Results:** the “Trojan horse” hypothesis would describe how Sars-CoV-2 could be capable of infiltrating into host immune cells as macrophages/glia cells and neutrophils together with fungi or bacteria scattering a secondary infection and a devastating im-

mune reaction. We speculated that Sars-CoV-2 has the ability to enter into an M1 via its ACer and start sabotaging their Arpin mechanism which is the core of M1 phagocytic mechanism. Therefore, once subverted the Arpin system the Sars-CoV-2 allow the connection with a second pathogen towards the lung interstices. The second specific trait of COVID-19 known as “cytokine storm” lead by IL-6 we hypothesized could depend on the lack of IL-10, due to gene polymorphisms (SNPs).

**Conclusion:** the Sars-CoV-2 is equipped with very ingenious mechanisms of attack, defense and invasion. The hypothetical though very truthful scenario considers its ability to use at its own desire a host carrier “Trojan horse”, which we speculate a macrophage and drives it towards lung alveoli; secondly, the host predisposition of lacking an effective anti-inflammatory response due to specific polymorphisms of the gene regulates the expression of IL-10.

## PERIPHERAL OXYGEN SATURATION VARIATION WEARING FACE MASKS DURING COVID-19 PANDEMIC

Laureti A., Alessandri-Bonetti A., Mangino G., Gallenzi P.

Dental School-Dean: Prof M. Cordaro, A. Gemelli Foundation, IRCCS - Catholic University of Sacred Heart, Rome, Italy

**Aim:** since the spread of SARS-CoV2 pandemic, a growing use of facemasks have been required.

Dentist has been reported to be the profession at the highest risk for COVID-19 and dental doctors have been forced to work with and increased number of safety protection devices (SPD), including the use of a Filtering Face Piece-2 (FFP2) under the traditional surgical mask.

The aim of this study is to investigate whether a variation in cardiovascular parameters such as peripheral oxygen saturation (Spo2) and heart rate (HR) is observed with a prolonged use of the FFP2 compared to surgical mask use only.

**Materials:** dental workers have been recruited from the A. Gemelli Hospital and Spo2 and HR have been recorded with a finger attached pulse oximeter at regular intervals: before wearing the FFP2 mask, after 30 minutes, after 1 hour and at the end of the day. Two measures were performed for each time point at 5 minutes distance and the median value was re-

corded for that period. The same measurements were performed on dental workers who wore surgical masks only. A decrease in Spo2 of 3% or more was considered significant. Mean differences in Spo2 were calculated with 95% confidence interval.

**Results:** forty dental workers were enrolled in the study; 30 subjects wore surgical and FFP2 masks and 10 subjects wore surgical masks only. The results showed that a variation in both Spo2 and HR are present at different measurements, but no statistically significant differences were found at different time points either in patients wearing FFP2 or in those wearing surgical mask.

**Conclusion:** no difference in Spo2 or HR have been observed in dental workers wearing FFP2 masks when compared to those wearing surgical masks. Therefore, FFP2 masks should be considered an essential SPD with no side effects on cardiovascular system.

## PREVENTION IN DENTAL HYGIENE DURING INFANT AGE: SURVEY ON COMMUNICATION WITH PARENTS

Ludovichetti F.S., Cavallari F., Gobbato E.A., Fioretti A., Di Fiore A., Mazzoleni S., Zuccon A.

Neurosciences Department, Dentistry Section, University of Padua, Padua, Italy

**Aim:** the aim of this cognitive survey is to investigate the knowledge regarding the basic notions of dental hygiene of parents and guardians of children aged between 0 and 1.

**Methods:** this study was based on the online publication from 10/01/2020 to 02/09/2020, of a questionnaire comprising 19 multiple choice questions, to which 1088 subjects answered. They were consequently analyzed, by crossing several variables, for the purpose of a statistical analysis. The investigation was supported by numerous scientific studies published in PubMed-Medline.

**Results:** among the results that emerged, 52.8% assert that they have never received any indication from the pediatrician to go to a dental office for a first pediatric visit, 64.9% do not

have the basic knowledge regarding directions to follow in the pre-eruptive period. 53.5% admit that they are not aware of prevention methods during the period of tooth eruption. 80.1% admit that they have not received information on the risks of poor oral hygiene during pregnancy.

**Conclusion:** prevention plays a fundamental role in maintaining oral health and this study confirms that communication with patients is still weak and not yet sufficient. Many parents are aware of the basics of home hygiene but have not been educated about the risks involved with poor oral hygiene. Environments such as family, school, in which younger subjects live, can and must contribute to education and prevention in dental hygiene.

## SARS-COV-2 DISEASE: HOW TO PREVENT INFECTIONS WITH ADJUVANT THERAPIES AND SUPPLEMENTS

Malcangi G.<sup>1</sup>, Patano A.<sup>1</sup>, Hazballa D.<sup>1</sup>, Laudadio C.<sup>1</sup>, Coloccia G.<sup>1</sup>, Marinelli G.<sup>1</sup>, Limongelli L.<sup>1</sup>, Inchingolo A.D.<sup>1</sup>, Montenegro V.<sup>1</sup>, D'Oria M.T.<sup>1</sup>, Dipalma G.<sup>1</sup>, Inchingolo F.<sup>1</sup>, Di Venere D.<sup>1</sup>, Farronato M.<sup>2</sup>, Tartaglia G.<sup>2</sup>

Complex Operative Unit of Odontostomatology Director: Prof. G. Favia

<sup>1</sup>Specialization School in Orthognatodontics, Director: Prof. F. Inchingolo, Interdisciplinary Department of Medicine D.I.M. University of Bari Aldo Moro, Bari, Italy

<sup>2</sup>Department of Biomedical, Surgical and Dental Sciences, School of Dentistry, University of Milan. UOC Maxillo-Facial Surgery and Dentistry. Fondazione IRCCS Ca' Granda, Ospedale Maggiore Policlinico, Milan, Italy

**Introduction:** the SARS-CoV-2 (Severe acute respiratory syndrome coronavirus 2) is the virus responsible for the recent pandemic COVID 19 declared all over the world by the World Health Organisation. The infection is mainly caused by a severe systemic and respiratory disease, which needs a clinical treatment with multidrug therapy.

**Aim:** currently it does not exist a specific pharmacological therapy for the treatment of the disease COVID-19.

The aim of this investigation is to assess the effect of the adjuvant therapies and the supplements for the SARS-CoV-2 infection which may provide a support therapy to treat the symptoms by trying to prevent the respiratory insufficiency.

**Methods:** the advantages of EK1C4 have been assessed (intranasal spray produced by China based on a peptide linked to a cholesterol molecule), the ENDOVIR STOP (intraoral spray based on polyphenols), the Resveratrol (RSV), Vitamin D and Melatonin, Lianhuaqingwen (LHQW) based on herbal extracts, produced by the Chinese Medicine, as adjuvant supplements for the prognosis and the clinical ongoing of the long-term patients.

**Results:** the substances assessed have reported meaningful advantages for the improvement of the immune system and they have acted as inhibitor molecules against the SARS-CoV-2.

## NOVEL ORIENTATION FOR INFECTION PREVENTION: ENDOVIR STOP SPRAY

Malcangi G.<sup>1</sup>, Patano A.<sup>1</sup>, Hazballa D.<sup>1</sup>, Laudadio C.<sup>1</sup>, Coloccia G.<sup>1</sup>, Marinelli G.<sup>1</sup>, Limongelli L.<sup>1</sup>, Inchingolo A.D.<sup>1</sup>, Montenegro V.<sup>1</sup>, D'Oria M.T.<sup>1</sup>, Dipalma G.<sup>1</sup>, Inchingolo F.<sup>1</sup>, Di Venere D.<sup>1</sup>, Farronato M.<sup>2</sup>, Tartaglia G.<sup>2</sup>

Complex Operative Unit of Odontostomatology Director: Prof. G. Favia

<sup>1</sup>Specialization School in Orthognatodontics Director: Prof. F. Inchingolo, Interdisciplinary Department of Medicine D.I.M. University of Bari Aldo Moro, Bari, Italy

<sup>2</sup>Department of Biomedical, Surgical and Dental Sciences, School of Dentistry, University of Milan. UOC Maxillo-Facial Surgery and Dentistry. Fondazione IRCCS Ca' Granda, Ospedale Maggiore Policlinico, Milan, Italy

**Introduction:** the two main processes which influence the SARS-CoV-2 pathogenesis are:

1. the entry of cells through endocytosis;
2. the trigger factor of an exaggerated inflammatory response.

**Aim:** the aim of this work is to introduce a natural product, the ENDOVIR STOP SPRAY, based on cyclodextrins and polyphenols, which may block the entry of the virus SARS-CoV-2 through the receptors ACE2 and lipid raft, with a specific substance which may destroy the virus SARS-CoV-2 in the first entry ways. The two proteins, ACE2 and TMPRSS2, are placed within the lipid raft, rich in cholesterol, of the cellular membrane.

**Methods:** the ENDOVIR STOP, produced by the Ebtna-Lab of the Gruppo Magi from Bolzano, is a food supplement, in form of spray, based on Alfa-cyclodextrin (mg 1,5). able to destroy

the sphingolipids, which, together with the cholesterol, form the lipid rafts where ACE2 is and hydroxytyrosol (mg 1,5), substance extracted by olive leaves and fruit with anti-inflammatory and antioxidant properties. The protocol includes a prophylaxis of 4 sprays per day (0,5ml): one in each nostril and two in the oral cavity, avoiding to introduce food immediately after. Distancing, face masks, cleaning gel and vaccine remain the priority recommendations.

**Results:** it was found that these natural molecules impede the virus SARS-CoV-2 entry according to the endocytosis process lipid-raft-mediated by reducing the risk of infection of the other viral respiratory tracts, included the Sars-Cov-2.

**Conclusion:** the study of the new natural molecules by the scientific community may help in preventing many diseases.

## COVID AND CHILDREN

Malcangi G.<sup>1</sup>, Patano A.<sup>1</sup>, Hazballa D.<sup>1</sup>, Laudadio C.<sup>1</sup>, Colocchia G.<sup>1</sup>, Marinelli G.<sup>1</sup>, Limongelli L.<sup>1</sup>, Inchingolo A.D.<sup>1</sup>, Montenegro V.<sup>1</sup>, D'Oria M.T.<sup>1</sup>, Dipalma G.<sup>1</sup>, Inchingolo F.<sup>1</sup>, Di Venere D.<sup>1</sup>, Farronato M.<sup>2</sup>, Tartaglia G.<sup>2</sup>

Complex Operative Unit of Odontostomatology Director: Prof. G. Favia

<sup>1</sup>Specialization School in Orthognatodontics Director: Prof. F. Inchingolo, Interdisciplinary Department of Medicine D.I.M. University of Bari Aldo Moro, Bari, Italy

<sup>2</sup>Department of Biomedical, Surgical and Dental Sciences, School of Dentistry, University of Milan. UOC Maxillo-Facial Surgery and Dentistry. Fondazione IRCCS Ca' Granda, Ospedale Maggiore Policlinico, Milan, Italy

**Aim:** scientific data show that the infection caused by the SARS-CoV-2 is expressed with a more favourable clinical course in paediatric patients than the adult with a lower mortality rate (0,06% in 0-15 years group age).

**Methods:** in Italian population the paediatric cases confirmed are 1.8% (during the phase of block, passed to 8,5% in transition phase (average age of 11 years slightly prevalent in male genre: 13% hospitalised, 3.5% in intensive care unit): The risk is inversely proportional to age and in case of comorbidity. The 0,6% of babies are symptomatic, and the 50% of them is less than 1 year. There is a correlation between the SARS-CoV-2 and a new syndrome: Acute Multisystem inflammatory syndrome (MIS-C) prevalent in teenagers, characterised by abdominal symptoms and left-ventricular systolic dysfunction.

**Results:** in symptomatic or paucisymptomatic babies, the SARS-CoV-2 remains more time in the upper respiratory ways and in faeces with not frequent symptoms in adults: more secretions in the upper respiratory ways and gastroenteritis which encourage the spreading of virus through the orofecal and respiratory ways.

The diffusion is higher in secondary schools as well as primary, while in pre-school it is almost absent.

There is a higher risk of infection among babies and teenagers in the English variant of SARS-CoV-2 B.1.1.7.

**Conclusion:** outbreaks at school are due to the lack of respect for prevention rules (hand washing, distancing, use of face mask). It is important to vaccinate babies for a coverage of 80% to obtain the herd immunity.

## SARS-COV-2 AND COVID 19. WHY PANDEMIC?

Malcangi G.<sup>1</sup>, Patano A.<sup>1</sup>, Hazballa D.<sup>1</sup>, Laudadio C.<sup>1</sup>, Colocchia G.<sup>1</sup>, Marinelli G.<sup>1</sup>, Limongelli L.<sup>1</sup>, Inchingolo A.D.<sup>1</sup>, Montenegro V.<sup>1</sup>, D'Oria M.T.<sup>1</sup>, Dipalma G.<sup>1</sup>, Inchingolo F.<sup>1</sup>, Di Venere D.<sup>1</sup>, Farronato M.<sup>2</sup>, Tartaglia G.<sup>2</sup>

Complex Operative Unit of Odontostomatology Director: Prof. G. Favia

<sup>1</sup>Specialization School in Orthognatodontics Director: Prof. F. Inchingolo, Interdisciplinary Department of Medicine D.I.M. University of Bari Aldo Moro, Bari, Italy

<sup>2</sup>Department of Biomedical, Surgical and Dental Sciences, School of Dentistry, University of Milan. UOC Maxillo-Facial Surgery and Dentistry. Fondazione IRCCS Ca' Granda, Ospedale Maggiore Policlinico, Milan, Italy

**Aim:** the aim of this study is to show the entry process and the reasons why the SARS-CoV-2 is highly contagious.

**Methods:** the ACE2 receptor (angiotensin-converting enzyme 2), Furin and TMPRSS2 of the host cell are involved in the entry process and infection of the SARS-CoV-2.

**Results:** ACE2 is a very important receptor for SARS-CoV-2, it is on the mucosa of almost all organs (16) (mouth, nose, throat, lungs, small intestine, colon, lymph nodes, thymus, bone marrow, spleen, liver, kidney, brain, heart (especially on the endothelium of the coronary walls and smooth muscle cells of the vessels walls).

The ACE2 receptors are involved in the renin-angiotensin system (RAS). The renin regulates the blood pressure and encourages the transformation of the angiotensinogen in angiotensin I.

The ACE2 receptor which degrades the angiotensin II in angiotensin (1-7), attacked by the virus, reduces this process.

Furin and TMPRSS2 are protease which are in many human tissues. The SARS-CoV-2 detects a cleavage site similar to the Furin between two subunits S1 and S2.

The Spike(S) proteins on the pericapsid, are made by 2 subunits S1 and S2. The S1 links the receptor-binding domain (RDB) of the ACE2 on the target cell. Simultaneously, the serin protease TMPRSS2 and the Furin determine a change of the structure of the S2 allowing the fusion with the membrane of the host cell allowing the access of the transfer of the viral content.

**Conclusion:** ACE2, Furin and TMPRSS2 are considerably present in the lung tissue, in the intestine and liver, this would make those organs as potential target of the 2019-nCoV infection.

## VACCINES AND COVID 19

Malcangi G.<sup>1</sup>, Inchingolo A.D.<sup>1</sup>, Hazballa D.<sup>1</sup>, Patano A.<sup>1</sup>, Laudadio C.<sup>1</sup>, Colocchia G.<sup>1</sup>, Marinelli G.<sup>1</sup>, Limongelli L.<sup>1</sup>, Montenegro V.<sup>1</sup>, D'Oria M.T.<sup>1</sup>, Inchingolo A.M.<sup>1</sup>, Corsalini M.<sup>1</sup>, Dipalma G.<sup>1</sup>, Inchingolo F.<sup>1</sup>, Di Venere D.<sup>1</sup>, Romeo M.<sup>1</sup>, Farronato M.<sup>2</sup>, Tartaglia G.<sup>2</sup>

Complex Operative Unit of Odontostomatology Director: Prof. G. Favia

<sup>1</sup>Specialization School in Orthognatodontics Director: Prof. F. Inchingolo, Interdisciplinary Department of Medicine D.I.M. University of Bari Aldo Moro, Bari, Italy

<sup>2</sup>Department of Biomedical, Surgical and Dental Sciences, School of Dentistry, University of Milan. UOC Maxillo-Facial Surgery and Dentistry. Fondazione IRCCS Ca' Granda, Ospedale Maggiore Policlinico, Milan, Italy

**Aim:** since December 2020, more than 200 vaccines (V) applied for COVID-19 under development. Few of them have obtained the authorisation by the European Medicine Agency (EMA) and Agenzia Italiana del Farmaco (AIFA).

**Methods:** types of vaccines:

- with a whole virus or bacteria (inactivated V., attenuated V., vectorial viral V);
- with parts of germ or virus which activate the immune system (subunit V.);
- with genetic material to produce specific proteins (nucleic acids DNA or mRNA V.).

**Results:** authorized vaccines:

21 December 2020 mRNA Pfizer-BioNTech V., encapsulated in lipid nanoparticles (LNP), code the antigen of the glycoprotein spike (S) of SARS-CoV-2.

2 doses i.m.(30 µg, da 0,3ml per dose) at 21 days of distance, people aged ≥ 16 years. Efficacy 95%, is conserved at -70°C / 6 months; 2-8°C / 5 days.

18 January 2021 Moderna mRNA V., encapsulated in LNP. Administered in people aged ≥ 18 years, 2 doses i.m. (100 µg, 0,5 ml per dose) at 28 days of distance. Efficacy 94,1%. It is conserved at -20 °C /6 months; 2-8°C /30 days.

29 January 2021 AstraZeneca V., non-replicating viral vector, (ADV) uses adenovirus from chimpanzees. Administered in people aged ≥ 18 years, 2 doses i.m. at 4-12 weeks of distance. Efficacy 70%; it is conserved at 2-8 °C /6 months.

27 February 2021 USA Johnson & Johnson V. (Ad26.CO2), human adenovirus vector, of stereotype 26, which expresses the spike protein (S) of SARS-CoV-2.

Single dose, age ≥ 18 years, is conserved at -20 °C / 2 years, 2-8°C/ three months, efficacy 66%.

**Conclusion:** according to the European Commission and with authorization of the European Medicine Agency (EMA), the vaccines available in 2021 should be: Pfizer-BioNTechm, Moderna, Astra Zeneca, Sanofi-Gsk, Janssen Pharmaceutical Companies of Johnson & Johnson, Curevac.

## INFLUENCE OF COVID-19 PANDEMIC ON DENTAL STUDENT CLINICAL TRAINING AND PSYCHOLOGICAL STATE

Carpegna G., Multari S., Alovisi M., Comba A., Scotti N., Pasqualini D., Berutti E.

Department of Surgical Science, Dental School Department of Endodontic and Restorative Dentistry, University of Turin, Turin, Italy

**Aim:** the Coronavirus-19 (COVID-19) pandemic has been an unprecedented time which changed resources availability and students' clinical practiced and routines. Stress-related symptoms such as anxiety and depression are reported in previous infectious-diseases outbreaks. The questionnaire proposed wants to evaluate if anxiety and depression symptoms among dentistry undergraduate students and their clinical training worsened during the pandemic.

**Methods:** 161 dentistry students from the University of Turin recruited through mailing list were asked to answer a survey about their psychological status during the pandemic. Impact on daily practice, sleep disorders, clinical training, university assessments and future concerns were investigated through

the Hospital Anxiety and Depression Scale (HADS), the Pittsburgh Sleep Quality Index (PSQI) and Perceived Stress Scale (PSS, by Sheldon Cohen).

**Results:** the students had a mean age of 23 ± 2 y and 56,8% were women. They were evenly distributed throughout years' class. Dental student exhibited signs of worsening anxiety and depression as measured by the overall HADS score (median 11 for anxiety [IQR 10 to 12] versus median 8 for depression [IQR 6 to 11] respectively). HADS score worsened among students from fourth to sixth year of the degree program. 86% of the respondents reported a bad impact on their university assessment, difficulties in keeping the level of attention high during lessons and concentrating during individ-

ual study. However, more than half of the students didn't refer a reduction of quality of the lessons, even if not in presence, while the majorities showed worries about the substantial decrease of clinical training.

**Conclusion:** the COVID-19 pandemic has impacted the daily practice of dental students and had important far-reaching consequences for their health and well-being. Future studies should confirm the long-term effects of these findings.

## IN VITRO ANTIBACTERIAL ACTIVITY OF TWO MOUTHWASHES AGAINST STREPTOCOCCUS SALIVARIUS M18

Amadori F., Bardellini E., Quaranta A., Albini G., Marella P., Majorana A.

Pediatric Dentistry Department, School of Specialization in Pediatric Dentistry, University of Brescia, Brescia, Italy

**Aim:** to investigate the antibacterial activity of chlorhexidine-containing mouthwashes (either 0.20% and 0.12%) against oral probiotic *Streptococcus salivarius* M18 (SSM18), in comparison with a new chlorhexidine-free mouthwash containing hydroxyapatite micro clusters and Zinc-PCA (Pyrrolidone Carboxylic Acid).

**Methods:** the antibacterial effect of examined mouthwashes were tested in agar diffusion assay. A soft Mitis salivarius agar was prepared and added with 2% sucrose and with *Streptococcus salivarius* M18. All mouthwashes were tested in different concentrations (pure, 1:2, 1:5, 1:10, 1:50, 1:100). Inhibition of bacterial growth was observed by the formation of halos with no visible bacteria, measured in mm. Each test was repeated five times, to evaluate specific antibacterial efficacy of each mouthwash.

**Results:** chlorhexidine-containing mouthwashes showed antibacterial activity at all tested concentrations against oral probiotic SSM18, even at low concentrations, mean values of inhibition ha-

los being 12,0 mm (11,1 – 13,0) and 11,5 mm (10,9 – 11,9) for pure mouthwash and 5,8 mm (5,6 – 6,0) and 5,2 mm (5,0 – 5,3) for 1:100, at 0,20% and 0,12% respectively. On the other hand, chlorhexidine-free mouthwash showed also an antibacterial activity against *Streptococcus salivarius* M18, but with lower rates and only at high concentrations, mean values being 5,4 mm (5,3 – 5,5) and 0,0 mm, pure and 1:100 respectively. The difference at each concentration was statistically significant (U Mann-Whitney test,  $p < 0,05$ ). The minimum concentration of chlorhexidine-free mouthwash at which inhibition against SSM18 could be detected was 1:50 (2,2 mm, range 0,0 – 2,5).

**Conclusion:** the preliminary results suggest that this new antiseptic chlorhexidine-free mouthwash containing hydroxyapatite micro clusters and Zinc-PCA might be prescribed both in the short term or during probiotic assumption, without interfering with SSM18 activity.

## CLINICAL AND DIAGNOSTIC FINDINGS IN COVID-19 PATIENTS: AN ORIGINAL SEARCH

Romeo M.<sup>1</sup>, Patano A.<sup>1</sup>, Laudadio C.<sup>1</sup>, Malcangi G.<sup>1</sup>, Coloccia G.<sup>1</sup>, Marinelli G.<sup>1</sup>, Limongelli L.<sup>1</sup>, Inchingolo A.D.<sup>1</sup>, Montenegro V.<sup>1</sup>, D'Oria M.T.<sup>1</sup>, Hazballa D.<sup>1</sup>, Corsalini M.<sup>1</sup>, Dipalma G.<sup>1</sup>, Inchingolo F.<sup>1</sup>, Di Venere D.<sup>1</sup>, Balzanelli M.G.<sup>2</sup>, Distratis P.<sup>2</sup>, Kieu Nguyen C.D.<sup>1,2</sup>, Gargiulo Isacco C.<sup>1,2</sup>, Farronato M.<sup>3</sup>, Tartaglia G.<sup>3</sup>

Complex Operative Unit of Odontostomatology Director: Prof. G. Favia

<sup>1</sup>Specialization School in Orthognatodontics Director: Prof. F. Inchingolo, Interdisciplinary Department of Medicine D.I.M. University of Bari Aldo Moro, Bari, Italy

<sup>2</sup>SET-118, Department of Pre-hospital and Emergency - SG Giuseppe Moscati Hospital, Taranto City, Italy

<sup>3</sup>Department of Biomedical, Surgical and Dental Sciences, School of Dentistry, University of Milan. UOC Maxillo-Facial Surgery and Dentistry. Fondazione IRCCS Ca' Granda, Ospedale Maggiore Policlinico, Milan, Italy

**Aim:** the aim of this study conducted by 118 Emergency Pre-Hospital and Emergency Department in the SG Moscati Hospital of Taranto was to set up a procedure for a rapid diagnose of COVID-19.

**Methods:** admitted patients showed two criteria, positive to the nasopharyngeal swab assessed by reverse-transcriptase-

polymerase-chain-reaction (RT-PCR) and lung ground glass opacity assessed by CT-scan image. Patients were divided into four groups, positive-positive (ER-PP), negative-positive (ER-NP), negative-negative (ER-NN) and a group admitted to the ICU (ER-IC). A further control group was added when the T and B lymphocyte subsets were analyzed. Data included gen-

der, age, vital signs, arterial blood gas analysis (ABG), laboratory results with microbiology and bronchoalveolar lavage fluid (BALF) were analyzed.

**Results:** main traits of COVID-19 were as follow, males significantly higher in PP, ICU, and NP groups, from 2 to 4-fold higher than females with a marked alkalotic, hypoxic, hypocapnia ABG profile in hyperventilation at the time of admission. These patients showed low lymphocytes, high fibrinogen, high ESR, high CRP, low eGFR, low vitamin D and high IL-6 with reduced total number of CD4<sup>+</sup> and CD8<sup>+</sup> T cells phenotypes.

The uncontrolled pro-inflammatory response lead by IL-6, the unrestrained accumulation of mucous within lung interstices have been related to uncontrolled activity of neutrophils, T cells, and local polarized M1 macrophages in response to virus. The neutrophil extracellular trap (NET) a viscous sediment in in the bronchoalveolar area was the main obstruction and the typical feature of “Ground glass opacity” in CT-scan images of COVID-19 patients.

**Conclusion:** the ABG analysis is able to identify COVID-19 infection even in absence of naso-pharyngeal swab test and thoracic CT-scan, allowing to start a timely life-safer treatment.

## THE PERCEPTION OF COVID-19 AMONG DENTAL PATIENTS: FROM THE FIRST LOCKDOWN TO TODAY

Martina S.<sup>1</sup>, Scelza G.<sup>1</sup>, Amato A<sup>1</sup>, Rongo R.<sup>2</sup>, Amato M.<sup>1</sup>

<sup>1</sup>Department of Medicine, Surgery and Dentistry Scuola Medica Salernitana, University of Salerno, Baronissi, Italy

<sup>2</sup>Department of Neurosciences, Reproductive Sciences and Oral Sciences, University of Naples Federico II, Naples, Italy

**Aim:** the present study aimed to investigate the patients’ perception of the dental practice during the COVID-19 outbreak, comparing the impression of patients at the end of the first lockdown, which lasted from March to May 2020, with the current condition.

**Methods:** two online questionnaires were submitted to Italian dental patients on May 2020 and on March 2021 with items about their perceived risks when going to the dentist, the Patient Health Questionnaire-4 (PHQ-4), and the onset of temporomandibular disorders (TMD).

**Results:** 1566 subjects completed the first survey, while 1556 subjects carried out the second one. After the first lockdown, 55.3% of participants thought the risk of contracting the COVID-19 infection was higher in a dental practice, whereas in March 2021 only 43.5% still believed this. However,

on May 2020, 57.1% of patients felt comfortable going back to the dentist, and, on March 2021, 62.4% of patients confirmed that they attended a dental practice in the last months.

The PHQ-4 score changed from 4.0 in May 2020 to 4.6 in March 2021, showing an overall increase in anxiety, depression and distress in the population. After the first lockdown, there was a slight increase in the frequency of TMD pain, and the incidence seems to have raised over the last year (33.4% versus 22.7%).

**Conclusion:** on May 2020, most of the participants believed that the dental practice is a place at greater risk of contracting COVID-19, but this perception decreased on March 2021. The prevalence of TMD pain and the PHQ-4 values in the population increased during the pandemic.

## FAST TRACKING DENTAL OUTPATIENT WITH HEALTH VULNERABILITY IN COVID PANDEMIC

Troiano A., Corridore D., Forte C., Mazur M., Capocci M., Ripari F., Guerra F., Ottolenghi L.

Department of Odontostomatological and Maxillofacial Sciences, Policlinico Umberto I in Rome, Rome, Italy

**Aim:** the primary aim of the project is to ensure priority access to second-level dental care for vulnerable NH outpatients, overcoming waiting lists barriers. The second objective is a specific health promotion-oriented annual recall plan, pro-active model, changing the waiting healthcare approach an initiative health-

care model. The Dental Fast Track outlines a model of intervention which is also effective in Covid-19 emergency.

**Methods:** through the Root Causes Analysis, the critical issues of care pathway were identified, and the vulnerable patient flowchart was organized, related to the outpatients attending

Rome Umberto I Dental clinic in January-June 2019. The fast-track project started from the analysis of patient flow and their effective priority care, followed by the opening of dedicated agendas (fast lanes/fast track) for second level visits, also considering the change of the traditional model induced by Covid-19 pandemic.

**Results:** following international guidelines, a strictly personal safety procedure was implemented regarding devices, intervention time and disinfection. To protect vulnerable patients, a first pre-diagnostic approach with telemedicine was envisaged, lim-

iting access to clinical facilities, with lower potential contagion risk. Patient were then sent directly to second level operative visit, to set up the therapeutic diagnostic path directly.

**Conclusion:** the Fast-track model could improve quality of care, by managerial control, long term resource-savings, limitation of waiting list, increasing health outcome and satisfaction of vulnerable patients. The project, adapted to the current timing and procedures for the Covid-19 emergency, can be considered a starting point for the management of the NH Dental facilities, emphasizing the centrality of the vulnerable patient.

## DENTAL AND SKELETAL CHARACTERISTICS IN PATIENTS WITH TURNER SYNDROME: A CASE SERIES

Venco J., Tagliente A., Chiamenti B., Pozzani E.

Special Care Dentistry Department, Marzana Hospital, Ulss 9, Verona, Italy

**Aim:** to evaluate alterations of oral functions, dental and skeletal characteristics in patients with Turner Syndrome (T S) in preventing the occurrence of oral complications. The study analyses 4 cases of T S in order to list anomalies of oral district.

**Methods:** case report of 4 patients between 20-45 years with diagnosis of T S Data collection is based on orthopantomography, clinic observations and anamnesis. The Authors analyse size and shape of teeth, quality of teeth tissue, cephalometric parameters with teleradiography and oral functions.

**Results:**

- Dental alterations: microsomal teeth in each four cases, amelogenesis imperfecta in 2 cases.
- Skeletal alterations: High arch palate, maxillary transverse deficiency, mandibular retrusion, anterior open bite.
- Alterations in oral functions and oral district: dysfunctional swallowing, adenoid hypertrophy with difficulties in breathing, OSAS high risk, oral myofunctional disorders, psychomotors disorders of speech productions.

**Conclusion:** T S is involved in oral diseases and all patients present alterations related with oral myofunctional disorder. Early diagnosis and preventive approach are important to modify wrong habits and stimulate a healthy development. No patient went under general anesthesia to treat oral problems, because all patients offered good collaboration in the dental office.

Clinicians have obtained their collaboration with periodic follow-up in our dental clinic, even if all patients present cognitive delay, through an individualized approach.

Primary prevention consists of noncariogenic diet, correct everyday home oral hygiene, periodic dental follow-up, orthodontic early treatment, to prevent maxillary deficiency and open bite.

Good oral health is fundamental in T S, considering congenital heart disease. Only with an interdisciplinary collaboration between all the physicians involved in rehabilitation, these patients can achieve a good lifelong quality of life.

## IMPACT OF A SCHOOL-BASED EDUCATIONAL INTERVENTION ON ORAL HEALTH

Vilbi G., Lodi G., Cagetti M.G.

Department of Biomedical, Surgical and Dental Sciences, University of Milan, Milan, Italy

**Aim:** the aim of this paper is to evaluate the effectiveness of a school-based oral health promotion program, carried out in primary schools. The work analyses data collected from students who have or have not received an educational program in order to assess the differences in oral hygiene habits, self-perceived oral health and knowledge.

**Methods:** an educational intervention, annually repeated, was carried out between 2014-15 and 2018-19 in two primary schools, involving all the students attending the last year of course. Then, in 2020, a public online questionnaire was created to investigate the following aspects: oral hygiene and eating habits, self-perception of oral health, risk factors that play a role on oral health.

**Result:** 470 subjects answered the questionnaire. Responders were divided in a) those who took part in some oral health promotion projects during their school career and those who had never participated in it and b) students who attended the

two schools involved in this promotional program and subjects of the same age who attended other schools where health promotion programs are not carried-out. Both comparisons show that subjects who took part in a school-based program reported to be less used to high-risk behaviours like smoking and alcohol consumption (non-smokers 95% vs 86%, non-drinkers 69% vs 39%) and reported to suffer toothache and gum bleeding less frequently than their peers who did not receive the promotional program (toothache 26% vs 37%, gum bleeding 21% vs 36%).

**Conclusion:** even if no scientific evidence of the effectiveness of oral health promotion in school is reported in literature, this work shows a positive effect on some high-risk habits and self-reported oral health status. Complete and integrated educational program on oral health, involving different school levels, would be desirable to improve oral health in future generations.

## ACCURACY EVALUATION OF DENTAL MOVEMENTS IN CLEAR ALIGNER THERAPY

Amato E., Fazio M., Crivello L., Scardina G.A., Messina P., Bilello G.

Department of Surgical, Oncological and Oral Sciences, University of Palermo, Palermo, Italy

**Aim:** in the last decade, the use of orthodontic aligners has been growing. This work aimed to evaluate the predictability of tooth movements obtained with these devices thanks to data analysis in literature.

**Methods:** this systematic review was carried out following the PRISMA guidelines and analysing both electronic databases (i.e. PubMed) and orthodontic journals (i.e. Angle Orthodontist, American Journal of Orthodontics) from 2009 to the present day. Invisalign was the aligner company considered in 80% of articles analyzed. Keywords used were: “clear aligners” “predictability” “accuracy” “orthodontic tooth movements”.

**Results:** 10 articles were analysed after passing a strict selection and each one received quality evaluation. In the past an accuracy of 41% was attributed to the aligners, whereas today it has increased to 73.6%, but it still does not reach 100%, in fact not all the results obtained with clear aligners were found to be accurate in the same way. Linear movements (mesiodis-

tal and vestibulingual tipping) were more predictable, arch expansion was tested with different outcomes, while extrusion and angular movements (rotation) were more difficult to achieve with clear aligners. In particular, the least predictable movement was the rotation of the mandibular canines (54.2%), followed by the rotation of the lower premolars or all the other teeth. Moreover, rotation > 15° were considered less predictable. While moderate and severe crowding could be successfully resolved with clear aligners. Among authors, there is certain agreement on the clinical irrelevance of the discrepancies between projected and real dental movements, which brings them to believe that overall results are predictable.

**Conclusion:** all of the papers analysed showed that some movements are more predictable than others are. Nevertheless, considering the high heterogeneity of the available publications, it is strongly needed to produce some homogeneous clinical data that will allow to draw more reliable conclusions.

## SINERGY BETWEEN CLEAR ALIGNERS AND AUXILIARY FEATURES IN DEEP BITE RESOLUTION: A CASE REPORT

Fazio M., Amato E., Crivello L., Messina P., Scardina G.A., Bilello G.

Department of Surgical, Oncological and Oral Sciences, University of Palermo, Palermo, Italy

**Aim:** in this work, we tested the efficacy of Invisalign auxiliaries during treatment of deep bite malocclusion with crowding and implant space opening needed. Severe deep bite resolution can be challenging and require long-lasting treatments even when complete control of biomechanics is maintained throughout the therapy. Often, when aligners are used, several refinements are needed to complete overbite correction.

**Methods:** a 31 years-old female patient came to our attention complaining about poor aesthetics of her smile and absence of one tooth. After evaluation of photos, 3D casts and cephalometry execution, we observed deep bite, moderate crowding in lower arch and need for opening the implant space for reposition of tooth #3.5. Initial Little’s Irregularity Index was calculated to be 8,5 and initial dental overbite was 77%, while the space for tooth repositioning started with a width of 3,2mm. Given treatment complexity, case resolution needed the employment of several auxiliary features as bite ramps, power ridges, precision cut for elastic use and different types of attachments.

**Results:** deep bite and crowding resolution and implant space opening were obtained through 17 upper and 28 lower aligners (changed every 7 days) and took 7 months to complete.

At the end of the treatment, which needed no refinements, Little’s Irregularity Index passed from 8,5 to 0,5, dental overbite from 77% to 31% and we obtained a 7,1 mm-wide implant space.

The use of auxiliaries significantly improved aligners’ biomechanics. In particular, power ridges allowed performing incisor intrusion maintaining correct torque, while bite ramps provided fundamental adjunctive force to deep bite opening. II class elastics supported space opening by countering unwanted distalization of tooth #3.6.

**Conclusion:** authors believe that combining aligners with correct prescription and use of auxiliary features was a key factor in reaching treatment goals in a short time-frame without need for refinements and giving to the patient the comfort and aesthetics typical of clear aligners.

## CLEAR ALIGNERS TREATMENT (CAT) IN A PATIENT TREATED FOR PERIODONTAL DISEASE

Arrigo M., Chiarello G., Maina G., Parrini S., Deregibus A., Castroflorio T.

Department of Surgical Sciences, School of Specialization in Orthodontics, Dental School, University of Turin, Turin, Italy

**Aim:** the aim of the study is to describe a patient with periodontitis, surgically treated for periodontal disease and then treated, with clear aligners treatment (CAT) to minimize the orthodontics-related negative effects on periodontal health.

**Methods:** a 45-year-old female patient with severe periodontitis and important loss bone, presented FMBS 38% and FMPS 81%, 57 BoF, 21 teeth with PPD > 4, 20 with PPD > 6, 51 with PPD 4-5 and 67 with PPD ≤ 3. The treatment started with four extractions of severally compromised elements then a resective surgery therapy. After surgery the patient presented acceptable periodontal disease index: FMBS 18%, FMPS 17%, 25 BoF, 14 teeth with PPD > 4, 6 with PPD > 6, 25 with PPD 4-5 and 83 with PPD ≤ 3, so she started orthodontic therapy with CA and with a mandibular orthodontic mini screw implant to

upright 47. Meanwhile six bone implants have been inserted and, at the end, upper and lower fixed retainers have been placed.

**Results:** four years after resective surgery the patient presented a good periodontal status. CAT has been demonstrated to be a safer procedure, for periodontal tissues, than fixed appliance treatment techniques, thanks to the removable nature of CAT, facilitating oral hygiene procedures, and to the reduced amount of plaque retentive surfaces.

**Conclusion:** in periodontally compromised patients an ortho-perio integrated approach is recommended. In terms of quantity and quality of plaque and in terms of improvement of periodontal indexes, CAT is highly recommended, rather than fixed appliance treatment.

## EFFECTS OF MAD IN CASE OF SEVERE OBSTRUCTIVE SLEEP APNEA SYNDROME: A THERAPY NOTE

Bellocchio A.M., Portelli M., Nastro Siniscalchi E., Caputo A., Militi A., Squillacioti A., De Ponte F.S., Nucera R.

Department of Biomedical Sciences, Dentistry and Morphological and Functional Imaging, University of Messina, Messina, Italy

**Aim:** mandibular Advancing Device (MAD) modify mandibular spatial position and increase the patency of the rhino-oro-pharyngeal airways space. MAD are usually indicated in cases of mild and moderate OSAS, however the most recent guidelines of international scientific societies provide for the use of these devices even in patients with severe OSAS who refuse C-PAP therapy. The aim of our study was to verify the increase in rhino-or-pharyngeal airspace in a patient suffering of severe OSAS and treated with MAD.

**Methods:** a 62-year-old male patient with severe OSAS underwent polysomnography and head and neck CT examination using a low dose protocol at pre-treatment (T0) and 4 weeks after therapy (T1). An original device was used consisting of two PET-G masks, in the thickness of which rare

earth magnets were inserted at the level of canine-molar region, whose attraction ensured mandibular advancement. CT images were processed using Dolphin 3D software (Dolphin Imaging & Management Solutions, Chatsworth, U.S.A.) and the total volume of rhino-oro-pharyngeal airspace was calculated.

**Results:** the hypo-apnea index measured by polysomnographic examination at T1 was lower than at T0, while the total volume of rhino-or-pharyngeal airspace at T1 was significantly increased compared to T0.

**Conclusion:** advancement devices mandibular are able to produce clinically relevant effects even in cases of severe OSAS, therefore they can represent a valid alternative in patients who refuse treatment with C-PAP.

## COMPARISON OF MASTICATORY EFFICIENCY IN SUBJECT WITH AND WITHOUT CLEAR ALIGNERS

Bocchieri S.<sup>1</sup>, Marullo F.<sup>1</sup>, Davanzo M.<sup>1</sup>, Del Fatti V.<sup>1</sup>, Mauceri F.<sup>2</sup>, Levrini L.<sup>3</sup>

<sup>1</sup>Postgraduate Program in Orthodontics, Department of Medicine and Surgery, University of Insubria, Varese-Como, Italy

<sup>2</sup>Private Practice, Como, Italy

<sup>3</sup>Director of Postgraduate Program in Orthodontics, Department of Human Sciences, Innovation and Territory, University of Insubria, Varese-Como, Italy

**Aim:** the purpose of the current investigation is to evaluate the masticatory efficiency of subjects with clear aligners, to evaluate if these devices are suitable to be worn even during meals, to increase wearing time, and therefore the effectiveness of the treatment.

**Methods:** 37 subjects in treatment with clear aligners were randomly selected for an inter-control test. Every subject was asked to chew for 20 seconds an almond of known weight while wearing an aligner (test group - TG). The procedure was repeated after 5 minutes without aligners (control group - CG). After every process, patients had to spit into a funnel with a filter at the bottom and to rinse several times; at the end, an inspection of the oral cavity was performed to verify that no residues were

left. Every filter with the chewed almond inside was dried in the oven at 130 ° for 30 minutes to restore the initial hygrometry of the almond. After desiccation, the rests were weighed with a precision balance with a sensitivity of 0.01 grams.

**Results:** statistical analysis was performed. Normality was checked with Shapiro Wilk test. TG showed a mean of 69,7% of the original almond weight, while CG showed a mean of 61,2%. T-test confirmed the statistical significance (set at  $p < 0.05$ ) with a p-value of 0.011.

**Conclusion:** results showed that masticatory function is less effective while wearing aligners. However, being these devices well tolerated by patients during meals, further research is needed to better evaluate this opportunity for clear aligners.

## LONG-TERM EFFECTS INDUCED BY ALT-RAMEC PROTOCOL FOR TREATMENT OF CLASS III MALOCCLUSION

Bosoni C., Franchi L., Masucci C., Caroccia F., Giuntini V.

Department of Experimental and Clinical Medicine, University of Florence, Florence, Italy

**Aim:** to evaluate the long-term effects of the Alt-RAMEC and facial mask (FM) *versus* conventional rapid maxillary expansion (RME) and FM for the early treatment of Class III malocclusion.

**Methods:** twenty-one patients ( $6.5 \pm 0.7$  years of age) treated with the Alt-RAMEC/FM treatment approach were evaluated by means of lateral cephalograms taken at 3 observation periods: before treatment (T1), immediately after treatment (T2) and at a postpubertal long-term observation (T3). The Alt-RAMEC/FM group was compared to a sample of 22 Class III patients ( $6.9 \pm 1.2$  years) treated with RME/FM. At T3, all patients presented with a post-pubertal stage of skeletal maturation (cervical stage 4-6 assessed with the cervical vertebral maturation method). Repeated Measures ANOVA test or Friedman's test was applied for intra-group statistical analysis. Between-group statistical comparisons at T1 and on the T2-T1,

T3-T2 and T3-T1 changes were performed with the independent sample t test or the Mann-Whitney U test.

**Results:** both the Alt-RAMEC/FM and RME/FM groups showed statistically significant favorable treatment results (SNA + 2.2° and +1.6°, respectively; ANB + 3.6° and + 2.8°, respectively). At the post-pubertal observation (T3), only the advancement of the maxilla (SNA + 2.0° and + 1.9°, respectively) remained stable in both groups. In the short term, the Alt-RAMEC/FM group exhibited a statistically significant greater improvement in the Wits appraisal (+ 1.6mm) than the RME/FM group. No statistically significant differences were found between the 2 groups at the post-pubertal observation (T3).

**Conclusion:** neither of the two therapeutic approaches could be considered more efficient and effective than the other, both in the short and long term.

## AN ORIGINAL 3D DIGITAL WORK-FLOW FOR INDIRECT ORTHODONTIC BONDING

Caputo A.<sup>1</sup>, Portelli M.<sup>1</sup>, Bellocchio A.M.<sup>1</sup>, Militi A.<sup>1</sup>, Rustico L.<sup>1</sup>, Fastuca R.<sup>2</sup>, Lo Giudice A.<sup>1</sup>, Nucera R.<sup>1</sup>

<sup>1</sup>Department of Biomedical Sciences, Dentistry and Morphological and Functional Imaging, University of Messina, Messina, Italy

<sup>2</sup>Department of Medicine and Surgery, University of Insubria, Varese-Como, Italy

**Aim:** success in orthodontics is related to a correct diagnosis and treatment planning. Aim of the study is to provide a reproducible and precise method, for orthodontic indirect bonding, using CBCT images and CAD-CAM process.

**Methods:** a case of a female patient, 37 years old, was selected. Plaster models were digitally acquired using the Extra-Oral scanner Maestro 3D and processed within the Studio Maestro 3D software. CBCT images were imported into the MIMICS software, and dental elements segmentation has been performed, obtaining a 3D dental arches model. The DICOM file has been reworked with Meshmixer software to improve image quality, and imported into the 3D Maestro software to be

superimposed on the digital model. A three-dimensional real model of the dental arches was developed. After an orthodontic virtual set-up, brackets positioning on the 3D model of the dental arches was done. A virtual transfer template was created, in order to digital printing a PET-G mask for indirect orthodontic bonding.

**Results:** the original digital workflow proposed in this study allows the development of a real and non-ideal three-dimensional coronal-root model of the dental arches.

**Conclusion:** technological advancements in oral scanning and 3D printing will allow the achievement of an easy and reproducible ideal positioning of the orthodontic brackets.

## CLASS II CORRECTION IN GROWING PATIENTS WITH CLEAR ALIGNERS (INVISALIGN®) AND ELASTICS

Carganico A.<sup>1</sup>, Abbate L.<sup>1</sup>, Dimola M.<sup>1</sup>, Castiglioni F.<sup>1</sup>, Migliori F.<sup>2</sup>, Levrini L.<sup>3</sup>

<sup>1</sup>Postgraduate Program in Orthodontics, Department of Medicine and Surgery, University of Insubria, Varese-Como, Italy

<sup>2</sup>Private Practice, Fano, Italy

<sup>3</sup>Director of Postgraduate Program in Orthodontics, Department of Human Sciences, Innovation and Territory, University of Insubria, Varese-Como, Italy

**Aim:** the aim of this preliminary retrospective study was to evaluate cephalometrically the skeletal and dentoalveolar changes of Class II correction in growing subjects through an Invisalign® treatment protocol involving both upper molar distalization and mandibular advancement supported by Class II Elastics.

**Methods:** a sample of 10 Class II malocclusion subjects (mean age: 13,6) was treated with a protocol including aligners and elastics. Lateral cephalograms were obtained before treatment (T0) and at the end of treatment (T1). Changes in skeletal cephalometric values after therapy were compared to a control group matched according to sex and age. Student *t* test was used to identify significant changes between T0 and T1.

**Results:** in all patients a molar Class I relationship was obtained, with mean treatment time of 12,8 months with 43,5

aligners. A refinement phase was requested for each case (mean of 2,2 months with 9,1 aligners).

A significant reduction in ANB angle and a mandibular length increase were observed but the craniofacial vertical dimension was not affected. The angle between the upper incisor and the palatal plane reduced of 7,76° while the interincisal angle increased.

The mandibular incisor inclination and the mandibular incisor position showed no statistical difference. Overjet and overbite were significantly reduced.

**Conclusion:** according to the data presented, Class II correction with the Invisalign® protocol seem to be a valid treatment option, more randomized clinical trials with larger samples need to be performed to confirm the findings.

## A CLASS II DIVISION 1 WITH SEVERE DISCREPANCE TREATMENT WITH 20 YEARS FOLLOW UP

Callea S., Dieni A., Finamore A., Rende F., Aiello D.

Department of Health, University Magna Graecia of Catanzaro, Catanzaro, Italy

**Aim:** the class II malocclusions, before the class I malocclusions, are the most frequent in the Italian population and are most often skeletal and due to mandibular retrusion. The functional devices seem to have a good effect on the growth of the jaw. The long-term maintenance of the results achieved is essential for the therapeutic success of an orthodontic treatment. We simply want to show how an orthodontic treatment carried out and can remain stable over the years.

**Methods:** a female, 10,3 years old, patient presented visible convex profile and a severe mandibular retrusion. The anamnesis showed the habit of oral breathing and sucking of the lower lip. The cephalometric analysis shows a skeletal class II normodivergent. The first phase involved the use of a Bass-type followed by a phase of fixed therapy was carried out. The photos

of the end of treatment show an important improvement in the profile a full class I ratio of molar and canine teeth was achieved with an excellent inter-arch relationship. The result is occlusally and profilometrically stable even after 2, 4, 5, 10, 14, 20 years.

**Results:** the maintenance of a stable orthodontic result over time is the result not only of a correct and physiological occlusion but also and above all of a correct diagnosis and correct identification of problems that can cause the malocclusion itself. Functional devices associated to an orthodontic fixed finishing and a correct retention phase were necessary to archive a good therapy and to keep the case stable over time.

**Conclusion:** this case report shows how it is possible to correctly treat a second class of mandibular retrusion whose result remains stable even 20 years after the end of therapy.

## SIDE EFFECTS OF FACIAL MASK: DERMATITIS, PERIODONTAL PROBLEMS AND DISCOMFORT

Poletti F., Cavallaro M., Fiorillo G., Mandelli G., Gastaldi G.

Department of Dentistry, Director Prof. E. Gherlone, Vita-Salute San University Raffaele, Milan, Italy. Vita-Salute San Raffaele University of Milan, School of Specialization in Orthodontics, Director Prof. G. Gastaldi, Milan, Italy

**Aim:** the correction of skeletal Class III in orthodontics is a hard goal.

This paper analyzes the therapeutic approach of Class III malocclusion and in particular the use of the facial mask in its variants and related side effects.

Many authors, such as Baccetti, Delaire, McNamara, highlight the benefits of early treatment of class III malocclusions. On the basis of the skeletal or dental alveolar etiology of the malocclusion we will address the therapeutic management differently. Early treatment of class III malocclusion with a face mask is recommended in order to reduce the severity of the malocclusion. The purpose of this article is to review the side effects associated with the use of the face mask (skin irritation, swelling and periodontal problems).

**Methods:** this paper includes 31 articles indexed in different databases: PubMed, Medline, Scopus, Science Direct. Literature reviews, longitudinal, cohort, case - control, and case se-

ries studies were compared. We excluded articles published before 2008.

**Results:** from the literature review, the main problems associated with this type of appliance are the decubitus on the forehead and the chin with the appearance of irritation, swelling and redness. Useful in some cases to avoid these types of complications is: to shape the chin support, use moisturizers, buy the mask with interchangeable supports or use cotton pads and in the presence of very pronounced Pogonion, mill the inside. We can identify the appearance of recessions in the lower incisal sector.

**Conclusion:** since today, the face mask (Delaire or Petit) is the treatment of choice for class III malocclusion but patient's compliance can be seriously compromised with the mentioned side effects that increase the discomfort. The digital technology in the dental field could allow the creation of custom-made devices in order to reduce discomfort for the patients.

## QUALITY AND READABILITY OF WEBSITES ON MANDIBULAR ADVANCEMENT DEVICES FOR OSA

Gamberini S.<sup>1</sup>, Fiordelli A.<sup>2</sup>, Incerti Parenti S.<sup>1</sup>, Bortolotti F.<sup>1</sup>, Laffranchi L.<sup>2</sup>, Alessandri-Bonetti G.<sup>1</sup>

<sup>1</sup>Department of Biomedical and Neuromotor Sciences (DIBINEM), Section of Orthodontics, University of Bologna, Bologna, Italy

<sup>2</sup>Dental School, University of Brescia, Brescia, Italy

**Aim:** to analyze quality and readability of the most likely visited websites providing information on mandibular advancement devices (MADs) for obstructive sleep apnea.

**Methods:** Google, Yahoo and Bing were queried with the terms “sleep apnea, mandibular advancement device and oral appliance”. The first 100 results for each search engine were screened. After removal of duplicates and irrelevant results, resources were grouped into academic, commercial, physician and non-physician websites and assessed with DISCERN instrument for quality of information, Flesch Reading Ease Score (FRES) and Flesch-Kincaid Reading Grade Level (FKGL) for readability.

**Results:** 155 websites were included (26 academic, 31 commercial, 82 physician and 16 non-physician). Quality was statistically significant lower for commercial websites (mean  $\pm$

standard deviation =  $28.68 \pm 11.65$ ) compared to others (ranging from  $40.97 \pm 10.43$  to  $47.19 \pm 14.01$ ;  $p < 0.001$ ). Academic websites were easier to read (FRES =  $66.18 \pm 19.41$ ) compared to commercial ( $52.97 \pm 10.85$ ;  $p < 0.0001$ ) and physician ( $59.41 \pm 8.09$ ;  $p = 0.048$ ) ones, while physician were easier compared to commercial websites ( $p = 0.043$ ). Reading level was lower for academic (FKGL =  $5.87 \pm 3.03$ ) compared to commercial ( $7.55 \pm 1.45$ ;  $p = 0.002$ ) and physician ( $6.98 \pm 1.15$ ;  $p = 0.026$ ) websites.

**Conclusion:** online information on MADs vary in quality and readability. Although generally readable by average consumers, the quality should be improved particularly for commercial websites. Clinicians should provide accurate information to patients in order to avoid unrealistic expectations delivered by internet.

## ATP BIOLUMINOMETER AND SEM ANALYSIS ON CLEAR ALIGNERS SURFACE AFTER THE USE OF BITEWASH

Kozokic J.<sup>1</sup>, Rossi O.<sup>1</sup>, Persano R.<sup>1</sup>, Dibetta A.<sup>1</sup>, Basile G.<sup>2</sup>, Levrini L.<sup>3</sup>

<sup>1</sup>Post Graduate Program in Orthodontics, Department of Medicine and Surgery, University of Insubria, Varese-Como, Italy

<sup>2</sup>Private Practice, Como, Italy

<sup>3</sup>Director of Postgraduate Program in Orthodontics, Department of Human Sciences, Innovation and Territory, University of Insubria, Varese-Como, Italy

**Aim:** the aim of this study is to evaluate the efficacy of removing bacterial biofilm with SEM and the bacterial concentration with bioluminometer on clear aligners after the use of BiteWash.

**Methods:** fifteen patients treated with clear aligners (Invisalign®, Align Technology Inc., Tempe, AZ, USA) were enrolled in this study (age range between 18 and 30 years old). All subjects were instructed to use a soft toothbrush and rolling brushing technique, fluoride toothpaste and dental floss. For the analysis with a bioluminometer, at the end of the first week of use, the aligners were divided into two groups, the control group (clear aligners cleaned with water only) and the experimental group, following the BiteWash indications. For the SEM

analysis, 2 aligners were randomly selected from the two groups.

**Results:** the analysis shows that in the control group, the bacterial concentration is 8.747 RLU (relative light unit), while on the experimental group is 1.107 RLU expressing a mean difference between the control group and the experimental group equal to 7.640 RLU (t-student  $p < 0.0001$ ).

**Conclusion:** the results of the qualitative (SEM analysis) and quantitative analysis (concentration of bacteria analyzed with a bioluminometer) show that the Bitewash product used in the study is effective in removing bacterial biofilm on the transparent orthodontic aligners.

## ARE SKELETAL ANOMALIES ASSOCIATED WITH CANINE IMPACTION?

Giuca M.R., Pasini M., Ligori S.

Department of Surgical, Medical, Molecular and Critical Area Pathology, Unit of Pediatric Dentistry, University of Pisa, Pisa, Italy

**Aim:** to determine the association between sella turcica bridging (STB), ponticulus posticus (PP), atlas posterior arch deficiency (APAD), variations in the morphology of sella turcica and pterygopalatine fissure and the maxillary canine impaction.

**Methods:** a retrospective study was performed on cephalographs and panoramic radiographs of 52 patients with maxillary canine impaction and 52 patients without dental anomalies. The patients' mean age in both groups was  $13.2 \pm 3.5$  years. The canine inclusion was diagnosed using panoramic radiographs and collecting clinical reports. STB, PP, APAD and the morphology of sella turcica and pterygopalatine fissure were evaluated on lateral cephalometric radiographs.

**Results:** in the test and control groups, 85% and 60% of patients had STB, respectively. PP was observed in 59% of pa-

tients in the test group and in 15% of patients in the controls. APAD was observed in 10% of test group patients and 5% of control group patients. All these skeletal anomalies resulted significantly and positively correlated with maxillary canine impaction. It was observed a significant difference between the two groups about the shape of pterygopalatine fissure (that is less wide or longer in the test group).

**Conclusion:** maxillary canine impaction is positively associated with the occurrence and severity of sella bridging, ponticulus posticus, atlas posterior arch deficiency, narrower pterygopalatine fissure. These skeletal anomalies could be precocious predictive bone markers for the impaction of maxillary canines. Moreover, telerradiographies are an early diagnostic test for STB, PP, APAD, which are sometimes associated with specific symptoms.

## MANDIBULAR RESPONSE AFTER MAXILLARY EXPANSION: A SYSTEMATIC REVIEW AND META-ANALYSIS

Mausoli F.<sup>1</sup>, Cassi D.<sup>1</sup>, D'Amico R.<sup>2</sup>, Generali L.<sup>1</sup>, Bellini P.<sup>1</sup>, Consolo U.<sup>1</sup>

<sup>1</sup>Department of Surgical, Medical, Dental and Morphological Science with interest in Transplant Oncological and Regenerative Medicine, School of Dentistry, University of Modena and Reggio Emilia, Modena, Italy

<sup>2</sup>Department of Maternal, Child and Adult Medical and Surgical Sciences, University of Modena and Reggio Emilia, Modena, Italy

**Aim:** the aim of this study is to investigate the published evidence regarding the mandibular changes on the three dimensions, following maxillary expansion in growing patients. A systematic review with meta-analysis was conducted to answer the following question: which is the mandibular response on the sagittal, vertical and transverse plane after maxillary expansion?

**Methods:** the Preferred Reporting Items for Systematic Reviews and Meta-analysis (PRISMA) statement was used to guide this study. A literature search was performed using the following electronic databases: PubMed, SciELO, Cochrane, Scopus and Scindirect. The search covered a period from 1 January 1990 to 30 March 2020. The methodological quality of the studies was evaluated by two operators independently, according to the Methodological Index for Non-Randomized Studies (MINORS) tool. Two skeletal outcomes (SNB angle and SnGoGn angle) and two dento-alveolar outcomes (mandibular inter-molar width and mandibular inter-canine width), observed after maxillary expansion were statistically pooled.

**Results:** a total of 6547 articles was found: 34 met the inclusion criteria and were included in the qualitative synthesis, whereas 20 of them were also included in the quantitative synthesis (meta-analysis). The selected studies reported the following maxillary therapies: slow, rapid or mixed expansion. Methodological assessment revealed quality scores ranging from "high" for 3 studies and "medium-high" for 3 studies, to "medium" for 22 studies and "low" for the remaining 6 studies. The meta-analysis showed that SNA and SnGoGn angles slightly increased: the total pooled weighted mean difference values (95% confidence interval) were  $0.09^\circ$  ( $-0.15^\circ$ ,  $0.34^\circ$ ) and  $0.25^\circ$  ( $0.24^\circ$ ,  $0.74^\circ$ ) respectively; a small increment was also found in the inter-canine width (mean difference, 0.19 mm, 95% CI,  $-0.16$ mm to 0.55mm) and inter-molar width (mean difference, 1.06 mm, 95% CI, 0.82mm to 1.31mm).

**Conclusion:** dento-skeletal mandibular response after maxillary expansion seems to be not clinically significant on the sagittal, vertical and transverse plane.

## ELASTODONTIC THERAPY OF A CLASS II MALOCCLUSION IN MIXED DENTITION: A CASE REPORT

Patano A.<sup>1</sup>, Laudadio C.<sup>1</sup>, Malcangi G.<sup>1</sup>, Coloccia G.<sup>1</sup>, Marinelli G.<sup>1</sup>, Limongelli L.<sup>1</sup>, Inchingolo A.D.<sup>1</sup>, Montenegro V.<sup>1</sup>, M.T.<sup>1</sup>, Laforgia A.<sup>1</sup>, Dipalma G.<sup>1</sup>, Inchingolo F.<sup>1</sup>, Di Venere D.<sup>1</sup>, Farronato M.<sup>2</sup>, Tartaglia G.<sup>2</sup>, Cardarelli F.<sup>1</sup>

Complex Operative Unit of Odontostomatology, Director: Prof. G. Favia

<sup>1</sup>Specialization School in Orthognatodontics, Director: Prof. F. Inchingolo, Interdisciplinary Department of Medicine D.I.M., University of Bari Aldo Moro, Bari, Italy

<sup>2</sup>Department of Biomedical, Surgical and Dental Sciences, School of Dentistry, University of Milan, Milan, Italy. UOC Maxillo-Facial Surgery and Dentistry. Fondazione IRCCS Ca' Granda, Ospedale Maggiore Policlinico, Milan, Italy

**Aim:** elastodontic therapy is a new approach to orthodontic therapy which uses light and biological forces of elastic type to correct malocclusions in young patients, affecting growth, eliminating functional disorders and correcting the position of teeth.

The aim of this report is to describe a case of elastodontic therapy in a growing patient in mixed dentition.

**Methods:** a 9,5 year old female presented with a dento-skeletal class II malocclusion, maxillary and mandibular contraction, lower arch crowding, lower midline deviation to left and upper incisors misalignment. Treatment plane involved the use of an elastodontic device with a flat occlusal plane. The active phase of therapy was conducted in eighteen months; retention time

was eight months. Cephalometric x-ray revealed also cervical vertebrae compression.

**Results:** at the end of treatment with the elastodontic device the patient showed molar and canine class I relationship, an excellent intercuspitation, normal overjet and overbite, no crowding and centered midlines. Correct posture was achieved only with the elastodontic therapy.

**Conclusion:** the elastodontic therapy is able to resolve most orthodontic problems quickly and easily as well as transforming most of these cases in ideal occlusion, in functional and aesthetic terms. Elastodontic devices allow to correct malocclusions and at the same time to resolve postural problems related to them.

## ELASTODONTIC THERAPY OF OPEN BITE IN MIXED DENTITION: A CASE REPORT

Patano A.<sup>1</sup>, Laudadio C.<sup>1</sup>, Malcangi G.<sup>1</sup>, Coloccia G.<sup>1</sup>, Marinelli G.<sup>1</sup>, Limongelli L.<sup>1</sup>, Inchingolo A.D.<sup>1</sup>, Montenegro V.<sup>1</sup>, D'Oria M.T.<sup>1</sup>, Laforgia A.<sup>1</sup>, Dipalma G.<sup>1</sup>, Inchingolo F.<sup>1</sup>, Di Venere D.<sup>1</sup>, Farronato M.<sup>2</sup>, Tartaglia G.<sup>2</sup>, Cardarelli F.<sup>1</sup>

Complex Operative Unit of Odontostomatology, Director: Prof. G. Favia

<sup>1</sup>Specialization School in Orthognatodontics, Director: Prof. F. Inchingolo, Interdisciplinary Department of Medicine D.I.M., University of Bari Aldo Moro, Bari, Italy

<sup>2</sup>Department of Biomedical, Surgical and Dental Sciences, School of Dentistry, University of Milan, Milan, Italy. UOC Maxillo-Facial Surgery and Dentistry. Fondazione IRCCS Ca' Granda, Ospedale Maggiore Policlinico, Milan, Italy

**Aim:** AMCOP Bio-Activators are elastic orthodontic devices which act in a three-dimensional manner in the oral cavity involving muscles, tongue, teeth and bone. This case report describes the use of elastodontic therapy for stopping a thumb sucking habit and for closing an anterior open bite.

**Methods:** a 7 year old female in mixed dentition presented a dento-skeletal open bite, short lingual frenulo, constricted maxillary arch with no space for the eruption of permanent teeth. Anamnesis revealed thumb sucking habit.

Treatment plane include the following steps: motivation, speech therapy, frenulectomy of the lingual frenulum, elastodontic therapy and elastodontic retention for 12 months. After a first step with an elastodontic appliance with a flat occlusal

plane, the patient was treated with AMCOP open device that is equipped with a thickening of the occlusal plane in the posterior area.

**Results:** the first appliance resulted ineffective due to the low height of the shields and the low thickness of the occlusal plane. AMCOP open favoured the correct development of the maxilla and the closure of the dento-skeletal open bite. Furthermore, post-treatment cephalometric x-ray showed the correction of the cervical curve.

**Conclusion:** open bite is considered one of the most challenging dento-facial deformities to treat. This case demonstrated that elastodontic therapy with AMCOP open device had skeletal, dental and postural effects.

## AESTHETIC MANAGEMENT OF PATIENT'S SMILE DURING ORTHODONTIC TRACTION OF DISPLACED CANINE

Provaroni R., Rosignoli L., Carillo M.

Department of System Medicine, University of Rome Tor Vergata, Rome, Italy

**Aim:** aligning a displaced maxillary canine into the dental arch is one of the most complex problem in orthodontics due to clinical aspects, but also because of the social-life implication and aesthetic demand during and after the orthodontic traction. This case report illustrates a low-cost device that can help to disguise the missing tooth while the traction phase of a right impacted canine.

**Methods:** L.M., 20 years old, presented with a right maxillary displaced canine associated with the corrisponde of deciduous canine. She was aware of her maxillary impacted canine and motivated to treat it because of the mobility of the primary element. It was planned to extract the primary canine during the surgical exposure of the MCI and in order to hide the missing tooth during her social moments, it has been manufactured a

vacuum-formed retainer from element 1.4 to 2.4 with resin pontic for 1.3. The patient was instructed to use the retainer only during university exams and social events.

**Results:** the retainer was given to the patient the same day of the surgical procedures. After we bonded the modified quad-helix for anchorage and during the traction of the canine, this aesthetic retainer was still efficient.

**Conclusion:** the management of impacted canines is important in terms of aesthetics and function. Furthermore the orthodontists must find out treatment plans that are in the best interest of the patient. With this easy-to-use, low-cost solution we can guarantee a good aesthetic during the traction of a maxillary displaced canine.

## EMG EVALUATION OF MASTICATORY MUSCLES IN PATIENTS WITH SEVERE DENTOFACIAL DISCREPANCIES

Romano M.J., Corvino I.R., Diana T., Cimino R.

School of Orthodontics, Department of Neurosciences, Reproductive Sciences and Oral Sciences, University of Naples Federico II, Naples, Italy

**Aim:** this study aimed at investigating, from an electromyographic point of view, masticatory function and swallowing in patients undergoing orthodontic-orthognathic treatment to evaluate the influence of severe malocclusions on the stomatognathic functions.

**Methods:** fourteen adult patients (7 males, 7 females; mean age  $27.8 \pm 10.5$ ) with dentofacial deformities were recruited. The group was composed by 8 skeletal Class III patients and 6 skeletal Class II patients. Among them, 7 patients presented skeletal crossbite malocclusion. The activity of the left and right anterior temporalis and masseter muscles was registered during static, chewing and swallowing tasks. Electromyographic indices comparing the activity of paired muscles were computed via software to estimate the extent of asymmetric activity. Mann-Whitney *U* test and chi-squared test were used in the statistical analysis.

**Results:** analysis of the results confirmed the influence of skeletal malocclusion on the electrical activity of temporalis and masseter. ASIM, ATTIV and POC show the presence of a general asymmetry in the masticatory muscle pattern of these patients during clenching. Modulus and Acrophase coefficients show a neuromuscular incoordination during chewing tasks. Class III patients have more asymmetrical muscular activity in comparison to Class II patients, while crossbite patients show greater neuromuscular incoordination during chewing.

**Conclusion:** patients with severe malocclusions tend to have an asymmetrical muscle activation during different tasks. Still, given the small sample size, it is not possible to draw definitive conclusions.

## CEPHALOMETRIC ANALYSIS PERFORMED BY A RADIOLOGICAL LABORATORY: IS IT A RELIABLE INSTRUMENT?

Salerno M, Alessandri Bonetti A., Cordaro M., Mollo A., Gallenzi P.

A. Gemelli Foundation, IRCCS - Catholic University of Sacred Heart, Orthodontics Residency Program: Director Prof. M. Cordaro, Rome, Italy

**Aim:** cephalometric analysis is an important instrument to formulate an orthodontic diagnosis. Today the traditional cephalometry performed by hand on acetate sheets has been gradually replaced by digital cephalometry. The aim of this study is to compare cephalometric tracing performed by a radiological laboratory to the tracing performed using Openceph and to assess statistically significant differences.

**Methods:** thirteen pre-treatment lateral telerradiographies of the skull taken by a radiological laboratory were analyzed. Laboratory's cephalometric tracings of Ricketts' analysis were

compared to data obtained using 'OpenCeph' software. The examiner who conducted measurements was blind to the results of the previous analysis. Intra-operator variability was observed. Data were compared through Bland-Altman analysis in order to evaluate statistically significant differences.

**Results:** no statistically significant differences have been detected between the two analysis.

**Conclusion:** cephalometric tracings conducted by the radiological laboratory can be considered a valid and reliable tool to help the clinician in the diagnostic process.

## SIGNS AND SYMPTOMS IN ADULTS TREATED WITH ALIGNERS: A SURVEY ANALYSIS ON 174 PATIENTS

Saran S., Cordaro M., Laganà D.

A. Gemelli IRCCS University Hospital Foundation, Catholic University of the Sacred Heart, Master's Degree Course in Dentistry and Dental Prosthetics, Director: Prof. M. Cordaro, Chair of Orthodontics: Prof. C. Grippaudò, Rome, Italy

**Aim:** in this study we tried to figure out which are the main signs and symptoms related to the orthodontic treatment with aligners in adults.

**Methods:** 174 adult patients who underwent to an orthodontic therapy based on aligners answered an anonymous survey. This questionnaire examined how this kind of treatment can influence salivation, clenching and bruxism. We tried as well to see if there was a relationship between the therapy and the development of oral lesions. Moreover different types of pain were analyzed: the one related to the TMJ and the development of headache during the therapy. Eventually the study evaluated if there and how much was the influence of the treatment on the smoking habits.

**Results:** the aligners treatment satisfied almost all patients, reaching a very high level of appreciation in the 83,3% of the

sample. About the interaction between the saliva and the aligners, it was ascertained that the 67,2% of the patients didn't suffer from dry mouth during the therapy, but the 54% of the interviewed people experienced sialorrhea.

The 50,6% of the sample had episodes of bruxism or clenching and the 46% of the patients had oral lesions during the treatment. Furthermore only the 23,6% had TMJ pain and only the 27% experienced headache throughout the orthodontic cure.

Eventually the 17,4% of the people who were used to smoke, reduced this habit during the aligners treatment.

**Conclusion:** at the end of the analysis we can say that aligners therapy can determine changes in some aspects of the oral health and we suggest more studies to deepen them.

## BRUXISM AND ORTHODONTIC TREATMENT: IS THERE A RELATIONSHIP? A SURVEY ON 236 PATIENTS

Saran S., Laganà D.

A. Gemelli IRCCS University Hospital Foundation, Catholic University of the Sacred Heart, Master's Degree Course in Dentistry and Dental Prosthetics. Director: Prof. M. Cordaro, Chair of Orthodontics: Prof. C. Grippaudo, Rome, Italy

**Aim:** the study analyzes how and if bruxism is influenced by different types of orthodontic therapy. We evaluated different TMJ symptoms too see if there are changes according to the type of the device used.

**Methods:** 236 adult orthodontic patients were asked to complete anonymously a survey in which age, gender and the type of the orthodontic device were considered.

The questions were about the typical symptoms of temporomandibular disorders, in particular headache, bruxism, clenching, pain while opening the mouth and joint's noise. Patient wearing ceramic and lingual braces were excluded from the analysis because too scarce to be representative; a

total of 208 patients were eventually included in the statistical analysis.

**Results:** it was found a significant difference in the patients affected by bruxism, when treated with various types of orthodontic therapy. In this survey we noticed that the fixed braces induced a reduction of this habit more than the aligners. However it is clear that bruxism is a multifactorial problem and it isn't influenced only by orthodontic therapy.

**Conclusion:** it seemed that orthodontic treatment didn't solve bruxism itself, but the fixed metal braces appeared to be more advisable than aligners in patients who needed orthodontic therapy and, in the meantime, suffered from bruxism.

## EVALUATION OF UPPER ARCH CHANGES IN PATIENTS WITH CLEFT LIP AND PALATE AFTER EXPANSION

Scerra M.S., Carozza D., Carrino R., Chiarenza M.C., Schiavone M.G., Grassia V.

Multidisciplinary Department of Medical-Surgical and Dental Specialties, University of Campania Luigi Vanvitelli, Caserta, Italy

**Aim:** children with UCLP usually suffer from a nasomaxillary complex deficiency with upper dental arch constricted which continues worsening until the end of their growth. Thus, it is suggested to begin an early dentofacial orthopedic treatment protocol during the mixed dentition with a palatal expander.

Thus, the aim was to compare the upper arch dimensions of young patients with unilateral cleft lip and palate (UCLP) before and after treatment with bonded maxillary expander and hybrid activation protocol using digital dental casts.

**Methods:** sixteen subjects with UCLP, aged between 7 and 14 years (mean age  $10.9 \pm 2.7$  years) consecutively treated with bonded maxillary expander and hybrid activation were included. The dental casts before and after treatment were digitalized using a 3Shape scanner. Inter canine, interpremolar and intermolar widths (at cusp and gingival levels) and arch perim-

eters were measured. The significance level for statistical analyses was set as  $p < 0.05$ .

**Results:** the total sample included 16 patients, 10 females and 6 males. The initial mean age was  $10.9 \pm 2.7$  years. The total treatment phase with the bonded expander (T0-T1) lasted  $12.0 \pm 1.9$  months while the active expansion phase was  $4.0 \pm 0.2$  months. Comparing measurements at T0 and T1 showed statistically significant improvements in all transverse arch widths while arch perimeter values revealed no significant outcomes. As to the different arch diameters at both cusp tips and gingival levels, data showed statistically significant results only for the diameter 3-3.

**Conclusion:** the use of a bonded maxillary expander with a hybrid activation protocol during growth may be efficient to improve all transverse upper arch widths in patients affected by UCLP.

## CEPHALOMETRIC ANALYSIS IN PATIENTS WITH UNILATERAL POSTERIOR CROSSBITE TREATED WITH FGB

Tortarolo A., Lugarà B., Ramirez E.L., Maticena G., di Benedetto L., Piacino M.G.

Department of Surgical Sciences, Dental School C.I.R., Division of Orthodontics, University of Turin, Turin, Italy

**Aim:** the aim of the study is to evaluate the change of cephalometric values in patients with unilateral posterior crossbite before and after therapy with Function Generating Bite.

**Methods:** 20 patients (9 boys and 11 girls,  $7,8 \pm 1,6$  years) with unilateral posterior crossbite corrected with Function Generating Bite were included in the study. Essential clinical data were collected: medical and dental history, clinical investigation, model casts, OPT, L/L and P/A telerradiography and cephalometric analysis, intra- and extraoral photos. The data were recorded before treatment and after the correction and the stabilization of the unilateral posterior crossbite. Cephalometric values recorded before and after correction were compared with T-Student analysis. The values examined was:  $SpP^{\wedge}GoGn$  ( $20^{\circ} \pm 5$ ),  $SpP^{\wedge}Oc$  ( $8^{\circ} \pm 3$ ),  $Oc^{\wedge}GoGn$  ( $12^{\circ} \pm 3$ ),  $SpP^{\wedge}F$  ( $5^{\circ} \pm 3$ ),  $Sn^{\wedge}GoGn$  ( $32^{\circ} \pm 2$ ),  $CoGo^{\wedge}GoGn$  ( $12^{\circ} \pm 2$ ),  $A-Po$  ( $2^{\circ} \pm 3$ ) and  $ANB$  ( $2^{\circ} \pm 2$ ).

**Results:** the results show that in all patients the crossbite was well corrected and the comparison between the cephalometric value before and after therapy with FGB showed a significant improvement of divergence. The mean value of  $SpP^{\wedge}GoGn$  before treatment was  $28,69^{\circ}$  and after therapy was  $26,78^{\circ}$  ( $p = 0,00257$ ),  $SpP^{\wedge}Oc$  was  $11,62^{\circ}$  before treatment and  $9,68^{\circ}$  after treatment ( $p = 0,00563$ ),  $SpP^{\wedge}F$  was  $-3,58^{\circ}$  before treatment and  $0,25^{\circ}$  after treatment ( $p = 0,00067$ ). The mean value of  $A-Po$  was  $7,9$  mm before therapy and  $5$  mm after therapy ( $p = 0,00021$ ).

**Conclusion:** function Generating Bite according to the Turin School is a non-cariogenic, removable appliance that allows not only the correction of dental malocclusion but also the control and improvement of the vertical growth during the orthognatodontic treatment.

## ACCURACY OF CNN-BASED METHOD FOR SEGMENTING SINO-NASAL CAVITY AND PHARYNGEAL AIRWAY

Venticinque V., Ronsivalle V., Isola G., Lacagnina C., Leonardi R., Lo Giudice A.

Department of Orthodontics, University of Catania, Catania, Italy

**Aim:** the purpose of the study was to estimate the accuracy of a new automatic deep learning-based method for fully automatic segmentation of the sino-nasal cavity and the pharyngeal airway from CBCTs.

**Methods:** 40 CBCT scans from healthy patients (20 females and 20 males, mean age  $23,37 \pm 3,34$ ) were selected to perform a manual segmentation of the sino-nasal cavity and pharyngeal sub-regions via Mimics software. 20 CBCT scans out of the total sample were randomly collected and employed to train the artificial intelligence model file. The accuracy of the CNN fully automatic method was tested by comparing the left-over 20 CBCT segmentation masks to the segmentation volumes of the 3D models, obtained with automatic and manual segmentations. The accuracy of the CNN-based method (Convolutional Neural Networks) was also determined by using the DICE Score coefficient (DSC) and by the surface-to-surface matching technique. The Intraclass correlation coefficient

(ICC) and Dahlberg's formula were used respectively to test the intra-observer reliability and method error. Independent Student's t-test was used for between-groups volumetric comparison.

**Results:** measurements were highly correlated with an ICC value of 0,921 while the method error was 0,31 mm<sup>3</sup>. A difference of 1,93 ( $\pm 0,73$ ) cm<sup>3</sup> was found between the methodologies but it was not statistically significant ( $p > 0,05$ ). The matching percentage detected was 85.35 %  $\pm 2,59$  % (tolerance 0.5 mm) and 93,44%  $\pm 2,54$  % (tolerance 1.0 mm). The differences, measured as DSC in percentage, between the assessments done with both methods were, respectively, 3.3% and 5.8%.

**Conclusion:** the argued new deep learning-based approach for automated segmentation of the sino-nasal cavity and the pharyngeal airway in CBCT scans is accurate and performs as equally well as an experienced image reader but faster.

## ANALYSIS OF MIDFACE SOFT TISSUE CHANGES AFTER TOOTH-BORNE AND BONE-BORNE RME TREATMENT

Venticinque V., Ronsivalle V., Isola G., Peters A., Palazzo G., Fichera G., Lo Giudice A.

Department of Orthodontics, University of Catania, Catania, Italy

**Aim:** the purpose of the study was to estimate the post-expansion and post-retention changes of the soft tissues of the nose after rapid maxillary expander (RME) based therapy, performed with tooth-borne (TB) and bone-borne (BB) devices.

**Methods:** this study included 40 patients who received tooth-borne RME (TB, average age:  $11.75 \pm 1.13$  years) or bone-borne RME (BB, average age:  $12.68 \pm 1.31$  years). Cone-beam computed tomography (CBCT) scans were taken before treatment (T0), after expansion (T1) and after a 6-month retention period (T2). Linear measurements of the skeletal components and of the soft-tissue region of the nose were performed at each time point on aforesaid CBCT scans. All data were statistically analyzed.

**Results:** by confronting BB and TB groups ( $p < 0.05$ ), BB group showed a greater skeletal expansion of the anterior and posterior region of the nose immediately after RME. Both TB and BB RME induce a small increment ( $> 1$  mm) of the alar base and alar width, without significant differences between the two expansion methods ( $p > 0.05$ ). High correlation was found between skeletal and soft-tissue expansion in TB group (from 0.903 to 0.941).

**Conclusion:** a similar slight increment of the alar width and alar base width was found in both TB and BB groups. Its clinical relevance, as regards facial appearance, remains questionable.

## EFFECTS OF THREE DIFFERENT PROTOCOLS OF RAPID MAXILLARY EXPANSION IN GROWING SUBJECTS

Alesi G., Marino L., Milazzo A., Fusaroli D.

Department of Orthodontics, Head: Paola Cozza, University of Rome Tor Vergata, Rome, Italy

**Aim:** to evaluate the dentoskeletal response in hyperdivergent growing patients comparing Rapid Maxillary Expansion (RME) using three different protocol systems.

**Methods:** three groups of hyperdivergent subjects treated with RME were analyzed. In 41 patients (23F, 18M) the RME was bonded on the maxillary deciduous second molars (E-RME group); in 40 patients (24F, 16M) the RME was bonded on the first permanent maxillary molars (6-RME group); in 45 patients (26F, 19M) the RME was bonded on the first permanent maxillary molars with a removable posterior Bite-Block in the lower arch (6-RME/BB group). Lateral cephalograms and dental casts were scanned and digitally measured before treatment (T1), at the appliance removal (T2) and 1 year after the appliance removal (T3). The comparison was made within the same group

and between the groups. Statistical comparisons were assessed with ANOVA multicomparison test ( $P < 0.05$ ).

**Results:** a significant increase of upper molars buccal tipping was observed in 6-RME group when compared with E-RME and 6-RME/BB groups in the short-term (T2-T1) and long-term (T3-T1); a significant intercanine width increase was observed in E-RME group at the same times. No significant differences in dentoalveolar variables were observed comparing E-RME group vs 6-RME/BB group.

**Conclusion:** the E-RME protocol allows for a greater skeletal expansion and produces a lower buccal tipping of the first permanent upper molars. The use of the Bite-Block in 6-RME/BB group shows a similar attitude to the E-RME protocol then can be considered an effective therapeutic alternative.

## HOW ECOGRAPHIC EVALUATION OF THE BONE GROWTH COULD BE USED IN ORTHODONTICS?

G. Caccianiga G.<sup>1</sup>, Caccianiga P.<sup>1</sup>, Lo Giudice A.<sup>2</sup>, Baldoni M.<sup>1</sup>, Leonida A.<sup>1</sup>, Ceraulo S.<sup>1</sup>

<sup>1</sup>School of Medicine and Surgery, University of Milano-Bicocca, Monza, Italy

<sup>2</sup>Department of General Surgery and Surgical-Medical Specialties, University of Catania, Catania, Italy

**Aim:** the purpose of this study was to assess the ability of soft tissue ultrasound to evaluate the development of wrist ossification centers, in particular for the monitoring of adolescents submitted to orthodontic treatments.

**Methods:** high-resolution ultrasound of the hand and wrist was performed along with x-ray examination on 54 patients undergoing orthodontic therapy. The choice of these patients was made based on age and precise clinical indication of the radiography of the carpus and metacarpal for the correct planning of the orthodontic therapy. Ultrasound scans were specifically directed to the search of ossification centers critical for the peak growth age, namely the pisiform, the adductor sesamoid of the metacarpal-phalangeal joint of the thumb and the cartilage of the distal phalanx of the third finger. The evaluation of the radiography and echography exams was done by an expert radiologist. After-

wards, the radiographs and ultrasounds of wrists and hands of each subject were revised by an expert clinician with a specialized professional and blinded about the age and the clinical history of the patients. Data were analyzed using the Wilcoxon test in order to establish possible discrepancies or correlations between the data obtained with the echography and the radiography.

**Results:** ultrasonography allowed the appreciation of all these structures and yielded results statistically equivalent to film examinations for the pisiform and the sesamoid of the thumb. A statistically significant difference between the two techniques was found for the cartilage of the third finger, due to the difficulty in recognizing its profile in some ultrasound scans.

**Conclusion:** ultrasound of the wrist can be proposed as a simple and valuable non-radiating substitute for the follow-up of skeletal maturation in adolescents during orthodontic treatments.

## DEEP BITE TREATMENT OF TWO TWINS: CERVERA APPLIANCE VS CLEAR ALIGNERS

Carillo M., Rosignoli L., Provaroni R.

Department of System Medicine, University of Rome Tor Vergata, Rome, Italy

**Aim:** to compare the effects of two different treatment approaches to the same malocclusion on the vertical plane: the deep bite. The comparison is very interesting because the malocclusion of the two patients, except for some small differences, is very similar as they are homozygous twins.

**Methods:** two fourteen years old homozygous twins were treated at the University of Rome Tor Vergata for their similar malocclusion. The cephalometric traces showed a skeletal class I, normal values of divergency, lingual inclination of mandibular incisors (IMPA = 89°) and normal inclination of maxillary incisors. At the dental analysis the patients presented an end-to-end Class II and a severe deep bite (Overbite was respectively 8 and 9 mm). One of the two also had an unilateral crossbite of 1.6 and 4.6. Therefore for this patient, after a first phase with rapid maxillary expander (RME), a Cervera appliance (PCF) has been used to reduce the increased overbite both through posterior extrusion favored by anterior bite plan and through incisors proclination made with activation of retro-in-

clinal Z springs. However the other twin was treated with clear aligners (CA) with the help of intermaxillary elastics. The deep bite correction took about two years. Two set of aligners were required for the CA patient. The RME+PCF patient decided not to continue with a finishing phase to obtain the perfect dental inclinations, while the CA patient is still refining the occlusion and teeth position with additional aligners.

**Results:** the final overbite in CA patient was equal to 2 mm, while RME+PCF patient showed 4 mm overbite.

**Conclusion:** deep bite correction was better with clear aligners treatment. This difference seem to be predominantly related to incisors inclinations. The twin treated with Cervera appliance resulted in incisors still retroclined at the end of treatment, suggesting that the correction of the deep bite occurred mainly by posterior extrusion, as it was expected. Instead clear aligners treatment allowed a greater proclination and therefore a relative intrusion of anterior teeth, resulting in a greater overbite reduction.

## A COMPARISON OF INTRAORAL MOLAR DISTALIZATION APPLIANCES WITH CONVENTIONAL ANCHORAGE

Carrieri M., Sturabotti G., Pingitore G., Dott.ssa Mezio M., Prof. Cassetta M.

Department of Oral Maxillofacial Sciences, Sapienza University of Rome, Rome, Italy

**Aim:** the aim of this review is to compare various intraoral molar distalization appliances with conventional anchorage.

**Methods:** the search was conducted through the PubMed browser database using a combination of keywords as shown below: ((upper) OR (maxillary)) AND (molar distalization) AND ((intraoral) OR (no compliance)) NOT ((miniscrew) OR (mini screw) OR (mini implant)).

**Results:** Vincenzo Quinzi et al. claimed that where the palatal button is present the anchoring of the upper anterior teeth is improved.

According to DevinDer Preet Singh et al. the appliances that they considered are all effective means of distalization of maxillary molars with limited anchorage loss

Gero S. et Al. said that the Hilgers pendulum resulted in the longest dental-linear distalization measurements, and it seem

that the first class appliance and the palatal distal jet are more efficient than the vestibular Jones Jig.

According to Lorena VILANOVA et al. Distal jet and First Class in some aspects turned out to be better than other devices Alberto Caprioglio et al. concluded that the Pendulum and the Fast-Back induce similar dentoskeletal effects.

Patricia P. Chiu et al. said that even if the efficiency between distal jet and pendulum appliances during the treatment can be very different, total molar correction was identical.

**Conclusion:** all these studies show on one hand a very similar efficiency of the various devices (dependent also on stability anchorage unit), but on the other hand also a systematic presence of reverse effects.

In conclusion, there is still the need to increase the number of comparative studies among various devices.

## DISTAL JET WITH SKELETAL ANCHORAGE: A CASE REPORT

Prof. Cassetta M., Dott.ssa Altieri F., Dott.ssa Mezio M., Carrieri M., Sturabotti G., Pingitore G.

Department of Oral Maxillofacial Sciences, Sapienza University of Rome, Rome, Italy

**Aim:** the aim of this case report is to demonstrate how the use of devices with skeletal anchorage allows distalization with body movement of molars, with minimal or no loss of anchorage and with minimal compliance.

**Methods:** 13 year old male patient. An extraoral clinical examination reveals a dolichofacial type and a convex profile. The intraoral clinical examination reveals the presence of permanent dentition with the absence of 1.3, a 1st molar class on the right and a 1st molar class on the left, lower midline deviated to the left by 2 mm and upper centered.

From the cephalometric analysis performed on the telerradiography of the skull in latero-lateral projection, a skeletal class I with a normal divergence is detected, and a tendency to normal facial growth; the upper and the lower incisors are normally inclined.

The treatment plan provided the correction of lack of upper space through the use of a skeletal anchored distal-jet.

The device was built on 2 palatal miniscrews, with a diameter of 2 mm and a length of 11 mm. The distalization protocol provided for activation every 4 weeks, with disassembly of the device and control of the extent of distalization at 6 months.

**Results:** after 6 months from the start of therapy, the success of the distalization was verified. During the 6-month follow-up, no miniscrews lost their primary stability and no inflammation of the peri-implant tissues was observed.

**Conclusion:** molar distalization at the 6-month control time was found to have been performed successfully, safely and without the need for patient cooperation.

The lack of dental support resulted in preservation of anchorage and periodontal integrity.

## THE ERUPTION OF SECOND MOLAR AND THE MAXILLARY MOLAR DISTALIZATION

Carrieri M., Sturabotti G., Pingitore G., Prof. Cassetta M., Dott.ssa Mezio M.

Department of Oral Maxillofacial Sciences, Sapienza University of Rome, Rome, Italy

**Aim:** the aim of this review is to evaluate the effects of maxillary second molar eruption status on the distalization of first molars.

**Methods:** the search was conducted through the PubMed browser database using a combination of keywords as shown below: (second molar) AND ((upper) OR (maxillary)) AND (molar distalization) AND (eruption).

**Results:** N. Shpack et Al. recommended to start headgear therapy before the eruption of second molar. But, after the eruption of it maxillary first molar distalization still continues at a slower pace.

According to C. Flores-Mir et Al. there is no difference in distalization among patients with erupted or unerupted maxillary second molars using a Xbow appliance.

C. Flores-Mir et Al. said also that the effect of second molar eruption stage appears to be minimal.

Karlsson and Bondemark concluded that intraoral movement of maxillary first molars before eruption of second maxillary molars will result in more effective molar movement.

J. Kang et Al. said that, in the presence of a partial erupted second molar, distalization of the first molar is present more at the root level.

While with a fully erupted second molar, extrusion and increased buccal tipping of the first molar resulted.

M. Nienkemper et Al. stated that the higher resistance caused by erupted second molars can be compensated using Beneslider appliance.

**Conclusion:** the anchorage loss is less before the second molar eruption, therefore, it's recommended to move maxillary molars distally before the second molar eruption. But, good treatment results have also been presented when second molars have erupted. Therefore there is still a need for further investigation on this topic.

## EARLY TREATMENT OF DENTOSKELETAL CLASS III MALOCCLUSION: MODIFIED SEC III VERSUS RME/FM

Correra A.<sup>1</sup>, Ciampa E.<sup>1</sup>, Federico F.<sup>1</sup>, Salafia S.G.M.<sup>1</sup>, Strangio B.M.<sup>1</sup>, Franchi L.<sup>2</sup>

<sup>1</sup>Multidisciplinary Department of Medical-Surgical and Dental Specialties Program of Orthodontics, University of Campania Luigi Vanvitelli, Naples, Italy

<sup>2</sup>Department of Experimental and Clinical Medicine, University of Florence, Florence, Italy

**Aim:** to compare the short-term cephalometric outcomes of the protocols modified splints, Class III elastics, chin cup (SEC III) and rapid maxillary expansion and facial mask (RME/FM) for the early treatment of growing subjects with Class III dentoskeletal malocclusion.

**Methods:** 20 patients (11 males, 9 females) treated with the modified SEC III protocol and 31 patients (16 males, 15 females) treated with the RME/FM one were included. The sample was evaluated before (T1, mean age  $7.9 \pm 1.0$  years) and at the end of treatment (T2, mean age  $9.0 \pm 1.0$  years). Statistical comparisons between the two groups were performed with independent sample t tests.

**Results:** the modified SEC III sample included 20 patients (11 males and 9 females, mean: 7.9 yrs; SD: 4.2) while RME/FM group was composed of 31 patients (16 males and 15 females, mean 6.9 yrs; SD: 4.2). The length of the modified SEC III protocol ranged between 9-15 mos (mean: 12.0 years; SD: 4.2),

whereas the length of the RME/FM ranged between 9-21 mos (mean: 13.1 yrs; SD: 2.6).

Both the modified SEC III and the RME/FM sample groups showed significantly favorable effects in terms of maxillary advancement (SNA  $+1.3^\circ$  and  $+1.5^\circ$ , respectively), control of mandibular projection (SNB  $-0.5^\circ$  and  $-0.8^\circ$ , respectively), and intermaxillary relationships (ANB  $+1.8^\circ$  and  $+2.3^\circ$ , respectively; Wits  $+3.4$  and  $+1.9$  mm, respectively). The modified SEC III group showed a statistically significant greater control in the intermaxillary divergency considering the SN to Pal. PI. ( $P < 0.006$ ) and Pal. PI. to Mand. PI. angle ( $P < 0.002$ ) with a difference of 2.3 mm between the two groups.

**Conclusion:** early treatment of growing patients with dentoskeletal Class III disharmonies is efficient using either modified SEC III or RME/FM protocols. However, a higher vertical control is achieved with the modified SEC III.

## DIGITAL INDIRECT BONDING TECHNIQUE: A LITERATURE REVIEW

Crivello L., Amato E., Fazio M., Currò G., Bilello G.

Department of Surgical, Oncological and Oral Sciences, University of Palermo, Palermo, Italy

**Aim:** rapid development of digital technologies and 3D printing has contributed to improve the orthodontic indirect bonding (IDB) technique.

The purpose of this literature review is to evaluate the efficiency and the accuracy of digital IDB.

**Methods:** a comprehensive review has been carried out by performing a search on the electronic database PubMed and on orthodontic journals (i.e. American Journal of Orthodontics, Angle Orthodontist), selecting articles from 2016 to nowadays. Keywords used are: “digital indirect bonding”, “transfer tray/jig”, “3D printing”, “3D setup”, “accuracy”.

**Results:** we found 10 articles. They have showed a digital IDB minimization of clinical chair time.

Brackets ready for digital IDB have virgin bracket bases not contaminated with resin or cast material, as it happens in the case of conventional IDB techniques.

Using digital transfer tray, the accuracy of bracket position for each tooth type is variable in the different studies but most of

the time these deviations are below the clinical acceptable ranges of 0.5 mm for linear measurements (vertical, mesiodistal and buccolingual) and 2° for angular measurements (tip, rotation and torque) according to the American Board of Orthodontics.

High-tech procedures can help in reducing the number of bracket positioning errors and can allow to have predictable results: the quality of these results and the marginal ridges levelling are better with digital IDB thanks to digital set up preview and treatment customization.

Digital set up can help to place brackets correctly, in fact, it allows to preview teeth position at the end of the treatment, in order to modify bracket position to obtain the desired movement.

**Conclusion:** digital IDB seems to reduce treatment time and the need for bracket repositioning and for arch-wire bending. However, given the recent use of this technique in orthodontics, future studies will be able to provide more accurate information on this technique.

## ANTERIOR VS POSTERIOR BITE-RAISING: ASSESSMENT OF PAIN EXPERIENCE AND QUALITY OF LIFE

Damonte S., Silvestrini-Biavati A., Ugolini A.

Department of Surgical Sciences and Integrated Diagnostics, Genoa University, Genoa, Italy

**Aim:** the aim of this clinical trial is to evaluate how bite-raising can affect patients' quality of life and to compare the effects of posterior and anterior build-ups.

**Methods:** 90 adolescent subjects needing a fixed orthodontic treatment were included and divided in two groups: anterior build-ups group (ABG) and posterior build-ups group (PBG). To compare the effect of build-ups, a control group (CG) of 50 subjects was added. A visual analogic scale (VAS) to evaluate the level of pain and a questionnaire regarding the oral health-related quality of life OHRQoL (OHIP-14, Italian validated version) were compiled by each subject.

**Results:** patients undergoing the orthodontic treatment without build-ups (CG) showed lower OHIP-14 scores than patients in ABG or PBG. Both in ABG than in PBG difficulty eating, mouth pain and embarrassment in public were the most reported collateral effects, as in the CG, but in ABG difficulties in pronouncing some words were referred, too. The ABG showed greater physical pain, physical disability and psychological disability compared to PBG and CG.

**Conclusion:** anterior build-ups affect patients' quality of life a lot more than posterior build-ups, in term of greater difficulties in eating and speech, physical pain, physical disability, psychological disability and greater intensity of pain after build-ups' placement.

## EVALUATION OF AIRWAYS BEFORE AND AFTER TREATMENT IN ADULT PATIENTS WITH HERBST MINISCOPE

Scire' Scappuzzo G., Distefano M.L., Callea S., Paduano F.P., Altilia M.

Health Department, University Magna Graecia of Catanzaro, Catanzaro, Italy

**Aim:** the purpose of this study is the assessment of upper airway size modification in skeletal Class II malocclusion with mandibular retrusion in adult patients treated by the Herbst Miniscope appliance.

**Methods:** in this retrospective study, 20 end-of-growth patients with skeletal class II were treated with the Herbst miniscope functional appliances for an average of 12 months.

**INCLUSION CRITERIA:**

- Skeletal class II malocclusions ( $ANB > 4^\circ$ );
- end-of-growth patients CS4-CS5-CS6;
- convex profile and aesthetically compromised;
- mesiofacial or brachyfacial pattern.

**EXCLUSION CRITERIA:**

- $ANB \leq 4$ ;
- periodontal disease and tooth mobility;
- growing subjects;
- dolicofacial pattern;
- retreated patients.

Cephalometric analyses were performed by the same operator using the Delta-Dent 2.0 software TM. Airway size changes were assessed by comparing lateral telerradiographs taken at time T0, just before the start of treatment, with that at time T1, after removal of the Herbst Miniscope appliance.

**Results:** the Herbst Miniscope is mainly used to correct skeletal class II malocclusions and shows maximum effectiveness in patients at the peak of growth. In last years, it has also been increasingly used in adult patients and in the treatment of mild to moderate OSA. Herbst is a fixed mandibular advancement device (MAD), holding jaw in a protruded and stable position. Increase was observed in upper airway size and reduction in air flow resistance.

**Conclusion:** according to our measurements, Herbst Miniscope appliance produces a significant increase in the upper airways size. Then this appliance is the first choice therapy in the treatment of mild to moderate OSA or when CPAP, the gold standard in sleep apnea therapy, is not well tolerated by the patient.

## DENTOSKELETAL RESPONSE TO RAPID MAXILLARY EXPANSION IN DIFFERENT VERTICAL GROWING PATTERNS

Fanelli S., Marino L., Milazzo A., Fusaroli D.

Department of Orthodontics, Head: P. Cozza, University of Rome Tor Vergata, Rome, Italy

**Aim:** the aim of this study was to analyze the variation of dentoskeletal effects after rapid maxillary expander therapy in subjects with different vertical growth patterns.

**Methods:** the study sample consisted of 94 patients (32 males, 62 females; mean age  $8.9 \pm 1.5$  years) treated with Rapid Maxillary Expander anchored on first permanent molars. For each subject, lateral cephalograms and maxillary digital dental casts were available before RME (T1), at appliance removal (T2), and 1 year after appliance removal (T3). All subjects were divided into three groups according to vertical facial patterns (Low-Angle, Normal-Angle and High-Angle). Cephalometric analyses were conducted on lateral cephalograms. The virtual 3D models were used to analyze the torque of the first permanent molars, the intercanine and intermolar width.

Mean differences between vertical facial subgroups were contrasted by Anova multicomparison test ( $P < 0.05$ ).

**Results:** in the short term (T2-T1), High-Angle subjects showed a mandibular clockwise-rotation respect to the other groups. No significant vertical and sagittal skeletal changes were found between the groups in the long-term (T3-T1). In High-Angle subjects, a greater increase in upper molar torque was observed when compared to the other groups. The Low-Angle patients showed a greater increase of the intercanine diameter.

**Conclusion:** hyperdivergent subjects showed an increased buccal tipping of the anchor molars after expansion. Hypodivergent subjects evidenced a lower buccal tipping after expansion and an increased effect in the anterior region.

## PREVALENCE OF DENTAL ANOMALIES IN A SAMPLE OF 840 SUBJECTS FROM SOUTH ITALY

Martina S., Gallotti A., Amato A., Orefice R., Amato M.

Department of Medicine, Surgery and Dentistry, Scuola Medica Salernitana, University of Salerno, Baronissi, Italy

**Aim:** to investigate the prevalence of dental anomalies such as impacted teeth, supernumerary teeth, dental agenesis, and dental transposition in a population of children and adolescents from Campania.

**Methods:** good diagnostic quality digital panoramic radiographs (performed in a single radiographic center in Naples in a period between 2010 and 2019) of 840 subjects aged 8-19 (438 F, 402 M, mean age = 12.0 years) were analyzed by two examiners. The following factors were studied: displaced maxillary canine (canine was considered displaced with  $\alpha$  angle > 45° and/or canine cusp in sector 3,4 or 5), impacted teeth (if they had not erupted 1 year after the mean age of eruption), dental agenesis (except third molar), dental transposition, supernumerary teeth.

**Results:** 142 subjects (16.9% of the sample) had one or more impacted teeth. Among these, the tooth most frequently included was the upper canine (10% of the total sample), followed by the lower canine (2.1%) and the upper central incisor (1.7%). In a 2.6% of the subjects, there were one or more supernumerary teeth, 1.3% had transpositions and in 14.3% there was at least one displaced maxillary canine, while in 3.9% both maxillary canines were displaced. The most frequent agenesis was of the second lower premolar (3.8%), followed by the upper lateral incisor (2.5%).

**Conclusion:** the results of the study demonstrate the prevalence of dental anomalies in the young population of Campania and the need to investigate their presence radiographically at an early stage.

## DENTO-SKELETAL EFFECTS OF CLASS 3 ORTHOPAEDIC TREATMENT WITH DIFFERENT INTRAORAL DEVICES

Garrisi L., Boggio A., Pittari L., Fiorillo G., Gastaldi G.

Department of Dentistry, Director Prof. E. Gherlone, Vita-Salute San Raffaele University, Milan, Italy

Vita-Salute San Raffaele University of Milan, School of Specialization in Orthodontics, Director Prof. G. Gastaldi Department of Dentistry, Director Prof. E. Gherlone, Vita-Salute San Raffaele University, Milan, Italy; Vita-Salute San Raffaele University of Milan, School of Specialization in Orthodontics, Director Prof. G. Gastaldi, Milan, Italy

**Aim:** the present literature review examined the dental and skeletal effects of maxillary protraction in skeletal Class III young patients treated with facial mask and different tooth-anchored devices.

**Methods:** a computerized literature research for studies was performed in PubMed, MEDLINE, Cochrane Database of Systematic Reviews, Embase, Lilacs, Scielo and Google Scholar, with no language limitation, up to february 2021.

Keywords used for the research were: "Skeletal and dental effect AND Reverse-Pull Headgear OR Protraction Headgear OR protraction facemask OR Maxillary protraction".

Research criteria included studies concerning orthopaedic maxillary protraction therapy in Skeletal Class III patients aged between 3 and 8 years old treated with face mask and tooth-borne intraoral devices.

Exclusion criteria were functional and dental Class III malocclusion, cleft lip palate, craniofacial anomalies or syndromes,

skeletal anchorage devices, previous orthodontic treatment. The initial research and quality assessment, with consideration of PRISMA protocol, was carried out independently by two reviewers. Then a descriptive statistic was performed when possible.

**Results:** the initial research identified 112 studies. After a thorough selection process and assessment of the individual quality score, a total of 13 articles met all the inclusion criteria. The results showed that there was no uniformity in the choice of tooth anchorage device design but there were similarities in dental and skeletal changes concerning the following cephalometric parameters: horizontal movement of point A, horizontal movement of point ANS, upper incisor proclination, maxillary first molar mesialization.

**Conclusion:** no significant differences were found considering the main skeletal and dental effects of different tooth-anchored protraction appliances in patients between 3 and 8 years old.

## VALIDATION OF A 3D IMAGING ORTHODONTIC PROTOCOL INCLUDING DIFFERENT DIGITAL RECORD

Giambò R., Tamà C., Bellocchio A.M., Portelli M., Militi A., Nucera R.

Department of Biomedical Sciences Dentistry and Morphological and Functional Imaging, University of Messina, Messina, Italy

**Aim:** the aims of this study were: to evaluate the time required to import in the same software environment the following acquisitions (CBCT scans of both arches in occlusion, digital models of dental arches, and face scan of the patient), and to estimate the method intra-observer reproducibility to scientifically validate the applied method.

**Methods:** the above-mentioned digital records were imported into the Dolphin 3D software (Dolphin Imaging, Chatsworth, CA). CBCT was divided into the upper and lower arch and then reassembled in occlusion using occlusion scan obtained from digital models in occlusion, digital models of arches were superimposed to the new obtained CBCT, finally, the face scan was superimposed to the DICOM volume.

On this assembled virtual patient the two following cephalometric outcomes were measured two time and two weeks apart to test method reproducibility: ANB angle (°) and Wits Appraisal(mm). The outcome evaluation was performed on five

patients repeating all the import and assembling procedures. The time interval required to complete the procedure was measured to calculate the average time the operator required to perform this software procedure.

To assess the methodological error, paired t-test and Intra-class correlation coefficient (ICC) were used to assess the intra-operator reliability.

**Results:** no differences ( $p < 0.05$ ) were found between the two readings, all measurements were highly reliable with the ICC varying from 0.76 to 0.84. On average 42 minutes are necessary in order to complete the assembling of the considered imported patient's records into the Dolphin 3D software interface.

**Conclusion:** the assembling procedure of considered digital records into the same software can be considered a scientifically validated procedure. However, it is a time-consuming procedure and it is not possible to imagine it during routinary treatment planning activities.

## PUBLIC COVERAGE OF ORTHODONTIC CARE IN EUROPE

Laganà D., Cordaro M., Saran S.

A. Gemelli University Hospital Foundation IRCCS, Catholic University of the Sacred Heart, Master's Degree Course in Dentistry and Dental Prosthetics. Director: Prof. M. Cordaro, Chair of Orthodontics: Prof. C. Grippaudo, Rome, Italy

**Aim:** the purpose of this study is to compare the different ways of coverage of the orthodontic care by the State healthcare systems and the compulsory insurances in these European nations.

**Methods:** we searched the information about the funding and refunding of the orthodontic therapies into the *European Orthodontic Guide*, published by the European Federation of Orthodontic Specialists Associations in 2013, the *Manual of Dental Practice*, published by the Council of European Dentists in 2015, the reports of the World Health Organization and the sites of the national health offices.

**Results:** the public coverage of the orthodontic care in Europe is very inhomogeneous both in criteria of access and in the percentage of coverage. The main criteria of access to this funds is

the age, mostly fixed in the limit of 18 years, only Austria, Czech Republic, Sweden and some Greek insurances provide some contributions for adults patients. Some countries as Croatia, Slovenia and Monaco fully cover the orthodontic treatments to young patients without exclusion criteria, while other nations as Bulgaria, Portugal, San Marino and Spain don't provide the orthodontic therapies in any case. Twelve countries fully cover the treatments for the most severe case or for some specific therapies and the same number of nations offer a partial contribution to the orthodontic costs with no severity exclusion, mainly limiting it to the youngest residents.

**Conclusion:** the majority of the European nations seems to offer an acceptable access to orthodontic care for the most severe malocclusions.

## THE INFLUENCE OF THE PANDEMIC ON THE ORTHODONTIC PATIENTS

Laganà D., Cordaro M., Saran S.

A. Gemelli University Hospital Foundation IRCCS, Catholic University of the Sacred Heart, Master's Degree Course in Dentistry and Dental Prosthetics. Director: Prof. M. Cordaro, Chair of Orthodontics: Prof. C. Grippaudo, Rome, Italy

**Aim:** the purpose of this study is to figure out how much and if the pandemic is influencing the orthodontic patients, in particular their requests and needs.

**Methods:** this study is based on a survey analysis of 155 patients who accepted to answer anonymously to few questions. This questionnaire examined how the pandemic influenced the decision to have this kind of therapy, the frequency of orthodontic checks, the importance that patients attributed to their smile, the attention to oral health and the preference of a specific orthodontic device. Furthermore they were demanded about the orthodontist's availability during this particular situation.

**Results:** the 43,5% of the patients revealed that the frequency of orthodontic visits didn't change and even for the 21,4% of

the sample it increased. The 76,8% of the answers clarified that the pandemic didn't influenced the decision to see an orthodontist, while the 81,4% affirmed that neither the obligatory use of facial mask conditioned this choice. Only 7,1% of the patients was pushed to ask a particular orthodontic device because of the pandemic. Even if the 83,3% admitted that the importance of smile aesthetic didn't change for them, in the 12,8% it increased. The 72,1% of the interviewed patients reported that their orthodontists' availability didn't change, instead the 22,7% reported a decrease.

**Conclusion:** it seems that the current sanitary emergency isn't making worse the orthodontic care unlike, unfortunately, it's happening in other medical fields.

## DIMENSIONAL VARIATIONS OF THE UPPER ARCH IN THE THERAPIES OF CL. II WITH INVISALIGN

Mampieri G., Poma G., Giaccotti A.

Department of Clinical Sciences and Translational Medicine, University of Rome Tor Vergata, Rome, Italy

**Aim:** class II is the most frequent malocclusion in the growing patients. Upper molar distalization is a common strategy of treatment to correct this malocclusion. The aim of this study is to evaluate the upper arch form variations after the correction by using the Invisalign® Technique.

**Methods:** 21 patients (average age 12.7 years) were treated with the Invisalign technique. Sequential distalization was programmed according to modified Align protocol. Digital 3D models (STL file) were obtained by intraoral scanner (iTero® Element). The STL files were imported into the Meshmixer software, to create an orthodontic model and subsequently imported into the Meshlab software. Reference points were identified by Moorrees, through which we calculated: length of the anterior and posterior arch; width of the Inter canine arch; 3 Measurement of the width of the arcade Inter molar.

**Results:** evaluation of the overall averages at time T1 and T2 shows that all widths increases after orthodontic treatment. In contrast, the anterior and posterior arch lengths decreases. For each variable the efficacy of the treatment was verified through the T-student test.

**Conclusion:** the analysis of the dimensional variations of the maxillary arch shows us that the major action is on the expansion of the arch and on the variation of the arch form than the pure distalization movement.

The aligners prove to be a valid tool to correct the malocclusions of Cl II, but their action, is mainly due to changes arch form and to the mesial repositioning of the mandible or to a residual mandibular growth, rather than a decisive action of distalization in the maxillary arch.

## CUSTOMIZED ORTHODONTIC TREATMENT IN PATIENT WITH ROOT STUNTING DUE TO RADIOTHERAPY

Mandelli A.<sup>1</sup>, Caldara G.<sup>1</sup>, Fiorillo G.<sup>2</sup>, Mandelli G.<sup>2</sup>, Gastaldi G.<sup>2</sup>

Department of Dentistry, Director Prof. E. Gherlone, Vita Salute San Raffaele University, Milan, Italy

<sup>1</sup>Master's Degree Course in Dentistry and Dental Prosthetics, Vita-Salute San Raffaele University of Milan, President: Prof. O. Cremona, Milan, Italy

<sup>2</sup>School of Specialization in Orthodontics, Vita-Salute San Raffaele University of Milan, Director: Prof. G. Gastaldi, Milan, Italy

**Aim:** to highlight the usefulness of a customized orthodontic treatment to increase the control of tooth movement and reduce the risk of root resorption in a patient with root stunting due to radiotherapy in early mixed dentition.

**Methods:** a 21-year-old patient requires an orthodontic treatment to improve the aesthetics of the relational smile. Medical history: at the age of 7 she was treated with radiotherapy and chemotherapy for rhabdomyosarcoma in the right infratemporal fossa with erosion of the orbital floor and extension to the maxillary sinus.

Problem list:

1. frontal macro aesthetics: hypoplasia of the right orbital cavity, facial asymmetry, vertical growth defect and chin deviation to the right.
2. LL x-ray: Class II div.1 hypodivergent.
3. Mini aesthetics: asymmetrical dento-gingival exposure.
4. OPT: root stunting of 15 14 13 12 45 44 43 42, asymmetry of the right condyle, reduced vertical and sagittal dimension on the right sight of the mandible.

5. Intraoral examination: slightly increased overjet, normal over-bite, second bilateral canine and molar class.

6. Good periodontal support.

Considering the patient's chief concern, the medical history, the problem list, the orthodontic treatment must avoid in particular a further root resorption and loss of periodontal support.

Basing on this statement, the orthodontic treatment is planned using light forces and must be stopped earlier than usual, accepting a less than perfect therapeutic result. A clear aligner (Spark Ormco) has been chosen for orthodontic treatment. Dental movements have been planned with gradual movement sequence.

**Results:** after few months of treatment a good periodontal support is observed while there is no root resorption in OPT.

**Conclusion:** the possibility of previewing the dental movement and the use of a custom made therapy could be considered useful to avoid side effects in patients after radiotherapy.

## ORTHODONTIC LINGUAL APPLIANCE EXTRACTION TREATMENT: ORIGINAL RESTORATIVE REHABILITATION

Scantamburlo D.<sup>1</sup>, Drago G.<sup>1</sup>, Favero R.<sup>1</sup>, Schiavon G.<sup>1</sup>, Favero L.<sup>2</sup>

<sup>1</sup>Department of Neuroscience, Odontostomatology Institute, University of Padua, Padua, Italy

<sup>2</sup>Professor, Director of Orthodontic Postgraduate Program, Odontostomatology Institute, University of Padua, Padua, Italy

**Aim:** the aim of this case report is to introduce direct composite restorative rehabilitation in orthodontic treatment finishing: a premolar was reshaped into a molar without other extractions.

**Methods:** a 29-year-old patient underwent orthodontic treatment. Class II malocclusion, open bite, severe crowding and periodontally compromised teeth were diagnosed. The patient had been treated with a lingual fixed orthodontic appliance, and extraction of 14, 35, 45. It was chosen to extract 26 -instead of 24 - because of his periodontally compromised condition, furcations involvement and ectopic position of 25.

Element 25 was orthodontically replaced and reshaped into 26. Direct composite restoration was chosen with these original procedures: alginate impressions; diagnostic wax-up; silicon impressions of diagnostic wax-up included in thermoplastic

device, holes were made for composite surplus; sectional matrix was fixed in liquid rubber dam to reproduce pontic anatomy; sectional matrix was placed on interproximal space; cervical restoration; direct restoration of tooth anatomy using silicon impression and thermoplastic device.

**Results:** morphological and functional restoration of 26 was obtained considering all of its surfaces. The space between 25 and 27 was closed respecting dental contact area. Occlusal surface was reproduced as the controlateral one. The cervical margin was restored with feather edge respecting the root and gingival anatomy.

**Conclusion:** this original restorative procedure described above allowed correct tridimensional restoration absolutely respecting the dental and parodontal health.

## THE USE OF NEW CLEAR ALIGNER FUNCTIONAL DEVICE IN A SKELETAL CLASS III: A CASE REPORT

Schiavon G.<sup>1</sup>, Favero R.<sup>1</sup>, Volpato A.<sup>1</sup>, Carraro B.<sup>1</sup>, Favero L.<sup>2</sup>

<sup>1</sup>Department of Neuroscience, Odontostomatology Institute, University of Padua, Padua, Italy

<sup>2</sup>Professor, Director of Orthodontic Postgraduate Program, Odontostomatology Institute, University of Padua, Padua, Italy

**Aim:** the aim of this case report consists in improving skeletal class III relationships using a new clear aligner functional device in a patient with mandibular overgrowth and iperdivergent growth pattern.

**Methods:** a 8-year-old boy presented with class III malocclusion, anterior and posterior crossbite, 5,5 mm overbite and - 2 mm overjet on casts. From cephalometric study -4,1 mm Wits and 3,3° ANB values of skeletal class III emerged. Intercisal angle of 142,7° with superior incisal endoinclination was evaluated. Non surgical treatment was decided. A rapid palatal expansion was performed to correct crossbite. Then after unsuccessful attempt with Petit face mask a new clear aligner intraoral functional device was used. An original removable interceptive aligner made of duran 1,5 x 125 mm Pet-G with sag-

ittal action for maxilla advancement and mandible retraction due to Ni-Ti open springs was developed by means of computerized technique. A year after the delivery, pictures to verify the achievements and measurements to evaluate the efficacy of the therapy were taken.

**Results:** cephalometric values were changed. Overbite of 3,5mm and 5,7 mm overjet were noticed. Wits of -1,5 mm and 4,9° ANB were evaluated. Intercisal angle of 129,4° with incisal normoinclination was assessed. Vestibularization of superior incisors with 109,5° U1-palatal plane was observed.

**Conclusion:** it's possible to conclude that our device can be used as an alternative to EOT. Improvements in skeletal class III relationships and also overjet were achieved, but other studies are needed to confirm this therapy as useful for selected patients.

## DISTALIZATION OF MANDIBULAR DENTITION WITH SKELETAL ANCHORAGE: MINISCREW VS RAMAL PLATE

Sturabotti G., Carrieri M., Altieri F., Cassetta M.

Department of Oral and Maxillo Facial Sciences, Sapienza, University of Rome, Rome, Italy

**Aim:** consider the advantages and disadvantages of using ramal plates instead of miniscrew.

**Methods:** the search was carried out on PubMed using the keywords "distalization" AND "mandibular" AND "miniscrew" OR "ramal plate". The search produced 78 articles and 4 were selected for this review.

**Results:** the articles analyzed show several advantages in using the ramal plate instead of the miniscrews, especially when it is necessary to distal the entire mandibular arch. In fact, they can withstand the higher forces required for this purpose with better stability because they are anchored by multiple screws. Furthermore, the force of the ramal plate is more parallel to the functional occlusal plane, and the lateral component is mini-

mal, causing less rotation of the occlusal plane than with miniscrews. This determines less molar distal tipping during the distalization. One disadvantages of using ramal plates is surgical procedures for placement and removal of the plates which creates greater discomfort for the patient compared to miniscrews. Another disadvantage in the use of ramal plates is the possibility that the retromolar foramen might be near the placement area, which may exist in 9–25% of the population. Finally, in the various studies analyzed, a higher amount of distalization results with the use of ramal plates.

**Conclusion:** despite several advantages in the use of ramal plates, the choice must be made according to the therapeutic needs and clinical characteristics of the patient.

## ETIOLOGY OF SECOND MANDIBULAR MOLARS IMPACTION: A REVIEW OF THE LITERATURE

Sturabotti G., Carrieri M., Altieri F., Cassetta M.

Department of Oral and Maxillo Facial Sciences, Sapienza, University of Rome, Rome, Italy

**Aim:** evaluate the main etiological factors underlying the impaction of the lower second molar.

**Methods:** the search was done through PubMed using keywords “mandibular” AND “second” AND “molar” AND “impaction” AND “etiology”.

The search produced 143 results, 5 were chosen for this review, those most closely related to the topic.

**Results:** the articles analyzed agree that crowding is the main cause of impaction of the second molar. Other possible etiological factors are vertical condylar growth direction, presence of dental anomalies such as follicular cyst of the second lower

molar, supernumerary in the region of interest, complicated root anatomy, ankylosis. There may still be a malfunction of the periodontal membrane. Some studies have also identified iatrogenic factors such as the presence of an incorrectly cemented band on the mandibular first molar or prevention of the mesial shift of the first permanent molar caused by lip bumper or lingual arch therapy. The presence of the 3rd molar does not appear to be a risk factor.

**Conclusion:** the etiological factors found are different, however in most cases we can find a multifactorial etiology at the basis of this condition.

## IMPACTION OF LOWER SECOND MOLARS: A CASE REPORT

Cassetta M., Altieri F., Padalino G., Sturabotti G., Carrieri M.

Department of Oral and Maxillo Facial Sciences, Sapienza University of Rome, Rome, Italy

**Aim:** resolution of a case of impaction of the lower second molar using orthodontic devices with skeletal anchoring.

**Methods:** a 15-year-old female patient who has been undergoing treatment for 5 years at the U.O.C of orthodontics at the Policlinico Umberto I in Rome has a right lower second molar impacted. The treatment plan provides for the uprighting of the dental element 4.7 through skeletal anchoring. First, the germectomy of the 4.8 is performed and a 2.3 mm diameter and 7 mm long miniscrew is inserted into the retromolar space, the miniscrew is connected to orthodontic buttons positioned on

the buccal and oral surfaces of 3.7 crown (previously exposed) through two elastic chains.

**Results:** the uprighting procedure took about 4 months and ended successfully with the presence of the dental element in the arch.

**Conclusion:** although this condition is not very common when it occurs it is a real challenge for the clinician. The use of a skeletal anchor instead of a dental anchor has several advantages: there are no unwanted dental effects, no patient cooperation is required and there is a reduction in treatment times.

## THE COMPUTER-GUIDED INSERTION OF MINISCREWS: DESCRIPTION OF A TECHNIQUE

Cassetta M., Altieri F., Mezio M., Padalino G., Sturabotti G., Carrieri M.

Department of Oral and Maxillo Facial Sciences, Sapienza University of Rome, Rome, Italy

**Aim:** the purpose of this work is to describe a computer-guided technique for correct insertion of palatal orthodontic miniscrews.

**Methods:** the protocol used provided, for each patient, the taking of a precision impression and the request of a CBCT. The localization phase of the site for the miniscrews was confirmed by

the clinician, with subsequent construction of the template and the orthodontic device. BENEFIT miniscrews were used.

The surgical guides are produced with the AM (Additive Manufacturing) technique and allow the doctor to safely apply the miniscrews, providing precise guidance on the inclination, parallelism and insertion stop.

The most favorable site and the insertion direction of the miniscrews were identified on a cone computed tomography (CBCT) scan. A digital scan of the upper jaw was superimposed on the patient's CBCT scan and a guide for surgical insertion was custom made. This consisted of four rigid cylindrical sheaths which ensured that the miniscrew head was inserted at the correct angle and depth required. Subsequently, two screws (Spider Screw K2 Regular Plus, HdC, Vicenza, Italy) were implanted, one 11 mm long and 2 mm in diameter on the right and one 9 mm long and 2

mm in diameter to the left. Then, a Hyrax RPE hybrid was cemented on the teeth and attached to the miniscrews.

**Results:** the technique used allows the insertion of orthodontic miniscrews with a correct angle and correct depth while respecting the limiting anatomical structures. The procedure used is safe and minimally invasive for the patient.

**Conclusion:** this technique finds a very wide field of application, being able to be applied for various orthodontic devices with skeletal anchorage.

## LEVELING THE CURVE OF SPEE: CONTINUOUS ARCHWIRE TREATMENT VS INVISALIGN SYSTEM

Tiberti G., Romano A., Franzin L., Turlà R.

Department of Orthodontics, Head: Paola Cozza, University of Rome Tor Vergata, Rome, Italy

**Aim:** to compare leveling of the curve of Spee (COS) achieved by fixed appliances and third generation clear aligners (Invisalign) without the use of virtual bite ramps.

**Methods:** this retrospective study involved 62 subjects with an increase COS depth. The first group of 32 patients was treated with full-fixed appliance (F-Group; male = 12, female = 20), mean age  $22 \pm 4$  months. The second group of 30 patients was treated with Invisalign appliance (I-Group; male = 13, female = 17), mean age  $24 \pm 5$  months. Pre-treatment (T0) and post-treatment (T1) lateral cephalograms and digital dental casts were analyzed. The cephalometric radiographs were scanned into imaging software (version 11.0; Dolphin Imaging, Chatsworth, Calif). Standard cephalometric landmarks were identified on each radiograph and a total of 21 variables were examined. Data were analyzed using SPSS version 23 for Win-

dows (IBM Corporation, Chicago, Ill). Measurements of COS were obtained on the right and left sides in the deepest points of the curve. The intragroup variation between T0 and T1 were analyzed with a paired *t*-test. The intergroup variation was evaluated using an unpaired *t*-test.

**Results:** the leveling of COS was statistically significant comparing post and pre-treatment within the groups. Flattening of the curve occurred mainly through posterior extrusion in the F-group, with a flaring of the lower incisors; differently, the levelling of COS was achieved through anterior intrusion in the I-group, with a greater control in the proclination of incisors, during the intrusion movement.

**Conclusion:** traditional continuous archwire treatment and Invisalign system were both effective for levelling the curve of Spee.

## EVALUATION OF MASTICATORY MUSCLES IN GROWING PATIENTS WITH SAGITTAL SKELETAL DISCREPANCIES

Barbiero V., Argenziano T., Iuorio M., De Rosa F., Puzo R., Rongo R.

Department of Neuroscience and Reproductive and Odontostomatological Sciences, School of Orthodontics and Temporomandibular disorders, University of Naples Federico II, Naples, Italy

**Aim:** this study aimed at evaluating the masticatory muscles activity in young patients with sagittal malocclusions by using a standardized surface electromyography protocol during static and dynamic tasks.

**Methods:** 17 children with Class I malocclusion (age  $12.9 \pm 2.4$ , 7 M, 10 F) and 14 children with Class II malocclusion (age  $11.8 \pm 2.2$ , 4 M, 10 F) were recruited. The electromyographic activity of

temporal, masseter and sub-mental muscles on both sides was recorded for both groups. Mann-Whitney U test and chi-squared test were used in the statistical analysis ( $P < 0.05$ ).

**Results:** In the static tasks no statistically significant differences were reported between the two groups (POC medium; Class I =  $75.1 \pm 8.1$ ; Class II =  $79.5 \pm 6$ , ES = 0.61) (ASIM; Class I =  $16.9 \pm 14$ ; Class II =  $11.23 \pm 10$ , ES = 0.46). All the subjects

showed a slight asymmetric muscular activity independently by the sagittal malocclusion. During masticatory tests, all the participants showed an asymmetric muscular activation between right and left chewing task, particularly in subjects with Class I malocclusion. During deglutition tasks the Class I group showed a more symmetric and greater activation of the

SM (POC SM; Class I =  $82.2 \pm 3.5$ ; Class II =  $70.9 \pm 17.1$ , ES = 0.91) and MM (POC MM; Class I =  $73.6 \pm 8.4$ ; Class II =  $60.4 \pm 22.3$ , ES = 0.78) respect to Class II.

**Conclusion:** sagittal malocclusion seems to have a small or insignificant effect on the muscular activation in children. All indices showed an asymmetric activation.

## GINGIVAL RECESSIONS AFTER MINIMUM 2-YR-RETENTION POST NON-EXTRACTION ORTHODONTIC TREATMENT

Bencivenga M.S., Carfora M., De Simone A., Fanuzzi F., Fiori A., Nucci L.

Multidisciplinary Department of Medical-Surgical and Dental Specialties, Program of Orthodontics, University of Campania Luigi Vanvitelli, Caserta, Italy

**Aim:** to assess gingival recessions (GR) and periodontal health in patients previously treated with non-extraction orthodontic treatment and retention at a follow up of minimum 2 years after the end of treatment.

**Methods:** data from patients aged between 16 and 35 yrs, with a previous non-extraction orthodontic treatment and at least 2 yrs of retention and full documentation were collected. The cast models were digitalized using the TRIOS® 3Shape intraoral scanner and the Viewbox 4 software was used for the measurements on digital models and cephalograms. The following parameters were scored: inclination of the lower and upper incisors (IMPA and I<sup>^</sup>SN); anterior crowding; transverse molar and canine diameters. At the clinical periodontal examination post-retention GR in mm; probing pocket depth, Bleeding of Probing score, Full Mouth Plaque Score; gingival phenotype and integrity of retention were recorded.

**Results:** from the 240 teeth of the frontal sextants examined, 6 had GR (from 1-6.5mm) found in 3 patients. 3 of these GR were in the upper arch and 3 in the lower. In the upper arch 2 GR were on the canines, 1 was on a central incisor, while all GR were present on incisors (2 central and 1 lateral) in the lower arch. An average expansion of the intermolar diameter of 3.29mm (SD 2.73) and an increase in the intercanine diameter of 1.43mm (SD 3.40) was performed during orthodontic treatment. The final average IMPA was 95.1° with an increase of 3.65° (SD 8.14). 7 of 20 patients completed orthodontic treatment with IMPA > 95°. There was no association between this finding and the presence of GR.

**Conclusion:** looking at our results, a non-extraction orthodontic treatment performed with controlled forces and correct biomechanics, seems to not affect the development of buccal and lingual GR or the periodontal health after at least two years of retention post-orthodontics.

## MANAGEMENT OF A GOLDENHAR PATIENT WITH A CUSTOM-MADE OSTEOSYNTHESIS PLATE: A CASE REPORT

Bianco A., Tonni I., Carlo T., Zanetti U., Visconti L., Paganelli C.

School of Dentistry, Department of Medical and Surgical Specialties, Radiological Sciences, and Public Health, University of Brescia, Brescia, Italy

**Description of the case:** craniofacial microsomia (CFM) is a syndrome characterized by accessory tragus, mandibular hypoplasia and epibulbar dermoid.

In this case report we describe the orthodontic-surgical treatment of a Pruzansky Kaban IIa type CFM associated with lip and palate cleft in a non-growing patient.

Pre-orthodontic examination showed a truly asymmetrical facial contour with an underdeveloped right side, class III hyperdivergent profile, class III malocclusion, transverse discrepancy, severe crowding, palatal displacement of 14, agenesis of 42.

**Treatment:** a combined surgical and orthodontic treatment plan has been designed. Orthodontically, after a maxillary expansion, a multiblocks device was used. Extraction of 14 and 24 and 32 was performed to correct crowding.

Surgical planning was developed using a three-dimensional virtual program (TruMatch 1.0). The patient was treated with a Le Fort I osteotomy without splints, a sagittal split osteotomy on the healthy mandibular side, and a vertical ramus osteotomy with prosthetic grid tailored to osteosynthesis on the dysmorphic side.

Post-treatment clinical and radiological evidence showed a strong improvement in facial harmony, symmetry and stable occlusion with adequate OJ and OB.

**Discussion:** this report underlines the importance of precise diagnosis based on virtual 3D modeling. Custom surgical cutting, drilling guides, osteosynthesis and prosthetic grid were realized in a computer aided design and manufacturing way,

produced by laser melting from a virtual .stl file. The procedure described helps and guides the surgeon to obtain a good final morphological result.

**Conclusion:** a splintless bimaxillary orthognathic surgery is an effective therapeutic option for CFM adult patients and the combined use of a custom-made osteosynthesis mesh improves the precision in respect of patient's individuality.

## ROOT RESORPTION: A LITERATURE REVIEW

Calò A, Tripicchio C., Vella M., Butti A.

Department of Biomedical, Surgical and Dental Sciences, IRCCS Ca' Granda Foundation, Ospedale Maggiore Policlinico, University of Milan, Milan, Italy

**Aim:** the Purpose of this study is to present a review of the literature concerning the phenomenon of root resorption, its diagnosis and its correlation with the field of orthodontics.

**Methods:** the review was conducted by consulting the Medline database. The research produced 4090 results including 357 reviews from which 159 were selected based on the topic.

**Results:** the predisposing factors to root resorption must be found in elements related to the patient or to the treatments, such as orthodontic therapies and dental whitening procedures. Going into more detail, its etiology can be traced back to various causes including pulp and periodontal infections, excessive pressure at the level of the ligament and dental trauma. Usually, the orthodon-

tic induced root resorption is mild to moderate. A root resorption is instead defined as severe when the resorption is greater than 4mm. To fully evaluate the root resorption, periapical radiographs with parallel beam technique are necessary, in order to avoid image distortions. To diagnose root resorption, it is also possible to use biological markers such as Dentin Matrix Protein 1 (DMP1) which, if present at high levels, represents sign of root resorption.

**Conclusion:** due to the absence of a resolutive therapy the most important thing to do is making an early diagnosis using periapical radiographs or biological markers and emphasizing the follow up in cases at greater risk such as traumatized dental elements or patients undergoing orthodontic therapy.

## MANAGEMENT OF CHILDREN BORN WITH CLEFT LIP AND PALATE (CLP): A REVIEW

Calò A., Tripicchio C., Vella M., Butti A.

Department of Biomedical, Surgical and Dental Sciences, IRCCS Ca' Granda Foundation, Ospedale Maggiore Policlinico, University of Milan, Milan, Italy

**Aim:** this review analyses the therapeutic management of children born with cleft lip and palate. In particular, its aim is to understand how the treatment evolved over the years.

**Methods:** the considered articles were the ones published in the last 50 years on various journals such as the American Journal of orthodontics.

**Results:** orofacial clefts cause implications in the development of dental and skeletal structures, hearing and phonation, thus, affecting the subjects' quality of life. Multidisciplinary treatment is required. The purpose is to divide the treatment interventions into defined stages: early diagnosis in prenatal period using ultrasonography, during neonatal period (3-5 months) with nasoalveolar molding practice (NAM), a nonsurgical way to reshape

the gums, lip and nostrils before cleft surgery. In mixed dentition (7-12) with bone graft techniques and orthopedic maxillary advancement. At the end, in permanent dentition (12 years) any remaining skeletal surgical corrections. Then, once skeletal defects are completed, plastic surgery of nasolabial soft tissues. During the years, important technical achievements as, distraction osteogenesis, temporary anchorage devices or miniscrews, were introduced, mainly due to the advent of CBCTs in order to make treatments more effective.

**Conclusion:** the treatment of orofacial clefts requires the collaboration of orthodontists and other professional figures including surgeons and speech therapists. This collaboration is essential for improving the patient's quality of life.

## TWO DIFFERENT PROTOCOLS FOR LATE MAXILLARY PROTRACTION IN CLEFT PATIENTS

Calò A., Tripicchio C., Vella M., Butti A.,

Department of Biomedical, Surgical and Dental Sciences, IRCCS Ca' Granda Foundation, Ospedale Maggiore Policlinico, University of Milan, Milan, Italy

**Aim:** the aim of this study is to present the major differences between the classical protocol proposed by Liou for maxillary protraction and the one used at Children's Hospital Los Angeles (CHLA) to treat patients with cleft lip and palate.

**Methods:** using PubMed, a literature search was performed with these keywords "cleft, maxillary protraction, maxillary rapid expansion, Alt-RAMEC".

**Results:** liou technique consists of a 2-hinged rapid maxillary expander, a repetitive weekly protocol of Alternate Rapid Maxillary Expansions and Constrictions (Alt-RAMEC) and intraoral maxillary protraction springs. Patients in Liou protocol are aged from 9 to 12, have a unilateral cleft lip and palate and hypoplastic maxillae ( $SNA < 82$ ). The maxillary protraction device is a pair

of noncompliant, tooth-borne, intraoral maxillary protraction spring (0.036-inch b-nickel-titanium helix spring). The CHLA protocol differs in the age at which treatment begins, application of a Hyrax rapid maxillary expansion device (Hyrax RME), fixed orthodontic appliances in the lower arch, Class III elastics and reverse-pull facemask. In a cooperative patient, the technique can correct a Class III malocclusion without the LeFort 1 maxillary advancement surgery. Maxillary protraction is achieved through orthopedic movements and dental compensations.

**Conclusion:** CHLA protocol is a good replacement for surgery. The protraction process is dynamic and the correction is attained gradually. For this reason, compliance is essential to achieve results.

## EVALUATION OF SAGITTAL AIRWAY DIMENSIONS AFTER FM THERAPY IN CLASS III GROWING PATIENTS

Chiavaroli A., Lugli L., Roberto S.

Department of Orthodontics, Head: Prof.ssa Paola Cozza, University of Rome Tor Vergata, Rome, Italy

**Aim:** the objective of this investigation was to analyze the effects of RME and FM on the airway dimensions in Class III patients compared with untreated controls.

**Methods:** a sample of 47 Class III patients treated with RME and FM was analyzed. The treated group was compared with 18 untreated controls. Lateral cephalograms for each patient at T1, T2, and T3 were digitized.

**Results:** at long-term evaluation a significant increase in airway size and a significant decrease in adenoid size were found

in the treated group as well as an improvement in the pharynx dimension.

During active treatment the treated group showed a significant improvement in lower airway size and in lower pharynx dimension.

A significant decrease in adenoid size was also found.

**Conclusion:** the treatment with RME and FM produced favorable stable changes in the airway dimensions in Class III subjects when compared with untreated controls.

## GEOMETRIC MORPHOMETRIC ANALYSIS OF PALATAL MORPHOLOGY IN GROWING SUBJECTS WITH OPEN BITE

Di Fazio V., Parrinello F., Cantiero V.

Department of Orthodontics, University of Rome Tor Vergata, Rome, Italy

**Aim:** to assess the morphological shape variations of the palatal vault in Open Bite (OB) growing subjects when compared with a Control Group (CG) by means of Geometric Morphometric Method (GMM).

**Methods:** the OB Group (OBG) consisted of 75 subjects (39 females, 36 males; mean age:  $8.5 \pm 0.8$  years) who were collected retrospectively with the following inclusion criteria: European ancestry, overbite less than 0 mm, mixed dentition stage, prepubertal skeletal maturation (CS1-CS2), hyperdivergent skeletal pattern ( $SN^{\wedge}GoGn > 37^{\circ}$ ). The OBG was compared with a CG of 46 prepubertal subjects presenting normal occlusion (24 females, 22 males; mean age of  $8.3 \pm 1.7$  years). For each subject, lateral cephalograms and maxillary dental casts were available. Landmarks and semilandmarks were digitized on digital dental casts and GMM was applied. Pro-

crustes analysis and principal component analysis (PCA) were performed. OBG was divided in two subgroups: Sucking Habits Group (SHG) (39 subjects) and Non-Sucking Habits Group (NSHG) (36 subjects).

**Results:** PC1 showed significant morphological changes in transverse and vertical dimensions with OBG palates higher and narrower when compared with CG. When comparing the two subgroups no statistically significant differences were found. NSHG demonstrated a slight reduction of the transverse dimension and a deeper palatal vault respect to SHG.

**Conclusion:** OB subjects presented with a significant constriction of the maxillary arch when compared with CG. The morphological palatal shape variations in OBG were not influenced by the presence or absence of non-nutritive sucking habits.

## EVALUATION OF ARCH ALTERATIONS ON DENTAL CASTS BETWEEN HYRAX AND TRANSVERSE SAGITTAL MAXIL

Grassi L.<sup>1</sup>, Pacini M.<sup>1</sup>, Tigani C.<sup>1</sup>, Matarese M.<sup>2</sup>, Fama A.<sup>1</sup>

<sup>1</sup>Fondazione IRCCS Cà Granda Ospedale Maggiore Policlinico, Department of Biomedical, Surgical and Dental Sciences, School of Dentistry, University of Milan, Milan, Italy

<sup>2</sup>Department of Biomedical and Dental Sciences, Morphological and Functional Images, School of Dentistry, University of Messina, Policlinico G. Martino, Messina, Italy; IRCCS Centro Neurolesi Bonino-Pulejo, Messina, Italy

**Aim:** maxillary hypoplasia is the most frequent orthodontic problems. TSME is a fixed appliance that was designed to develop arch form in patients with constricted dental arches both in transverse and in antero-posterior plane. The TSME consists of two bands cemented to the right and left first upper molars, a Hyrax-type transverse expansion screw, two 0.045-inch stainless steel wires extending to the palatal surfaces of the incisors, and two Hyrax-type screws (8 mm) between the molar bands and the incisors.

**Methods:** sample examined of 40 patients (20 males and 20 females mean age  $9.2 \pm 2.6$  years), whose records were selected from the archive of the Orthodontic Department. All the patients were randomly divided into two groups: patients in group 1 were treated with HPE as they presented transverse deficiency of the maxilla only, while patients in group 2 were treated with TSME. Measurements were performed on casts obtained from study models taken before appliance bonding

(T0), immediately after appliance debonding (T1) and at a 6 months follow-up (T2). Additionally, the variations in the following distances have been taken into consideration: inter-molar distance, inter-canine distance, palatal depth, palatal length and arch circumference.

**Results:** both the Friedman test and the rm-ANOVA test, along with their respective post-hoc, show that within both groups the respective variables have a statistically significant increase between T0 and T1 ( $p < 0,05$ ) and a slight decrease between T1 and T2 ( $p < 0,05$ ) that is not clinically relevant, meaning that T2 is greater than T0 in a statistically and clinically relevant way ( $p < 0,05$ ).

**Conclusion:** the study has shown that both RPE and TSME can obtain similar results in transversal palatal expansion. However, TSME seems to be more effective, owing to its specific construction shape, in palatal length and in the arch perimeter.

## INVISALIGN® SYSTEM IN A PATIENT WITH BUDD CHIARI SYNDROME

Maina G., Arrigo M., Chiarello G., Parrini S., Deregibus A., Castrolforio T.

Specialization School of Orthodontics, C.I.R. Dental School Lingotto, Turin, Italy

**Aim:** the aim of the work was to demonstrate the possibility of treating special needs patients with potential no-compliance issues. What makes the case noteworthy were the results that followed the foreseen stages and above all the perfect management by patients' family, who found in this treatment a comfortable and suitable solution for their needs.

**Methods:** patient was a dentoskeletal Class II 11 year old, with increased overjet. The teen described is a type I Budd Chiari Syndrome patient suffering from drug resistant epilepsy. Treatment was based on clear aligner treatment (CAT) with mandibular advancement feature in order to improve dental alignment, to obtain a molar Class I relationship, to reduce overjet and overbite, promoting lower arch advancement. Treatment duration was forecasted in 24 months. Con-

trol appointments were fixed every month, aligners were worn 22 hours per day and aligner change was set at 14 days.

**Results:** the final records showed a molar Class I on both sides with functional overbite and overjet. The patient was treated with only one set of aligners: the forecasted treatment time was respected without any delay. Patient and family compliances were excellent.

**Conclusion:** this case represents a turning point for CAT. The management of a special need patient was relatively easy, especially considering possible therapeutic alternatives and the cognitive disorder associated with the syndrome. This treatment opens the doors to new therapeutic scenarios also for patients with special needs.

## INTERPROXIMAL REDUCTION DURING CLEAR ALIGNERS TREATMENT: RELIABILITY OF DIGITAL PLANNING

Malara A., Palmacci D., Meuli S., Laganà G.

Department of Orthodontics, Head: Prof.ssa P. Cozza University of Rome Tor Vergata, Rome, Italy

**Aim:** to evaluate the accuracy of interproximal reduction (IPR) digitally planned comparing IPR provided on Clincheck software and IPR carried out by the orthodontist during clear aligners treatment.

**Methods:** 20 subjects (10 males, 10 females;  $22.5 \pm 2.3$  years) were recruited from the Invisalign® account of Department of Orthodontics at the University of Rome "Tor Vergata". The inclusion criteria were: mild to moderate dento-alveolar discrepancy (1.5– 6.5mm), Class I canine and molar relationship, full permanent dentition (excluding third molars.), both arches treated using Comprehensive Package by Invisalign® system, treatment plan including IPR.

Pre- (T0) and post-treatment (T1) digital models (.stl files), created from an iTero® scan, were collected. The OrthoCAD® digital soft-

ware was used to measure each tooth mesiodistal width, excluding molars, in upper and lower arches at T0 and at T1. The total amount of IPR performed during treatment was obtained comparing the total of mesio-distal widths at T0 and T1. Significant differences were tested with dependent sample t-test ( $p < 0.05$ ).

**Results:** in the upper arch, IPR was digitally planned on average for 0.62 mm; in the lower arch was 1.87 mm. The amount of enamel actually removed after IPR performing was on average 0.62 mm in the maxillary arch. In the mandibular arch, it was 1.88 mm.

**Conclusion:** the enamel removed *in vivo* corresponded with IPR planned by the Orthodontist using ClinCheck software demonstrating the predictability and reliability of ClinCheck as a fundamental tool in Invisalign® treatment planning.

## MANDIBLE GMM AFTER ORTHODONTIC TREATMENT IN OPEN BITE GROWING SUBJECTS

Marino L., Fanelli S., Alesi G., Mucedero M.

Department of Orthodontics, Head: Prof.ssa P. Cozza, University of Rome Tor Vergata, Rome, Italy

**Aim:** to assess the mandibular changes in anterior open bite (OB) growing subjects treated by Rapid Maxillary Expansion and bite block (RME/BB) or Quad Helix with crib (QH/C) when compared with a Control Group (CG) by using Geometric Morphometric Method (GMM) and conventional cephalometric.

**Methods:** the OB group included 34 subjects (26 girls, 8 boys, mean age  $8.0 \pm 1.0$  y) with dentoskeletal OB and it was divided in two subgroups: RME/BB group and QH/C group. Each subgroup comprised 17 subjects (13 girls, 4 boys). The two subgroups were compared with a CG of 17 subjects (13 girls, 4 boys) matched for sex, age, vertical pattern, and observation periods. Lateral cephalograms were taken before treatment (T1), and at a follow-up observation at least 4 years after the end of treatment (T2). Landmarks and semilandmarks were

digitized on lateral cephalograms and GMM was applied. Procrustes analysis and principal component analysis were performed. Analysis of variance (ANOVA) with Tukey post hoc tests was used to compare the T2–T1 cephalometric changes between RME/BB, QH/C, and CG.

**Results:** in the long term, RME/BB showed a significantly greater decrease of the Condylar axis to mandibular plane angle when compared to CG and QH/C. GMM showed an increased in height of the mandibular ramus in RME/BB group with tendency to counterclockwise rotation of the mandible when compared with QH/C and CG groups.

**Conclusion:** RME/BB subjects showed significant changes in the shape of the mandibular ramus with a counterclockwise rotation tendency when compared with QH/C and CG subjects.

## ANTERIOR OPEN BITE CLOSURE WITH ALIGNERS

Montenegro V.<sup>1</sup>, Patano A.<sup>1</sup>, Laudadio C.<sup>1</sup>, Malcangi G.<sup>1</sup>, Hazballa D.<sup>1</sup>, Coloccia G.<sup>1</sup>, Marinelli G.<sup>1</sup>, Limongelli L.<sup>1</sup>, Inchingolo A.D.<sup>1</sup>, Romeo M.<sup>1</sup>, D’Oria M.T.<sup>1</sup>, Laforgia A.<sup>1</sup>, Dipalma G.<sup>1</sup>, Inchingolo F.<sup>1</sup>, Di Venere D.<sup>1</sup>, Inchingolo A.M.<sup>1</sup>, Farronato M.<sup>2</sup>, Tartaglia G.<sup>2</sup>

Complex Operative Unit of Odontostomatology, Director: Prof. G. Favia

<sup>1</sup>Specialization School in Orthognatodontics Director Prof. F. Inchingolo, Interdisciplinary, Department of Medicine D.I.M. University of Bari Aldo Moro, Bari, Italy

<sup>2</sup>Department of Biomedical, Surgical and Dental Sciences, School of Dentistry, University of Milan, Milan, Italy. UOC Maxillo-Facial Surgery and Dentistry, Fondazione IRCCS Ca’ Granda, Ospedale Maggiore Policlinico, Milan, Italy

**Aim:** adult orthodontic patients are increasingly motivated by aesthetic demands, refusing to wear fixed appliances. Cases of anterior open bite are very difficult to treat satisfactorily, due to their multifactorial etiology and very high recurrence rate. The open bite fascinates orthodontics for the difficulties in treating and maintaining results. This case report describes a case of a 19-year-old female patient presenting skeletal Class II malocclusion, anterior open bite and severe overjet of 7 mm, short lingual frenum.

**Methods:** orthopantomogram and latero-lateral telerradiography of the head, dental impressions and photos were examined. Laser lingual frenectomy and silicone impressions were done

to correct the malocclusion with clear aligners (Invisalign®, Align Technology).

**Results:** the treatment was conducted with 30 aligners changed every 7 days. The patient was instructed to wear aligners 22 hours a day for all the treatment. After the first phase, it was conducted two refinements respectively of 13 and 11 aligners to improve overbite. After 1 year and 7 months, the treatment was concluded with resolution of the malocclusion. It was asked to the patient to wear vacuum-formed retainers during the night for retention.

**Conclusion:** anterior malocclusion of the open bite can be successfully treated with aligners, respecting the right protocols and with the collaboration of the patient.

## FUNCTIONAL ELASTODONTIC THERAPY WITH AMCOP APPLIANCES: A CASE REPORT

Montenegro V.<sup>1</sup>, Malcangi G.<sup>1</sup>, Coloccia G.<sup>1</sup>, Patano A.<sup>1</sup>, Laudadio C.<sup>1</sup>, Marinelli G.<sup>1</sup>, Inchingolo A.D.<sup>1</sup>, Limongelli L.<sup>1</sup>, Dipalma G.<sup>1</sup>, Laforgia A.<sup>1</sup>, Inchingolo F.<sup>1</sup>, Di Venere D.<sup>1</sup>, Cardarelli F.<sup>1</sup>, Farronato M.<sup>2</sup>, Tartaglia G.<sup>2</sup>

Complex Operative Unit of Odontostomatology Director: Prof. G. Favia

<sup>1</sup>Specialization School in Orthognatodontics Director Prof. F. Inchingolo, Interdisciplinary Department of Medicine D.I.M. University of Bari Aldo Moro, Bari, Italy

<sup>2</sup>Department of Biomedical, Surgical and Dental Sciences, School of Dentistry, University of Milan, Milan, Italy. UOC Maxillo-Facial Surgery and Dentistry. Fondazione IRCCS Ca' Granda, Ospedale Maggiore Policlinico, Milan, Italy

**Aim:** to describe a case of a patient with dento-skeletal class II malocclusion, deep bite.

**Methods:** a 9,5-year-old female patient presents Skeletal Class II malocclusion, class II canine and molar, deep bite, periodontal problem affecting the 4.1. Postural problems are also associated with malocclusion, as can be seen by the initial telerradiography, which evidences compression of the first cervical vertebrae with an increase of the cervical curve. The patient used only one elastodontic AMCOP appliance (Micerium), made with a thermoplastic, certified and biocompatible material.

**Results:** the therapy duration was 18 months and the contention, with the same appliance, lasted another 8 months. The result obtained shows first bilateral molar and canine class and excellent intercuspitation, centering the midline and the frenu-

la. After therapy, latero-lateral telerradiography shows a normal cervical lordosis and a correct hyoid position. The resolution of skeletal and dental malocclusion is associated with a recovery of posture, with consequent improvement of the cervical curve, as can be read in the final telerradiography. Once the anterior and molar correction has been obtained, the patient wears appliance only during the night, to stabilize the result obtained and guide the eruption of the permanent dental elements.

**Conclusion:** an early elastodontic orthodontic treatment simplifies the therapy of malocclusions and reduces any relapse, eliminating the need for extractions. Elastodontic therapy was decisive in resolving the skeletal class II disgnathia, as well as the excess overbite and overjet.

## POSTURAL EFFECTS OF ORTHODONTIC AND ELASTODONTIC THERAPY IN COMPARISON

Montenegro V.<sup>1</sup>, Patano A.<sup>1</sup>, Laudadio C.<sup>1</sup>, Malcangi G.<sup>1</sup>, Coloccia G.<sup>1</sup>, Marinelli G.<sup>1</sup>, Limongelli L.<sup>1</sup>, Inchingolo A.D.<sup>1</sup>, D'Oria M.T.<sup>1</sup>, Hazballa D.<sup>1</sup>, Dipalma G.<sup>1</sup>, Inchingolo F.<sup>1</sup>, Di Venere D.<sup>1</sup>, Cardarelli F.<sup>1</sup>, Farronato M.<sup>2</sup>, Tartaglia G.<sup>2</sup>

Complex Operative Unit of Odontostomatology Director: Prof. G. Favia

<sup>1</sup>Specialization School in Orthognatodontics Director Prof. F. Inchingolo, Interdisciplinary Department of Medicine D.I.M. University of Bari Aldo Moro, Bari, Italy

<sup>2</sup>Department of Biomedical, Surgical and Dental Sciences, School of Dentistry, University of Milan, Milan, Italy. UOC Maxillo-Facial Surgery and Dentistry. Fondazione IRCCS Ca' Granda, Ospedale Maggiore Policlinico, Milan, Italy

**Aim:** to compare the position of the cervical vertebrae according to the orthodontic appliance used. Malocclusions are often a causal factor of many osteo-articular pathologies, in fact the masticatory muscles are part of the "postural chain". Skeletal Class II is often associated with advanced posture and hyperlordosis of the cervical spine, while Class III is mainly associated with backward posture. Through a careful analysis of the patient's posture, from a simple clinical examination to radiographs, it is possible to see a correlation between malocclusion and significant postural alterations.

**Methods:** we compared the latero-lateral telerradiographs of 5 patients before and after treatment, with rapid palatal expander, lingual grid, Andresen monobloc and elastodontic appliance.

**Results:** the analysis of the radiographs shows the different position of the cervical vertebrae, depending on the therapy used. The rapid palatal expander makes a significant straightening of the cervical spine. After lingual grid, inversion of the curve is observed. After functional therapy with Andresen monoblock, it is noted compression of the cervical vertebrae. A repositioning of the correct cervical vertebrae curve is achieved after elastodontic functional therapy with AMCOP appliance.

**Conclusion:** elastodontic therapy shows the great postural benefit, following the correct occlusal planes. During skeletal class II treatment, the position of upper cervical spine changes. It can be assumed that a change in cervical posture occurs as a consequence of the correct repositioning of the mandible.

## FUNCTIONAL MANDIBULAR LATERO-DEVIATION TREATED WITH FIXED APPLIANCES: A CASE REPORT

Pilato E., Currò G., Caradonna C., Scardina G.A., Bilello G.

Department of Surgical, Oncological and Oral Sciences, University of Palermo, Palermo, Italy

**Aim:** an 11-year-old male patient presented to our observation with skeletal class I, dental class I to right dental class II to left, functional latero-deviation mandibular and a deep bite. We have evidenced typical signs of mouth breathing such as “Adenoid Facies” and an ogival palate. We suggest a early correction to avoid disorders skeleton. The aim of this work is to show a protocol treatment to correct mandibular latero deviation.

**Methods:** we observed on physical examination bad habits such as onychophagia, lip sucking and mouth breathing as well as left mandibular latero-deviation (3 mm) and dental midline deviation. The maxillary arch showed ogival palate, due to mouth breathing, and deep bite. Articular click was present on auscultation of left TMJ. Teleradiography L-L evaluation revealed skeletal class I, OVJ (4mm) and OVB (5 mm). The OPT showed normal age-related dentition. Rapid maxillary expan-

sion was realized by a rapid expander. The activation protocol provided 1 activation a day only for the first 29 days and the expander must stay in place for about 6 months. This was followed by the application of self-ligating MBT brackets (upper and lower bonding) and the use of intermaxillary class II elastics to improve intercuspitation and dental midline deviation.

**Results:** the treatment with rapid palatal expander has proved to be an effective therapy of latero-deviation mandibular and mouth breathing. The application of self-ligating MBT brackets allowed to complete the treatment in dental class I right and left. Treatment duration is 15 months.

**Conclusion:** the mandibular latero-deviation can be optimally resolved, in a patient with good compliance, by applying a rapid maxillary expander and combining a self-ligating MBT brackets treatment.

## HOW A FUNCTIONAL ORTHODONTIC DEVICE CAN INFLUENCE THE COGNITIVE FUNCTION

Romano A., Jeraci C., Parrinello F., Pachi F.

Department of Orthodontics, Head: Paola Cozza, University of Rome Tor Vergata, Rome, Italy

**Aim:** the aim of this study was to investigate the link between occlusal balance – without which there would be no proper mastication – and fundamental aspects as cognitive function, stress, arousal and concentration.

**Methods:** we used specific tools to observe the electrical activity of the brain in 10 healthy volunteers, with an average of 27.7 years ( $\pm$  SD 2.6). The inclusion criteria were: complete permanent dentition; no previous or in course orthodontic or elastodontic therapy; no temporomandibular joint disorders or degenerative pathologies affecting the nervous system. The *Emotiv Pro+* helmet allowed us to detect electric waves and an appropriate software converted them in numerical data about six different aspects of cognitive performance: stress, engage-

ment, interest, focus, excitement. All the measurements for each participant were executed in three different phases, each lasting 10 minutes: in the first phase the subjects were in a condition of starting occlusion; in the second phase the occlusion was modified using a functional orthodontic device; in the third phase, subjects removed the device. The variations between three phases were evaluated by using *Student's t-test*, and we considered them significant for  $p < 0,05$ .

**Results:** the results underlined an effective variation of conditions such as stress, arousal and concentration between three phases.

**Conclusion:** according to the obtained results, occlusal balance can influence cognitive performance.

## THE PHARYNGEAL AIRWAY SPACE AND THE CRANIOFACIAL MORPHOLOGY: A SYSTEMATIC REVIEW

D'Antiochia S., Galluccio G.

Department of Odontostomatological and Maxillofacial Sciences, Teaching of Orthodontics and Clinical Gnathology; Prof. G. Galluccio, Sapienza University of Rome, Rome, Italy

**Aim:** the pharyngeal airway space is of interest of many studies in the Literature. The majority focuses on the relationship of airway pathologies and the stomatognathic system, such as, e.g., oral breathing and OSAS. On the other hand, the mandibular bone connected with the tongue and the soft palate through muscle insertions, can in turn influence the pharyngeal airway space dimensions. The purpose of our systematic review is to investigate the relationship between the upper airway morphology and the craniofacial morphology, with a particular emphasis on the mandibular position.

**Methods:** PubMed was searched to conduct this systematic review. We included research articles published in the last 14 years and focusing on cephalometric evaluation and three dimensional analysis. We filtered out studies by applying the following inclusion criteria: patient age (growing age, late adolescence and early adulthood); healthy patients (absence of sys-

temic or airway diseases, e.g., OSAS and oral breathing). We excluded those studies covering patients undergone previous orthodontic or surgical treatments.

**Results:** regarding the cephalometric evaluation, the majority of studies clearly observe that a small, retrognathic and in post-rotation mandible is related to reduced values of the smaller portions of the oropharynx. However, a few studies conclude that, due to the too high inter-subject variability of the collected parameters, there is no such a relation.

Concerning the three dimensional analysis, the authors observe a negative correlation between ANB and oropharyngeal volume, and a positive correlation between the minimal cross-section area (identified on the transverse plane) and the OP volume.

**Conclusion:** many of the analysed studies agreed on functional relationship between the craniofacial region and the size of the pharyngeal space.

## FORCES AND MOMENTS GENERATED BY VARIOUS THICKNESSES PETG'S ALIGNERS: A REVIEW

Spolaore E.<sup>1</sup>, Favero R.<sup>1</sup>, Sanguin S.<sup>1</sup>, Volpato A.<sup>1</sup>, Favero L.<sup>2</sup>

<sup>1</sup>Department of Neurosciences, School of Dentistry, University of Padua, Padua, Italy

<sup>2</sup>Professor, Director of Orthodontic Postgraduate, Odontostomatology Institute, University of Padua, Padua, Italy

**Aim:** ideal forces and moments have been historically proposed for efficient and damageless orthodontically tooth movement. In removable clear aligner treatment, those magnitude depends on different variables such as the material of the foil, the extent of the setup increments, the type of movement prescribed and the foil thickness. The aim of this review is to investigate the impact of the latter on constant aforementioned variables.

**Methods:** PubMed databases was searched for articles published up to february 2021 including only in-vitro studies. 7 *in vitro* articles were selected with the following inclusion criteria: petg foils, different foil thicknesses, single tooth movement. PETG foils ranging from 0,3 mm to 1,0 mm in thickness were tested in these studies.

**Results:** all the studies found a direct correlation between the aligner thickness, the stiffness and therefore the exerted forces and moments in all the movements studied except for the movement of intrusion in 1 article. Under common setup increments extent, even the thinner aligner exerted higher magnitudes than those recommended. The 0,625 mm thick foil presented a similar value in stiffness in comparison with the 0,5 and 0,75 foils', making it unnecessary for constant increment in load during treatment.

**Conclusion:** aligner thickness is related to forces and moments magnitude. The values in these studies overcome those recommended but these *in vitro* reproductions doesn't consider the behaviour of the pdl, nor the stress relaxation of the aligners overtime. Therefore the magnitudes to be expected *in vivo* should be lower.

## UNILATERAL CROSSBITE AND NEUROMUSCULAR EVALUATION BEFORE AND AFTER RAPID PALATAL EXPANSION

Vella M., Tripicchio C., Butti A., Porro A.

Department of Biomedical, Surgical and Dental Sciences, IRCCS Ca' Granda Foundation, Ospedale Maggiore Policlinico, University of Milan, Milan, Italy

**Aim:** the aim of the study is to present a neuromuscular evaluation of young patients with unilateral crossbite with electromyography and kinesiography before and after rapid maxillary expansion (RME) and to compare the results.

**Methods:** a Medline database search was performed looking for studies from the past five years. Keywords chosen were “emg” AND “unilateral crossbite”, “crossbite” AND “RME”.

**Results:** in this study 55 young patients (age ranging between 6 to 10 years old) with unilateral crossbite were treated with the Hyrax RME appliance and analysed before expansion (T0), after RME (T1) and six months later (T2). At T0 all patients underwent electromyographic investigations analysing masseter and anterior temporal activity, swallowing and kinesiographic

investigations studying maximum mouth opening, opening and closing speeds, protrusion, laterality, rest position, centric occlusion and freeway space post TENS. At T1, an increase in muscle activity and an improvement in maximum opening were found. Comparing T0, T1 and T2, muscles before RME appeared contracted with altered patterns. Muscle activity after RME during swallowing gradually improves, but there are no statistically significant differences between right and left.

**Conclusion:** maxillary expansion does not directly affect the masticatory muscles but produces changes in muscle tone. Facial musculature is related to the development of malocclusion. The results underline the advantages of crossbite treatment with mandibular shift as soon as possible.

## FUNCTIONAL APPLIANCE ANDREASEN AND NEUROMUSCULAR CHANGES

Vella M., Butti A., Tripicchio C., Porro A.

Department of Biomedical, Surgical and Dental Sciences, IRCCS Ca' Granda Foundation, Ospedale Maggiore Policlinico, University of Milan, Milan, Italy

**Aim:** the aim of the study is to present neuromuscular changes following the use of Andreasen's functional appliance.

**Methods:** a review of the literature was performed using the Medline database searching for “emg and functional appliances” and “emg and andreasen activator”, selecting clinical trials and reviews.

**Results:** several authors have analyzed this topic. The literature shows that the use of EMG in patients treated with activators has led to different results. Scholars affirm that the activator acts following an increase in muscle activity. Others have shown how muscle lengthening explains changes in the EMG parameters and that this change is in proportion to the protrusion and elevation of the bite. Other authors affirm that chang-

es of neuromuscular balance are given by the viscoelasticity of the tissues and therefore the tension of the soft tissues is more relevant than the muscular contraction. Another thesis states that the myotatic reflex is prevalent over the passive tension of soft tissues. The theory of occlusal instability, on the other hand, states that muscle instability is present at the beginning of treatment and then compensatory mechanisms help restore neuromuscular balance. If the treatment is effective, a new neuromuscular balance is reached.

**Conclusion:** the literature proposes several theories, and it is not yet clear which is the exact one. In any case, despite the dysgnathic skeletal situation, the system abandons a state of neuromuscular equilibrium to try to reach a new orthological balance.

## MAXILLARY EXPANSION AND RESPIRATORY FUNCTION

Vella M., Porro A., Tripicchio C., Butti A.

Department of Biomedical, Surgical and Dental Sciences, IRCCS Ca' Granda Foundation, Ospedale Maggiore Policlinico, University of Milan, Milan, Italy

**Aim:** the aim of the study is to present improvements in respiratory function following maxillary expansion.

**Methods:** PubMed search was analyzed. The keywords were "maxillary expansion AND rhinomanometry" of the last 10 years by selecting review, randomized controlled trial and clinical trial.

**Results:** in the studies analyzed there are both results deriving from rapid maxillary expansion (RME) in young patients and surgical expansions (SARPE) or bimaxillary repositionings. Specific skeletal and dental features, such as a reduced transverse palate diameter, can lead to increased upper airway resistance. In studies in which respiratory function is analyzed by rhinomanometry before and after RME in young patients there is a statistically significant improvement in the decrease in air-

way resistance, improving respiratory capacity. Even in adults subjected to surgically assisted rapid palatal expansion (SARPE) or bimaxillary repositioning of bony bases, after active anterior (AAR) and active posterior rhinomanometry (APR) they recorded a statistically significant decrease in resistance of the upper airways. For the AAR, comparing pre-and post-treatment, a difference of 0.19 Pa/s/cm<sup>3</sup> was found. The difference found for APR at a reference pressure of 75 Pa was 0.24 Pa/s/cm<sup>3</sup>, while at 150 Pa it was 0.20 Pa/s/cm<sup>3</sup>.

**Conclusion:** according to the analyzed studies, breathing difficulties due to strong resistance of the upper airways if associated with a reduced transverse diameter of the maxilla, could be resolved by surgical or orthopedic palatal expansion.

## PYCNODYSOSTOSIS AND ORTHODONTIC TREATMENT

Vella M., Tripicchio C., Butti A., Porro A.

Department of Biomedical, Surgical and Dental Sciences, IRCCS Ca' Granda Foundation, Ospedale Maggiore Policlinico, University of Milan, Milan, Italy

**Aim:** the aim of the study is to present the pycnodysostosis and the orthodontic implications that can often be found in patients suffering from this rare genetic pathology.

**Methods:** clinical studies present in the literature were analyzed by consulting PubMed. The keywords used were "pycnodysostosis and orthodontic".

**Results:** approximately 200 patients with pycnodysostosis have been reported in literature. It is characterized by short stature, increased bone density (osteosclerosis), craniosynostosis and cleft palate. There is a predisposition for fractures, OSAS and oral breathing can be found. From a dental point of view, there is a predisposition to caries and periodontal disease, agenesis, hypodontia, eruption delays and malocclu-

sions (III molar and canine class, bilateral crossbite). The dysgnathic condition can also be found in the cephalometric analysis. Often maxillary retrognathia with skeletal class III or maxillary biretrusion (skeletal class I), transverse hypoplasia of the maxilla, hyperdivergent vertical growth with open goniac angle can be found. The extraction of deciduous teeth to resolve crowding must be taken into consideration by performing the surgery in an atraumatic and non-sequential way to avoid fractures and bone necrosis for osteosclerosis. Dental alignment is complicated. Orthognathic surgery can only be approached in cases of low risk.

**Conclusion:** these patients should receive special dental care and undergo follow-up to monitor craniofacial development.

## PATIENTS WITH JUVENILE IDIOPATHIC ARTHRITIS ELECTROMYOGRAPHIC RESPONSE IN RPE THERAPY

Zerva A., Cressoni P., Lombroni L.G., Colangelo B., Tigani C., Parisi F.M.R.

Specialization School of Orthodontics - Ca' Granda Foundation IRCCS - Ospedale Maggiore Policlinico, U.O.C. Maxillofacial Surgery and Odontostomatology, University of Milan, Milan, Italy

**Aim:** in the Orthodontic Department of the dental clinic of the Polyclinic of Milan, electromyography is used to demonstrate whether we have changes in the neuromuscular area in patients with transverse deficit in the upper arch treated with Rapid Palate Expander (REP). The aim of this work is to highlight the alterations of the neuromuscular system and myofunctional balance.

**Methods:** this study was conducted on a group of 5 patients (5 females) diagnosed with JIA. The subjects were evaluated by electromyographic examinations using EASY-MYO® with pre-established protocols in order to make the examinations repeatable and the same both among the various patients and among the various records of the same patient.

The electromyographic evaluation was carried out by standardized electromyography and by analysis with DAQ software. The recordings were performed by placing the patient in a seated position, using disposable bipolar electrodes pregeled in Ag/AgCl.

The test included one measurement in maximum clench and two in occlusion on cotton rolls to determine the Percentage Overlapping Coefficient (POC). The POC obtained allowed the evaluation of joint symmetry during muscle activation. In

addition, the two measurements allowed to calculate other indices, such as: the asymmetry index, the activation index, the torsion index and the impact index.

**Results:** at the end of the therapy with the device we obtain with respect to T0 the variations of the various indices:

- POC: an improvement in the asymmetry in the TA muscle pair, an asymmetry in the MM muscle pair, a slight improvement in the asymmetry in the MM and TA muscle pairs;
- asymmetry: a slight asymmetry towards the right, 40% of patients have the asymmetry index with normal values;
- activation: correct distribution of the front and rear contact points. 60% of patients have normal values;
- torc: we maintain a balance between muscle pairs, keeping relationships similar to T0. 20% of patients have normal values;
- impact: we get balanced muscle work with respect to T0.

**Conclusion:** electromyographic monitoring of the orthodontic case, can therefore be considered among the examinations useful to the dentist to investigate how, therapies such as rapid expansion of the palatal, can affect the neuromuscular level, valuating muscle balance. Comparing healthy patients (subjected to the same tests) with those with JIA, we found a greater improvement in those with JIA.

## HEALTHY PATIENTS ELECTROMYOGRAPHIC RESPONSE AFTER RAPID PALATAL EXPANSION THERAPY

Zerva A., Parisi F.M.R., Colangelo B., Cressoni P., Lombroni L.G., Tigani C.

Specialization School of Orthodontics - Cà Granda Foundation IRCCS - Ospedale Maggiore Policlinico, U.O.C. Maxillofacial Surgery and Odontostomatology, University of Milan, Milan, Italy

**Aim:** in the Orthodontic Department of the dental clinic of the Polyclinic of Milan, electromyography is used to demonstrate whether we have changes in the neuromuscular area in patients with transverse deficit in the upper arch treated with Rapid Palate Expander (REP).

The aim of this work is to highlight the alterations of the neuromuscular system and myofunctional balance.

**Methods:** this study was conducted on a group of 16 healthy patients (8 females, 8 males).

The subjects were evaluated by electromyographic examinations using EASYMYO® with pre-established protocols in order to make the examinations repeatable and the same both among the various patients and among the various records of the same patient.

The electromyographic evaluation was carried out by standardized electromyography and by analysis with DAQ software. The recordings were performed by placing the patient in a seated position, using disposable bipolar electrodes pregeled in Ag/AgCl.

The test included one measurement in maximum clench and two in occlusion on cotton rolls to determine the Percentage Overlapping Coefficient (POC). The POC obtained allowed the evaluation of joint symmetry during muscle activation. In addition, the two measurements allowed to calculate other indices, such as: the asymmetry index, the activation index, the torsion index and the impact index.

**Results:** at the end of the therapy with the device we obtain with respect to T0 (at the beginning of the therapy) the variations of the various indices:

- POC: an average improvement and a slight asymmetry in the TA muscle couple, a slight asymmetry in the MM muscle couple, a slight asymmetry in the muscle couples;
- asymmetry: we maintain a symmetry between right and left hemi arch, 100% of patients have normal values;

- activation: correct distribution of the front and rear contact points. 50% of patients have normal values;
- torc: we maintain a balance between muscle pairs, keeping the ratios similar to T0. 83.33% of patients have normal values;
- impact: we get balanced muscle work with respect to T0.

**Conclusion:** electromyographic monitoring of the orthodontic case, can therefore be considered among the examinations useful to the dentist to investigate how, therapies such as rapid expansion of the palatal, can affect the neuromuscular level, valuating muscle balance.

Comparing healthy patients (subjected to the same tests) with those with JIA, we found a greater improvement in those with JIA.

## ORTHODONTIC TREATMENT OF OBSTRUCTIVE SLEEP APNEA SYNDROME

Bica E., Parisi F., Nucci F., Nardi N., Maspero C., Spadari F., Gianni A.B.

Department of Dentistry, IRCCS Ca' Granda Maggiore Policlinico Hospital, Milan, Italy; University of Milan, Milan, Italy

**Aim:** obstructive Sleep Apnea Syndrome is a respiratory sleep disorder that may occur in both adult and pediatric age, characterized by repeated episodes of complete or partial, hypoapnea, upper airway obstruction with signs and symptoms that can determine the onset of important systemic dysfunctions that cause a reduction of the quality of life.

**Methods:** two documented clinical cases, show how whether in adulthood or pediatric age, the dentist has the ability to intervene in a therapeutic way on mild and moderate OSAS with MAD (mandibular advancement device) SILENSOR and RME respectively. These devices have the goal to maintain the upper airway patency during sleep through protrusion and advanced positioning of the jaw in the case of SILENSOR and with the transverse maxillary expansion by opening the mid - palatal suture in the case of the RPE.

**Results:** documented case reports demonstrate a reduction in the number of sleep apneas in post-orthodontic polysomnography. The pediatric patient treated with RME presents the complete cessation of apneas. The adult patient treated with SILENSOR showed an improvement in respiratory performance. SILENSOR MAD was modified in order to obtain gradually increasing mandibular advancements, after checking the efficacy adapt it to the patient's therapeutic needs and obtain the optimal reduction/disappearance of the apneas.

**Conclusion:** the orthodontist plays an important role in the diagnostic and therapeutic because they have the ability to intercept early signs and symptoms of OSAS thanks to a careful clinical and instrumental examination, polysomnography, at the same time, especially for mild and moderate cases, can evaluate if the patient has the indications for treatment with specific oral devices.

## ORTHODONTIC MANAGEMENT IN A SPECIAL PATIENT WITH RETT SYNDROME: A CASE REPORT

Bilello G., Fazio M., Amato E., Crivello L., Caradonna C., Currò G.

Department of Surgical, Oncological and Oral Sciences, University of Palermo, Palermo, Italy

**Aim:** the "special patient" in dentistry requires different operating professional, times and ways of intervention from those used in daily professional practice. The aim of this work is to describe the orthodontic management of a patient affected by

Rett syndrome, the second most common cause of mental retardation in females after Down syndrome. It is a severe neurodevelopmental disease caused by mutations in the X-linked gene encoding for the methyl-CpG-binding protein MeCP2.

**Methods:** the patient came to our attention at the age of 9 years and 2 months. The diagnosis, obtained through radiographic and clinical examination, was: dental and skeletal class II malocclusion (ANB > 5°, overjet = 6,5 mm), presence of lip competence, oral breathing, diurnal bruxism, followed by stereotyped tongue movements. We focused on early clinical diagnosis to highlight and limit craniofacial alterations and improve the functional aspect according to a therapeutic scheme which, through muscle rehabilitation and patient compliance, allows to achieve appreciable orthodontic results.

A 3-step procedure was adopted called R. I. O. (Rehabilitation, Hygiene and Orthodontics). 1) Rehabilitation through proprioceptive physiotherapy of the tongue, swallowing and masticatory functions.

2) Hygiene also associating a correct and healthy diet. 3) Application of removable devices, to correct malocclusion and reduce signs of bruxism.

**Results:** with R.I.O. it was possible to draw the attention of the patient who collaborated without fear, using the orthodontic device. The 2-year follow-up showed an improvement in overjet (< 5mm), tongue position and respiratory function. Oral cavity clinical situation improved associating hygiene and a healthy diet.

**Conclusion:** in this syndrome early identification and timely intervention can prevent greater disability and help both the patient and his family. An integrated multidisciplinary approach inclusive of symptomatic, supportive medical management, therapy and supportive services is needed.

## ORTHOSURGICAL TREATMENT OF A SEVERE CLASS III MALOCCLUSION IN ADULT PATIENT: A CASE REPORT

Bogni V., Bazzini E., Fornaciari P., Anti M., Caneva M., Micelli N.

Department of Biomedical, Surgical and Dental Sciences, University of Milan, Milan, Italy

**Aim:** to show the multidisciplinary management of a class III malocclusion with severe maxillary hypoplasia, in a 21 year old man with upper second premolars agenesis, skeletal and molar class III malocclusion, severe maxillary retrusion, -6° ANB angle, Wits index of -13 mm and an overjet of 0 mm.

**Methods:** the orthodontic treatment started removing dental compensation due to skeletal discrepancy. Extractions of mandibular second premolars were performed due to the severe lack of space in the mandibular arch and two orthodontic miniscrews were placed as an anchorage to mesialize lower first molars; to speed up the movement, alveolar corticotomies were performed. The pre-surgical orthodontic treatment with multibracket fixed appliance lasted 18 months, then the patient underwent maxillary

surgical advancement. Two months later, post-surgical refinement was performed. The post-orthodontic retention was ensured by a lower fixed retainer and an upper Essix retainer.

**Results:** following the multidisciplinary treatment, the cephalometric analysis results were: improvement of ANB angle (-1,4°), Wits index (-8 mm) and overjet (2mm). A good occlusal stability and a good aesthetic result were obtained.

**Conclusion:** correct diagnosis and treatment planning as well as appropriate execution of the treatment plan are determinant factors for success and long-term stability. According to the literature, combined ortho-surgical treatment is the gold standard treatment to solve severe skeletal class III malocclusion in adult patients.

## SURGERY FIRST APPROACH OF A CLASS III MALOCCLUSION IN ADULT PATIENTS: A CASE REPORT

Bogni V., Bazzini E., Fornaciari P., Anti M., Caneva M., Preatoni M.

Department of Biomedical, Surgical and Dental Sciences, University of Milan, Milan, Italy

**Aim:** the aim of this report is to show the effectiveness of a “surgery first” approach to treat a severe skeletal class III malocclusion in a 21-year-old male patient with maxillary hypoplasia, severe proinclination of the upper incisors, skeletal and molar class III malocclusion (ANB=-9° and Wits index=-14 mm) and an overjet of 0 mm.

**Methods:** according to the literature, the patient was a good candidate for surgery first approach. Immediately before orthognathic surgery, .022 MBT brackets were bonded and passive 019” x .025” NiTi arch-wires (heated up) were inserted; then the patient underwent bimaxillary orthognathic surgery with “surgery first” approach and chin surgery. Four months after surgery, an orthodontic treat-

ment of 12 months with multibracket fixed appliance was performed. The postorthodontic retention was ensured by an upper removable retainer and a lower fixed retainer from 3.3 to 4.3.

**Results:** a significant improvement of the original malocclusion was achieved (ANB =  $-5^\circ$ , Witts index = -5 mm, OJ = 2mm). A good occlusal stability and a good aesthetic result were also obtained. The patient was very satisfied with the

treatment because he saw a major improvement in the profile right from the start of the treatment.

**Conclusion:** according to international literature, surgery first approach offers several advantages when applicable: the profile shows an immediate improvement, the patient offers better compliance and the overall treatment time is reduced compared with traditional surgical-orthodontic treatment.

## MAXILLARY ARCH EXPANSION WITH THE INVISALIGN SYSTEM

Cantiero V., Provaroni R., Brunelli V.

Department of Orthodontics, Head: Prof.ssa Paola Cozza, University of Rome Tor Vergata, Rome, Italy

**Aim:** to investigate the predictability and the efficiency of Invisalign system, during maxillary expansion.

**Methods:** eighteen adult patients, with a mean age of 34.9 years (SD 9.8 years), have been included in the study group according to the following criteria: european ancestry, permanent dentition (with second molars fully erupted), mild or moderate crowding, posterior transverse interarch discrepancy  $\geq 3$  mm, good tooth anatomy (with sufficient clinical crowns), good compliance; where the average treatment duration was 95 weeks. Pre and post treatment digital models (.stl files) were obtained from each patient of this study. Digital models from Clincheck were also achieved from Align Technology to evaluate the planning accuracy. Linear values of arch width were measured. Paired t-test (with a level of significance set at 5%) was applied to measure and compare data. The ICC test was employed to establish the reliability of the measures.

**Results:** statistically significant differences between pre and post treatment measures ( $P < .001$ ) for all linear values, except for the second molars, were detected. The greatest increase was observed at the level of inter-premolars width, with an average of 3.8 mm of expansion. It was found not statistically significant differences between Clincheck prediction and post-treatment measurements, except for the inter-canines width ( $P < .05$ ) and for gingival margins of the first molars ( $P < .01$ ).

**Conclusion:** Invisalign system could realize an efficient dentoalveolar expansion with an overall high accuracy compared with the expected outcomes. The different amount of expansion achieved between the anterior, lateral and posterior teeth leads to a development of the maxillary arch from a V-shape to a more parabolic form.

## ORTHO-PERIO APPROACH IN A PERIODONTALLY COMPROMISED ADULT PATIENT: A CASE REPORT

Chiarello G., Maina G., Arrigo M., Parrini S., Deregibus A., Castrolorio T.

Department of Surgical Sciences, School of Specialization in Orthodontics, Dental School, University of Turin, Turin, Italy

**Aim:** the aim of this report is to present a clinical case of a 50-year-old male patient, referred to the department of Orthodontics at the University of Torino Dental School, suffering from generalized chronic severe periodontitis and treated with orthodontic treatment combined with periodontal etiological therapy and continuous periodontal follow-up.

**Methods:** PubMed, Cochrane library, Scopus, Google Scholar were searched from 2000 to 2021 to identify guidelines for the orthodontic treatment of periodontally compromised patients. The patient was referred to the Dental School with unsatisfactory periodontal status, presence of drifting in frontal teeth and bone loss in different areas. The treatment was carried out with periodontal etiological therapy combined with clear aligners

treatment and mild forces were applied for gradual levelling of the teeth, with constant control of the periodontal status. At least, an implant-prosthetic rehabilitation was performed.

**Results:** after 24 months of treatment with aligners, the patient showed optimal orthodontic and periodontal results. Bone resorption was stabilized, vertical bone defect was improved and incisor flaring was reduced.

**Conclusion:** orthodontic procedures in periodontally compromised patients require extensive periodontal care to maintain the periodontium in a healthy condition during and after treatment. Orthodontic treatment should be gradual, with mild forces and performed under strict plaque control measures. In those cases a multidisciplinary approach it's crucial in order to obtain satisfactory outcomes.

## NEW FUNCTIONAL ELASTODONTIC AMCOP THERAPY

Coloccia G.<sup>1</sup>, Patano A.<sup>1</sup>, Laudadio C.<sup>1</sup>, Malcangi G.<sup>1</sup>, Marinelli G.<sup>1</sup>, Limongelli L.<sup>1</sup>, Inchingolo A.D.<sup>1</sup>, Montenegro V.<sup>1</sup>, D'Oria M.T.<sup>1</sup>, Laforgia A.<sup>1</sup>, Dipalma G.<sup>1</sup>, Inchingolo F.<sup>1</sup>, Di Venere D.<sup>1</sup>, Cardarelli F.<sup>1</sup>, Farronato M.<sup>2</sup>, Tartaglia G.<sup>2</sup>

Complex Operative Unit of Odontostomatology Director: Prof. G. Favia

<sup>1</sup>Specialization School in Orthognatodontics Director Prof. F. Inchingolo, Interdisciplinary Department of Medicine D.I.M. University of Bari Aldo Moro, Bari, Italy

<sup>2</sup>Department of Biomedical, Surgical and Dental Sciences, School of Dentistry, University of Milan. UOC Maxillo-Facial Surgery and Dentistry. Fondazione IRCCS Ca Granda, Ospedale Maggiore Policlinico, Milan, Italy

**Aim:** the aim of this work is to introduce elastodontic AMCOP therapy. The AMCOP elastodontic therapy is an orthodontic mobile therapy that takes inspiration from Soulet and Besombes appliances of about 1950, and it is directed not only to the teeth, but also to all functions that are involved in craniofacial growth and are connected with development of occlusion (swallowing, breathing, chewing) and cranio-mandibular posture. The orthodontist prescribes to the patient to wear an AMCOP appliance chosen between different sizes and shape. These appliances are made of 51-60 shore thermoplastic and thermoactivable material that has a high elastic consistency that is better accepted by the patients. The common characteristics of these appliances is the presence of a buccal shield, a tongue shield, and a smooth bite plane that involves all teeth. These appliances are not individualized and do not need den-

tal impression but are made of different shapes and sizes to fit for almost all patients.

**Materials and Results:** in this work is described the classification of AMCOP appliances and the differences between them. For every appliance is discussed the clinical meaning of different shape and of different distribution of bite plane thickness. It is also described a clinical case that shows the correction of anterior and posterior crossbite with AMCOP therapy at early age.

**Conclusion:** elastodontic therapy results strengthen the importance of early orthodontic treatment to help the patient to have better oral function and better occlusion as soon as possible. It is necessary to improve scientific knowledge about elastodontic therapy to better understand short and long term effects of these appliances and their influence about the improvement of oral functions, that are the basis of orthodontic stability

## EFFECTIVENESS OF SKELETAL EXPANSION THROUGH CONE BEAM TOMOGRAPHY: A SYSTEMATIC REVIEW

Coloccia G.<sup>1</sup>, Patano A.<sup>1</sup>, Laudadio C.<sup>1</sup>, Malcangi G.<sup>1</sup>, Marinelli G.<sup>1</sup>, Limongelli L.<sup>1</sup>, Inchingolo A.D.<sup>1</sup>, Montenegro V.<sup>1</sup>, D'Oria M.T.<sup>1</sup>, Hazballa D.<sup>1</sup>, Inchingolo A.M.<sup>1</sup>, Dipalma G.<sup>1</sup>, Inchingolo F.<sup>1</sup>, Di Venere D.<sup>1</sup>, Cardarelli F.<sup>1</sup>, Farronato M.<sup>2</sup>, Tartaglia G.<sup>2</sup>

Complex Operative Unit of Odontostomatology Director: Prof. G. Favia

<sup>1</sup>Specialization School in Orthognatodontics Director Prof. F. Inchingolo, Interdisciplinary Department of Medicine D.I.M. University of Bari "Aldo Moro", Bari, Italy

<sup>2</sup>Department of Biomedical, Surgical and Dental Sciences, School of Dentistry, University of Milan. UOC Maxillo-Facial Surgery and Dentistry. Fondazione IRCCS Ca Granda, Ospedale Maggiore Policlinico, Milan, Italy

**Aim:** the palatal expansion is a common orthodontic technique able to increase the transverse changes for subjects with constricted maxillary arches. The aim of the present investigation was to evaluate through a systematic review the dental and bone effects of tooth-borne, hybrid and bone-borne palatal expanders approaches with cone beam tomography findings.

**Methods:** the database search was conducted PubMed (Medline) to perform the screening and the eligibility of the clinical papers. Inclusion criteria included observational and RCT studies investigating with CBCT the effects of different palatal expanders.

**Results:** the database search included a total of 284 results, while 271 articles were excluded. A total of 14 articles were included for the qualitative assessment. It was extracted data about the amount of bone and dental expansion at upper first molars level, age of patients, type of expander, activation protocol, observation period.

**Conclusion:** there is not sufficient data about the effectiveness of skeletal expansion with different appliances or different protocols, but every study reported that the skeletal expansion was a useful approach to increase the transverse changes for subjects with constricted maxillary arches. Expansion in adult or late adolescent patients has reported less stability of skeletal expansion also in bone-borne expansions.

## SINERGY OF ALIGNERS AND CARRIERE MOTION IN ADULT II CLASS MALOCCLUSION: A CASE REPORT

Coloccia G.<sup>1</sup>, Patano A.<sup>1</sup>, Laudadio C.<sup>1</sup>, Malcangi G.<sup>1</sup>, Marinelli G.<sup>1</sup>, Limongelli L.<sup>1</sup>, Inchingolo A.D.<sup>1</sup>, Montenegro V.<sup>1</sup>, D'Oria M.T.<sup>1</sup>, Laforgia A.<sup>1</sup>, Dipalma G.<sup>1</sup>, Inchingolo F.<sup>1</sup>, Di Venere D.<sup>1</sup>, Cardarelli F.<sup>1</sup>, Farronato M.<sup>2</sup>, Tartaglia G.<sup>2</sup>

Complex Operative Unit of Odontostomatology Director: Prof. G. Favia

<sup>1</sup>Specialization School in Orthognatodontics Director Prof. F. Inchingolo, Interdisciplinary Department of Medicine D.I.M. University of Bari Aldo Moro, Bari, Italy

<sup>2</sup>Department of Biomedical, Surgical and Dental Sciences, School of Dentistry, University of Milan. UOC Maxillo-Facial Surgery and Dentistry. Fondazione IRCCS Ca Granda, Ospedale Maggiore Policlinico, Milan, Italy

**Aim:** this work wants to describe the clinical case of a 30 years old female patient with class II / II division malocclusion with deep bite, crowding of upper arch, upper molar rotation, anterior spaces and deep Spee curve, treated with Carriere motion and orthodontic aligners.

**Methods:** carriere motion was applied to upper canines and molars, while aligner therapy started with esthetic start on upper frontal teeth and on the lower arch. The patient was instructed to wear full time elastics dimension 3/16 8 Oz from lower six to carriere motion canine hooks. Inferior aligners had precision cut for elastics. Inferior therapy of inferior arch had the objective to correct deep Spee curve, closure of spaces and increase of overjet to better correct the II class malocclusion with class II elastics.

After 6 months the upper molars were derotated and the canines were in class I, with diastemas between canines and upper lateral incisors. The Carriere motion was removed and it

were taken new impressions to start a new phase of treatment with just aligners to expand and derotate upper posterior teeth, close the spaces, give better palatal root torque of upper incisors and canines and give better occlusion to the patient. The case ended within 18 months of active therapy. It was necessary at the end of treatment to add composite distal to 22 to correct Bolton discrepancy. The bite jump from II class to I class was possible because the mandible had a better repositioning due to the molar distorotation, upper arch expansion and initial increase of overjet.

**Conclusion:** carriere motion and aligners are a good way to treat II class malocclusion because aligners better control the proclination of teeth with class II elastics during distorotation and distalization of posterior teeth with carriere motion. In this case report is shown the usefulness of esthetic start of upper incisors during carriere motion therapy.

## ORTHODONTIC EXTRUSION TO REHABILITATE SEVERELY DAMAGED TEETH: A CASE REPORT

Cordaro M., Galeano P., Alessandri-Bonetti A., Gallenzi P.

A. Gemelli Foundation, IRCCS - Catholic University of Sacred Heart, Orthodontics Residency Program: Director Prof M. Cordaro, Rome, Italy

**Aim:** orthodontic extrusion can be used to move coronally a severely damaged tooth in order to make it restorable. Purpose of this work is to describe step by step a simple method to perform it.

**Methods:** a 25 y.o. female patient presented with a fracture of tooth 2.4 extending up to the coronal third of the root. Orthodontic extrusion was performed using standard MBT brackets (0.022"x0.025") that were bonded on the buccal surface of the tooth to be extruded and on the adjacent elements (teeth 2.3, 2.5, 2.6). A 0.016" Ni-Ti arch and a 0.016"x 0.022" NiTi arch were used in succession for 3 weeks each to obtain the amount of extrusion desired (4 mm). During this period, supracrestal circumferential fiberotomy (CSF) was performed using a scalpel blade every 10 days to avoid coronal gingival mi-

gration. A 0.019"x0.025" stainless steel arch was maintained for 8 weeks to stabilize the result. At the end of this period, when it was possible to place the rubber dam, the tooth was reconstructed using composite and then covered with a fixed prosthetic restoration.

**Results:** the desired amount of extrusion was obtained in 6 weeks of extrusion and 8 weeks of retention. Despite CSF was performed, a significant gingival coronal migration was observed which required corrective periodontal surgery at the end of the treatment.

**Conclusion:** orthodontic extrusion is a predictable technique to restore severely compromised teeth. However, corrective periodontal surgery is often required to correct the excessive soft tissue migration associated with this technique.

## ORTHODONTIC EXTRUSION VS SURGICAL EXTRUSION TO REHABILITATE SEVERELY DAMAGED TEETH

Cordaro M., Grande N.M., Alessandri-Bonetti A., Torsello F., Gallenzi P.

A. Gemelli Foundation, IRCCS - Catholic University of Sacred Heart, Orthodontics Residency Program: Director Prof M. Cordaro, Rome, Italy

**Aim:** to analyze pros and cons of both techniques when they are used to coronally relocate damaged teeth in order to improve its restorability and provide space for biological width.

**Methods:** in order to compare advantages, disadvantages, time of therapy required, contraindications and complications for both orthodontic extrusion and surgical extrusion, a narrative literature review was performed using PubMed database. The keywords used were “orthodontic extrusion”, “forced orthodontic extrusion” and “surgical extrusion”. Original articles and systematic reviews describing one or both techniques were selected.

**Results:** two systematic reviews about surgical extrusion were selected. Two articles exposing the guidelines on the clinical practice of orthodontic extrusion and its effects on periodontal tissue were selected, due to the lack of systematic reviews regarding this topic.

**Conclusion:** both techniques present several advantages and some disadvantages. Since it is not possible to determine which technique is superior, the therapeutic choice has to be made taking into account the specific clinical case and patient's choice.

## MORPHOMETRIC COVARIATION ANALYSIS IN CLASS III MALOCCLUSION GROWING SUBJECTS

De Razza F.C., Paoloni V., Lugli L.

Department of Orthodontics, Head: Prof.ssa P. Cozza, University of Rome Tor Vergata, Rome, Italy

**Aim:** to study the covariation between palatal and craniofacial skeletal morphology in Class III growing patients through geometric morphometric analysis (GMM).

**Methods:** 54 Class III subjects (24F,30M;  $7.6 \pm 0.8$ yy) were enrolled following these inclusion criteria: European ancestry, Class III skeletal and dental relationship, early mixed dentition, prepubertal skeletal maturation, familiarity for Class III malocclusion, no pseudo Class III malocclusion. For each patient upper digital cast and cephalogram were collected before treatment. Landmarks and semilandmarks were digitized (239 on casts; 121 on lateral radiographs) and GMM was used. Procrustes analysis and principal component analysis (PCA) were applied to show the principal components of palatal and cran-

iofacial skeletal shape variation. Two-block partial least squares analysis (PLS) was used to assess pattern of covariation between palatal and craniofacial morphology.

**Results:** regarding palatal shape variation, PC with largest variance (PC1) described morphological changes in the three space dimensions, while, concerning the craniofacial complex components, PC1 revealed morphological differences along the vertical plane. A significant covariation was found between palatal and craniofacial shape. PLS1 accounted for more than 61,7% of the whole covariation, correlating the craniofacial divergence to palatal height and width.

**Conclusion:** in Class III subjects increments of angle divergence are related to a narrow and high palate.

## PERIODONTAL HEALTH AND ORTHODONTICS: WHICH SYNERGIES AND WHICH RISKS?

Di Benedetto L.

**Aim:** we present some orthodontic cases with different periodontal issue that need different diagnostic and treatment approach.

**Methods:** Case 1 conflict mandibular canine/ lower incisor: adequate treatment with correct management of roots movements and without gingival recession.

Case 2 conflict mandibular canine/ lower incisor: inadequate treatment with gingival recession.

Case 3 inferior incisal retraction resolved with adequate orthodontics for restoring roots malposition and periodontal tissue.

Case 4 lower incisal retraction worsened by the forced alignment of the arches.

**Results:** one of the problems that the orthodontist often must face during diagnosis or orthodontic treatment it's the gingival recession especially in the lower incised region. This problem leads to the exposure of root with evident aesthetic damage, dental hypersensitivity and increased risk of caries. The fact that alignment treatments can worsen the situation makes the

argument noteworthy also for the increasing medical-legal responsibilities to manage and prevent. A review of 2014 concluded that in the current state there isn't significant evidence for no type of therapy. It's clear that the argument is complex and not standardizable. We have chosen to present some cases to demonstrate how orthodontic treatment performed with awareness and competence can improve recessions, the other way around, when orthodontic therapy aren't concerned with a correct diagnosis can be responsible for biological damage.

**Conclusion:** the complexity of the ortho-paro topic makes impossible and dangerous to standardize orthodontic treatment. Medicine is evolving towards individualization of therapies, "precision medicine", with studied therapies for the individual patient.

Collaboration between orthodontist and parodontist are fundamental for a correct diagnosis and the monitoring of orthodontic treatment.

## MODIFIED ORTHODONTIC BONE STRETCHING FOR ANKYLOSED TOOTH REPOSITIONING: A CASE REPORT

Dissegna M., Stacchi C., Barlone L., Rapani A., Berton F., Contardo L., Di Lenarda R.

Department of Medical, Surgical and Health Sciences, University of Trieste, Trieste, Italy

**Aim:** different approaches were proposed in the literature for the treatment of malpositioned ankylosed teeth. The present case report describes a modification of Orthodontic Bone Stretching Technique (OBS) for the repositioning of ankylosed teeth, consisting of dentoalveolar segmental osteotomies performed with piezoelectric instruments followed by orthodontic and orthopedic traction.

**Methods:** a 22-year-old female in good general health was referred by her orthodontist due to an infraoccluded and ankylosed maxillary upper left canine.

Attempts of conventional and corticotomy-assisted orthodontic alignment of the tooth were previously performed with no success. After elevating full-thickness flap, three osteotomies were performed by using piezoelectric inserts (Piezotome Cube, Acteon, Merignac, France). Mesial and distal cuts were

full-thickness osteotomies, parallel to the long axis of the tooth, through the buccal and palatal cortical plates. The apical osseous incision was a horizontal corticotomy, involving only the buccal plate, and connecting the vertical osteotomies two millimeters over the apex of the tooth. Heavy orthodontic forces were immediately applied by using both dental and skeletal anchorage.

**Results:** the initial movement of the dentoalveolar segment was observed three weeks after surgery and case finishing has been completed in two months. At a one-year follow-up, the repositioned canine showed good periodontal conditions, no discoloration and positive pulp response to the electric test.

**Conclusion:** modified OBS technique was effective in repositioning an infraoccluded and ankylosed maxillary canine, providing satisfactory function and esthetics with short treatment time.

## MESIODISTAL ANGULATION AND BUCCOLINGUAL INCLINATION OF PREMOLARS EVALUATED ON 2D AND 3D

Fontana M.<sup>1</sup>, Fastuca R.<sup>1</sup>, Zecca P.A.<sup>1</sup>, Nucera R.<sup>2</sup>, Militi A.<sup>2</sup>, Lo Giudice A.<sup>3</sup>, Portelli M.<sup>2</sup>, Caprioglio A.<sup>4</sup>

<sup>1</sup>Department of Medicine and Surgery, University of Insubria, Como-Varese, Italy

<sup>2</sup>Department of Biomedical Sciences, Dentistry and Morphological and Functional Imaging, University of Messina, Messina, Italy

<sup>3</sup>Department of Medical-Surgical Specialties-Section of Orthodontics, School of Dentistry, University of Catania, Policlinico Universitario V. Emanuele, Catania, Italy

<sup>4</sup>Department of Biomedical, Surgical and Dental Science, University of Milan, Milan, Italy

**Aim:** panoramic radiography creates distortion in teeth position and inclination especially in lateral areas of the arches due to acquisition and curved shape of dental arch. This study aimed to evaluate panoramic distortion compared to cone beam computed tomography.

**Methods:** mesiodistal angulations were measured on panoramic radiography. Mesiodistal angulations and buccolingual inclinations of the teeth were determined on cone beam computed tomography scans. The previous measurements were then compared through Pearson correlation coefficient.

**Results:** the results showed higher correlation between mesiodistal 2D angulation and buccolingual 3D inclination especially for first premolars, rather than between mesiodistal angulations measured in 2D and 3D.

**Conclusion:** especially for the lateral areas of the dental arches root mesiodistal angulation measured on panoramic radiography is not reliable, in fact it is greatly influenced by bucco-lingual inclination. Therefore, clinical evaluation is highly recommended with panoramic radiography to provide correct diagnosis and the most satisfactory results.

## ORTHODONTIC EXTRUSION AND TEMPORARY PROSTHETIC REHABILITATION OF ELEMENT 2.1 AFTER TRAUMA

Fornarelli G., Trebbi G., Mbanefo S., Bagatta S., Munari A., Varacca A., Salerno C., Bazzini E.

Department of Orthodontics, ASST Santi Paolo e Carlo, University of Milan, Milan, Italy

**Aim:** the goal of this treatment was to restore aesthetics and, most of all, to maintain the height and thickness of the alveolar bone of 2.1 after a severe (double) dental trauma.

**Methods:** a 14 year old patient came to the Orthodontics Department (San Paolo Hospital, Milan) after a dento-facial trauma. 2.1 (8 years before this tooth underwent another trauma and it had been repositioned, splinted and endodontically treated) showed root fracture because of root external resorption (coronal third). The tooth underwent surgical exposure of the fracture margin and the placing of an endocanal pin to allow its extrusion. The natural crown of 2.1 was later removed because it was unstable and the pin was exposed. Brackets from tooth 14 to 24 were bonded and a temporary crown was fixed to the orthodontic arch to replace

the missing incisor; then the traction of the root began through a NiTi closed coil spring. As the extrusion proceeded, the temporary crown was gradually reduced. At the end of the treatment, another pin was placed inside the root and the definitive prosthetic rehabilitation has been completed.

**Results:** at the end of orthodontic and prosthetic treatments, 2.1's root was preserved so that the alveolar bone can keep on growing and the patient was satisfied with the aesthetic and functional result.

**Conclusion:** a growing patients orthodontic extrusion associated with prosthetic rehabilitation of an injured tooth can preserve the alveolar bone development until the correct timing to perform implant-prosthetic rehabilitation.

## ALT RAMEC PROTOCOL IN A PATIENT WITH UNILATERAL CLEFT LIP AND PALATE: 8 YEARS FOLLOW UP

Fornarelli G., Bagatta S., Micelli N., Preatoni S.M., Madeo E., Bazzini E.

Department of Orthodontics, ASST Santi Paolo e Carlo, University of Milan, Milan, Italy

**Aim:** the aim of this study is to verify the efficacy of the Alt-Ramec protocol in a patient with skeletal class III and unilateral right cleft lip and palate.

**Methods:** orthodontic/orthopedic treatment began with the Alt-Ramec protocol: there was an initial phase with a double hinged palatal expander; the activations (1mm per day) were performed for 9 weeks alternating one in expansion and the following in constriction, followed by 9 months treatment with facemask to gain maxillary advancement. The treatment continued with the extraction of elements 12-24-34-44 and upper and lower traditional orthodontic therapy. The therapy ended with orthodontic retainers and the extraction of 38 and 48.

**Results:** after 8 years from the end of orthodontic therapy, the patient shows molar and canine I class, has normal overjet and overbite and is satisfied with the aesthetic result. Once a year the patient is monitored through a complete series of photographs and radiographic investigations (Orthopantomography and lateral-lateral telerradiography of the skull) that demonstrates the stability of the treatment over time.

**Conclusion:** the Alt-RAMEC technique was an effective early treatment in skeletal class III and it allowed to achieve stable results after 8 years. The effectiveness of the therapy is related to a high compliance of the patient as the facemask and the elastics are removable devices.

## NUTRIENTS AND CRANIAL STRUCTURE: A PRELIMINARY STUDY

Lugarà B., Spina D., Maticena G., di Benedetto L., Piacino M.G.

Department of Surgical Sciences, Dental School C.I.R., Division of Orthodontics, University of Turin, Turin, Italy

**Aim:** the importance of nutrition for our health is worldwide recognized. We are used to mainly consider the biochemical, biological and dietary aspects thinking that the dental world is mainly involved with sugar and caries pathology. Indeed dentists are directly involved if we consider the role of the bolus consistency and the related muscular activity, which exert a fundamental action for cranio-facial growth. In this preliminary study we tested a questionnaire to evaluate the nutritional habits of subjects classified according to their cranial structure.

**Methods:** fifty-two subjects with malocclusions (25M, 27F; 11.7 y.o.) referring to the Orthodontic Department of the University of Turin were selected for the study and divided into 3 groups according to their cephalometric divergency (Sp-P<sup>^</sup>GoGn): hipodivergent = < 20°, mesodivergent = 20°-25° and hiperdivergent = >25°. The survey was conducted giving a questionnaire to patients' parents about children's eating

and nutrition habits. Parents had to mark a list of 32 suggested foods, 16 of soft consistency and 16 of hard consistency. The questionnaire was elaborated in collaboration with University of Gastronomic Scienze of Pollenzo. For statistical analysis, a multivariate analysis was conducted to verify the influence of covariates (hard or soft foods) on the dependent variable (divergency).

**Results:** the statistical analysis did not show significant differences among the groups ( $p > 0.05$ ), but it was relevant that there was a general choice of soft food (75% soft food, 61% hard food) especially among mesodivergent group who showed a significant preference of soft food ( $p = 0.0245$ ).

**Conclusion:** the future direction of this research will be to increase the number of the study sample to highlight a food plan which may help the psycho-physical development of the growing subjects.

## PERIODONTAL CONDITIONS IN OSA ADULT SUBJECTS TREATED WITH MAD

Palmacci D., Malara A., Azmy S., Venza N.

Department of Orthodontics, Head: Prof.ssa Paola Cozza, University of Rome Tor Vergata, Rome, Italy

**Aim:** to evaluate the periodontal conditions in adult patients with OSAS treated with MAD, comparing them with a control group of healthy subjects.

**Methods:** 16 patients (9 M. and 7 F. mean age of 53.7 years) were selected at Department of Orthodontics of Policlinico "Tor Vergata". The OSAS group was composed by 8 patients OSAS confirmed by polysomnography. Inclusion criteria were: AHI between 5 and 58, severe OSAS not treated with CPAP, treatment with MAD for at least 12 months. Exclusion criteria were: untreated or poorly cooperating patients with MAD, non-cooperation in the collection of periodontal and anamnestic data. Control group was composed by 8 patients with the following inclusion criteria: absence of systemic pathologies and respiratory problems. Each patient underwent a periodon-

tal evaluation by examining the following clinical parameters: bleeding, plaque index, probing depth and clinical attachment level. T test student and Levene test have been used for statistical analysis and comparison of the means.

**Results:** in the OSAS group, periodontal disease occurred in a mild stage in two patients, moderate in four and severe in two others. Significant parameters were the level of clinical attack, the plaque index, and the depth of the survey. Comparing the different types of MAD it is possible to observe that the MAD Telescopic predisposed more to periodontal disease than the MAD Forward.

**Conclusion:** there is a correlation between OSAS and periodontal disease. The severity primarily depends on the patient's hygienic conditions and secondary on the type of MAD.

## ORTHODONTIC TREATMENT IN A PATIENT WITH A CLEFT PALATE

Preatoni S.M.<sup>1</sup>, Bazzini E.<sup>2</sup>, Bagatta S.<sup>3</sup>, Bogni V.<sup>1</sup>, Micelli N.<sup>1</sup>, Fornarelli G.<sup>1</sup>

<sup>1</sup>Student, Department of Biomedical Sciences, University of Milan, Milan, Italy

<sup>2</sup>Visiting Professor, University of Milan, Milan, Italy

<sup>3</sup>Postgraduated student, University of Milan, Milan, Italy

**Aim:** the aim of this article is to show the orthodontic treatment in a patient with a cleft palate. These patients often present a maxillary hypoplasia because of scar tissue, which can restrict the growth of the maxilla in the forwards and downwards direction.

**Methods:** a male 10-years patient, with a cleft palate, presented at the first examination: concave profile, reduced transverse diameter of the palate, maxillary hypoplasia, significant reduced space in the upper arch and the maxillary dental midline deviated to the left side. The orthodontic treatment included a Pendex appliance to expand the maxilla and to distalize upper molars, for correcting midline. Once a good distalization

and expansion were achieved, the patient started upper and lower fixed orthodontic therapy (MBT 022 brackets). At the end of the treatment, the patient received a removable upper retainer and a lower fixed one, to maintain the result.

**Results:** at the end of treatment patient reaches good aesthetic and functional outcome, centered midlines, normal OJ and OB and class I molar and canine relationship.

**Conclusion:** the treatment for patients with CLP is challenging because of the difficulties due to the unfavorable facial growth, the necessity of a multidisciplinary approach and the need for good patient cooperation.

## PATIENTS AND PARENTS' SATISFACTION FOLLOWING INTERCEPTIVE ORTHODONTIC TREATMENT WITH EGA

Ruggiero C., Buono R., Puzo R., Valletta R.

Section of Orthodontics, Department of Neurosciences, Reproductive Sciences and Oral Sciences, University of Naples Federico II, Naples, Italy

**Aim:** currently, beyond objective treatment outcomes, it's essential to take into account the level of satisfaction and the improvements perceived by patients and parents about the daily life of the children. Eruption Guidance Appliances (EGA) represent a valid method for early orthodontic treatments in order to intercept and prevent different types of malocclusions. The aim of the current study was to evaluate patients and parents' satisfaction with the EGA treatment, by means of a dedicated questionnaire.

**Methods:** for the current cross-sectional survey patients aged between 6 and 12 years, who had completed their active phase of treatment with EGA, and whose parents accepted to be enrolled in the study were included. A questionnaire addressing social, functional and aesthetics domains was provided to patients and parents. Each question could be answered on a numerical Likert scales for parents, and smiley

face Likert scales for the children. Descriptive statistics was computed.

**Results:** most of the parents were satisfied with the improvement achieved by their children in terms of aesthetic appearance. Most common improvements were reported in breathing and chewing, followed by snoring, grinding and speaking. The majority of the children were satisfied with their teeth's appearance after orthodontic treatment with EGA. Both parents and children reported the appliance wearing being neither painful nor difficult.

**Conclusion:** to our knowledge, this is the first study evaluating patients and parents' level of satisfaction following interceptive orthodontic treatment with EGA. The results of this study support that both parents and patients who have finalized an interceptive treatment with EGA show a high level of satisfaction considering the studied outcome.

## LITERATURE REVIEW OF COMPLIANCE IN ALIGNERS TREATMENT

Scagliotti C.<sup>1</sup>, Gugino L.<sup>1</sup>, Quaglia A.<sup>1</sup>, Fiorillo G.<sup>2</sup>, Gastaldi G.<sup>2</sup>

Department of Dentistry, Director Prof. E. Gherlone, Vita Salute San Raffaele University, Milan, Italy

<sup>1</sup>Vita-Salute San Raffaele University of Milan, Master's Degree Course in Dentistry and Dental Prosthetics President: Prof. O. Cremona, Milan, Italy

<sup>2</sup>Vita-Salute San Raffaele University of Milan, School of Specialization in Orthodontics, director: Prof. G. Gastaldi, Milan, Italy

**Aim:** compliance with aligners is fundamental in orthodontic treatment but "patients routinely overestimate duration of wear" (Al-Moghrabi et al., AJODO 2017).

The aim of this review is to determine whether there is an efficient method to evaluate the compliance in patients treated with removable aligners.

**Methods:** the authors performed an extensive search of the literature on database PubMed. Literature search was accomplished using combinations of different keywords: Removable aligners OR Invisalign AND Compliance.

**Results:** there are several articles about removable aligners but only a few of these analyze the patients' compliance and the devices used to evaluate it. Align Technology recently introduced a "compliance indicator". It uses the food dye Erioglaucine disodium salt which is encapsulated in the clear Invisalign aligner and it is released from the polymer in the presence of oral fluid. There are opposing opinions about this de-

vice: some articles support its validity, although other authors claim that it is not suitable as an objective measure of wear time.

The device is effective but there are different color changes. The service times determined from the compliance indicators show good agreement with the number of service hours reported by the patients.

The experiments indicate that the wide variation of color changes between aligners (despite similar wear times) is not only caused by individual differences in the composition of saliva but also by effects of external factors, such as drinking water or acidic soft drinks examined at different temperatures.

**Conclusion:** according to this review there are not enough studies regarding specific devices designed to assess the compliance of patients. More high-quality clinical trials are needed to further demonstrate general levels of compliance in aligners treatment.

## MULTIDISCIPLINARY MANAGEMENT OF IMMATURE CENTRAL UPPER INCISORS INTRUSIVE TRAUMA

Simionato A., Salerno C., Balian A., Malerba A.

Department of Pediatric Dentistry, G. Vogel Dental Clinic, University of Milan, Milan, Italy

**Aim:** analyze the resolution of a case of the two upper central incisor intrusive trauma by direct orthodontic traction, evaluate its predictability, monitoring the vitality of the same elements, positive at the time of admission.

**Methods:** G.P., a 7.5-year-old girl, showed up in the pediatric dentistry department of the ASST Santi Paolo e Carlo referring a dental trauma. The clinical examination evidenced the presence of 1.1 and 2.1 elements intrusion, a cryo-test was made with a positive response. The peri-apical endoral X-ray showed no signs of root fracture and presence of 11 and 21 immature apices. With a multidisciplinary equipe an orthodontic therapy for active extrusion of 11 and 21 was planned. The therapy consisted in a palatal bar welded on 1.6 and 2.6 with a Nance button, equipped with TMA springs with eyelets for orthodontic traction. The orthodontic therapy was completed in about 10 months.

**Results:** a month after the orthodontic device removal, the control X-ray evidenced a radiotransparent area at 1.1 and 2.1 apices level.

Clinically 1.1 and 2.1 elements presented dyschromia and negative response at cryo-test. A CBCT X-ray was prescribed and a retrograde endodontic treatment with apicectomy was planned. After 1 month there was good healing of the soft tissues; after 6 months the elements 11-21 were stable and with physiological mobility.

**Conclusion:** the present case highlights the possible distant complications that can occur after complex trauma, such as the loss of vitality of the dental elements involved. The multidisciplinary approach was essential. Despite the reduction in root length, the traumatized and endodontically treated elements were stable.

## OSA AND AORTIC DILATATION IN MARFAN SYNDROME GROWING SUBJECTS

Venza N., Malara A., Laganà G.

Department of Orthodontics, University of Rome Tor Vergata, Rome, Italy

**Aim:** aortic aneurysm remain the most life-threatening manifestations of Marfan Syndrome (MS) and it represents the leading cause of mortality in this clinical group. Obstructive sleep apnea (OSA) is highly prevalent in MS, associated with cardiovascular risk. Aim of this research was to analyze the possible relations between OSA and aortic root diameters in growing subjects.

**Methods:** a group of 15 growing subjects with MS and a control group of 15 healthy peers was selected. In order to compare the physical characteristics, control group subjects were selected as closely as possible for average/frequency of age, gender, height and weight to the study group. All of them underwent nocturnal polygraphic monitoring and transthoracic echocardiography.

**Results:** aortic diameters are significantly higher in the study group especially in the sections of the aortic annulus and aortic root. Nocturnal polygraphic monitoring showed significant increased value of apnea hypopnea index and obstructive apnea index in the Marfan syndrome group.

No correlation between OSA severity and increased aortic diameters occurred.

**Conclusion:** high prevalence of OSA and increased aortic dimensions were observed in MS, compared with control group. OSA may not directly be associated with aortic dilation but it might contribute to the development and progression of aortic aneurysm from a young age.

## OPERATIONAL PROTOCOL OF A RHEUMATOID ARTHRITIS PATIENT IN ORTHODONTICS

Viti G., Imbesi E., Viti S., Costantino A.R., Maspero C., Manuelli M., Lucchese A.

Department of Dentistry, Dental School, Cattedra di Ortodonzia, CLOMPD, Pres. Prof. O. Cremona, IRCCS San Raffaele Hospital Vita Salute San Raffaele University, Milan, Italy  
Unit of Dentistry, Research Center for Oral Pathology and Implantology, Director Prof. E. Gherlone, IRCCS San Raffaele Scientific Institute, Milan, Italy

**Aim:** rheumatoid arthritis is a chronic inflammatory disease, its incidence and prevalence range from 12 to 1200 per 100000.

Female sex is more affected with a F:M ratio of 2:1 and peaks of disease onset detected between 1 and 3 years in females. The purpose of this study is to develop a protocol by a multi-specialist medical team to have an early diagnosis about temporomandibular functional problems in patients suffering from JRA.

There are necessary steps in the screening phase for these patients.

**Methods:** in this specific case we are going to illustrate the operational protocol and the planning of the therapy in order to respect the functional and aesthetic needs of our patient.

1. Rheumatological examination: physical examination and identification of risk factors involving atm;
2. ultrasound with power doppler study that is capable of: to identify synovitis and to study the translation of condyles;
3. orthognatodontic visit: extraoral (profile, symmetry) and intraoral inspection (type of occlusion), palpation of masticatory, neck and joint capsule muscles, loading (to identify the indirect signs not appreciable at EO);
4. radiographic examinations aimed at the atm;

5. preventive-therapeutic approach: local and systemic therapy, correction of parafunctions, targeted physiotherapy, gnathological therapy, orthodontic therapy, arthrocentesis, maxillofacial therapy;

6. laboratory exams: VES, PCR, positivity to FR.

**Results:** the protocol we adopted is a valid aid to prevent TMJ functional problems in patients affected by JIA.

Following our analysis they were found:

- absence of statistically significant correlation between symptoms reported by the patient and clinical signs detected;
- absence of statistically significant correlation between clinical signs revealed by the visit and structural alterations highlighted radiographically.

**Conclusion:** the results obtained in this study underline the importance of a careful gnathological evaluation at the onset of JIA.

Moreover, periodic follow-ups associated with an early diagnosis are indeed capable of reducing and improving functional and aesthetic problems in the patient.

At the end of orthodontic treatment, the operating protocol has been successful because the patient didn't have a reactivation of the disease. During the years the patient was well without any complications.

## STANDARDIZED ELECTROMYOGRAPHY OF MASTICATORY MUSCLES IN GROWING PATIENTS WITH DEEP BITE

Argenziano T., Barbiero V., Ruggiero C., Iuorio M., Rongo R.

School of Orthodontics, Department of Neurosciences, Reproductive Sciences and Oral Sciences, University of Naples Federico II, Naples, Italy

**Aim:** the aim of this study was to evaluate the surface electromyography (sEMG) characteristics in young patients with Deep Bite (DB), using standardized indices during static and dynamic tasks.

**Methods:** 20 children with DB (DBG, overbite > 5 mm; mean age  $11.7 \pm 2.1$  years) and 16 with a normal overbite (CG,  $1 < \text{overbite} < 3$ ; mean age  $12.8 \pm 2.5$  years) were recruited. The activity of the left and right anterior temporalis (AT), masseter muscles (MM) and submental muscles (SM) was recorded

during clenching, chewing and deglutition tasks, using a standardized sEMG method. Mann-Whitney test and chi-square test were used in the statistical analysis ( $P < 0.05$ ).

**Results:** in the clenching tests, the Torque Coefficient (TC) was lower in DBG than CG ( $P = 0.03$ ). The Asymmetry Coefficient (ASIM) and Activity Index (ATTIV) showed an asymmetry muscular activity in both groups. Regarding the masticatory tests, both groups showed an asymmetric activity but in CG there were patients with neuromuscular incoordination more

frequent than in DBG ( $P = 0.002$ ). Finally, during the deglutition tests, both groups showed an asymmetric activation of MM but in DBG there was a lower activation of MM for both sides respect to CG.

**Conclusion:** our study showed that growing patients have an asymmetric activity of masticatory muscles but patients with DB have a lower asymmetry, probably this is due to the anatomical position of the jaw which has less mobility in DB.

## SPINAL FLEXION IN A PATIENT WITH UNILATERAL CROSSBITE BEFORE/AFTER TREATMENT WITH FGB

Cagnotti F., Sicca N., Lombardo L., Ventura F., Di Benedetto L., Maticena G., Piacino M.G.

Department of Surgical Sciences, C.I.R. Dental School, University of Turin, Turin, Italy

**Aim:** presentation of a case of a growing patient with right unilateral anterior and posterior crossbite treated with Function Generating Bite (FGB) and analysis of spinal curvature and flexion in the frontal plane before and after functional orthognatodontic therapy.

**Methods:** female patient 7.5 years old. The following diagnostic data were collected: medical and dental history, model casts, OPT, L/L, P/A radiographies with relative cephalometric analyzes. It was also registered the spinal curvature in the frontal plane with the use of the Spinal Mouse before and after the correction of the initial malocclusion. The therapy was carried out with Function Generating Bite (FGB).

**Results:** before therapy, the patient presented a significant asymmetrical curvature of the whole spine in the frontal plane with greater flexion along the crossbite side ( $28.2^\circ$  left side curvature,  $35.7^\circ$  right side curvature). After 11 months, the

right unilateral anterior and posterior crossbite was corrected and there was a significant change in the curvature of the spine with symmetrization of lateral spinal bending in the frontal plane ( $23.6^\circ$  left side curvature,  $23.3^\circ$  right side curvature). After functional correction of an asymmetrical malocclusion as unilateral crossbite with Function Generating Bite, the spine curvature of the entire spine registered a postural symmetry, showing a general healthier muscular balance.

**Conclusion:** patients with unilateral posterior crossbite showed an asymmetrical body posture. The correction of the malocclusion with the functional appliance FGB induced not only the correction of dental malocclusion but also a symmetric favorable change in the neuromuscular postural control of growing patients, allowing the effective achievement of patients' oral and general health after orthognatodontic therapy.

## CLASS II GROWING PATIENTS TREATED WITH 3 FUNCTIONAL APPLIANCES: DENTO-SKELETAL COMPARISON

Calzolari C., De Mari A., Posadino M., Gjini L., Ferrante W., Migliorati M., Silvestrini Biavati A.

Orthodontic Department, DISC, Genoa University, Genoa, Italy

**Aim:** compare skeletal and dental effects produced by 3 different functional devices in Class II division 1 growing patients.

**Methods:** thanks to the following criteria 30 Class II Division 1 Patients (11F,19M) were included in this study: patients who could benefit from a class II treatment; the sample had a bilateral Angle Class II division 1 malocclusion,  $\geq 1/2$  cusp width, overjet greater than 5mm. 10 Patients (4F,6M, mean age 11,9yy) were treated with Twin-Block (removal) device and formed the Twin Block Group (TBG). 10 Patients (4F,6M, mean age of 9,44yy) were treated with Elastodontic (removal) appliance and formed the Elastodontic Group (EG). 10 patients (3F,7M, mean age 10,8yy) were treated with Herbst (fixed) device reinforced by 2 mini-screws and formed the Herbst Group (HBG). The SO-ceph-

alometric analysis of Pancherz was performed for each patient before (T0) and at the end (T1) of the treatment to analyze skeletal and dental changes. Measurements were compared using the Tstudent test. The value for significance was set at 0.05.

**Results:** a significant advancement of lower jaw with improvement of facial aesthetic was observed in every groups. In every group was seen a minimum proclination of lower incisors, in particular for HG ( $1,9^\circ$ ). Every group showed a significant improvement of ANB and Wits index. For the Wits index the differences between T1 to T0 values were statistically significant for TB ( $p = 0,009$ ) and for ANB the differences between T1 and T0 were statistically significant for HG ( $p = 0,04$ ). Lower molar showed an advancement in every treatment. Overjet correc-

tion was also obtained in every groups and the difference between T1 and T0 were statistically significant for EG ( $p = 0,09$ ) and for TBG ( $p = 0,009$ ).

**Conclusion:** every functional appliance analyzed in this study lead to a significant skeletal and dental correction of Class II Division 1 malocclusion.

## QUALITATIVE EVALUATION OF VOMER BONE POSITION BEFORE AND AFTER RAPID MAXILLARY EXPANSION

Gazzani F., Moretti S., Canigiola M.

Department of Orthodontics, University of Rome Tor Vergata, Rome, Italy

**Aim:** to evaluate positional changes of vomer bone before and after rapid maxillary expansion to confirm the possibility of skeletal effects on nasal septum deviation.

**Methods:** 10 subjects (6 m, 4 f) treated with RME were selected. All patients presented transverse maxillary deficit, crowding, and impacted incisors. CT low dose scans were taken before appliance placement (T0), at the end of active expansion (T1) to evaluate the exact position of impacted incisors. Qualitative evaluation of modality of expansion and vomer position was evaluated before and after suture opening.

**Results:** all the subjects showed a pattern of asymmetric suture opening. The right maxillary half tended to stay locked

while the left side showed less resistances during suture opening.

The asymmetrical changes were also appreciable clinically in the significant diastema between the maxillary central incisors. No changes of the vomer bone position were observed since it remained anchored to the more resistant side of the hemi-maxilla.

**Conclusion:** a pattern of asymmetric suture opening was observed during rapid maxillary expansion.

Vomer bone did not change its position after rapid maxillary expansion remaining locked to the more resistant and anchored hemi-maxilla.

## STABILOMETRIC RESPONSE AFTER RAPID PALATAL EXPANSION

Grassi L., Tigani C., Lombroni L.G., Zerva A., Cigni L., Cressoni C., Parisi F.M.R., Gianni A.B., Spadari F.

Department of Biomedical, Surgical and Dental Sciences, School of Dentistry, Fondazione IRCCS Cà Granda Ospedale Maggiore Policlinico, University of Milan, Milan, Italy

**Aim:** the Lizard Posturometric bipodal platform, is an instrument that allows us to qualify and quantify the postural oscillations of the subject placed in fixed orthostasis in neutral posture and analyze the maintenance of balance.

**Methods:** in a sample of 60 healthy patients without any disease.

We applied the equipment used by Hyrax. It is consisting of two or four anchor bands on the first molars permanent and on the first premolars or second deciduous molars. The protocol included five assessment times:

- T0: before initiation of orthodontic therapy by RPE;
- T1: just after adhesive cementation of the RPE;
- T2: after activation of the RPE;
- T3: before the removal of the RPE;
- T4: after the removal of the RPE.

The platform in question is bipodalic Lizard Ultimate® Posturometric, the examination was done with the patient standing on

the platform, the examination is also performed both with open and closed eyes.

**Results:** T0: the weight distribution is slightly unbalanced, with a recording of the load difference of 3,75 % with left foot head; T1: we keep the weight distribution slightly unbalanced; T2: we get a slight worsening of the weight distribution; T3: we keep the weight distribution slightly unbalanced, with a recording of the load difference 3.41% with right foot prevalence; T4: we keep the weight distribution slightly unbalanced; T0-T4: the weight distribution remains slightly unbalanced but we observe a 0.83% improvement over T0.

**Conclusion:** among diagnostic examinations to be integrated into daily practice in the use of RPE, postural analysis is important to investigate occlusal stability before and after expansion. It is able to assess how much can affect the posture in patients with transverse deficits in the upper arch treated with RPE and demonstrate whether we have any changes in neuromuscular and postural.

## THE EFFECTS OF MANDIBULAR DISTRACTION IN THE TREATMENT OF CLASS II

Lucchese A.<sup>1,2,3</sup>, Vrijens N.M.P.<sup>4</sup>, Sertori F.<sup>2</sup>, Santamaria A.<sup>2</sup>, Cicala P.<sup>2</sup>, Manuelli M.<sup>1,2,5</sup>

<sup>1</sup>Unit of Orthodontics, Division of Dentistry, IRCCS San Raffaele Scientific Institute, Milan, Italy

<sup>2</sup>Unit of Orthodontics, School of Dentistry, Vita-Salute San Raffaele University, Milan, Italy

<sup>3</sup>Unit of Dentistry, Research Center for Oral Pathology and Implantology, IRCCS San Raffaele Scientific Institute, Milan, Italy

<sup>4</sup>Department of Cranio-Maxillofacial Surgery, Maastricht University Medical Centre – MUMC+, Maastricht, Netherlands

<sup>5</sup>Private Practice, Milan, Pavia and Bologna, Italy

**Aim:** dental Class II is the most common indication for combined orthodontic-orthognathic treatment. Intermolar mandibular distraction osteogenesis (IMDO) treatment was performed during the growth spurt, to avoid surgery at a later age. The aim of this study is to present our first experience with IMDO.

**Methods:** this is a retrospective case series of patients who underwent an IMDO. All patients showed mandibular retrusion and orthodontic treatment with functional appliances was not successful or impossible.

**Results:** in total patients with a mean age of 14.8 (SD = 0.9) years were included. All patients achieved a Class I occlusion.

An average length gain of 9.6 (SD = 3.7mm) was seen. In one patient an abscess occurred. Nine patients presented with root fractures of the second molar, three were lost, one treated endodontically. The average time between insertion and removal of the distractors was 4.6 (SD = 1.5) months. One distractor side showed premature consolidation.

**Conclusion:** we achieved satisfactory results with IMDO. An advantage is the relatively manageable period of time in which the treatment could be completed. Questions remain: How did the root fractures occur? Are the results stable in terms of occlusion? What influence does the dynamic distraction treatment have on the temporomandibular joint?

## STABILITY PREDICTION OF EARLY TREATMENT IN OPEN BITE MALOCCLUSION: A MORPHOLOGIC ANALYSIS

Lugli L., Paoloni V., De Razza F.C.

Department of Orthodontics, Head: Prof.ssa P. Cozza, University of Rome Tor Vergata, Rome, Italy

**Aim:** to evaluate morphologic differences between success and failure Open Bite malocclusion early orthodontic treatment in growing subjects in order to identify predictors of relapse.

**Methods:** 23 patients were enrolled from the Department of Orthodontics at the University of Rome Tor Vergata. Inclusion criteria were: white ancestry, OVB < 0 mm, mixed dentition phase, cervical skeletal maturation CS1-CS2, no previous orthodontic treatment, no congenital diseases. Pre-treatment (T0) panoramic and lateral cephalograms were acquired. Each patient underwent early orthodontic treatment with Rapid Maxillary Expander (RME) or Quad-Helix Crib (QHC) until open bite correction. Radiographic records were recollected at T1 two years after debonding. According to treatment stability, Relapse Group (RG, 11) and Success Group (SG,12) were identified. Vertical and mandibular cephalometric measure-

ments were analyzed. Inter and intra group statistically significant differences were performed using student's *t*-tests.

**Results:** at T0 no statistically significant differences were found between RG and SG. T1-T0 comparison showed in RG statistically significant increases in Co-Gn ( $p = 0.04$ ), Go-Gn ( $p = 0.02$ ), SN<sup>^</sup>PP angle ( $p = 0.04$ ) and N-Me distance ( $p = 0.04$ ). At T1, SN<sup>^</sup>MP angle ( $p = 0.0051$ ), PP<sup>^</sup>MP angle ( $p = 0,0179$ ), ANS-Me distance ( $p = 0.0072$ ), NGo<sup>^</sup>GoMe angle ( $p = 0.0079$ ), negative overbite ( $p < 0.0001$ ) and antegonial notch depth ( $p = 0,0427$ ) were statistically significant higher in RG than in SG.

**Conclusion:** the increased mandibular length and antegonial notch depth and the clockwise growth could be predisposing factors for relapse in early orthodontic treatment in open bite growing subjects.

## STIMULATED AND UNSTIMULATED SALIVARY FLOW RATES IN JUVENILE IDIOPATHIC ARTHRITIS

Marino S., Parisi F.M.R., Cressoni C., Occhipinti C., Garagiola U., Spadari F.

Specialization School in Orthodontics, University of Milan - UOC Maxillofacial Surgery and Odontostomatology, Maggiore Hospital of Milan IRCCS Ca' Granda, Milan, Italy

**Aim:** the aim of this study is to investigate unstimulated salivary flow (USF) and stimulated salivary flow (SSF) in a sample of patients affected by Juvenile Idiopathic Arthritis (JIA).

**Methods:** USF and SSF were collected from 38 randomly selected JIA patients visiting Orthodontics Clinic at Ospedale Maggiore Policlinico in Milan.

The spitting method was used to collect repeated saliva samples. 3 samples were collected without stimulation consecutively for 5' and 3 more samples were collected after stimulation by citric acid. A 1' interval was spent measuring the sample with a graduated syringe after each 5' period. The collection was performed between 9 a.m. and 10 a.m., at least 2 hours after the last intake of food or drink. The flow rate was calculated in milliliters per minute.

**Results:** the sample included 30 females and 8 males. Age ranged between 6 and 28 years (mean = 13,5; median = 12). Mean flow rates resulted as follows: USF rate after 5' = 0,395158; USF rate after 10' = 0,365526 mL/min; USF after 15' = 0,427895 mL/min. SSF rate after 5' = 0,976474 mL/min; SSF rate after 10' = 0,991211 mL/min; SSF after 15' = 1,011526 mL/min. SSF/USF ratio was maximum after 10' (2,711735) and minimum after 15' (2,363961). 22 patients wore orthodontic appliance and the 15 did not. No statistical difference in mean USF or mean SSF between these two groups has been appreciated.

**Conclusion:** data confirm that JIA patients have lower USF and SSF compared to the general population. Salivary flow rates remain stable over a period of 15'. Orthodontic appliances seem not to influence USF and SSF.

## SUCCESS RATE OF MINISCREWS AS ANCHORAGE FOR HERBST IN THE LOWER ARCH: A PROSPECTIVE STUDY

Migliorati M.<sup>1</sup>, Drago S.<sup>1</sup>, Manni A.<sup>2</sup>, Silvestrini-Biavati A.<sup>1</sup>

<sup>1</sup>Orthodontic Department, School of Dentistry, Genoa University, Genoa, Italy

<sup>2</sup>Private Practice, Racale, Lecce, Italy

**Aim:** this study aimed to evaluate the success rate of orthodontic miniscrews used to reinforce anchorage in the lower arch during the therapy with the Herbst appliance.

**Methods:** patients in need of fixed orthodontic treatment were enrolled in this single-blinded clinical trial. Eligibility criteria were no systemic disease and absence of using drugs altering bone metabolism. Patients received a symmetrical bilateral interradicular anchorage in the lower arch with a pair of 1.2 mm or 1.4 mm diameter miniscrews. The success rate was examined, and the association of success with demographical, clinical and geometrical characteristics was investigated. The fail-

ure rate differences were tested by the generalized linear mixed effects model.

**Results:** 100 miniscrews were inserted in 41 patients (23 F and 18 M, mean age: 15.55 ± 7.91). The total failure rate was 24%. No significant differences in failure rate were found between miniscrew diameters, patients sex or age.

A strong correlation was observed between the 4-5 location and success.

**Conclusion:** demographical and geometrical characteristics did not affect significantly the success rate. The location between 4 and 5 was strongly related to success.

## PREVALENCE OF MALOCCLUSIONS IN DOWN SYNDROME VS HEALTHY SUBJECTS: A CROSS-SECTIONAL STUDY

Mollo A., Guglielmi F., Alessandri Bonetti A., Salerno M, Gallenzi P.

A. Gemelli Foundation, IRCCS – Catholic University of Sacred Heart, Orthodontics Residency Program: Director: Prof. M. Cordaro, Rome, Italy

**Aim:** down syndrome is the most common chromosomal disorder with an incidence of 1: 792 live births. Down patients have been reported to often present false macroglossia, hypotonia and ogival palate. In this cross-sectional study, the aim was to analyse the differences in orthodontic variables between patients presenting Down syndrome and a control group.

**Methods:** we recruited consecutive patients affected by Down syndrome from the dental clinic of the A. Gemelli Hospital. The following parameters were taken into consideration: age, sex, DMFT Index, profile, midline, molar and canine class, overjet, overbite, crowding, crossbite, openbite, scissorbite. The same measurements and examinations were performed in healthy subjects matched for sex and age with the study group. Patients with a history of a previous orthodontic treatment were excluded. Demographic data were analyzed using descriptive

statistics. The results were noted on a dedicated questionnaire related to the orthodontic features that were evaluated.

**Results:** a total of 41 patients (22F, 19M) presenting with Down syndrome were included in the analysis and compared to 41 healthy patients without known and/or reported genetic anomalies matched by age and sex. The median age was  $14,9 \pm 10,7$  DS years old.

The most common malocclusion in Down patients were the III skeletal and dental class with a prevalence of 63%, while healthy subjects presented a prevalence of the same malocclusion of 7%. Maxillary contraction was 75% in the study group, while 17% in the control group.

**Conclusion:** patients with Down syndrome reported a higher prevalence of malocclusions, mostly characterized by a transverse maxillary deficit and a skeletal class III tendency with class III molar, null OVJ and OVB.

## STOMATOGNATHIC APPARATUS AND THE RESPIRATORY FUNCTION

Nucci F, Bica E., Nardi N., Maspero C., Spadari F, Gianni A.B.

Department of Dentistry, IRCCS Ca' Granda Maggiore Policlinico Hospital, Milan, Italy; University of Milan, Milan, Italy

**Aim:** the objective of this study is to evaluate if after rapid palatal expansion there is an improvement of the upper airways and if it is necessary and enough to make the rhinomanometric and spirometric exams for the diagnosis and the control of the upper airways.

**Methods:** using the keywords: ERP, rhinomanometric and spirometric exams a literature review of 50 articles was made. Inclusive criterias for this review were articles in which every patient had a constricted maxilla and some of them presenting posterior crossbite. They all have had orthodontic treatment with the rapid palatal expander, that was activated for 1 week 2 a day. After the orthodontic treatment the respiratory exams were evaluated again.

**Results:** it has been observed an improvement of the patency of the upper airways in the patients with oral breathing after rapid palatal expansion. The rhinomanometric, spirometric and otorinolaringoiatric exams allow a valid diagnosis of the breathing dysfunction and furthermore allow the control of the patient during the orthodontic therapy because they are not invasive.

**Conclusion:** we can assert the patency of the upper airways improve with the rapid palatal expansion therapy, that the active anterior rhinomanometric (AAR) is an excellent method for diagnosis but also for the control. Finally, the rhinomanometric and spirometric exams can be considered ordinary in orthodontic diagnosis.

## CORRELATION BETWEEN MALOCCLUSION AND ALLERGIC RHINITIS IN PEDIATRIC PATIENTS

Pacini M., Fama A., Grassi L., C. Tigani C.

Department of Biomedical, Surgical and Dental Sciences, School of Dentistry, Fondazione IRCCS Ca' Granda Ospedale Maggiore Policlinico; University of Milan, Milan, Italy

**Aim:** allergic rhinitis is often reported as associated to several conditions such as asthma, sinusitis, hypertrophy of the lymphoid tissue, obstructive sleep apnea (OSAS), oral breathing, nasal obstruction and airway space reduction. Some of these conditions, in particular oral breathing and nasal obstruction, have been linked to altered facial patterns and dento-skeletal changes. However, no firm correlation based on the evidence has been established. The aim of this systematic review is to evaluate the available evidence between malocclusion and allergic rhinitis in pediatric patients.

**Methods:** the research refers to Preferred Reporting Items for Systematic Reviews and Meta-Analyses Protocols (PRISMA-P) guidelines, databases (Medline, Cochrane Library, PubMed, Embase and Google Scholar) were screened and the quality was evaluated through Quality Assessment of Diagnostic Accuracy Studies (QUADAS-2). The inclusion criteria

were articles specifically related to the correlation between allergic rhinitis and malocclusion, with a reliable or accurate diagnostic method and with information about etiology, diagnosis and therapy. The articles selected (6 out of initial 1782) were divided on the basis of the study design: two observational randomized study, three case-control study, one descriptive cross-sectional study, and one longitudinal study. A total of 2188 patients were considered.

**Results:** different results were reported as related to allergic rhinitis such as a higher incidence of dental malocclusion, of posterior cross-bite and anterior open-bite, an increase of palatal depth and longer faces and shorter maxillas.

**Conclusion:** most of the studies selected found a rise in the prevalence of both malocclusion and allergic rhinitis in children. However, the level of bias is high, and further studies are needed to draw conclusive evidence of this correlation.

## POSTEROANTERIOR DIAMETERS OF CONDYLES IN PATIENTS WITH JUVENILE IDIOPATHIC ARTHRITIS

Parisi F.M.R., Cressoni P., Colangelo B., Lombroni L.G., Zerva A., Tigani C., Grassi L., Garagiola U., Gianni A.B., Spadari F.

School of Specialization in Orthodontics, Director: Prof. F. Spadari; Department of Biomedical, Surgical and Dental Sciences IRCCS Ca' Granda Foundation - Ospedale Maggiore Policlinico, UOC, Maxillofacial Surgery and Odontostomatology, Director: Prof. A. B. Gianni, Milan, Italy

**Aim:** Juvenile Idiopathic Arthritis (JIA) is an inflammatory joint disease of unknown etiology that occurs before the age of 16, with a higher incidence in females and it lasts for more than 6 weeks. It leads to erosion and damage of many body joints, including the temporomandibular joint. The aim of this work is to evaluate the difference in size between healthy and diseased posteroanterior condylar diameters in children with JIA.

**Methods:** 50 patients were selected, 40 females and 10 males, out of an initial sample of 70. They were between 4 and 16 years old and their CBCTs were analyzed. The posteroanterior diameters of the right and the left condyles were measured through 3Diagnosys program and the difference in size between healthy and pathological ones was evaluated.

**Results:** a mean difference between healthy diameter and JIA eroded diameter of 2.1 mm was observed.

The minimum diameter difference found was 1 mm and the maximum was 7 mm. The differences tend to be greatest during the child's growth phase, between the ages of 11 and 16. There was no correlation with sex and the age of onset of the disease.

**Conclusion:** condyles affected by JIA are smaller in size than healthy ones. The differences between the posteroanterior diameters of healthy and diseased condyles in patients with JIA tend to be independent of sex and age of onset of the disease. However, it was found an increase in difference in correspondence with the patients' growth phase.

## ASSESSMENT OF CONDYLAR ANGULATIONS IN PATIENTS WITH JUVENILE IDIOPATHIC ARTHRITIS

Cressoni P., Parisi F.M.R., Zerva A., Bica E., Tigani C., Lombroni L.G., Grassi L., Garagiola U., Gianni A.B., Spadari F.

School of Specialization in Orthodontics, Director: Prof. F. Spadari; Department of Biomedical, Surgical and Dental Sciences IRCCS Ca' Granda Foundation - Ospedale Maggiore Policlinico; UOC, Maxillofacial Surgery and Odontostomatology, Director: Prof. A. B. Gianni, Milan, Italy

**Aim:** Juvenile Idiopathic Arthritis (JIA) is an inflammatory joint disease of unknown etiology which affects the body joints, including the temporomandibular joint. However, it is often asymptomatic at the level of the temporomandibular joint and, for this reason, its diagnosis is easily delayed.

It occurs before the age of 16, with a higher incidence in females and it lasts for more than 6 weeks. It not only leads to the erosion of the condyles, but also it causes an alteration of their angulation.

The aim of this work is to evaluate the difference in angulation between healthy and diseased condyles in patients affected by JIA.

**Methods:** 30 patients were selected, 25 females and 5 males, out of an initial sample of 50, so that they were aged between 4 and 16 years, and their CBCTs were analyzed. The angles between healthy and diseased right and left condyles were measured using the 3Diagnosys program and the difference in angulation was evaluated.

**Results:** an average difference of 9.8 ° in angulation was observed between healthy and diseased condyles, with greater angulation in those eroded by JIA.

**Conclusion:** Juvenile Idiopathic Arthritis not only leads to the erosion and reduction of the size of the condyles affected, but also causes a greater angulation than the corresponding healthy condyle.

## MEDIOLATERAL DIAMETERS OF CONDYLES IN PATIENTS WITH JUVENILE IDIOPATHIC ARTHRITIS

Parisi F.M.R., Cressoni P., Cigni L., Marino S., Grassi L., Zerva A., Lombroni L.G., Tigani C., Garagiola U., Gianni A.B., Spadari F.

School of Specialization in Orthodontics, Director: Prof. F. Spadari; Department of Biomedical, Surgical and Dental Sciences IRCCS Ca' Granda Foundation - Ospedale Maggiore Policlinico UOC, Maxillofacial Surgery and Odontostomatology, Director: Prof. A. B. Gianni, Milan, Italy

**Aim:** rheumatoid arthritis is a chronic inflammatory progressive disease that can lead to ankylosis and deformity of the joints. It can also affect young people as juvenile idiopathic arthritis (JIA), an inflammatory joint disease of unknown etiology that occurs before the age of 16, with higher incidence in females and lasting more than 6 weeks.

Among the affected joints there is the temporomandibular joint too. The aim of this work is to evaluate the difference in size between healthy and diseased mediolateral condylar diameters in children with JIA.

**Methods:** the CBCTs of 50 children, 40 girls and 10 boys between 5 and 16 years old, were analyzed through the 3Diagnosys program. The mediolateral diameters of the right and left

condyles were analyzed and the difference in size between healthy and pathological ones was evaluated.

**Results:** the minimum diameter difference found was 1 mm and the maximum was 5 mm. A mean difference between healthy and pathological mediolateral diameters of 1.2 mm was observed. Differences were more evident during the child's growth phase, between the ages of 11 and 16. There was no correlation with sex and the age of onset of the disease.

**Conclusion:** condyles affected by JIA are smaller in size than healthy ones and an increase in the difference between mediolateral diameters of healthy vs pathological condyles was found at the patients' growth phase. Differences seem to be independent of sex and age of onset of the disease.

## SKELETAL CLASS II AND TEMPOROMANDIBULAR DISORDERS: A LITERATURE REVIEW

Porro A., Vella M., Tripicchio C., Butti A.

Department of Biomedical, Surgical and Dental Sciences, IRCCS Ca' Granda Foundation, Ospedale Maggiore Policlinico, University of Milan, Milan, Italy

**Aim:** the aim of the study is to perform a literature review on the correlation between skeletal class II and the onset of TMD.

**Methods:** the Medline database was consulted using as keywords “temporomandibular disorders AND class II malocclusion”, selecting articles published in the last five years.

**Results:** the role of occlusion is of great interest in the study of TMDs. Most of the literature is based on retrospective studies based on questionnaires to investigate the presence of TMD in the presence of class II malocclusions. Some reviews analyze older studies, and these show a positive correlation between the presence of TMD and malocclusion, including skeletal

class II. More recent studies, performed with more rigorous methodologies, decreasing the risk of bias, improving the choice of the patient sample do not reveal statistically significant differences between the group with malocclusion and the control group. Epidemiological studies on incidence and prevalence of TMD in the population show that the etiology is multifactorial and not limited to the presence of malocclusions.

**Conclusion:** in the past, class II malocclusion, especially division II, has often been associated with TMD. Most recent studies agree that occlusion is not a fundamental element for the onset of TMDs.

## THE EFFECT OF DIGITAL IN ORTHODONTICS

Salvaterra A., Toma G., Carezzi L., D'innella E., Zechini G., Santamaria A., Cipparrone C., Lucchese A., Manuelli M.

Master's Degree Course in Dentistry and Dental Prosthetics. (Pres. Prof. O. Cremona); Chair of Orthodontics and Gnathology San Raffaele Life and Health University, Milan, Italy. IRCCS San Raffaele, Scientific Institute, Milan, Italy  
Private practice, Pavia, Italy

**Aim:** the aim of the present study is to analyze new orthodontic therapy protocols that through an entirely digital workflow manage to design a custom-made treatment plan. There are four basic principles behind the use of new technologies:

- custom-made devices;
- precision and Accuracy of the products;
- repeatability of the results;
- reduction of total treatment time.

**Methods:** facial scanners provide the three-dimensional topography of the anatomy surface. The use of intraoral scanners are well tolerated by the patient, since they don't require the use of conventional materials. The main application in Orthodontics of 3D printing is to create epoxy resin models for aligners.

In recent years the acquisition technique “TC Cone Beam” (CBCT) has allowed the 3D visualization of the maxillofacial complex. After analyzing the diagnostic tools, new planning methods for a custom-made therapy and CAD/CAM designed orthodontic device were investigated.

- Invisalign (Align Technology®);
- Insigna (Ormco®);
- Incognito (3M®);
- Digital protocols to realize Indirect Bonding have been analyzed;
- Memotain Retainer (Ormco);
- Sure Smile (Orametrix®);
- Orthopedic/functional devices created with a completely digital workflow such as REP and the realization of surgical templates for the insertion of miniscrews using CAD/CAM techniques have been analyzed.

**Results:** a digital workflow is able to reduce the time of treatment especially during the initial phase and the finishing phase of the case.

**Conclusion:** in the future, a greater integration between software, digital models, 3D facial scanner and CBCT will further allow and facilitate treatment planning and patient communication.

## STABILOMETRIC RESPONSE AFTER RAPID PALATE EXPANSION IN PATIENT WITH JUVENILE IDIOPATHIC ARTHRITIS (JIA)

Tigani C., Lombroni L.G., Parisi F.M.R., Zerva A., Cigni L., Cressoni P., Gianni A.B., Spadari F.

Fondazione IRCCS Cà Granda Ospedale Maggiore Policlinico, Department of Biomedical, Surgical and Dental Sciences, School of Dentistry, University of Milan, Milan, Italy

**Aim:** to highlight how the Lizard Ultimate Posturometric bipodal platform, for computerized recordings stabilometric and baropodometric computerized recordings, can assist in assessing the effective ability of a rapid palatal expander to influence posture, in a patient with JIA.

**Methods:** we applied a rapid palatal expander with bands on the sixths to 20 patients (six of which had JIA).

The patient's parents were instructed on the activation protocol (one activation per day for 15 days).

The protocol included five assessment times:

- T0: before initiation of orthodontic therapy by REP;
- T1: just after adhesive cementation of the Rapid Palatal Expander (same day as T0);
- T2: after 14 activation of the Rapid Palatal Expander;
- T3: before the removal of the Rapid Palatal Expander;
- T4: after the removal of the Rapid Palatal Expander (same day as T3).

The platform in question is bipodalic Lizard Ultimate® Posturometric, the examination was done with the patient standing on

the platform, the examination is also performed both with open and closed eyes, with and without glasses.

**Results:** before and after the application of the rapid palate expander, the results were as follows: Weight distribution on the footplate with eyes open remains unbalanced but we observe a clear improvement of 7.18% compared to T0. The weight distribution with eyes closed remains unbalanced between right and left foot but we observe a clear improvement of 5.11% compared to T0. In the analysis of Pronosupination instead OA/OC in JIA patients we have no significant change in the value.

**Conclusion:** postural monitoring of the orthodontic case, can therefore be considered among the examinations useful to the dentist to investigate how, therapies such as rapid expansion of the palatal, can affect the postural balance, then on the receptors designed to allow a condition that minimizes the expenditure of energy to maintain an upright position both at the neuromuscular level and occlusal stability. Comparing healthy patients (subjected to the same tests) with those with JIA, we found a greater improvement in those with JIA.

## CORRELATION BETWEEN ROOT RESORPTION AND ORTHODONTIC TREATMENT: A REVIEW OF THE LITERATURE

Tigani C., Fama A., Pacini M., Grassi L., Maschio M.

Fondazione IRCCS Ca Granda Ospedale Maggiore Policlinico, Department of Biomedical, Surgical and Dental Sciences, School of Dentistry, University of Milan, Milan, Italy

**Aim:** the aim of this work is to perform a review about root resorption and its correlation with orthodontics.

**Methods:** the systematic review of the literature was conducted through the following electronic databases: Medline database, Embase and Cochrane Library. The keywords "root resorption", "dental resorption", "apical root resorption", "orthodontic" and "ankylosis". Inclusion criteria: articles between 1976 and 2018, case-reports and series, reviews and clinical trials. Using the "limits" option, only articles referring to "Humans" were considered. Exclusion criteria: articles referring to a non-dentistry topic and those published before 1960 were not considered.

**Results:** initially 4090 articles were found in total 357 of them were reviewed and 159 papers were selected because of their relevance about the subject.

**Conclusion:** taking into consideration the prevalence of the problem, it is important to perform an early diagnosis through careful control of high-risk cases, such as the traumatized elements. Sex, malocclusion, crowding, and post treatment approximation to the cortical plates significantly affected the percentage of change in root length. Post-treatment approximation of root apices to the palatal cortical plate showed the strongest association for increased orthodontically induced-inflammatory root resorption.

## DIFFERENT POSSIBILITIES FOR TREATMENT OF DILACERATED DENTAL ELEMENTS: A REVIEW OF THE LITERATURE

Tigani C., Fama A., Pacini M., Grassi L., Maschio M.

Fondazione IRCCS Ca' Granda Ospedale Maggiore Policlinico, Department of Biomedical, Surgical and Dental Sciences, School of Dentistry, University of Milan, Milan, Italy

**Aim:** a dilacerated dental element is a tooth with a noticeable alteration in the axial inclination between the crown and the root. Several therapeutic approaches are proposed in the literature. The aim of this systematic review is to analyze treatment options and outcomes by considering epidemiology, etiology and diagnosis.

**Methods:** the systematic review of the literature was conducted through the following electronic databases: Medline database, Embase and Cochrane Library.

Keywords selected are: "dilacerated tooth", "dilacerated root", "dilacerated crown", "dilaceration".

Inclusion criteria: articles between 1970 and 2018, case-reports and series, reviews and clinical trials. Using the "limits" option, only articles referring to "Humans" were considered. Commentaries, letters to the editor, short communication, arti-

cles referring to non-dentistry topic and those published before 1963 were not contemplated.

**Results:** a total of 1023 articles were found, from which duplicates were discarded, resulting in a total of 390 articles. Two hundred and seven articles were selected from the database. Subsequently 156 articles were excluded as not relevant based on the abstract, title and study design. Full texts of 51 articles were read to rule out further irrelevant studies. Finally only 31 articles met the inclusion criteria.

**Conclusion:** adequate periodontal support and tooth vitality can be maintained through the use of light and continuous orthodontic forces (30-40g). Surgical solutions are preferred in case of particularly compromised dental elements. Combined orthodontic-surgical options should be investigated in long-term longitudinal studies.

## STRESS COMPARISON BETWEEN THREE MADs FOR OSAS ON PERIODONTAL LIGAMENTS BY FEM ANALYSIS

Zalunardo F.<sup>1</sup>, G. Bruno G.<sup>2</sup>, De Stefani A.<sup>2</sup>, Gracco A.<sup>3</sup>, Stellini E.<sup>3</sup>

<sup>1</sup>Undergraduate student, Department of Neuroscience, School of Dentistry, University of Padua, Padua, Italy

<sup>2</sup>DDS, Department of Neuroscience, School of Dentistry, University of Padua, Padua, Italy

<sup>3</sup>Professor, Department of Neuroscience, School of Dentistry, University of Padua, Padua, Italy

**Aim:** obstructive sleep apnea syndrome (OSAS) is characterized by repeated partial or total occlusion of the upper airways. Mandibular advancement devices (MAD) represent the gold standard treatment for mild and moderate OSAS. MADs have good compliance; however, they have adverse effects such as occlusal changes and their use is not recommended in cases of active periodontal disease. The purpose of the study is to compare the stress effects developed on periodontal ligaments by 3 MADs using a finite element method (FEM) analysis.

**Methods:** a 3D reconstruction of the maxilla and mandible were implemented from the computed tomography (CT) scan of a patient's skull. 3 MADs (Orthoapnea, Herbst, Somnodent) were prepared, scanned and coupled with the models of the

jaws. A FEM analysis was performed to calculate the stress on periodontal ligaments created by applying an advancement force.

**Results:** orthoapnea has high and concentrated stress values, especially in the anterior maxillary and mandibular area with 4.26 kPa as maximum value. Herbst and Somnodent devices, instead, present very similar stress values, mainly concentrated on lateral teeth. The forces are very mild and distributed. The maximum values are 3.27 kPa for Somnodent and 3.56 kPa for Herbst.

**Conclusion:** devices with bilateral mechanism generate less and more distributed stress than anterior connecting rod mechanism. Therefore, they may be advisable to patients with compromised periodontal health in the anterior area.

## TREATMENT OF CLASS II MALOCCLUSION IN GROWING PATIENTS WITH ALIGNERS

Buono R.<sup>1</sup>, Rongo R.<sup>1</sup>, Dianiskova S.<sup>2</sup>, Valletta R.<sup>1</sup>, Michelotti A.<sup>1</sup>, D'Antò V.<sup>1</sup>

<sup>1</sup>School of Orthodontics, Department of Neurosciences, Reproductive Sciences and Oral Sciences, University of Naples Federico II, Naples, Italy

<sup>2</sup>Department of Orthodontics, Medical Faculty, Slovak Medical University, Bratislava, Slovakia

**Aim:** to compare the dental and skeletal effects of intermaxillary elastics on the correction of Angle's Class II division 1 malocclusion with clear aligner treatment (CA) *versus* fixed multi-bracket (FMB) in growing patients.

**Methods:** the study sample consisted of 49 consecutively patients (mean age  $\pm$  SD 12.9  $\pm$  1.7 years), 32 females and 17 males referred from the University of Bratislava. All patients were treated with a non-extraction orthodontic treatment, 25 with FMB and 24 with CA.

The cephalometric analysis was performed at the beginning (T0) and the end of the treatment (T1). The T test for unpaired data was carried out to compare cephalometric values at T0 and changes at T1-T0 between the two groups. The level of significance was set as  $P < 0.0035$ .

**Results:** the two groups showed no statistically significant differences (ANPg =  $-0.1^\circ$ ;  $P = 0.762$ ) in the correction of the sagittal intermaxillary relation. The analysis of vertical skeletal changes showed no statistically significant effects on mandibular inclination (SN/MP =  $0.1^\circ$ ;  $P = 0.840$ ). The two treatments had a statistically significant and clinically relevant difference in controlling the inclination of the lower incisors (L1/GoGn =  $4.8^\circ$ , CAG =  $-0.5^\circ \pm 3.9^\circ$ ; FMB =  $4.3^\circ \pm 5.8^\circ$ ;  $P < 0.001$ ).

**Conclusion:** class II elastics combined with CA and FMB produce a similar correction on sagittal discrepancies in growing patients. CA presented a better control in the proclination of the lower incisors. CA and elastics might be a good alternative in the correction of Class II malocclusion in cases where a proclination of lower incisors is unwanted.

## DENTAL AGENESIS: INCIDENCE, PREVALENCE AND TREATMENT

Butti A., Tripicchio C., Porro A., Vella M.

Department of Biomedical, Surgical and Dental Sciences, IRCCS Ca' Granda Foundation, Ospedale Maggiore Policlinico, University of Milan, Milan, Italy

**Aim:** the purpose of this study is to present the incidence and prevalence of dental agenesis and analyze different therapeutic options.

**Methods:** articles searched on PubMed, Scopus and WOS from the past 10 years including systematic reviews have been selected.

**Results:** agenesis mainly affects permanent dentition, the incidence in deciduous dentition is around 0,5%. In Italy 7,7% of population is affected by agenesis, with prevalence of female compared to male (ratio 3:2). The most affected teeth are the third molars followed by upper lateral incisors and lower second premolars. Agenesis can be single, multiple, symmetrical or asymmetrical. The etiopathogenesis consists of a disturbance in the maturation of the cells of the dental buds in the

early stages of dentition. Various causes can cause agenesis (genetics, trauma, diseases, drugs). Orthodontist will have to decide whether to open or close the space. Opening the space maintains physiological intercuspation between the arches and the patient will have to wear a removable prosthesis or a Maryland bridge until the implant is inserted. In some cases, it is possible to open the space just before implant insertion to avoid bone resorption in the edentulous area. The choice to close the space is a much more practical decision that avoids the patient from prosthetic problems. It is possible to keep the deciduous teeth in place.

**Conclusion:** a multidisciplinary approach is required, analyzing the affected arch, the molar class, the skeletal class and missing elements.

## EVALUATION OF PATIENT USE OF THE ORTHOPULSE DEVICE DURING A CLEAR ALIGNERS TREATMENT

Calvaruso C.<sup>1</sup>, Bocchieri S.<sup>2</sup>, Carganico A.<sup>2</sup>, Bertini S.<sup>1</sup>, Capotosto I.<sup>1</sup>, Zanini A.<sup>1</sup>, Levrini L.<sup>3</sup>

<sup>1</sup>Private Practice, G.O.T., Turin, Italy

<sup>2</sup>Postgraduate Program in Orthodontics, Department of Medicine and Surgery, University of Insubria, Varese-Como, Italy

<sup>3</sup>Director of Postgraduate Program in Orthodontics, Department of Human Sciences, Innovation and Territory, University of Insubria, Varese-Como, Italy

**Aim:** the aim of the study is to evaluate if compliance is correlated with treatment time in patients using OrthoPulse device while being treated orthodontically with clear aligners, focusing on the variation of collaboration rate during the therapy, in order to establish the ideal moment to plan a recall to enhance patients motivation.

**Methods:** 354 patients treated with clear aligners and OrthoPulse were considered for this study. They were instructed to use the device 10 minutes per day. Inclusion criteria for the study were: compliance higher than 20% and treatment time longer than 30 days. After the selection, 272 subjects were included. Statistical analysis was performed with Jamovi software (version 1.6.14, the Jamovi project, Sydney, Australia). Spermann's rho test was then carried out to assess any correlation.

**Results:** Spermann's test scored -0,312 ( $p < 0.001$ ), showing moderate correlation between the compliance and the treatment time: compliance rate is in fact lower in longer orthodontic therapies. After one year, the compliance rate is reduced of about 50% of the prescription.

**Conclusion:** these preliminary results showed and emphasize the importance of patient's motivation. If patients are well instructed and clinicians explains in a proper way the use of OrthoPulse device, its use is more likely to be constant from the beginning to the end of the treatment. Planning a new session of motivation could be useful after one year in order to keep the compliance high, especially in longer therapies, planned for at least 18-24 months.

## CLUBFOOT AND EFFECTS OF TRAUMATIC INJURIES ON CONDYLAR DEVELOPMENT IN GROWING PATIENT

Cigni L., Cressoni P., Garagiola U.

Department of Biomedical, Surgical and Dental Sciences, School of Specialization in Orthodontics - Director: Prof. F. Spadari, Fondazione IRCCS Ca' Granda - Ospedale Maggiore Policlinico, UOC Maxillofacial Surgery and Odontostomatology - Director: Prof. A. B. Gianni, University of Milan, Milan, Italy

**Aim:** a young patient G.F., 12 years old female, came to visit at Unit of Orthodontics in Dental Clinic at Policlinico of Milano for an orthodontic evaluation and for a postural evaluation. The patient suffering from congenital left clubfoot was affected by a severe second class malocclusion and by asymmetry of the left hemimandible. The aim of this work is to demonstrate that the role of the orthodontist is crucial to detect the consequences of traumatic injuries in early childhood.

**Methods:** a young patient affected by congenital left clubfoot showed a dimetric left legs and a severe second class malocclusion. The malocclusion consisted of insufficient transversal development of the maxilla, mandibular retrusion and left condyle hypoplasia. A traumatic event could have damaged the regular development of left condyle. The patient underwent to panoramic radiography, cephalometric radiography, CBCT, initial records, cephalometric analysis. The treatment plan consisted of a first phase for orthopedical expansion of maxilla by

means of rapid palatal expander; in the second phase the patient underwent to multibracket appliance for recovering the upper impacted canine, for alignment and leveling of dental elements and at last for correction of sagittal and vertical discrepancy.

**Results:** the orthopedic treatment of maxilla by means of rapid palatal expander and multibracket appliance proved to be an adequate therapeutic strategy to reduce transversal, sagittal and vertical discrepancies in growing patient. It also is mandatory to detect the consequences of traumatic injuries in order to minimize condylar growth defects.

**Conclusion:** the Orthodontist plays a fundamental role in the multidisciplinary team that treats the patient affected by congenital disorder. Infact a careful analysis of the radiographies and an accurate clinical examination of the growing patient can lead to the detection of mandibular asymmetries resulting from a traumatic event.

## THE USE OF A HYBRID APPLIANCE FOR CONTROLLED EXTRUSION MOVEMENT IN THE ESTHETIC ZONE

Ciraolo L., Barbera S., Costa S., Militi A., Portelli M., Nucera R.

Department of Biomedical, Dental and Morphological and Functional Imaging Sciences, University of Messina, Messina, Italy

**Aim:** the demand for orthodontic esthetic appliances increased significantly in recent years for orthodontic treatment involving the esthetic zone.

Currently, the main two orthodontic “esthetic” treatment options are treatment conducted with lingual appliances and aligner orthodontic treatment. Both these two treatments alternative showed some limitations in the case of pure extrusion dental movements.

The extrusion performed with appliances placed on the lingual/palatal side causes an undesirable buccolingual tooth inclination. The extrusion performed with aligners is considered a challenging movement.

The aim of this case report is to propose, for the first time in the orthodontic literature, the use of a hybrid appliance (lingual appliance and aligners) for the extrusion of a central maxillary incisor. The dental element needed to be extruded in order to expose a horizontal rim fracture of the root for further prosthodontic rehabilitation.

**Methods:** the tooth was preliminarily treated with a composite build-up that was extended to the whole new crown of the dental element. Subsequently, impressions were taken, and dental cast models were scanned and digitalized. A treatment set-up was designed with CAD software for aligner production (Maestro 3D, Age Solution, Pisa, IT). The set-up was designed to produce 2mm extrusion on the maxillary incisor, and a set of aligners were designed to create 0.2mm of extrusion every ten 10 days. Digital indirect bonding of lingual 2D appliance was performed planning 2mm of extrusion on the fractured central incisor.

**Results:** the desired extrusion was achieved after two months of treatment avoiding unwanted movements on the adjacent teeth.

**Conclusion:** the use of the hybrid appliance obtained combining aligners and lingual appliances can be helpful to improve treatment results in the esthetic zone avoiding undesired dental movements on the anchorage units.

## VIRTUAL SURGICAL PLANNING IN ORTHOGNATHIC SURGERY

Corvino I.R., Romano M.J., Diana T.

School of Orthodontics Department of Neuroscience, Reproductive Science and Oral Science, University of Naples Federico II, Naples, Italy

**Aim:** our scientific work aims to evaluate the accuracy of the virtual planning made with the Dolphin, Dolphin Imaging and Management Solutions through a superimposition between morphing, expression of virtual planning, and one-year post facial scans through the software CloudCompare Version 2.6.1.

**Methods:** a total of 30 cases were surgically treated for dento-skeletal deformities (19 F, 11 M) 14 had a Class II profile and 16 had a Class III profile. In the light of Cephalometric prediction track were planned and simulated the surgical displacements with the help of Dolphin. For all cases, a superimposition between the morphing expression of the virtual planning and the 1-year post-facial optical scans performed by 3dMDface system has been realized through the software

CloudCompare Version 2.6.1. The comparison between the facial meshes produced a histogram with a Gaussian curve where the C2M distances (approximate distance between the two-point clouds) and the total number of points (count) were reported.

**Results:** out of 30 patients subject to our work in only 5 cases (17%) the average C2M distances were found to be  $> 4$  with a value expressed in mm  $> 2$ , beyond therefore the defined threshold of accuracy. In 25 cases (83%) we obtained results that were perfectly in line with the accuracy threshold.

**Conclusion:** virtual Surgical Planning offers a three-dimensional diagnostic evaluation of hard and soft tissues, the possibility to simulate and pre-visualize for the same clinical case more surgical possibilities.

## USE OF CUSTOMIZED ABUTMENTS FOR BONE-BORNE PALATAL EXPANDER

Costa S., Bellocchio M., Ciancio E., Portelli M., Militi A., Nucera R.

Department of Biomedical, Dental and Morphological and Functional Imaging Sciences, Master's Degree Course in Dentistry and Dental Prosthetics, Teaching of Orthodontics, Prof R. Nucera, University of Messina, Messina, Italy

**Aim:** the use of palatal orthodontic miniscrew and skeletal anchorage improved therapeutic skeletal effects of palatal expansion. Moreover, it modified the indications offering the possibility of suture opening in adolescents at the end of growth and young adults. However, to expand a partially ossified suture require the use of four palatal miniscrew: two miniscrew in the anterior region of the palate and two miniscrew in the posterior maxillary region. This type of skeletal expander was previously defined bone-borne palatal expander. Literature showed the amount of bone in the posterior region decrease dramatically and consequently the miniscrew application within the maxillary bone is not always possible. To overcome these issues some authors proposed a supra-alveolar insertion site in the posterior palatal region. However, this treatment option creates some undercuts that could make difficult the insertion of a bone-borne palatal ex-

pander. The aim of this case report is to propose, for the first time in the orthodontic literature, the use of customized abutments connecting the palatal screw with the palatal miniscrews.

**Methods:** customized abutments were designed with a fully digital workflow and mainly with the Exocad software (Exocad GmbH, Darmstadt, Germany), and were produced with the metal 3D printing produce named SLS (Selective Laser Sintering). Custom abutments were connected to the palatal screw with conventional soldering.

**Results and Conclusion:** the use of customized abutments avoid the presence of undesirable undercuts and offers the advantage of a non-traumatic appliance insertion, ultimately making easier for the clinician the insertion procedure and minimizing the risks of miniscrew failure for traumatic screw load during palatal appliance insertion.

## UPPER ARCH DIMENSIONAL CHANGES WITH ALIGNERS IN EARLY MIXED DENTITION: A PROSPECTIVE STUDY

E. Cretella Lombardo, V. Cantiero, R. Lione

Department of Orthodontics, Head: P. Cozza, University of Rome Tor Vergata, Rome, Italy

**Aim:** the first goal of orthodontic treatment in mixed dentition is to expand the maxillary arch to allow proper tooth alignment and a correction of sagittal and vertical malocclusions. However, treatment protocols are not so clearly described to allow for a standardization of phase I orthodontic treatments. This lack of information makes it difficult for clinicians to define tooth movement, including transverse expansion efficiency of Invisalign® in children. Therefore, the aim of the present study was to evaluate the transverse maxillary arch development with Invisalign First System® in growing subjects.

**Methods:** the study group included 23 subjects (9 females, 14 males, mean age  $9.4 \pm 1.2$  years). Patients were treated non-extraction with Invisalign First System® clear aligners with no other auxiliaries than Invisalign® attachments. Transverse interdental widths were measured only on the upper arch for each model at the start (T1) and at the end (T2) of the treatment. A paired t-test

was chosen to compare T2-T1 changes. The level of significance was set at 5%.

**Results:** the greatest increase of maxillary width was detected at the level of the upper first deciduous molars ( $+3.7 \text{ mm} \pm 1.4 \text{ mm}$ ) ( $P < 0.001$ ), followed by the level of second deciduous molars ( $+3.4 \text{ mm} \pm 1.6 \text{ mm}$ ) ( $P < 0.001$ ) and by the deciduous canine ( $+2.6 \text{ mm} \pm 2.0 \text{ mm}$ ) ( $P < 0.001$ ). Upper first permanent molars showed a greater expansion in the inter-molar mesial width ( $+3.2 \text{ mm} \pm 1.2 \text{ mm}$ ) ( $P < 0.001$ ) than in the inter-molar distal ( $+1.7 \text{ mm} \pm 1.2 \text{ mm}$ ) ( $P < 0.001$ ) and transpalatal width ( $+1.2 \text{ mm} \pm 1.2 \text{ mm}$ ) ( $P < 0.01$ ).

**Conclusion:** the Invisalign First System® can be considered an effective treatment in growing patients who require maxillary arch development. The greatest net increase was detected at the level of upper first deciduous molars whereas the upper first permanent molars showed a greater expansion in the inter-molar mesial width due to a rotation that occurs around its palatal root.

## THE EFFECT OF SURGICAL PROCEDURES ON THE ACCELERATION OF ORTHODONTIC TREATMENT: AN OVERVIEW

De Rosa F., Gasparro R., Bucci R., D'Antò V., Bucci P.

Department of Neuroscience, Reproductive Sciences and Oral Sciences, University of Naples Federico II, Naples, Italy

**Aim:** this overview aimed to summarise the evidence provided by systematic reviews (SRs) on the effect of surgical procedures in the acceleration of tooth movement and to assess the methodological quality of the included SRs.

**Methods:** three electronic databases have been explored up to December 2020. After title and abstract screening, SRs addressing the effects of surgical procedures on the acceleration of tooth movement were included. The methodological quality of the included SRs was assessed using the updated version of "A Measurement Tool to Assess Systematic Review" (AMSTAR-2).

**Results:** twenty-eight (28) SRs were included. The methodological quality of the included reviews ranged between critically low (6 studies) and high (12 studies). The most common critical weakness in the included reviews was the absence of clearly a-prior established review methods and any significant deviations from the protocol. Although the majority of the in-

cluded studies reported a tendency of orthodontic treatment time acceleration using piezocision, corticotomy and micro-osteoperforation, there is a limited amount of low-quality primary evidence concerning the effectiveness of surgical interventions to accelerate orthodontic treatment. However, these techniques are not associated with complications such as loss of tooth vitality, periodontal problems, or severe root resorption.

**Conclusion:** surgically facilitated orthodontic treatment can increase the velocity of tooth movement and shorten treatment duration in healthy orthodontic patients, compared with conventional orthodontics. However, due to the low/critically low quality of primary studies included in SRs supporting these results, minimally invasive surgically accelerated orthodontics cannot currently be recommended in everyday clinical practice.

## ELASTODONTIC THERAPY IN A PATIENT WITH DENTO-SKELETAL CLASS II MALOCCLUSION: A CASE REPORT

Laudadio C.<sup>1</sup>, Patano A.<sup>1</sup>, Malcangi G.<sup>1</sup>, Coloccia G.<sup>1</sup>, Marinelli G.<sup>1</sup>, Limongelli L.<sup>1</sup>, Inchingolo A.D.<sup>1</sup>, Montenegro V.<sup>1</sup>, D'Oria M.T.<sup>1</sup>, Laforgia A.<sup>1</sup>, Dipalma G.<sup>1</sup>, Inchingolo F.<sup>1</sup>, Di Venere D.<sup>1</sup>, Cardarelli F.<sup>1</sup>, Farronato M.<sup>2</sup>, Tartaglia G.<sup>2</sup>

Complex Operative Unit of Odontostomatology, Director: Prof. G. Favia

<sup>1</sup>Specialization School in Orthognatodontics Director Prof. F. Inchingolo, Interdisciplinary Department of Medicine D.I.M. University of Bari Aldo Moro, Bari, Italy

<sup>2</sup>Department of Biomedical, Surgical and Dental Sciences, School of Dentistry, University of Milan, Milan, Italy. UOC Maxillo-Facial Surgery and Dentistry. Fondazione IRCCS Ca' Granda, Ospedale Maggiore Policlinico, Milan, Italy

**Aim:** early treatment with elastodontic A.M.C.O.P. bio-activators allows to eliminate functional disorders and to guide dento-skeletal growth, by using light and biological forces generated by facial muscles activity. The aim of this case report was to illustrate the correction of dento-skeletal class II malocclusion in a patient affected by atypical swallowing during the mixed dentition.

**Methods:** a 11 years-old patient with class II malocclusion associated with altered form of upper lateral incisors (1.2 -2.2) and atypical swallowing was treated with A.M.C.O.P. integral C appliance. No impressions were needed. Patient was instruct-

ed to use the device. The appliance was placed at night for the first year and at alternate night for other one-year.

**Results:** after 13 months of active therapy altered tongue position was corrected and 1.2 and 2.2 form was re-habilitated with veneers. In the fourth year of follow-up patient showed the right stable occlusion due to the myofunctional tongue correction.

**Conclusion:** the early therapy is efficient to restore functional and aesthetical normal occlusion. Elastodontic therapy with A.M.C.O.P. improves facial harmony and simplifies as well as shortens the second orthodontic appliances phase.

## UNILATERAL CROSSBITE TREATED WITH FGB AND EVALUATION OF SPINAL FLEXION: A CASE REPORT

Lombardo L., Sicca N., Cagnotti F., Ventura F., Di Benedetto L., Maticena G., Piacino M.G.

Department of Surgical Sciences, C.I.R. Dental School, University of Turin, Turin, Italy

**Aim:** analysis of lateral spinal curvature and flexion in the frontal plane in a growing patient with right unilateral anterior and posterior crossbite treated with Function Generating Bite (FGB) before and after functional orthognatodontic therapy.

**Methods:** male patient 6.4 years old. The following diagnostic data were collected: medical and dental history, model casts, OPT, L/L, P/A radiographies with relative cephalometric analyzes. It was also registered the spinal curvature in the frontal plane with the use of the Spinal Mouse before and after the correction of the initial malocclusion. The orthodontic therapy was carried out with Function Generating Bite (FGB).

**Results:** before therapy, the patient presented an asymmetrical curvature of the whole spine in the frontal plane with greater flexion on the crossbite side (30.0° left side curvature, 35.1° right side curvature). After 13 months, the right unilateral ante-

rior and posterior crossbite was corrected and there was a significant change in the curvature of the spine with symmetrization of lateral spinal bending in the frontal plane (27.5° left side curvature, 28.3° right side curvature). After functional correction of an asymmetrical malocclusion as unilateral crossbite with Function Generating Bite in a growing patient, the spine curvature of the entire column registered a postural symmetry, showing a general healthier muscular balance.

**Conclusion:** patients with unilateral posterior crossbite showed an asymmetrical body posture. The correction of the malocclusion with the functional appliance FGB induced not only the correction of dental malocclusion but also a symmetric favorable change in the neuromuscular postural control of growing patients, allowing the effective achievement of patients' oral and general health after orthognatodontic therapy.

## USE OF TADS IN INTRUSIVE MECHANICS

Maddalone M., Ferrari M., Bianco E., Mirabelli L., Baldoni M.

Department of Medicine e Surgery, University of Milano-Bicocca, Monza, Italy

**Aim:** the use of mini-screws, for intrusion of lower and upper incisors, offers the possibility to improve the speed of orthodontic treatment. TADs, also offer a safe method to achieve vertical control where posterior teeth don't offer a good bone anchorage. The purpose of this study is to compare advantages of intrusive mechanics with mini-screws or with a traditional method.

**Methods:** we examined 50 patients, aged between 12 and 54 years, who needed an intrusion of lower or upper incisors from 3 to 7 mm. Patients were randomly divided into two groups: 25 treated with utility arch and other 25 treated with continuous arch connected with TADs. All mini-screws had a length of 8 mm to give greater uniformity to the study group. The intrusive force was released through an elastic chain connected to the mini-screw. The head of a TAD has served as a reference point to evaluate speed of intrusion for all 50 patients in the study during the 4 months of examination.

**Results:** in cases treated with utility arch the results showed an average speed of intrusion of 0.9 mm/month. The target of intrusion has not been achieved in 8 cases out of 25. In all cases we had a dislocation of molars with distal tipping. In cases treated with mini-screws the results showed, an average speed of intrusion of 1.3 mm/month. All patients of this group reached intrusive objectives. In 2 cases out of 25 there was loss of the mini-screw. 7 patients showed an inflammatory reaction around the head of the mini-screw, but without lack of stability of the TAD themselves.

**Conclusion:** the process of intrusion using mini-screw technique has proved to be faster and reliable allowing to avoid some common side effects such as distal tipping of the molars. At present TADs can guarantee, in every situation, neutralization of reaction forces and an absolute anchorage. They also allow a sectional approach to the orthodontic treatment.

## THE USE OF AMCOP S INTEGRAL DEVICE IN A GROWING PATIENT WITH MIXED DENTITION: A CASE REPORT

Marinelli G.<sup>1</sup>, Patano A.<sup>1</sup>, Laudadio C.<sup>1</sup>, Malcangi G.<sup>1</sup>, Colocchia G.<sup>1</sup>, Limongelli L.<sup>1</sup>, Inchingolo A.D.<sup>1</sup>, Montenegro V.<sup>1</sup>, D'Oria M.T.<sup>1</sup>, Laforgia A.<sup>1</sup>, Dipalma G.<sup>1</sup>, Inchingolo F.<sup>1</sup>, Di Venere D.<sup>1</sup>, Farronato M.<sup>2</sup>, Tartaglia G.<sup>2</sup>, Cardarelli F.<sup>1</sup>

Complex Operative Unit of Odontostomatology Director: Prof. G. Favia

<sup>1</sup>Specialization School in Orthognatodontics Director Prof. F. Inchingolo, Interdisciplinary Department of Medicine D.I.M. University of Bari Aldo Moro, Bari, Italy

<sup>2</sup>Department of Biomedical, Surgical and Dental Sciences, School of Dentistry, University of Milan. UOC Maxillo-Facial Surgery and Dentistry. Fondazione IRCCS Ca' Granda, Ospedale Maggiore Policlinico, Milan, Italy

**Aim:** AMCOP Bio-Activators are innovative orthodontic devices, made of elastic, heat-activated material capable of solving skeletal, dental and functional problems through the development of light and biological forces. The aim of this work is to demonstrate the ability of these devices to rebalance and re-educate function by creating the conditions for the development of an ideal occlusion in a growing subject.

**Methods:** a 9-year-old female with upper and lower arch contraction, slight left cross-bite, deviated midline, no space for eruptions of 12, 22, 33 and 43, dental misalignment, atypical swallowing, breathing difficulties and recurrent colds was treated for 8 months with the AMCOP S Integral elastodontic

device, applying it every night and 1h during the day followed by an 8-month restraint phase.

**Results:** the plasticity of the skeletal structures during the growth peak allowed to obtain excellent results in a short time: molar and canine bilateral I Class, cross-bite correction, re-centering of the midline, creation of space for the eruption of permanent teeth. The restoration of a correct function of the lips and tongue muscles allowed to obtain a correct dental relationship more stable over time.

**Conclusion:** early treatment of these malocclusions is essential as it is easier to obtain orthopedic effects when the sutures are in an active phase of proliferation.

## THIRD CLASS INTERCEPTIVE THERAPY WITH ELASTODONTIC APPLIANCES: A CASE REPORT

Marinelli G.<sup>1</sup>, Patano A.<sup>1</sup>, Laudadio C.<sup>1</sup>, Malcangi G.<sup>1</sup>, Colocchia G.<sup>1</sup>, Limongelli L.<sup>1</sup>, Inchingolo A.D.<sup>1</sup>, Hazballa D.<sup>1</sup>, Montenegro V.<sup>1</sup>, D'Oria M.T.<sup>1</sup>, Inchingolo A.M.<sup>1</sup>, Dipalma G.<sup>1</sup>, Inchingolo F.<sup>1</sup>, Di Venere D.<sup>1</sup>, Farronato M.<sup>2</sup>, Tartaglia G.<sup>2</sup>, Cardarelli F.<sup>1</sup>

Complex Operative Unit of Odontostomatology Director: Prof. G. Favia

<sup>1</sup>Specialization School in Orthognatodontics Director Prof. F. Inchingolo, Interdisciplinary Department of Medicine D.I.M. University of Bari Aldo Moro, Bari, Italy

<sup>2</sup>Department of Biomedical, Surgical and Dental Sciences, School of Dentistry, University of Milan. UOC Maxillo-Facial Surgery and Dentistry. Fondazione IRCCS Ca' Granda, Ospedale Maggiore Policlinico, Milan, Italy

**Aim:** third class malocclusion associated with atypical swallowing with contraction of the upper arch is complex in therapy and stabilization. Elastodontic therapy is able to influence growth by acting on functional disorders responsible for dental malocclusion. The aim of this study is to demonstrate the ability of AMCOP TC device to intercept this type of malocclusion at an early stage.

**Methods:** a 6.5-year-old male patient with mild skeletal third class and upper maxillary contraction from atypical swallowing is treated with AMCOP TC elastodontic device for 16 months and speech therapy. Then the patient continued to wear the device at alternate nights for 6 months and was revalued after 3 years. At 10 years the case was finalized with AMCOP F elastodontic device with flat chewing plan.

**Results:** after 16 months of AMCOP TC and speech therapy there was an improvement of the skeletal class, resolution of the cross of 11, reduction of the maxillary contraction, but persistence of the lower midline deviation that was then corrected by Integral F which favored the transverse growth of the upper arch and its coordination with the lower.

At the end of the therapy there was also a normalization of the cervical curve.

**Conclusion:** this study demonstrates the therapeutic three-dimensionality of these devices: with Elastodontic therapy it's possible to obtain irreversible skeletal and dental results and at the same time a great postural advantage as can be seen from the comparison of T-LL.

## EFFICIENCY OF THE FACIAL MASK IN THE THERAPY OF CLASSES III: A SYSTEMATIC REVIEW

Nardi N.

Department of Orthodontics, Policlinico Ca' Granda, University of Milan, Milan, Italy

**Aim:** orthopedic therapy with a protraction mask is the most common method for resolving skeletal Class III malocclusions and anterior cross-bite. This kind of therapy, is interesting in cases of Class III malocclusion due to the development of upper jaw, affecting 57% - 67% of Class III dysmorphisms.

After having established that the orthopedic devices are more efficient than the functional ones, the purpose of this review is to evaluate the real efficacy and efficiency of the therapy with a facial mask, associated or not with the use of a palatal expander, in relation to patient compliance.

**Methods:** the review was based on the PRISMA protocol. The research included all the articles published until February 2018 with the keywords: "Class III malocclusion\* AND (facial mask OR Delaire mask OR Petit mask OR protraction head gear OR alt-RAMEC Or maxillary protraction OR reverse occlusion OR chin cup OR Extraoral appliance)" on PubMed, PMC, Scopus, Lilacs, Scielo, Cochrane Trial Library, Web of Science. Inclusion criteria were: clinical trials in humans; Class III skeletal and molar malocclusion; Wits Index  $\leq 2$  mm; anterior crossbite or incisor "head to head" relationship; treatment period which includes a deciduous or mixed dentition; with at least 10 patients analyzed; with at least two times for the longitudinal analysis of one or more groups and with appropriate statistical analysis of the results.

The methodological quality of selected papers was scored, using the "Swedish Council on Technology Assessment in Health Care Criteria for Grading Assessed Studies (SBU) method.

**Results:** with the initial research, we found 3152 articles of which 29 met the inclusion criteria. Of the 29 studies, 8 of them were classified with a high methodological quality, 14 studies showed a moderate quality, while the other 7 were classified as having a low methodological quality. The articles classified as having poor quality were excluded. The results showed that the face mask treatment is effective and efficient for sagittal bone and dental correction.

There has never been a significant improvement in maxillary protraction if it precedes an additional expansion, therefore the transverse palatine expansion has not been improved with sagittal protraction. The use of the alt-RAMEC / FM protocol can improve the biomachine of the Class III therapy, especially if associated with the maximum compliance of the patient.

**Conclusion:** the overall level of the quality of the studies was high, the achievement and maintenance of a short and long term success has depended on many factors.

A further need for more randomized controlled studies was identified especially regarding the new concept of alternating maxillary expansion and compression, which showed a positive influence on the maxillary protraction based on two studies.

## TIMING OF INTERVENTION IN CASE OF ODONTOMA IN THE LOWER FRONTAL REGION

Rende F., Dieni A., Finamore A., Altiglia M., Aiello D.

Department of Health, University Magna Graecia of Catanzaro, Catanzaro, Italy

**Aim:** the aim of this study is to show the need for an early approach in the presence of an odontoma. Odontoma is the most frequent odontogenic tumor of the oral cavity and can result in the failure of the eruption of one or more permanent teeth or be associated with impacted teeth.

**Methods:** Carola and Paolo presented mixed dentitions with various orthodontic problems.

On radiographic examinations, Carola presented at the first examination a retention of permanent central incisor (4.1) accompanied by the presence of an odontoma below the root of

the right deciduous central incisor (8.1) visible also in an old OPT presented by the patient, while Paolo presented an Odontoma above the crowns of the teeth 3.2 and 3.3 in the eruption phase. Carola was not given any surgical treatment to remove the odontogenic lesion, while Paolo received surgical treatment to remove the lesion.

The removal of an Odontoma in growing subjects and with mixed dentition is preferable to conservative treatments to reduce or eliminate the risk of inclusion and ectopy of teeth not yet erupted.

**Results:** at the follow-up a complete eruption of all the dental elements was highlighted in the patient undergoing surgical treatment with removal of the lesion, while in the patient in which no type of treatment was performed to remove the odontoma there was a retention of the right permanent central incisor (4.1).

**Conclusion:** our cases show how early surgical treatment with complete removal of an odontoma in mixed dentition can be an effective approach to reduce the risk of complications such as dental inclusion and/or uncontrolled inclination of permanent elements not yet erupted with respect to a conservative treatment that has not avoided the presence of the aforementioned problems.

## MANDIBULAR GROWTH PREDICTION BASED ON CVM STAGE, GENDER, AND CHRONOLOGICAL AGE

Rutili V., Franchi L., Castiglia D., Paolini E., Giuntini V.

Department of Experimental and Clinical Medicine, University of Florence, Florence, Italy

**Aim:** to develop a prediction model that combines the information derived from chronological age (curvilinear variable), gender, and the cervical vertebral maturation (CVM) method to predict mandibular growth.

**Methods:** 50 subjects (29 females, 21 males) were selected from the AAOF Craniofacial Growth Legacy Collection, the Michigan Growth Study, and the Denver Child Growth study. A total of 456 lateral cephalograms were evaluated. analyzed by applying a mixed effect model. The outcome variable was the annualized increase in total mandibular length (Co-Gn) during the year following the lateral cephalogram on which the cervical stage (CS) and chronological age were assessed. The predictive variables were chronological age up to the fifth order,

gender, stage of CVM, as well as interactions between age and gender, age and CS, and gender and CS. A mixed effect model was applied.

**Results:** significant predictors of annualized increases in total mandibular length were CS, chronological age up to the fourth order, gender, and the interaction between age and gender. The annualized increase in Co-Gn was significantly greater for CS 3 with respect to all other CSs. Annualized increases in Co-Gn for CS 1 and CS 2 were significantly greater when compared to CS 5.

**Conclusion:** mandibular growth can be predicted by combining the information derived from CS, chronological age, and gender. CS 3 exhibited the greatest annualized increase in total mandibular length.

## A SURVEY ON COVID-19 PROFESSIONAL CHALLENGE AMONG SPECIALISTS IN ORTHODONTICS

Pizzetti G.B.<sup>1</sup>, Madeo E.<sup>2,3</sup>, Serafin M.<sup>2,3</sup>, Fastuca R.<sup>2,3</sup>, Tartaglia G.M.<sup>2,3</sup>, Caprioglio A.<sup>2,3</sup>

<sup>1</sup>Private practice, Milan, Italy

<sup>2</sup>Department of Biomedical, Surgical and Dental Sciences, School of Dentistry, University of Milan, Milan, Italy

<sup>3</sup>Fondazione IRCCS Cà Granda, Ospedale Maggiore Policlinico, Milan, Italy

**Aim:** the objective of this study was to survey orthodontic challenges that arose during the COVID-19 pandemic among Italian and international SIDO (Società Italiana di Ortodonzia) members.

An online electronic questionnaire was published on SIDO website. Information as to background data on the orthodontist, patient's management during the lockdown, reopening after the lockdown, management of the dental office were collected.

**Methods:** this was a descriptive, cross-sectional study in which an online questionnaire was distributed to members of

SIDO using a direct link on the SIDO website and/or a personal email with the invitation link to the survey. The survey was anonymous, and it was divided into four parts, for a total of 23 multiple-choice questions. It was available for 2 months, from 15th July until 15th September 2020. The survey was administered, and results collected using Toluna QuickSurveys. Descriptive analysis was performed on the collected data.

**Results:** there were 352 Italian respondents and 76 international respondents. For both Italian and international members, the most frequently observed orthodontic emergencies were linked to the multi-bracket appliance (46%). Concerning

the management of the dental office, the majority of the participants did not increase the costs of the therapies (91%), and a high percentage will maintain all the hygienic procedures adopted for COVID-19 even after the pandemics (67%).

**Conclusion:** the majority of the SIDO members will maintain the new hygienic procedures even after the pandemics, for the

moment there was not an increase in the cost of the therapy for the patient.

The appliance that caused most of the urgencies in the dental office was the multi-bracket one, so it would be useful to explain to the patient how the urgencies could be managed at home.

## OCCLUSAL PLANE CHANGES AFTER MOLAR DISTALIZATION WITH PENDULUM IN CLASS II PATIENTS

Serafin M.<sup>1,2</sup>, Giamboi S.<sup>1,2</sup>, Dolci C.<sup>1,2</sup>, Boccalari E.<sup>1,2</sup>, Fastuca R.<sup>1,2</sup>, Tartaglia G.M.<sup>1,2</sup>, Caprioglio A.<sup>1,2</sup>

<sup>1</sup>Department of Biomedical, Surgical and Dental Sciences, School of Dentistry, University of Milan, Milan, Italy

<sup>2</sup>Fondazione IRCCS Cà Granda, Ospedale Maggiore Policlinico, Milan, Italy

**Aim:** this study aimed to evaluate the skeletal and dental changes after distalization with a Pendulum appliance in growing patients with Class II malocclusion, focusing on the occlusal plane (OP).

**Methods:** the sample included 24 patients with Class II malocclusion (10 boys, 14 girls); their mean age was 12.1 years. All patients underwent molar distalization and had two serial cephalograms traced at baseline (T1) and after molar distalization (T2). Angular and linear dental changes were calculated by taking the Sella-Nasion (SN), Palatal Plane (PP), and Pterygoid Vertical as reference. OP inclination was compared with SN, PP, and Mandibular Plane (MP). The collected data were computed for all the tested variables, and one-way paired t-test was used to assess the significance of the differences between the time points.  $\alpha$  was set at 0.05. Multiple linear regressions were used to predict the OP changes.

**Results:** the mean total treatment time was  $8 \pm 2$  months to obtain a super Class I molar relationship. In T1-T2 interval, statistically significant incisor buccal tipping of  $5^\circ \pm 3.6^\circ$  ( $p < 0.05$ ), first molar distal tipping of  $8.9^\circ \pm 8.3^\circ$  ( $p < 0.001$ ), and second molar tipping of  $8.2^\circ \pm 8.1^\circ$  ( $p < 0.001$ ) were observed. The maxillary first and second molars moved significantly backward by  $2.8 \pm 3.2$  mm ( $p < 0.05$ ) and  $3.7 \pm 2.7$  mm ( $p < 0.001$ ), respectively. Only the premolars showed a statistically significant anchorage loss of  $2.7 \pm 3.3$  mm ( $p < 0.05$ ); overjet increased significantly at  $1.3 \pm 1.2$  mm ( $p < 0.05$ ). Regarding the OP, none of the tested variables showed any statistically significant changes between T1-T2.

**Conclusion:** the Pendulum appliance showed efficacy in distalizing the maxillary first and second molars at the expense of anterior anchorage loss. The OP did not show statistically significant changes after molar distalization.

## UNILATERAL CROSSBITE TREATED WITH FGB AND EVALUATION OF POSTURAL STABILITY: A CASE REPORT

Sicca N., Cagnotti F., Lombardo L., Ventura F., Di Benedetto L., Maticena G., Piancino M.G.

Department of Surgical Sciences, C.I.R. Dental School, University of Turin, Turin, Italy

**Aim:** analysis of postural stability in a case of right unilateral anterior and posterior crossbite treated with Function Generating Bite, using stabilometric platform before and after functional orthognatodontic therapy.

**Methods:** female patient 12.1 years old. The following diagnostic data were collected: medical and dental history, model casts, OPT, L/L, P/A radiographies with relative cephalometric analyzes. It was also registered postural balance with the use of Lizard

stabilometric platform before and after the correction of the malocclusion. The following stabilometric measurements were considered: weight distribution on foot area, speed of body sway, right and left center of gravity, expended energy.

Tests were performed for 51,2 seconds under two occlusal conditions: teeth in maximal intercuspal position (MI) and in rest position without dental contacts (RP). The functional orthodontic therapy was carried out with Function Generating Bite (FGB).

**Results:** before therapy, the patient presented significant differences in weight distribution and in body sway speed between the two conditions MI/RP.

It was registered an increased instability and effort of the tonic postural system in maximal intercuspal position. It was registered also asymmetrical weight distribution and foot pressure in the frontal plane.

After 8 months, the right unilateral anterior and posterior cross-bite was corrected with Function Generating Bite and there

was a significant change in the postural stabilometric features with symmetrization of the all stabilometric measurements, reduced energy expenditure needed to keep the body upright and greater stability of the entire spine.

**Conclusion:** functional orthodontic therapy with Function Generating bite was not limited to the only correction of the dental malocclusion, but in growing patients induced also a symmetric change in the neuromuscular postural control, allowing a better postural stability and general balance.

## TREATMENT OF MODERATE OBSTRUCTIVE SLEEP APNEA WITH IMYS

Suriano C., Cazzolla A.P., Guida L., Illuzzi G., Laurenziello M., Ciavarella D.

Department of Clinical and Experimental Medicine, University of Foggia, Foggia, Italy

**Aim:** the purpose of this study was to investigate the effectiveness of a mandibular advancement device (MAD) called IMYS (It Make You Sleep) for treatment of moderate obstructive sleep apnea (OSAS) in an adult population.

**Methods:** a total of 15 patients (13 males and 2 females) with mean age 51.1 years (SD 3.1) were treated with overnight MAD: an initial mandibular advancement of 70% of the possible protrusive movement was set. Every 20 days the therapeutic mandibular protrusion was adjusted in order to achieve a final mandibular advancement of 100%. At baseline patients were assessed by PSG (Polysomnography) and DISE (Drug induced Sleep Endoscopy). Three months later the polysomnographic exam was repeated.

The following variable were assessed: AHI, SpO<sub>2</sub> (mean) and NADIR.

Student's t-test was used for evaluating data.

**Results:** reductions from 27,62 to 6,893 in AHI ( $p < 0,05$ ) were observed after IMYS use in moderate OSA patients and treatment success was defined as a  $> 60\%$  reduction in the AHI with a residual AHI  $< 7\%$ .

NADIR increased from 76,00 to 81,20 ( $p < 0,05$ ). The other index showed no statistically significant difference.

**Conclusion:** the MAD of this study (IMYS) was effective in increasing NADIR and in reducing the AHI value below 7 (statistically significant difference) in patients with moderate OSAS.

## CAUSES OF MAXILLARY CANINE IMPACTION

Tripicchio C., Vella M., Butti A., Calò A.

Department of Biomedical, Surgical and Dental Sciences, IRCCS Ca' Granda Foundation, Ospedale Maggiore Policlinico, University of Milan, Milan, Italy

**Aim:** the aim of this study is reviewing the etiology of impaction of maxillary permanent canines, and analyzing the relationship between environmental and genetic factors that influence the impaction.

**Methods:** a search on the main electronic databases as PubMed, Chocrane library, Medline was performed. Reviews published from 2010 to 2020 were selected.

**Results:** alteration of the environment, close to the unerupted maxillary canine, can cause the tooth impaction, but its elimination often outcomes in complete resolution.

Creating space, by anteroposterior or lateral expansion, by extraction of teeth, and by uprighting premolar or incisor roots, is

effective in redirecting the eruption path of an errant canine. The timing discrepancy that is seen in the normal development of neighbour teeth has been shown to be linked with canine impaction.

The morphological anomalies of the lateral incisor are often correlated with the inclusion of the adjacent canine, while in cases of absence of the lateral incisor it is very likely that impaction of the canine will not occur.

**Conclusion:** the evidence points out that the that eruption of the canine is influenced by environmental factors. The identification of the genetic factor as the fundamental cause of canine impaction appears to be unjustified.

## ATYPICAL SWALLOWING: ANALYSIS OF LITERATURE

Tripicchio C., Vella M., Butti A., Calò A.

Department of Biomedical, Surgical and Dental Sciences, IRCCS Ca' Granda Foundation, Ospedale Maggiore Policlinico, University of Milan, Milan, Italy

**Aim:** atypical swallowing is a myofunctional problem due by a failed transition from the childhood swallowing mechanism model to the adult one, thus, resulting in the persistence of a childlike deglutition mechanism. The aim of this review is to understand the connection between atypical swallowing and malocclusion and, also, the therapy to solve it.

**Methods:** a review has been done examining all the documents since 2000 to 2020 on PubMed Medline database, using the keywords: "atypical swallowing" and "tongue thrust".

**Results:** most authors assert that this habit is a risk factor for tooth displacement and for the alteration of the mimic and mastication muscles. Others, state that the altered morpho-functional development of the stomatognathic apparatus is

not caused by atypical shallowing, instead the tongue posture alteration would be the results of a physical defect, thus, it would be a compensation mechanism to overcome a pre-existing structural anomaly.

Some case reports prove how atypical swallowing could complicate or prevent the progress of an orthodontic treatment. The 35% of the studies underline that this problem needs a multidisciplinary treatment.

**Conclusion:** the relationship between oral habits and malocclusion can be define biunique. The best therapeutic treatment consists in orthodontic and myofunctional rehabilitation procedures. It is also proved that an early diagnosis and intervention have a positive influence on the therapy outcomes.

## TSME: VERTICAL AND SAGITTAL EFFECTS IN CLASS I, II, III SUBJECTS

Tripicchio C., Vella M., Butti A., Calò A.

Department of Biomedical, Surgical and Dental Sciences, IRCCS Ca' Granda Foundation, Ospedale Maggiore Policlinico, University of Milan, Milan, Italy

**Aim:** the aim of the study is to evaluate if treatment with Transverse Sagittal Maxillary Expander (TSME) can produce skeletal changes with beneficial effects in skeletal class I, II, III growing patients.

**Methods:** in this study were considered three groups of patients: 15 skeletal class I subjects, 15 skeletal class II subjects, 15 skeletal class III subjects.

The sample included 45 growing patients with maxillary bilateral cross-bite in mixed or permanent dentition. For each patient, a lateral cephalogram was taken before treatment (T0) and a second one was taken at the end of the retention period (T1) with the aim to compare the cephalometric values and to show the changes.

**Results:** the cephalometric values showed significant changes comparing T0 and T1 analysis. In each groups TSME produced significant modifications of SNP-A, I<sup>^</sup>SN, I<sup>^</sup>FH, SN-SNP. SNA angle showed a statistically significant increase; SNA angle increased significantly in class I and III patients. SNB angle increased meaningfully in class II patients and decreased in class III patients. In class II patients, ANB angle decreased, while in class III patients, it increased. No remarkable differences were found in the anterior vertical dimension. The posterior vertical dimension remained stable in classes I and III and increased in class II.

**Conclusion:** TSME is a fixed device designed for transvers and antero-posterior arch development; its use has beneficial effects in all skeletal classes, with good vertical and sagittal results.

## EFFECT OF TOPICAL ALENDRONATE IN PERIODONTAL DEFECTS: SYSTEMATIC REVIEW AND META-ANALYSIS

Arena C.<sup>1</sup>, Zhurakivska K.<sup>1</sup>, Caponio V. C. A.<sup>1</sup>, Lo Russo L.<sup>1</sup>, Mauceri R.<sup>2</sup>, Mascitti M.<sup>3</sup>, Lo Muzio E.<sup>4</sup>, Panzarella V.<sup>2</sup>, Troiano G.<sup>1</sup>

<sup>1</sup>Department of Clinical and Experimental Medicine, University of Foggia, Foggia, Italy

<sup>2</sup>Sector of Oral Medicine, Department of Surgical, Oncological, and Oral Sciences (DiChirOnS), University of Palermo, Palermo, Italy

<sup>3</sup>Department of Clinical Specialistic and Dental Sciences, Marche Polytechnic University, Ancona, Italy

<sup>4</sup>School of Orthodontics, University of Ferrara, Ferrara, Italy

**Aim:** considering the emerging role of host-inflammatory response in treatment of periodontitis and the antiresorptive and osteostimulative properties of bisphosphonates several studies are focusing their attention on the role of alendronate as an adjunctive to non-surgical periodontal therapy.

This systematic review and meta-analysis aimed to investigate the role of alendronate combined with NSPT in reducing probing pocket depth, improving clinical attachment level and reducing bone defect depth in periodontal intraosseous defects.

**Methods:** RCTs with more than 6 months follow-up were included in this study. Risk of bias assessment was performed

using the Cochrane collaboration tool. In addition, meta-analysis and trial sequential analysis were used to aggregate the available evidences.

**Results:** seven studies met the inclusion criteria and were included in the systematic review. All the included studies were RCTs comparing the combination therapy of SRP+Alendronate gel 1% (test group) with SRP alone (control group). Topical application of alendronate in addition to NSPT significantly improved PD and CAL.

**Conclusion:** local application of alendronate may confer a beneficial effect in combination with NSPT even if long term studies are needed to confirm these results.

## CORONALLY ADVANCED FLAP TECHNIQUE FOR THE TREATMENT OF MULTIPLE RECESSION

Butti A., Guerrieri P., Vella M., Rossi F., Calò A., Porro A.

Department of Biomedical, Surgical and Orthodontic Sciences, University of Milan, Milan, Italy

**Aim:** the creation of a coronally advanced flap is the gold standard treatment in case of a multiple gingival recessions. This surgical approach allows to have a multiple root coverage using the keratinized tissue that the patients already presents, positioned it apically to the recession.

**Methods:** a 45 years old patient reports strong pain symptomatology and aesthetic request related to recessions on elements 16, 15, 13. The creation of the flap begins by creating oblique paramarginal incisions that should converging to the fulcrum tooth, that is the axis of rotation around which the flap rotates and displaces coronally.

The oblique incision allows the apex of each surgical papilla to be moved correctly to the apex of the corresponding anatomical papilla. The flap in the region of the marginal gingival tissue

is full thickness instead at the apical level the detachment is at partial thickness. Is necessary the disepithelialization of the anatomical papillae, in order to create a periosteum bed to receive the surgical papillae.

suture allows the anchoring of surgical papillae to the underlying connective interdental beds.

**Results:** from clinical re-evaluation, done one year after the surgery, is evident how the keratinized displaced coronal tissue has remained stable over time and has increased in terms of volume and crown-peak amplitude without leaving unsightly scarring results.

**Conclusion:** in case a clinician has to deal with multiple recessions the coronally advanced flap can be considered adequate and satisfactory with a good outcome after a year.

## LOCALLY DELIVERED STATINS AS ADJUNCTIVE TREATMENT FOR PERIODONTITIS

Cecoro G.<sup>1</sup>, Piccirillo A.<sup>1</sup>, Martuscelli G.<sup>1</sup>, del Fabbro M.<sup>2</sup>, Annunziata M.<sup>1</sup>, Guida L.<sup>1</sup>

<sup>1</sup>Department of Medical-Surgical and Dental Specialties, University of Campania Luigi Vanvitelli, Caserta, Italy

<sup>2</sup>Department of Biomedical, Surgical and Dental Sciences, University of Milan, Milan, Italy

**Aim:** the present systematic review and meta-analysis aimed to assess the efficacy of locally delivered statins used in adjunct to scaling and root planing (SRP) compared with SRP alone.

**Methods:** the study protocol was registered in PROSPERO (CRD42020181742) and the search strategy used in this systematic review was based on the PRISMA guidelines. After electronic and hand search, only randomized controlled trials (RCTs) were included. Clinical attachment level gain (CALgain), probing depth reduction (PDred), modified sulcular bleeding index reduction (mSBIred) and intrabony defect reduction (IBDred) were the investigated outcomes. The quality of the included studies was assessed using the Cochrane Risk of Bias Tool for RCTs (RoB 2). Meta-analysis was performed and the power of the meta-analytic findings determined by trial sequential analysis (TSA). Studies were also sub-grouped basing on the type of statin used. Statistical heterogeneity and publication bias were assessed.

**Results:** twenty RCTs were included (1212 patients, 1289 defects). An overall statistically significant effect size in favour of statins for CALgain ( $P = .002$ ) and PDred ( $P = .000$ ) was found. Differently from atorvastatin and rosuvastatin, simvastatin did not reach statistical significance for these outcomes. TSA confirmed that the meta-analysis had sufficient power to detect the beneficial effect of statins over the control treatment for these outcomes.

**Conclusion:** within the limits of the available studies, the local administration of statins in adjunct to SRP might add significant improvement in terms of CALgain and PDred compared with SRP alone. The high data heterogeneity, however, imposes caution. No approved preparations exist, and further well-designed RCTs would be needed to confirm the beneficial effects of the different types of statins in the non surgical treatment of the periodontitis.

## EFFICACY OF SUBGINGIVAL AIR-POLISHING WITH ERYTHRITOL POWDER IN PERIODONTAL DISEASE

Mensi M.<sup>1</sup>, Scotti E.<sup>1</sup>, Sordillo A.<sup>1</sup>, Calza S.<sup>1</sup>, Guarnelli M.E.<sup>2</sup>, Fabbri C.<sup>2</sup>, Farina R.<sup>2</sup>, Trombelli L.<sup>2</sup>

<sup>1</sup>Department of Surgical Specialties, Radiological Science and Public Health, University of Brescia, Brescia, Italy

<sup>2</sup>Department of Molecular and Translational Medicine, University of Brescia, Brescia, Italy

<sup>3</sup>Research Centre for the Study of Periodontal and Peri-Implant Diseases, University of Ferrara, Ferrara, Italy

**Aim:** to date, scarce evidence exists around the application of subgingival air polishing during treatment of severe periodontitis. The aim of this study was to evaluate the benefits of subgingival air polishing during non-surgical treatment of deep bleeding pockets in stages III–IV periodontitis patients.

**Methods:** forty patients with stages III–IV periodontitis were included, and pockets with probing depth (PD) 5–9 mm and bleeding on probing (BoP) were selected as experimental sites. All patients underwent a full-mouth session of erythritol powder supragingival air polishing and ultrasonic instrumentation. Test group received additional subgingival air polishing at experimental sites. The proportion of experimental sites shifting to  $PD \leq 4$  mm in absence of BoP at 3 months (i.e., non-bleeding closed pockets, NBCPs) was regarded as the primary outcome variable.

**Results:** the proportion of NBCP was comparable between test and control group (47.9 and 44.7%, respectively). Baseline PD of 7–9 mm, multi-rooted teeth and the presence of plaque negatively influenced the probability of obtaining NBCP.

**Conclusion:** the additional application of subgingival air polishing does not seem to provide any significant clinical advantage in achieving closure at moderate to deep bleeding pockets in treatment of stages III–IV periodontitis patients. The study was registered on ClinicalTrials.gov (NCT04264624). Clinical relevance While air polishing can play a role in biofilm removal at supragingival and shallow sites, ultrasonic root surface debridement alone is still the choice for non-surgical treatment of deep bleeding periodontal pockets.

## LATERAL APPROACH OF THE MULTIPLE BILAMINAR TECHNIQUE

Guerrieri P., Vella M., Rossi F., Calò A., Porro A., Butti A., Tripicchio C.

Department of Biomedical, Surgical and Dental Sciences, University of Milan, Milan, Italy

**Aim:** usually, root coverage in presence of multiple lateral recessions in the lower arch can be a practical problem for the clinician. The aim of this study is describing a therapeutic approach using a bilaminar technique with lateral approach could be a remarkable solution.

**Methods:** the treatment plan consists in a mucogingival surgery made through the creation of a coronally advanced flap associated with the insertion of two connective grafts. From the first molar to the canine all the incisions are executed par-amarginal, oblique and convergent towards the line that passes in the centre of the buccal surface of the canine. A vertical incision is made mesially to the canine and reaches the alveolar mucosa. Subsequently, the epithelium-connective soft tissues of the flap are separated from the structures through a

superficial incision that runs parallel to the mucous plane. Connectival grafts are sutured to the periosteum bed using re-absorbable sutures.

**Results:** clinically, after five months from the surgery, it is evident how a good looking band of keratinized tissue developed on the buccal-apical side of elements 46,45,44 and how it remained ensuring a good camouflage of the treated area in terms of colour and thickness, compared to adjacent soft tissues.

**Conclusion:** root covering in presence of multiple lateral recessions in the lower arch with inadequate apical amount of keratinized tissue, using a bilaminar technique with a coronal advanced flap, with mesial release incision and insertion of two connective grafts it can be considered.

## MULTIPLE CORONALLY ADVANCED FLAP WITH CONNECTIVE TISSUE GRAFT TO TREAT GINGIVAL RECESSIONS

Lubrano M.R., Cernera M., Cafasso M., Armogida N.G., Vaia E.

Department of Neuroscience and Reproductive and Odontostomatological Sciences, University of Naples Federico II, Naples, Italy

**Aim:** gingival recessions (GRs) are apical migrations of the gingival margin beyond the CEJ. They can create discomfort to the patient, especially in the aesthetic area, thus they could require a surgical treatment. This case describes the treatment of multiple recessions with a Coronally Advanced Flap (CAF) and a Connective Tissue Graft (CTG).

**Methods:** a 40 y.o. non-smoker man, in good systemic health, came to our attention complaining an aesthetic discomfort due to 3 mm and 2 mm gingival recessions on 2.1 and 2.2 respectively. We opted for a multiple CAF with CTG. Flap design consisted in an incision of surgical papillae on rec+1mm from the tip of the papilla and two beveled releasing incisions. Surgical papillae were elevated with a split-thickness up to the recession.

Then, we set up a full-thickness flap, periosteum incision and a deep split-thickness for 1 mm. A CTG was harvested from the palate and then sutured to the de-epithelialized papillae. Flap was coronally advanced and sutured by sling and single sutures.

**Results:** two weeks after the surgery, in presence of an early healing of the tissue, sutures were removed. At one month, it was possible to observe a complete healing but a partial maturation of the soft tissues that would be complete after one year. A completely root coverage was obtained and the patient was satisfied with the results.

**Conclusion:** this technique has proven to be effective to treat multiple GR in aesthetic areas. The addition of a CTG improves the stability of gingival margins after years.

## GLUCOSE AND HBA1C BLOOD LEVELS IN PERIODONTITIS: A SYSTEMATIC REVIEW AND META-ANALYSIS

Marhl U., Perić M., Ceretto D., Gennai S., Izzetti R., Nisi M., Graziani F.

Department of Surgical, Medical and Molecular Pathology and Critical Care Medicine, University of Pisa, Pisa, Italy; Sub-Unit of Periodontology, Halitosis and Periodontal Medicine, University Hospital of Pisa, Pisa, Italy

**Aim:** to assess the effects of periodontitis (PD) on glucose (Glu) and glycated haemoglobin (HbA1c) blood levels in patients with or without comorbidities.

**Methods:** observational studies, evaluating systemic blood biomarkers and periodontitis were searched by electronic databases and relevant hand-searched journals to answer the following PICO question: *Do subjects with periodontitis have elevated blood values of systemic inflammatory biomarkers when compared to controls without periodontitis?* The protocol was registered at PROSPERO (CRD42019118831). Findings were summarized in evidence tables according to the PRISMA statement.

The quality assessment of included studies was assessed using NOS for case-control and cohort studies, and modified NOS for cross-sectional studies.

**Results:** a total of 712 results was identified. After screening of titles and abstracts and further full-text analysis, 629 citations were excluded. The final 83 articles were analyzed for methodological quality and availability of data for meta-analysis. Finally, 4 studies met the inclusion criteria in assessing the blood levels of HbA1c and 5 studies assessed Glu levels. The overall HbA1c level in subjects with PD was 5.58% (95% CI, 5.49 to 5.67). The overall Glu level in subjects with PD was 94.42mg/dL (95% CI, 89.50 to 99.33). The Glu blood levels in the subgroup without comorbidities was 84.90mg/dL (95% CI, 78.02 to 91.78), and 103.03mg/dL (95% CI, 95.36 to 110.69) in the subgroup with comorbidities.

**Conclusion:** patients with PD have elevated glucose and HBA1c levels, respectively. Therefore, the importance of periodontal care should be further promoted, especially in patients with comorbidities.

## FUNCTIONALIZED NANOFIBERS TO REGENERATE ORAL MUCOSA: AN IN VITRO STUDY ON GINGIVAL STEM CELLS

Meroni S.<sup>1</sup>, Canciani E.<sup>1</sup>, Paino F.<sup>1</sup>, Denti L.<sup>2</sup>, Henin D.<sup>1</sup>, Amler E.<sup>3</sup>, Gagliano N.<sup>2</sup>, Dellavia C.<sup>1</sup>

<sup>1</sup>Department of Biomedical, Surgical and Dental Sciences, University of Milan, Milan, Italy

<sup>2</sup>Department of Biomedical Sciences for Health, University of Milan, Milan, Italy

<sup>3</sup>UCEEB, Czech Technical University, Trinecka, Bustehrad, Czech Republic

**Aim:** to analyze the effects of polycaprolactone (PCL) nanofibers enriched with hyaluronic acid (HA) on human mesenchymal stromal cells isolated from gingival interdental papilla (GinPa-MSCs) for periodontal soft tissue regeneration purposes.

**Methods:** nanofibers were produced in PCL (NF) or PCL enriched with HA (NFE) by electrospinning technology, using Nanospider TM device (Elmarco, Czech Republic). NF and NFE were then stereologically and morphologically characterized by means of a JCM-6000 Neoscope™ Scanning Electron Microscope (SEM) (JEOL-Nikon, Japan).

GinPa-MSCs were obtained from gingival tissue fragments and then seeded on NF and NFE and on plastic (CT). After 24 hours from seeding, cell adhesion and morphology were evaluated using SEM. Also, after 24, 48 and 72 hours from seeding, cell viability was assessed by Alamar Blue® assay (Thermo

Fisher Scientific, Waltham, MA), determining the % variations of cells proliferation in contact with NF and NFE in relation to CT proliferation. Mean ± standard deviation was computed.

**Results:** NF and NFE demonstrated the following stereological features: diameter range between 0.30-2.08 µm for NF vs 0.60-3.02 µm for NFE. Diameter of NFE was increased by 30% compared with NF. At 24 hours GinPa-MSCs adhered on NF and NFE conserving fibroblast like morphology and extending their cytoplasmatic protrusions as to build a network. GinPa-MSCs were not impeded by the presence of NF and NFE. After a slight reduction of viability observed between 24 and 48 hours, at 72 hours GinPa-MSCs proliferated more than CT.

**Conclusion:** these preliminary in vitro findings suggest that NFE could represent a device to stimulate GinPa-MSCs to increase their proliferation and adhesion and thus favour gingival connective tissue restoration.

## NON-SURGICAL TREATMENT OF PERI-IMPLANT MUCOSITIS: A SYSTEMATIC REVIEW AND META-ANALYSIS

Minoli M.<sup>1</sup>, Clementini M.<sup>1</sup>, Pioli M.C.<sup>2</sup>, Albanesi S.<sup>2</sup>, Gennai S.<sup>2</sup>, Graziani F.<sup>2</sup>, De Sanctis M.<sup>1</sup>

<sup>1</sup> Department of Periodontology, Vita-Salute San Raffaele University, Milan, Italy

<sup>2</sup> Department of Surgical, Medical and Molecular Pathology and Critical Care Medicine, University of Pisa, Pisa, Italy; Sub-Unit of Periodontology, Halitosis and Periodontal Medicine, University Hospital of Pisa, Pisa, Italy

**Aim:** to assess the clinical performance of non-surgical treatment of peri-implant mucositis (PM) in terms of probing pocket depth reduction (PPD) and bleeding on probing (BoP).

**Methods:** RCTs on PM treatment with at least 10 subjects per group and 6 months follow-up were identified through electronic databases (PubMed, CENTRAL, and Embase) and hand-searched journals (until October 2020). According to the PRISMA (Preferred Reporting Items for Systematic Review and Meta-Analyses) statement, a detailed protocol was developed and registered on PROSPERO (CRD42021226653). The systematic review was designed to answer to the following focused question: "What is the performance of non-surgical

treatment of peri-implant mucositis in terms of PPD and BoP, 6 months after treatment?"

**Results:** 11 RCTs met the inclusion criteria (421 patients, 689 implants) and 8 were included in the meta-analysis (328 patients, 528 implants). The overall weighted mean differences (WMD) implant-based and subject-based for PPD reduction were 0.35 mm (CI:[0.09, 0.61],  $p < 0.01$ ) and 0.42 mm (CI:[0.17, 0.68],  $p < 0.01$ ) respectively. The overall WMD implant-based and subject-based for BoP reduction were 18.47% (CI:[13.23, 23.70],  $p < 0.01$ ) and 29.52% (CI:[24.93, 34.11],  $p < 0.01$ ) respectively.

**Conclusion:** non-surgical treatment of PM showed a significant reduction of PPD and BoP after 6 months follow-up.

## THE ADJUNCTIVE EFFECT OF AIR ABRASIVE DEVICE FOR THE TREATMENT OF PERI-IMPLANT MUCOSITIS

Mirra R., Marruganti C., Ciocci C., Belcari B., Discepoli N.

Department of Periodontics, University of Siena, Siena, Italy

**Aim:** the aim of this randomized clinical trial is to assess the adjunctive effect of an air abrasive device to the conventional mechanical treatment of peri-implant mucositis.

**Methods:** individuals diagnosed with peri-implant mucositis were consecutively enrolled. Full-mouth periodontal evaluation together with intraoral radiographs were recorded at baseline (T0) by a single calibrated examiner. The treatment consisted in a full mouth ultrasonic debridement (FMUD) approach, with the use of a specific PEEK tip for experimental implants (T7). At the end of this session a sealed envelope containing the treatment allocation was opened: implants belonging to the test group were additionally treated with an air abrasive device. All treatments were performed by the same experienced operator. Individually tailored oral hygiene instruction were delivered at T7 and every month until the end of

the experimental period that was scheduled at 3 months (T3M) after the non surgical procedure. Clinical variables were again recorded at this time (T3M) by the same examiner and the implant was chosen as experimental unit.

**Results:** to the date, 8 patients (2 control; 6 test) with 23 experimental implants were included. No differences were detected at baseline between test and control implants, except for the number of bleeding sites ( $p = 0,014$ ). After three months implant pocket depth decreased in both group, whereas bleeding sites decreased significantly only for the control group ( $p=0,027$ ).

**Conclusion:** within the limitations of the current protocol non surgical peri-implant therapy (NSPIT) positively affect the clinical conditions on both groups after 3 months of healing. Further inclusions are needed to reach the programmed sample size.

## GUIDED TISSUE REGENERATION OF AN EXTENDED ENDO-PERIO LESION: A CASE REPORT

Muwalla M., Iaderosa G., Squillace E., Romano F., Citterio F., Baima G., Mariani G. M., Aimetti M.

Department of Surgical Sciences, C.I.R. Dental School, University of Turin, Turin, Italy

**Aim:** teeth with combined endodontic and periodontal lesion represent a challenge for many general practitioners. These teeth are usually considered hopeless due to the complex and multidisciplinary treatment approach. The aim of this case report was to evaluate the long term outcome of a tooth with endo-perio lesion after successful endodontic and periodontal regenerative therapy.

**Methods:** a 61 years old patient diagnosed with a stage III grade B generalized periodontitis presenting a combined endodontic-periodontal lesion all around the apex of the element 4.3 was included in the study. After splinting the tooth, endodontic and nonsurgical periodontal treatment were performed by a skilled clinician. Three months later, following the healing of the periapical lesion, periodontal regeneration was per-

formed with the application of amelogenin, bone substitute and resorbable membrane fixed using pins. Thereafter, the patient was placed in a strict maintenance protocol.

**Results:** after a follow-up of 2 years, it was possible to appreciate a radiographic bone fill combined with a remineralization of the defect. New clinical attachment was achieved, with no residual pathological pocket, no bleeding on probing and minimal gingival recession. The tooth presented no residual mobility after the removal of the splinting.

**Conclusion:** this case report demonstrated that is possible to change the long term outcome of an hopeless tooth and proved the biological potential of a severe endodontic-periodontal lesion treated by guided tissue regeneration.

## NON-SURGICAL TREATMENT OF PERI-IMPLANTITIS: A SYSTEMATIC REVIEW AND META-ANALYSIS

Gennai S.<sup>2</sup>, Pioli M.C.<sup>2</sup>, Clementini M.<sup>1</sup>, Minoli M.<sup>1</sup>, Izzetti R.<sup>2</sup>, Nisi M.<sup>2</sup>, De Sanctis M.<sup>1</sup>, Graziani F.<sup>2</sup>

<sup>1</sup> Department of Periodontology, Vita-Salute San Raffaele University, Milan, Italy

<sup>2</sup> Department of Surgical, Medical and Molecular Pathology and Critical Care Medicine, University of Pisa, Pisa, Italy; Sub-Unit of Periodontology, Halitosis and Periodontal Medicine, University Hospital of Pisa, Pisa, Italy

**Aim:** to assess the clinical performance of non-surgical treatment of peri-implantitis (PI) in terms of probing pocket depth reduction (PPD) and bleeding on probing (BoP).

**Methods:** RCTs on PI treatment with at least 10 subjects per group and 6 months follow-up were identified through electronic databases (PubMed, CENTRAL and Embase) and hand-searched journals (until October 2020). According to the PRISMA (Preferred Reporting Items for Systematic Review and Meta-Analyses) statement, a detailed protocol was designed and registered on PROSPERO (CRD42021226653). The systematic review was designed to answer the following focused question:

“What is the performance of non-surgical treatment of peri-implantitis in terms of PPD, BoP, 6 months after treatment?”

**Results:** 12 trials met the inclusion criteria (449 patients, 811 implants). The overall weighted mean differences (WMD) implant-based and subject-based for PPD reduction were 0.44 mm (CI:[0.15, 0.72],  $p < 0.01$ ) and 0.60 mm (CI:[0.21, 0.99],  $p < 0.01$ ) respectively. The overall WMD implant-based and subject-based for BoP reduction were 27.82% (CI:[10.49, 45.15],  $p < 0.01$ ) and 27.51% (CI:[12.37, 42.65],  $p < 0.01$ ) respectively.

**Conclusion:** non-surgical treatment of PI showed a significant reduction of PPD and BoP after 6 months follow-up.

## CASE REPORT OF A Laterally and Coronally Advanced Flap

Porro A., Butti A., Vella M., Guerrieri P., Rossi F., Calò A., Tripicchio C.

Department of Biomedical, Surgical and Dental Sciences, University of Milan, Milan, Italy

**Aim:** laterally and coronally advanced flap may be indicated with single recessions in presence of conditions that don't allow to perform the coronally advanced flap. Single recessions increase the probability that the adjacent teeth have sufficient amount of keratinized tissue to perform a laterally and coronally advanced flap.

**Methods:** the treatment plan is to correct a single recession on element 43, in a 38-years-old patient that reports aesthetic problems. It starts with instructions on non-traumatic brushing technique, followed by a mucogingival surgery through a laterally and coronally advanced flap. The flap design consists in a vertical intrasulcular incision followed by a horizontal paramarginal incision on keratinized tissue with a mesio-distal extension 6 mm larger than the recession size. The last incisions are

vertical and oblique ones. Disepithelialization was made. The detachment of the flap is created as a partial and full thickness: partial at the surgical papillae level, then moves on to a mixed detachment (first full then partial). At this point, a root planing is performed and the intervention can be completed using an absorbable 6.0 suture. The anchoring of the surgical papillae to the disepithelialized anatomical papillae is done by suspended suture.

**Results:** after five months a good band of keratinized tissue developed on the element ensuring a good camouflage of the treated area in terms of colour and thickness.

**Conclusion:** root coverage of a single recession using a laterally and coronally advanced flap represent an important alternative when coronally advanced flap is not indicated.

## ENTIRE PAPILLA PRESERVATION TECHNIQUE: A CASE SERIES

Porro A., Butti A., Guerrieri P., Vella M., Rossi F., Calò A., Tripicchio C.

Department of Biomedical, Surgical and Dental Sciences, University of Milan, Milan, Italy

**Aim:** the aim of this study is to describe the clinical and surgical management of two case series treated with the entire papilla preservation technique.

**Methods:** two clinical cases of intrabony defects on mandibular molars were treated with the entire papilla preservation technique. The operative protocol involved the execution of a buccal full-thickness mucoperiosteal flap extending to the defect-associated papilla. The defects were rinsed with sterile saline and the exposed roots were treated with EDTA. EMD were applied on the exposed root surfaces, afterwards heterologous bone chips were placed into the intrabony defects. The flap was sutured with 5/0.

**Results:** entire papilla preservation technique is a novel tunnel-like surgical approach for the regenerative treatment of

deep and wide intrabony defects. This approach aims to preserve the whole integrity of the defect-associated papilla providing a tunnel-like undermining incision. The completely preserved interdental papilla provides an intact gingival chamber to stabilize the blood clot and improve the wound healing process. This technique could favour primary healing over the biomaterial and enhance the stability of the blood clot formation in the intrabony defect space, a defect that involved the lingual side of the tooth or a defect that requires the elevation of the papilla for the debridement.

**Conclusion:** the entire papilla preservation approach in the two clinical cases has shown excellent healing results and seems to provide ideal clinical condition to favour the early and late wound healing phases.

## CLINICAL EFFICACY OF PROBIOTICS IN CHRONIC PERIODONTITIS: A REVIEW

Romeo M.<sup>1</sup>, Hazballa D.<sup>1</sup>, Laudadio C.<sup>1</sup>, Patano A.<sup>1</sup>, Malcangi G.<sup>1</sup>, Coloccia G.<sup>1</sup>, Marinelli G.<sup>1</sup>, Limongelli L.<sup>1</sup>, Inchingolo A.D.<sup>1</sup>, Montenegro V.<sup>1</sup>, D'Oria M.T.<sup>1</sup>, Inchingolo A.M.<sup>1</sup>, Dipalma G.<sup>1</sup>, Inchingolo F.<sup>1</sup>, Di Venere D.<sup>1</sup>, Cardarelli F.<sup>1</sup>, Farronato M.<sup>2</sup>, Tartaglia G.<sup>2</sup>

Complex Operative Unit of Odontostomatology, Director: Prof. G. Favia

<sup>1</sup>Specialization School in Orthognatodontics Director Prof. F. Inchingolo, Interdisciplinary Department of Medicine D.I.M. University of Bari Aldo Moro, Bari, Italy

<sup>2</sup>Department of Biomedical, Surgical and Dental Sciences, School of Dentistry, University of Milan. UOC Maxillo-Facial Surgery and Dentistry, Fondazione IRCCS Ca' Granda, Ospedale Maggiore Policlinico, Milan, Italy

**Aim:** chronic periodontitis (CP) is a complex pathology with a notable impact worldwide causing bone loss. CP might be thought about as part of a complex systemic disease often co-existent with metabolic syndrome and obesity. In this scenario, under the control of local bacteria the balance between pro/anti-inflammatory responses plays a key role. Oral dysbiosis is a highly inflammatory state associated to a durable insulting infection that represents an underestimated CP key factor. The proposed mechanisms of the pro-inflammatory response may follow the direct effect of the NF- $\kappa$ B (NuclearFactor-KB) overexpression or be the consequence of the diminution of crucial commensal strains, such as *Lactobacillus*, due to the high level of aggressive pathogens typical of a dysbiotic environment. As probiotics are considered a new implement for combating infectious diseases, in this study we systematically reviewed the evidences for their efficacy in the management of periodontitis.

**Methods:** electronic databases were searched up to December 2020 using the terms chronic periodontiti, periodontitis, probiotic(s), prebiotic(s), *Bifidobacterium* and *Lactobacillus*. In the present study only randomized controlled trials (RCTs) were included.

**Results:** in general, oral administration of probiotics ameliorate the recognized clinical signs of chronic and aggressive periodontitis such as bleeding on probing, probing pocket depth and attachment loss with an associated reduction of major periodontal pathogens levels. Continuous probiotic administration, mainly with *Lactobacillus* species, helps to maintain these benefits.

**Conclusion:** oral administration of probiotics is an effective and safe adjunct to conventional mechanical treatment in the management of periodontitis, especially the chronic disease entity. Their additional use is likely to improve disease state and reduce the need for antibiotics.

## MUCOSAL-ASSOCIATED DYSBIOSIS AS A LINK BETWEEN PERIODONTITIS AND IBD: A SYSTEMATIC REVIEW

Squillace E.<sup>1</sup>, Muwalla M.<sup>1</sup>, Romano F.<sup>1</sup>, Citterio F.<sup>1</sup>, Baima G.<sup>1</sup>, Buduneli N.<sup>2</sup>, Aimetti M.<sup>1</sup>

<sup>1</sup>Department of Surgical Sciences, C.I.R. Dental School, University of Turin, Turin, Italy

<sup>2</sup>Department of Periodontology, Ege University, Izmir, Turkey

**Aim:** the present systematic review aimed to critically examine the association between periodontitis and inflammatory bowel disease (IBD), specifically with regard to the microbiological component.

**Methods:** a systemic search was conducted via PubMed, Embase, Scopus, and Web of Science up to March 2021. The Preferred Reporting Items for Systematic Reviews and Meta-Analyses manual was used as a guide. The available evidence was grouped into two major clusters: a) studies examining oral microbial changes in patients with IBD; b) studies investigating gut dysbiosis in patients with different periodontal conditions.

**Results:** a total of 10 observational studies comprehensive of 953 patients were included. Subgingival and salivary microbiome of patients with IBD was significantly altered compared to healthy subjects, despite some differences were detectable between Crohn's disease and ulcerative colitis. Genera *Bacte-*

*roidetes*, *Prevotella* and *Veilonella* were significantly higher in IBD; while *Proteobacteria*, *Streptococcus* and *Haemophilus* followed the opposite direction. In parallel, the intestinal dysbiotic microflora of patients with IBD was colonized by pathogens translocated from the oral cavity via hematogenous or enteric routes. Metagenomics analysis of stool samples demonstrated that periodontitis significantly altered bacterial alpha diversity and exacerbated gut inflammation. However, current evidence demonstrates a great degree of heterogeneity and concerns of possible unknown confounding factors.

**Conclusion:** the relationship between intestinal dysbiosis and periodontitis may have a bidirectional character. Therefore well-designed preclinical models, longitudinal cohort studies and interventional studies should be conducted in order to achieve a better understanding and explore causal pathways between the two conditions.

## CLINICAL AND AESTHETIC OUTCOMES IN ROOT COVERAGE AT LOWER INCISORS: A RETROSPECTIVE STUDY

Zuffellato N.<sup>1</sup>, Liboni P.<sup>1</sup>, Signoriello A.<sup>1</sup>, Hu J.<sup>1</sup>, Armando Vila L.<sup>2</sup>, Wilches Visbal J. H.<sup>2</sup>, Lombardo G.<sup>1</sup>

<sup>1</sup>Dentistry and Maxillo-facial Surgery Section, Department of Surgery, Dentistry, Paediatrics and Gynaecology (DIPSCOMI), University of Verona, Verona, Italy

<sup>2</sup>Research Group in Family Health, University of Magdalena, Santa Marta, Colombia

**Aim:** the aim of this study was to evaluate, clinically and aesthetically, two surgical root coverage techniques (modified Coronally Advanced Flap with Connective Tissue Graft (mCAF+CTG) and modified-Free Gingival Graft sec. Miller (mFGG)), performed to treat single Miller Class I and II gingival recessions, with a depth greater than 2 mm, in the anterior areas of the mandible.

**Methods:** twenty-seven patients (six males and twenty-one females), with one single recession, were treated: mCAF+CTG and mFGG was respectively performed in fifteen (56%) and twelve (44%) patients. Main outcomes included recession reduction ( $\Delta$ REC), keratinized tissue gain ( $\Delta$ KT), complete root coverage (CRC), and mean percentage of recession coverage (MRC). Root coverages were evaluated with the Total Clinical Score (TCS) and the modified-Root coverage Aesthetic Score (m-RES).

**Results:** overall results regarding MRC were  $87.1\% \pm 0.2$  for mCAF+CTG and  $73\% \pm 0.2$  for mFGG. CRC was obtained in 8/15 cases (53.3%) with mCAF+CTG and in 3/12 cases (25%) with mFGG. KT increased to  $3.27 \pm 2.3$  mm for mCAF+CTG and  $4.17 \pm 2.1$  mm for mFGG. TCS was  $10.73 \pm 2.31$  in mCAF+CTG and  $10.58 \pm 2.43$  in mFGG. The m-RES was 8 points ( $8.00 \pm 1.96$ ) for mCAF+CTG and 5.9 points ( $5.92 \pm 1.44$ ) for m-FGG.

**Conclusion:** the mCAF+CTG technique reported better clinical and aesthetic results when compared to mFGG. Outcomes showed highest potential for mFGG in increasing both height and thickness of KT, and in the apical repositioning of the frenula. The mFGG technique showed poorer aesthetic results due to the misalignment of the mucogingival junction and the formation of scars.

## IDENTIFICATION OF SALIVARY METABOLITES ASSOCIATED TO GINGIVAL BLEEDING

Anonelli R.<sup>1</sup>, Pezzi M.E.<sup>1</sup>, Viani M.V., Setti G.<sup>1</sup>, Ferrari E.<sup>3</sup>, Pertinhez T.A.<sup>2</sup>, Quartieri E.<sup>3</sup>, Meleti M.<sup>1</sup>

<sup>1</sup>University Center of Dentistry, Department of Medicine and Surgery, University of Parma, Parma, Italy

<sup>2</sup>Section of Biochemistry, Department of Medicine and Surgery, University of Parma, Parma, Italy

**Aim:** according to the new classification scheme for periodontal and peri-implant diseases and conditions (Chicago, 2017), bleeding on probing should be the primary parameter to set thresholds for gingivitis. The aim of the present work is to identify salivary metabolites possibly associated to the early stages of gingival disease.

**Methods:** whole saliva samples of 20 healthy subjects aged between 20 and 25 years were collected and analyzed by <sup>1</sup>H-Nuclear Magnetic Resonance (NMR). Study population was divided in two subgroups based on "Full Mouth Bleeding Score" (FMBS):  $< 4\%$  ( $n = 12$ ) and  $> 4\%$  ( $n = 8$ ). Through evaluation of NMR spectra, metabolites were identified and quantified. Multivariate statistical analysis was carried out on targeted metabolites using sparse partial least squares analysis (SPLS) on MetaboAnalystR 4.0. All variables were normalized by reference feature and auto-scaling prior to analysis. ROC curve was implemented to validate the results obtained by SPLS model. The area under the curve (AUC) of ROC curve estimates the accuracy of the comparison.

**Results:** multivariate statistical analysis was carried out on the metabolites database and clearly indicate the separation in two clusters, corresponding to the two groups of FMBS. Ten metabolites contribute to the separation of the two groups: particularly isocaproate, 3-phenylpropionate, glucose, propionate and isobutyrate. All identified compounds were more concentrated in the population with a FMBS  $> 4\%$ . The ROC curve elaborated with the combination of these 5 metabolites determine an AUC of 0.93: meaning that the model composed by this set of metabolites is very efficient to distinguish the two populations.

**Conclusion:** the concentration of the 5 metabolites described is strongly related to gingival bleeding and the present model could be used as basis for the development of an early diagnostic tool for periodontal diseases. Gingival inflammation is associated to an imbalance of oral bacterial metabolism. The metabolites identified as discriminant between populations with different scores of FMBS are probably related to oral bacterial colonization.

## TOOTH LOSS ACCORDING TO COMPLIANCE AND PERIODONTAL RISK DURING SUPPORTIVE PERIODONTAL CARE

Baraldi A.<sup>1</sup>, Farina R.<sup>1,2</sup>, Simonelli A.<sup>1</sup>, Pramstraller M.<sup>1,2</sup>, Minenna L.<sup>1</sup>, Toselli L.<sup>1</sup>, Maietti E.<sup>3</sup>, Trombelli L.<sup>1,2</sup>

<sup>1</sup>Research Centre for the Study of Periodontal and Peri-Implant Diseases, University of Ferrara, Ferrara, Italy

<sup>2</sup>Operative Unit of Dentistry, Azienda Unità Sanitaria Locale of Ferrara, Ferrara, Italy

<sup>3</sup>Department of Medical and Surgical Sciences, University of Bologna, Bologna, Italy

**Aim:** to evaluate yearly tooth loss rate (TLR) in periodontitis patients with different periodontal risk levels who had complied or not complied with supportive periodontal care (SPC).

**Methods:** data from 168 periodontitis patients enrolled in a SPC program based on a 3-month suggested recall interval for at least 3.5 years were analyzed. For patients with a mean recall interval within 2-4 months ("compliers") or > 4 months ("non-compliers") with different periodontal risk levels according to PerioRisk (Trombelli et al. 2009), TLR (irrespective of the cause for tooth loss) was calculated. TLR values were considered in relation to meaningful TLR benchmarks from the literature for either periodontitis patients either under SPC (0.15

teeth/year; positive benchmark) or irregularly complying with SPC (0.36 teeth/year; negative benchmark).

**Results:** in both compliers and non-compliers, TLR was significantly below or similar to the positive benchmark in PerioRisk level 3 (0.08 and 0.03 teeth/year, respectively) and PerioRisk level 4 (0.12 and 0.18 teeth/year, respectively), and similar to the negative benchmark in PerioRisk level 5 (0.32 and 0.52 teeth/year, respectively).

**Conclusion:** a SPC protocol based on a 3 to 6-month recall interval may effectively limit long-term tooth loss in periodontitis patients with PerioRisk 3 and 4. A fully-complied 3-month SPC protocol seems ineffective when applied to PerioRisk 5 patients.

## PHOTO-DYNAMIC-THERAPY NO DYE VS. LANAP IN NON-SURGICAL PERIODONTAL TREATMENT LASER AIDED

Caccianiga G., Caccianiga P., Porcaro G., Baldoni M., Ceraulo S.

School of Medicine and Surgery, University of Milano-Bicocca, Monza, Italy

**Aim:** the purpose of our study is to show the effects of Oxygen high level laser therapy (OHLLT) in removing all bacterial deposits on root or implant surface by mean of mechanical instrumentation and laser irradiation, compared to LANAP and to non-surgical debridement of periodontal pockets.

**Methods:** this study evaluated the effectiveness of laser therapy combined with two different types of protocols. 30 patients aged between 18 and 65 were recruited. They were randomly divided into 3 groups of 10 subjects each: patients treated following the LANAP protocol; patients treated following the OHLLT protocol; patients treated exclusively with scaling and root-planing (control group). From each patient with periodontal disease, a triple sampling of sub-gingival plaque was removed in 2 distinct sites of the oral cavity. The first sampling was carried out before the applica-

tion of the protocols; the second 1 week after the end of the treatments and the third 9 months after the end of the treatments. Each plaque sample was tested in the laboratory.

**Results:** at 7 days post-treatment, PCR real time test had similar results on OHLLT and LANAP groups. After 9 months, all periodontal pockets were treated successfully, without having any complications and not showing significant differences in clinical results between OHLLT and LANAP, with a decrease both of plaque index, bleeding on probing and probing depth, but OHLLT groups had the best results compared to LANAP group on PCR real time bacterial counts.

**Conclusion:** OHLLT is efficacy in treatment of chronic periodontitis as demonstrated by clinical and microbiological parameters, going beyond the traditional periodontal therapy.

## VESTIBULAR FORNIX DEPTH AND PERIODONTAL HEALTH PARAMETERS: A PRELIMINARY REPORT

Casarin M., Veronese A., Stellini E., Sbricoli L.

Department of Neuroscience, University of Padua, Padua, Italy

**Aim:** a shallow vestibular fornix causes patient discomfort during brushing and general difficulty in oral hygiene maneuvers. The correlation between the depth of the vestibular fornix and the periodontal health has not been fully investigated in dentistry field. Nowadays, there are only three studies about this argument and the results are confounding. The aim of the present study is to investigate the possible correlation between depth of the vestibular fornix and attached gingiva. Moreover, for the first time, this study considers the differences between natural teeth and dental implants, in matter of depth of fornix.

**Methods:** the study considered 65 patients (44 females, 21 males) aged between 21 and 49 years, without missing anterior teeth, without mandibular anterior restorative crowns and without diseases or medications that could affect gingiva and peri-implant mucosa. BI, PI, depth of vestibular fornix, width of keratinized gingiva and gingival recession were recorded using

a digital calliper and a periodontal probe. The gingival biotype of each patient was also considered.

**Results:** the results of this preliminary report showed a mean fornix depth in the maxilla of 9,99mm (range 5-15mm) and of 8,08mm (range 3-15mm) in the mandibula. The mean width of keratinized gingiva in the maxilla was 5,85mm (range 1-13mm) and 4,22mm (range 1-9mm) in the mandibula. In the maxilla a mean of 39% of vestibular fornix was represented by keratinized gingiva, while in the mandible a mean of 30% of the vestibular fornix was represented by keratinized gingiva. At the time of this report no data about implant sites was available.

**Conclusion:** there is high variability between subjects in vestibular fornix depth and keratinized gingiva width. Preliminary data showed that vestibular fornix in maxilla is deeper than mandibula and covered by more attached gingiva. At the moment, the study shows that periodontal health can be maintained with shallow fornix of 3mm covered by 1mm of attached gingiva.

## THE COMBINED EFFECT OF ORTHODONTIC TOOTH MOVEMENT AND PERIODONTAL REGENERATIVE SURGERY

Ciccarelli M., Mohammadi G., Arduino A., Mantovani E., Romano F., Citterio F., Baima G., Castrolforio T., Aimetti M.

Department of Surgical Sciences, C.I.R. Dental School, University of Turin, Turin, Italy

**Aim:** to answer the following focused questions (FQ): what is the efficacy of periodontal regenerative surgery and orthodontic tooth movement (OTM) in the therapy of infraosseous defects in pathologic migrated teeth (FQ-1); what is the ideal timing to start OTM (FQ-2); and which is the best biomaterial for regeneration when the OTM is planned thereafter (FQ-3).

**Methods:** systematic electronic search up to March 2021 was conducted to identify randomized controlled trials (RCT), controlled trials and cohort studies reporting on combined ortho-perio treatment of periodontal infraosseous defects. Screening and data extraction were performed in duplicate to summarize the available evidence.

**Results:** baseline and final data from 13 studies were considered, although only one RCT compared the efficacy of periodontal regeneration with or without OTM (FQ-1). A sig-

nificant improvement for clinical attachment level (CAL) and probing depth (PD) was found after OTM. Fifteen studies adopted different timings of OTM following periodontal regeneration (FQ-2). Both immediate (7-10 days) or delayed OTM (12 months) obtained similar outcomes. Immediate approach was found superior to early approach (2 months after surgery) in terms of CAL gain in one study. Lastly, 6 studies evaluated regenerative approaches using either membranes, bone substitutes or amelogenins (FQ-3), but no direct comparisons could be performed.

**Conclusion:** if periodontal infection is under control, the orthodontic treatment improves the outcomes of periodontal regeneration of pathologic migrated tooth irrespective of the type of material selected and OTM timing (low level of evidence).

## PERIODONTAL DISEASE: A FOCUS ON ORAL MICROORGANISMS. A PRELIMINARY STUDY

Del Giudice C.<sup>1</sup>, Carraturo F.<sup>2</sup>, Spagnuolo G.<sup>1</sup>, Rengo G.<sup>3</sup>, Cannavo A.<sup>3</sup>, Rengo S.<sup>1</sup>, Guida M.<sup>2</sup>

<sup>1</sup>Department of Neurosciences, Reproductive and Odontostomatological Sciences, University of Naples Federico II, Naples, Italy

<sup>2</sup>Department of Biology, University of Naples Federico II, Naples, Italy

<sup>3</sup>Department of Translational Medical Sciences, University of Naples Federico II, Naples, Italy

**Aim:** periodontitis is a chronic inflammatory disease caused by an alteration of symbiotic oral microbiota, with major proliferation of anaerobic Gram-negative bacteria, that can determine loss of dental attachment. Nonetheless, recent studies demonstrated that Gram-positive bacteria, such as *Streptococcus* sp., are also involved. When bacteria proliferate in periodontal pockets, they are able to induce an inflammatory response, representing a risk factor for systemic conditions. In this study, we evaluated microbial communities of two different areas of oral cavity, gingival papilla and retromolar trigone, collected from a hospitalized patient.

**Methods:** to characterize microbial communities, microbiological analysis, following standardized cultural protocols, and Sanger sequencing, amplifying bacterial r16S gene, were performed. Moreover, specific primers for *Porphyromonas gingivalis* were utilized, pointing to a faster microbial identification.

**Results:** in aerobic conditions, the total bacterial count (TBC) at 37°C of the gingival papilla ( $10^2$  CFU/g) resulted less of 2-log lower than retromolar trigone ( $10^4$  CFU/g). In addition, in the retromolar trigone the majority of microorganisms isolated were anaerobic Gram-negative bacteria, belonging to Porphyromonaceae and Enterobacteriaceae families and, to a lesser extent, Gram-positive aerobic bacteria such as Staphylococcaceae.

**Conclusion:** our results showed that microbial communities at gingival papilla was characterized by aerobic microorganisms. The lower microbial load compared to the retromolar trigone may be explained by the area which is the most exposed to daily oral hygiene. Furthermore, the preliminary data suggest that microbial diversity in the retromolar trigone could establish a competition in favor of periodontal pathogens.

## POCKET CLOSURE ONE YEAR AFTER ACTIVE PERIODONTAL THERAPY: A MULTILEVEL ANALYSIS

Di Venanzio A., De Caroli M., Romano F., Baima G., Citterio F., Aimetti M.

Department of Surgical Sciences, C.I.R. Dental School, University of Turin, Turin, Italy

**Aim:** to evaluate the patient-, tooth- and site-related factors that influence pocket closure (PC) [pocket depth (PD)  $\leq$  4 mm and no bleeding on probing (BoP -)] 1 year after active periodontal therapy (APT) and to assess the factors affecting different treatment approaches.

**Methods:** clinical data of 40 patients with stage III-IV periodontitis were retrospectively collected, at 3 months after the completion of non surgical therapy (T1) and 1 year after the end of APT (T2). Stepwise multilevel logistic regression models were built to evaluate factors that influence the probability of obtaining PC at T2.

**Results:** periodontal regeneration (REG) (OR = 19.77), osseous resective surgery (ORS) (OR = 38.18), BoP at T1 (OR =

0.12), and presence of plaque at T2 (OR = 0.09) were significantly associated to PC in the sample. Sites treated with REG resulted in 76.45% of PC. The probability of PC after REG were associated to BoP at T1 (OR = 0.20), and plaque at T2 (OR = 0.12). PC occurred in 86.33% of sites treated with ORS and was associated to plaque at T2 (OR = 0.09). Supportive periodontal treatment (SPT) achieved PC in 78.06% of the cases; BoP at T1 (OR=0.36), and plaque at T2 (OR = 0.13) were statistically associated PC in sites receiving SPT.

**Conclusion:** periodontal treatment has high probability of success. Pre-surgical control of inflammation and post-surgical oral hygiene seem to be major factors affecting the outcome of periodontal treatment.

## THE EFFECT OF ADD-ON SYSTEMIC HIGH-DOSE TETRACYCLINE THERAPY ON GINGIVAL RESSION

Figliuzzi M.M., Sestito S., Brancaccio Y., Buffone C., Delfina P.

Department of Periodontics and Oral Sciences, University Magna Graecia of Catanzaro, Catanzaro, Italy

**Aim:** the objective of the current randomized, double-blind, placebo-controlled, parallel-arm study was to examine the efficacy of LDD in combination with surgical periodontal therapy of gingival recessions, evaluating the level of coverage achieved and the levels of metalloproteinases. -8 (MMP-8) of the gingival crevicular fluid (GCF) compared to surgical periodontal therapy alone without the aid of tetracycline.

**Methods:** GCF samples were collected and clinical parameters were recorded including probing depth (PD), recession (REC), THEN clinical attack level, FORTY E3 patients with chronic periodontitis WITH AT LEAST ONE Miller CLASS 3 RECESSION, twenty patients were randomized to a tetracycline (LDD) or placebo group. The LDD group received a dose of 750 mg x of x 10 days per month for 2 months repeated twice while the placebo group was given placebo capsules b.i.d. patients were evaluated at the time 0 3 months and for the study period A 12 months. All clinical measurements and GCF sampling were repeated at

each visit. MMP-8 GCF levels were determined by a time-resolved immunofluorescence assay. Comparisons within the group were tested by the Friedman test followed by the Wilcoxon classification test to analyze the significance of changes over time. The Mann-Whitney test was used to determine the differences between the LDD and placebo groups.

**Results:** LDD showed a significantly greater reduction in mean PD scores at 3 maintained through to and 12 months and significantly higher levels of coverage compared to the placebo group. The level of GCF MMP-8 metalloproteinase in the LDD group was significantly lower than that of the placebo group at 3 months and 12 months.

**Conclusion:** current results indicate that high-dose tetracycline therapy in Muileer class 3 recession surgical therapy, combined with can significantly improve coverage level and reduce MMP-8 GCF levels and improve clinical periodontal parameters. in patients with chronic periodontitis.

## THE INFLUENCE OF NON-CARIOUS LESIONS IN THE SURGICAL TREATMENT OF GINGIVAL RESSIONS

Gennai S.<sup>1,2</sup>, Orsolini C.<sup>1,2</sup>, Nisi M.<sup>1,2</sup>, Izzetti R.<sup>1,2</sup>, Ben Guiza Z.<sup>3,4</sup>, Gosset M.<sup>4,5</sup>, Graziani F.<sup>1,2</sup>

<sup>1</sup>Department of Surgical, Medical and Molecular Pathology and Critical Care Medicine, University of Pisa, Pisa, Italy

<sup>2</sup>Sub-Unit of Periodontology, Halitosis and Periodontal Medicine, University Hospital of Pisa, Pisa, Italy

<sup>3</sup>Faculté de Médecine Dentaire, Université de Monastir, Monastir, Tunisie

<sup>4</sup>Laboratory Orofacial Pathologies, Imaging and Biotherapies, Université de Paris, Montrouge, France

<sup>5</sup>Service de Médecine Bucco-Dentaire, Hôpital Charles Foix, Ivry/Seine, France

**Aim:** we conducted a systematic review and a two-arms meta-analysis to compare the effects of performing or not a restorative procedure of a non-carious cervical lesion (NCCL) in adjunction to periodontal plastic surgery.

**Methods:** randomized clinical trials on patients who underwent periodontal plastic surgery to treat Miller's class I and II or Cairo's type I isolated gingival recessions were included in this review. Studies should have presented at least ten patients per group and a follow-up of at least 6 months. Two-arm meta-analyses were made comparing groups with a treatment protocol comprising the restorative treatment of the NCCL *versus* those not comprising the restorative treatment. The primary outcome was complete root coverage (CRC), and secondary outcomes were the percentage of root coverage (PRC), recession reduction (RecRed), keratinized tissue width (KTW), keratinized tissue thickness (KTT) and dental hypersensitivity (DH).

**Results:** seven studies were analyzed.

RecRed showed a weighted mean difference of -0.17 mm (95% CI: [-0.34, 0.00], favour to non-restored NCCL), -0.03 mm for KT thickness increase (95% CI: [-0.15, 0.09], favour to non-restored NCCL), -0.02 mm for the KT width increase (95% CI: [-0.41, 0.37], favour to non-restored NCCL) and of -1.64% (95% CI: [-6.11, 2.83], favour to non-restored NCCL) for the PRC. Odds Ratio was 1.00 (95% CI: [0.33, 2.99], equality for the comparison) for the CRC.

A two-arms meta-analysis on DH showed a statistically significant difference favouring the restored NCCL group (OR = 13.61, 95% CI: [4.02, 46.00]).

**Conclusion:** performing or not a restorative procedure of the non-carious cervical lesion does not influence the surgical treatment outcomes. The restoration of the defect appears to reduce dental hypersensitivity.

## SIGNS AND SYMPTOMS OF PERIODONTAL DISEASE: CLUSTER ANALYSIS IN A COHORT OF 468 PATIENTS

Gennai S.<sup>1,2</sup>, Palumbo I.<sup>1,2</sup>, Biancarini M.L.<sup>1,2</sup>, Tinto M.<sup>1,2</sup>, Izzetti R.<sup>1,2</sup>, Nisi M.<sup>1,2</sup>, Graziani F.<sup>1,2</sup>

<sup>1</sup>Department of Surgical, Medical and Molecular Pathology and Critical Care Medicine, University of Pisa, Pisa, Italy

<sup>2</sup>Sub-Unit of Periodontology, Halitosis and Periodontal Medicine, University Hospital of Pisa, Pisa, Italy

**Aim:** the aim of this work was to evaluate the perception of periodontitis (P) and its possible impact on the overall health of a cohort of subjects treated for P.

**Methods:** 468 subjects affected by P and treated with non-surgical periodontal therapy were included in the study. Following questionnaires were administered pre- and post-treatment: Memory Assessment Clinics Questionnaire (MAC-Q), Oral Health Impact Profile 14 (OHIP-14), International Index of Erectile Function Questionnaire 5 (IIEF-5), Pittsburgh Sleep Quality Index (PSQI), Fagerström Test for nicotine addiction, stress test (ST), and two novel questionnaires for periodontal symptomatology (Periodontal symptomatology test (PS), Perioperception test (PPP)). Clinical parameters were recorded pre- and post-treatment. K-means method was conducted to identify the number of potential clusters. ANCOVA with the LSD method made it possible to evaluate the pre-post treatment difference between the identified clusters.

**Results:** the K-means analysis identified two main clusters. The analysis reveals that there was no difference in terms of demographic variables between the two clusters. In contrast, it revealed differences for clinical parameters and questionnaires. Cluster 1 showed higher values of FMBS, FMPS, PSQI, MAC-Q, ST, PS, PPP, OHIP-14, fewer periodontal sites < 4mm, more sites > 3mm at baseline T0 and a greater percentage of healed sites at T1. Considering pre- and post-treatment difference between two identified clusters, the following variables were significant: sites < 4mm, FMBS, FMPS, MAC-Q, Fagerström, PS and OHIP-14.

**Conclusion:** the current study showed that subjects with worse periodontal status had worse health conditions and more periodontal symptoms. The response to the periodontal treatment was different, and subjects with worse periodontal status had minor improvement in clinical and systemic conditions.

## SERS OF CREVICULAR FLUID IN THE SCREENING OF PERIODONTAL PATHOLOGIES

Stacchi C.<sup>1</sup>, Berton F.<sup>1</sup>, Rapani A.<sup>1</sup>, Pasquali R.<sup>1</sup>, Fornasaro S.<sup>2</sup>, Bonifacio A.<sup>2</sup>, Di Lenarda R.<sup>1</sup>

<sup>1</sup>Department of Medical, Surgical and Health Sciences, University of Trieste, Trieste, Italy

<sup>2</sup>Department of Engineering and Architecture, University of Trieste, Trieste, Italy

**Aim:** the purpose of this study was to evaluate the application of Surface Enhanced Raman Spectroscopy (SERS) as a non-invasive tool for the early diagnosis of periodontal pathologies.

**Methods:** periodontally healthy patients, patients with gingivitis and patients with periodontitis were included in this study. Six teeth for each patient were selected following a standardized protocol and paper strips were used for sampling. The strip was inserted 1 mm into the gingival sulcus for 30 seconds and then placed into an Eppendorf tube and stored at -15° C in a clear bag. Samples were subsequently treated with specific silver colloid and analyzed by means of SERS.

**Results:** samples from 25 patients (150 dental elements) were collected and spectral differences among the three groups were highlighted. Variations in three bands (uric acid,

hypoxanthine and ergothioneine) were found to be correlated to periodontal conditions: uric acid showed higher concentrations in periodontal healthy sites, whilst hypoxanthine and ergothioneine levels increase in gingivitis and, particularly, in periodontitis.

**Conclusion:** this preliminary study aimed to find a method to obtain a molecular footprint of the crevicular fluid through SERS, and correlate it with the periodontal status. Ag-NPs-coated paper strips allowed to obtain a reproducible and stable signal. Most significant differences in spectral profiles were related to uric acid, hypoxanthine and ergothioneine. In this study the presence of ergothioneine was first documented in SERS spectra of GCF and is highly concentrated at tissue injury sites.

## THE EFFECT OF PERIODONTITIS ON C-REACTIVE PROTEIN: A SYSTEMATIC REVIEW AND META-ANALYSIS

Perić M., Marhl U., Cerreto D., Gennai S., Nisi M., Izzetti R., Graziani F.

Department of Surgical, Medical and Molecular Pathology and Critical Care Medicine, University of Pisa, Pisa, Italy; Sub-Unit of Periodontology, Halitosis and Periodontal Medicine, University Hospital of Pisa, Pisa, Italy

**Aim:** to assess the effects of periodontitis on serum levels of C reactive protein (CRP).

**Methods:** a detailed protocol was designed according to the PRISMA statement to answer the focused PICO question: *Do subjects with periodontitis have elevated blood values of systemic inflammatory biomarkers when compared to controls without periodontitis?* The protocol was registered at PROSPERO (CRD42019118831). Observational studies evaluating systemic blood biomarkers and periodontitis were searched by electronic databases and relevant hand-searched journals. The quality assessment of included studies was assessed using NOS for case-control and cohort studies, and modified NOS for cross-sectional studies. Meta-analysis was performed for continuous outcomes using both fixed and random models with the OpenMeta[Analyst] and summarized in forest-plots. Primary outcome measure was the blood level of CRP in subjects with periodontitis when compared to controls without periodontitis.

**Results:** a total of 712 citations were identified, and after screening of titles and abstracts, 466 citations were excluded.

The remaining 246 citations were assessed for the full-text analysis that led to the exclusion of further 163 citations. The full text of remaining 83 citations was analysed for methodological quality and availability of data for meta-analysis.

Lastly, 19 citations met the inclusion criteria in this meta-analysis assessing the serum levels of CRP. The overall CRP in subjects with periodontitis was 2.52 mg/l (95% CI, 1.68 to 3.36). The serum CRP levels in subgroup without comorbidities was 1.36 mg/l (95% CI, 0.96 to 1.75); the subgroup with comorbidities 3.29 (95% CI, 2.34 to 4.23).

**Conclusion:** present findings highlight further the importance of promoting periodontal care in the management of subjects with periodontitis, and especially those with concomitant medical pathologies.

## SALIVARY AND SERUM ADMA LEVELS IN PATIENTS WITH PERIODONTAL AND CARDIOVASCULAR DISEASE

Polizzi A.<sup>1</sup>, Santonocito S.<sup>1</sup>, Williams R.C.<sup>2</sup>, Kocher T.<sup>3</sup>, Lo Giudice A.<sup>1</sup>, Isola G.<sup>1</sup>

<sup>1</sup>Department of General Surgery and Surgical-Medical Specialties, School of Dentistry, University of Catania, Catania, Italy

<sup>2</sup>Department of Periodontology, School of Dentistry, University of North Carolina, Chapel Hill, NC, USA

<sup>3</sup>Department of Restorative Dentistry, Periodontology, Endodontology and Preventive and Pediatric Dentistry, University Medicine Greifswald, Greifswald, Germany

**Aim:** asymmetric dimethylarginine (ADMA) is an endogenous inhibitor of the metabolism of nitric oxide (NO) and plays a crucial role in endothelial function: ADMA maybe a link for the known interaction of periodontitis (CP) and coronary heart disease (CHD). This is a pilot study with the aim to evaluate the impact of periodontal (CP), cardiovascular (CHD) or both (CP+CDH) diseases on salivary and serum ADMA levels.

**Methods:** clinical and periodontal parameters and serum and salivary samples were collected from four groups of patients: 35 with CP, 33 with CHD, 35 with both CP+CHD and 35 healthy subjects. ADMA and C-reactive protein (hs-CRP) levels were measured with a commercially available kit.

**Results:** CHD and CP+CHD groups showed that the median (25% and 75% percentile) salivary and serum ADMA levels

were significantly higher [CHD: serum: 1.5 (1.2 to 1.8)  $\mu\text{mol/L}$ ; salivary 1.3 (1 to 1.7)  $\mu\text{mol/g}$  protein,  $P < 0.001$ ] [CP+CHD: serum: 1.8 (1.4 to 2.0)  $\mu\text{mol/L}$ ; salivary 1.5 (1.2 to 1.7)  $\mu\text{mol/g}$  protein,  $P < 0.001$ ] compared to CP patients and control subjects. In univariate models, serum ADMA levels were associated with CP ( $P = 0.034$ ), CHD ( $P < 0.001$ ), and hs-CRP ( $P < 0.001$ ). In a multivariate model the predictor of serum ADMA was hs-CRP ( $P < 0.001$ ), whereas the salivary ADMA levels predictors were hs-CRP ( $P < 0.001$ ) and the education socioeconomic status ( $P = 0.042$ ).

**Conclusion:** patients with CHD and CP+CHD showed higher salivary and serum ADMA concentrations compared to CP and healthy subjects. hs-CRP was a significant predictor of increased salivary and serum ADMA levels.

## MANDIBULAR CORTICAL WIDTH TO SCREEN FOR POST-MENOPAUSAL OSTEOPOROSIS

Rossetti S.<sup>1</sup>, Rivara F.<sup>1</sup>, Goldoni M.<sup>2</sup>, Macaluso G.M.<sup>1</sup>, Passeri G.<sup>3</sup>, Calciolari E.<sup>4</sup>

<sup>1</sup>Center of Dentistry, Department of Medicine and Surgery, University of Parma, Parma, Italy

<sup>2</sup>Center for Medical Statistics, Department of Medicine and Surgery, University of Parma, Parma, Italy

<sup>3</sup>Unit of Andrology, Metabolic Bone Diseases and Endocrinology, Department of Medicine and Surgery, University of Parma, Parma, Italy

<sup>4</sup>Centre for Oral and Clinical Research and Centre for Oral Immunobiology and Regenerative Medicine, Institute of Dentistry, Barts and The London School of Medicine and Dentistry, Queen Mary University of London, London, UK

**Aim:** this cross-sectional study aimed to assess the feasibility of using the mandibular cortical width (MCW) calculated on dental panoramic radiographs to screen for post-menopausal osteoporosis.

**Methods:** 124,  $\geq 50$  years old post-menopausal women who performed a Dual-energy X-ray absorptiometry scan to assess their bone mineral density (based on a T score) within the previous 12 months were recruited at the Dental School, University of Parma. All participants received a dental examination and a dental panoramic radiograph (OPG). A blind calibrated examiner calculated MCW and assessed its accuracy to screen for osteoporosis.

**Results:** based on DXA results, 41 osteoporotic and 83 healthy/osteopenic women with a mean age of 64.24 (SD 8.35)

years were recruited. MCW had a sensitivity of 73.2% and a specificity of 95.2% to screen for osteoporosis. Moreover, there was a significant negative association between T score and percentage of missing teeth ( $p = 0.028$ ).

**Conclusion:** MCW showed to be a promising and straight forward tool that can be opportunistically used by dentists to intercept post-menopausal women affected by osteoporosis and potentially early refer them to the specialist before they fracture. In particular, MCW with a cut-off of 3.5 mm seems more accurate to exclude for osteoporosis (better specificity) rather than identifying it. The study was supported by UNESCO- L'Oréal for Women in science fellowship that was awarded to Dr Calciolari.

## ROOT COVERAGE PROCEDURES FOR SINGLE MAXILLARY RECESSIONS: A RETROSPECTIVE EVALUATION

Tandurella M.<sup>1</sup>, Pighi J.<sup>1</sup>, Kadim A.<sup>1</sup>, Signoriello A.<sup>1</sup>, Serpa Romero X.<sup>2</sup>, M. C. Castillo Pedraza M. C.<sup>2</sup>, Lombardo G.<sup>1</sup>

<sup>1</sup>Dentistry and Maxillo-facial Surgery Section, Department of Surgery, Dentistry, Paediatrics and Gynaecology (DIPSCOMI), University of Verona, Verona, Italy

<sup>2</sup>Research Group in Family Health, University of Magdalena, Santa Marta, Colombia

**Aim:** the aim of this study was to assess the clinical and aesthetic results of four different surgical techniques [modified Coronally Advanced Flap (mCAF) with or without Connective Tissue Graft (CTG), Subepithelial Connective Tissue Graft (SECTG) and Subpedicle Connective Tissue Graft (SPCTG)], in order to establish which obtained the most satisfactory results for the treatment of single Miller Class I and II gingival recessions in the aesthetic areas of the mouth.

**Methods:** twenty-nine patients, with thirty-four single recessions, were treated with mCAF (9 cases), mCAF plus CTG (7 cases), SECTG (7 cases) and SPCTG (11 cases). Main outcomes included recession reduction ( $\Delta$ REC), keratinized tissue gain ( $\Delta$ KT), complete root coverage (CRC), and mean percentage of recession coverage (MRC). The clinical cases were

evaluated aesthetically with the Root coverage Aesthetic Score (RES).

**Results:** after the surgery, CRC was achieved in 28/34 cases (82.4%). Overall recessions coverage was  $3.6 \pm 1.6$  mm, overall MRC was 95% and overall KT was increased to  $1 \pm 1.2$  mm. All techniques resulted in high MRC: mCAF = 97%; mCAF+CTG = 100%; SECTG = 98%; SPCTG = 95%. Bilaminar techniques demonstrated higher KT gain, leading, in some cases, to cheloid formation due to tissue overgrowth. The average RES score in the entire sample was 8.3 (range 6-10).

**Conclusion:** from an aesthetic point of view, the best results were achieved by mCAF, while the worst by SPCTG. The surgical technique which seemed best able to combine both aesthetic and clinical outcomes was mCAF+CTG.

## THE USE OF SONIC INSTRUMENTS IN PERIODONTOLOGY

Vella M., Butti A., Porro A., Guerrieri P., Rossi F., Calò A.

Department of Biomedical, Surgical and Dental Sciences, University of Milan, Milan, Italy

**Aim:** the study aims to assess how Komet's Sonic Line instruments® with sonic vibration, can treat compromised periodontal pocket.

**Methods:** 20 patients between 30 and 45, were chosen for the study. The selection criteria were based on: filling out the periodontal chart according to University of Bern: probing depth, clinical attachment, bleeding, presence of furcations, mobility, gingival recessions, presence of dental implants were studied. The subjects were treated in two sessions: the first one, in which the sonic instruments Komet Sonic Line Scaler® were used. The control was set at 40 days after the first one and compared with first visit.

**Results:** Komet® series sonic tips, allowed to scrape the root of the tooth with less invasive movements and with a final clinical result of increased periodontal recovery and reduced post-operative sensitivity, leaving a smooth and clean surface. These sonic tips with the terminal part in shape of a slot, are placed on the roots of the tooth and work with delicate and circular movements. The part in contact with the roots is the one that cuts, while the outer part is passive and can also be used in closed-air mode.

**Conclusion:** sonic instruments allowed a gentle and precise removal of the supragingival and subgingival tartar, with great simplicity of cleaning pockets over 4 mm.

## CANCER STEM CELLS MARKERS IN ORAL SQUAMOUS CELL CARCINOMA: A GENE EXPRESSION ANALYSIS

Buffone C.<sup>1</sup>, Battaglia A.M.<sup>2</sup>, Sacco A.<sup>2</sup>, Bennardo F.<sup>1</sup>, Antonelli A.<sup>1</sup>, Brancaccio Y.<sup>1</sup>, Barone S.<sup>1</sup>, Biamonte F.<sup>2,3</sup>

<sup>1</sup>School of Dentistry, Division of Oral Surgery and Pathology, Department of Health Sciences, University Magna Graecia of Catanzaro, Catanzaro, Italy

<sup>2</sup>Research Center of Biochemistry and Advanced Molecular Biology, Department of Experimental and Clinical Medicine, University Magna Graecia of Catanzaro, Catanzaro, Italy

<sup>3</sup>Interdepartmental Center of Services (CIS), University Magna Graecia of Catanzaro, Catanzaro, Italy

**Aim:** local recurrence in oral squamous cell carcinoma (OSCC) has driven an interest in the molecular characterization of margins. Cancer stem cells (CSCs) have been proposed as potential key of recurrence. Here, we analyzed the expression profile of CSCs markers in core and margins of OSCC.

**Methods:** seventeen OSCC patients were enrolled at the Oral Pathology Unit of “Magna Graecia” University of Catanzaro. Biopsies were taken from health mucosa (H), tumor (T) and clinical margin (CM). Specimens were digested and 2 µg of RNA was isolated from each sample. The expression analysis of 13 target genes (KLF4, BMI1, UBE2C, CD44, ALDH, NANOG, SOX2, OCT4, CD133, CXCR4, FAM3C, RRM2, IGF1-L) was performed using absolute qPCR. A p value < 0.05 was considered statistically significant.

**Results:** a total of 51 samples, obtained from 17 lesions (58.8% tongue, 29.4% alveolar mucosa, 5.9% cheek, 5.9% palate), classified as well, moderately and poorly differentiated, were analyzed. All genes, except for *IGF1-L* and *KLF4*, showed a high expression in T vs H in 13 out of 17 patients regardless of clinicopathological data ( $p < 0.05$ ). Among these, *CXCR4* and *BMI1* were found significantly up-regulated also in CM vs H ( $p < 0.05$ ). Notably, *CD133* expression was significantly higher in CM vs H uniquely in patients with poorly differentiated OSCC ( $p < 0.001$ ).

**Conclusion:** the molecular characterization highlighted that, in OSCC, not only tumor, but also clinical margin, could harbor cells enriched for CSC markers. In particular, CD133 could be a promising molecule for the early diagnosis and staging of poorly differentiated OSCC.

## NATURAL REMEDIES AND PHOTOBIO-MODULATION AGAINST IDIOPATHIC ORAL BURNING: A BRIEF OVERVIEW

Cabras M., De Paola S., Longhi F., Arduino P.G.

Department of Surgical Sciences, Oral Medicine Section, CIR-Dental School, University of Turin, Turin, Italy

**Aim:** to evaluate which experimental evidence is available for natural treatments and photobiomodulation as potential alternatives for persistent, idiopathic oral burning sensation.

**Methods:** a review of the literature was carried out. PubMed was the electronic database of choice. Inclusion criteria were: randomized controlled trials focused on the following therapeutic protocols against persistent, idiopathic oral burning sensation: photobiomodulation, alpha lipoic acid, vitamins, herbs, aloe vera, capsaicin, cognitive therapy, psychotherapy, and acupuncture. A concurrent search for narrative and/or systematic reviews previously published on this subject was pursued, for a bibliographic cross-check.

**Results:** 40 trials emerged; of these, 13 were on photobiomodulation, 10 on alpha-lipoic acid, 7 on herbs, 4 on capsaicin, 4 on acupuncture, 1 on cognitive therapy and 1 on psy-

chotherapy. Great heterogeneity among the various trials prevented statistical evaluations. Sample of patients varied greatly, as well as the evaluation scales developed for outcome assessment. Overall, the duration of these studies was of no more than 3-4 months, with very scarce information on the long-term efficacy of each proposed protocol. Psychological repercussions of the persisting oral symptoms were also scarcely detailed.

**Conclusion:** persistent, idiopathic oral burning sensation remains challenging for the oral physician. Photobiomodulation offers some encouraging evidence. The remaining natural remedies seem to provide contrasting, if not anecdotal, outcomes. Further studies are warranted, with a more robust methodology, deploying standardized scales for evaluation of oral burning and psychological status of patients.

## ELISA TEST IN ORAL BULLOUS DISEASES: DIAGNOSTIC SUPPORT AND CORRELATION WITH CLINICAL FORM

Canuti A.<sup>1</sup>, Gabusi A.<sup>1</sup>, Loi C.<sup>2</sup>, Gissi D.B.<sup>1</sup>, Luccarini L.<sup>1</sup>

<sup>1</sup>Department of Biomedical and Neuromotor Sciences, University of Bologna, Bologna, Italy

<sup>2</sup>Department of Experimental, Diagnostic and Specialty Medicine – DIMES, section of Dermatology, University of Bologna, Bologna, Italy

**Aim:** commercially available enzyme-linked immunosorbent assay (ELISA) test kit for Anti desmoglein 3 (Dsg3) and anti BP180 have been recently introduced in dermatology for serological diagnosis of Pemphigus and Pemphigoid diseases with good results. In this study the aim was to evaluate the utility of the ELISA test as a supportive tool in the diagnosis of autoimmune blistering diseases with oral involvement.

**Methods:** serological results for Dsg3 and BP180 of 26 patients (10 Pemphigus vulgaris, 12 Pemphigoid, 4 Oral Lichen Planus confirmed by Direct Immunofluorescence) have been studied. Diagnostic cut-off was set at 20 U/ml, while the clinical severity of Pemphigus and Pemphigoid was measured using the PDAI and BPDAI index (Pemphigus/ Bullous Pemphigoid Disease Area Index).

**Results:** ELISA test anti Dsg3 resulted positive in 9/10 patients with Pemphigus Vulgaris (Sensitivity 90%), while the serological research of BP180 resulted positive in 6/12 patients with Pemphigoid (Sensitivity 50%). 4/4 patients with OLP tested negative both for Dsg3 and BP180.

Anti BP180 titer resulted statistically correlated with clinical severity in patients with Pemphigoid ( $p = 0.0299$ ). No correlation was found in patients with Pemphigus.

**Conclusion:** Anti Dsg3 ELISA resulted highly sensitive in the diagnosis of Oral Pemphigus.

Despite low diagnostic sensitivity, antibody titer of anti BP180 ELISA emerged statistically correlated with clinical severity and may be useful in clinical management of patients with Pemphigoid disease.

## ANTIBODY-DRUG CONJUGATES: A SYSTEMATIC REVIEW OF *IN VITRO* STUDIES IN ORAL CANCER

Caponio V.C. A.<sup>1</sup>, Zhurakivska K.<sup>1</sup>, Troiano G.<sup>1</sup>, Arena C.<sup>1</sup>, Campisi G.<sup>2</sup>, Mascitti M.<sup>3</sup>, Lo Muzio L.<sup>1</sup>, Sala G.<sup>4</sup>, Perrotti V.<sup>5</sup>

<sup>1</sup>Department of Clinical and Experimental Medicine, University of Foggia, Foggia, Italy

<sup>2</sup>Sector of Oral Medicine, Department of Surgical, Oncological, and Oral Sciences (DiChirOnS), University of Palermo, Palermo, Italy

<sup>3</sup>Department of Clinical Specialistic and Dental Sciences, Marche Polytechnic University, Ancona, Italy

<sup>4</sup>Department of Innovative Technologies in Medicine and Dentistry, University of Chieti-Pescara, Chieti, Italy

<sup>5</sup>Department of Medical, Oral and Biotechnological Sciences, University of Chieti-Pescara, Chieti, Italy

**Aim:** oral squamous cell carcinoma (OSCC) represents the main type of cancer affecting head and neck region. Although new therapies (Cetuximab, Nivolumab, Pembrolizumab) have been approved, survival of these patients has not shown improvements. Moreover, general toxicity and adverse events have been reported. Antibody-drug conjugates (ADCs) are a new class of therapeutic molecules. ADCs consist of a small molecule with anticancer activity, linked to an antibody through a cleavable or non-cleavable linker. The antibody targets specifically an antigen found on the surface of cancer cells. Aim of this systematic review is to summarize the efficacy of ADCs in cell-line models of OSCC.

**Methods:** an electronic search was performed on PubMed database. Data about cell-line model, ADCs and efficacy were extracted. Risk of bias was assessed by Newcastle-Ottawa Scale.

**Results:** 114 studies were retrieved by electronic search and screened by title and abstract. In last instance, only 3 studies

resulted eligible to be included; 22 studies were excluded for the following reasons: not OSCC models or in-vivo models. Tongue was the most studied (HN-5, OSC-1, CAL-27, SCC-4, SCC-9, SCC-15 and SCC-25). Only Sweeny et al. used a floor of the mouth model – SCC-1. Three different ADC were tested, such as SPA470-doxorubicin, targeting HSP47/CBP2; EDC22, targeting CD147 and Idarubicin-ZHER2:342, targeting HER2. Cytotoxic assay was the main test used to assess the efficacy of ADCs, showing up to 80% in reduction of cell proliferation and viability.

**Conclusion:** ADCs are a new class of pharmacological molecules with promising cancer cytotoxic activity. Although a limited number of studies has been performed in OSCC models, results from this systematic review highlight their future application, which has to be furtherly explored by in-vivo and prospective studies.

## ORAL ADVERSE EVENTS IN NOVEL ANTINEOPLASTIC THERAPIES: BEYOND MUCOSITIS

Cornacchia A., Rupel K., Ottaviani G., Poropat A., Bogdan Preda M.T., Di Lenarda R., Biasotto M.

Department of Medical, Surgical and Health Sciences - S.C. of Maxillofacial Surgery and Odontostomatology of the Giuliano-Isontina Health Authority (ASUGI), Maggiore Hospital, Trieste, Italy

**Introduction:** Nivolumab and Pembrolizumab, monoclonal antibodies used in antineoplastic therapy, block PD-1 receptor that activates T cells against cancer.

Olaparib, a targeted therapy against uterus and breast cancers, blocks poly (ADP-ribose) polymerase (PARP) involved in damaged DNA repairmen. Although these therapies are effective against cancer, they have side effects scarcely known by oncologists and oral health specialists.

**Case reports:** 81-year-old male: treated with pembrolizumab for bladder cancer, was referred for dysgeusia and oral dryness. The objective examination showed objective xerostomia, whitish and brownish patina of the tongue. Culturing for oral candidiasis was negative. Biopsy of minor salivary glands highlighted severe hypotrophy and multiple fibrous septae. 60-year-old female: treated with nivolumab for renal carcinoma, was referred for stomatitis. Objective examination showed

reticular hyperkeratosis of buccal mucosa and lower lip. Culturing for oral candidiasis was negative. Biopsy showed a band-like lymphocytic infiltrate in dermis, degeneration of basal keratinocytes and eosinophils.

57-year-old female: treated with olaparib for mammary and ovarian carcinoma, was referred for oral and cutaneous (upper limbs and neck) brownish lesions. Objective examination showed macular lesions of gingiva, buccal mucosa, both lips, tongue and palate. Biopsy showed pigment deposits in dermis and epidermis of drug metabolite accumulation.

**Conclusion:** there is scarce literature on oral side effects of novel antineoplastic therapies. These cases of lichenoid lesions and xerostomia can be included among side effects of PD-1 inhibitors, as reported by published case reports. However, oral macular hyperpigmentations, following therapy with PARP1-inhibitors, have never been reported before.

## EARLY DETECTION OF ORAL CANCER: A CASE SERIES

del Rosso R., Lissoni A., Peri A., Polizzi E.M., Abati S.

IRCCS San Raffaele Hospital, Vita-Salute San Raffaele University, Milan, Italy

**Aim:** the aim of this case series is to highlight how a thorough intraoral examination can lead to an early detection of malignant lesions, even the subtle ones.

**Methods:** we present a case series consisting of three patients presenting small oral lesions that were believed to be benign by general dentists. However, after a specialistic evaluation at the Oral Pathology and Oral Medicine Unit, IRCCS San Raffaele Hospital, Dept. of Dentistry, a diagnosis of oral squamous cell carcinoma (OSCC) was made.

**Results:** the male to female ratio was 2:1, with a mean age of 66 years. The patients were non-smokers who had a moderate daily intake of alcoholic beverages, mainly wine. All were affected by hypertension.

Intraoral examinations were performed and small oral erythematous lesions (one lesion on the hard palate, and the remaining two on the borders of the tongue) were identified, biopsied, and sent for a histopathologic evaluation. The three bioptic specimens showed features compatible with OSCC, Gleason score 2.

**Conclusion:** general practitioners must remember that even the slightest change in the physiological appearance of tissues might be a sign of an underlying mutation process, therefore it is of utmost importance to detect said changes at an early stage and proceed with a biopsy. Besides, early detection is strongly correlated with a successful treatment and a better clinical prognosis making it an essential finding that should always be aimed for.

## EXTRAPLEURAL SOLITARY FIBROUS TUMORS REPORT OF A CASE IN MAXILLOFACIAL REGION

Di Pasquale R., Andrisani M., De Cicco C., Bernardi S., Varvara G., Piattelli M.

**Aim:** solitary fibrous tumor (SFT) is a spindle cells class of tumor usually occurring in the thorax, but literature widely reports occurrence at almost every anatomic site. Here we report a case of extrapleural solitary fibrous tumor occurring in the mucosal cheek. Case presentation: an 18 month old male patient presented a painless swelling on the left cheek area, with a smooth surface, fibrous consistency and slightly sliding on the surround tissues. The magnetic resonance imaging investigated the nature and the content of the lesion, which resulted homogeneous, roundish lesion of medium-low signal intensity, with regular margins, involving the left nasal fossa, the periorbital tissues and the homolateral middle turbinate.

**Results:** the planned surgical resection included an intra-oral approach, paying attention to the infraorbital nerve

Macroscopically the lesion appeared rounded, smooth, capsulated and measuring 2-3 cm. The immunohistochemical staining showed positivity for CD34 and CD99. The long term follows up 9 years after the operation showed no recurrence of the lesion.

**Conclusion:** 40% of SFTs in literature are extrapleural, mostly in the orbits and the soft tissues of the extremities. The buccal mucosa, the tongue and the lower lip are the more affected sites, when oral cavity is involved, leading to the suggestion that SFTs may be associated with trauma.

Complete surgical removal is the first treatment to choose. The most of the SFT lesions are considered benign tumor. If the margins of resection results positive, adjuvant radiation therapy is recommended.

## DEFINING THE HEALTHY ORAL MICROBIOME: WHOLEGENOME SEQUENCING AND RESISTOME ANALYSIS

Caselli E.<sup>1,2</sup>, Fabbri C.<sup>3</sup>, D'Accolti M.<sup>1,2</sup>, Soffritti I.<sup>1,2</sup>, Bassi C.<sup>4</sup>, Mazzacane S.<sup>2</sup>, Franchi M.<sup>3</sup>

<sup>1</sup>Section of Microbiology and Medical Genetics, Department of Chemical and Pharmaceutical Sciences, University of Ferrara, Ferrara, Italy

<sup>2</sup>CIAS Research Center, University of Ferrara, Ferrara, Italy

<sup>3</sup>Section of Dentistry, Department of Biomedical and Specialty Surgical Sciences, University of Ferrara, Ferrara, Italy

<sup>4</sup>NGS Service, Department of Morphology, Surgery and Experimental Medicine, University of Ferrara, Ferrara, Italy

**Aim:** to obtain a comprehensive view of the healthy oral microbiome (HOM), including its drug-resistance features.

**Methods:** the oral microbiome of twenty healthy subjects was analyzed by whole-genome sequencing (WGS) and real-time quantitative PCR microarray. For each subject, nine oral micro-habitat were sampled, including tongue dorsum, hard palate, buccal mucosa, keratinized gingiva, supra/sub-gingival plaque and saliva with or without rinsing.

**Results:** each sampled oral niche evidenced a different microbial community, including bacteria, fungi, and viruses. Alpha-diversity evidenced significant differences among the different sampled sites ( $p < 0.0001$ ) but not among the enrolled subjects ( $p = 0.876$ ), strengthening the notion of a recogniza-

ble HOM. Of note, oral rinse microbiome was more representative of the whole site-specific microbiomes, compared with that of not-rinsed-saliva. Interestingly, HOM resistome included highly prevalent genes conferring resistance to macrolide, lincosamides, streptogramin, and tetracycline.

**Conclusion:** the data obtained provide for the first time a comprehensive view of HOM and its resistome, contributing to a deeper understanding of the composition of oral microbiome in the healthy subject, and providing an important reference for future studies, allowing to identify microbial signatures related to functional and metabolic alterations associated with diseases, potentially useful for targeted therapies and precision medicine.

## CONCORDANCE IN UHFUS ASSESSMENT OF MINOR SALIVARY GLANDS

Izzetti R.<sup>1</sup>, Nisi M.<sup>1</sup>, Grasso E.<sup>1</sup>, Gennai S.<sup>1</sup>, Fulvio G.<sup>2</sup>, Ferro F.<sup>2</sup>, Caramella D.<sup>3</sup>, Baldini C.<sup>2</sup>, Graziani F.<sup>1</sup>

<sup>1</sup>Unit of Dentistry and Oral surgery, Department of Surgical, Medical and Molecular Pathology and Critical Care Medicine, University of Pisa, Pisa, Italy

<sup>2</sup>Unit of Rheumatology, Department of Clinical and Experimental Medicine, University of Pisa, Pisa, Italy

<sup>3</sup>Diagnostic and Interventional Radiology, Department of Translational Research and of New Technologies in Medicine and Surgery, University of Pisa, Pisa, Italy

**Aim:** to test the inter-reader concordance in the score assignment of minor salivary glands UHFUS in patients with suspected primary Sjögren Syndrome (pSS).

**Methods:** 170 minor salivary glands UHFUS of patients with suspected pSS were retrieved and exported as anonymized DICOM files. Three independent readers performed UHFUS images evaluation using the OMERACT scoring system. Score 0 was assigned in absence of glandular alterations, score 1 corresponded to the presence of mild glandular alteration, with fine echogenicity, or slight, diffuse glandular hypoechogenicity, score 2 presented moderate glandular alteration, with the presence of focal hypoechoic areas, but partial conservation of normal glandular parenchyma, and score 3 was assigned in cases of severe glandular alteration, with diffuse

presence of hypoechoic areas in the absence of normal glandular parenchyma or presence of glandular fibrosis. The concordance between examiners was assessed using Cohen k.

**Results:** overall concordance between readers reached the 83.1%. Higher values were encountered in the assignment of scores 0 and 1, with a concordance of 93.8% and 95.8% respectively. In Score 2, 87.1% concordance was found. Interestingly, in Score 3 the lowest concordance rates were found, with a value of 53.8%, as a tendency to underestimate glandular alteration was found.

**Conclusion:** according to these results, UHFUS interpretation shows good inter-observer reliability, suggesting that OMERACT score can be effectively used for the evaluation of glandular alterations even for minor salivary glands.

## CORRELATION BETWEEN COFFIN-SIRIS SYNDROME AND ORAL MANIFESTATIONS? A CASE REPORT

Inchingolo A.D.<sup>1</sup>, Marinelli G.<sup>2</sup>, Dell'olio F.<sup>1</sup>, Barile G.<sup>1</sup>, De Giglio N.<sup>1</sup>, Inchingolo F.<sup>2</sup>, Favia G.<sup>1</sup>

Complex Operative Unit of Odontostomatology Director: Prof. G. Favia

<sup>1</sup>Specialization School of Oral Surgery, Director Prof. G. Favia, Interdisciplinary Department of Medicine D.I.M. University of Bari Aldo Moro, Bari, Italy

<sup>2</sup>Specialization School of Orthognatodontics, Director Prof. F. Inchingolo, Interdisciplinary Department of Medicine D.I.M. University of Bari Aldo Moro, Bari, Italy

**Aim:** Coffin-Siris Syndrome is a rare congenital multisystem syndrome caused by heterozygous mutations or genomic rearrangement in genes encoding subunits of the BAF chromatin-remodelling complex, which is involved in the regulation of gene expression during development. This syndrome is characterized by aplasia or hypoplasia of the distal phalanx or nail of the fifth finger, distinctive facial features, development delay, behavioral abnormalities. Malformations of the cardiac, gastrointestinal, genitourinary and/or central nervous systems may also be present.

The aim of this work is to describe intra-oral pathological conditions that may be manifestations of the syndrome.

**Case presentation:** a 39 y.o. male patient affected by Coffin-Siris Syndrome came to the attention of our Operating Unit of Odontostomatology suffering widespread odontalgia associated to dental mobility. This uncooperative patient presented

mental delay and typical coarse facial features. The intraoral examination revealed the presence of inflammatory gingivitis, accumulations of plaque and tartar, anomalies of shape (lateral conoid incisors) and number of teeth (hypodontia), with related mobility of some of them, occlusal abrasions caused by bruxism, macroglossia.

Rx OPT confirmed anomaly shape of the molars compatible with taurodontism, early atypical rhizalysia that caused the teeth mobility, dental inclusions, agenesis.

After collection of anamnestic data and anesthetic evaluation (ASA II), tartar was removed and movable teeth were extracted under general anesthesia.

**Conclusion:** our case highlighted the presence of multiple dental abnormalities that could be associated with Coffin-Siris Syndrome; further studies involving a larger sample of patients will be needed to confirm this correlation

## BRUXISM IN CHILDREN AND ADOLESCENTS WITH DOWN SYNDROME: A COMPREHENSIVE REVIEW

E. Luconi<sup>1</sup>, M. Mascitti<sup>1</sup>, A. Tesei<sup>2</sup>, L. Togni<sup>1</sup>, A. Barlattani<sup>3</sup>, O. Di Fede<sup>4</sup>, M. Iurato Carbone<sup>4</sup>, C. Arena<sup>5</sup>, A. Santarelli<sup>1</sup>

<sup>1</sup>Department of Clinical Specialistic and Dental Sciences, Marche Polytechnic University, Ancona, Italy

<sup>2</sup>Department of Surgical and Special Odontostomatology, Umberto I General Hospital, Ancona, Italy

<sup>3</sup>Department of Clinical Sciences and Translational Medicine, Tor Vergata University, Rome, Italy

<sup>4</sup>Department of Surgical, Oncological and Oral Sciences (DiChirOnS), University of Palermo, Palermo, Italy

<sup>5</sup>Department of Clinical and Experimental Medicine, University of Foggia, Foggia, Italy

**Aim:** the role of bruxism in children and adolescents with Down Syndrome (DS), the most often diagnosed congenital syndrome, is still unclear. This study aims to conduct a comprehensive review of the literature about bruxism in children and adolescents with Down syndrome to identify the prevalence, risk factors, and possible treatments of this disorder.

**Methods:** literature research was performed on the major electronic databases for studies published until 31st December 2020: PubMed, Scopus, Web of Science, and Google scholar databases.

**Results:** there were initially identified 11 studies on PubMed, 20 on Scopus, 6 on Web of Science, and 986 on Google scholar. Of these articles, 16 were assessed for eligibility. Four additional articles were retrieved from the bibliographic references.

Although an accurate estimate of its prevalence could not be inferred, it appears that bruxism is more prevalent in DS individuals rather than in the general pediatric population. No sex difference was observed, but a reduction in its prevalence was described with increasing age. The variability in the diagnostic techniques contributed to the heterogeneity of the literature data. Clinic-pathological features of DS, such as muscle spasticity, oral breathing, and predisposition to obstructive sleep apnea, may suggest the higher prevalence of bruxism in these patients.

**Conclusion:** given the paucity of studies on the management of bruxism in this population, it was not possible to outline a standard protocol for the non-invasive treatment of cases in which an observational approach is not sufficient.

## THE PROGNOSTIC ROLE OF LYMPHOVASCULAR INVASION IN ORAL SQUAMOUS CELL CARCINOMA

Mascitti M.<sup>1</sup>, Togni L.<sup>1</sup>, Procaccini M.<sup>1</sup>, Aquilanti L.<sup>1</sup>, Rappelli G.<sup>1</sup>, Panzarella V.<sup>2</sup>, Troiano G.<sup>3</sup>, Lo Muzio L.<sup>3</sup>, Santarelli A.<sup>1</sup>

<sup>1</sup>Department of Clinical Specialistic and Dental Sciences, Marche Polytechnic University, Ancona, Italy

<sup>2</sup>Department of Surgical, Oncological, and Oral Sciences (DiChirOnS), University of Palermo, Palermo, Italy

<sup>3</sup>Department of Clinical and Experimental Medicine, University of Foggia, Foggia, Italy

**Aim:** oral squamous cell carcinoma (OSCC) is the most common head and neck malignancy, characterised by poor prognosis. Novel prognostic markers are needed to better stratify these patients. Lymphovascular invasion (LVI) has been included in the 8th edition of AJCC Cancer Staging Manual as an additional prognostic factor, but its influence on recurrence risk and lymph node metastasis is relatively understudied. This is a comprehensive review of literature regarding the clinical and prognostic role of LVI in OSCC.

**Methods:** a relevant search of PubMed, Scopus, Web of Science databases yielded 29 articles that satisfied the inclusion criteria.

**Results:** findings indicated that LVI is an independent negative prognostic factor in OSCC patients and appears associated to

cervical lymph-node metastases and locoregional recurrence. Notably, in oral tongue cancer survival outcomes progressively worsen when LVI is associated with others adverse pathological features, especially in early stages. Therefore, these patients could benefit from elective neck dissection and/or adjuvant therapy. The highly variability of LVI prevalence hindering the comparison of literature results.

**Conclusion:** several methodological limitations are present on the collected articles, such as the lack of a rigorous definition for LVI, the difficult detection in routine histological section, the presence of potential confounders, the retrospective nature and the inadequate sample size used in most studies. Therefore, it is necessary to conduct prognostic studies using standardized methods to define and quantify LVI.

## METHOTREXATE STOMATITIS: REPORT OF THREE CASES AND SYSTEMATIC REVIEW OF LITERATURE

Nisi M., Izzetti R., Mattiozzi M., Gennai S., Graziani F.

Department of Surgical Pathology, Medicine, Molecular and Critical Area, University of Pisa, Pisa, Italy

**Aim:** methotrexate (MTX) is an antimetabolic drug used to treat both benign conditions and malignancies. As a folic acid analog, MTX interferes with the synthesis of DNA bases by inhibiting enzymes of the folate pathway, especially dihydrofolate (DHF) reductase. Methotrexate is commonly administered to improve the symptoms of rheumatoid arthritis through its anti-inflammatory effects. However, there are many reports on the adverse effects of MTX therapy. In particular, oral ulcers may appear in 11%-17% of patients treated with MTX at low doses.

**Methods:** in this report, we described three cases of ulcerative stomatitis in patients with longstanding arthritis treated with low dose methotrexate in the absence of a lymphoproliferative disorder. A literature review was performed to identify all cases of intraoral localized MTX-related ulcerative stomati-

tis and to investigate the characteristics and prognosis of these cases.

**Results:** in case 1, mucositis was caused by an unintended MTX overdose, while in cases 2 and 3 oral lesions were the result of chronic MTX toxicity. In cases 1 and 2 ulcerations involved lip and buccal mucosa, while in case 3 the lesions were localized on the floor of the mouth. After consultation with the rheumatologist, the MTX was discontinued, and folic acid was prescribed. The stomatitis and related symptoms resolved 1 month later. In the present literature, 24 cases of MTX ulcerative stomatitis were reported.

**Conclusion:** as shown in the cases presented, oral mucosal lesions can be an early indicator of severe underlying systemic disorders. An increase of oral toxicity in patients receiving low-dose MTX therapy can be anticipated due to the limited supply of antagonistic drugs.

## DRUG-INDUCED GINGIVAL OVERGROWTH: AN *IN VITRO* STUDY

Lauritano D.<sup>1</sup>, Moreo G.<sup>1</sup>, Palmieri A.<sup>2</sup>, Carinci F.<sup>3</sup>, Baldoni M.<sup>1</sup>

<sup>1</sup>Department of Medicine and Surgery, Centre of Neuroscience of Milan, University of Milano-Bicocca, Milan, Italy

<sup>2</sup>Department of Experimental, Diagnostic and Specialty Medicine, University of Bologna, Bologna, Italy

<sup>3</sup>Department of Morphology, Surgery and Experimental Medicine, University of Ferrara, Ferrara, Italy

**Aim:** anticonvulsants, immunosuppressants and calcium channel blockers represent three classes of systemic drugs, whose chronic administration may be related to the onset of gingival enlargement. This study aimed to investigate how cyclosporin A and mycophenolate mophetil, immunosuppressant drugs, could affect human gingival fibroblasts functions, leading to drug – induced gingival overgrowth (DIGO).

**Methods:** human gingival fibroblasts derived from the tissue of a 60-year-old female were cultured in a DMEM medium. A stock solution with 1 mg/mL of mycophenolate and 1 mg/mL of cyclosporine were prepared and dissolved in a DMEM medium to prepare a serial dilution at the concentrations of 5000, 2000, 1000, 500, and 100 ng/mL, for both treatments. Cell viability was measured using the PrestoBlue™ Reagent Protocol and the expression profile of 57 genes coding for gingival fi-

broblasts “Extracellular Matrix and Adhesion Molecules” was analyzed using Quantitative Real-time RT-PCR.

**Results:** treated cells were similarly affected by both molecules: most extracellular matrix metalloproteases genes showed downregulation (MMP8, MMP11, MMP15, MMP16, MMP24), while CDH1, ITGA2, ITGA7, LAMB3, MMP12, and MMP13 were recorded to be upregulated. Mycophenolate and cyclosporine had no effect on fibroblast cell viability at 1000 ng/mL.

**Conclusion:** the obtained data demonstrated that the chronic administration of cyclosporin A and mycophenolate mophetil can contribute to the onset of gingival overgrowth. However, given the contrasting data of literature, further investigations are needed, in order to clarify the possible effects of immunosuppressive drugs on fibroblasts.

## ORAL HEALTH AND SARCOPENIA AMONG INSTITUTIONALIZED ELDERLY: A CROSS-SECTIONAL STUDY

Aquilanti L.<sup>1</sup>, Vignini A.<sup>1</sup>, Moreschi R.<sup>1</sup>, Rappelli G.<sup>1,2</sup>

<sup>1</sup>Department of Clinical Specialistic and Dental Sciences, Marche Polytechnic University, Ancona, Italy

<sup>2</sup>Dentistry Clinic, National Institute of Health and Science of Ageing, IRCCS INRCA, Ancona, Italy

**Aim:** the aim of the study was to assess oral health status and the prevalence of sarcopenia in aged care facilities residents, improving awareness among caregivers about the importance of preventing malnourishment and poor oral conditions.

**Methods:** elderly living in a residential aged care facility were enrolled. Individual sociodemographic data, nutritional and oral health data were collected. For sarcopenia diagnosis, muscle mass, physical performance, muscle strength and anthropometric parameters were recorded. Participants underwent a food interview and a dental examination: Mini Nutritional Assessment and masticatory mixing ability test were performed, respectively.

**Results:** thirty-two adults aged  $\geq 65$  years were enrolled. A high prevalence of subjects diagnosed as being at risk of de-

veloping sarcopenia or of being sarcopenic was assessed. Males recorded a hand strength significantly higher than females,  $25.5 \pm 7.2$  kg vs  $12.8 \pm 5.9$  kg, respectively ( $p < 0.01$ ). Gait speed test showed that only 20.8% of the participants had a speed of more than 0.8m/s. A strong negative correlation was detected between missing teeth and masticatory performance ( $r = -0.84$ , 95% CI [-0.92; -0.69],  $p < 0.01$ ). No significant associations were found among masticatory performance and the other studied parameters ( $p > 0.05$ ).

**Conclusion:** the reduction of the musculoskeletal mass and of masticatory performance could be responsible of the worsening of clinical status. Regular diet, specific physical activity and oral health preventive programs should be crucial goals to be pursued in aged care facilities residents.

## INVOLVEMENT OF ORAL MICROBIOTA IN ORAL SQUAMOUS CELL CARCINOMA (OSCC): A SYSTEMATIC REVIEW

Pignatelli P.<sup>1,2</sup>, Romei F. M.<sup>1</sup>, Bondi D.<sup>3</sup>, Petrini M.<sup>1</sup>, Tumedei M.<sup>1</sup>, Piattelli A.<sup>1,4</sup>, Iezzi G.<sup>1</sup>, Curia M.C.<sup>1</sup>

<sup>1</sup>Department of Medical, Oral and Biotechnological Sciences, University G. D'Annunzio of Chieti-Pescara, Chieti, Italy

<sup>2</sup>Department of Oral Sciences and Maxillofacial Surgery, Sapienza University of Rome, Rome, Italy

<sup>3</sup>Department of Neuroscience, Imaging and Clinical Sciences, University G. D'Annunzio of Chieti-Pescara, Chieti, Italy

<sup>4</sup>Villa Serena Foundation for Research, Città Sant'Angelo, Pescara, Italy

**Aim:** dysbiosis may influence the progression of oral squamous cell carcinoma (OSCC) via microbial toxins, modulating host immune response, sustaining inflammation, and altering the  $\beta$ -Catenin pathway. The aim of the study was to identify a microbial model associated with OSCC that may have clinical potential regarding biomarkers for early detection or intervention.

**Methods:** articles were searched in Medline/PubMed, Science Direct, Google Scholar, Scopus between January 2011 and January 2021 with key terms "oral microbiota" OR "oral bacteria" AND "oral squamous cell carcinoma" OR "OSCC". The PICO question used to formulate the search strategy was: "What are the oral bacteria in patients with oral squamous cell carcinoma (OSCC) compared with healthy subjects?". In vivo studies assessing the compositional profile microbiota using Next Generation Sequencing (NGS) with full text available were included. Risk of bias assessment of the included studies was performed.

**Results:** the system selection provided a total of 1239 papers. Initially, 48 full-text articles were identified; after taking into consideration of inclusion/exclusion criteria, 19 articles were included. The analysis revealed that *F. nucleatum*, *C. morbi*, *P. stomatis*, *F. naviforme*, *C. showae*, *P. micra*, *P. intermedia* were the most representative bacteria in OSCC tissue specimens regardless of anatomical site. Instead, *C. gingivalis*, *C. ochracea*, *P. catoniae*, *P. endodontalis*, *P. melaninogenica* increased in the saliva. Microbial community in saliva changed in a group manner and no single bacterium could be proposed as a potential biomarker to the oral carcinogenesis transition.

**Conclusion:** the microbiota of saliva differed from microbiota of oral cancer tissue in terms of community structure. Microbial community could be a biomarker in the early diagnosis of oral carcinoma.

## ACROMEGALY AND DENTISTRY: AN IMPORTANT BUT STILL LITTLE CONSIDERED RELATIONSHIP

Preo G.<sup>1</sup>, De Stefani A.<sup>2</sup>, Bruno G.<sup>2</sup>, Gracco A.<sup>3</sup>, Stellini E.<sup>4</sup>

<sup>1</sup>Undergraduate student, University of Padua, Padua, Italy

<sup>2</sup>DDS, Faculty of Dentistry, University of Padua, Padua, Italy

<sup>3</sup>Associate professor, Faculty of Dentistry, University of Padua, Padua, Italy

<sup>4</sup>Professor, Department of Neuroscience, School of Dentistry, University of Padua, Padua, Italy

**Aim:** acromegaly is a rare disease characterized by an excessive and continuous secretion of growth hormone and an increase in circulating concentrations of insulin-like growth factor 1. Among the physical characteristics that the patients manifest early, there are alterations of some parts of the face and the oral cavity. Our study aims to evaluate patients' perception of the physical changes related to the syndrome and to evaluate the relation between acromegaly and dentistry.

**Methods:** seventeen patients treated in the endocrinology department of the Hospital of Padua were recruited in the study. We first visited the acromegalic patients and shot pictures of their oral cavity and face, then we submitted an anonymous

questionnaire to the patients, with the aim of investigating their personal clinical experience.

**Results:** all patients perceived physical changes to their face and oral cavity due to the syndrome but also reported that in most cases these changes were ignored by the medical figures who visited them.

**Conclusion:** according to literature, the figure of the dentist is not significant for diagnosis of acromegaly, despite there being a high prevalence of oral symptoms among this type of patients. Greater awareness of acromegaly's typical signs and symptoms among dentists is essential and an early recognition of them by healthcare professionals would reduce the time required for diagnosis.

## DNA METHYLATION ANALYSIS FROM ORAL BRUSHING AS ORAL CANCER RISK INDICATOR: A CASE REPORT

Rossi R.<sup>1</sup>, Morandi L.<sup>2</sup>, Tarsitano A.<sup>3</sup>, Servidio D.<sup>1</sup>, Felicetti L.<sup>1</sup>, Gabusi A.<sup>1</sup>, Gissi, D.B.<sup>1</sup>

<sup>1</sup>Section of Oral Sciences, DIBINEM, University of Bologna, Bologna, Italy

<sup>2</sup>Functional MR Unit, IRCCS ISNB, DIBINEM, University of Bologna, Bologna, Italy

<sup>3</sup>Section of Maxillofacial Surgery, DIBINEM, University of Bologna, Bologna, Italy

**Aim:** we describe the potential application of a procedure based on 13-gene DNA methylation analysis from oral brushing in a patient affected by an Oral Leukoplakia (OL) who developed two metachronous oral squamous cell carcinomas (OSCCs) during the follow up period.

**Methods:** in December 2016 we diagnosed an OL without presence of dysplasia in a 68 years-old man. In April 2019 the patient developed a primary OSCC and in May 2020 a secondary oral neoplasia. 13-gene DNA methylation analysis was applied in four different moments: at the time of OL diagnosis in the surface of white lesion, in concomitance with the biopsy which led to the diagnosis of the index OSCC in the dyshomogeneous and proliferative area (April, 2019), six months after the primitive OSCC surgical removal in the regenerative area

after primary OSCC resection (October, 2019) and in the tumor mass when the secondary tumor appeared (May, 2020). Each sample was determined as positive based on a predefined cutoff value (> 1.0637).

**Results:** a positive score was calculated in the specimens collected from primary (score 5.21) and secondary OSCC (score 8.14). A positive score was also determined in the OL lesion (score 1.61) 28 months before development of primary OSCC and in the regenerative clinically healthy mucosa 8 months before appearance of second OSCC (1.85).

**Conclusion:** in the present case, DNA methylation analysis from oral brushing showed not only a diagnostic value but also a promising predictive power, suggesting a potential role of our procedure as oral cancer risk indicator.

## COMPARISON OF PROTOCOLS FOR THE ORAL LICHEN PLANUS TREATMENT: A RANDOMIZED CLINICAL TRIAL

Santonocito S., Polizzi A., Ronsivalle V., Lo Giudice A., Isola G.

Department of General Surgery and Surgical-Medical Specialties, School of Dentistry, University of Catania, Catania, Italy

**Aim:** topical application of clobetasol propionate oral gel is the first-line treatment in symptomatic oral lichen planus (OLP). However, prolonged use may induce oral mucosal atrophy and oral candidiasis. The aim of this randomized clinical trial was to compare the therapeutic efficacy of clobetasol propionate oral gel 0.05% versus an anti-inflammatory in oral solution (mouthwash), for which no contraindications to long-term use have been reported, in the management of patients suffering from symptomatic OLP.

**Methods:** forty patients, who met the criteria for inclusion in the study, were selected to participate in the randomized clinical trial. Each patient, through a randomized design, was assigned to a treatment protocol: clobetasol propionate oral gel (20 patients) or anti-inflammatory in oral solution, which contains calcium hydroxide, hyaluronic acid, Umbelliferone and Oligomeric Proanthocyanidins (20 patients). At

baseline (T0) and after 3 months (T1), patients underwent dental and dermatological examinations to assess the intensity of symptoms using the Numerical Pain Scale (NRS) and the severity of signs using the Thongprasom Score. Data were calculated using T-test for the dependent variable, Wilcoxon test and Mann-Whitney u test.

**Results:** both clobetasol and anti-inflammatory in a statistically significant reduction of signs ( $p < 0.001$  and  $p = 0.02$ , respectively) and symptoms ( $p < 0.001$  and  $p = 0.02$  respectively).

**Conclusion:** the results showed that both treatments were effective in improving the signs and symptoms of the disease. However, clobetasol was shown to have a greater ability to induce remission of signs in subjects with severe forms of OLP (Thongprasom Score  $> 2$ ) respect the anti-inflammatory (mouthwash) that has shown a limited ability to induce remission of signs in subjects with severe forms of OLP.

## DIAGNOSTIC ACCURACY IN ORAL MEDICINE: A CASE REPORT OF NECROTIZING SIALOMETAPLASIA

Caggiano M., Scognamiglio B., Amato A., Acerra A., Pisano M., Sisalli L.

Department of Medicine, Surgery and Dentistry, Scuola Medica Salernitana, University of Salerno, Baronissi, Italy

**Aim:** the aim of this study was to show a case of Necrotizing Sialometaplasia (NS) localized in the posterior hard palate of a bulimic patient and to highlight that a correct clinical approach is mandatory for the diagnosis in case of suspected and uncommon oral lesion.

**Methods:** a 21-year-old female patient presented a single crater-like ulcer with well-defined, hardened and elevated margins located in the posterior region of the left hemi-palate that had lasted for 15 days. At the anamnestic investigation the patient claimed she was bulimic, with an average of 6-8 episodes of self-induced vomiting per week. For diagnostic purposes, maxillo-facial computed tomography scan and blood chemistry screening tests were prescribed and an incisional biopsy was performed.

**Results:** CT scan showed the absence of bone lesion of the palatine vault. Blood screening tests showed higher than normal transaminase and amylase levels, no other metabolic or mitochondrial disease or systemic disorders were detected. Histopathological examination of incisional biopsies showed lobular necrosis with associated areas of squamous metaplasia of the ductular epithelium of the minor salivary glands involved, report compatible with the diagnosis of NS.

**Conclusion:** considered the anatomopathological and clinical aspects, the diagnosis of NS is still a challenge for the clinician. A correct collection of medical history and a matching of clinical and histological data allow to correctly handle the clinical case, excluding neoplastic or infectious pathologies and directing the diagnosis to the correct path.

## ODONTOGENIC KERATOCYST SIMULATING A NASOPALATINE DUCT CYST: A CASE REPORT

Serni L., Cavuoto M., Parisi E.

Postgraduate School of Oral Surgery, University of Florence, Florence, Italy

**Aim:** the Odontogenic Keratocyst (OKC) is a distinctive form of developmental odontogenic cyst that deserves special consideration because of its specific histopathologic features and clinical behavior, in particular, high growth potential and recurrence rate.

The aim of this study is to describe a case of OKC showing unusual clinical and radiographic features, mimicking a Nasopalatine Duct Cyst (NDC).

**Methods:** this case report was retrospectively conducted. Patient's medical record data, surgical procedure details, radiographic and histopathologic images were collected.

**Results:** a rare case of OKC manifested in a 52-year-old male, systemically healthy, non-smoker patient is reported. The lesion was asymptomatic but clinically detectable as a hard-elastic swelling of the vestibular alveolar mucosa in the midline maxillary region. A preoperative CBCT was then prescribed, showing a lesion of 1,2 x 0,7 x 1,1 cm in size, between the upper central

incisors, with no root resorption, in contact with and anterior to the Nasopalatine Duct, simulating the usual radiographic features of an NDC. The surgical enucleation with a vestibular approach and a perilesional ostectomy was performed. The histopathology report issued the definitive diagnosis of OKC, in which the peculiar features of the lesion were present: a palisaded, basal epithelial cell layer and a wavy, parakeratotic, luminal surface. A 15-months-follow-up CBCT showed an area of radiolucency at the surgical site, probably due to a slow bone healing even if the relapse hypothesis cannot be excluded a priori. Thus, the patient will continue to undergo periodic clinical and radiographic follow-ups.

**Conclusion:** OKC can occur, even if rarely, also in the anterior midline maxillary region, entering into differential diagnosis with the NDC. Therefore, the definitive diagnosis is always histological. Considering the relatively high recurrence rate, OKC follow-up is mandatory.

## A NEW ORAL LESION BY REGORAFENIB: A CASE REPORT

Sisalli L., Caggiano M., Spirito F., Amato A., Amato M.

Department of Medicine, Surgery and Dentistry, Scuola Medica Salernitana, University of Salerno, Baronissi, Italy

**Aim:** to describe a not yet reported in literature effect of Regorafenib on the oral mucosa of a patient in cancer treatment.

**Methods:** a 54 y.o. male patient previously operated for colorectal cancer with hepatic and pelvic recurrence and treated with Regorafenib, reported orodynia in contact with hot food and palmar-plantar erythrodysesthesia (Hand Foot Skin Reaction-HFSR), for about six months. A systematic clinical and neurological examination of the mouth and the cranial nerves was performed. The patient was demitted with control at 15 days.

**Results:** clinical examination of the oral cavity revealed the presence of keratotic lesions, absent before treatment with Regorafenib, localized on the right and left lingual margins and on the right ventral surfaces. No morphological and / or chro-

matic lesions in other districts were observed, salivary flow was normal for quantity and quality, neurological examination of the cranial nerves resulted negative. After 15 days the clinical aspect of the oral lesion was unvaried, but it was not possible to perform a biopsy due to the systemic conditions worsening.

**Conclusion:** Regorafenib is a multi-targeting kinases inhibitor that can cause adverse effects in the oral cavity. Those described in the literature are 12% dysesthesia without clinical signs (when present there is an increased risk of HFSR), mucositis, dysgeusia-hypogeusia and xerostomy. Inhibitory action on BRAF kinase, responsible for controlling cell proliferation, may be the basis of the genesis of the keratotic lesion found in the oral cavity of this patient.

## NON-LASER PHOTOBIMODULATION AND BENZODIAZEPINES IN BMS MANAGEMENT

Tateo D., Lilli D., Magri C., Ventura N.

Department of Oral Pathology, School of Dentistry, University of Bari, Bari, Italy

**Aim:** the aim of this study was to compare a photobiomodulation device (Biopton™) used as light therapy and Benzodiazepines (BDZ) in burning mouth syndrome (BMS) treatment.

**Methods:** clinical and demographical data of 43 patients with a clinical diagnosis of BMS were randomized in two split groups. Group A was treated with Biopton™ light therapy, whereas group B was treated with BDZ. Visual Analogue Scale (VAS) was used to assess the therapeutic effects of the given treatments in both groups. Outcomes were recorded at the beginning of the treatment (t0) and at the end (tf).

**Results:** reduction of VAS was recorded in both groups with a significant improvement ( $p < 0.05$ ). In Group A, the VAS decreased significantly (t0: 7.07: tf: 4.64). Also, in group B, mean

VAS decreased significantly from 7.52 to 6.41. This study does not show a statistically significant difference between the two therapies ( $P = 0.064$ ;  $p > 0.05$ ).

**Conclusion:** results of the present study showed that both treatment were effective in reducing the patient-perceived pain and discomfort, although Biopton™ light treatment showed a slightly bigger reduction in VAS points. As Biopton™ light therapy has no known side-effects, and is a non-invasive procedure, this can allow for management of BMS patients in which customary medicaments with BZD may not be feasible. Further studies may focus on using light therapy and pharmaceuticals in combination, to try and understand if they may work better together in helping BMS patients.

## IMMUNOHISTOCHEMICAL DETECTION OF BRAF V600E MUTATION IN AMELOBLASTOMA

Togni L.<sup>1</sup>, Mascitti M.<sup>1</sup>, Rubini C.<sup>2</sup>, Procaccini M.<sup>1</sup>, Barlattani A.<sup>3</sup>, Mauceri R.<sup>4</sup>, Caponio V.C.A.<sup>5</sup>, Lo Muzio L.<sup>5</sup>, Santarelli A.<sup>1</sup>

<sup>1</sup>Department of Clinical Specialistic and Dental Sciences, Marche Polytechnic University, Ancona, Italy

<sup>2</sup>Department of Biomedical Sciences and Public Health, Marche Polytechnic University, Ancona, Italy

<sup>3</sup>Department of Clinical Sciences and Translational Medicine, Tor Vergata University, Rome, Italy

<sup>4</sup>Department of Surgical, Oncological and Oral Sciences (DiChirOnS), University of Palermo, Palermo, Italy

<sup>5</sup>Department of Clinical and Experimental Medicine, University of Foggia, Foggia, Italy

**Aim:** the ameloblastoma is the most frequent odontogenic tumor. Despite its benign nature, the local aggressiveness and a high recurrence rate characterize some entities. Literature data suggest the BRAF V600E mutation is involved in 46-82% of ameloblastomas, offering a biological rationale for developing new therapeutic strategies. The study aims to evaluate the correlations between the presence of BRAF V600E mutation and the clinicopathological data in a cohort of ameloblastoma patients.

**Methods:** 50 ameloblastomas were subjected to immunohistochemical analysis using VENTANA anti-BRAFV600E Mouse Monoclonal Primary Antibody. A uniform, cytoplasmic staining of viable tumor cells was considered as “positive” staining. Differences among ameloblastoma groups were established by

Chi-square and Mann-Whitney tests. A p-value  $< 0.05$  was accepted as significant.

**Results:** the 46% of ameloblastomas harbored the BRAF V600E mutation. Its presence was significantly associated with the mandibular site ( $p = 0.0004$ ) and unicystic histotype ( $p = 0.0383$ ). All BRAF unicystic ameloblastomas arose in the mandible ( $p < 0.0001$ ). There was a trend between the presence of BRAF and the late onset of recurrent ( $p = 0.0521$ ), without reaching a significance difference in term of disease-free survival time.

**Conclusion:** our results suggest the MAP-kinase pathway could contribute on ameloblastic tumorigenesis. Moreover, they could indicate the anatomical specificity of the driving mutations of mandibular tumors, providing a biological rationale for developing new targeted therapies.

## ORAL LESIONS DURING SARS-COV-2 INFECTION: A CLINICAL STUDY ON 273 HOSPITALIZED PATIENTS

Barile G.<sup>1</sup>, Acella V.<sup>2</sup>, Casorelli A.<sup>2</sup>, Dell'olio F.<sup>1</sup>, Mezzapesa P.<sup>1</sup>, Vestito M. C.<sup>3</sup>

<sup>1</sup>Specialization School of Oral Surgery; Department of Interdisciplinary Medicine, University of Bari Aldo Moro, Bari, Italy

<sup>2</sup>Department of Interdisciplinary Medicine, Aldo Moro University of Bari Aldo Moro, Bari, Italy

<sup>3</sup>Covid-19 Intensive Care Unit, Department of Interdisciplinary Medicine, University of Bari Aldo Moro, Bari, Italy

**Aim:** since identification in Wuhan, China, in December 2019, Sars-Cov-2 disease has spread all over the world, changing human habits forever. Millions of people were involved with different severity, from asymptomatic cases to death. Sars-Cov-2 infection lead to multi-organ implication: many case reports in literature described oral manifestation. Aim of this study is to describe a large sample composed by patients affected by Coronavirus disease presenting oral manifestation.

**Methods:** inclusion criteria were: patients with nasal and oropharyngeal molecular swabs positive to Sars-Cov-2 and patients with severe form hospitalized in First Aid, Emergency and Intensive Care units from December 2020 to February 2021.

General, specialistic and pharmacological anamnesis were collected, including quality of oral hygiene. Extraoral and intraoral examination was conducted with a 1000 Lumens specific torch and common first visit dental kit.

**Results:** 273 patients were visited, 152 males (56%) and 121 females (44%).

Most common lesion were ulcers: 158 (58%), which could be single or multiple, followed by hyperplasia of papillae present in 104 patients (38%), often associated with taste disorders. Candidiasis was showed by 62 patients (23%), probably due to prolonged antibiotic therapies. 41 patients (15%) showed blisters while 30 patients (11%) showed petechiae. Angina bullosa was present in 23 patients (8%), in all cases after therapies. Atrophic glossitis is a very common finding presented by 197 patients (72%) probably due to dry oxygen of non-invasive ventilation.

**Conclusion:** this retrospective observational study described oral lesion in patients affected by Sars-Cov-2 with severe-critical form of illness. Further study may be conducted to establish the real etiopathogenetic cause of this great variety of lesion.

## PHOTOBIMODULATION WITH OR WITHOUT APPLICATION OF CBPG IN THE THERAPY OF PATIENTS WITH EB

Basiglio L., Vallone V., Astesano S., Sindici E., Arduino P.G., Cafaro A., Broccoletti R., Carossa S.

Department of Surgical Sciences, University of Turin, Turin, Italy

**Aim:** evaluate the efficacy of the topic application of a cord blood platelet gel (CBPG) followed by photobiomodulation therapy (PBMT) compared to the PBMT alone in the treatment of blisters and ulceration of the oral mucosae in patients with epidermolysis bullosa (EB).

**Methods:** 18 patients with EB and two bilateral symptomatic oral lesions were prospectively selected between November and December 2018. The ethics review board of the "Azienda Ospedaliera Città della Salute e della Scienza of Turin", Turin, Italy, approved the study (protocol number 0089210\_CS/585/09-2015). CB units not fulfilling the criteria for banking for transplant purposes were processed within 48 h of collection to obtain CBPG, according to the "Italian Cord Blood Platelet Gel project" protocol. For the PBMT, we used a diode laser (Wavelength 645nm, Fluence 8J/cm<sup>2</sup>, PD 500mW/cm<sup>2</sup>, Total energy 4J, Power 250mW, spot area 0,5cm<sup>2</sup>, gaussian beam profile, application time 16s) using a point-to-point technique, without contact, and

keeping the ray as perpendicular as possible. Morphological changes were measured and the symptom score was recorded using a visual analogue scale (VAS). The therapy has been repeated for 3 days every 24h (T1, T2, T3). All data were collected during a six month follow up period (at 1(T4); 12(T5); and 24(T6) weeks after the end of the therapy).

**Results:** 35 oral lesions were included (18 treated with the only PBMT and 17 with CBPG + PBMT); Both treatments proved to be effective in pain control and in promoting clinical healing. All patients reported a reduction in the frequency of the formation of new lesions in the treated area, and a reduction in pain caused by recurrences.

**Conclusion:** this study revealed that CBPG could be a proper therapeutic option for oral lesions of patients with EB; the novelty is represented by the results obtained with the PBMT alone: good control of symptoms and acceleration of wound healing, absence of adverse effects and possibility of being repeated over time.

## TELEDENTISTRY FOR THE EARLY DETECTION OF ORAL LESIONS: A LESSON FROM THE COVID-19 PANDEMIC

Capocasale G.<sup>1</sup>, Alberti C.<sup>1</sup>, Donadello D.<sup>1</sup>, Causarano G.<sup>1</sup>, Luciano U.<sup>1</sup>, Guerini A.<sup>2</sup>, Albanese M.<sup>1</sup>

<sup>1</sup>Department of Surgical Sciences, Paediatrics and Gynecology, University of Verona, Verona, Italy

<sup>2</sup>Department of Pathology, Bassano del Grappa General Hospital, Bassano del Grappa, Vicenza, Italy

**Aim:** telemedicine can be defined as the sharing of medical data through technologies, used to provide, by distance, patient medical care.

We would draw attention to the feasibility of the technology in the early diagnosis of oral lesions, particularly during the COVID-19 pandemic; indeed, the need to avoid interpersonal contacts to prevent the spread of the virus has made electronic consultations again even more significant.

**Case report:** a 49-year-old Caucasian man contacted our oral surgeon by telephone to explain his symptoms and signs: he reported gingiva swelling associated with lip paresthesia.

Considering his report, we asked him to send pictures of the oral lesion by WhatsApp chat room. A self-portrait taken by the patient with his smartphone camera showed the presence of red swelling of the anterior mandibular gingiva. Thanks to an

immediate telephonic evaluation, we were able to set an urgent incisional biopsy.

The histological examination showed the diagnosis of diffuse large B-cell Lymphoma.

The patient was referred to the oncologist, and he started treatment with chemo-radiation therapy.

**Conclusion:** for oral lesions, it is important to support strategies for early diagnosis and to improve prognosis: smartphone and apps are easy to access and use by most of the population. Considering the lesson from the COVID-19 pandemic outbreak, telemedicine could play an increasingly key role in future of oral medicine, patient referral and consultation, especially in cases in which any delay in diagnosis may have important implications on the morbidity and mortality of the condition.

## VIDEOCAPILLAROSCOPY FOR EVALUATION OF THE MICROCIRCULATION OF ORAL MUCOSA

Cristofalo A., Pellegrini G., Henin D., Toma M., Sirello R., Canciani E., Graziano D., Dellavia C.

Department of Biomedical, Surgical and Dental Sciences, University of Milan, Milan, Italy

**Aim:** to describe morphological aspects of microvessels in the various areas of oral cavity's mucosa and between patients with different gingival phenotypes by Videocapillaroscopy (VideoCap® 3.0).

**Methods:** microphotographs (200x) of gingiva, lips, dorsum of the tongue, labial and buccal mucosa were taken in 20 healthy volunteers. For each microphotograph, loops morphology and orientation, capillary density, loops length and diameter were evaluated. The gingival phenotype was assessed by means of colored probes and related to these parameters.

**Results:** frontal maxillary gingiva and labial mucosa showed the greatest capillary visibility due to their easier accessibility. Gingiva presented hairpin loops in the area of the gingival sulcus

and dots in the attached gingiva. Labial and buccal mucosa presented similar morphology of the loops shining through a 3D network. Lips presented the same hairpin morphology but a greater tortuosity than all other analyzed areas. Lingual dorsum was the area with less capillary visibility, but microcirculation of the lingual papillae was visible with a tree morphology in some cases. The evaluation of different phenotypes showed a higher amount of microvessels in subjects with medium biotype.

**Conclusion:** capillaroscopy allows to evaluate the microcirculation of different areas of the oral cavity and thus it may be used as a screening tool for diseases that affect peripheric microvessels. Labial mucosa appears the ideal site for the investigation due to its easy accessibility and minimal keratinization.

## STUDY OF MUCOSAL HUMORAL IMMUNITY IN SUBJECTS VACCINATED AGAINST COVID-19 BY BNT162B2 MRNA

Croveri F.<sup>1</sup>, Azzi L.<sup>1</sup>, Shallak M.<sup>2</sup>, Forlani G.<sup>2</sup>

<sup>1</sup>Unit of Oral Medicine and Pathology, Dental Clinic, ASST dei Sette Laghi-Ospedale di Circolo; Department of Medicine and Surgery, University of Insubria, Varese, Italy

<sup>2</sup>Laboratory of General Pathology and Immunology G. Tosi, Department of Medicine and Surgery, University of Insubria, Varese, Italy

**Aim:** Coronavirus disease 2019 (COVID-19) caused by severe acute respiratory syndrome coronavirus 2 (SARS-CoV-2) has recently become a pandemic, leading the scientific community and pharmaceutical company to the development, testing, and production of a safe and effective vaccine to control the spread of infection. Mucosal surfaces represent the primary portal of entry for SARS-CoV-2 in the human body, and the mucosal immunity is the first line of defense against viral infection. Preclinical studies of mRNA vaccines showed the persistency of the virus in nasal swabs suggesting that vaccinated patients, may still be become infected and transmit the infection from the upper airways. In this work, we evaluated SARS-CoV-2-specific IgA and IgG in serum and saliva of who received two injections of BNT162b2 mRNA vaccine, in order to verify the induction and the efficacy of systemic and mucosal immunity in vaccinated subjects.

**Methods:** using immunoassays specific for SARS-CoV-2 spike protein subunit S1, we determined SARS-CoV-2-specific IgG and IgA in the sera and saliva of sixty health care worker volunteers of ASST Sette Laghi, who received two injections of BNT162b2 mRNA vaccine. Samples were collected on the day of the first dose

(T0), two weeks after the first injection (T1) and two weeks after the second injection (T2). The presence of neutralizing antibodies in serum and salivary samples at time T2 was also analyzed using a competitive ELISA assay. The CLIA serological test on serum was used as a standard diagnostic reference for the evaluation of IgG neutralizing antibodies in serum.

**Results:** high titers of SARS-CoV-2-specific serum IgG was detected in 88% of vaccinated subjects after the first dose of BNT162b2 mRNA vaccine, and of subjects after the injection of the second dose of vaccine, with an average concentration of 40 mg/ml. In saliva we could detect SARS-CoV-2-specific IgG only after the second dose of vaccine, with a concentration 1000 lower than that observed in serum. Consistently with other reports, in 60% of seropositive subjects, the amount of IgG antibodies measured in serum after the first dose was comparable to that present in seronegative subjects after the second dose.

**Conclusion:** BNT162b2 mRNA vaccination induces a high titer of SARS-CoV-2-specific serum/saliva IgG, at least after the second dose of vaccine and the amount of IgG significantly correlates with percentage of virus inhibition both in serum and saliva.

## OROFACIAL GRANULOMATOSIS OF THE LOWER LIP: A DIAGNOSTIC CHALLENGE

D'Aiuto A., Maurino V., Croveri F., Dani M., Azzi L.

Department of Medicine and Surgery, University of Insubria, ASST dei Sette Laghi, Dental Clinic, Unit of Oral Medicine and Pathology, Varese, Italy

**Aim:** this report describes the case of a 50-year-old male with a persistent painless swelling of the lower lip which was noticed 3 months before.

The medical and pharmacological history of the patient was non-contributory.

**Methods:** the extraoral examination revealed a nontender swelling involving the left lower lip. The surrounding skin and rest of the oral mucosa were normal, but the patient reported a previous manifestation also in the lower left part of the face. There were not signs of Bell's palsy. The regional lymph nodes were not palpable. Haematochemical parameters were within the normal range, including ANA, ANCA and ASCA.

An incisional biopsy was performed with relative histopathological analysis.

**Results:** the histopathological examination showed the presence of a chronic inflammatory infiltrate, perivascular aggregation of lymphocytes, and non-caseating granulomas formation with epithelioid cells. A final diagnosis of Orofacial Granulomatosis (OFG) was made after correlating clinical, haematological, radiological and histopathological findings and by excluding other possible conditions. Thereafter, the patient was given intralesional triamcinolone injections 10 mg/ml once a week for 3 weeks.

**Conclusion:** the diagnosis of OFG is by exclusion of other granulomatous diseases involving the orofacial district. The exact etiology of OFG is still unclear and is considered to be multifactorial. The clinical challenge of this diseases relies in achieving the correct diagnosis, thus ruling out systemic involvement, and then choosing the appropriate treatment plan.

## A CASE OF DIFFUSE LARGE B CELL LYMPHOMA ARISEN FROM THE ORAL CAVITY

Dani M.<sup>1</sup>, Maurino V.<sup>2</sup>, Croveri F.<sup>1</sup>, D'Aiuto A.<sup>1</sup>, Azzi L.<sup>1</sup>

<sup>1</sup>Unit of Oral Medicine and Pathology, ASST Sette Laghi – Ospedale di Circolo, Department of Medicine and Surgery, University of Insubria, Varese, Italy

<sup>2</sup>Unit of Paediatric Dentistry, ASST Sette Laghi – Ospedale di Circolo, Department of Medicine and Surgery, University of Insubria, Varese, Italy

**Aim:** an 83-year-old man was visited at our Hospital, because of a palatal ulcerative lesion. He had had an ulcerative lesion since 1 month, localized on the right hard palate next to a periodontally compromised tooth. The painless lesion was characterized by rapid growth and thickened edges.

**Methods:** an Incisional Biopsy Was Performed, Including Both Part Of Edges And Part Of The Ulcer Bottom.

**Results:** the histopathological examination provided the diagnosis of high grade Diffuse Large B Cell Lymphoma (DLBCL). The PET scan showed that the lesion had extended to the right maxillary arch with probable infiltration of the adjacent bone structure. The patient did not report any systemic symptoms, had a good general state of health, so he was treated by immunochemotherapy with rituximab.

**Conclusion:** DLBCL is a non-Hodgkin lymphoma, which accounts for about 20% of all NHLs. It arises in older adults and it develops in lymph nodes, but approximately 20% to 40% of lymphomas develop in an extra nodal site. There are two histopathologic patterns: the nodular or follicular and the diffuse subtypes.

Lymphomas are classified as high grade or low grade lymphomas; this feature influences the treatment and determines prognosis. In the oral cavity, non-Hodgkin lymphomas show predilection for the posterior hard palate, but also buccal vestibule and gingiva. The localization and the rapid growth suggest the diagnosis. Differential diagnosis should consider oral squamous cells carcinoma, fungal infections, TBC and other ulcerative lesions.

## SALIVARY MICRO-RNA AND ORAL SQUAMOUS CELL CARCINOMA: A SYSTEMATIC REVIEW

De Giorgis L.<sup>1</sup>, De Giovanni E.<sup>1</sup>, Bagnasco F.<sup>1</sup>, Delucchi F.<sup>1</sup>, Pera F.<sup>2</sup>, Baldi D.<sup>1</sup>, Pesce P.<sup>1</sup>, Menini M.<sup>1</sup>

<sup>1</sup>Division of Prosthodontics and Implant Prosthodontics, Department of Surgical Sciences (DISC), Genoa University, Genoa, Italy

<sup>2</sup>CIR-Dental School, University of Turin, Turin, Italy

**Aim:** oral squamous cell carcinoma (OSCC) is a widespread malignancy with high mortality. In particular, a delay in its diagnosis dramatically decreases the survival rate. Research is focused on finding non-invasive and cost-effective methods to provide a comprehensive view of the cancer profile. The aim of this systematic review was to investigate and summarize results in literature regarding the use of salivary microRNAs (miRNAs) as diagnostic and prognostic biomarkers for OSCC patients.

**Methods:** PubMed, Scopus and Cochrane Library were used to search for clinical studies evaluating salivary miRNAs differently expressed in patients with OSCC compared to healthy subjects. The last search was done on December 8, 2020. Eligible articles included: cross-sectional, case-control and co-

hort studies. The risk of bias of included studies was assessed using the Newcastle Ottawa scale (NOS).

**Results:** twelve papers were selected and all of them detected significantly dysregulated miRNAs in OSCC patients compared to healthy controls: mir21 and mir31 were identified in different studies as upregulated; mir200a and mir125a were identified as downregulated.

**Conclusion:** salivary miRNAs might provide a non-invasive and cost-effective method in the diagnosis of OSCC and also a way to monitor more easily its evolution and therapeutic response and to aid the establishment of specific therapeutic strategies. Further longitudinal studies are needed in order to confirm which specific salivary miRNAs are the most effective biomarkers for the diagnosis and management of OSCC patients.

## QUANTITATIVE ULTRASOUND ASSESSMENT FOR THE CHARACTERIZATION OF THE ORAL MUCOSA

Romano A., Fiori F., Romano M.J., Lucchese A., Serpico R., Di Stasio D.

Multidisciplinary Department of Medical-Surgical and Dental Specialties, University of Campania Luigi Vanvitelli, Caserta, Italy

**Aim:** the ultrasound (US) attenuation measures the amount of intensity dispersion (dB) that the beam undergoes in contact with structures. This value will be called Echo Level (EL), and at each value of EL corresponds a gray value from 0 to 255. Ultrasonography is based on the conversion of dB values into a grayscale, resulting in different echogenicity. This study aims to evaluate the feasibility of High-frequency US for the analysis of oral mucosa and detection and characterization of each layer based on different Echo Levels (EL) measured in dB.

**Methods:** 52 patients (26 women and 26 men, mean age  $59.72 \pm 16.73$ ) underwent an ultrasonographic examination of the oral mucosa in the Oral Medicine Unit of the University of Campania "Luigi Vanvitelli". The images were acquired using a GE Logiq-e R7 device (18 MHz probe). In each image, a region of interest (ROI) was selected for each tissue layer, and dB

were measured. The ELs were subjected to analysis of variance (ANOVA) and Tukey test.

**Results:** the attenuation values obtained were the following: epithelium (EP-mean =  $35.37 \pm 2.44$  dB), connective (CL-mean =  $33.93 \pm 4.77$  dB); epithelial-connective interface (EC-mean =  $46.45 \pm 3.84$  dB). There is no significant difference between the EL mean of EP ( $p = 0.13$ ) with CL, while there is a significant difference between EP and ECI ( $p < 0.01$ ) and between CL and ECI ( $p < 0.01$ ).

**Conclusion:** the Quantitative US Assessment of the different echographic interfaces allows to distinguish tissues based on their echogenicity and to identify the connective epithelium interface, improving the potential usefulness of US in oral medicine. Further studies are necessary to corroborate this perspective.

## ORAL LESIONS POST INJECTION OF SARS-COV-2 VACCINE: A CASE REPORT

Manfredi M., Ghidini G., Vescovi P., Pizzi S.

Department of Medicine and Surgery, University of Parma, University Hospital of Parma, Parma, Italy

**Aim:** the aim of this study is to report a case of oral ulcerative and erythematous lesions appeared after the first injection with one of the vaccine against SARS-CoV-2.

**Methods:** a 34 year-old healthy woman, a biologist working in the Azienda Ospedaliera-Universitaria of Parma, referred the appearance of painful and diffuse oral lesions of the oral cavity from two days after the first dose of Pfizer-BioNTech SARS-CoV-2 vaccine. She reported that she never had fever, but had mild joint pain, asthenia and pain at the injection site of the vaccine. She did not report any previous allergic reaction to any drug or vaccine.

**Results:** at clinical examination, diffuse ulcerative lesions on the floor of the mouth, in association with oral eritema of the

ventral surface and anterior area of the dorsum of the tongue, were observed. The oral mucosa of the lips appeared dry and inflamed and signs of angular cheilitis were also present. She also referred a sense of swelling of the lips and oral gingiva. Lesions were treated with antibacterial agents and moisturizing lip balm. The patient was reviewed 7 and 15 days after the appearance of the lesions with gradual healing.

**Conclusion:** as reported in literature, similar to other medications, allergic reactions can occur during vaccination. However, oral side effects of non-orally administered vaccines are extremely rare. The case report aims to focus on the possible oral manifestations of the new vaccines against SARS-CoV-2.

## TOPICAL PLATELET RICH PLASMA (PRP) IN ORAL BLISTERING DISEASES: A PILOT STUDY

Grillini S.<sup>1</sup>, Gabusi A.<sup>1</sup>, Loi C.<sup>2</sup>, Bernardi A.<sup>1</sup>, Gissi D. B.<sup>1</sup>

<sup>1</sup>Department of Biomedical and Neuromotor Sciences, University of Bologna, Bologna, Italy

<sup>2</sup>Department of Experimental, Diagnostic and Specialty Medicine- DIMES, Section of Dermatology, University of Bologna, Bologna, Italy

**Aim:** treatment modalities for autoimmune blistering diseases include corticosteroids, immunosuppressants and biologic therapies. PRP injections have been recently reported to be beneficial in the treatment of recalcitrant oral erosions of Pemphigus Vulgaris, Oral Graft Versus Host Disease and Oral Lichen Planus. Local injections however, can be painful and less attractive for patients. In this pilot study, the aim was to test effectiveness of topical PRP in refractory oral lesions and feasibility for larger scale studies.

**Methods:** 8 patients (1 Pemphigus Vulgaris, 7 Mucous Membrane Pemphigoid) with lesions non respondent to previous local/systemic therapy were treated with heterologous PRP topical application. The Oral Disease Severity Score was used to assess disease severity before and after treatment. Similarly,

VAS were assessed for Pain level changes and FMPS was recorded for improvements in oral care. The applications of PRP were performed once a week for 2 months and endpoint for clinical evaluation was set 1 week after the last session. Paired Samples T-Test was calculated for all studied variables.

**Results:** a reduction in ODSS and FMPS value was seen in 7/8 patients whereas an improvement in VAS was seen in 8/8. Interestingly, non respondent patient had high FMPS rate at baseline. All parameters resulted to be statistically significant ODSS t:3,50386 P < .05; VAS t:5,79892 P < .05; FMPS t:2,78308 P < .05.

**Conclusion:** within the limits of this study, treatment with PRP seems to be a safe procedure for the management of oral bul- lous diseases.

## TOPICAL SELENIUM TO MANAGE ORAL LICHEN PLANUS: A DOUBLE-BLIND PROSPECTIVE STUDY PROPOSAL

Keller E., Ottaviani G., Rupel K., Poropat A., Bogdan Preda M.T., Di Lenarda R., Biasotto M.

Department of Medical, Surgical and Health Sciences - S.C. of Maxillofacial Surgery and Odontostomatology of the Giuliano-Isontina Health Authority (ASUGI), Maggiore Hospital, Trieste, Italy

**Introduction:** the role of selenium deficiency in the pathogenesis of oral conditions, such as pemphigus vulgaris and oral lichen planus (OLP), has been already unraveled. Consequently, selenium has been considered as treatment, based on its antioxidant properties.

**AIM:** herein we propose the present study protocol to assess the efficacy of hydrogel and mouthwash selenium formulations in patients affected by erosive OLP.

**Methods:** reviewing present literature on this topic we decided to enrol patients with histological diagnosis of OLP and presence of symptomatic erosive oral lesions. Patients will be then randomly assigned to one of three groups (T1):

- group A: topical corticosteroid (3 applications/day for 6 weeks);
- group B: selenium hydrogel (3 applications /day for 6 weeks);
- group C: selenium mouthwash (3 applications/day for 6 weeks).

Both patients and operators will be blinded to the treatment since the three formulations will be bottled in anonymous containers, each labelled with a specific code. Patients will be monitored at the following time points: T2 (3 weeks from T1), T3 (6 weeks T1), T4 (30 days from T3), T5 (90 day from T3) and T6 (180 days from T3). During each visit (from T1 to T6) the following items will be registered: pain score (NRS scale 0-10), REU scoring system to 10 oral sites, selenium serum level and photographic documentation. Moreover, salivary sampling will be collected at every time point to investigate patients' oxidative status through the following colorimetric tests: FRAS, AOPP, TBARS and TOS.

**Discussion:** we hypothesize that the antioxidant properties of selenium could represent a valid therapeutic strategy to manage symptoms associated to OLP. The topical formulation of selenium represents a simple route of administration and could reduce the incidence of secondary candidiasis associated to topical corticosteroids formulations.

## ORAL LESIONS ASSOCIATED WITH COVID-19: A COMPREHENSIVE LITERATURE REVIEW

La Rosa G.R.M.<sup>1</sup>, Libra M.<sup>2</sup>, Ferlito S.<sup>1</sup>, De Pasquale R.<sup>1</sup>, Pedullà E.<sup>1</sup>

<sup>1</sup>Department of General Surgery and Medical-Surgical Specialties, University of Catania, Catania, Italy

<sup>2</sup>Department of Biomedical and Biotechnological Sciences, Oncologic, Clinic and General Pathology Section, University of Catania, Catania, Italy

**Aim:** Coronavirus disease 2019 (COVID-19) has been associated with cutaneous manifestations, including oral cavity. Nevertheless, the significance of this association is still unclear. Aim of this review was to synthesize the current literature and provide a clinical overview of oral injuries in severe acute respiratory syndrome coronavirus 2 (SARS-CoV-2) infection.

**Methods:** an online literature search was performed in PubMed, Scopus, and Web of Science to identify the pertinent studies. The following keywords were applied: “oral mucosal lesions” OR “oral lesions” AND “COVID-19” OR “SARS-CoV-2” OR “novel coronavirus disease”. All types of studies, excluding only literature reviews, with laboratory-confirmed COVID-19 cases associated with oral manifestations were included.

**Results:** from the 86 studies retrieved, only 17 were included. The oral manifestations were variable including ulcerations, aphthous-like lesions, petechiae, and macules. The tongue, lips, and palate were the most frequent anatomical locations.

**Conclusion:** to date, no strong evidence is available regarding the diagnostic and prognostic significance of oral manifestations during COVID-19. On the basis of the current knowledge, the oral examination in patients with COVID-19 should be emphasized, promoting a multidisciplinary approach, including dental practitioners. Indeed, early recognition of oral lesions associated with COVID-19 could be crucial in the dental setting to ensure a more accurate triage of patients and improve operator safety, avoiding underestimation and misdiagnosis of oral manifestations.

## PATIENT REPORTED OUTCOMES IN PRIMARY SJÖGREN SYNDROME

Izzetti R.<sup>1</sup>, Nisi M.<sup>1</sup>, Lepore Y.<sup>1</sup>, Gennai S.<sup>1</sup>, Fulvio G.<sup>2</sup>, Ferro F.<sup>2</sup>, Caramella D.<sup>3</sup>, Baldini C.<sup>2</sup>, Graziani F.<sup>1</sup>

<sup>1</sup>Unit of Dentistry and Oral surgery, Department of Surgical, Medical and Molecular Pathology and Critical Care Medicine, University of Pisa, Pisa, Italy

<sup>2</sup>Unit of Rheumatology, Department of Clinical and Experimental Medicine, University of Pisa, Pisa, Italy

<sup>3</sup>Diagnostic and Interventional Radiology, Department of Translational Research and of New Technologies in Medicine and Surgery, University of Pisa, Pisa, Italy

**Aim:** to evaluate the Oral Health Impact Profile (OHIP) and other Patient Reported outcomes (PROs) in a cohort of patients with suspected primary Sjögren's syndrome (pSS).

**Methods:** consecutive patients referred to the Unit of Rheumatology were enrolled. All the patients underwent screening for pSS, which involved clinical assessment, laboratory tests, ultra-high frequency ultrasonography examination of major and minor salivary glands, minor salivary glands biopsy. The final diagnosis was either pSS or sicca syndrome. All the patients were administered the following set of questionnaires: OHIP, EULAR Sjögren Syndrome Patient Reported Index (ESSPRI), Ocular Surface Disease Index, Visual Analogue Scale Mouth, Eyes, Fatigue, Pain.

**Results:** 171 patients in total were enrolled: 83 were diagnosed with pSS, while 88 with sicca syndrome. No differences were found in terms of OHIP among the two groups. OHIP score and USFR were inversely related, as an increase in OHIP appeared to be correlated with a decrease in the USFR. Similarly, a correlation was detected between OHIP and all the other PROs. No correlation between PROs and age/gender, laboratory tests, histology or UHFUS was found.

**Conclusion:** although OHIP shows to be related to USFR, no correlation can be found with the other clinical, laboratory, histological and ultrasonographic parameters employed for pSS diagnosis. Nevertheless, PROs can provide additional information and support the assessment of patients with dry mouth.

## ORAL MUCOSAL MELANOMA: A REPORT OF TWO CASES AND SYSTEMATIC REVIEW OF LITERATURE

Nisi M., Izzetti R., Gennai S., Mariotti S., Pucci A., Lenzi C., Graziani F.

Department of Surgical Pathology, Medicine, Molecular and Critical Area, University of Pisa, Pisa, Italy

**Aim:** primary oral mucosal melanoma (OMM) is a rare neoplasm accounting for the 0.2-0.8% of all melanomas. The aim of the present manuscript is i) to describe two cases of primary OMM treated at our department, and ii) to perform a systematic literature review on primary OMM occurrence and treatment.

**Methods:** two cases of primary OMM were described. A literature search was performed on PubMed, EMBASE, and Cochrane Library. A systematic review was performed in order to assess the treatment options, recurrence, metastasis development and survival rate of primary OMM.

**Results:** two patients, a 92-year-old female and a 62-year-old male, were referred for the development of a lesion of the hard palate and the maxillary gingival mucosa respectively. An incisional biopsy was performed in both patients, fol-

lowed by extensive surgical resection after a thorough consideration of patient history and systemic involvement. During the follow-up, local recurrence in the female patient and distant metastases in the male patient were observed, which required adjuvant immunotherapy. The literature search retrieved 445 primary OMM cases, mostly involving the maxillary and palatal mucosa. In the 30% of cases, distant metastases were already present at the time of diagnosis. The management of primary OMM most frequently involved surgical treatment and adjuvant radiotherapy.

**Conclusion:** primary OMM still represents a challenge for the clinician, as the diagnosis is often performed when metastases have already developed. The prognosis is generally poor, thus highlighting the need for further investigations to improve early diagnosis.

## ORAL HEALTH STATUS IN PATIENTS WITH SUSPECTED PRIMARY SJÖGREN SYNDROME

Izzetti R.<sup>1</sup>, Nisi M.<sup>1</sup>, Pacini S.<sup>1</sup>, Gennai S.<sup>1</sup>, Fulvio G.<sup>2</sup>, Ferro F.<sup>2</sup>, Nisi M.<sup>1</sup>, Pacini S.<sup>1</sup>, Gennai S.<sup>1</sup>, Caramella D.<sup>3</sup>, Baldini C.<sup>2</sup>, Graziani F.<sup>1</sup>

<sup>1</sup>Unit of Dentistry and Oral surgery, Department of Surgical, Medical and Molecular Pathology and Critical Care Medicine, University of Pisa, Pisa, Italy

<sup>2</sup>Unit of Rheumatology, Department of Clinical and Experimental Medicine, University of Pisa, Pisa, Italy

<sup>3</sup>Diagnostic and Interventional Radiology, Department of Translational Research and of New Technologies in Medicine and Surgery, University of Pisa, Pisa, Italy

**Aim:** to evaluate the oral health status of patients with suspected primary Sjögren Syndrome (pSS).

**Methods:** consecutive patients with suspected pSS referred to the Unit of Rheumatology were enrolled in the study. All the patients underwent a complete rheumatological screening for pSS, including clinical examination, laboratory tests, and histology. Oral health status was assessed at the Unit of Dentistry and Oral Surgery, and involved the evaluation of the number of missed, decayed, and restored teeth, along with a complete periodontal examination.

**Results:** 40 patients in total were enrolled. 23 patients were diagnosed with pSS. No differences were found among the pSS and sicca patients. USFR appeared related to the number of

filled teeth, while the other pSS parameters did not show significant correlation with oral health status. A trend could be observed in the values retrieved from the periodontal examination, with higher mean values of PPD and BOP in pSS patients.

**Conclusion:** the diagnosis of pSS does not seem to significantly affect oral health status. However, a decrease in USFR appears related to an overall worsening of oral health, in both pSS and sicca syndrome. In particular, a decrease in salivary flow could have an impact on the risk of caries development in both groups. Moreover, periodontal status was mildly affected by USFR. Further assessment on a larger cohort of patients is needed to better evaluate the actual effects of pSS and sicca syndrome on oral health.

## OPTICAL COHERENCE TOMOGRAPHY ASSESSING OSCC: SOMETHING IN COMMON WITH MELANOMA?

Panzarella V.<sup>1,2</sup>, Iurato Carbone M.<sup>1,2</sup>, Mauceri R.<sup>1,2</sup>, Di Fede O.<sup>1,2</sup>, Mascitti M.<sup>3</sup>, Arena A.<sup>4</sup>, Lo Muzio L.<sup>4</sup>, Campisi G.<sup>1,2</sup>, Capocasale G.<sup>5</sup>

<sup>1</sup>Department of Surgical, Oncological and Oral Sciences, University of Palermo, Palermo, Italy

<sup>2</sup>Oral Medicine and Dentistry for patients with special needs, AUOP P. Giaccone of Palermo, Palermo, Italy

<sup>3</sup>Department of Oral and Head-Neck Surgery, Umberto I General Hospital, Ancona, Italy

<sup>4</sup>Department of Clinical and Experimental Medicine, University of Foggia, Foggia, Italy

<sup>5</sup>Department of Surgical Sciences, Paediatrics and Gynaecology, University of Verona, Verona, Italy

**Aim:** Optical Coherence Tomography (OCT) is a diagnostic imaging widely used in the dermatological field for the evaluation of melanotic lesions. The potential validity of OCT in oral medicine is also investigated and it is considered a potential diagnostic device for oral carcinogenesis. This case report focus attention on assessment of oral squamous cell carcinoma (OSCC) by OCT and comparison with histological examination.

**Case report:** an 80-year-old female patient was referred to the Sector of Oral Medicine of Palermo for evaluation of chronic and symptomatic ulceration of the gum, strongly suspected of OSCC.

After informed consent, OCT assessment of the lesions was performed. We used the *in vivo* VivoSight® OCT (Michelson Diagnosis, Maidstone, England). Histological examination, by incisional biopsy was made in the same area of OCT evaluation, confirmed the diagnosis of OSCC.

OCT scan was selected and compared with histological features. The image demonstrated the presence of a structure generated by the altered epithelial layer inserted into the chorion, interrupting the continuity of the basement membrane. These features were associated with the presence of dense infiltrates of tumour cells and lymphocytes in histological examination. This neoplastic 'epithelial tissue island' invades the connective both in OCT and in histological images. Moreover, the normal architectural division of the mucosa appeared extremely distorted, and the keratin layer was impossible to identify.

**Conclusion:** OCT discrimination of our OSCC revealed an altered/hyperreflective tissue already detected for cutaneous melanoma, called "vertical icicle shaped structure". This finding supports the possibility of translating in oral medicine practice the consolidated OCT dermatological knowledges. Future studies are needed to better understand this prospective.

## ORAL LICHENOID REACTIONS WITH TARGETED THERAPIES: A LARGE-SCALE PHARMACOVIGILANCE ANALYSIS

Perulli L.<sup>1</sup>, Gissi D.B.<sup>1</sup>, Fusaroli M.<sup>2</sup>, Gabusi A.<sup>1</sup>, Raschi E.<sup>2</sup>, Poluzzi E.<sup>2</sup>, Montebugnoli L.<sup>1</sup>

<sup>1</sup>Department of Biomedical and Neuromotor Sciences, Section of Oral Sciences, University of Bologna, Bologna, Italy

<sup>2</sup>Pharmacology Unit, Department of Medical and Surgical Sciences, Alma Mater Studiorum - University of Bologna, Bologna, Italy

**Aim:** the purpose of the present study is to investigate the association between recently-marketed biological drugs, namely "targeted therapy" and/or immunotherapy, and the appearance of an Oral Lichenoid Drug Reaction (OLDR) through the analysis of spontaneous adverse event reports collected in the FDA Adverse Event Reporting System (FAERS).

**Methods:** the association between four pharmacological classes (monoclonal antibodies, tyrosine kinase inhibitors, fusion protein and mTOR inhibitors) and appearance of an OLDR was analyzed through the case/non-case approach using spontaneous adverse events recorded in FAERS (2004-2018), by calculating the reporting odds ratio (ROR) with the relevant 95% Confidence Intervals (95%CI). Association was considered statistically significant in case of: number of cases >3 and lower limit of the 95CI >1.

**Results:** a significant association was found for thirteen out of 94 analyzed drugs: Infliximab, Denosumab, Pembrolizumab Rituximab, Certolizumab, Secukinumab, Ipilimumab, Atezolizumab, Imatinib, Dabrafenib, Trametinib, Ponatinib, Abatacept. OLDRs have been signaled only in adults and elderly with a median time of insurgence of 108.2 days (ranging from 26.5 days for Pembrolizumab to 176.5 for atezolizumab).

**Conclusion:** although dedicated prospective studies with identification of accurate diagnostic protocols are needed to confirm these associations, dental practitioners and other health professionals should consider OLDRs among differential diagnoses, especially in subjects receiving oncological drugs such as immunotherapy.

## ORAL MANIFESTATIONS RELATED TO LEUKOPENIA DRUG-INDUCED: A CASE REPORT

Russo V., Rossi R., Tiberio C., Gabusi A., Gissi D.B.

Department of Biomedical and Neuromotor Sciences, Section of Oral Sciences, University of Bologna, Bologna, Italy

**Aim:** the present report described the clinical course of a patient with gingival ulcerations related to a systemic leukopenia induced by azathioprine therapy.

**Methods:** in April 2013 a 58 years-old female was referred to the Department of Oral Science, University of Bologna, for the appearance of painful diffuse ulcerated lesions located in the upper and lower gingiva. Medical history revealed a diagnosis of Adult Still's disease, a rare systemic inflammatory disease characterized by fevers, joint pain, and a distinctive salmon-colored bumpy rash in September 2012. In October 2012 the patient initiated pharmacological treatment with prednisone and in February 2013 systemic therapy was adjusted adding azathioprine 50 mg. Diffuse painful lesions appeared and rapidly progressed 20 days after treatment with azathioprine.

**Results:** serological exams revealed the presence of a marked leukopenia (3.66/mmc), and in agreement with rheumatologist azathioprine was immediately discontinued and patient started therapy with amoxicillin. Twenty days after azathioprine suspension, a significant clinical improvement was noted and new serological exams showed a mild leucocytosis (10.80/mmc).

**Conclusion:** the gingival crevice is the main source of leukocytes and leukopenic conditions can probably stimulate opportunistic bacterial infections with aggressive behavior, even if etiopathogenesis remains unclear. In case of wide gingival ulcerations a careful evaluation of medical history and laboratory exams is necessary for a correct diagnosis, treatment and to prevent potential systemic complications.

## RECALCITRANT EROSIVE ORAL LICHEN PLANUS TREATED BY LASER PHOTOBIO-MODULATION

Schiazano C.<sup>1</sup>, Roccon A.<sup>1</sup>, Tomansin M.<sup>1</sup>, Angelini A.<sup>2</sup>, Fedrigo M.<sup>2</sup>, Bacci C.<sup>1</sup>

<sup>1</sup>Section of Clinical Dentistry, Unit of Oral Surgery and Pathology, Dept of Neurosciences, University of Padova, Padova, Italy

<sup>2</sup>Department of Cardiac, Thoracic, Vascular Sciences and Public Health, University of Padova, Padova, Italy

**Aim:** the aim of this study is to describe a case of recalcitrant erosive Oral Lichen Planus (OLP) treated successfully with laser photobiomodulation (PBM).

**Methods:** a female patient with history of Sjogren's syndrome, Fibromyalgia and oral squamous cell carcinoma was referred to our Department for the evaluation of an erosive OLP. The patient clinically showed erithroleukoplasic oral lesions and reported burning and painful symptoms. After unsuccessful attempts with topical therapy with fluocinonide and miconazole, the patient underwent multiple PBM Laser session. The patient was also treated by the Immunodermatology Division which prescribed her systemic retinoid *per os*. Before starting the Laser PBM, a biopsy was performed and showed "Focal atrophic aspects of the epidermis associated with low-grade

dysplasia at unscathed surgical margins". After the treatment, a further biopsy was made.

**Results:** the therapy was well tolerated by the patient and there was no side effects. At the end of the treatment the extent and thickness of the lesions decreased and the patient was asymptomatic. Moreover, the histopatologic examination after the therapy showed a significant reduction of the inflammatory infiltrate and absence of the low-grade dysplasia.

**Conclusion:** the marked reduction of symptoms and the histopathological examination after the treatment could confirm the analgesic and immunomodulatory effect attributed to Laser. The absence of dysplasia after the PBM biopsy is a particularly important finding that should be investigated in future studies.

## ORAL METASTASES OF LUNG CANCER: A CASE REPORT

Setti G.<sup>1,2</sup>, Caramaschi S.<sup>3</sup>, Garuti G.<sup>2</sup>, Consolo U.<sup>2</sup>, Bellini P.<sup>2</sup>

<sup>1</sup>Molecular Medicine PhD School, Department of Medicine and Surgery, University of Parma, Parma, Italy

<sup>2</sup>Unit of Dentistry and Oral-Maxillofacial Surgery, Surgical, Medical and Dental Department of Morphological Sciences related to Transplant, Oncology and Regenerative Medicine, University of Modena and Reggio Emilia, Modena, Italy

<sup>3</sup>Unit of Anatomical and Histological Pathology, Department of Medical and Surgical Sciences, University of Modena and Reggio Emilia, Modena, Italy

Metastatic spreading to the oral cavity is infrequent and is usually the evidence of a disseminated disease with a very poor survival prognosis. However, solitary manifestations were described, reflecting the presence of an occult malignancy at a distant site. Most frequently involved oral cavity sites are jawbones and soft tissues, such as gingiva, alveolar mucosa and tongue. Primary neoplasms spreading oral metastases mainly affects breast, lung, kidney and prostate.

Lung cancer is the second most common cause of cancer-related death in both men and women. It is classified in non-

small cell carcinoma (squamous cell carcinoma, adenocarcinoma and large cell carcinoma), small cell carcinoma (SCLC) and lung carcinoid tumors. The high mortality rate is related to the diagnostic delay. Head and neck region metastatic localization are mainly observed in brain, maxilla and mandibular bones and parotid glands. The dissemination into oral soft tissues occurs mostly in alveolar mucosa, gingiva and, less frequently, into the tongue. This report describes a case of lung cancer oral metastasis in a 55 year-old woman, referred for the investigation of a long-lasting gingival swelling.

## AN UNUSUAL PRESENTATION OF AMELOBLASTOMA ON ANTERIOR MANDIBLE: A CASE REPORT

Tozzo P.<sup>3</sup>, Campanella A.F.<sup>3</sup>, Galioto V.<sup>3</sup>, Mascitti M.<sup>1</sup>, Santarelli A.<sup>1</sup>, Zhurakivska K.<sup>2</sup>, Caponio V.C.<sup>2</sup>

<sup>1</sup>Department of Clinical Specialistic and Dental Sciences, Marche Polytechnic University, Ancona, Italy

<sup>2</sup>Department of Clinical and Experimental Medicine, University of Foggia, Foggia, Italy

<sup>3</sup>U.O.C. of Stomatology, A.O.O.R. Villa Sofia-Cervello of Palermo, Palermo, Italy

**Aim:** ameloblastoma is a benign odontogenic tumor representing about 9-11% of odontogenic tumor. It occurs predominantly in the lower jaw (80%), and in the posterior area; it is often asymptomatic and slow-growing tumor, usually with no evidence of swelling and with a high tendency to recur. If left untreated, it can resorb the cortical plate and extend into adjacent tissue with the resorption of the roots of adjacent teeth.

**Methods:** case report of a man who attended the sector of Odontostomatology (AO Ospedali Riuniti Cto "Villa Sofia-Cervello" Palermo, Italy) due to neof ormation on the jaw. Patient underwent Maxillofacial Computed Tomography (CT); then an incisional biopsy was performed.

**Results:** on July 2020, a 72-year-old Caucasian man presented at the Odontostomatology Unit complaining about a painful swelling mass.

Oral clinical examination revealed a 2 cm hard submucosal ulcerated mass on the left side of the edentulous crest in the third quadrant. Additionally, oral hygiene was poor. The CT detected an osteolytic lesion on the jaw with noticeable thinning and interruption of the cortical bone, without evidence of hyperplasia of submandibular lymph nodes. Based on the histological and radiological findings, the diagnosis of ameloblastoma was confirmed. Patient was referred to maxillofacial surgery for treatment.

**Conclusion:** about 70% of ameloblastoma undergo malignant transformation, and up to 2% metastasize to other sites, usually the lungs.

Currently, radical surgical approach is the principal treatment. Chemo and radiotherapy could be useful for non-surgical patients. Periodic clinical and radiological follow-up is necessary due to the high risk of recurrence and malignant transformation.

## THE ODONTOGENIC MYXOMA: A CASE REPORT

Venuleo A.<sup>1</sup>, Sawadogo V.<sup>1</sup>, Venuleo M.<sup>2</sup>, Benazzato A.<sup>2</sup>

<sup>1</sup>Department of Neuroscience, University of Padua, Padua, Italy

<sup>2</sup>AULSS 6 Euganea Dental Clinic, Padua, Italy

**Aim:** the aim is to introduce a case report which describes a unique case of odontogenic myxoma of the mandibular posterior region in a 11-year-old male, with an emphasis on a histopathological diagnosis.

**Methods:** a 11 year old male came to our examination for a first visit. The x-ray examination revealed a well defined unilocular radiolucency with distinctive borders extending between the second left premolar and the first left molar, which apparently did not have any relationship with the endodontic condition of the tooth. The small lesion was asymptomatic. Based on the x-ray, provisional diagnosis of odontogenic fibroma, ameloblastoma, fibrous dysplasia was considered. The patient underwent surgical enucleation with aggressive curettage of the site.

**Results:** based on histological analysis, the lesion was diagnosed as odontogenic myxoma.

The odontogenic myxoma is an uncommon tumor that has the potential for extensive bone destruction, which tends to extend into the surrounding structures, and has a relatively high recurrence rate.

**Conclusion:** odontogenic myxoma shares common clinical and radiographic features with various other odontogenic and fibrous tumors. A histopathological diagnosis is of utmost importance, in order to establish an accurate diagnosis and treatment plan. The follow up of patients for at least 2 years at regular 3 monthly intervals is mandatory, due to the likelihood of tumor reappearance.

## SALIVARY MICRORNA ANALYSIS IN A GROUP OF PATIENTS WITH BRCA1-2 MUTATIONS: A PILOT STUDY

Viani M.V.<sup>1</sup>, Pezzi M.<sup>1</sup>, Antonelli R.<sup>1</sup>, Musolino A.<sup>2</sup>, Pertinhez T.<sup>3,4</sup>, Meleti M.<sup>1</sup>

<sup>1</sup>Section of Oral Medicine and Surgery, Centro Universitario di Odontoiatria, Department of Medicine and Surgery, University of Parma, Parma, Italy

<sup>2</sup>Medical Oncology and Brest Unit, University Hospital of Parma, Parma, Italy

<sup>3</sup>Department of Medicine and Surgery, University of Parma, Parma, Italy

<sup>4</sup>Transfusion Medicine Unit, Azienda USL-IRCCS di Reggio Emilia, Reggio Emilia, Italy

**Aim:** microRNAs are small, non-coding RNAs, regulating the expression of more than 30% of human genes, including BRCA 1-2. BRCA 1-2 are tumor suppressor genes that play critical roles in maintenance of genomic stability: mutations in BRCA 1-2 predispose to breast, ovarian, and other cancers.

The aim of the present work is to report the preliminary results of a pilot study on salivary miRNAs in Breast Cancer (BRCA) 1-2 genes mutated females. We attempt to describe the previously unreported miRNA profile of women with BRCA mutations, compared to the blood profile.

**Methods:** nine subjects (aged between 18 and 40 years) underwent saliva collection for miRNA analysis. They were interviewed on medical history and underwent a thorough oral investigation, including a careful examination of teeth, periodontal tissues and oral mucosa. Subjects not needing a preliminary non-surgical periodontal session underwent saliva collection on the second appointment. Immediately before saliva

collection, patients rinsed the mouth with water for one minute. They were instructed not to swallow saliva.

The whole saliva was spat into a sterile container. The collection finished when 2 mL of saliva were collected. Presence and concentration of 84 selected miRNAs were evaluated through real-time polymerase chain reaction (rt-PCR).

**Results:** nine miRNAs (let-7b-5p, miR-130b-3, miR-193b-3, miR-203a, miR-205-5p, miR-210, miR-29a-3p, miR-328, miR-489) were identified in saliva and 32 in serum. Only 5 miRNAs (let-7b-5p, miR-130b-3, miR-203a, miR-29a-3p, miR-489) were detected both in serum and saliva.

All of the 36 miRNAs have an oncogenic and/or tumor suppressor role in development of breast tumors.

**Conclusion:** our preliminary finding would suggest that healthy but predisposed subjects have already a changed miRNA pattern either in blood and in saliva, probably different from healthy and not predisposed subjects.

## AN UNCOMMON BASAL CELL ADENOMA OF PALATE: A CASE REPORT

Iurato Carbone M.<sup>1</sup>, Mauceri R.<sup>1,2</sup>, Panzarella V.<sup>1</sup>, Di Fede O.<sup>1</sup>, Tozzo P.<sup>3</sup>, Mascitti M.<sup>4</sup>, Santarelli A.<sup>4</sup>, Troiano G.<sup>5</sup>, Campisi G.<sup>1</sup>

<sup>1</sup>Sector of Oral Medicine and Dentistry for patients with special needs, University of Palermo, Palermo, Italy

<sup>2</sup>Department of BIOMORF, University of Messina, Messina, Italy

<sup>3</sup>U.O.C. of Stomatology, A.O.O.R. Villa Sofia-Cervello of Palermo, Palermo, Italy

<sup>4</sup>Department of Clinical Specialistic and Dental Sciences, Marche Polytechnic University, Ancona, Italy

<sup>5</sup>Department of Clinical and Experimental Medicine, University of Foggia, Foggia, Italy

**Aim:** basal cell adenoma (BCA) is an uncommon type of benign monomorphic adenoma; it constitutes 5% to 6% of benign salivary gland tumors. The site most involved is major salivary glands, while it rarely occurs in minor salivary glands.

**Methods:** we report a case of a man who has attended our sector of Oral Medicine (AOUP "P. Giaccone" Palermo, Italy) due to a soft movable submucous mass on the left side of the soft palate.

**Results:** a 71-year-old caucasian man presented at our sector of Oral Medicine Unit on March 2019 complaining about a one-month painless swelling mass. Oral clinical examination revealed a 1 cm soft movable submucous mass slightly purplish on the left side of the palate. Additionally, he was a smoker and oral hygiene was very poor. Due to the clinical aspects of the lesion, a suspicion of oral BCA was raised. Patient underwent head and neck magnetic resonance imaging (MRI); then an incisional biopsy was

performed by mean of quantic molecular resonance scalpel. The MRI did not detect significant alterations in the oral mucosa (probably due to the presence of metal dental prostheses); additionally, there were no evidence of hyperplasia of submandibular lymph nodes. Based on the histological and radiological findings, the diagnosis of BCA was confirmed. Patient was referred to plastic surgery for complete excision of the lesion.

**Conclusion:** parotid being the most frequent site of occurrence of BCA followed by minor salivary glands of upper lip. Primary treatment of BCA is surgical excision; however, BCA is associated with a high recurrence rate (about 25%), probably because BCA are usually multinodular. Additionally, follow up is mandatory because BCA may be the precursor of basal cell adenocarcinoma. This case report describes a rare case of basal cell adenoma involving the minor salivary gland of palate.

## SECOND PRIMARY ORAL SQUAMOUS CELL CARCINOMA IN ORAL LICHEN PLANUS PATIENT: A CASE REPORT

Iurato Carbone M.<sup>1</sup>, Campisi G.<sup>1</sup>, Panzarella V.<sup>1</sup>, Di Fede O.<sup>1</sup>, Tozzo P.<sup>2</sup>, Mascitti M.<sup>3</sup>, Santarelli A.<sup>3</sup>, Dioguardi M.<sup>4</sup>, Mauceri R.<sup>1,5</sup>

<sup>1</sup>Sector of Oral Medicine and Dentistry for patients with special needs, University of Palermo, Palermo, Italy

<sup>2</sup>U.O.C. of Stomatology, A.O.O.R. Villa Sofia-Cervello of Palermo, Palermo, Italy

<sup>3</sup>Department of Clinical Specialistic and Dental Sciences, Marche Polytechnic University, Ancona, Italy

<sup>4</sup>Department of Clinical and Experimental Medicine, University of Foggia, Foggia, Italy

<sup>5</sup>Department of BIOMORF, University of Messina, Messina, Italy

**Aim:** oral lichen planus (OLP) is a potential malignant lesion, with a lifetime transformation rate of about 1.1%. The tongue has been reported as the most common site of malignant transformation. It was also noted a high rate of second primary tumor (SPT) (33.3%) in patients with prior OLP; metachronous SPT that is usually associated with poor prognosis and decreased survival rates.

**Methods:** we report a case of a woman who has attended our sector of Oral Medicine (AOUP "P. Giaccone" Palermo, Italy) with a white plaque on the right lingual margin and white reticular lesions on the buccal mucosa.

**Results:** a 65-year-old Caucasian woman presented at our sector of Oral Medicine on February 2010 complaining about white plaques in the mouth. Due to the clinical aspects of the lesions, a suspicion of OLP was raised. An incisional biopsy was performed. Based on the histological findings, the diagnosis of OLP was con-

firmed. Patient underwent periodic follow-ups. On November 2013, the patient presented to the follow-up visit with 0,6 cm ulcerated roundish lesion on the right lingual margin. Based on the histological and radiological findings, the diagnosis of OSCC was done. Patient was referred to plastic surgery for radical exeresis. On November 2020, the patient presented to the follow-up visit with a 3,5 cm painful ulcerated lesion on the gingival margin of the 4-5<sup>th</sup> sextant. Based on the histological and radiological findings, the diagnosis of a new primary OSCC was confirmed. Patient was referred to oncology sector for the prosecution of therapy.

**Conclusion:** despite a low risk of malignant transformation, close follow-up screening of all patients with OLP is necessary to facilitate early detection of a malignant transformation. The need of follow-up is highlighted by our case, as those who develop OSCC on LPO have also a high risk of developing SPT.

## PERIODONTITIS AND FEMALE INFERTILITY, CURRENT SCIENTIFIC EVIDENCE: A LITERATURE REVIEW

Ludovichetti F.S., Artuso A., Signoriello A.G., Gangemi G., Mazzoleni S., Stellini E.

Neurosciences Department – Dentistry Section, University of Padua, Padua, Italy

**Aim:** periodontal health is considered today as an integral part of systemic health. The literature recognizes that the presence of periodontal disease can represent a risk factor for numerous systemic conditions such as heart disease and diabetes; in recent years, there has been a progressive increase of interest regarding the influence exerted by this condition on reproduction, as well as the possible repercussions on conception possibilities. This work aims to review all the available literature about this topic in order to verify the existence of a correlation between female infertility and periodontal disease.

**Methods:** following the insertion of specific keywords, a total of 10 studies arising from biomedical scientific literature sites such as PubMed, Cochrane and Sciondirect were analyzed.

**Results:** through the analysis of studies available, it could be inferred that this condition can be equated to the presence of a real outbreak of infection and therefore exert its influence, not only through bacterial translocation in the bloodstream, causing the systemic dissemination of pathogens, but also through the production of cytokines and immunoglobulins by inflammatory mediators. This situation limits bacterial growth, but it could cause damage to the fetus, to the reproductive system, and could hinder conception attempts.

**Conclusion:** although further research is needed to clarify the mechanism underlying the possible correlation between periodontal disease and female infertility, many studies don't exclude the possibility of a correlation between these conditions.

## THE DENTAL HYGIENIST AND ENAMEL DEVELOPMENT DEFECTS: KNOWLEDGE AND CLINICAL APPROACH

Azab J., Bontà G., Bosia T., Cagetti M.G.

Department of Biomedical, Surgical and Dental Science, University of Milan, Milan, Italy

**Aim:** this study aims to assess the knowledge of dental hygienists regarding the developmental defects of the enamel (DDE) and their ability to differentiate among different clinical manifestations of the defects, allowing so to plan a correct preventive and therapeutic treatment.

**Method:** an online questionnaire was created and administered to 1423 graduate dental hygienists with at least one year of work experience and registered with the Italian Dental Hygienists Association (AIDI). The questionnaire included questions on DDE etiology; in addition, images of teeth affected by DDE were shown, asking to participants to choose among a selection of preventive and therapeutic treatments in order to evaluate the knowledge and the clinical approach of dental hygienists regarding DDE.

**Results:** two-hundred-ten responses were obtained. 66.20% (n = 139) of the sample correctly recognized the Molar Incisor

Hypomineralization (MIH), 54.30% (n = 114) the Amelogenesis Imperfecta, 43.80% (n = 92) the dental fluorosis, 71.90% (n = 151) a decalcification due to dental plaque acids and 44.79% (n = 94) an initial carious lesion of a groove. Respondents were then divided in two groups on the basis of years of work experience in Experts (+5 years) and non-Experts (from 1 to 5 years). The ability to perform a correct diagnosis of the defect was not related to the years of work experience. Non-Expert dental hygienists correctly identified MIH (69.87% compared to 63.78% of the Experts), Amelogenesis imperfecta (59.03% compared to 51.18% of the Experts) and carious lesion (48.19% compared to 42,52% of Experts).

**Conclusion:** the ability to intercept and differentiate among different developmental defects of the enamel is not associated with the years of clinical experience. Furthermore, the knowledge of dental hygienists on DDE seems to be adequate.

## THE EFFECTS OF BARIATRIC SURGERY ON ORAL AND PERIODONTAL HEALTH

Tetè G.<sup>1</sup>, Battista D.<sup>2</sup>, Polizzi E.M.<sup>3</sup>

<sup>1</sup>Department of Dentistry, Vita-Salute San Raffaele University, IRCSS San Raffaele, Milan, Italy

<sup>2</sup>CLID student, Vita-Salute San Raffaele University, IRCSS San Raffaele, Milan, Italy

<sup>3</sup>CLID coordinator, Vita-Salute San Raffaele University, Oral Hygiene and Prevention Center, Department of Dentistry, IRCSS San Raffaele, Milan, Italy

**Aim:** the incidence of obesity in recent years has increased exponentially, not only in adults, but also in children. Obesity is therefore a significant risk factor for cardiovascular diseases such as heart attack, stroke, hypertension, type 2 diabetes mellitus, tumors and periodontitis.

Bariatric Surgery (BS) is only a form of surgical treatment for obesity.

The objective of this review is to identify the consequences of Bariatric Surgery on oral and periodontal health with its repercussions on oral hygiene.

**Method:** the authors performed a research of MEDLINE (PubMed), using key word: “Bariatric surgery and Periodonti-

tis, Obesity, Metabolic Syndrome and Periodontitis” between from 2012 to 2020.

**Results:** we were found 17 articles. 9 articles were considered; while 8 were excluded as it not relevant to the aim of the study and not in line with inclusion criteria.

**Conclusion:** despite the small number of articles examined we can say that the periodontal status, oral health and oral hygiene in the first 6 months after surgery are worse. Consequently, periodontal screening and management of the Bariatric patient’s is necessary. Therefore, dental hygienist could be included in the bariatric medical team to plan a follow-up and prevention program contributing to the patient’s health.

## SIDE EFFECTS OF ORTHODONTIC TREATMENT - LITERATURE EVIDENCE AND LONGITUDINAL STUDY DATA

Castellani I., Gronelli G., Contardo L., Frattini C., Nicolini V., Costantinides F.

Department of Medicine, Surgery and Health Sciences, University of Trieste, Trieste, Italy

**Aim:** the aim of this study was to highlight the side effects of orthodontic treatment with a focus on White Spot Lesions (WSL) and reviewing the literature about the diagnosis.

**Methods:** in this clinical-experimental longitudinal study were enrolled 57 patients. The data were collected from the beginning of the orthodontic therapy (T0) until the debonding (TF), with 3 months recalls. The parameters were: sex, age, biotype, plaque index (PI), bleeding on probing (BoP), gingival recession, WSL and decays. The review was focused on the search for an objective and user-friendly method for early detection of WSL. A total of 1.021 studies were analyzed and, after the exclusion process, 13 studies were included.

**Results:** PI increased to T12 (a year after bonding) and then reduced until the debonding (40%), with values similar to T0 (37%). The incidence of decay showed no differences (5.26% at T0 and 7.68% at debonding). Recessions, after an initial peak, remained stable.

84.2% of patients at the end of therapy had at least one WSL; 17% grade 1, 33% grade 2, 50% grade 3. The trend of the progression showed an increase in the first months, remained stable up to the first 6 months, when a further peak occurred. The incidence of the WSL was higher at the end of the treatment in the male sex (57%).

As regards the review, 7 different methods have been analyzed, and compared. Quantitative Light-Induced Fluorescence (QLF) and Optical Coherence Tomography (OCT) are the most specific and effective ones but have not been yet developed for chairside use.

**Conclusion:** WSL is a worrying problem for its rapid occurrence and ability to affect a large number of subjects. It seems instead not to play a significant role in terms of time exposure, but the early prevention could be relevant. The review concludes that today, for the WSL, there is not yet a universal diagnostic criteria and instrument.

## WOMEN'S ORAL HEALTH: FROM PUBERTY TO MENOPAUSE

Cressoni C.<sup>1,3</sup>, D'Avola V.<sup>1,4</sup>, Pasculli A.<sup>1,3</sup>, Kashkaval V.<sup>1,3</sup>, Quartiroli F.<sup>1,3</sup>, Maia Corrêa F.<sup>1,3</sup>, Dolci C.<sup>2,3</sup>, Boccalari E.<sup>2,3</sup>, Occhipinti C.<sup>1,3</sup>

<sup>1</sup>Department of Biomedical, Surgical and Dental Sciences, School of Dental Hygiene, University of Milan, Milan, Italy

<sup>2</sup>Department of Biomedical, Surgical and Dental Sciences, Postgraduate School of Orthodontics, University of Milan, Milan, Italy

<sup>3</sup>Fondazione IRCCS Ca' Granda, Ospedale Maggiore Policlinico, Milan, Italy

<sup>4</sup>Department of Biomedical, Surgical and Dental Sciences, Postgraduate School of Pediatric Dentistry, University of Milan, Milan, Italy

**Aim:** to study the oral effects caused by the hormonal changes that characterize the stages of women's lives: puberty, childbearing age and menopause.

**Methods:** a female population, free from pathologies and drug intake, was selected and divided according to the hormonal phase in: puberty (group A), ovulation phase without any therapy (group B), ovulation phase on estroprogestinic therapy (group C) and menopause (D). For each patient it was evaluated the status of the oral health through a screening examination involving the assessment of: Periodontal Screening Record (PSR); quantitative (FMBS) and semi-qualitative (IS) examination of bleeding; quantitative (FMPS) and semi-qualitative (IP) examination of plaque; salivary pH; antioxidant analysis at salivary level (sample processing to spectrophotometric analysis); quantitative examination of basal salivary flow compared to standard values ( $0.25 \text{ mL/min} \leq \text{basal salivary Vs} \leq 0.35 \text{ mL/min}$ ).

**Results:** the comparison of the results obtained in the different phases of female life allowed to establish a correlation between the status of gingival/periodontal inflammation and hormonal variations. In particular, group D (menopause) has to be considered at high risk of periodontitis, since the subjects in this group present FMBS at 29%, with a high number of salivary antioxidants (2238 thousand equivalents/L of vitamin C  $\mu\text{Mol/L}$ ), and a low value of the average salivary volume ( $0.19 \text{ mL/min}$ ). The other three groups present instead a reduced value of salivary antioxidants compared to the normal range ( $< 1000$ ), and index values of bleeding indicating the presence of gingivitis.

**Conclusion:** the results showed the need of planning screening and oro-dental prevention programs as a protection for the women's oral health during the hormonal changes that characterize her life.

## DENTAL VENEERS: HYGIENIC PROFESSIONAL NON INVASIVE APPROACH

Tetè G.<sup>1</sup>, Di Petto L.F.<sup>2</sup>, Polizzi E.M.<sup>3</sup>

<sup>1</sup>Department of Dentistry, Vita-Salute San Raffaele University, IRCCS San Raffaele, Milan, Italy

<sup>2</sup>CLID student, Vita-Salute San Raffaele University, IRCCS San Raffaele, Milan, Italy

<sup>3</sup>CLID coordinator, Vita-Salute San Raffaele University, Oral Hygiene and Prevention Center, Department of Dentistry, IRCCS San Raffaele, Milan, Italy

**Aim:** dental veneers are ceramic envelopes, thin plates cemented on the buccal surface of the healthy dental element, used to improve the aesthetics of the smile. In this way, defects in the shape, color or position of the teeth are hidden, sometimes also to modify occlusal parameters. A particular type of veneers are the additive or non-invasive aesthetic ones, also called no-prep: these are ultra-thin ceramic shells that are characterized by being 0.3-0.5 mm thick. In dentists there are various types of ceramics used for veneers.

**Methods:** literature research of MEDLINE (PubMed) and Cochrane Library was performed; no search field was restricted given the small number of articles.

**Results:** we were found 13 articles; 12 articles were considered according to inclusion and exclusion criteria.

Then one was excluded as it was not relevant to the aim of the study.

**Conclusion:** all in all, despite the small number of articles, we can say that the manual oral hygiene procedure makes the dental surface of the restorations smoother; while the use of ultrasonic may produce iatrogenic damage on the surface of the prosthetic elements. Furthermore, it is possible to state that only with the observance of a correct home protocol associated with a correct clinical protocol is it possible to maintain aesthetic rehabilitations and the integrity of the soft tissues adjacent to the prosthetic margin for a long term.

Further, *in vivo* clinical studies will be needed to confirm and reinforce these data and translate the results into the daily clinical practice of the dental hygienist.

## THE EFFICACY OF A NEW MOUTHWASH IN PLAQUE INDUCED GINGIVITIS: A PILOT RCT

Dolci C.<sup>1</sup>, Occhipinti C.<sup>2</sup>, Boccalari E.<sup>1</sup>

<sup>1</sup>Department of Biomedical, Surgical and Dental Sciences, Postgraduate School of Orthodontics, Fondazione IRCCS Cà Granda Ospedale Maggiore Policlinico, University of Milan, Milan, Italy

<sup>2</sup>Department of Biomedical, Surgical and Dental Sciences, Dental Hygiene degree course, Fondazione IRCCS Ca' Granda Ospedale Maggiore Policlinico, University of Milan, Milan, Italy

**Aim:** this study aims to analyse the efficacy of a mouthwash with a new formulation, enriched with Hyaluronic Acid (HA) and Hydrogen Peroxide (H<sub>2</sub>O<sub>2</sub>), compared with a hydro-based placebo.

**Methods:** this is a double blinded, randomized, 21-day, two-arm placebo-controlled pilot clinical trial. Fifty subjects with a diagnosis of plaque induced gingivitis were enrolled at the IRCCS Ca' Granda Ospedale Maggiore Policlinico of Milan. They were educated on oral hygiene and instructed to use the allocated mouthwash twice a day for 21 days. Subjects were evaluated at three time points during the 21 days by the same expert dental clinician. Silness and Löe Plaque Index (PI) and Gingival Index (GI) were used to assess the primary outcomes, which were represented by plaque accumulation and gingival

inflammation. Secondary outcomes were the evaluation of taste and smell between the two products.

**Results:** after 21 days both groups showed an improvement in both indexes, but only GI showed a statistically significant improvement with the new H<sub>2</sub>O<sub>2</sub>/HA formulation ( $p < 0.001$ ). Despite a remarkable decrease of PI too, this parameter did not statistically vary between the two groups ( $p = 0.084$ ). Regarding secondary outcomes, the new mouthwash had a pleasant taste and smell. No adverse events were reported by patients during the 21-day study period.

**Conclusion:** the new mouthwash proved to be effective in reducing gingival inflammation, especially when paired with proper oral hygiene.

## ORAL HEALTH IN PREGNANCY

Maia Corrêa F.<sup>1,4</sup>, Fraone I.<sup>1,4</sup>, D'Avola V.<sup>3,4</sup>, Bonura S.<sup>1,4</sup>, Cressoni C.<sup>1,4</sup>, Kashkaval V.<sup>1,4</sup>, Pasculli A.<sup>1,4</sup>, Quartiroli F.<sup>1,4</sup>, Occhipinti C.<sup>1,4</sup>, Boccalari E.<sup>2,4</sup>, Dolci C.<sup>2,4</sup>

<sup>1</sup>Department of Biomedical, Surgical and Dental Sciences, School of Dental Hygiene, University of Milan, Milan, Italy

<sup>2</sup>Department of Biomedical, Surgical and Dental Sciences, Postgraduate School of Orthodontics, University of Milan, Milan, Italy

<sup>3</sup>Department of Biomedical, Surgical and Dental Sciences, Postgraduate School of Pediatric Dentistry, University of Milan, Milan, Italy

<sup>4</sup>Fondazione IRCCS Ca' Granda, Ospedale Maggiore Policlinico, Milan, Italy

**Aim:** to assess the level of knowledge and bad oral and systemic unhealthy habits performed by pregnant women in order to plan prevention programs aimed at maintaining oral and systemic health status and ensuring support during the covid-19 emergency through social technology.

**Methods:** an epidemiological survey was conducted through a questionnaire composed of twenty-four-questions, was disseminated on the main social media platforms during the first lockdown of 2020 (March-April).

The participation was anonymous and on a voluntary basis. The sample consisted of 121 pregnant women and new mothers, between less than 18 years and 43 years of age.

The questionnaire concerned non-sensitive personal data such as: home oral hygiene devices (frequency of use, mode of purchase), importance attributed to the oral health, bad habits, correlation between oral cavity and pregnancy, signs and symptoms of pregnancy hormones, intake of supple-

ments and medications, presence of pregnancy-related and non-pregnancy-related diseases.

**Results:** among the majority of the sample agreed on the importance of oral health. 81% of participants did not use tongue cleaners and 69% did not use interdental hygiene devices. 51% of the volunteers stated that they had only heard about gingival/periodontal diseases during pregnancy. While 40.5% of the participants are not aware of the effects that oral diseases and smoke may have on children. They are also not aware of the age at which it is recommended to begin the taking care of their children's oral hygiene.

**Conclusion:** the results showed a confused discrepancy in the correlation between oral hygiene and pregnancy, but also the willingness of almost all of the participants to investigate the subject. This suggesting insisting with educational and preventive programs aimed to increase the awareness of among on pregnant women.

## OVER SIXTY YEARS OF SMILE: ORAL HEALTH IN ELDERLY PATIENTS

Maia Corrêa F.<sup>1,3</sup>, Quartirolì F.<sup>1,3</sup>, Kashkaval V.<sup>1,3</sup>, Pasculli A.<sup>1,3</sup>, Cressoni C.<sup>1,3</sup>, Boccalari E.<sup>2,3</sup>, Dolci C.<sup>2,3</sup>, Hu L.<sup>1,3</sup>, Occhipinti C.<sup>1,3</sup>

<sup>1</sup>Department of Biomedical, Surgical and Dental Sciences, School of Dental Hygiene, University of Milan, Milan, Italy

<sup>2</sup>Department of Biomedical, Surgical and Dental Sciences, Postgraduate School of Orthodontics, University of Milan, Milan, Italy

<sup>3</sup>Fondazione IRCCS Ca' Granda, Ospedale Maggiore Policlinico, Milan, Italy

**Aim:** our research aims to assess the self-perception of the elderly regarding their oral health and dental needs.

**Methods:** forty-four subjects (27 females and 17 males) between 62 and 92 years of age were interviewed. Thirty questions divided into four categories were given: personal information; oral health; home hygiene; and the patient and his or her needs. The Geriatric Oral Health Assessment Index (GO-HAI) was used to assess oral self-perception, masticatory function, and psychosocial impact.

**Results:** 22.7% said they limit contact with other people because of problems with their teeth or prosthesis, and 34,1% responded that they had taken medication to relieve some dis-

comfort or pain in the mouth. 70.5% considered having all their teeth in their mouth to be the most important thing in smiling while 40,9% would choose to treat the health of the gum and 45,5% would change the color of the teeth if given the opportunity.

**Conclusion:** the elderly patient represents the future of dentistry. This age group highlights problems related to poor or lack of oral prevention, and in many cases, misinformation about the maintenance and care of teeth, gums, dentures, and medical devices for oral buccal hygiene. People over the age of 60 need personalized attention to their needs and requirements.

## PREVALENCE OF POSITIVE TESTS FOR SARS-COV-2 IN DENTAL PRIVATE OFFICE

Muneratto A.<sup>1</sup>, Hatami S.<sup>1</sup>, De Stefani A.<sup>2</sup>, Bruno G.<sup>2</sup>, Gracco A.<sup>3</sup>, Stellini E.<sup>4</sup>

<sup>1</sup>Undergraduate student, University of Padua, Padua, Italy

<sup>2</sup>DDS, Faculty of Dentistry, University of Padua, Padua, Italy

<sup>3</sup>Associate Professor, Faculty of Dentistry, University of Padua, Padua, Italy

<sup>4</sup>Professor, Department of Neuroscience, School of Dentistry, University of Padua, Padua, Italy

**Aim:** a quick diagnosis is crucial in effectively limiting the spread of SARS-CoV-2. The aim of this study is to assess the prevalence of positive rapid tests in private dental practices. 532 tests were carried out in the Veneto region of Italy, 38 of them resulted positive.

**Methods:** patients of 4 dental practices in different cities in the Veneto region (Caorle, Montebelluna, Treviso and Vicenza) were screened with a rapid test throughout November and December 2020. All the positive results from rapid tests were further investigated with a molecular test. All of the patients tested showed no symptoms associated with SARS-CoV-2 infection and had already undergone triage and temperature measurement. In total 532 tests were taken: 202 in Caorle, 130 in Montebelluna, 100 in Treviso and 100 in Vicenza.

**Results:** the prevalence of positive tests was 38 out of 532 (7.14%): 22 out of 202 in Caorle, 6 out of 130 in Montebelluna, 4 out of 100 in Treviso and 6 out of 100 in Vicenza.

The patients with positive test performed a molecular test and 36 of them resulted positive (94.74%), in particular 21 in Caorle, 5 in Montebelluna, 4 in Treviso and 6 in Vicenza. Only 2 positive rapid test were not confirmed by the molecular.

**Conclusion:** the prevalence of positive patients screened with a rapid test in private dental practices stands at 7.14% and it is confirmed in most of the patients with molecular tests. Therefore, in high risk environments like dental practices, it is imperative to follow thoroughly all the precautionary measures and having every patient tested with a rapid swab could be taken into consideration.

## OZONIZED GEL IN THE TREATMENT OF PERIODONTITIS

Pellegrini M., Gallo S., Spinelli A., Ciuffreda M., Viola M., Nardi M.G.

Department of Clinical-Surgical, Diagnostic and Pediatric Sciences, Section of Dentistry, University of Pavia, Pavia, Italy

**Aim:** evaluation of the effectiveness of subgingival application of an experimental ozone gel in addition to standard SRP, as well as to compare this protocol with SRP plus a conventional chlorhexidine gel, in patients with chronic periodontitis.

**Methods:**

- ozonized gel (GeliO3, Bioemmei Srl, Vicenza, Italy);
- chlorhexidine gel (Curasept Parodontal gel 1% Ads, Curasept SPA, Saronno, Varese, Italy).

A total of 10 patients was selected for the study respecting the inclusion and exclusion criteria.

During the first visit, participants underwent a professional oral hygiene and two weeks later (T0) periodontal clinical indexes were assessed: PPD, CAL, GI, PI, BoP. Each quadrant of the mouth was randomly assigned to a treatment with SRP + Curasept Parodontal gel and with SRP + GeliO<sub>3</sub>. After 1 (T1) and 3 months (T2) from baseline (T0), patients were revisited and periodontal clinical indexes were assessed. Chairside instructions for a correct domiciliary oral hygiene were repeated

to participants at each appointment. Professional oral procedures and outcomes assessment were respectively executed by two operators and data analyst was always blinded during the study. Patients were asked not to reveal their respective treatment to the data assessor. Statistical analysis using software R; normality of data calculated by Kolmogorov-Smirnov test and subsequently a repeated measures ANOVA was applied. Significance for all statistical tests was predetermined at  $P < 0.05$ .

**Results:** all clinical indexes tested significantly improved after 1 and 3 months from baseline, both with ozone and chlorhexidine, with statistically significant intragroup differences ( $P < 0.05$ ). The additional use of GeliO<sub>3</sub> in addition to SRP does not show significant differences compared to SRP plus Curasept Parodontal gel ( $P > 0.05$ ).

**Conclusion:** GeliO<sub>3</sub> could be a valid support for nonsurgical treatment of chronic periodontal disease, given the lack of the major shortcomings associated with chlorhexidine.

## SEROLOGICAL PROFILE OF CHILDREN AND YOUNG ADULTS WITH SARS-COV-2 POSITIVE COHABITANT

Farronato M.<sup>1,2</sup>, Dolci C.<sup>1,2</sup>, Boccari E.<sup>1,2</sup>, Pacini M.<sup>1,2</sup>, Serafin M.<sup>1,2</sup>, Caprioglio A.<sup>1,2</sup>, Tartaglia G.M.<sup>1,2</sup>

<sup>1</sup>Department of Biomedical, Surgical and Dental Sciences, School of Dentistry, University of Milan, Milan, Italy

<sup>2</sup>Fondazione IRCCS Ca' Granda, Ospedale Maggiore Policlinico, Milan, Italy

**Aim:** the aim of this study is to evaluate, through a qualitative detection of IgG and IgM antibodies to SARS-CoV-2, the impact of COVID-19 on people between 4 and 16 years old who belong to families with at least one positive swab result for the virus. Evaluation of the serological profile of this sample could allow us to assess the rate of contagion of children directly exposed to a known positive family member within a family cluster.

**Methods:** the analyzed sample included children between 4 and 16 years of age who belonged to families with at least one positive swab result for COVID-19. Forty-nine children and adolescents with a mean age of 11 years were then subjected to a rapid lateral flow chromatographic test for IgM/IgG antibodies to Coronavirus. T-test and Mann Whitney test were used to evaluate quantitative variables while Chi-squared test and Fisher's exact test were used to evaluate categorical ones.

**Results:** the serological tests were carried out between 22 and 152 days after adult's diagnosis and between 7 and 134 after the adult's negativization. Seven (14.3%) were immunoglobulin G (IgG)-positive and 4 (8.2%) were immunoglobulin M (IgM)-positive. The logistic regression on IgG positivity did not show a statistically significant influence by the evaluated variables. However, subjects tested more than 73 days after the adult negativization showed a lower probability of receiving a positive result.

**Conclusion:** in total, 16.3% of the tested sample had antibodies against SARS-CoV-2; this may confirm the lower vulnerability of children to COVID-19, despite the small sample size. The time from the negativization of the cohabitant until the test day may have influenced the results, especially when this timeframe is wide.

## THE ADHESION OF BACTERIAL PLAQUE ON ZIRCONIA CROWNS: A NARRATIVE REVISION

Triggiani C.

**Aim:** this narrative review aims to investigate the adhesion of bacteria-biofilm bacterial plaque to zirconia crowns on prosthetic-implant rehabilitation in terms of quality and quantity.

**Methods:** a literature research of MEDLINE (PubMed) between 2003 and 2020 including the key words “plaque and zirconia crown”.

**Results:** we found 60 articles, and respect to inclusion criteria only 2 articles was considered.

**Conclusion:** prosthetic rehabilitations require an oral hygiene maintenance program to avoid failure. During the follow-up period, zirconia crowns on natural teeth were observed to

have low bacterial biofilm adhesion and excellent gingival sealing, this is due to the smoothness of the surface and excellent biocompatibility of the material.

When the profile of the zirconium crown cemented on implant components is correct, the adhesion of the bacterial biofilm is the same as a crown cemented on a natural tooth.

The comparison between customized and standard abutments do not show any particular aesthetic and functional differences.

Despite the limitations of this review, for the low number of articles, our study can be a basis for further *in vitro* or *in vivo* studies.

## IN VITRO COMPARISON BETWEEN ELECTRIC AND MANUAL TOOTHBRUSHES

Agalliu A., Gronelli G., Semez G., Nicolin V., Costantinides F., Frattini C., Bevilacqua L.

Unit of Periodontology and Dental Hygiene, School of Dental Sciences, Department of Medical, Surgical and Health Sciences, University of Trieste, Trieste, Italy

**Aim:** to evaluate four types of toothbrushes (manual, sonic, oscillating-rotating and magnetic) and their effectiveness *in vitro* in removing plaque.

**Methods:** the tests have been performed on the four lower incisors of a typodont. A dental spray (Techim ST 18 Spray), to simulate the plaque, was removed with each of the toothbrushes at three different stages (T1 = 10 sec, T2 = 20 sec and T3 = 30 sec).

Photos of each of the phases were analyzed by a cad program which provides a percentage of residual plaque dividing each dental element into three macro-areas (mesial, distal and vestibulo-lingual surface).

All data were subjected to a descriptive analysis and two statistical tests: Kruskal Wallis and Mann-Whitney.

**Results:** all devices are more effective on the buccal-lingual surfaces than the interproximal ones. The oscillating rotating toothbrush is more effective than the sonic at T1 and T2 showing a worse data, however, at T3. The manual toothbrush, although effective, shows the worst performance among the four technologies; the best, in all time stages, is magnetic toothbrush.

**Conclusion:** the present study confirms superior effectiveness and efficacy of electric toothbrushes. It could be suggested that magnetic technology is the only one that at the end of the cycle (30 sec) falls below 10% of residual plaque.

## ORAL DISORDERS AND ORAL HYGIENE HABITS IN PREGNANCY: A COGNITIVE SURVEY

Ludovichetti F.S., Piovan S., Fioretti A., Cavallari F., Signoriello A.G., Barrucci G., Zuccon A.

Neurosciences Department – Dentistry Section, University of Padua, Padua, Italy

**Aim:** the gestation period involves a series of changes in all maternal organs and systems, due to hormonal fluctuations that also affect the oral cavity, leading to possible development of diseases such as gingivitis, oral pregnancy tumor or periodontitis. Over the years, the positive correlation between poor oral health and adverse outcomes in pregnancy, such as fetal changes, low birth weight, preterm birth or preeclampsia, has also been highlighted. Purpose: to analyze and understand the levels of knowledge and information of pregnant women about the possible repercussions that they may have on the oral cavity, caused by hormonal alterations.

**Methods:** a questionnaire of 28 multiple choice questions was formulated and published online from 01/02/2020 to 31/08/2020, aimed at pregnant women and new mothers. The

Google Forms platform was used to collect the data which were then statistically analyzed by creating crosstabs with multiple dependency variables.

**Results:** the study cohort was represented by 1191 women, whose responses first showed that about half were unaware of the predisposition to develop infections and periodontal problems during the gestation period. The same noticed bleeding and gum swelling during brushing and despite this, only 21% visited their dentist to resolve the situation. Furthermore, 88.2% of all women did not know that problems in the oral cavity can lead to adverse pregnancy outcomes.

**Conclusion:** primary prevention is essential and must be implemented with the collaboration of the various professional figures who follow the woman during gestation.

## IN VITRO STUDIES EVALUATING THE EFFICACY OF MOUTHWASHES ON SARS-COV-2: A SYSTEMATIC REVIEW

Boccalari E., Serafin M., Dolci C.

Department of Biomedical, Surgical and Dental Sciences, Postgraduate School of Orthodontics, University of Milan, Milan, Italy

**Aim:** the aim of this systematic review is to evaluate the efficacy of several mouth rinses on SARS-CoV-2 in *in vitro* studies.

**Methods:** five databases were searched up to February 2021. Both selection and data extraction processes were conducted by two independent reviewers. The risk of bias was assessed using the toxicological data reliability assessment tool (TOXR-TOOL).

**Results:** starting from 239 articles, retrieved by the electronic search, only 8 studies were then included in our systematic review. The analysis of the results was performed considering several groups of actives, including povidone-iodine (PVP-I), hydrogen peroxide (H<sub>2</sub>O<sub>2</sub>), chlorhexidine (CHX) and ethanol, evaluating their virucidal activity. Regarding the risk of bias, 6 of the included studies reported a low risk of bias, with a score  $\geq 15$  while 2 articles had a score equal to 14, suggesting their

reliability even with restrictions. PVP-I proved to be effective in killing SARS-CoV-2, even though cytotoxicity of the active must be considered. Some articles have shown its effectiveness even at different concentrations and after only 15 seconds. Other compounds, such as dequalinium chloride/benzalkonium chloride and ethanol (alone or combined with essential oils) have also shown good results in reducing viral load. H<sub>2</sub>O<sub>2</sub>, on the other hand, showed less efficacy and greater cytotoxicity than PVP-I. Conflicting results were found about the effectiveness of CHX.

**Conclusion:** *in vitro* researches have shown the efficacy of some actives, such as PVP-I, dequalinium chloride/benzalkonium chloride and ethanol (alone or with essential oils), in reducing viral load. Clinical studies will be essential to confirm their effectiveness *in vivo*.

## IMPACT OF ORAL HEALTH ON THE QUALITY OF LIFE OF CHILDREN WITH ASD AND THEIR FAMILIES

Caserta I.<sup>1</sup>, Bontà G.<sup>1</sup>, Campus G.<sup>2</sup>, Cagetti M.G.<sup>1</sup>

<sup>1</sup>Department of Biomedical, Surgical and Dental Sciences, University of Milan, Milan, Italy

<sup>2</sup>Klinik für Zahnerhaltung, Präventiv- und Kinderzahnmedizin, Zahnmedizinische Kliniken (ZMK), Universität Bern, Bern, Switzerland

**Aim:** this study aims to evaluate the impact of Oral Health on the quality of life of children with autism spectrum disorder (ASD) and their families.

**Methods:** three-hundred parents/caregivers of children with ASD (aged 3-18 years), regularly attending a preventive program based on fluoride varnish and oral hygiene maintenance at the Pediatric Dentistry Department of the Dental Clinic of the ASST Santi Paolo e Carlo in Milan, were invited to participate in two standardized questionnaires. The Parental/Caregiver Perception Questionnaire (PCPQ), which investigates the measure of parental/caregivers' perceptions of the impact of children's oral health on quality of life, and the Family Impact Scale Questionnaire (FIS), which measures the impact of the oral condition on the quality of life of the entire family, were sent via e-mail.

**Results:** one-hundred-sixty-nine questionnaires returned; the risk of worsening the quality of life related to PCPQ was low in

62.70% of the children (106 subjects), moderate in 36.68% (62 subjects), and only in one subject the risk was high (0.59%). Regarding the FIS, the majority of the subjects resulted at moderate risk (66.86%, 113 subjects out of 169), followed by subjects presenting a low risk (30.76%, 52 subjects) and finally those who present a high risk, equal to 2.36% of the sample (4 subjects).

The overall risk of worsening quality of life was calculated (PCPQ+FIS). The majority of participants showed a moderate risk (52.66%, 89 subjects), followed by subjects at low risk (46.74%, 79 subjects) and finally by children at high risk (0.59%, one subject).

**Conclusion:** regular dental visits and oral health preventive programs are essential for children with ASD to maintain a low risk of worsening the quality of life of children and families, reducing stress in the family members.

## ORAL HEALTH STATUS IN PARENTS OF CHILDREN WITH DISABILITIES: A COGNITIVE SURVEY

Corridore D., Di Blasio A., Mazur M., Capocci M., Ndokaj A., Voza I., Nardi G.M., Guerra F., Ottolenghi L.

Department of Odontostomatological and Maxillofacial Sciences, Policlinico Umberto I of Rome, Rome, Italy

**Aim:** evaluate, through digital questionnaires, the oral health of parents / guardians of patients with disabilities, their habits regarding oral health and treatments and finally to evaluate clinical oral health conditions.

**Methods:** parents belonging to the Tuberous Sclerosis Association based in Rome were involved in this study. Questionnaire has been created on top of four different types of questionnaires and delivered through web link generated by Survio platform.

**Results:** 39% of the sample had to give up visits despite needing them for the following reasons: 23.5% had to look after children or other people, 29.4% could not pay, it cost too much, 47.1% for other reasons. 24.4% have suffered or still suffer from problems related to depression. Does the presence of a disabled child prevent or materially delay the prac-

tice of dental hygiene or the use of dental care? “ for 34% of the sample.

To the question: “How do you perceive your overall oral health?” the answers were the following (On a scale of 0 = very bad to 5 = excellent): 2.4% answered 0, 4.9% answered 1, 9.8% answered 2, 46.3% answered 3, 29.3% answered 4 and 7.3% answered 5.

**Conclusion:** the birth of a disabled child implicates a redefinition of family life. Parents face something they are not prepared for, which affects their mental health, often experiencing anxiety and other depression related problems. The halo effect interferes with both the disabled patient care and the oral health of their parents/guardians. It is also evident that families need support from various health professionals to cope with the various commitments involving the care of a disabled child.

## EFFICACY OF NUTRACEUTICAL AGENTS FOR PERIODONTAL PROPHYLAXIS: A RANDOMISED CLINICAL TRIAL

Di Gregorio F.<sup>1</sup>, Polizzi A.<sup>1</sup>, Santonocito S.<sup>1</sup>, Iorio Siciliano V.<sup>2</sup>, Ramaglia L.<sup>2</sup>, Isola G.<sup>1</sup>

<sup>1</sup>Department of General Surgery and Surgical-Medical Specialties, School of Dentistry, University of Catania, Catania, Italy

<sup>2</sup>Department of Neurosciences, Reproductive and Odontostomatological Sciences, School of Medicine, University of Naples Federico II, Naples, Italy

**Aim:** persistence of periodontal inflammation could bring to residual pocketing and periodontal bacteria's constant presence, which, in turn, rebound tissue destruction. The present study analyzed and compared new nutraceutical agent as an adjunct to NSPT versus NSPT alone for the treatment of periodontitis.

**Methods:** 66 patients with a diagnosis of periodontitis were enrolled. Patients were randomly allocated to the test group (NSPT + nutraceutical agent) or the control group (NSPT alone). Clinical data, inflammatory mediators and VAS were recorded in all patients over a 6-month period. CAL was chosen as the primary outcome.

**Results:** the test group determined a significant PD ( $p = 0.003$ ) and BOP reduction ( $p < 0.001$ ) compared with the control

group. The test group obtained a significant CAL gain at 30 and 60 days after treatment ( $p < 0.05$ ). The test group presented significantly lower median levels of IL-1 $\beta$  at 15, 30 and 60 days after treatment compared with controls ( $p < 0.05$ ). Median levels of TNF- $\alpha$  at 30 days ( $p < 0.05$ ) were significantly lower in the test group compared with controls. The treatments carried out in the test group influenced the VAS score significantly at 6, 12, 24 and 48 h after treatment ( $p < 0.05$ ).

**Conclusion:** nutraceutical agent in the non-surgical periodontal therapy was demonstrated to be effective in reducing periodontal parameters and controlling the levels of Inflammatory mediators and pain in comparison to NSPT alone treatment.

## A RANDOMISED CLINICAL TRIAL FOR BETWEEN TWO SALIVARY SUBSTITUTES IN RADIO-TREATED PATIENTS

Gaiero C.<sup>1</sup>, Gassino L.<sup>2</sup>, La Bruna P.<sup>3</sup>, Lanzetti J.<sup>3</sup>, Bassi F.<sup>4</sup>

<sup>1</sup>Student, University of Turin, Turin, Italy

<sup>2</sup>Student, Universidade Fernando Pessoa, Oporto, Portugal

<sup>3</sup>DH, University of Turin, Turin, Italy

<sup>4</sup>MD, DDS, Full Professor, University of Turin, Turin, Italy

**Aim:** xerostomia is the subjective sensation of dry mouth, a common symptom with a variety of causes. A major cause of xerostomia is radiation therapy for cancers of the head and neck, where the salivary glands are close to or within the field irradiated. The aim of this study was to evaluate the incidence of radiotherapy on the both quantitative and qualitative alteration of the saliva and consequent frequency of radio-induced dental decay.

**Methods:** twenty-six patients with head and neck cancer were randomly allocated to receive either Biõtene Oral Balance gel than Hydral Gum, each product for 2 weeks. Subjects-based dry mouth scores derived from 100 mm visual analogue scales were recorded at day 0 and 7, together with a subjective perception of changes in dry-mouth symptoms. Visual inspection

of level of hydration, consistency of saliva, pH measurements were recorded at baseline and two months following radiation therapy.

**Results:** both products were effective in alleviating the symptoms of post-radiotherapy xerostomia, resulting in improvements in salivary flow ( $p < 0,05$ ). Between groups comparison no statistical differences were found.

**Conclusion:** however, the study only found a moderate benefit, as decrease of baseline VAS xerostomia values did not exceed. Importantly, dry mouth is a chronic problem in many clinical settings, and trials should evaluate not only the effectiveness of treatment in reducing xerostomia but also the impact of the long-term effects of treatments on the quality of life in patients with chronic dry mouth symptoms.

## ORAL HEALTH AND PREGNANCY: THE ROLE OF PREGNANCY HORMONES: A CASE REPORT

Kashkaval V.<sup>1,4</sup>, Bonura S.<sup>1,4</sup>, D'Avola V.<sup>3,4</sup>, Fraone I.<sup>1,4</sup>, Quartiroli F.<sup>1,4</sup>, Maia Corrêa F.<sup>1,4</sup>, Cressoni C.<sup>1,4</sup>, Pasculli A.<sup>1,4</sup>, Boccalari E.<sup>2,4</sup>, Dolci C.<sup>2,4</sup>, Occhipinti C.<sup>1,4</sup>

<sup>1</sup>Department of Biomedical, Surgical and Dental Sciences, School of Dental Hygiene, University of Milan, Milan, Italy

<sup>2</sup>Department of Biomedical, Surgical and Dental Sciences, Postgraduate School of Orthodontics, University of Milan, Milan, Italy

<sup>3</sup>Department of Biomedical, Surgical and Dental Sciences, Postgraduate School of Pediatric Dentistry, University of Milan, Milan, Italy

<sup>4</sup>Fondazione IRCCS Ca' Granda, Ospedale Maggiore Policlinico, Milan, Italy

**Aim:** to evaluate the oral effects of pregnancy hormones through the observation of a single clinical case.

**Methods:** a pregnant woman was monitored from the third to the thirty-sixth week of gestation. We evaluated the following parameters: basal salivary flow, salivary pH, bleeding during brushing, presence of halitosis, home remedies used and bad eating habits.

**Results:** it was found that in the first trimester the value of salivary pH reached an average value of 5.8, due to the presence of gastroesophageal reflux, emesis and diet rich in simple sug-

ars. In the same period it has been observed an increase in the average basal salivary flow of 0.5 mL/min as a result of the natural defense of the body implemented to counteract the acidity. Finally, gingival bleeding was recorded in both arches, during the home oral hygiene maneuvers, mostly in the 5th and 6th month of pregnancy.

**Conclusion:** the correlation between pregnancy and oral health was confirmed. In addition, it was observed that in the first trimester of gestation, the risk of developing problems in the oral cavity, is increased.

## ARTIFICIAL INTELLIGENCE (AI) IN DENTISTRY: WHERE ARE WE NOW AND WHERE ARE WE GOING

Mazur M., Jedlinski M., Ndokaj A., Corridore D., Capocci M., Pasqualotto D., Ripari F., Guerra F., Ottolenghi L.

Department of Odontostomatological and Maxillofacial Sciences, Policlinico Umberto I of Rome, Rome, Italy

**Background:** artificial intelligence is a term describing processes occurring in machines that are associated with processes such as an attempt to define a given concept, classify concepts or draw conclusions based on experiences from the past. Its use is becoming more and more popular in dentistry.

**Aim:** the aim of the study is to discuss the use of artificial intelligence in various dental specialties and identify the limitations and future opportunities.

**Methods:** a systematic review was conducted. Literature searches were performed using MedLine (PubMed), Web of Science, Scopus (December 2020).

**Discussion:** artificial intelligence and deep learning are used with success in many branches of dentistry. Successes and constantly increasing accuracy can cause the spread of its use outside of academic centers.

**Conclusion:** the Artificial Intelligence concept in medicine meets contemporary approaches to disease as precise forecasting, prevention, individualized planning and treatment. They have certainly shorten the diagnostic process and allow it to be objectively verified. It should begin to trust it, use it and improve by adding new cases through the deep learning process.

## TREATMENT OF DENTINE HYPERSENSITIVITY: ONE SHOT THERAPY OR REPEATED APPLICATIONS? COMPARIS

Mazur M., Jedlinski M., Ndokaj A., Corridore D., Capocci M., Pasqualotto D., Ripari F., Guerra F., Ottolenghi L.

Department of Odontostomatological and Maxillofacial Sciences, Policlinico Umberto I of Rome, Rome, Italy

**Background:** the definition of dental hypersensitivity is "pain derived from exposed dentin in response to chemical, thermal tactile or osmotic stimuli which cannot be clarified as result

from other dental disease. The reported prevalence varies from 1% to 98% with great variability among studies. In clinical practice the diagnosis is done after excluding other causes

of unpleasant sensations. No specific pathogenesis has been assigned to dental hypersensitivity, except for Brannstrom's hydrodynamic theory. One of the treatments proposed by this theory is tubular occlusion with different working agents.

**Aim:** the aim of this *in vivo* randomized clinical trial with split-mouth design was to evaluate the clinical efficacy of one in-office application of a fluoride containing varnish, Bifluorid (Voco, Cuxhaven, Niedersachsen, Germany) and in office application of a bonding resin, Futurabond (Voco, Cuxhaven, Niedersachsen, Germany) in adult patients presenting with dentin hypersensitivity. Material and methods: A total of 90 teeth were treated by Bifluorid and 80 – by Futurabond U. Baseline pain in Bifluorid group was slightly higher on both scales (SCHIFF and VAS). Outcome measurements were assessed one or two

weeks before product application (enrollment), at baseline at the application days (end of the run-in period: T0a, T0b, T0c), and at 1 week and at 1-2-6 months after first treatment.

**Results:** both treatments reduced pain intensity at each stage. Bifluorid 10 and Futurabond U have similar efficacy in reducing SCHIFF-measured pain reduction, while Bifluorid 10 is significantly more efficient for VAS-measured pain reduction, mainly due to reduction at last stage of study (i.e., 2-6 month after last treatment). Patient's age has significant negative influence on pain reduction (both SCHIFF and VAS-measured), while influence of patient's gender and BEWE of the tooth is insignificant.

**Conclusion:** Bifluorid 10 and Futurabond U are effective agents in the treatment of dental hypersensitivity.

## EVALUATION OF PLAQUE AND BLEEDING IN A DIFFERENT ORTHODONTIC PATIENTS THERAPY

Nardi N., Bica E., Nucci F., Maspero C., Gianni A.B., Spadari F.

Department of Orthodontics, Policlinico Ca' Granda, University of Milan, Milan, Italy

**Aim:** the aim of this study is to compare everyday's oral hygiene in patients treated with fixed appliances (metal and ceramic brackets) and Invisalign.

**Methods:** 40 patients in orthodontic treatment, were selected from the department of orthodontics of the University of Milan. 19 men and 21 women in a range between 13 to 23 years old.

The group of patients was divided equally, 20 treated with invisalign and 20 treated with fixed appliances. Plaque score (PS) and bleeding score (BS) was calculated on all patients at T0 (after a month of therapy) and at T1 after 4 months of therapy. Each patient at T0 was instructed on how to maintain a

good oral hygiene (brushing and flossing 3 times per day with both manual and electric toothbrush).

**Results:** at the end of the third month of therapy, each patient was then analyzed again. Significant differences have been observed between the two group of patients. Patients treated with Invisalign had a bleeding score increased of 20% and the plaque score increased of the 5%. Patients treated with fixed appliances (metal and ceramic brackets) had a bleeding score increased of 20, 30%, while a plaque score between the 30-35%.

**Conclusion:** patients treated with invisalign can have a better control of their oral hygiene than patients treated with conventional fixed appliances.

## ANTIBACTERIAL EFFECTS OF BIOREPAIR PERIBIOMA TOOTHPASTE AND CHEWING GUM: AN *IN VITRO* STUDY

Odorici A.<sup>1</sup>, Colombari B.<sup>2</sup>, Meto A.<sup>1</sup>, Pericolini E.<sup>2</sup>, Blasi E.<sup>2</sup>

<sup>1</sup>School of Doctorate in Clinical and Experimental Medicine, Laboratory of Microbiology and Virology, University of Modena and Reggio Emilia, Modena, Italy  
<sup>2</sup>Department of Surgery, Medicine, Dentistry and Morphological Sciences with interest in Transplant, Oncology and Regenerative Medicine, Laboratory of Microbiology and Virology, University of Modena and Reggio Emilia, Modena, Italy

**Aim:** we evaluated *in vitro* the antibacterial effects of two commercially available products, a toothpaste and chewing gum named Biorepair®PERIBIOMA™, on oral microorganisms from healthy donors.

**Methods:** six healthy volunteers were selected, according to the inclusion and exclusion criteria. Moreover, mouthwashes were prohibited for the duration of the study, while food and drinks were allowed up to 1 h before dentistry visit. The en-

rolled patients were asked donate their own saliva in 3 subsequent sessions (every 2 weeks). For the saliva collection, the volunteers were provided with two different types of chewing gum, a traditional gum (gum A) and a Biorepair®PERIBIOMA™ gum (gum P) (Coswell SpA, Bologna, Italy), both sugar-free, hereinafter referred to as gum A and gum P. Saliva from these volunteers was collected during mastication of such chewing gums (20 min: gum A; 20 min: gum P). Then, the salivary samples were pooled to obtain the saliva A and saliva P that were then used to contaminate *in vitro* the orthodontic elastics (OE). Once contaminated, the OE were exposed or not to a supernatant conditioned with toothpaste Biorepair®PERIBIOMA™ (Tp-SUP). By standard colony forming units (CFU) assays, the initial microbial load was evaluated in saliva A and P; also, microbial growth, adhesion, biofilm formation and persistence onto OE were assessed; species identification was achieved by MALDI-TOF analysis.

**Results:** we found that salivary samples A and P had somehow a similar microbial load; in contrast, microbial adhesion to OE was detected to a lower extent, when using saliva P compared

to saliva A. Also, microbial growth and biofilm formation, assessed at 24 h, remained at lower levels in OE exposed to saliva P, with respect to those exposed to saliva A. Such a difference between A and P saliva was further confirmed by measuring the persistence of the biofilm (48 h), while it was lost in terms of microbial regrowth (48 h). Finally, Tp-SUP treatment drastically influenced the microbial load at 24 h and strongly impaired biofilm formation/persistence in OE exposed to either saliva A or saliva P samples. Eventually, this treatment resulted in an overgrowth of Lactobacilli, bacterial species originally present in both Biorepair®PERIBIOMA™ toothpaste and gum. In preliminary experiments, Tp-SUP was found to drastically impair also growth and biofilm production of *Pseudomonas aeruginosa*, a highly tolerant pathogen, thus further strengthening the antimicrobial efficacy of the Biorepair®PERIBIOMA™ products.

**Conclusion:** by this *in vitro* study, we demonstrate that Biorepair®PERIBIOMA™ toothpaste and gum profoundly affect the behavior of oral microorganisms, drastically compromising their ability to contaminate and produce plaque on orthodontic devices.

## ENAMEL DEFECTS IN CELIAC DISEASE

Pasculi A.<sup>1,3</sup>, Cicero A.<sup>1,3</sup>, Boccari E.<sup>2,3</sup>, Dolci C.<sup>2,3</sup>, Kashkaval V.<sup>1,3</sup>, Quartiroli F.<sup>1,3</sup>, Cressoni C.<sup>1,3</sup>, Maia Corrêa F.<sup>1,3</sup>, Occhipinti C.<sup>1,3</sup>

<sup>1</sup>Department of Biomedical, Surgical and Dental Sciences, School of Dental Hygiene, University of Milan, Milan, Italy

<sup>2</sup>Department of Biomedical, Surgical and Dental Sciences, Postgraduate School of Orthodontics, University of Milan, Milan, Italy

<sup>3</sup>Fondazione IRCCS Ca' Granda, Ospedale Maggiore Policlinico, Milan, Italy

**Aim:** the purpose of this research is to investigate the possible correlation between Celiac Disease (CD) and the Developmental Defects of Enamel (DDE), in order to allow an early detection and treatment.

**Methods:** we collected data of 1569 subjects with CD (1403 females and 166 males), aged between 2 and 72 years old and coming from all over Italy, through an interview. It included 28 questions about their personal information, home oral hygiene, professional oral hygiene, dietary habits, fluoride exposure and the presence of White Spot Lesions (WSL), namely pre-carious white-chalky lesions, and Brown Spot Lesions (BSL), namely yellow to dark brown spots.

**Results:** the results showed that 47.9% of subjects with CD had WSL visible to the naked eye and in 60% of cases these were present on two or more teeth.

With regard to BSL, they were found in 19.4% of the included subjects and in 60.4% of cases the affected teeth were two or more. The teeth that were most frequently affected by both White Spot and Brown Spot Lesions turned out to be the upper central incisors (11 and 21).

In addition, 85.9% of subjects reported that they never underwent fluoroprophyllaxis and 36.3% of them reported that they wore fixed orthodontic braces.

**Conclusion:** the study shows a possible correlation between CD and DDE. As reported by scientific literature, demineralization can be caused by the decrease in salivary flow, which reduce the buffering capacity of saliva. A careful examination of the oral cavity can allow dentists and dental hygienists to detect demineralization sites potentially associated with CD, allowing early diagnosis and prevention of complications of the disease.

## “TWO CHEWING GUM TEST”: A MEAN TO MEASURE MASTICATORY FUNCTION OF OBTURATOR PROSTHESIS

Albanese G.<sup>1</sup>, Ciocia A.<sup>2</sup>, Barile G.<sup>1</sup>, Carnevale A.<sup>2</sup>, Pedone S.<sup>2</sup>, Liotino G.<sup>2</sup>

<sup>1</sup>Specialization School of Oral Surgery, Department of Interdisciplinary Medicine, University of Bari Aldo Moro, Bari, Italy

<sup>2</sup>Department of Interdisciplinary Medicine, University of Bari Aldo Moro, Bari, Italy

**Aim:** the most common approach to reconstruct the maxillary defect after neoplasms resection is the use of a removable prosthetic obturator. In this study authors evaluate either aesthetic or function rehabilitation by obturator prosthesis in oncologic patients.

**Methods:** all patients have been provided with surgical, temporary and definitive obturator. During follow up visits patients asked a questionnaire formed by 3 domains to give a subjective evaluation, then clinician conducted an objective evaluation giving a score with Kapur system. When obturator didn't need no further changes, it was evaluated masticatory function with “two colours chewing gum test”.

**Results:** 25 patients were included into the study: 14 males and 11 females, with a mean age of 63.4 years.

Regarding subjective evaluation 7 patients (28%) rated low score and 18 patients (72%) rated high score. Objective evaluation domain demonstrates good results regarding retention (2.4/3 points) and stability (1.6/2 points).

Two colors chewing gum test demonstrated good function: 1 patient showed first grade (4%), 6 patients showed second grade (24%), 8 patients showed third grade (32%), 10 patients showed fourth grade (40%).

**Conclusion:** obturator is widely accepted, for a long time, as gold standard prosthetic treatment of oncologic patients with acquired maxillary defects. Good design is mandatory to overcome type and size of maxillary defects, confirming to be most predictable solution in order to improve oncologic patients QoL.

## TiO<sub>2</sub>(TITANIUM DIOXIDE) AND Ag(SILVER) NANOPARTICLES INCLUSION INTO POLYMETHYL-METHACRYLATE PHYSICAL-MECHANICAL AND MICROBIOLOGICAL EVALUATION STUDY

Albanese G., Salerno C., Carminucci F., Soranna A., Campanella G., Ciocia A.

Interdisciplinary Department of Medicine (D.I.M.) – Dental School, University of Bari Aldo Moro, Bari, Italy

**Aim:** experimental study on the role of Pmma and their effect in antimicrobial efficacy by adding titanium and silver nanoparticles.

**Methods:** 16 samples of Pmma have been added with Nps of SiO<sub>2</sub>, TiO<sub>2</sub>, and Ag. 3 samples have been isolated, and roughness has been studied with an atomic force microscope. A microbiological test of the *Candida albicans* colonization was made too. Samples were fitted in cultural fields at 37°C and evaluated at T0, after 24 hours and 48 hours. They have been fixed with immersion in methyl alcohol, after metallization they have been studied with SEM for quantitative analysis of *Candida Albicans* presence.

**Results:** samples with NPS of TiO<sub>2</sub> and silver ions had a roughness of 32.78nm compared to 126nm of the control sample. From a microbiological point of view, made with an SEM study, samples had reduced colonization of *Candida Albicans* than the control sample, considering also the time factor.

**Conclusion:** from the experimental data gathered we can say that Pmma with NPS of TiO<sub>2</sub> and Ag had a clear improvement in physical-mechanical characteristics, also a reduction of the colonization from *Candida Albicans* has been observed.

## EFFECTS ON THE FRACTURE RESISTANCE OF OCCLUSAL VENEERS WITH DIFFERENT MATERIALS

Camurri Piloni A., Marchesi G., Barazzuol M., Di Lenarda R., Turco G., Angerame D.

Department of Medical Sciences, University of Trieste, Trieste, Italy

**Aim:** consequentially to the development of CAD/CAM restorative dental materials, limited data regarding their survival rate and fracture strength is available when they are used as occlusal veneers. The aim of this study is to evaluate the influence of thermomechanical loading on fracture strength of minimally invasive occlusal veneer restorations fabricated from different CAD/CAM materials and bonded to human maxillary molars.

**Methods:** twenty extracted maxillary molars were assigned to two groups ( $n = 10$ ). LS (zirconia-reinforced lithium silicate) (Celtra Duo, Dentsply Sirona), and PI (polymer-infiltrated ceramic) (Enamic, Vita). The teeth received a preparation for a conservative full-coverage occlusal veneer with a 1-mm cusp

reduction with a marginal chamfer. Restorations were obtained using the CEREC chair-side (CEREC MC X) and luted with a two-step self-etch adhesive system (Clearfil SE, Kuraray) and a dual resin cement (Variolink II, Ivoclar-Vivadent). After thermomechanical aging (240.000 cycles at 50 N with 5-55°C thermocycling), the specimens were loaded to fracture using a universal testing machine. The statistical analysis was made using one-way ANOVA and Tukey test.

**Results:** all specimens survived the fatigue test. PI showed a higher mean fracture load value ( $3409 \pm 694$  N) with statistically significant differences than LS ( $2352 \pm 772$  N).

**Conclusion:** PI showed the highest values of fracture resistance followed by LS favoring their use for occlusal veneers.

## MONOLITHIC ZIRCONIA CROWNS IN THE POSTERIOR AREAS: A RETROSPECTIVE STUDY

Carnevale A., Pedone S., Ciocia A., Vanzanelli A., Lagioia M., Liotino G.

Interdisciplinary Department of Medicine (D.I.M.) - Dental School, University of Bari Aldo Moro, Bari, Italy

**Aim:** a retrospective study of the condition of monolithic zirconia crowns for natural teeth in posterior areas in the short and medium term.

**Methods:** the clinical cases show the following inclusion criteria: periodontal health condition, stable occlusion, presence of an opposing occlusal surface and absence of parafunctions. For the evaluation of the prosthetic maintenance status over time, the California systematic was adopted (C.D.A).

**Results:** the study was made on 40 clinical cases with a follow up at 8 and 78 months (with an average duration of 37.8 months). The results were “Excellent” on 32 cases (80%); “Acceptable” on 7 samples (17.5%) and a single case was marked

as “Need to be redone” (2.5%). Acceptable cases share a partial compromise of a single evaluation parameter: in 1 case it was the color, in another 1 was the surface, 3 cases were compromised for anatomical factor, the last 2 cases were compromised for the marginal integration. The sample that needed to be redone had a dentinal exposure on the base and at the margin.

**Conclusion:** the experimental study shows a high trust level for monolithic zirconia crown in posterior areas for natural teeth based on the percentage of survival at both short (3 years) and medium-term (3-5 months). Therefore, monolithic zirconia looks like a valid option to the conventional bilayers.

## CHARCHOT SYNDROME: A PROSTHETIC SOLUTION FOR PALATAL LIFTING

Carossa M.<sup>1</sup>, Caliò S.<sup>1</sup>, Gassino L.<sup>2</sup>, Bassi F.<sup>1</sup>

<sup>1</sup>C.I.R Dental School, Department of Surgical Sciences, University of Turin, Turin, Italy

<sup>2</sup>University of Fernando Pessoa, Oporto, Portugal

**Aim:** SLA or Charchot syndrome induces progressive and increasing sclerosis of the anterior horn and the pyramidal bundle of motor neurons of the spinal cord with possible bulbar involvement at the level of the nucleus of the cranial nerves. Bulbar lesion induces the classic labial-gloss-laryngeal paralysis involving a nasal voice, atrophied tongue and palate paralysis that causes severe swallowing problems. It is a pathology of unknown etiology that often arises between 45 and 60 years and in a few years leads to death from damage to swallowing and breathing. The prosthetic treatment must satisfy two needs: simplicity and abutment teeth with adequate retentions. The aim of the present case report is to describe a prosthetic solution for palatal lifting in a patient with Charchot syndrome.

**Methods:** patient underwent all the necessary dental treatment. 1.4 was extracted and 1.5 was rehabilitated with a fixed full crown. Then, all the residual elements were prepared in order to create sufficient retentions for a removable partial prosthesis. This prosthesis was modified by adding a posterior support to lift the palatal. After the manufacturing process, the prosthesis was delivered and the patient was then rehabilitated with a removable partial prosthesis with palatal lift.

**Results:** after an initial phase of adaptation, the patient reported an improvement in the oral cavity functions that were previously impaired.

**Conclusion:** lifting the palate with the prosthesis improved the patient's swallowing and phonetic function.

## SUBJECTIVE AND OBJECTIVE EVALUATION OF PROsthESIS AFTER PREPROSTHETIC SURGERY

Ciocia A.<sup>1</sup>, Barile G.<sup>2</sup>, Carnevale A.<sup>1</sup>, Pedone S.<sup>1</sup>, Vanzanelli A.<sup>1</sup>, De Luca A.<sup>1</sup>

<sup>1</sup>Interdisciplinary Department of Medicine (D.I.M.) - Dental School, University of Bari Aldo Moro, Bari, Italy

<sup>2</sup>Specialization School of Oral Surgery, Interdisciplinary Department of Medicine (D.I.M.) - Dental School, University of Bari Aldo Moro, Bari, Italy

**Aim:** preprosthetic surgery includes a series of interventions aimed at restoring or creating, in totally or partially edentulous patients, correct local anatomy that offers adequate support from hard and soft tissues of the jaws to the prosthetic manufacture. Through a subjective and objective scoring of prosthetic manufacture, this study can demonstrate the efficacy of preprosthetic surgery, where needed.

**Methods:** according to declaration of Helsinki were included patients with total or partial edentulous that present hard or soft tissue defects, from 03/18 to 01/19, with 1 year follow up. First visit was executed and initial subjective score of the previous prosthesis was conducted then surgery was performed to correct following defects: fibrous hyperplasia, tori and exostosis and tuber hyperplasia. In follow up visits, authors collect patient scoring 0 to 10 points: first score was referred to subjective evaluation, asking a questionnaire, then second score

was referred to objective evaluation of retention and stability with the Kapur system.

**Results:** 18 patients were recruited into the study, considering 12 of them which completed follow-up visits. 7 patients were treated for fibrous hyperplasia, 3 for tori and exostosis and 2 for tuber hyperplasia. Regarding the subjective evaluation, averages scoring was 8.3/10 for the removable partial prosthesis and 7.9/10 for the total prosthesis was registered, far from respectively 4.2/10 and 3.7/10 evaluation of previous prosthesis, before surgery.

Regarding objective evaluation: mean retention was 2.3/3 points and mean stability was 1.7/2 points for the removable partial prosthesis and respectively 2.1/3 and 1.4/2 for total prosthesis.

**Conclusion:** this study has shown that preprosthetic surgery is a predictable technique to obtain a correct prosthetic rehabilitation that is functional and well accepted by the patient.

## DIFFERENT BUILD UP PROCEDURES OF ENDODONTICALLY TREATED POSTERIOR TEETH

Ferrari Cagidiaco E., Corsentino G., Grandini S., Ferrari M.

Department of Prosthodontic and Dental Materials, University of Siena, Siena, Italy

**Aim:** the aim was to investigate the clinical behavior of endodontically treated (ET) posterior teeth (premolars and molars) restored by various fiber-reinforced post-core composites (FRCs) or fiber posts (FP).

**Methods:** 120 ET posteriors, with 50% or less of coronal residual structure were selected and randomly divided into four groups (n = 30). Group 1: FP GC FIBER POST, GC (FP) luted with GRADIA CORE, GC (GC) + Initial LiSi Press, GC partial crown luted with G-CEM LinkForce, GC (LF) (as control); Group 2: everX Flow, GC (EXF) core build up + Initial LiSi Press partial crown luted with LF; Group 3: EXF + G-ænial Universal Injectable, GC (GUI); Group 4: FP + EXF + GUI. Natural teeth were as opposing dentition and patients were free from parafunctions. Patients were recalled at six months and 1 year from baseline. Mechanical and biological parameters were evaluated accordingly with Functional Index of Teeth (Ferrari Cagidiaco et al.,

2020). FIT was used for the objective assessment of outcomes including clinical and radiographic examinations. FIT is made up of 7 variables (Interproximal, Occlusion, Design, Mucosa, Bone, Biology and Margins), each of them to be evaluated using a 0-1-2 score. The Mann-Whitney U test was applied for statistical analysis and the level of significance was set at  $p < 0.05$ .

**Results:** at one year recall all the restorations were in place without any biological or mechanical complication. FIT scores for each restoration ranged between 13.4 and 14. No statistically significant differences were found among groups.

**Conclusion:** under the limitations of this study, posterior ET showed no difference when restored with or without a fiber post, and when occlusal surface was covered by an adhesive partial crown or not. Longer observation time of this study is needed to confirm these findings. Similar studies on patients with different degree of parafunctions are desirable.

## IMPLANT-PROSTHETIC AESTHETIC REHABILITATION: DIGITAL PROJECT AND FUNCTIONAL EVALUATION

Ferri S., Faben A., Robbiano F., Broggi R., Cattoni F.

Department of Dentistry, IRCCS San Raffaele Hospital, Milan, Italy; Dental School, Vita – Salute San Raffaele University, Milan, Italy

**Aim:** the aim of this study is to evaluate the occlusal and myoelectric characteristics of a prosthetic rehabilitation.

**Methods:** a 52-year-old healthy female patient was referred to our Dentistry Department (IRCCS San Raffaele Hospital – Milan). She presented dental blemishes at the level of the frontal group, a reduced vertical dimension and imperfection of the lips. After clinical and radiological evaluation, a prosthetic treatment plan was proposed through digital smile design protocol Smile LYNX (Smile Lynx, 3D LYNX srl, Varese). A double full arch Mock-Up was realized with CAD-CAM technology supported by digital drawing Software CAD-LINX. The CAD Software is able to match automatically the information defined in 2D project. Occlusal-aesthetic Mock-Up test and EMG pre-post treatment were performed. Then the extraction of elements 14-15-16 and integration of post-extraction implants were carried out. The provisional step was performed

and afterwards that the double cord impression technique taken. A PEEK manufact was tested in the oral cavity and the definitive double zirconia arches were produced. The final EMG test was done. The patient was added into a maintenance program.

**Results:** at time T0 the patient presents in the electromyography an initial occlusal and muscular balance of 82%. At time T1 post provisional prosthetic rehabilitation the patient presents a good occlusal and muscular balance with a 90% increase. At time T2 post definitive prosthetic rehabilitation the patient presents a good maintenance equal to 90% as at time T1.

**Conclusion:** the digitization of the diagnostic phase and the computerized EMG control of muscle activity, can help the clinician improve the patient's understanding of the rehabilitation project, to maintain the initial design during the work phases, respecting the function and aesthetics of the patient.

## CONSERVATIVE AESTHETIC SMILE AMELIORATION USING LITHIUM DISILICATE VENEERS

Florenzano F.<sup>1</sup>, Del Bianco F.<sup>1</sup>, Mancuso E.<sup>1</sup>, Josic U.<sup>1</sup>, Maravic T.<sup>1</sup>, Comba A.<sup>2</sup>, Mazzitelli C.<sup>1</sup>, Breschi L.<sup>1</sup>, Mazzoni A.<sup>1</sup>

<sup>1</sup>DIBINEM, University of Bologna – Alma Mater Studiorum, Bologna, Italy

<sup>2</sup>Department of Surgical Sciences, Dental school, Cariology and Operative Dentistry University of Turin, Turin, Italy

**Aim:** the conservative restoration of the maxillary anterior teeth is presented.

**Methods:** a 50-yr old woman referred to the clinic complaining dissatisfaction of her smile. Medical history was negative. Infiltrated resin composite restorations (1.1, 1.4, 1.5, 2.4) and a dyschromic devitalized upper left central incisor were clinically and radiographically observed. Wear of 1.1 and 2.1 was also observed. Treatment plan consisted of lithium disilicate veneers (1.3 – 2.3) and veneerlays (1.4, 1.5, 2.4) restorations. Data were recorded (intra- and extra-oral photos, radiographs, impressions) and a mock-up (1.5 – 2.4) was prescribed to the dental technician. After caries removal, build-ups (Optibond FL, Kerr + Gaenial, GC) were performed on 1.5 and 2.4. Teeth from 1.3 to 2.3 were minimally prepared to receive veneers. Af-

ter 10 days, definitive luting procedures of all lithium disilicate monolithic restorations (Emax press, Ivoclar Vivadent) were performed under rubber dam isolation with a 3-steps etch-and-rinse adhesive (Optibond FL) and a dual-cure resin cement (Variolink DC, Ivoclar Vivadent). Occlusal adjustments were performed where necessary. A night-guard was delivered to the patient.

**Results:** controls were systematically scheduled. After 2 yr, no chipping, debondings, discolorations or fractures were observed. The patient showed satisfaction with the aesthetic results achieved and no discomfort or pain were reported.

**Conclusion:** the evolution of ceramic materials and adhesive systems allow for conservative enhancement of the smile's aesthetic and reinforce the patient's self-esteem.

## BALTIC DENTURE SYSTEM

Malcangi G.<sup>1</sup>, Patano A.<sup>1</sup>, Hazballa D.<sup>1</sup>, Laudadio C.<sup>1</sup>, Colocchia G.<sup>1</sup>, Marinelli G.<sup>1</sup>, Limongelli L.<sup>1</sup>, Inchingolo A.D.<sup>1</sup>, Montenegro V.<sup>1</sup>, De Vanna F.<sup>4</sup>, D'Oria M.T.<sup>1</sup>, Corsalini M.<sup>2</sup>, Dipalma G.<sup>1</sup>, Inchingolo F.<sup>1</sup>, Di Venere D.<sup>1</sup>, Ciocia A.M.<sup>2</sup>, Pedone S.<sup>2</sup>, Farronato M.<sup>3</sup>, Tartaglia G.<sup>3</sup>

Complex Operative Unit of Odontostomatology, Director: Prof. G. Favia

<sup>1</sup>Specialization School in Orthognatodontics Director: Prof. F. Inchingolo, Interdisciplinary Department of Medicine D.I.M., University of Bari Aldo Moro, Bari, Italy

<sup>2</sup>Specialization School in Pediatric Dentistry, Director: Prof. M. Corsalini, Interdisciplinary Department of Medicine D.I.M., University of Bari Aldo Moro, Bari, Italy

<sup>3</sup>Department of Biomedical, Surgical and Dental Sciences, School of Dentistry, University of Milan. UOC Maxillo-Facial Surgery and Dentistry, Fondazione IRCCS Ca' Granda, Ospedale Maggiore Policlinico, Milan, Italy

<sup>4</sup>Private Practice, Ruvo di Puglia, Bari, Italy

**Aim:** Baltic Denture System (BDS) is a technique which allows to produce mobile full dentures through the digital system CAD/CAM by combining the clinical and laboratory phases in a whole workflow.

**Methods:** clinical phase: impression is taken with the *KEY SET*, registration of the vertical dimension and bite, key data transfer to the digital system of laboratory. Laboratory phase: acquisition of data, project, elaboration of computerized numerical control (CNC) and finalization. The data of alveolar crest of maxilla is 3D scanned in laboratory. This data is reported for the CAD project of dentures with the software *CAD Creator PLUS*. Thanks to the *KEY Set* used by the clinician, the relation of the dental arches clinically registered is perfectly re-

ported in the software. Once data is transferred to the CAM software, the milling CNC process for the Load working (raw workpiece of milling) can start.

**Results:** the milling and finalization of dentures occur in less steps than the traditional dental processes.

During the delivery, the dental works require a minimal regulation at the chair, show an excellent adaption and stability to the edentulous ridges.

**Conclusion:** this kind of work allows us to be more competitive by offering an excellent quality in both functional and aesthetic results, while reducing clinical and laboratory work.

As the number of session decrease, risks of exposure to infections, as the COVID-19 are reduced too.

## COMPARISON OF THE PINK ESTHETIC SCORE BETWEEN THE DIGITAL AND ANALOGICAL WORKFLOW

Massaglia M.M., Bellantoni G., Franceschi L., Gonnella A., Ruscica C., Ferrini F.

Department of Dentistry, IRCCS San Raffaele Hospital, Milan, Italy; Dental School, Vita – Salute San Raffaele University, Milan, Italy

**Aim:** 50 patients were evaluated and recruited at the Department of Dentistry of the IRCCS San Raffaele Hospital in Milan from March 2017 to May 2018. The purpose of this clinical study was to evaluate the Pink Esthetic Score (PES) in single rehabilitations in the aesthetic area, using the digital workflow in a test group (GT) and the analogical ones in a control group (GC).

**Methods:** after implant placement, randomly 25 patients (GT) were assigned to the immediate loading protocol using digital flow and 25 patients (GC) with analogical one. The esthetic result was evaluated using the PES after 1 year follow-up. The PES parameters evaluated are the presence/absence of the interproximal papilla, the scallop of the gingival margin in correspondence with the implant, the position of marginal tissue, color and the appearance of peri-implant tissue.

**Results:** in GT the presence of the mesial and distal papillae obtained an average score of  $1.48 \pm 0.49$  and of  $1.22 \pm 0.41$ ;

the scallop and the position of the soft tissue margin in relation to the prosthetic restoration margin achieved a score of  $1.83 \pm 0.32$  for both parameters; the soft tissue color was  $1.21 \pm 0.49$ . In the GC the presence of the mesial and distal papillae obtained an average score of  $1.68 \pm 0.43$  and at  $1.35 \pm 0.47$ ; the scallop of soft tissue margin achieved a score of  $1.71 \pm 0.40$ ; the position of the soft tissue margin in relation to the prosthetic restoration margin achieved an average score of  $1.52 \pm 0.46$ ; the soft tissue color was  $1.04 \pm 0.57$ . The overall PES equal of  $7.72 \pm 0.8$  for the GT and  $7.35 \pm 0.75$  for the GC.

**Conclusion:** within the limits of this study, there statistically were no significant differences between the GT and the GC in the mean values of PES.

This demonstrates that the immediate protocol using digital flow does not compromise the aesthetic result of the implant-prosthetic rehabilitation.

## BONE LOSS IN OSTEOINTEGRATED DENTAL IMPLANTS DUE TO OCCLUSAL OVERLOAD: A SYSTEMATIC REVIEW

Montagner M., Di Fiore A., Granata S., Sambugaro M., Litta G., Stellini E.

Department of Neurosciences, School of Dentistry, University of Padua, Padua, Italy

**Aim:** implant therapy represents the first way to rehabilitate both complete and partial edentulous patient. Osseointegrated implant failure can occur due to a bacterial infection (peri-implantitis) and/or a chronic traumatic event. Therefore, the aim of this review is to assess the possible interaction between overload and periimplantitis.

**Methods:** PubMed database was searched for articles published up to December 2020. The search strategy applied was: implants AND (overload OR excessive load OR occlusal wear) AND (bone loss OR periimplantitis OR failure). Reference lists of any potential study were examined to find other papers related to the focus. Exclusion criteria were *in vitro* researches, reviews and guidelines articles.

**Results:** 16 clinical studies and 14 animal studies were included in this review. The only randomized controlled trial did not report a positive correlation between bone loss and overload. 11 clinical studies showed high bone loss in presence of occlusal wear, long cantilever or bruxism habits without plaque-accumulation. 6 animal studies found a positive correlation, especially when the applied force has lateral direction.

**Conclusion:** the problem remains uncertain. Increased mechanical load may have a positive effect on the implant surrounding the bone below a certain limit. However, overload results in bone resorption beyond this limit, which seems to be individual and depends on bone quality. Further clinical studies including T-Scan to perform occlusal analysis are required to confirm the correlation.

## POST-ONCOLOGICAL REHABILITATION OF THE MAXILLO-FACIAL DISTRICT USING A PROSTHETIC DEVICE

Palumbo L., Sertori F., Palmacci M., Pensa V., Panerai F., Gastaldi G.

Department of Dentistry, IRCCS San Raffaele Hospital, Milan, Italy; Dental School, Vita-Salute San Raffaele University, Milan, Italy

**Aim:** for massive defects that include multiple facial subunits, as a consequence of resective cancer surgery, the elective treatment still remains the surgical reconstruction with free flaps, because it is very difficult to recover these defects by the grafting techniques using autogenous tissue.

The aim of this work is to present a complex clinical case concerning the post-oncological prosthetic rehabilitation of the nasal and maxillary.

**Methods:** a 52-year-old woman comes to our observation at the Department of Dentistry and Dental Prosthetics of San Rocco Hospital Clinic, Ome (BS), with a maxillofacial defect involving the nasal pyramid and part of the maxillary bone with an extensive oro-nasal communication, result of resective oncological surgery for epidermoid carcinoma infiltrating the tip of the nose, involving in addition to the nasal cavities, pre-maxilla and labial filter. It was decided for a rehabilitation with tradi-

tional facial epitheses anchored to the obturator prosthesis, already in the patient's possession.

An acrylic resin extension is made on the palatal obturator that allows the attachment of the nasal epitheses via a knight hook. This system allowed the easy removal of the prosthesis, a better hygiene and the prosthetic device by the patient.

**Results:** one year after rehabilitation, the epithesis is well tolerated. From an oncological view, there is no recurrence of the disease. Rehabilitation is useful to give a better aesthetic appearance to patient and assuring greater self-confidence.

**Conclusion:** the clinical use of facial epitheses is based on the cooperation between the surgeon and the prosthetist. With the limitations of this study, maxillofacial epitheses are an excellent solution to significantly increase the quality of life of patients who have undergone resective cancer surgery, improving their aesthetic appearance and social interactions.

## IN VITRO STUDY TO COMPARE ROUGHNESS OF DIFFERENT RESINS USING FOR REMOVABLE PROSTHESES

Pedone S., Carnevale A., Ciocia A., Albanese G., Vanzanelli A., Minenna S.

Interdisciplinary Department of Medicine (D.I.M.), Dental School, University of Bari Aldo Moro, Italy

**Aim:** to evaluate and compare the roughness of different resins using for removable prostheses. Identify the material that has the lowest degree of roughness, and that guarantees the least engraftment of microorganisms.

**Methods:** four types of resins were used: heat-curing acrylic, self-curing acrylic, polyamide and CAD/ CAM resin. Five specimens of specific sizes were obtained for each type of resin, subsequently they were finished and polished. Finally, the average roughness of the samples was measured with a roughness tester (Surtronic 25).

**Results:** the results obtained were: polyamide 1.13 micrometers, Baltic CAD / CAM resin 0.25 micrometers, self-cured Ivoclar Cold 0.48 micrometers, Ivoclar Hot thermopolymerizable 0.34 micrometers.

**Conclusion:** industrial resins, compared to those made with analog procedures, have a lower degree of roughness because in the different work phases there are fewer operator-dependent errors. This allows for less engraftment of microorganisms.

## CONFOCAL LASER MICROSCOPE EVALUATION OF PEEK ABUTMENTS ROUGHNESS

Lo Giudice R.<sup>1</sup>, Pinizzotto M.<sup>2</sup>, Tribst J.P.M.<sup>3</sup>, Famà F.<sup>1</sup>, Rizzo D.<sup>3</sup>, Puleio F.<sup>4</sup>

<sup>1</sup>Department of Human Pathology in Adulthood and Childhood G. Barresi, University Hospital G. Martino of Messina, Messina, Italy

<sup>2</sup>Student School of Dentistry, University of Messina, Messina, Italy

<sup>3</sup>Postgraduate Program, School of Dentistry, University of Taubaté, Taubaté, São Paulo, Brazil

<sup>4</sup>Dental practitioner, Messina, Italy

**Aim:** the relationship between implant abutments and soft tissues constitutes a protective barrier to separate peri-implant bone from the oral environment. Customized prosthetic abutments could be realized with several materials: metals, ceramics, hybrid materials and composites.

Among composite materials, the High Performance Polymer, based on a polyether-ether-ketone (PEEK) polymer, was introduced as an innovative alternative to titanium. Many studies highlighted a decrease in the risk of marginal bone loss and soft tissue recession in PEEK abutments compared to those in titanium.

The aim of this study was to evaluate the surface characteristics of PEEK abutments for CAD/CAM milling.

**Methods:** measurements of roughness were made in three areas of PEEK abutments (2.7 mm height, 3.22 diameter) (Bredent, Senden, Germany), using the Confocal Laser Microscope. The two parameters considered: Ra (absolute distanc-

es of roughness profile from the center line) and Rz (maximum peak-to-valley of five consecutive sampling lengths) were measured in vertical and horizontal axis. A DICe software was used to present confocal measurement data as a differential interference contrast image.

**Results:** in horizontal axis the values of Ra and Rz were:  $0,082\mu\text{m} \pm 0,017\mu\text{m}$  and  $0,503\mu\text{m} \pm 0,113\mu\text{m}$ . In the vertical axis, the measurements Ra and Rz were:  $0,361\mu\text{m} \pm 0,241\mu\text{m}$  and  $0,788\mu\text{m} \pm 0,233\mu\text{m}$ . The Ra and Rz means were:  $0,116\mu\text{m} \pm 0,06\mu\text{m}$  and  $0,661\mu\text{m} \pm 0,274\mu\text{m}$ . The 3D profiles presented good smoothness surface characteristics.

**Conclusion:** the roughness profile showed to be appropriate for realization of prosthetic abutments because of its capacity to enhance fibroblast cells adhesion and growth. Moreover, the analysis of literature highlighted the characteristics of biocompatibility and excellent chemical and color stability of this material.

## PRADER-WILLI SYNDROME: ORAL FINDINGS

Prota G., Pietrantonio M., Epifania E.

Dipartimento di Neuroscienze, Scienze Riproduttive e Odontostomatologiche 17

**Aim:** Prader-Willi syndrome is a rare multisystemic genetic disorder caused by lack of expression of certain paternal genes located on chromosome 15.

The syndrome, associated to hypothalamic and pituitary dysfunction, is characterized by severe neonatal hypotonia and feeding problems. Neonatal hypotonia is followed, during childhood by hyperphagia and obesity. In addition, hypothalamic alterations can cause intellectual disability, behavioral problems, a high pain threshold, respiratory sleep disorders. The aim of this work is to evaluate the main dental aspects and the therapeutic implications.

**Methods:** an analysis of the literature was performed using databases.

**Results:** common clinical findings: gingivitis and periodontitis, dental and skeletal malocclusions, enamel hypoplasia, tooth wear and dental erosion, bruxism, xerostomia, candidiasis and angular cheilitis, high risk of caries and increased DMFT score. The typical poor oral hygiene in PWS patients is related to qualitative-quantitative changes in saliva and incoordination in tooth brushing.

**Conclusion:** it is necessary to motivate family and patient to maintain oral hygiene. Due to the various systemic and dental problems, a six-monthly follow-up is required since early childhood. Dental treatment purposes require a multidisciplinary approach which includes periodontal and conservative cares. In prosthetics, we suggest the use of removable dentures because of the difficulty in maintaining oral hygiene.

## A MICROSCOPICAL STUDY OF DENTIN EXPOSURE AFTER PREPARATION FOR PORCELAIN LAMINATE VENEERS

Ruggiero G., Sorrentino R., Zarone F.

Department of Neurosciences, Reproductive and Odontostomatological Sciences, Division of Prosthodontics and Digital Dentistry, University of Naples Federico II, Naples, Italy

**Aim:** the purpose of the present study was to assess the quantity of dentin exposure detected by 3 operators for 2 different geometries of tooth preparations, window (WI) and butt joint (BJ).

**Methods:** twenty intact maxillary central incisors were collected. One prosthodontist prepared the specimens for porcelain laminate veneers to a depth of 0.6 mm, with a cervical chamfer-line of 0.3 mm, using a silicone index. Subsequently, each prepared tooth was analyzed by 3 operators with different clinical experience, undergraduate student (ST), general practitioner (GP), and prosthodontist (PR), to calculate the percentage and area (in mm<sup>2</sup>) of exposed dentin at sight under magnification. In addition to descriptive statistics (CI 95%), a 2-way ANOVA and the Games-Howell test were used to analyze differences among groups ( $\alpha = .05$ ).

**Results:** the means of dentin exposure were: WI =30.48%, 21.57 mm<sup>2</sup>; BJ = 30.99%, 21.97 mm<sup>2</sup>; ST/WI = 22.82%, 16.44 mm<sup>2</sup>; GP/WI = 58.05%, 40.64 mm<sup>2</sup>; PR/WI = 10.55%, 7.63 mm<sup>2</sup>; ST/BJ = 28.99%, 20.83 mm<sup>2</sup>; GP/BJ = 40.56%, 28.32 mm<sup>2</sup>; PR/BJ = 23.42%, 16.75 mm<sup>2</sup>.

The 2-way ANOVA detected significant differences among operators ( $p < .001$ ) but not between WI and BJ ( $p = .898$ ). The Games-Howell test detected differences between ST/WI and GP/WI ( $p = .005$ ) and between GP/WI and PR/WI ( $p < .001$ ).

**Conclusion:** there is no difference in the detection of exposed dentin among operators with different expertise for BJ preparation, whereas differences were detected between GP and the other 2 operators in the WI scenario. Moreover, the quantity of exposed dentin is not related to different tooth preparation geometry.

## ASSESSMENT OF MECHANICAL PROPERTIES OF CAD/CAM MATERIALS: A SYSTEMATIC REVIEW

Sambugaro M., Di Fiore A., Granata S., Montagner M., Litta G., Stellini E.

Department of Neurosciences, School of Dentistry, University of Padua, Padua, Italy

**Aim:** the aim of this review is to examine and compare the mechanical properties of the most used Cad/Cam materials worked with subtractive (SM) and additive process (AM).

**Methods:** a search of literature was conducted with MEDLINE database (via PubMed) combined the key words: "Digital dentistry"; "Ceramic"; "Zirconia"; "Composite resin"; "Additive manufacturing"; "Dental Materials", and "Cad/Cam Dentistry" from January 2016 to January 2021. The search was supplemented by hand-searching (checking references of the relevant review articles and eligible studies for additional useful publications). No investigations were conducted regarding the different alloys used in 3D-printing by using selective laser melting (SLA).

**Results:** a total of 9 articles were identified in the electronic and manual search during initial screening. After a full text evaluation only 4 articles were included according to the inclusion and exclusion criteria. Actually, all articles demonstrated the better mechanical properties and surface characteristics of the milled materials than the 3D-printed materials.

**Conclusion:** additive manufacturing has demonstrated promising experimental outcomes. Therefore, the 3D-print allow to realize a more sophisticated structure than milling machine, also mitigates raw material wastage and tooling stresses of the burs. Few articles are published in literature regarding these field, however, new investigation must be conducted to know the performance of this technology in the prosthetic manufacturing.

## OVERDENTURE'S ATTACHMENT WEAR: COMPARISON BETWEEN TWO LOW-PROFILE RETENTIVE SYSTEMS

Sassi A. N., Olivieri G., Todaro C., Vigorelli P., Lupi S. M.

Department of Clinical Surgical, Diagnostic and Pediatric Sciences, University of Pavia, Pavia, Italy

**Aim:** implant supported overdentures are considered a valid treatment option when a simplified treatment is needed and economy is an important factor. Two mandibular implants are usually considered the minimum standard of care. The aim of this study is to evaluate the attachment wearing of two low-profile retentive systems after *in vitro* simulation of mastication.

**Methods:** two edentulous mandibular models, made of epoxy resin, were prepared and covered with a synthetic gum. Two implants were placed in each one of them, positioned at the canine level. Further, two complete prothesis were considered. In model A, the OT Equator® retention system was used, with a diameter of 3.3mm and height of 2mm. In model B, the Zest

Anchors Locator® system was used instead, with same dimensions. A number of cycles equivalent to three years of use were simulated. The masticatory force was assumed to be equal to 250 N force. A realistic humid environment, at a constant temperature of 37°, was used.

**Results:** both systems tested showed gradual alteration of the surfaces, with a different wear pattern.

**Conclusion:** the obtained results provide a valuable database to be used in further research efforts aiming at the continuous improvements of the retentions systems' stability. Finally, the outcome of this research path will improve today's technologies, identifying best practices and providing the practitioner with important data for optimal patient's health.

## DIGITAL DISTANCE TUTORING ON DENTAL STUDENTS VIA SMART GLASSES DURING COVID-19 PANDEMIC

Scazzero N., Dalessandri D., Massetti F., Tonni I., Bonetti S., Visconti L., Paganelli C.

School of Dentistry, Department of Medical and Surgical Specialties, Radiological Sciences, and Public Health, University of Brescia, Brescia, Italy

**Aim:** the effect of Covid-19 pandemic has a certain influence on everyday life and dental professionals (teachers and students) are one part of the healthcare workers that face the major risk of contracting the disease. Specifically, because in traditional dental education a close contact between tutors and students is required for an effective learning process, several measures were imposed to limit the spread of the virus. For these reasons, faculties are called to find new methods to keep on the learning process but away from the risk of infection. The aim of our study was to evaluate the feasibility of digital distance tutoring delivered through smart glasses and to compare this to the traditional method based on tutoring dental students chair-side during Covid-19 pandemic.

**Methods:** four dental teachers tutored twelve students in the Prosthodontics department through digital and traditional method. Students were randomly assigned to group 1 (traditional learning process with chair-side tutoring) and group 2

(real-time audiovisual communication from tutors located at a distance via Google Glass devices worn by students). Subsequently, group 1 and group 2 were crossed. All participants compared the alternative methods through a qualitative questionnaire.

**Results:** the evaluation of the data collected showed that the digital tutoring method was feasible and widely accepted by the students, while tutors reported that tutoring remotely had almost the same effectiveness as chair-side. Overall usefulness of smart glasses for dental tutoring was rated as very high by 52% and high by 34% of students.

**Conclusion:** in this study, dental students were able to perform traineeship activities through tele-mentored education using smart glasses. Preliminary data suggest the use of these devices as an alternative, effective and realistic method to avoid the overcrowding of dental departments during Covid-19 pandemic.

## FULL-ARCH IMPLANT-SUPPORTED HYBRID PROsthESIS IN MONOLITHIC ZIRCONIA AND TITANIUM

Toffoli A.<sup>1</sup>, Noè G.<sup>1</sup>, Bonfiglioli R.<sup>2</sup>, Manfredi E.<sup>1</sup>, Meglioli M.<sup>1</sup>, Macaluso G.M.<sup>1</sup>

<sup>1</sup>University Center of Dentistry, Department of Medicine and Surgery, University of Parma, Parma, Italy

<sup>2</sup>Private Practice, Bologna, Italy

**Aim:** Toronto bridges are a reliable therapeutic option to treat complete edentulism and failing dentition. We present an innovative digital protocol for implant-supported full-arch hybrid prosthesis.

**Methods:** we describe a new method to build a hybrid toronto bridge consisting of a milled implant-retained titanium bar and a monolithic zirconia bridge cemented on the bar.

Working on an adequate digital master model of the edentulous arch with inserted implants, the zirconia bridge and the implant-retained titanium bar are designed and milled through a CAD software and a milling machine.

After checking the passivity of the titanium bar on the implants and the functional and esthetic performance of the zirconia

coating, the prosthesis is finished by cementing the monolithic zirconia on the bar.

**Results:** this procedure has some important advantages. The full digital CAD-CAM manufacturing process leads to a cost reduction and allows both the technician and the clinician to shorten operating times and to simplify the procedures. Moreover, the availability of CAD-CAM files for subsequent uses allows the dental team to easily re-engineer the prosthesis in case of damage or other changing needs, simply by decementing the zirconia part from the bar through heat and cementing a new one.

**Conclusion:** the protocol represents a cost-effective solution, relatively simple to execute and open to easy subsequent re-make or changes.

## CLINICAL PERFORMANCES OF IMPLANT-SUPPORTED CEMENT-RETAINED MONOLITHIC ZIRCONIA CROWNS

Toska E., Zarone F., Ruggiero G., Sorrentino R.

Department of Neurosciences, Reproductive and Odontostomatological Sciences, Division of Prosthodontics and Digital Dentistry, University of Naples Federico II, Naples, Italy

**Aim:** the primary aim of this clinical study was to evaluate the clinical performances of CAD/CAM implant-supported monolithic zirconia single crowns cemented onto titanium implant abutments with dual-curing resin cement. The secondary aim was to assess possible biological and technical complications over time during function.

**Methods:** fifty patients in need of at least one single crown in posterior regions of both maxilla and mandible were enrolled as participants in this prospective clinical study. A 2-stage surgical technique with 1 endosseous dental implant and no additional soft/hard tissue grafts were planned for all the patients. A total of 50 crowns were fabricated using a CAD software. CAM milling was used to fabricate monolithic tetragonal zirconia single crowns. Titanium abutments were screwed onto osseointegrated implants after a healing period of 3 months, using a torque-controlled device at 35 Ncm according to manufacturer's recommendations. Monolithic ZrSCs were cement-

ed onto the abutments with a dual-curing resin cement that contains MDP monomer.

**Results:** after 4 years of clinical service, the restorations were available for the follow-up examinations. This study showed that titanium abutments demonstrated a good level of retention over time during function and no decementation was reported. MDP monomer increased the tensile bond strength between zirconia and resin-based luting agent. No technical failure like fracture behavior of monolithic ZrSCs was reported. The technical evaluation by means of the USPHS criteria revealed acceptable clinical performances of the ZrSCs on titanium abutment.

**Conclusion:** the restorative system (titanium abutments + monolithic ZrSCs) and the dual-curing resin cement tested in the present prospective clinical study showed good clinical performances and proved to be a viable clinical option to restore posterior regions.

## RETROSPECTIVE OBSERVATIONAL REVIEW ON ORAL HEALTH OF INSTITUTIONALIZED PATIENTS

Vaccaro R., Storari M., Spinas E.

Department of Surgical Science, Institute of Dentistry, University of Cagliari, Cagliari, Italy

**Aim:** in these studies has been evaluated the level of oral health and prosthetic care of institutionalized patients, living in retirement structures. Everything related to eating habits, nutritional status and chewing difficulty.

**Methods:** the first study has been conducted on 128 individuals with an average age of 78 years old (F 85%, M 15%), in 8 different structures of Cagliari province.

Questionnaires such as SPMSQ (Short Portable Mental Status Questionnaire), mental status questions, MINA (mini nutritional assessment) and general health test, have been submitted.

Last part of the investigation regards the relation between remaining teeth (or prosthesis if present) and eating ability.

The second study has been conducted on 52 individuals with an average age of 79 years old (F 73%, M 27%) in 3 different structures of Cagliari province using NAIK, ADL, SPSMQ and GOHAI index.

**Results:** the first study shows a not sufficient Oral Hygiene in the 62% of the individuals, with a chewing difficulty in 48% and a hunger loss in 17% of cases.

Patients wearing prosthesis devices are the 43% of which the 70% need to be modified and improved. Prosthesis Hygiene is inadequate for the 48% of cases.

The second study shows that Oral Hygiene is not sufficient in the 83% of the individuals. Patients wearing prosthesis devices are the 29% of which the 60% need to be modified and improved.

**Conclusion:** it is necessary a positive cooperation between all medical activities which should includes the Dentist role helped by Dental Hygienist.

Facilities staff needs to be trained and they have to consider Oral Care as an important goal to reach in order to improve Oral health and to give a better lifestyle to elder institutionalized people.

## LOAD RESISTANCE OF TABLE-TOP RESTORATIONS: CAD/CAM VERSUS HEAT-PRESSED LITHIUM DISILICATE

Angerame D.<sup>1</sup>, Zanin R.<sup>1</sup>, Marchesi G.<sup>1</sup>, Turco G.<sup>1</sup>, Bevilacqua L.<sup>1</sup>, Zarone F.<sup>2</sup>, Sorrentino R.<sup>2</sup>

<sup>1</sup>Clinical Department of Medical Science, Surgery and Health, University of Trieste, Trieste, Italy

<sup>2</sup>Department of Neurosciences, Reproductive and Odontostomatological Sciences, University of Naples Federico II, Naples, Italy

**Aim:** to assess the fracture resistance of maxillary molars restored using lithium disilicate glass-ceramic (LDG) table-top restorations fabricated with two different production protocols.

**Methods:** sixteen maxillary molars were randomly assigned to two groups (n = 8). The teeth received a preparation for a full-coverage table-top restoration with a 90° rounded shoulder margin. Restorations were fabricated using monolithic LDG blocks milled via Cerec 3 CAD/CAM System in group 1 (G1) and heat-pressed LDG in group 2 (G2). All table-tops were luted with Variolink II cement. The specimens were loaded to fracture after thermomechanical aging (1 250 000 cycles). A

qualitative analysis on the type of fracture was conducted. Collected data were statistically analyzed with non-parametric test (Mann Whitney U-test).

**Results:** the mean load to fracture was 2395.01 ± 150.96 N in G1 and 1796.58 ± 307.27 N in G2; the difference was statistically significant (p < 0.05). The majority of the specimens showed restorable fractures (6 specimens in G1 and 6 specimens in G2).

**Conclusion:** the milled CAD/CAM LDG table-top restorations withstood higher load before fracturing than the restorations made with the heat-pressed LDG production protocol.

# FORMAZIONE CONTINUA CON IL NOSTRO UNIVERSITY PROGRAM

Noi di Hu-Friedy crediamo che il mondo accademico rappresenti il futuro del settore dentale.

Ed è per questo motivo che abbiamo creato il nostro Programma Universitario, sviluppato con lo scopo di stabilire un contatto diretto tra gli studenti, le Università e la nostra azienda, semplificando l'accesso ai nostri prodotti e servizi.

L'obiettivo principale di questo programma è quello di offrire supporto a studenti e docenti, fornendo soluzioni e prodotti innovativi per accompagnarli durante tutta la loro carriera.

Il programma è rivolto a:

 **Studenti, Masterizzandi e Neolaureati**

 **Docenti e Tutor**

 **Università**

Scopri di più!

[universityprogram.hu-friedy.eu/it/](http://universityprogram.hu-friedy.eu/it/)

Seguici su Facebook: @HuFriedyUniProgramEMEA

Free Call: 00800 48374339

Hu-Friedy Mfg. Co., LLC • European Headquarters • Lyoner Str. 9 • 60528 Frankfurt am Main, Germany • HuFriedy.eu  
Tutti i nomi delle società e i prodotti sono marchi di Hu-Friedy Mfg. Co., LLC, delle sue affiliate o società collegate, se non diversamente indicato.  
©2021 Hu-Friedy Mfg. Co., LLC. Tutti i diritti riservati. HFL-5021T/0521

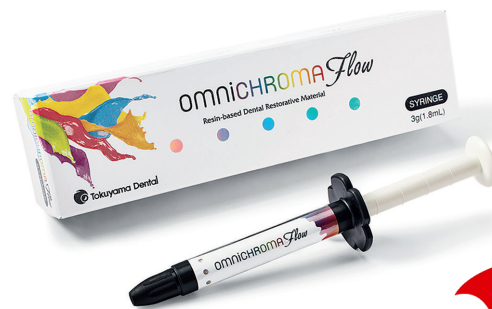

Hu-Friedy, Omnia, and Crosstex are now proud members of  **HuFriedyGroup**  
The Best In Practice

## Scopri il NUOVO OMNICHROMA Flow

Nel corso del 2019 la storia dell'odontoiatria è stata "contrassegnata" da una pietra miliare importante con **OMNICHROMA** - il primo composito universale "omni cromatico" al mondo. Nel 2021, una nuova pietra miliare è stata scritta con **OMNICHROMA Flow**, il primo composito flowable monocoloro al mondo che si adatta esteticamente alle 16 tonalità classiche della scala Vita, grazie alla **Smart Chromatic Technology**, che sfrutta il colore strutturale e la fisica del colore.

**OMNICHROMA FLOW** è adatto per un'ampia gamma di indicazioni cliniche, non solo come semplice liner di cavità o per piccoli restauri minori, grazie all'elevata percentuale di riempitivo sferico inorganico che ne esalta le proprietà fisico-meccaniche.



**COMPLIMENTI**  
Edoardo Italia  
(Università di Torino)  
**VINCITORE DEL  
POSTER DI  
CONSERVATIVA**  
[www.cduo.it](http://www.cduo.it)

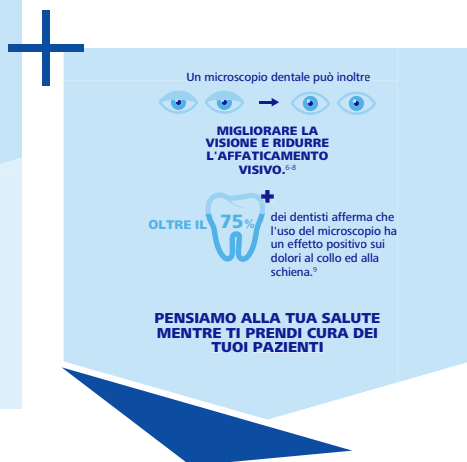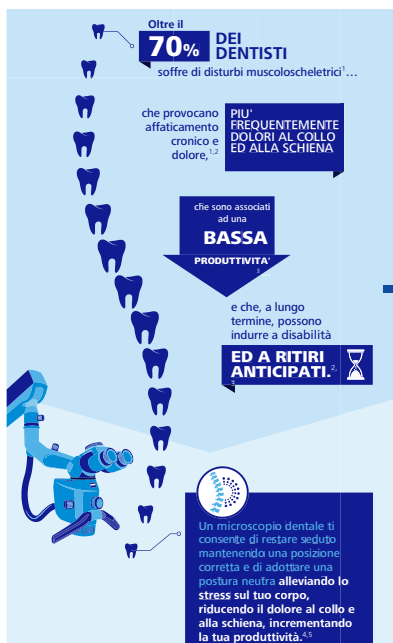
 **Tokuyama Dental**  
Innovating Tomorrow's Dentistry, Today.™

**Tokuyama  
Dental Italy srl**  
tel. +39 0444 659650  
fax +39 0444 750345  
info@tokuyama.it

**Umbra Spa**  
**Distributore esclusivo**  
tel. +39 075 5069040  
fax +39 075 5019861  
team.mkt@umbra.it

**Stay tuned!**  
Tante novità in arrivo  
nel mondo Tokuyama  
[www.tokuyama.it](http://www.tokuyama.it)





Seeing beyond

## Migliorare l'ergonomia ZEISS EXTARO 300

Uno dei maggiori vantaggi offerti dall'impiego di un microscopio operatorio, è quello di consentire all'odontoiatra il mantenimento di una postura corretta.

Operare al microscopio con una postura di lavoro adeguata, consente la salvaguardia della salute stessa dell'odontoiatra e permette di ottimizzare l'efficienza e l'efficacia delle sue prestazioni, dalle più semplici alle più complesse.



- Lavorando con una postura fisiologica adeguata, sia per il paziente, sia per gli operatori, si riducono stress ed affaticamento muscolare.

- Tutti gli accessori sono a portata di mano, consentendo un'ottimizzazione dell'ergonomia.

L'ottima visibilità del campo operatorio garantisce una visione ben definita dei particolari e

- condizioni ottimali di illuminazione.

Per informazioni: [marketing.czi@zeiss.com](mailto:marketing.czi@zeiss.com) Tel. 0293773249

### References

#### SUPERIOR ERGONOMICS:

1. Gopinath A, et al. Ergonomics and musculoskeletal disorder: as an occupational hazard in dentistry. J Contemp Dent Pract 2013;14:299-303.
2. Jodali PS, et al. Posturedentistry: How does dentistry fit you? J Pharm Bioallied Sci 2015;(Suppl 2):S393-S397.
3. Neddlermeyer W. Aus der Praxis für die Praxis. Ein besonderes Behandlungskonzept. In Zahnärztliche Mitteilungen (August 2011). Berlin.
4. Ng A, et al. Musculoskeletal disorders and working posture among dental and oral health students. Healthcare (Basel) 2016;4:13.
5. Linger W. Advantages for patients under the dental microscope. Available from: <https://www.dringer.com/blog/dental-microscope>
6. Perrin P, et al. Visual acuities of dentists in their respective clinical conditions. Clin Oral Investig 2014;19:2055-2058.
7. Eichenberger M, et al. Visual acuity of dentists under simulated clinical conditions. Clin Oral Investig 2013;17:725-729.
8. Yadav VS, et al. Periodontal microsurgery: Reaching new heights of precision. J Indian Soc Periodontol 2018;22:5-11.
9. Zaugg B et al. Influence of magnification tools on the recognition of artificial preparation and restoration defects (in German). Schweiz Monatsschr Zahnmed 2004;114:890-896.

# TAGLIO E FORMA

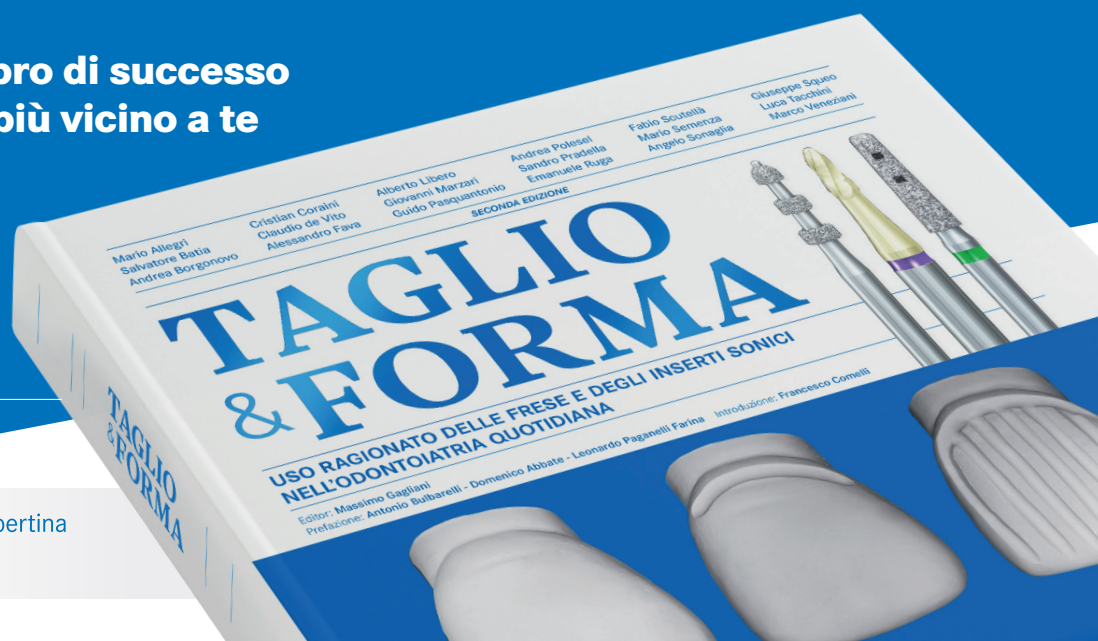Uso ragionato delle frese e degli inserti sonici nell'odontoiatria quotidiana.



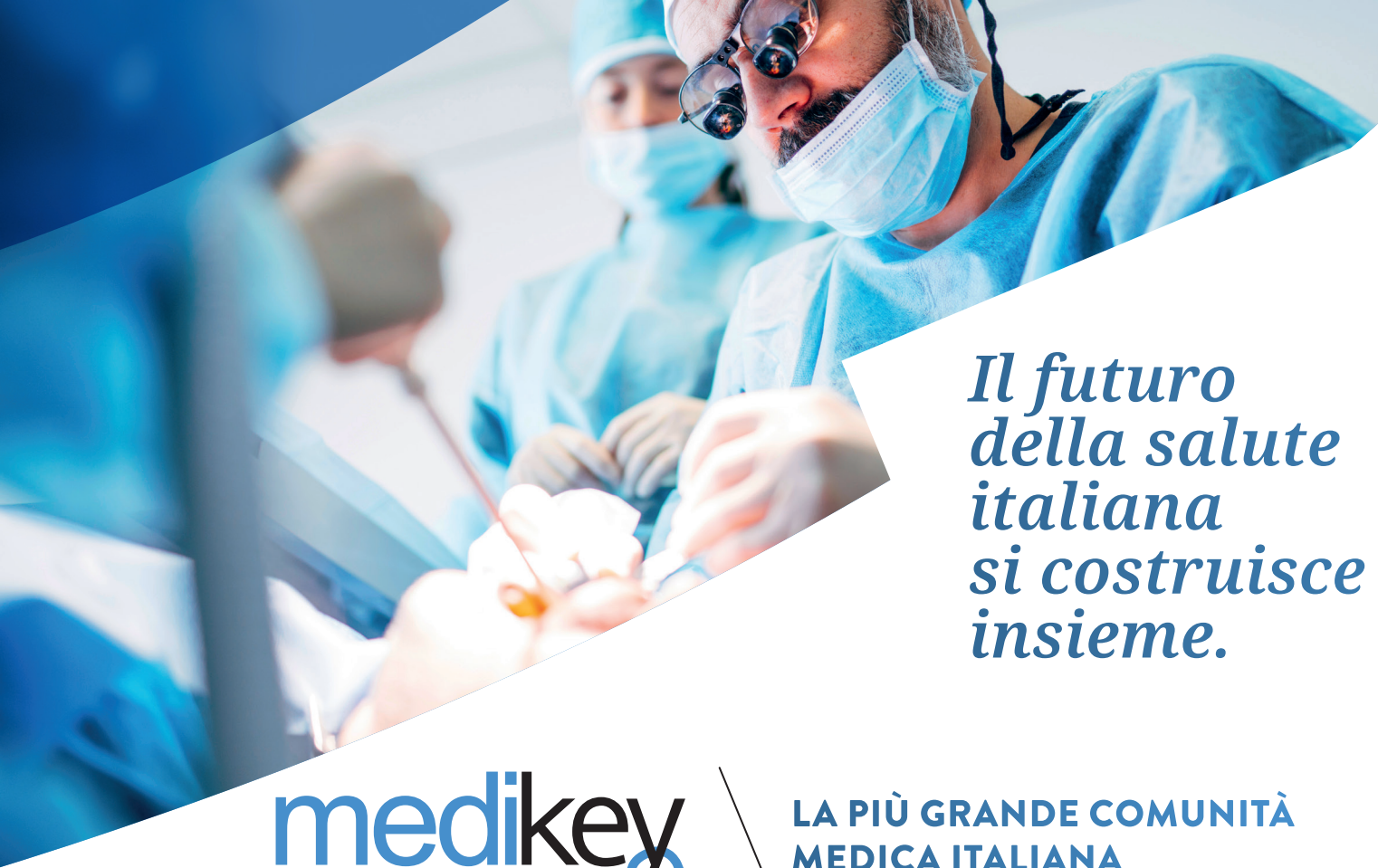Richiedi questo libro di successo al Komet Partner più vicino a te

#TaglioEForma

SECONDA EDIZIONE  
AGGIORNATA 400 PAGINE



Prezzo di copertina  
129 €

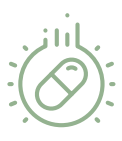

*Il futuro della salute italiana si costruisce insieme.*



**LA PIÙ GRANDE COMUNITÀ MEDICA ITALIANA**

**Essere in Medikey® significa:**



Informarti tempestivamente sulle novità farmacologiche e scientifiche grazie alle nostre newsletter quotidiane



Avere a disposizione forum, canali tematici e il prontuario Codifa attraverso il portale Doctor33



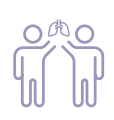Accedere gratuitamente a corsi di formazione ECM



Essere protagonista nella community de "L'Esperto risponde" di Dica33, in qualità di Esperto



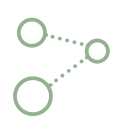Partecipare a webinar e eventi live tenuti dai più autorevoli esponenti del mondo scientifico



Avere la possibilità di scambio con altri professionisti della salute di file e messaggi e creare gruppi di discussione



Condividere percorsi di informazione scientifica remota



Disporre del network di siti web dedicati alla medicina (ad es. Odontoiatria33, Doctor33, Farmacista33.....)

*Costruisci il futuro con noi*  
**REGISTRATI SUBITO!**

**WWW.MEDIKEY.IT**



# DENTAL CADMOS

# 50

## CREDITI ECM

TUTTA L'ECCELLENZA  
CHE TI SERVE PER  
LA TUA FORMAZIONE

INDICIZZATA  
IN EMBASE,  
SCOPUS E  
WEB OF SCIENCE



**DentalCadmos** è l'**UNICA RIVISTA**  
che ti permette di ottenere  
tutti i **50 crediti ECM** necessari  
per il tuo aggiornamento professionale.  
I relatori più autorevoli e i temi  
più importanti per l'odontoiatria.

**SCOPRI I CORSI 2021 SU**  
[www.edracorsi.it](http://www.edracorsi.it)

Odontoiatria **33**

DENTAL  
CADMOS

MX  
MAXILLARIS

Dentistry **33**

CLINICAL  
TRIALS  
DENTISTRY

edra

