

Off-label use limitation of the Super Arrow-Flex® sheath introducer in congenital heart disease interventions

Original

Off-label use limitation of the Super Arrow-Flex® sheath introducer in congenital heart disease interventions / Haddad, Raymond N; Piccinelli, Enrico; Saliba, Zakhia; Fraise, Alain. - In: CARDIOLOGY IN THE YOUNG. - ISSN 1047-9511. - 32:3(2022), pp. 482-483. [10.1017/S104795112100305X]

Availability:

This version is available at: 11583/2970586 since: 2022-08-10T15:31:26Z

Publisher:

CAMBRIDGE UNIV PRESS

Published

DOI:10.1017/S104795112100305X

Terms of use:

This article is made available under terms and conditions as specified in the corresponding bibliographic description in the repository

Publisher copyright

(Article begins on next page)

Off-label use limitation of the Super Arrow-Flex[®] sheath introducer in congenital heart disease interventions

Brief Report

Cite this article: Haddad RN, Piccinelli E, Saliba Z, and Fraise A (2021). Off-label use limitation of the Super Arrow-Flex[®] sheath introducer in congenital heart disease interventions. *Cardiology in the Young*, page 1 of 2. doi: [10.1017/S104795112100305X](https://doi.org/10.1017/S104795112100305X)

Received: 19 April 2021

Revised: 30 May 2021

Accepted: 5 July 2021

Keywords:

Congenital heart disease; cardiac catheterisation; device closure; Super Arrow-Flex[®] sheath; coilwire design

Author for correspondence:

Dr. Raymond N. Haddad, MD, Department of Pediatric Cardiology, Hotel Dieu de France University Medical Center, Saint Joseph University, Alfred Naccache Boulevard, Achrafieh, Beirut, BP 166830, Lebanon. Tel: +961 70 605 800; Fax: +961 1 604 976. E-mail: raymondhaddad@live.com

Raymond N. Haddad¹ , Enrico Piccinelli², Zakhia Saliba¹  and Alain Fraise²

¹Department of Pediatric Cardiology, Hotel Dieu de France University Medical Center, Saint Joseph University, Beirut, Lebanon and ²Paediatric Cardiology Services, Royal Brompton Hospital and Harefield NHS Foundation Trust, London, UK

Abstract

Many interventionists are infatuated by the recent resurgence of the coilwire design with the Super Arrow-Flex[®] sheath (Teleflex, Inc., NC, United States of America). This exclusive sheath is a highly flexible, durable, conduit intended for use in diagnostic and interventional procedures with several advantages and maximum effectiveness in challenging cases. We report failure to easily advance memory shape occluders through Super Arrow-Flex[®] sheaths larger than the recommended implant French size. We detail the technical reasons behind this non-previously reported drawback and describe benchside tests as possible solutions.

High flexibility and the ability to pass through tortuous vessels without collapsing are the main assets of long braided sheaths.¹ They have been widely used by interventionists all around the world for more than three decades. Many interventionists are infatuated by the recent resurgence of the coilwire design with the Super Arrow-Flex[®] sheath (Teleflex, Inc., NC, United States of America). This special sheath is a highly flexible, durable, conduit intended for use in multiple diagnostic and interventional procedures with maximum effectiveness even in challenging cases. The exclusive coilwire design allows the sheath to flex at any point and in any direction without kinking or losing support. From its easy handling to its excellent steerability, the Super Arrow-Flex[®] sheath helps negotiate tortuous vascular anatomies while maintaining its internal integrity. The radiopaque tip marker enhances visualisation during insertion and enables precise positioning for optimal vascular access. The sheath is radiopaque, but the spacing between coils enables visualisation of inserted material during fluoroscopy. The sheath offers a large portfolio in terms of sheath sizes (5–11 Fr.) and lengths (7.5–100 cm) for multiple vascular applications. It even exists in specific designs for alternative carotid, crossover, and antegrade brachial access routes. The Super Arrow-Flex[®] sheath was also reported to provide the necessary access site security and durability for long-term transaxillary intra-aortic balloon pump in advanced heart failure patients requiring an extended duration of temporary circulatory support.² Despite the aforementioned advantages, we experienced an important drawback that needs to be reported to the interventional cardiologist's community: failure to advance memory shape occluders even when French size was larger than the required implant sheath. Indeed, during recent transjugular atrial septal defect closures. It was impossible to advance 19 mm and 17 mm Amplatzer septal occluders through 9 Fr and 8 Fr 24 cm-long Super Arrow-Flex[®] sheaths, respectively. These devices were advanced easily when passed through an 8 Fr/13 cm-long Performer[™] Introducer (Cook Medical, IN, United States of America) and a 7 Fr manufacturer's sheath. This technical limitation is secondary to the long transition between the larger haemostasis valve section and the smaller inner sheath lumen, where devices can easily get stuck inside. The "soft" device also attempt to reform in the proximal larger section resulting in secondary resistance to advancement. The design of the coilwire segments can also interfere with device advancement (Fig 1). This braided introducer is very flexible and tends to stretch out when the device is jammed possibly leading to a reduction of inner lumen, making the devices delivery even more complicated.

Unapproved products are used for an off-label indication only after the failure of the products with approved indication. Yet, technical difficulties in transjugular closure of atrial septal defects are well known and frequently encountered.^{1,3,4} Several techniques were described to ease the procedure including the "off-label" use of heat-shaped, pre-shaped, or steerable sheath introducers.^{1,3–6} In transjugular closures, it is certain that a shorter operation path with a shorter delivery system makes device implantation better controlled and less cumbersome. Therefore, the off-label use of intermediate-length sheaths is an ideal alternative.^{1,3,5} If unapproved sheaths are used instead of the manufacturer's recommended equipment, encountered limitations may not necessarily be related to sheath design, but rather to the problem with off-label use. Indeed, the technical specifications of the sheath's off-label use need to be fully understood and it is the

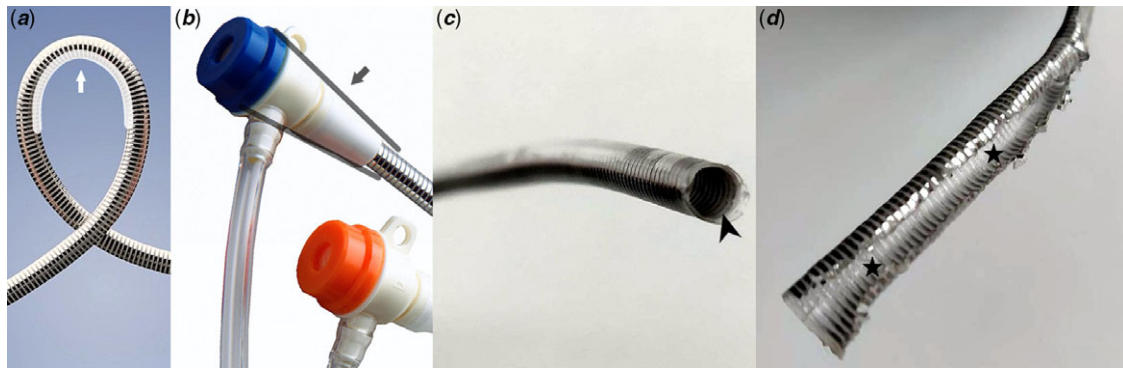


Figure 1. Super Arrow-Flex® sheath (Teleflex, Inc.). High-performance flexibility (white arrow) (a). Long linear-tapered transition from the larger tri-cusped haemostasis valve to the smaller inner sheath lumen (grey lines and arrow) (b). Irregularities of the inner lumen can be clearly seen when the sheath is opened in axial (c) (black pointed arrow) and median (d) (black stars) planes, corresponding to the integrated coils and the small hollows that interfere with the advancement of shape memory devices.

operators' responsibility to "adapt" the equipment. This limitation was easily rectified by introducing the loader deeper into the sheath during benchside tests. The loader of the Amplatzer septal occluder has a short loading segment prior to the hub and a distal locking mechanism to secure it to its sheath during device delivery. Therefore, if the device is not used with the manufacturer's sheath, and inserted with an alternate sheath, the loader should be cut proximal to the hub/locking mechanism so it can be advanced deeper within the haemostatic valve to enable smooth insertion of the device. Most importantly, our benchside tests showed that device progression or retrieval of embolised devices within Super Arrow-Flex® sheaths is feasible even though more difficult when compared to standard long sheaths.⁷ Therefore, if a Super Arrow-Flex® sheath had to be used, we recommend cutting the distal tip of the loader to introduce it deeper into the sheath, to keep the pin of the preloaded device slightly (1–2 mm) protruding outside the cut loader, and to use one French size larger than the one recommended by the manufacturer to avoid device friction on wall irregularities. Finally, it is noteworthy that our aforementioned suggested solutions were not tested in vivo.

Acknowledgements. None.

Financial support. This research received no specific grant from any funding agency, commercial, or not-for-profit sectors.

Conflicts of interest. ZS is a proctor/consultant for LifeTech and Abbott Vascular since 2017. AF is a proctor/consultant for Abbott, Occlutech, and Medtronic. The other authors have no conflict of interest to declare.

Ethical standards. The authors assert that all procedures contributing to this work comply with the ethical standards of the relevant national guidelines on human experimentation, and with the Helsinki Declaration of 1975, as revised

in 2008. The patient's legal guardians signed informed consent was obtained for the reported procedures.

Author contributions. RH collected clinical data, designed illustrative material, and took the lead in writing the entire manuscript. All authors have revised and approved the final version of the manuscript.

References

- Butera G, Chessa M, Eicken A, Thomson J. Cardiac Catheterization for Congenital Heart Disease: From Fetal Life to Adulthood. Springer-Verlag, Milan, 2015, [10.1007/978-88-470-5681-7](https://doi.org/10.1007/978-88-470-5681-7).
- Hirst CS, Davila CD, Garcia R, Kapur NK. Transaxillary intra-aortic balloon pump deployment through a novel braided sheath for advanced heart failure patients requiring an extended duration of temporary circulatory support. *Cardiovasc Revasc Med* 2020; 21: 112–115. DOI [10.1016/j.carrev.2020.01.024](https://doi.org/10.1016/j.carrev.2020.01.024).
- Rigatelli G, Zuin M, Nghia NT. Interatrial shunts: technical approaches to percutaneous closure. *Expert Rev Med Devices* 2018; 15: 707–716. DOI [10.1080/17434440.2018.1526674](https://doi.org/10.1080/17434440.2018.1526674).
- Butera G, Lovin N, Basile DP. How to deal with atrial septal defect closure from right internal jugular vein: role of venous-arterial circuit for sizing and over-the-wire device implantation. *Catheter Cardiovasc Interv* 2017; 89: 120–123. DOI [10.1002/ccd.26621](https://doi.org/10.1002/ccd.26621).
- Yarrabolu TR, Robinson A, Qureshi AM. A novel technique for percutaneous closure of an atrial septal defect in a patient with interrupted inferior vena cava using a "modified" short sheath from an internal jugular vein approach. *Ann Pediatr Cardiol* 2017; 10: 102–103. DOI [10.4103/0974-2069.197056](https://doi.org/10.4103/0974-2069.197056).
- Gao M, Li Z, Zhao Y, Wen P. Analysis of the therapeutic effect of transesophageal echocardiography-guided percutaneous device closure of atrial septal defects via the right internal jugular vein in children. *Echocardiography* 2019; 36: 1357–1363. DOI [10.1111/echo.14396](https://doi.org/10.1111/echo.14396).
- Tan CA, Levi DS, Moore JW. Embolization and transcatheter retrieval of coils and devices. *Pediatr Cardiol* 2005; 26: 267–274. DOI [10.1007/s00246-005-1009-1](https://doi.org/10.1007/s00246-005-1009-1).