

Digital Image Correlation analysis on the bone displacement during split crest: An ex vivo study

Original

Digital Image Correlation analysis on the bone displacement during split crest: An ex vivo study / Lugas, A. T.; Terzini, M.; Stacchi, C.; Lombardi, T.; Di Donato, D.; Baldi, D.; Schierano, G.; Bignardi, C.. - In: JOURNAL OF PHYSICS. CONFERENCE SERIES. - ISSN 1742-6588. - ELETTRONICO. - 2293:(2022), p. 012011. (Intervento presentato al convegno XXIX AIVELA National Meeting 2021) [10.1088/1742-6596/2293/1/012011].

Availability:

This version is available at: 11583/2970328 since: 2022-07-27T10:28:51Z

Publisher:

IOPscience

Published

DOI:10.1088/1742-6596/2293/1/012011

Terms of use:

This article is made available under terms and conditions as specified in the corresponding bibliographic description in the repository

Publisher copyright

(Article begins on next page)

PAPER • OPEN ACCESS


Digital Image Correlation analysis on the bone displacement during split crest: an *ex vivo* study

To cite this article: A T Lugas *et al* 2022 *J. Phys.: Conf. Ser.* **2293** 012011

View the [article online](#) for updates and enhancements.

You may also like

- [Biofabrication of vasculature in microphysiological models of bone](#)
Ian T Whelan, E Moeendarbary, David A Hoey *et al.*
- [NMR relaxation times of trabecular bone—reproducibility, relationships to tissue structure and effects of sample freezing](#)
Viktória Prantner, Hanna Isaksson, Johanna Närväinen *et al.*
- [Application of a 3D printed customized implant for canine cruciate ligament treatment by tibial tuberosity advancement](#)
Miguel Castilho, Marta Dias, Elke Vorndran *et al.*




The Electrochemical Society
Advancing solid state & electrochemical science & technology

242nd ECS Meeting
Oct 9 – 13, 2022 • Atlanta, GA, US
Presenting more than 2,400 technical abstracts in 50 symposia


ECS Plenary Lecture
featuring
M. Stanley Whittingham,
Binghamton University
Nobel Laureate –
2019 Nobel Prize in Chemistry

 Register now!




Digital Image Correlation analysis on the bone displacement during split crest: an *ex vivo* study

A T Lugas^{1,2,8}, M Terzini^{1,2}, C Stacchi³, T Lombardi⁴, D Di Donato⁵, D Baldi⁶, G Schierano⁷ and C Bignardi^{1,2}

¹ Polito^{BIO}Med Lab, Politecnico di Torino, Torino, Italy.

² Department of Mechanical and Aerospace Engineering, Politecnico di Torino, Torino, Italy.

³ Department of Medical, Surgical and Health Sciences, University of Trieste, Trieste, Italy.

⁴ Department of Health Sciences, University "Magna Graecia", Catanzaro, Italy.

⁵ GOM Italia S.r.l. – a ZEISS Company, Buccinasco, Italy.

⁶ Division of Implant Prosthodontics, Department of Surgical Sciences, University of Genova, Genova, Italy.

⁷ Department of Surgical Science, C.I.R. - Dental School, University of Turin, Torino, Italy.

⁸ Corresponding author, e-mail: andrea.lugas@polito.it

Abstract. The split crest is an established surgical technique for horizontal bone augmentation. It allows to place implants of adequate diameter in sites where the bone would be too thin for the implantation. In this study, two split crest techniques (using threaded bone expanders or ultrasonic bone surgery) were performed *ex vivo* on bovine ribs, and dental implants were then inserted in the so prepared implantation sites. Digital image correlation was used to measure the bone external surface displacement throughout the surgical procedures. Both techniques provided an adequate bone volume for implant insertion, and no significant differences were highlighted regarding the displacement. However, bone accidental fracture only occurred during split crest with threaded bone expanders, suggesting differences in the internal strain distribution induced by the two techniques.

1. Introduction

Implant-retained dental prostheses are a widely used treatment for edentulous patients [1–5], and dental implants of different length and diameter are indicated for different defects or conditions. However, sometimes the edentulous crest does not have sufficient bone for a correct implant insertion [6]. The edentulism is the major cause of mandibular and maxillary bone loss, but in some cases bone defects could be caused by trauma, tumor resection, or prior surgical intervention [7–12].

Since successful osteointegration is only possible when the dental implant is completely inserted into the bone [13–16], bone augmentation techniques are used to increase bone volume when it would be insufficient to allocate an adequate implant. In particular, when the bone is affected by horizontal atrophy, ridge thickness may be augmented by means of a technique called split crest or split ridge. It consists in the buccal and lingual cortices separation through a controlled fracture of the bone crest



[17,18]. In some cases, lateral relief osteotomies are performed on the buccal surface of the bone in order to facilitate and guide the split crest, making the procedure more controllable [19]. Nonetheless, the presence of additional osteotomies may cause intra- and post-operative complications [20].

The traditional split crest techniques involve various types of tools, such as chisels, hand mallets, and osteotomes. However, the surgery is usually extremely technique-dependent and sometimes may cause patient discomfort [21]. Most recent techniques such as ultrasonic bone surgery and threaded bone expanders provide a simpler and more controllable procedure, reducing injury risk and discomfort for the patients [22–26]. Threaded conical bone expanders compress and compact the bone during the split crest procedure, thus producing an adequate space for the implant without bone loss [19]. The ultrasonic bone surgery exploits the inverse piezoelectric effect: an electric current is applied to piezoelectric crystals, generating a controlled vibration. Vibration is transferred to a working tip, whose oscillations are able to disrupt mineralized tissues [27]. Since the vibration frequency necessary to cut the bone ranges between 25 and 30 kHz, and the soft tissues are not damaged by oscillations below 50 kHz, the technique is completely safe for the surrounding tissues [28,29]. Furthermore, ultrasonic bone surgery is less technique-sensitive than traditional split crest, reducing the inter-operator differences while achieving similar results in terms of implant survival rate [30,31].

In this study, split crest was performed *ex vivo* on bovine ribs, mimicking the surgery applied on the human jawbone, by means of threaded bone expanders (TBEs) and ultrasonic bone surgery (UBS), and the external bone cortices displacement was measured through digital image correlation (DIC). The DIC is a non-invasive, full-field measurement technique that requires a random speckle pattern on the surface of the sample in order to compute displacements and strains of the sample itself through an image-processing algorithm [32]. It is particularly suitable for biomechanical applications compared to other strain measurement techniques such as strain gauges, which are invasive and only provide a local measurement, or thermoelastic analyses, which in some conditions are not applicable to biological tissues [33,34]. Furthermore, optical measurements can be successfully coupled with finite element method and multibody modeling in order to achieve a complete mechanical characterization [35–39].

2. Materials and methods

During this study, threaded dental implants (NobelActive RP, length 13 mm, diameter 4.3 mm, Nobel Biocare Italiana S.r.l., Sesto San Giovanni, Italy) were inserted in 18 bovine ribs (mean thickness at the crest 3.51 ± 0.17 mm, TecnoDental S.r.l., Torino, Italy) selected to have a bone volume which required split crest to allocate the implants. In order to mimic the clinical procedure, the bone thickness and the implant size were selected according to case studies reported in the literature [40].

2.1. Design of experiment

The TBE and UBS split crest techniques were performed by means of respectively (1) Bone Expanders Dr. Sentineri (Mectron S.p.A., Carasco, Italy) and (2) Crest Splitting Kit (Acteon Group, Mérignac, France), and for the two techniques three types of implant site preparation were explored: (1) no relief osteotomies, (2) one relief osteotomy, or (3) two relief osteotomies. For the purpose of this study, a combination of split crest technique and type of implant site preparation is called *split crest procedure*: six different split crest procedures were therefore analyzed (figure 1), performing three replicas per procedure. Lastly, two implants were inserted in the mesial and distal sides of each bovine rib, thus inserting 36 implants in 18 bones.

The maximum displacement reached in the external surface of each implant site during the split crest procedure and the maximum displacement in the whole bone external surface interested by the split crest procedure were measured and considered as the dependent variables of the analysis.

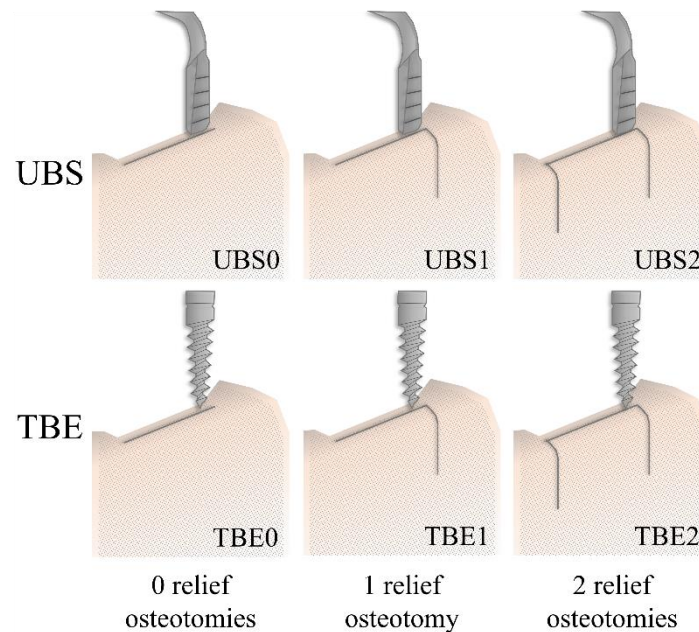


Figure 1. Split crest procedures investigated combining split crest techniques (UBS and TBE) and types of implant site preparation (0 relief osteotomies, 1 relief osteotomy, and 2 relief osteotomies).

2.2. Split crest procedure

The split crest procedure was performed in accordance with the clinical practice and the manufacturer's instructions [20,40,41]. At first, a longitudinal osteotomy of adequate depth was performed on the crest, and lateral relief osteotomies were added when included in the test plan. Secondly, tools of increasing size were used to perform the actual split crest, and finally the implants were screwed onto the obtained sites. The whole procedure was coupled with abundant irrigation to avoid bone overheating.

2.2.1. Threaded bone expanders

The split crest procedures involving the TBEs were conducted as follows: the first osteotomy was executed using an osteotome (OT7 micro-saw, Mectron S.p.A., Carasco, Italy), and two different Bone Expanders Dr. Sentineri (length 11.5 mm, diameter 2.5 and 3.5 mm) were inserted sequentially in each implant site. Lastly, a final drill (length 13 mm, diameter 3.5 mm) was used to complete the implant sites preparation before the insertion.

2.2.2. Ultrasonic bone surgery

Different surgical tools provided with Crest Splitting Kit were used for the split crest procedures involving the UBS. Each tool is named with the acronym CS (which stands for *crest splitting*) followed by a number that increases with the tool thickness: CS1 and CS2 were used for the first and second pilot osteotomies, at 8 mm of depth in the bone crest. CS3 was used for mesial and distal relief osteotomies when needed, and the split crest was performed using CS4, CS5, and CS6 (thickness 1.8 mm, 2.75 mm, and 3.75 mm respectively). As for the TBEs, the implant sites were completed with a final drill before the implant insertion.

2.3. Experimental setup

Before the tests, a random speckle pattern was applied on the external surface of each bone using a black ink spray can (figure 2a).




Figure 2. (a) Specimen surface prepared for DIC measurements; (b) Experimental setup.

The bones were held still using a vise during the tests, and the split crest procedure was carried out while recording the bone external surface with two cameras for 3D digital image correlation (ARAMIS 3D 6M, GOM Italia S.r.l. – a ZEISS Company, Buccinasco, Italy). The area was illuminated under a blue led light (figure 2b).

2.4. Displacement measurement

The bone external surface around and between the implant sites was selected as region of interest (ROI) for the displacement measurement. The ROI was identified with the image processing software (GOM Correlate, GOM Italia S.r.l. – a ZEISS Company, Buccinasco, Italy) and a reference frame was created with the X-Y plane lying on it. The displacement was measured in the out-of-plane direction (Z axis). Two inspection points were placed in correspondence of the implant axes at a distance of 5 mm from the upper edge of the bone along the X axis, as shown in figure 3, and the corresponding displacement of the external surface along the Z axis was computed, as well as the absolute maximum displacement in the entire ROI.

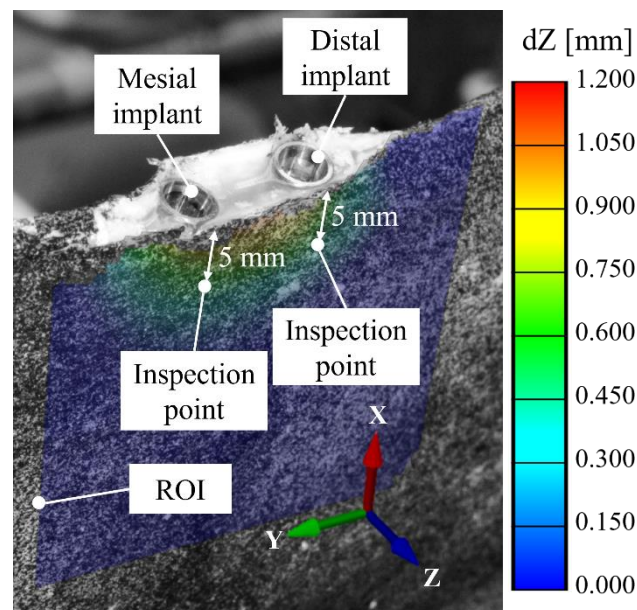


Figure 3. Image processing.

2.5. Statistical analysis

A two-way analysis of variance (ANOVA) was conducted to investigate the influence of the different split crest techniques and the number of relief osteotomies on bone displacement (table 1).

Table 1. Two-way ANOVA.

Factor	Levels
Split crest technique	Threaded bone expanders
	Ultrasonic bone surgery
Site preparation	0 relief osteotomies
	1 relief osteotomy
	2 relief osteotomies

3. Results and discussion

In this study, 18 split crest procedures were performed exploring the influence on the implant insertion outcome of the split crest technique and the site preparation. Implant insertion was always possible after the split crest, with no regard for the adopted technique nor the number of relief osteotomies. However, the statistical analysis highlighted a significant effect of the number of relief osteotomies on the maximum displacement of the whole ROI. A Bonferroni post-hoc correction was therefore conducted for pairwise comparison; the results are shown in figure 4c. This result reflects clinical outcomes [42] and suggests that the space gained inside the bone volume is enough to insert an implant even in absence of additional osteotomies. Furthermore, no statistical significance was detected regarding the displacement at the inspection points, neither for split crest techniques nor for site preparation ($p > 0.05$).

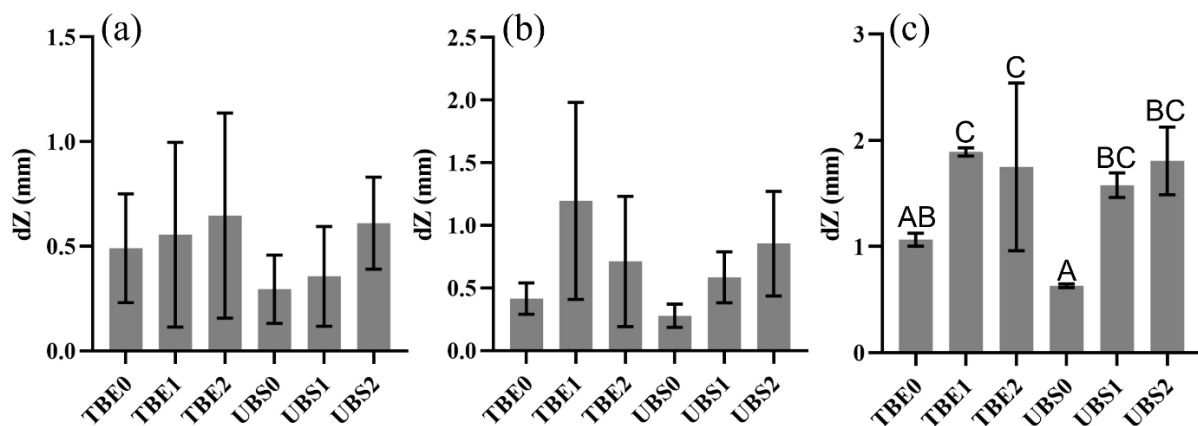


Figure 4. Maximum displacement in correspondence of (a) the mesial implant site, (b) the distal implant site, and (c) the whole ROI. In (c) different letters above the bars show statistical significant differences. TBE: Threaded Bone Expanders; UBS: Ultrasonic Bone Surgery; 0, 1, or 2: number of relief osteotomies.

Although the ANOVA did not find significant differences between the displacement obtained with TBEs and the one obtained with UBS, the bar plots in figure 4 show that in most cases a slightly lower displacement was obtained with the UBS compared with TBEs, which suggests a different internal bone strain distribution induced by the two techniques.

Unexpected bone fracture occurred two times during split crest with TBEs, while it never happened with UBS. Both fractures occurred in presence of relief osteotomies, which reflects previous findings about the enhanced fracture risk when additional osteotomies are performed [20].

4. Conclusions

This study explored bone behavior during six different split crest procedures and highlighted the potentialities of the DIC application in the dental field. To the authors' knowledge, this is the first work that applies DIC to measure the bone response to split crest. Within the limitations of this study, the Ultrasonic Bone Surgery was confirmed to be safer and easier to use in comparison with Threaded Bone Expanders. Further development might include the exploration of the bone behavior at the bone-surgical tool interface during the split crest procedure. A combination of finite element modeling, digital image correlation, and microtomography could be a promising yet ambitious strategy to reach this goal.

References

- [1] Baldi D, Colombo J, Gavoglio P, De Giorgis L, Motta F, Lugas A T, Lertora E and Schierano G 2022 Roughness and SEM Analysis of Manual and Ultrasonic Instrumentation over Different Crown Materials for Dental Implants Restorations *Materials (Basel)*. **15** 1159
- [2] Schierano G, Bellone G, Manzella C, Preti G and Emanuelli G 2001 In Vitro Effect of Transforming Growth Factor- β on Adhesion Molecule Expression by Human Gingival Fibroblasts Cultured in the Presence of a Titanium Abutment *J. Periodontol.* **72** 1658–65
- [3] Lugas A T, Terzini M, Zanetti E M, Schierano G, Manzella C, Baldi D, Bignardi C and Audenino A L 2020 In Vitro Impact Testing to Simulate Implant-Supported Prosthesis Retrieval in Clinical Practice: Influence of Cement and Abutment Geometry *Materials (Basel)*. **13** 1749
- [4] Lugas A T, Terzini M, Zanetti E M, Schierano G, Manzella C, Baldi D, Bignardi C and Audenino A L 2020 In Vitro Simulation of Dental Implant Bridges Removal: Influence of Luting Agent and Abutments Geometry on Retrieval *Materials (Basel)*. **13** 2797
- [5] Bignardi C, Zanetti E M, Terzini M, Ciccola A R, Schierano G and Audenino A L 2018 Reliability, Learnability and Efficiency of Two Tools for Cement Crowns Retrieval in Dentistry *Open Biomed. Eng. J.* **12** 27–35
- [6] Moro A, De Angelis P, Pelo S, Gasparini G, D'Amato G, Passarelli P C and Saponaro G 2018 Alveolar ridge augmentation with maxillary sinus elevation and split crest: Comparison of 2 surgical procedures. *Medicine (Baltimore)*. **97** e11029
- [7] Colletti G, Allevi F, Moneghini L, Rabbiosi D, Bertossi D, Frau I, Biglioli F and Tadini G 2014 Epidermal nevus and ameloblastoma: a rare association *Oral Surg. Oral Med. Oral Pathol. Oral Radiol.* **117** e275–9
- [8] Bertossi D, Favero V, Albanese M, De-Santis D, Martano M, Padovano-di-Leva A, De-Florio I, Nocini P and Lo-Muzio L 2014 Peripheral ameloblastoma of the upper gingiva: Report of a case and literature review *J. Clin. Exp. Dent.* **6** e180–4
- [9] Aimetti M, Manavella V, Corano L, Ercoli E, Bignardi C and Romano F 2018 Three-dimensional analysis of bone remodeling following ridge augmentation of compromised extraction sockets in periodontitis patients: A randomized controlled study *Clin. Oral Implants Res.* **29** 202–14
- [10] Aimetti M, Mariani G M, Ferrarotti F, Ercoli E, Audagna M, Bignardi C and Romano F 2015 Osseous resective surgery with and without fibre retention technique in the treatment of shallow intrabony defects: a split-mouth randomized clinical trial *J. Clin. Periodontol.* **42** 182–9
- [11] Manavella V, Romano F, Corano L, Bignardi C and Aimetti M 2018 Three-Dimensional Volumetric Changes in Severely Resorbed Alveolar Sockets After Ridge Augmentation with Bovine-Derived Xenograft and Resorbable Barrier: A Preliminary Study on CBCT Imaging *Int. J. Oral Maxillofac. Implants* **33** 373–82
- [12] Manavella V, Romano F, Garrone F, Terzini M, Bignardi C and Aimetti M 2017 A novel image processing technique for 3D volumetric analysis of severely resorbed alveolar sockets with CBCT *Minerva Dent. Oral Sci.* **66** 81–90

- [13] Brånemark P I, Hansson B O, Adell R, Breine U, Lindström J, Hallén O and Ohman A 1977 Osseointegrated implants in the treatment of the edentulous jaw. Experience from a 10-year period. *Scand. J. Plast. Reconstr. Surg. Suppl.* **16** 1–132
- [14] De Santis D, Cucchi A, Rigoni G and Longhi C 2015 Short Implants with Oxidized Surface in Posterior Areas of Atrophic Jaws: 3- to 5-Year Results of a Multicenter Study *Clin. Implant Dent. Relat. Res.* **17** 442–52
- [15] De Santis D, Cucchi A, Rigoni G, Longhi C and Nocini P 2016 Relationship Between Primary Stability and Crestal Bone Loss of Implants Placed with High Insertion Torque: A 3-Year Prospective Study *Int. J. Oral Maxillofac. Implants* **31** 1126–34
- [16] Bellia E, Boggione L, Terzini M, Manzella C and Menicucci G 2018 Immediate Loading of Mandibular Overdentures Retained by Two Mini-Implants: A Case Series Preliminary Report *Int. J. Prosthodont.* **31** 558–64
- [17] Simion M, Baldoni M and Zaffe D 1992 Jawbone enlargement using immediate implant placement associated with a split-crest technique and guided tissue regeneration. *Int. J. Periodontics Restorative Dent.* **12** 462–73
- [18] Scipioni A, Bruschi G B and Calesini G 1994 The edentulous ridge expansion technique: a five-year study. *Int. J. Periodontics Restorative Dent.* **14** 451–9
- [19] Bassi M A and Di Stefano D A 2012 Bone splitting with threaded conical expanders: new perspectives *Ital. Oral Surg.* **11** 140–53
- [20] Di Lauro A E, Abbate D, Dell'Angelo B, Mariniello M, di Lauro F and Sammartino G 2012 Controlled expansion of an atrophic mandibular ridge for implant purposes: a case report *Ital. Oral Surg.* **11** 105–10
- [21] Chiriac G, Herten M, Schwarz F, Rothamel D and Becker J 2005 Autogenous bone chips: influence of a new piezoelectric device (Piezosurgery®) on chip morphology, cell viability and differentiation *J. Clin. Periodontol.* **32** 994–9
- [22] Summers R B 1994 The osteotome technique: Part 2--The ridge expansion osteotomy (REO) procedure. *Compendium* **15** 422–36
- [23] Summers R B 1994 A new concept in maxillary implant surgery: the osteotome technique. *Compendium* **15** 152–62
- [24] Vercellotti T, Nevins M L, Kim D M, Nevins M, Wada K, Schenk R K and Fiorellini J P 2005 Osseous response following resective therapy with piezosurgery. *Int. J. Periodontics Restorative Dent.* **25** 543–9
- [25] Preti G, Martinasso G, Peirone B, Navone R, Manzella C, Muzio G, Russo C, Canuto R A and Schierano G 2007 Cytokines and Growth Factors Involved in the Osseointegration of Oral Titanium Implants Positioned Using Piezoelectric Bone Surgery Versus a Drill Technique: A Pilot Study in Minipigs *J. Periodontol.* **78** 716–22
- [26] Danza M, Guidi R and Carinci F 2009 Comparison Between Implants Inserted Into Piezo Split and Unsplit Alveolar Crests *J. Oral Maxillofac. Surg.* **67** 2460–5
- [27] Leclercq P, Zenati C and Dohan D M 2008 Ultrasonic Bone Cut Part 2: State-of-the-Art Specific Clinical Applications *J. Oral Maxillofac. Surg.* **66** 183–8
- [28] Leclercq P, Zenati C, Amr S and Dohan D M 2008 Ultrasonic Bone Cut Part 1: State-of-the-Art Technologies and Common Applications *J. Oral Maxillofac. Surg.* **66** 177–82
- [29] González-García A, Diniz-Freitas M, Somoza-Martín M and García-García A 2008 Piezoelectric and conventional osteotomy in alveolar distraction osteogenesis in a series of 17 patients. *Int. J. Oral Maxillofac. Implants* **23** 891–6
- [30] Robiony M, Polini F, Costa F, Vercellotti T and Politi M 2004 Piezoelectric bone cutting in multipiece maxillary osteotomies *J. Oral Maxillofac. Surg.* **62** 759–61
- [31] Stacchi C, Lombardi T, Baldi D, Bugea C, Rapani A, Perinetti G, Itri A, Carpita D, Audenino G, Bianco G, Verardi S, Carossa S and Schierano G 2018 Immediate Loading of Implant-Supported Single Crowns after Conventional and Ultrasonic Implant Site Preparation: A Multicenter Randomized Controlled Clinical Trial *Biomed Res. Int.* **2018** 1–8

- [32] Palanca M, Tozzi G and Cristofolini L 2016 The use of digital image correlation in the biomechanical area: a review *Int. Biomech.* **3** 1–21
- [33] Zanetti E M and Audenino A L 2010 Differential thermography for experimental, full-field stress analysis of hip arthroplasty *J. Mech. Med. Biol.* **10** 515–29
- [34] Zanetti E M, Musso S S and Audenino A L 2007 Thermoelastic stress analysis by means of a standard thermocamera *Exp. Tech.* **31** 42–50
- [35] Tiozzi R, Vasco M A A, Lin L, Conrad H J, Bezzon O L, Ribeiro R F and Fok A S L 2013 Validation of finite element models for strain analysis of implant-supported prostheses using digital image correlation *Dent. Mater.* **29** 788–96
- [36] Qian L, Todo M, Morita Y, Matsushita Y and Koyano K 2009 Deformation analysis of the periodontium considering the viscoelasticity of the periodontal ligament *Dent. Mater.* **25** 1285–92
- [37] Borrelli S, Formaggio A, Civilini V and Lugas A T 2021 Phantom-based lumbar spine experimental investigation and validation of a multibody model *Int. J. Comput. Methods Exp. Meas.* **9** 226–38
- [38] Pascoletti G, Cali M, Bignardi C, Conti P and Zanetti E M 2020 Mandible Morphing Through Principal Components Analysis BT - Design Tools and Methods in Industrial Engineering *Design Tools and Methods in Industrial Engineering: Proceedings of the International Conference on Design Tools and Methods in Industrial Engineering, ADM 2019* ed C Rizzi, A O Andrisano, F Leali, F Gherardini, F Pini and A Vergnano (Cham: Springer International Publishing) pp 15–23
- [39] Pascoletti G, Aldieri A, Terzini M, Bhattacharya P, Cali M and Zanetti E M 2021 Stochastic PCA-Based Bone Models from Inverse Transform Sampling: Proof of Concept for Mandibles and Proximal Femurs *Appl. Sci.* **11** 5204
- [40] Kelly A and Flanagan D 2013 Ridge Expansion and Immediate Placement With Piezosurgery and Screw Expanders in Atrophic Maxillary Sites: Two Case Reports *J. Oral Implantol.* **39** 85–90
- [41] Brugnami F, Caiazzo A and Mehra P 2014 Piezosurgery-Assisted, Flapless Split Crest Surgery for Implant Site Preparation *J. Maxillofac. Oral Surg.* **13** 67–72
- [42] Esposito M, Hirsch J-M, Lekholm U and Thomsen P 1998 Biological factors contributing to failures of osseointegrated oral implants, (I). Success criteria and epidemiology *Eur. J. Oral Sci.* **106** 527–51