

The role of intraoperative ultrasound in the assessment of hepatic deposits in intra-abdominal malignancies

Original

The role of intraoperative ultrasound in the assessment of hepatic deposits in intra-abdominal malignancies / Elkeleny, Mr; Abdel-Salam, H; Mansour, A. - In: EGYPTIAN JOURNAL OF SURGERY. - ISSN 1110-1121. - ELETTRONICO. - 38:2(2019), pp. 277-281. [10.4103/ejs.ejs_197_18]

Availability:

This version is available at: 11583/2912714 since: 2021-07-16T00:02:09Z

Publisher:

WOLTERS KLUWER MEDKNOW PUBLICATIONS

Published

DOI:10.4103/ejs.ejs_197_18

Terms of use:

This article is made available under terms and conditions as specified in the corresponding bibliographic description in the repository

Publisher copyright

(Article begins on next page)

The role of intraoperative ultrasound in the assessment of hepatic deposits in intra-abdominal malignancies

Mostafa R. Elkeleny, Hassan Abdel-Salam, Ahmed M. Farid

Department of General Surgery, Faculty of Medicine, University of Alexandria, Alexandria, Egypt

Correspondence to Mostafa R. Elkeleny, MD, MRCS, Department of General Surgery, Faculty of Medicine, University of Alexandria, Alexandria, Egypt. Tel: 01005814622; e-mail: mostafa.refaie910@gmail.com, Mostafa.refaie@alexmed.edu.eg

Received 6 December 2018

Accepted 3 January 2019

The Egyptian Journal of Surgery 2019, 38:277–281

Introduction/background

The liver is the most common site of metastatic disease with up to 40–50% of all cancers having the potentiality for sending liver metastasis during the disease. Consequently, there has been increasing value for surgical resection of hepatic deposits of different types of cancers. The need for accurate evaluation of the extent of hepatic metastasis was established for choosing the most suitable patients for surgery and in planning the extent of hepatic resection.

Aim

The aim of this study was to evaluate the role of intraoperative ultrasound (IOUS) in the detection of hepatic deposits in intra-abdominal malignancies with special emphasis on its accuracy, sensitivity, and specificity.

Patients and methods

This study was carried out on 30 patients who were admitted to the Gastrointestinal Surgery Unit, Main Alexandria University Hospital, with intra-abdominal malignancies for whom elective open surgical intervention was recommended in the period from 1 September 2017 till the 31 March 2018.

Results

This study consisted of 17 (56.7%) men and 13 (43.3%) women. Their mean age at admission was 52.77 ± 9.12 years. Six (20%) of the included patients were found to have hepatic lesions by using IOUS including the four (13.3%) cases already detected by preoperative imaging. Two (6.67%) cases were newly discovered in the operative room by using IOUS.

Conclusion

This study has proved that IOUS demonstrates superior lesion detection over the various noninvasive preoperative imaging modalities causing significant impact on change of the planned surgical strategy.

Keywords:

intra-abdominal malignancies, intraoperative ultrasound, liver metastasis

Egyptian J Surgery 38:277–281

© 2019 The Egyptian Journal of Surgery
1110-1121

Introduction

The liver is the most common site of metastatic disease. Metastatic liver disease is common in most gastrointestinal malignancies, with patient survival being highly dependent on the control of metastatic disease mandating accurate localization of hepatic deposits [1,2].

Intraoperative ultrasound (IOUS) has proven accuracy for the detection of liver metastases, with reported sensitivity of 93.8%, specificity of 94.4%, positive predictive value of 92.0%, and negative predictive value of 95.7%. However, with the recent advances in preoperative images the role of IOUS was controversial [3,4].

In spite of the increasing rates of preoperative detection of liver lesions, preoperative imaging studies cannot compensate for the dynamic intraoperative localization offered by IOUS that allows an accurate parenchymal transaction thus improving the safety of liver surgery

and the margin status. IOUS not only helps the surgeon to understand the three-dimensional relationship between the liver vasculature and tumor it also improves patient outcome by getting adequate margins of resection [5].

The aim of this study was to evaluate the role of IOUS in the detection of hepatic deposits in intra-abdominal malignancies with special emphasis on its accuracy, sensitivity, and specificity.

Patients and methods

This study was carried out on 30 consecutive patients who were admitted to the Gastrointestinal Surgery Unit, Alexandria Main University Hospital, with

This is an open access journal, and articles are distributed under the terms of the Creative Commons Attribution-NonCommercial-ShareAlike 4.0 License, which allows others to remix, tweak, and build upon the work non-commercially, as long as appropriate credit is given and the new creations are licensed under the identical terms.

intra-abdominal malignancies for whom elective open surgical intervention was recommended in the period from 1 September 2017 till the 31 March 2018.

Only patients with an interval of not more than a month between dedicated preoperative imaging study and the time of surgery were included in the study.

After approval of the local ethics committee, all patients included in the study were informed well about the procedure and an informed written consent was obtained from every patient before carrying out the procedure.

All the included patients performed full laboratory investigations, preoperative imaging study including computed tomography (CT) scan, as well as the required investigations to fully assess the primary tumor (e.g. endoscopy).

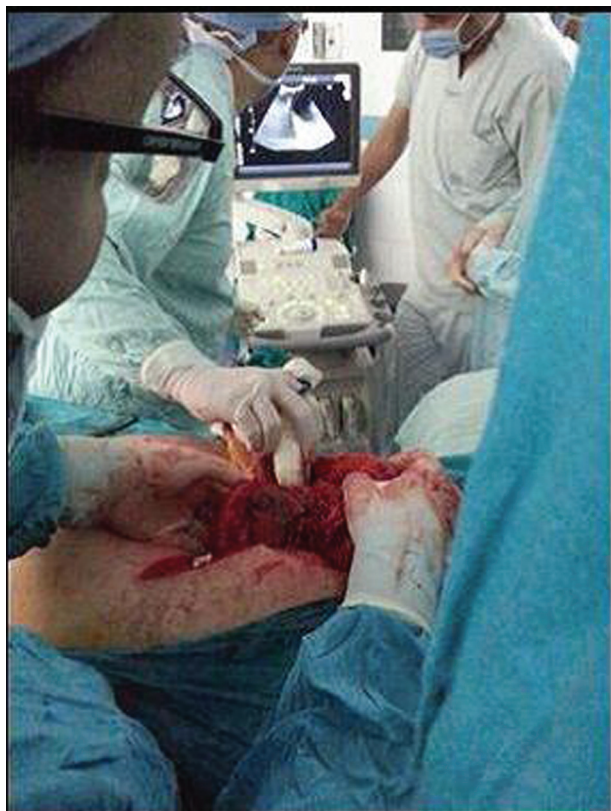Through the standard midline abdominal exploratory incision or extended right subcostal incision, taking down any inflammatory adhesions was done (Fig. 1). Sectioning of the falciform and round ligaments may be done. Careful inspection and palpation of the liver's surface was performed first followed by IOUS probe

placement and examination of the liver for the detection of liver metastases without mobilization of the liver by a radiologist.

A real-time B-mode with color Doppler capabilities electronic scanner system, Toshiba TA311 (Tokyo, Japan) with a 7.5-10 MHz T-shaped linear array probe, or a convex-array probe was used. The liver was scanned with overlapping fields from the dome to the caudal edge, proceeding from the left to the right through the entire organ in a sequential manner. The examination started with identifying the hepatic veins by placing the probe on the anterior portion of segment IV with its inclination superiorly as they enter the inferior vena cava are characterized by their almost hyperechoic walls and following each vein out to its peripheral tributary branches which were used to identify the sectors and segments.

The next step is to identify the left portal pedicles to segments I, II, III, and IV and the right portal pedicles to segments V, VI, VII, and VIII by inclining the transducer inferiorly. Finally, the porta hepatis was evaluated. Once a lesion had been identified, it was examined thoroughly (site, maximum size, character, and shape) with its relation to the intrahepatic vessels determined.

Figure 1



Placement of the intraoperative ultrasound probe.

Results

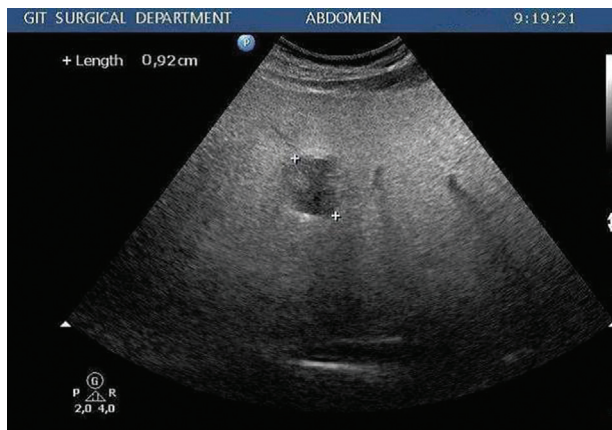
The 30 patients included in this study consisted of 17 (56.7%) men and 13 (43.3%) women. Their mean age at admission was 52.77 ± 9.12 years (ranged from 37 to 70 years). This study included eight (26.7%) patients who underwent surgery for hepatobiliary pancreatic tumors and 22 (73.3%) for gastrointestinal tract tumors.

All the included patients did preoperative CT, whereas two (6.7%) patients did MRI as well with four (13.3%) cases having hepatic lesions; one (3.33%) case with a simple cyst, two (6.7%) cases with a single mostly benign lesion, and one (3.33%) case with a single mostly malignant lesion.

All cases included in this study had their preoperative imaging studies within the month preceding surgery during which IOUS was performed. The time elapsed between the preoperative imaging and surgery in this study ranged from 10 to 28 days with a median of 22 days and a mean of 20.93 ± 4.72 days.

Six (20%) of the included patients were found to have hepatic lesions by using IOUS including the four

Figure 2



Likely metastatic lesion detected by intraoperative ultrasound as a hypo-echoic mass of about 9mm in segment VII (not detected by preoperative computed tomography).

(13.3%) cases already detected by preoperative imaging. The two lesions that were diagnosed preoperatively by CT as a simple hepatic cyst and benign hepatic lesion had the same diagnosis reported by IOUS.

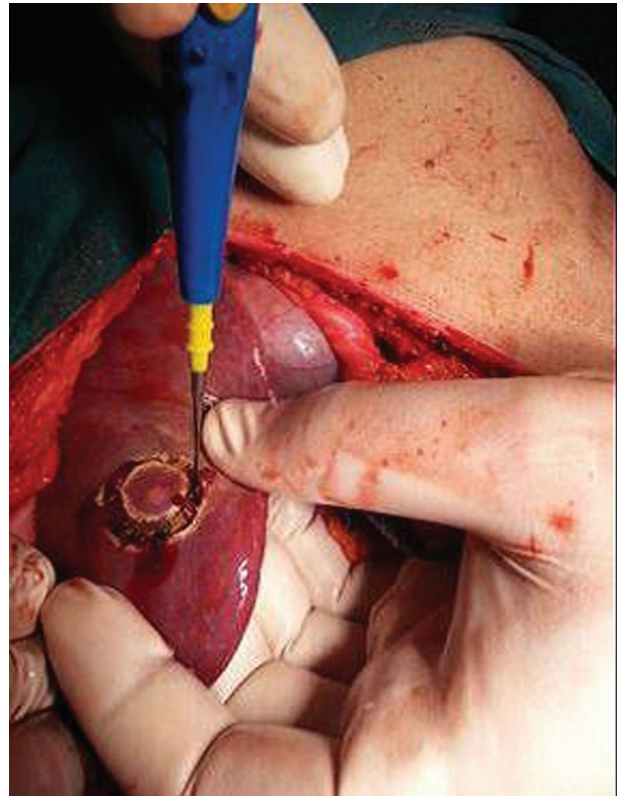The two lesions that required further assessment by MRI preoperatively were both found to have malignant criteria by IOUS, thus, contradicting the interpretation of preoperative imaging in one case.

Two (6.67%) cases were newly discovered in the operative room by using IOUS; one case with a single mostly malignant lesion (Fig. 2) and the other case with multiple mostly malignant lesions. Analyzing the data obtained showed a statistically significant higher efficacy of IOUS in both detecting and characterizing hepatic lesions when compared with preoperative imaging.

By recording the time consumed by the operators for complete hepatic scanning and characterization of detected lesions using IOUS, the duration of IOUS procedure did not exceed 5 min in most of the cases (70%). The time needed for complete hepatic scanning ranged from 2 to 8 min with a mean of 4.97 ± 1.38 min and a median of 5 min, obviously not affecting much the operative time of the planned surgical procedure.

The application of IOUS in this study resulted in change in the operative decision in three (10% of the included patients and 50% of the cases of detected liver lesions) out of the 30 included cases. In one (3.33%) of those cases, extension of surgery was done to include hepatic metastasectomy for hepatic deposits in a case of small intestinal carcinoid tumor

Figure 3



Hepatic metastasectomy of deposits discovered intraoperatively in a case of small intestinal carcinoid.

(Fig. 3). In the other two (6.67%) cases, limitation of surgery was done by performing gastrojejunostomy in a case of cancer stomach (that was planned for distal gastrectomy) and another of cancer pancreas (that was planned for Whipple's operation) after proved presence of hepatic deposits as both patients had some degree of gastric outlet obstruction.

Discussion

Although there was a historical decrease in rates of adopting IOUS between decades in the evaluation of hepatic metastasis, the results reported in most of the published literature confirm that the impact of IOUS has plateaued over the last decade despite further advances in preoperative imaging. With the current rates of change in surgical strategy, it appears that modern preoperative imaging alone does not preclude the use of IOUS and that combining preoperative imaging together with IOUS can give the best results in detecting hepatic deposits [6,7].

IOUS is considered by the literature to be the imaging exploration with the highest resolution in the examination of the liver. It allows for a very good characterization of focal liver lesions, with both sensitivity and specificity values of more than 90% [8].

The purpose of this study as previously discussed was to determine the diagnostic performance of IOUS in the detection of hepatic lesions, malignant or benign, in patients with abdominal tumors independent of their primary site with its impact on changing the planned surgical strategy.

All the included patients had preoperative CT, whereas two (6.7%) patients had additional MRI. IOUS was done for all the patients with a mean of 20.93 ± 4.72 days (from 10 to 28 days) from their last preoperative imaging which is not far from the interval reported by Yang *et al.* [9] who reported that the utility of the preoperative CT to evaluate colorectal liver metastasis was inversely proportional to the time interval between imaging and surgery. Their model predicted that in order to achieve a sensitivity of more than 90%, CT had to be performed no more than 26 days before the surgery. Also Wagnetz *et al.* [3] stated that studies performed within 6 weeks of surgery can judge well the sensitivity of IOUS.

Of the 30 patients included in our study, six (20%) patients by IOUS had focal hepatic lesions; in four (66.7%) patients the lesions were classified as malignant and in two (33.3%) patients the lesions were classified as benign. Zacherl *et al.* [10] reported a frequency of benign liver lesions of 10–30% which is not far from the frequency of this study, whereas Damian *et al.* [11] reported that benign liver lesions constituted 43.8% of their detected lesions.

It is worth mentioning that two (6.66% of included patients) of the four lesions were classified as malignant in this study were discovered only intraoperatively by the application of IOUS besides one (3.33%) lesion that had been misinterpreted preoperatively by being benign.

These results were not far from the results reported by D'Hondt *et al.* [6] where IOUS detected lesions not found on preoperative investigation in 11.2% of the patients. Ciriembei *et al.* [12] stated that IOUS detected new hepatic lesions in 22.91% of the cases. Zacherl *et al.* [10] also reported that IOUS was found to provide new treatment-relevant information on hepatic metastases in 29.5% of the cases. Luck and Maddern [13] stated that IOUS determines new hepatic lesions in various percentages, depending on the complexity of preoperative investigations, type and dimensions of the lesion, these percentages varying between 5 and 30% of the cases.

Like most of the published studies, in our series IOUS findings of focal hepatic lesions lead to the change in

Table 1 Percentage of change in planned surgical strategy according to intraoperative ultrasound

References	%
This study	10
Damian <i>et al.</i> [11]	12.3
Cirimbei <i>et al.</i> [12]	12.28
Jreaz <i>et al.</i> [4]	17
D'Hondt <i>et al.</i> [6]	16.5
D'Onofrio <i>et al.</i> [14]	7
Figueras <i>et al.</i> [15]	11

the operative strategy in three (10%) cases as discussed earlier (Table 1) [4,6,11,12,14,15].

Despite their increasing rates of preoperative detection of liver lesions, preoperative imaging studies cannot compensate for the dynamic intraoperative mapping offered by IOUS that allows a precise parenchymal transaction thus improving the safety of liver surgery and the margin status. IOUS not only helps the surgeon to understand the three-dimensional relationship between the liver vasculature and tumor but also improves the patient outcome by defining adequate margins of resection [16–18].

By analyzing the data retrieved in this study and as previously displayed, although improved preoperative imaging has lessened the need for IOUS, our study confirms that this approach still offers excellent accuracy in the detection and characterization of focal liver lesions.

Nevertheless, the study clearly demonstrated that the use of IOUS is still recommended not only to confirm the results found on preoperative imaging, but also to provide additional information to the surgeon which could change the surgical strategy intraoperatively.

Limitation

The small number of the included patients, the absence of histopathological analysis of liver deposits as well as the nonblindness of the radiologists and surgeons performing IOUS in our series to the results of the preoperative imaging modalities are considered as limitations of this study. So, further studies with larger number of patients, which include histopathological interpretation of the detected liver lesions, are needed for formal testing of the results reported in this study.

Conclusion

This study has proved that IOUS demonstrates superior lesion detection over the various

noninvasive preoperative imaging modalities causing a significant impact on change of the planned surgical strategy.

Financial support and sponsorship

Nil.

Conflicts of interest

There are no conflicts of interest.

References

- 1 Breitenstein S, Apestegui C, Petrowsky H, Clavien PA. State of the art' in liver resection and living donor liver transplantation: a worldwide survey of 100 liver centers. *World J Surg* 2009; 33:797–803.
- 2 Kane RA, Hughes LA, Cua EJ, Steele GD, Jenkins RL, Cady B. The impact of intraoperative ultrasonography on surgery for liver neoplasms. *J Ultrasound Med* 1994; 13:1–6.
- 3 Wagnetz U, Atri M, Massey C, Wei AC, Metser U. Intraoperative ultrasound of the liver in primary and secondary hepatic malignancies: comparison with preoperative 1.5-T MRI and 64-MDCT. *Am J Roentgenol* 2011; 196:562–568.
- 4 Jreaz R, Hart R, Jayaraman S. Intraoperative ultrasonography and surgical strategy in hepatic resection: What difference does it make? *Can J Surg* 2015; 58:318–322.
- 5 Itabashi T, Sasaki A, Otsuka K, Kimura T, Nitta H, Wakabayashi G. Potential value of sonazoid-enhanced intraoperative laparoscopic ultrasonography for liver assessment during laparoscopy-assisted colectomy. *Surg Today* 2014; 44:696–701.
- 6 D'Hondt M, Vandenbroucke-Menu F, Preville-Ratelle S, Turcotte S, Chagnon M, Plasse M, *et al.* Is intra-operative ultrasound still useful for the detection of a hepatic tumour in the era of modern pre-operative imaging? *HPB (Oxford)* 2011; 13:665–669.
- 7 Bhattacharjya S, Bhattacharjya T, Baber S, Tibballs JM, Watkinson AF, Davidson BR. Prospective study of contrast-enhanced computed tomography, computed tomography during arteriportography, and magnetic resonance imaging for staging colorectal liver metastases for liver resection. *Br J Surg* 2004; 91:1361–1369.
- 8 Reiner CS, Stolzmann P, Husmann L, Burger IA, Hullner MW, Schaefer NG, *et al.* Protocol requirements and diagnostic value of PET/MR imaging for liver metastasis detection. *Eur J Nucl Med Mol Imaging* 2014; 41:649–658.
- 9 Yang S, Hongjinda S, Hanna SS, Gallinger S, Wei AC, Kiss A, *et al.* Utility of preoperative imaging in evaluating colorectal liver metastases declines over time. *HPB (Oxford)* 2010; 12:605–609.
- 10 Zacherl J, Scheuba C, Imhof M, Zacherl M, Langle F, Pokieser P, *et al.* Current value of intraoperative sonography during surgery for hepatic neoplasms. *World J Surg* 2002; 26:550–554.
- 11 Damian CD, Rednic N, Munteanu D, Cazacu M. The role of intraoperative ultrasound for the assessment of the focal liver lesions in patients with colorectal cancer. *Med Ultrason* 2014; 16:114–118.
- 12 Cirimbei S, Puscu C, Lucenco L, Bratucu E. The role of intraoperative ultrasound in establishing the surgical strategy regarding hepato-bilio-pancreatic pathology. *Chirurgia (Bucur)* 2013; 108: 643–651.
- 13 Luck AJ, Maddern GJ. Intraoperative abdominal ultrasonography. *Br J Surg* 1999; 86:5–16.
- 14 D'Onofrio M, Gallotti A, Martone E, Nicoli L, Mautone S, Ruzzenente A, *et al.* Is intraoperative ultrasound (IOUS) still useful for the detection of liver metastases? *J Ultrasound* 2009; 12:144–147.
- 15 Figueras J, Planellas P, Albiol M, Lopez-Ben S, Soriano J, Codina-Barreras A, *et al.* Role of intra-operative echography and computed tomography with multiple detectors in the surgery of hepatic metastases: a prospective study. *Cir Esp* 2008; 83:134–138.
- 16 Leen E, Ceccotti P, Moug SJ, Glen P, MacQuarrie J, Angerson WJ, *et al.* Potential value of contrast-enhanced intraoperative ultrasonography during partial hepatectomy for metastases: an essential investigation before resection? *Ann Surg* 2006; 243:236–240.
- 17 Joo I. The role of intraoperative ultrasonography in the diagnosis and management of focal hepatic lesions. *Ultrasonography* 2015; 34:246–257.
- 18 Patel NA, Roh MS. Utility of intraoperative liver ultrasound. *Surg Clin North Am* 2004; 84: 513–524.