

First Report of the One-Point Transradial Two Sheathless Catheters Insertion (OTRANTO) Technique

Original

First Report of the One-Point Transradial Two Sheathless Catheters Insertion (OTRANTO) Technique / Sgueglia, G. A.; Gioffre, G.; Chiastra, C.; Di Giorgio, A.; Gaspardone, A.. - In: JACC: CARDIOVASCULAR INTERVENTIONS. - ISSN 1936-8798. - ELETTRONICO. - 13:1(2020), pp. e9-e10. [10.1016/j.jcin.2019.09.004]

Availability:

This version is available at: 11583/2859275 since: 2020-12-30T13:18:28Z

Publisher:

Elsevier Inc.

Published

DOI:10.1016/j.jcin.2019.09.004

Terms of use:

openAccess

This article is made available under terms and conditions as specified in the corresponding bibliographic description in the repository

Publisher copyright

(Article begins on next page)

First Report of the One-Point Transradial Two Sheathless Catheters Insertion (OTRANTO) Technique

Gregory A. Sgueglia¹, Gaetano Giofrè¹, Claudio Chiastra²,

Angela Di Giorgio³, Achille Gasparone¹

1. Division of Cardiology, Ospedale S. Eugenio, Rome, Italy
2. PoliTo^{BIO}Med Lab, Department of Mechanical and Aerospace Engineering, Politecnico di Torino, Turin, Italy
3. Angiologia Columbus, Fondazione Policlinico Universitario Agostino Gemelli, Rome, Italy.

Corresponding author:

Dr. Gregory A. Sgueglia, MD, PhD

Division of Cardiology

Ospedale S. Eugenio

Piazzale dell'Umanesimo, 10

Rome 00144, Italy

E-mail: g.a.sgueglia@gmail.com

Keywords: femoropoplital artery, moving leg, computational fluid dynamics, moving boundary, wall shear stress

A 67-year-old patient with a complex clinical history including multiple revascularization procedures was scheduled to undergo percutaneous coronary intervention on a severely calcified left main coronary artery, aiming to simultaneously treat its two branches with intravascular lithotripsy. Given their bulky profile, the advancement of two coronary lithotripsy balloons would have required a single 8-F guide catheter or two smaller diameter guide catheters, one for each device. Both alternatives were unattractive, because the patient's vascular access options were limited to the right upper extremity.

Because the C2 coronary lithotripsy balloon (Shockwave Medical, Fremont, California) is 5-F compatible (1), we devised the one-point transradial two sheathless catheters insertion (OTRANTO) technique to advance the lithotripsy balloons in two 5-F guide catheters inserted sheathless according to the balloon-assisted tracking technique via the same radial artery access (Figure 1).

With the OTRANTO technique, only one forearm artery is needed. Moreover, the sheathless insertion of the two guide catheters allowed us to save the thickness of the sheath introducer, thereby potentially reducing vessel trauma and increasing residual patency (Figure 2).

The OTRANTO approach was carefully considered during pre-procedural planning and believed to be the most rational solution to the patient's complexity. In this case it was found to be safe and effective. Further study is needed to understand the risks and benefits among other patients.

Footnotes

The authors have reported that they have no relationships relevant to the contents of this paper to disclose.

References

- (1) Sgueglia GA, Gioffre G, Piccioni F, Gaspardone A. Slender distal radial five French coronary shockwave lithotripsy. *Catheter Cardiovasc Interv* 2019;94:395–8.

Figures

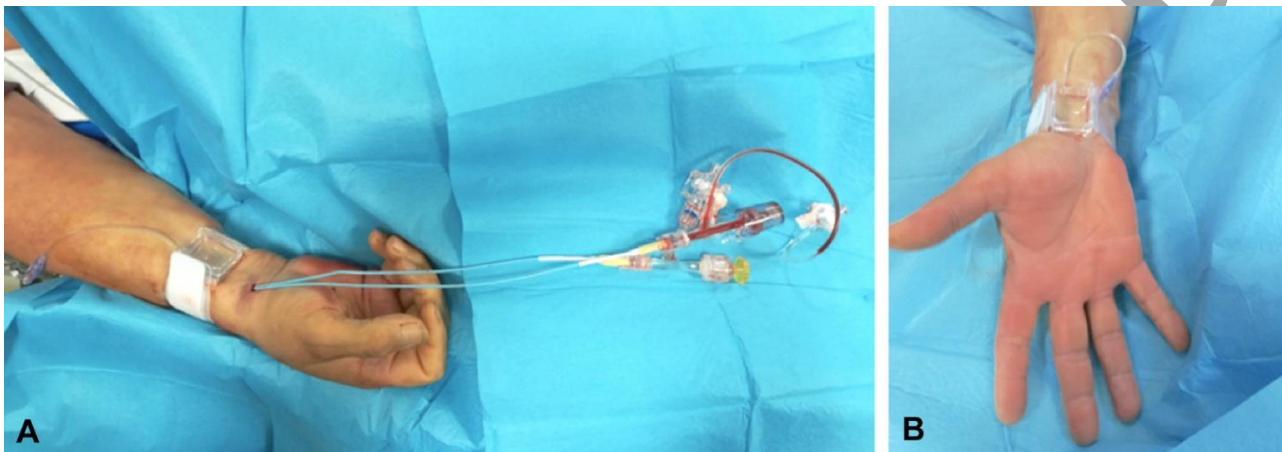


Figure 1. (A) Picture taken at the end of the procedure showing two 5-F guiding catheters inserted sheathless according to the balloon-assisted tracking technique via the same radial artery access. A radial compression device was moderately inflated proximal to the puncture site to avoid mild bleeding caused by a skin incision to allow catheter insertion. (B) The same inflation device was subsequently used to facilitate patent hemostasis.

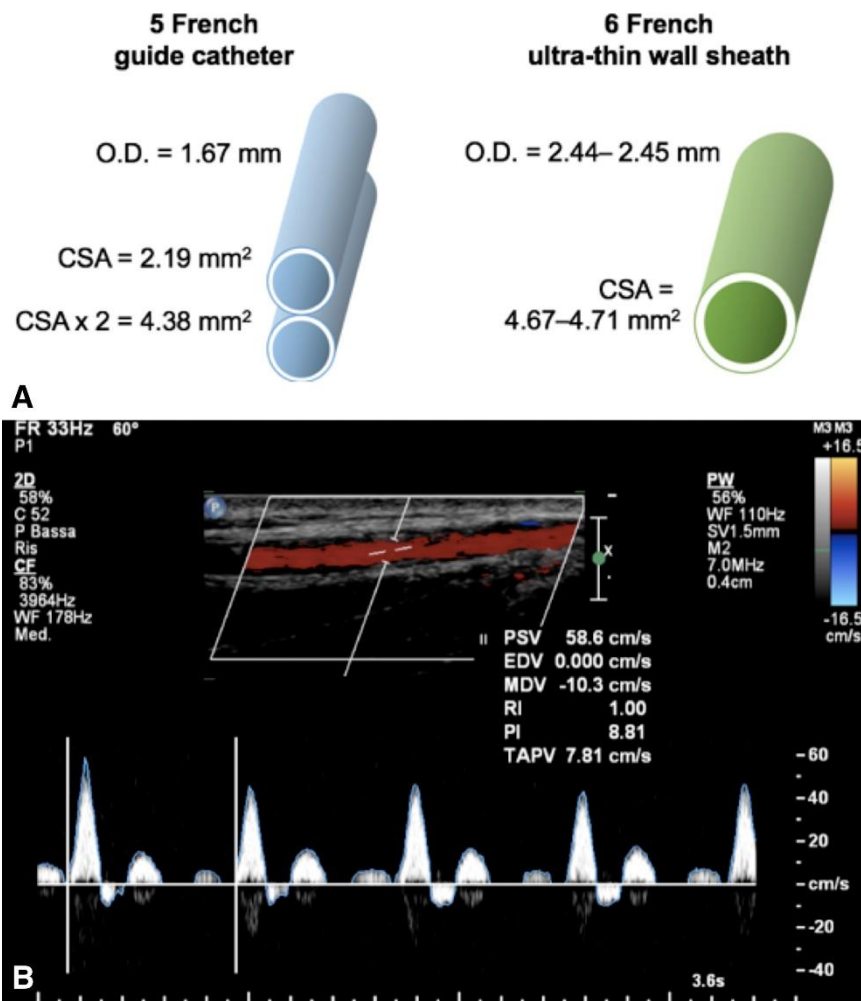


Figure 2. (A) Two 5-F guide catheters inserted per the one-point transradial two sheathless catheters insertion (OTRANTO) technique yield an overall cross-sectional area (CSA) of 4.38 mm², which is 7% to 8% less than the 4.67- to 4.71-mm² CSA of one 6-F ultra-thin-wall sheath introducer (IDeal, Prelude Medical, South Jordan, Utah; or Glidesheath Slender, Terumo, Tokyo, Japan) having the smallest outer diameter among all the 6-F sheath introducers currently available. (B) Spectral duplex scan performed the day after the procedure showing patent radial artery with physiological triphasic flow. O.D. = outer diameter.