

CLINICAL APPLICATION OF AUTOLOGOUS PLATELET RICH PLASMA (P.R.P.) IN
THE EXTRACTION OF THIRD IMPACTED MANDIBULAR MOLAR

Original

CLINICAL APPLICATION OF AUTOLOGOUS PLATELET RICH PLASMA (P.R.P.) IN THE EXTRACTION OF THIRD IMPACTED MANDIBULAR MOLAR / Mozzati, M.; Scoletta, M.; Gallarato, Iordache. - In: REVISTA ROMÂN DE STOMATOLOGIE. - ISSN 1843-0805. - ELETTRONICO. - LIII:2(2007), pp. 81-88.

Availability:

This version is available at: 11583/2683470 since: 2017-09-29T13:32:30Z

Publisher:

Editura Medicala Amaltea, Bucuresti

Published

DOI:

Terms of use:

openAccess

This article is made available under terms and conditions as specified in the corresponding bibliographic description in the repository

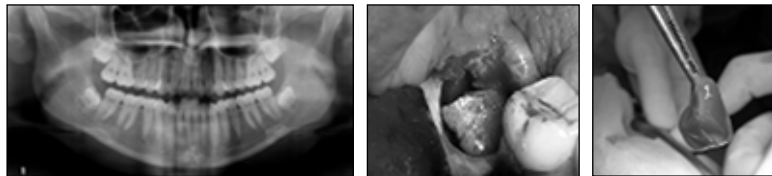
Publisher copyright

(Article begins on next page)

CLINICAL APPLICATION OF AUTOLOGOUS PLATELET RICH PLASMA (P.R.P.) IN THE EXTRACTION OF THIRD IMPACTED MANDIBULAR MOLAR

Mozzati M M.D,D.D.S¹, Scoletta M D.D.S.¹, Gallarato I D.D.S²

¹director department of Oral Surgery University of Torino, private practice in Torino
²private practice in Torino



ABSTRACT

The impacted third molar surgery has various limits; one of these limit is the type of surgery applied, often demolitive for the patients with long term consequences in the post-op period. Aim of our study is to get a better healing of soft and hard tissues with the applications of PRP in this type of surgery. 5 patients were included in the study with these requests: the impacted or semi impacted third molar were on both side; the acceptance of PRP technique on one side (considered as the case) the extraction of the other impacted molar as the control side to our case; both teeth were extracted on the same day, both sockets were closed by hermetically suturing the flap; on one socket it has been inserted the platelet gel on the other side nothing. Pre operative measurements were: 1. probing depth of both the seventh (3.7-4.7); 2. ortopantomography (OPT). Post operative measurements included: 1. probing depth two months after surgery; 2. OPT at one week, one month, two month.

One week after surgery patients were asked about the post-op through a questionnaire on the course of the week, in specific they were asked to assess a score from one to three on swelling and pain of the two side. One week after a clinician who was out of the study (not the surgeon) evaluated the eventual bacterial sovrafections, the dehiscence of the flaps, the eventual collateral effects given by the application of PRP giving a score from one to three to the type of healing. Periodontal healing was evaluated on both side after 2 months after surgery in all the cases treated the initial P.D. was 2-3mm on both sides. It showed an improvement in the sites treated with P.R.P. Swelling (perceived by the patients during the course of the first week) was not reduced by the application of PRP gel, while there has been a reduction in the pain in comparison with the control side referred by the patients. Clinical evaluation realized a week after the extractions showed a better healing on the PRP side vs the control side (total score 12 vs 8) where three patients from five realized a primary closure with no bacterial sovrafection or dehiscence of the flap vs one primary closure on the control side. Bone healing measured by digital OPT did not show a real improvement on PRP side after two months in the cases analyzed.

Key words: third molar surgery, PRP gel, bacterial sovrafections, periodontal healing.

REZUMAT

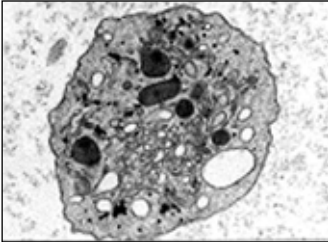
Chirurgia molarului 3 inclus are stabilite anumite reguli, una dintre aceste limite ține de tipul de operație ales, tehnici ce pot avea repercusiuni pe termen lung asupra molarului, în special în perioada postoperatorie. Scopul acestui studiu este obținerea unei vindecări mai bune la nivelul țesuturilor moi și dure prin utilizarea PRP-ului în cadrul acestei operații. Cei 5 pacienți incluși în studiu trebuiau să îndeplinească anumite cerințe: molarii incluși sau semiincluși bilateral; acceptul pacientului pentru utilizarea tehnicii PRP pentru unul dintre molari (acesta fiind considerat studiu de caz) și extracția celui alt molar inclus pentru controlul rezultatelor obținute în studiul nostru; ambii dinți au fost extrași în aceeași ședință și ambele alveole au fost închise prin sutură; într-o alveolă a fost inclus gel PRP, iar pe partea cealaltă nu s-a folosit nimic. Preoperator s-au realizat: 1. verificarea adâncimii la care se găsesc molarii(37, 47); 2. ortopantomografie. Măsurile postoperatorii au inclus: 1. controlul alveolei la 2 luni după operație; 2. ortopantomografie la o săptămână, o lună, 2 luni.

La o săptămână după operație, pacienților li s-au adresat o serie de întrebări în cadrul unui chestionar în care li s-a cerut să evalueze pe o scară de la 1 la 3 gradul inflamației și durerea postoperatorie pentru fiecare parte. Tot la o săptămână, un medic care nu a participat la studiu a evaluat eventuala suprainfecție bacteriană, apariția unor dehiscente și eventuale reacții adverse apărute datorită utilizării PRP-ului, notând pe o scară de la 1 la 3 tipul vindecării. Vindecare parodontală a fost analizată la 2 luni după intervenții pe ambele părți, evaluare ce a evidențiat o îmbunătățire pe părțile care au fost tratate cu PRP. Inflamația nu a fost diminuată prin utilizarea gelului PRP, deși s-a observat o diminuare a durerii. Evaluarea clinică realizată la o săptămână după extracții a evidențiat o vindecare superioară pe partea pe care s-a aplicat PRP comparativ cu partea folosită ca etalon, unde la 3 din cei 5 pacienți s-a obținut o bună închidere a alveolei cu lipsa suprainfecției bacteriene și a dehiscentei versus 1 caz în care s-a obținut o închidere bună pe partea de control. Vindecarea osoasă analizată cu OPT digital la 2 luni nu a evidențiat o îmbunătățire reală prin utilizarea gelului PRP.

Cuvinte cheie: chirurgia molarului 3, gel PRP, suprainfecție bacteriană, vindecare parodontală.

INTRODUCTION

Platelet concentrate is defined as a volume of peripheral blood with a platelet concentration superior to the basal concentration. Here we can see a platelet



Here we can see a platelet

In Stomatology there have been invented 3 types of platelet concentration:

- PRP (PLATELET RICH PLASMA, Marx 1993)
- PRGF (PLATELET RICH IN GROWTH FACTORS, Anitua 1999)
- PRF (PLATELET RICH IN FIBRIN, Couckroun 2004)

– here we can see the centrifuge used in our study*



*Courtesy of Emodinamic Department San Giovanni Hospital, Torino

These techniques differ for many biological and clinical features, such as the type of Centrifuge used, the speed (rpm), the type of platelet anti-aggregant.

In this type of study we decided to follow PRP's technique for its daily application in dermatology (treatment of diabetic ulcers) and ortopedic (treatment of multiple bone fractures and osseous Kystes).

In litterature it has never been declared any colleteral effect to the application of PRP gel, it can not induce any GVHD (graft versus host disease) since it rappresent an autologous source of growth factors.

Aim of the study was to evaluate the effect of the PRP gel and its growth factors without the cooperation of osteocunductive material that's the reason why PRP was inserted in the post-extraction socket without the application of other graft material such as DFDBA or hidroxyapatite.

PRP is obtained through two blood centrifugation at 2400 rpm (following the Marx' metod invented in 1993) with this double centrifugation it is possible to get a platelet concentration 10 times higher than the peripheral blood.

Through these centrifugation it is possile to get 3 blood fractions:

1. Platelet rich plasma (PRP)
2. Platelet poor plasma (PPP)
3. Platelet rich in red cells (RBC)

Once obtained and activeted P.R.P. intervenes through the first phases in hemostasis when the degranulation of the platelets'alpha granules realise important factors for bone healing and for soft tissue healing.

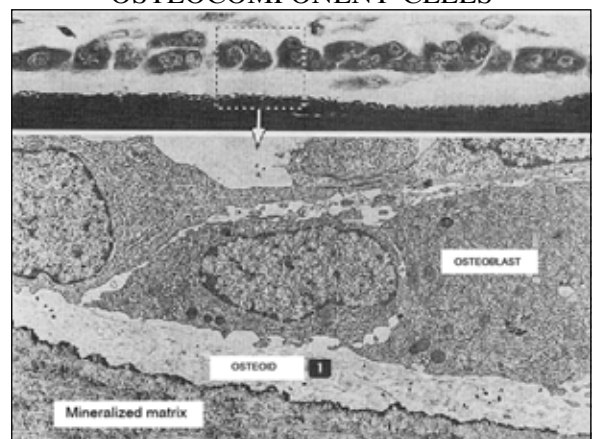
In the post-extraction socket platelets get in touch with some important activators such as:

ADP which is freed from the endothelium lesion.

TROMBIN which is generated in the vacular site physiologically due to the hemostatic process COLLAGEN FIBERS shown naked due to surgical lesion.

In all the bone regenerative process it is possible to identify a triangle, at the apex there are the osteocomponets cell such as osteoblasts, at the base there is on one side the matrix and on the other soluble proteins.

OSTEOCOMPONENT CELLS



MATRIX

SOLUBLE PROTEINS

OSTEOCOMPONENTS CELLS are responsible for the osteogenetic process.

MATRIX in the post-extraction socket is represented by autologous fibrin which has a key role in the bone healing process since it is the scaffold through which the fibroblasts first and osteoblasts later on produce OSTEOID TISSUE .

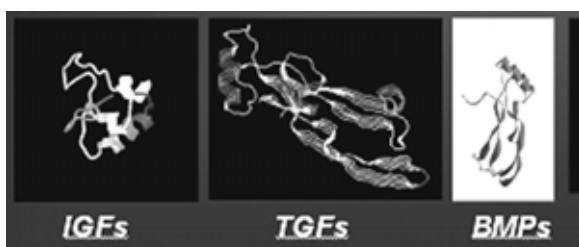
SOLUBLE PROTEINS are Growth Factors (GF's) and BMP's.

Physiologically platelets realise gf's during degranulation, thanks to a higher concentration in platelets in P.R.P it is possible to have ten times higher the percentage of GF'S as well. The more important growth factors identified in this process are:

1. PDGF (platelet derived growth factor)
2. TGF-beta1 (transforming growth factor beta1)
3. TGF-beta 2 (transforming growth factor beta2)
4. IGF1 (insulin like growth factor)
 - PDGF is involved in the wound healing procedures for its effects on mitosis, angiogenesis, realising of other growth factors.
 - TGF-beta 1 and TGF-beta2 stimulate chemiotaxis and mitogenesis of the osteoblasts'precursors and they are responsible for the osteoclasts' inhibition.
 - ILGF has a role in the activation of the osteoblasts'precursors and the activation of the endostium osteoblasts responsible for the deposition of bone in the initial phases of bone regeneration.

Here we can see the most important growth factors realized by the platelets.

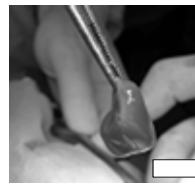
In this image we can see BMP's as well which are now considered the other main alternative in bone healing vs the use of GF's



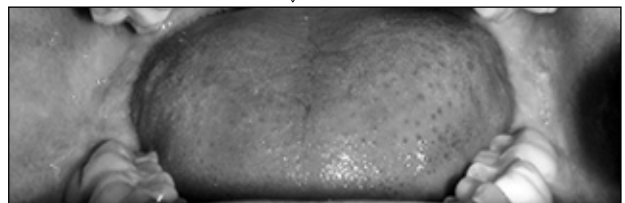
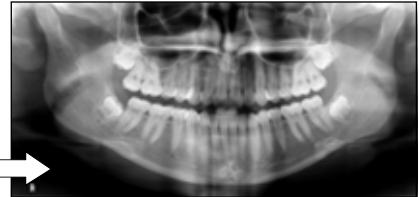
MATERIALS AND METOD

5 patients were included in the study, panoramic radiographs were taken before surgery, probing depth distal to 4.7 and 3.7.

PRP CASE



CONTROL CASE



Inclusion criteria for the study were:

1. totally or partially bone-impacted mandibular third molar on both mandibular side.
2. No systemic disease and good general health,
3. FMBS<20%,
4. age below 30 years,
5. cooperation with the study and with post-operative follow up,
6. the patients had to accept the PRP technique on one side,
7. the patients were not informed on which side PRP was inserted.
8. One week before surgery they had to go to the blood bank in San Giovanni Battista Hospital Torino where they were taken an amount of 150cc of peripheral blood.
9. A digital Opt was taken a week later, a month, two month later.
10. PD was taken 2 months later as well.

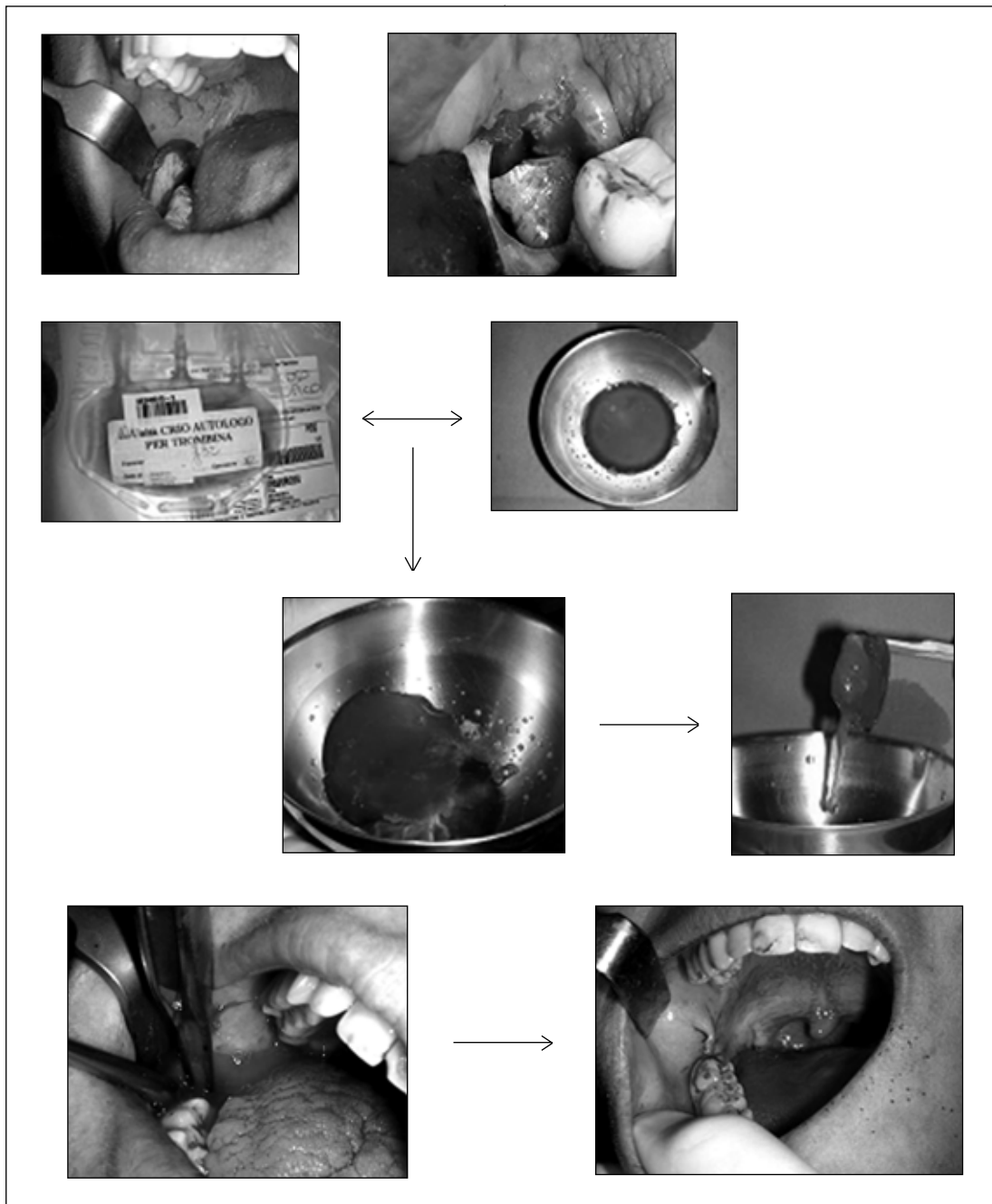
In the early day from the emodinamic department the P.R.P. centrifuge prepared the two main components (autologous fibrin and P.R.P).

First they centrifugated the patients' blood: PRP and autologous trombine were prevailed after centrifugation.

Before surgery patients rinsed with 0.12% cloroxidine for 1 min; they were not given pre-operative antimicrobica, or others drugs that might influence healing.

Loco-regional anesthesia was applied by blocking the inferior alveolar nerve together with vestibular infiltration of mepivacaine hydrochloride plus adrenaline, 1:100,000.

The surgeon started from P.R.P side with a full – thickness incision and the opening of the flap



The tooth crown was sectioned with a tungsten carbide burr.

After completing the extraction, curettage of the socket was performed plus irrigation with 20 ml sterile saline solution. Then the PRP was activated.

The gel was produced after extraction mixing the platelet concentrate (10cc) with autologous trombone (1-1.5cc) (taken from the RBC's fraction) then activated with calcium gluconate (0.8cc) in a no-eparined becker. Finally inserted in the post- extraction socket, the flap was repositioned and sutured. (ethicon3-0)

The procedure kept going on the other side in the end without inserting PRP in the post-extrac-

tion socket. The same post-operative instruction were given for both sides.

EVALUATION CRITERIA

One week later patients entered the degree of pain and swelling on the record, day by day, from one to three, answering a questionnaire based on a personal evaluation.

Patients did not know on which side PRP was inserted. Here we can see the questionnaire showed to the patients.

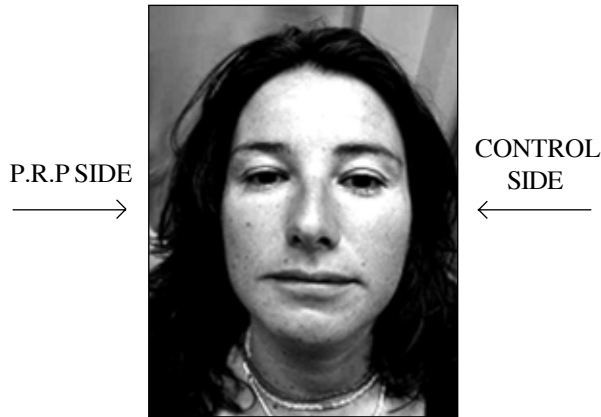
On the same day a clinician not involved in the study gave an evaluation from zero to three on the type of wound healing observed one week

later. The clinician assessed a score to the soft tissue healing from one to three.

Zero corresponded to post-extraction alveolitis, one to initial healing, two to secondary closure, three to primary closure of the flap.

On the same day an OPT was taken in order to see the two post-extraction sockets.

Two months later patients were called for making the OPT and the PD proof.



Here it is possible to see the questionnaire given to the patients. They were asked to give a score from one to three to the type of swelling and pain that they referred during the course of the first post-op week.

The last line which represents the wound healing is reserved to the clinician who has to assess a score from zero to three when the patients come back for cutting off the sutures a week after surgery.

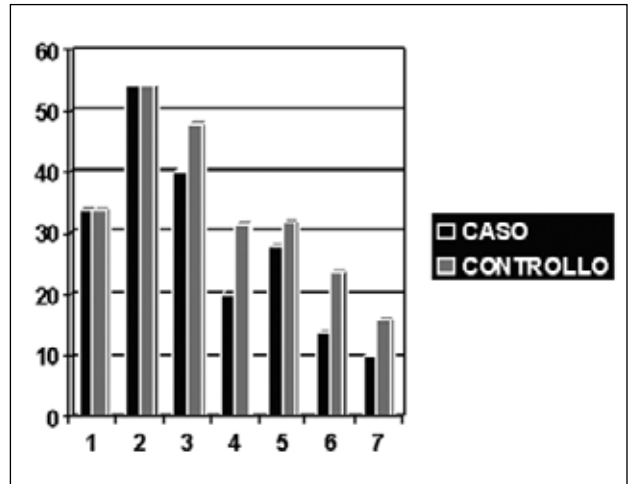
Patient' name				Surgery date:			
CASE	1DAY	2	3	4	5	6	7
SWELLING							
PAIN							
WOUND HEALING							
CONTROLL							
SWELLING							
PAIN							
WOUND HEALING							

Results of the questionnaire

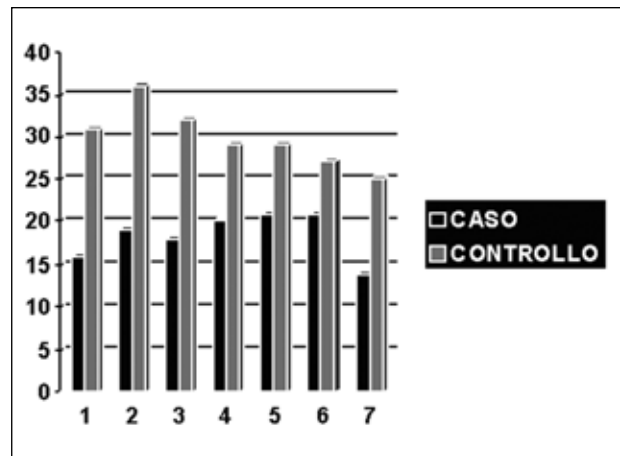
Here it is possible to observe the results, we can see them organized day by day.

	SWELLING CASE PRP	SWELLING CONTROLL
1G	12	14
2G	12	12
3G	10	12
4G	9	10
5G	7	10
6G	4	5
7G	0	0

Here shown in percentage



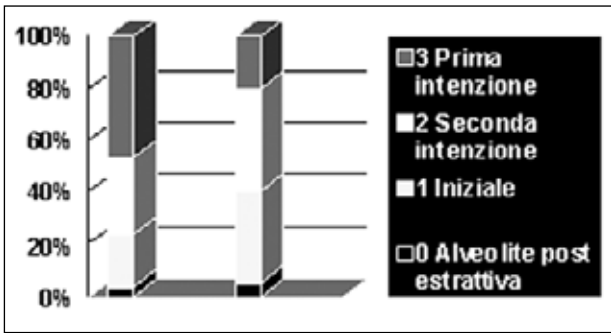
	PAIN CASE	PAIN CONTROLL
1G	6	15
2G	5	14
3G	5	14
4G	4	8
5G	5	4
6G	3	8
7G	0	4



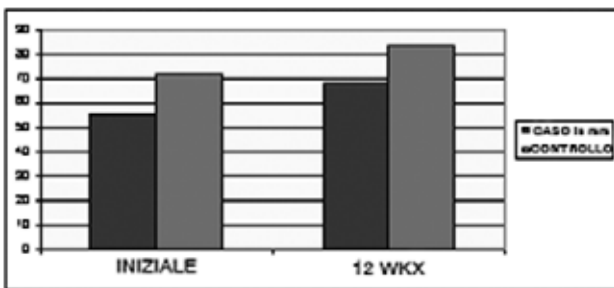
Then we can see the results in wound healing: a score from one to three was given to type of healing found a week after surgery.

- 0 corresponded to post-extraction aveolitis
- 1 corresponded to initial healing
- 2 corresponded to a second type healing with granulation tissue still found in site
- 3 corresponded to a primary closure of the flap with no granulation tissue and perfect scar tissue with an overlapping flap

	Case	controll
1 week after	12	8



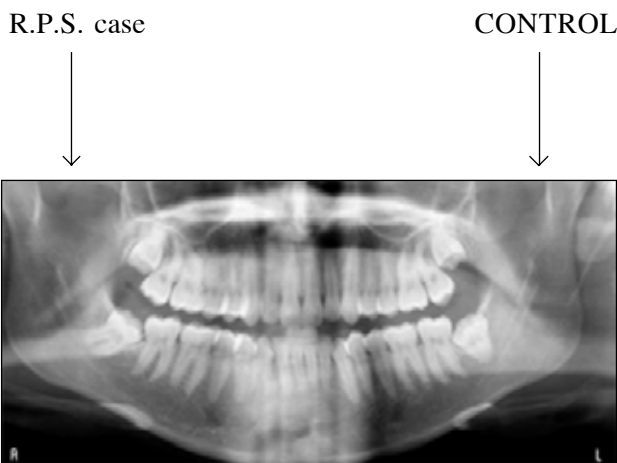
The periodontal healing after 2 months, in the 5 case treated we had a good periodontal health P.D. was 3-2mm in both sides. Summing up the total P.D. on both sides we could see the difference two months later on.



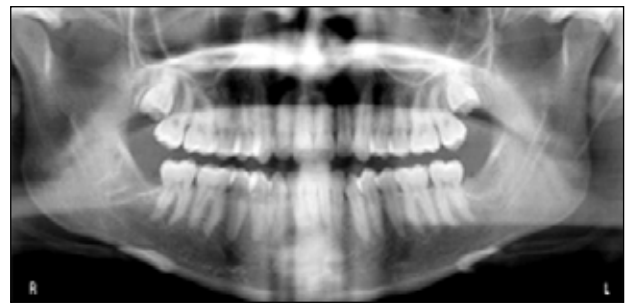
PD	P.D. P.R.P CASE in mm	CONTROL
initial	17	16
2months	23	27

Results: opt

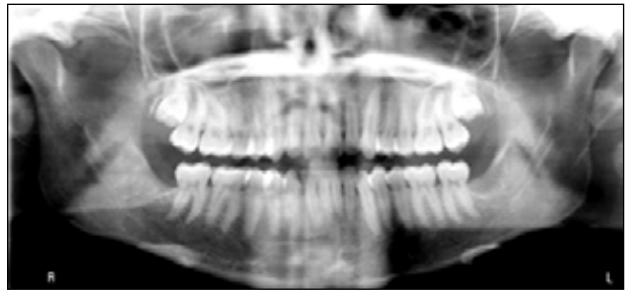Then we can see a case from a radiographic point of view, before extraction, a week later, a month later, two months later. On the right side we can see the side where P.R.P gel has been inserted while on the other side we can see the control side.



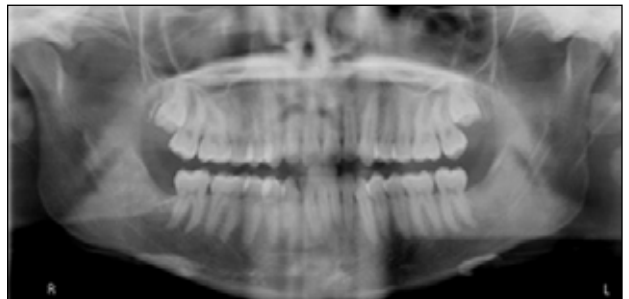
A week after we can see the post-extraction socket and on the other side the control area



A month after surgery it is possible to evaluate the bone healing in both sides



Two months after surgery we can see the mature healing in both sides which is completely equal in P.R.P. case as well as in the control side.



DISCUSSION

According to what has been found in litterature, P.R.P has got an important role in all the wound healing process, since it realises important factors such as I.G.F and P.D.G.F.

That is the reason why nowadays it is used in the treatment of diabetic ulcers (all the recent works published on P.R.P. belong to dermatologic literature) and in oftalmology.

In stomatology we experienced how it does not really work in reducing swelling which is comparable in both sides.

In the case we followed P.R.R reduces the pain referred by the patients but this is particulary due to the fact that P.R.P. has a key role in the soft tissue regeneration.

This allows a reduction in the percentage of prostaglandines such as PG2 probably the main responsible in the pain perceived by the patients.

A week after extraction the post-extraction socket has a better healing with no case of post-extraction alveolitis while on the other side apart a post-extraction alveolitis we experienced a greater percentage in second intention wound healing.

The better condition in wound healing can be also experienced in a better periodontal healing.

In all the 5 cases treated we started from a good periodontal situation where the P.D measured distally to 4.7 and 3.7 were physiological (2-3 mm). Summing up the total P.D. in P.R.P case as in the control case we can see a better periodontal healing which is 1.32 mm lower in P.R.P case respect to the control side. This means that in two months there has been a reduction in P.D in the cases treated with PRP gel.

We can not experience a better bone healing regeneration, this is also due to the fact that no allograft material has been inserted in the post-extraction socket.

CONCLUSIONS

Since we do not have a huge numbers of cases we can not affirm that our work offers answers to the use of P.R.P in Stomatology.

From our experience we may affirm that P.R.P. can be considered an alternative method in obtaining a better wound healing process.

It is anyway a quite invasive method which can not be applied daily in private practice.

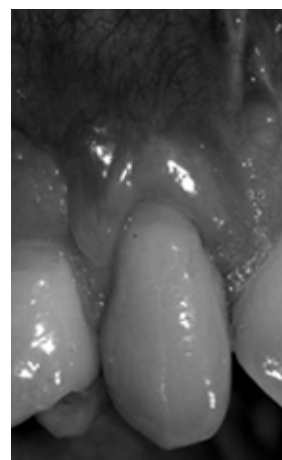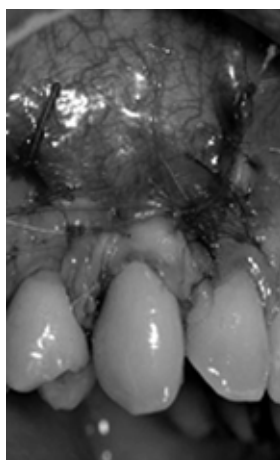
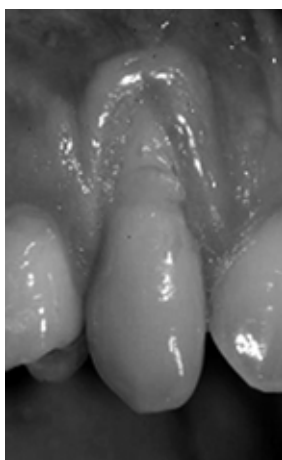
It can be a good alternative for obtaining a better periodontal healing where the condition in the impacted third molars quite surely may cause a damage distally to the seventh (4.7-3.7)

In the case that has been treated we can not affirm that P.R.P can really make the difference in bone regeneration (GBR), in litterature we did not find any works where this type of platelet gel was applied alone, in these works P.R.P has always been melted with some allograft material such as hydroxiapatite or other autogenous source of bone.

Allograft material or other source of bone may represent the osteoconductive support to the GF's (Growth Factors) realised by P.R.P GEL, without that support the Gf's alone realised during the platelet degranulation may loose part of their bone regeneration potentialities.

After all these consideration we may affirm how P.R.P can have a key role in the wound healing optimum, in stomatology this type of healing is searched especially in the periodontal regeneration in extremely complex cases such as recessions in frontal areas.

Thanks to dr Abundo for the case shown with the use of tissucol glue (as source of GF's)in periodontal healing in a frontal extremely complex case.



REFERENCES

1. Marx RE, Garg AK. – Bone structure, metabolism and physiology: its impact on dental implantology. *Implant Dent* 1998 ;7(4) :267-76
2. Marx RE, Carlson ER, Eichstaedt RM, et al. – Platelet-rich plasma: Growth factor enhancement for bone grafts. *Oral Surg Oral Med Oral Pathol Endod* 1998 Jun; 85(6):63846.
3. Marx RE. – Platelet-rich plasma: a source of multiple autologous growth factors for bone grafts. *Quintessence* 1999; Chicago.
4. Anitua E. – Plasma rich in growth factors: preliminary results of use in the preparation of future sites for implants. *Int J Oral Maxillofac Implants* 1999. Tul -Aug; 14(4):529-35
5. Sacchi MC, Bellanda M, Vercellotti T. – Il concentrato piastrinico in chirurgia orale e implantare. *Il Dentista Moderno*, Gennaio 2000.
6. La Banca L., Facco G., Gariglio W., Mattiazzo L., Lajolo di Cossano D., Massaro A.L. – Concentrato di piastrine autologo per uso topico in chirurgia orale e maxillo-faciale: iniziale esperienza del dipartimento 14 servizio trasfusionale AVIS di Torino. *Atti del XXXIV Convegno Nazionale di Studi di Medicina Trasfusionale*; Rimini 2000: s148.

7. **Eppley et Al.** – Platelet quantification and growth factor analysis from platelet rich plasma: implications for wound healing. *Plastic Reconstruction Surgery* 2004 Nov; 114(6) :1502-8).
8. **Sammartino et Al.** – Use of autologous Platelet-Rich Plasma (PRP) in periodontal defect treatment after extraction of impacted mandibular third molars).
9. **Huang L.H. et Al.** – The effect of platelet – rich plasma on the coronally advanced flap root coverage procedure: a human pilot trial.
10. **Ferreira et Al.** – Effect of mechanical treatment on healing after third molar extraction. *Int. J. Periodontics Restorative Dent.*
11. **Kughelberg et Al.** – The influence of anatomical,pathophysiological and other factors on periodontal healing after impacted third molar surgery. A multiple regression analysis. *Journal Clinic of periodontology* 1991 Jan;18(1):37-43.
12. **Anitua** – “A new approach to bone regeneration”, Plasma Rich in Growth Factors.
13. **Simon D et Al** – Potential for osseous regeneration of platelet- rich plasma-a comparative study in mandibular third molar sockets. *Indian J Dent Res* 2004 Oct-Dec.
14. **Carlson NE, Roach RB Jr** – Platelet rich plasma: clinical application in dentistry. *J Am Assoc* 2002 Oct.
15. **Tischler M** – platelet rich plasma. The use of autologous growth factors to enhance bone and soft tissue grafts. *N Y State Dent J*, 2002 Mar
16. **Everts PA et AL** – Platelet rich plasma and platelet el: a review; *J Extra Corpor Technol.* 2006 Jun
17. **Dohan DM. Choukroun J. Diss A. Dohan SL. Dohan AJ. Mouhyi J. Gogly B.** – Platelet-rich fibrin (PRF): a second-generation platelet concentrate. Part I: technological concepts and evolution. *Oral Surgery Oral Medicine Oral Pathology Oral Radiology & Endodontics.* 101(3):e37-44, 2006 Mar