

REHABILITATION OF AMELOGENESIS IMPERFECTA AND VDO REDUCTION WITH DISILICATE VENEERS AND OVER- LAYS: A CASE REPORT.

Original

REHABILITATION OF AMELOGENESIS IMPERFECTA AND VDO REDUCTION WITH DISILICATE VENEERS AND OVER- LAYS: A CASE REPORT / Gallarato, I., Campanella, F., Bellia, E., Audenino, G., Carossa, S.. - In: "Viata Stomatologica" nr.2 Iulie 2015. - STAMPA. - Revista "Viata Stomatologica" nr.2 Iulie 2015:Revista "Viata Stomatologica" nr.2 Iulie 2015(2015), pp. 13-18.

Availability:

This version is available at: 11583/2683462 since: 2017-09-29T12:20:54Z

Publisher:

ISUU

Published

DOI:

Terms of use:

This article is made available under terms and conditions as specified in the corresponding bibliographic description in the repository

Publisher copyright

(Article begins on next page)

REHABILITATION OF AMELOGENESIS IMPERFECTA AND VDO REDUCTION WITH DISILICATE VENEERS AND OVERLAYS: A CASE REPORT.

Gallarato I *.Campanella F., Bellia E., Audenino G., Carossa S.**

Department of surgical sciences, CIR Dental School, Prosthodontic Section, University of Turin

Abstract

Amelogenesis imperfecta(AI) is an inherited enamel dysplasia involving both dentitions with no other systemic effects.

Here it is presented a case of a hypocalcified enamel dysplasia(type III according to Wiktop classification) in a 21 year old male who was successfully treated with disilicate veneers and overlays.

Key words: amelogenesis imperfecta, dental anomalies, esthetics, full-mouth rehabilitation, tooth wear

Introduction:

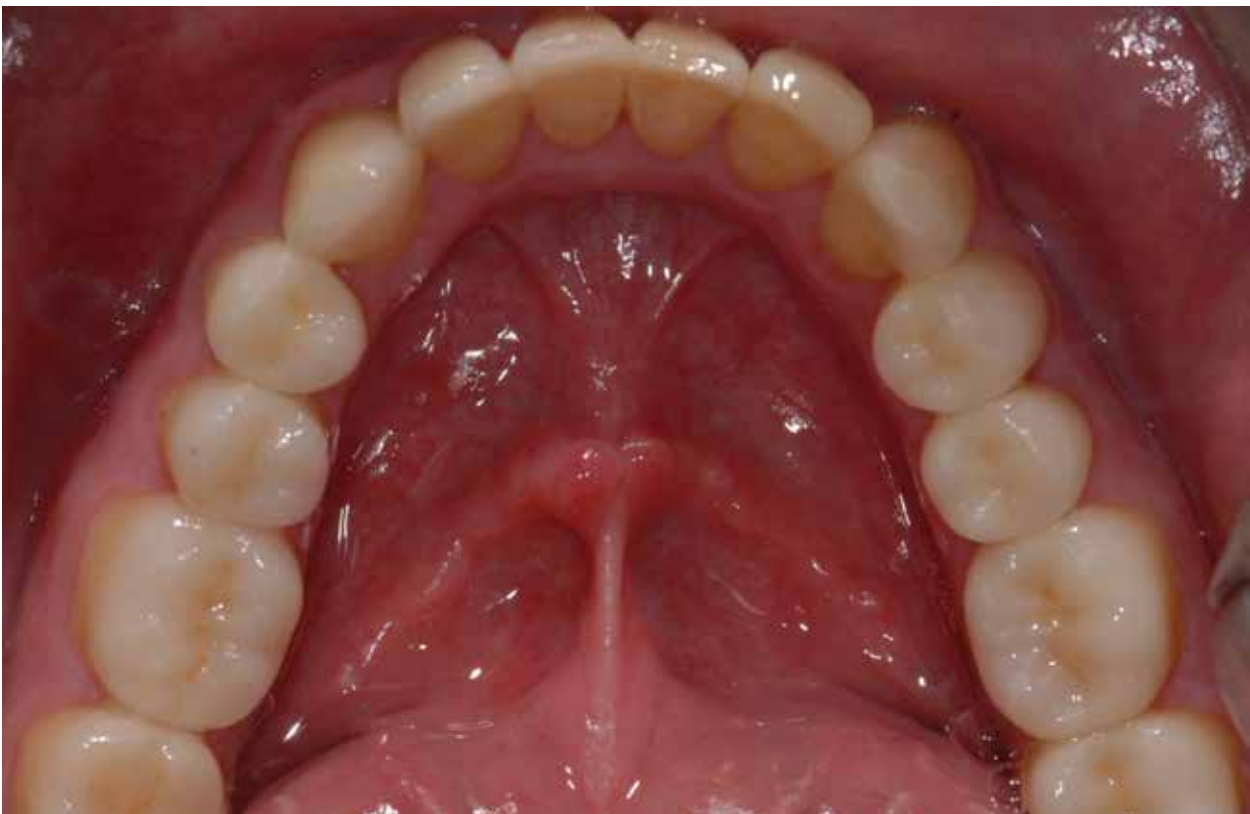Amelogenesis imperfecta (AI) is an inherited enamel dysplasia involving both dentitions with no other systemic effects. Amelogenesis imperfecta (AI) presents with a rare abnormal formation of the enamel [1] or external layer of the crown of teeth. Enamel is composed mostly of mineral that is formed and regulated by the proteins in it. Amelogenesis imperfecta is due to the malfunction of the proteins in the enamel: ameloblastin, enamelin, tuftelin and amelogenin.

People afflicted with amelogenesis im-

perfecta have teeth with abnormal color: yellow, brown or grey; this disorder can afflict any number of teeth of both dentitions. The teeth have a higher risk for dental cavities and are hypersensitive to temperature changes as well as rapid attrition, excessive calculus deposition, and gingival hyperplasia.

The ereditary pattern is autosomal or X related dominant or recessive. The prevalence of amelogenesis imperfecta varies in different populations from 1/700 in Europe to 1/14000 in United States.

According to clinical, radiological, histolo-



gical and hereditary findings, amelogenesis Imperfecta has been categorized into 4 broad groups: (1) hypoplastic(2) Hypomaturation(3) hypocalcified (4) hypomaturation and hypoplastic with taurodontism.

However at least 14 subtypes of amelogenesis imperfecta are identified when phenotype and mode of inheritance are considered. The hypoplastic form, presents quantitative deficiency of enamel matrix formation. The hypocalcified form (3) occurs as a result of inadequate primary mineralization while the hypomature form arises from a defect in pre-eruptive enamel maturation.

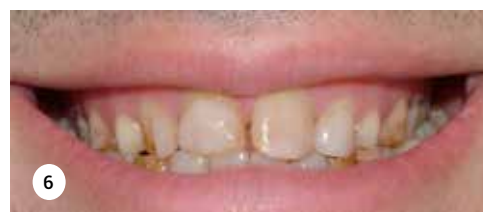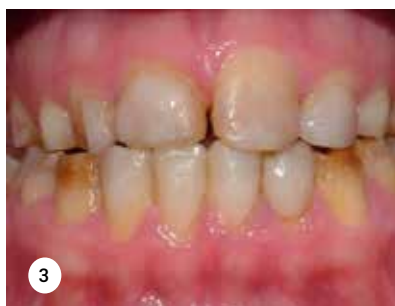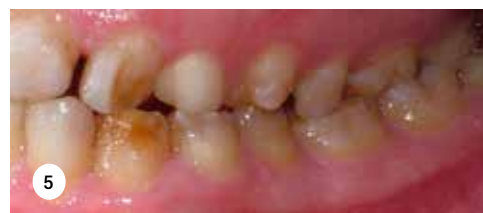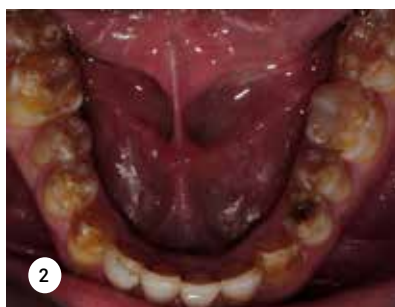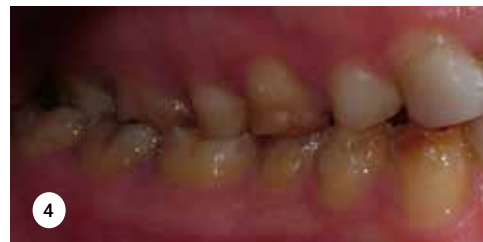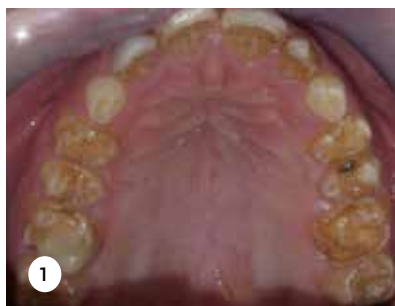Amelogenesis imperfecta include quantitative and qualitative enamel deficiencies : tooth sensibility, poor dental esthetics, pulpal calcification, multiple impacted teeth, congenitally missing teeth, hypercementosis, root malformation, taurodontism, Anterior open bite and posterior vertical deep bite .

Patients affected by amelogenesis im-

perfecta reported to have disabilities in oral function, discomfort in eating and social embarrassment all of which compromise quality of life.

Amelogenesis imperfecta is often complicated with occlusal disharmony, reduced vertical dimension and limited interocclusal clearance that require establishment of a new occlusion.

Treatment planning for amelogenesis imperfecta is dependent on various factors including patient's age and socioeconomic status, type of disorder, and severity. In addition to this a designed and executed provisionalization is vital.



Fig, 1 2,3,4,5,6 - Pre –operative intra-oral view

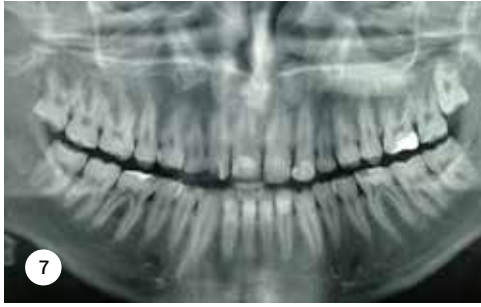

Fig 7 - Pre-operative Panorex

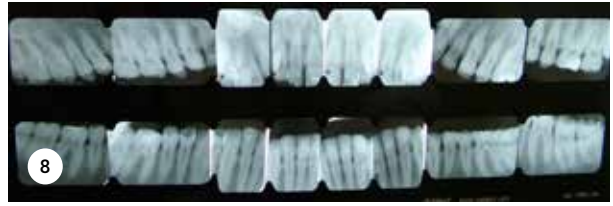

Fig 8 - Pre-operative full mouth ERSE

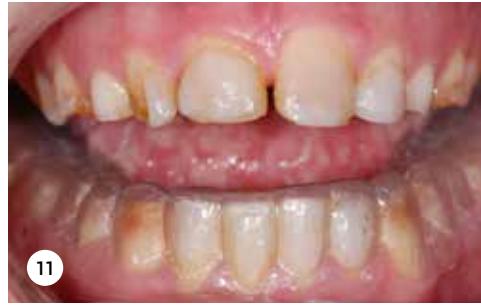
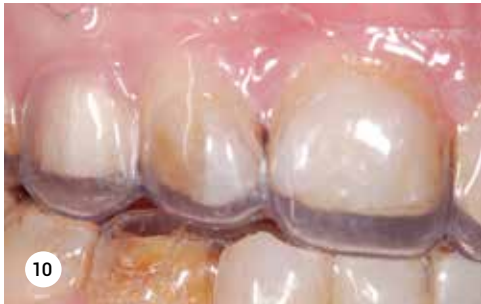
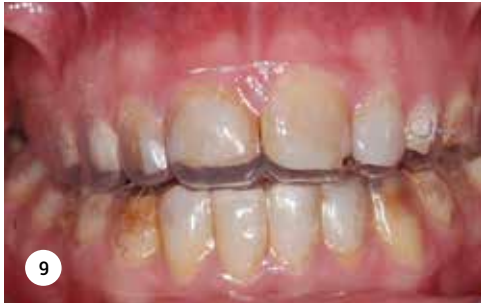Fig 9,10,11,12 - Occlusal splint based on the diagnostic wax up at the established new VDO and new VDO mounted on articulator (Panadent)

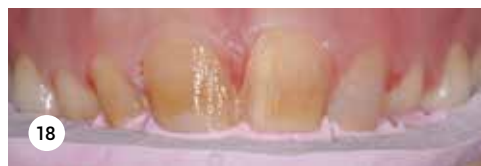
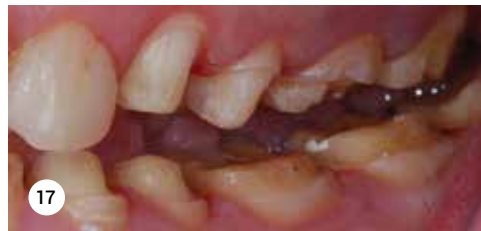
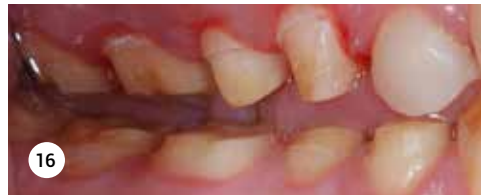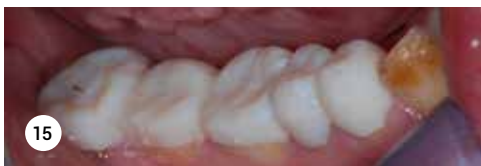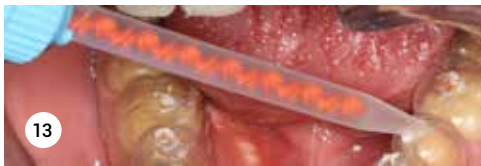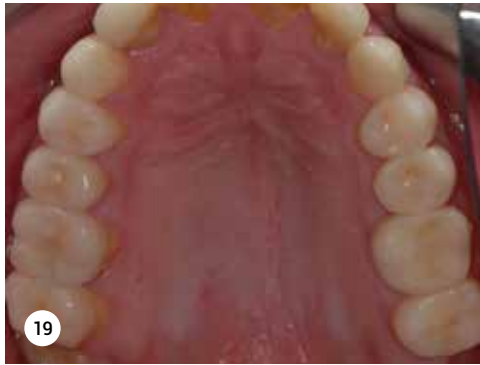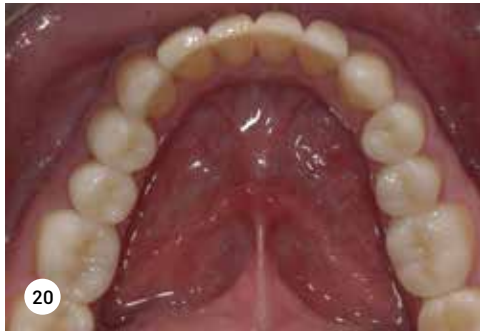Fig 13, 14,15 - Full mouth direct composite build-up with plastic template (build-up material 3EMME Pro -Temp)

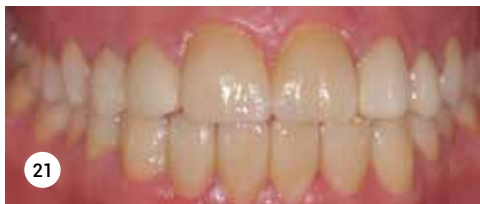Fig 16, 17, 18 - Tooth preparations for lithium disilicate veneers and overlays



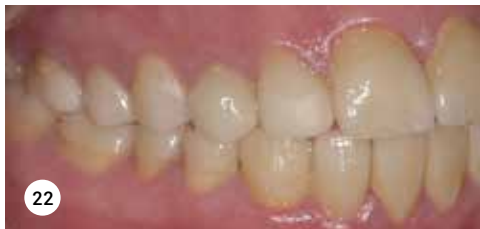19



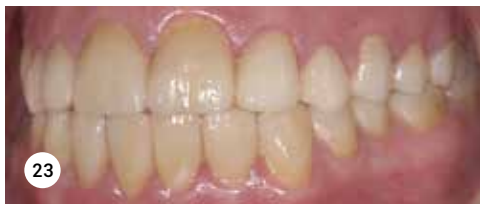20



21

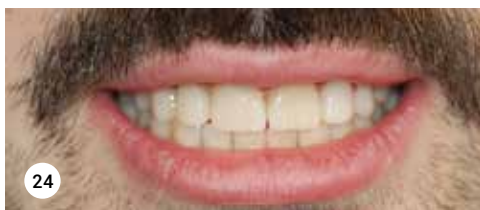

22

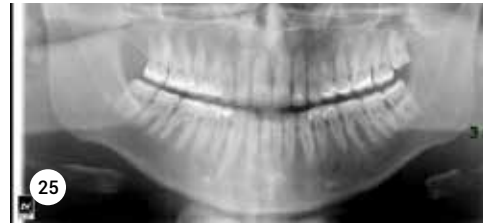


23

Fig 19, 20, 21, 22, 23 - Definitive restoration in situ , intra-oral view

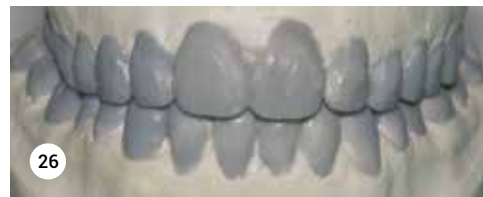

24

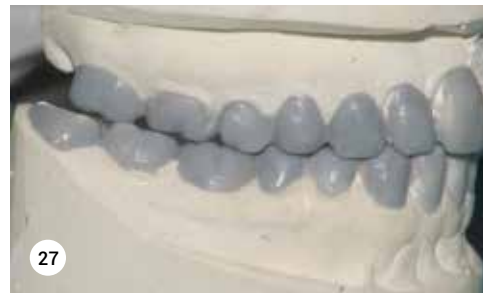

25

Fig.25 - 1 year follow up Panorex



26



27



27

CASE HISTORY

A 21 year old male referred to the Prosthodontic department of Turin Dental School after completing previous dental treatment in the Pedodontic Department.

Since early stage of primary dentition he was diagnosed with amelogenesis Imperfecta type III, following Wit kop classification.

He was dissatisfied with his poor dental appearance and concerned about this long-term condition of his own teeth, which had been discolored since his early childhood.

Family history revealed that none of his relatives suffered from amelogenesis imperfecta.

Extra oral examination revealed that the patient's face was symmetric with no lymphadenopathy and his facial height was

reduced with a freeway space of 5 mm.

Temporomandibular joints displayed normal range and path of movements. Masticatory muscles were also found to be normal.

Intraoral examination showed partial completion of permanent dentition both his upper left and upper right deciduous canines were present. Chipped enamel discoloration and generalized tooth wear were detected. (Fig.1, 2,3,4,5,6,7)

He presented dental and skeletal class III, with both upper right and left molar cross bite and anterior edge to edge open bite. His oral hygiene was insufficient.

Discoloration and generalized tooth wear were detected.

Radiographic examination showed that the enamel layer of the entire dentition was generally thin (fig 8).

The upper left and upper right permanent canine and the upper left third molar were still impacted.

Treatment goals were to alleviate pain and sensitivity prevents further tooth destruction, improve esthetics, restore occlusal vertical dimension and oral function. Before proceeding with the therapy it was decided not to follow orthodontic therapy. Moreover, enamel damage did not require root canal treatment. Therapy was carried over 1 year. The patient first received a full mouth disinfection regime, diet analysis and advices such as avoiding sweets which could develop more decays on such fragile enamel as well as oral hygiene instruction and scaling.

Patient study cast were first mounted on the articulator, then a jaw relationship record followed, using a dynamic face bow (Panadent TM- face bow and articulator). Based on this analysis a diagnostic wax up was made, on the study casts, according to the therapeutic VDO set on the articulator. A vertical repositioning bite was built according to the determined VDO and the patient wore it for two months both night and day.

Once an acceptable oral comfort zone was obtained, the patient stopped wearing the vertical repositioning bite and the therapeutic provisional phase began. Vacuum-foamed transparent matrixes were fabricated over the diagnostic wax up.

With the help of the matrixes, full mouth direct provisional (PRO-TEMP 3EMME) was performed in one clinical sitting.

A canine –guided occlusion was provided. Teeth were prepared utilizing silicone guide templates over the diagnostic wax up.

Antagonist teeth were prepared (fig 4) at the same time to allow optimization of the occlusion. All preparation margins were placed on sound enamel, while unsupported enamel was removed.

Working impressions were made by AQUASIL (DENTSPLY), a hydrophilic A-silicone impression material with bi-phase tech-

nique.

Provisional restoration was cemented using TEMP-BOND.

Tooth preparation for disilicate veneers with slight vestibular chamfer was made without violating the tooth vitality.

Reviews were arranged at 2-week interval for 2 months with some minor adjustments made to optimize occlusion and appearance. The patient showed good adaptability to the new occlusion and was satisfied with the esthetic and functional outcome.

New study casts were made from the provisionally restored dentition. Refined wax –ups were made on the casts and new templates were then fabricated for inspection.

Partial ceramic crown on posterior teeth (overlays) and veneer on anterior were made on the maxillary and mandibular teeth.

The ceramic restorations were resin-cemented under dental dam (RELYX UNICEM ULTIMATE 3EMME).

Antagonist teeth were prepared (fig 4) at the same time to allow optimization of the occlusion. All preparation margins were placed on sound enamel, while unsupported enamel was removed.

A plastic night guard was provided to protect the teeth and restorations against para-functional activity.

The patient was reviewed for 6 months follow-up sittings were scheduled once a month for six months. The patient showed good acceptance of the restorations and was pleased with the esthetics.

Oral hygiene was maintained at a high level and the gingival margin was stable with no inflammation or recession.

All teeth showed perfect periodontal situation ever since the restorations were placed.

DISCUSSION

Full mouth rehabilitation of an adult with Amelogenesis Imperfecta type 3 can be demanding. It requires good treatment planning and patient communication before proceeding with restorative therapy. Treatment choice is affected by the patient's complaint, age, severity of dental deformities, periodontal condition and orthodontic need.

It requires a treatment plan including the increase of vertical dimension in first place to provide sufficient interocclusal space and crown height.)While most patients could adapt the increase of vertical dimension, it has been reported that some patients may develop headache, muscle fatigue, sore teeth, and parafunction.

It is always helpful to evaluate patient's adaptability by providing a diagnostic provisional splint for a trial period.

Different occlusal schemes have been advocated for full mouth rehabilitation.

Posterior teeth should be loaded axially in centric occlusion, while there is no scientific

evidence that a guide is preferable to another. In the presented case canine guided occlusion could not be used because of the presence of deciduous canines, whose either orthodontic or prosthetic substitution was suggested to the patient but he denied undergoing any further surgery.

In such a way, the treatment plan decided was to leave the impacted canines in their original position, while placing veneer on both the deciduous canines even though the periodontal support was limited.

All ceramic restorations were used for biocompatibility, esthetics and improved physical properties.

It has been suggested that all-ceramic restorations bonded to tooth structures with adhesive resin cements could enhance not only the fracture resistance of the restoration or the abutment tooth but also prevent post operative sensitivity. On the other hand, some studies reveal that acid-etch bonding to amelogenesis imperfecta enamel is suboptimal compared to normal enamel. Clinical studies have shown that all-ceramic bonded restorations could be used to treat cases of extensive tooth wear, including AMELOGENESIS IMPERFECTA, successfully. In the presented case, crowns were constructed on most teeth to enhance retention thus reducing the reliance on resin cement adhesion. On the other hand, veneers were used on the maxillary and mandibular incisors to be more conservative and prevent endangering the pulp.

CONCLUSION

Full-mouth rehabilitation of amelogenesis imperfecta patients needs to be supported by a correct and extensive treatment plan. This case shows how to increase the vertical dimension with a system that verified the adaptability of the patient before any other restorative treatment.

REFERENCES

- 1) Rajpar MH, Harley K, Laing C., Davies RM, Dixon MJ. Mutation of the gene encoding the enamel-specific protein, enamelin, causes autosomal-dominant amelogenesis imperfecta. *Hum Mol Genet* 2001;10:1673-1677
- 2) Aldred MJ, Savarirayan R., Crawford P.J. Amelogenesis imperfecta: a classification and catalogue for the 21st century. *Oral Disease* 2003; 9:19-23
- 3) Backman B, Holm A.K. Amelogenesis imperfecta, Prevalence and incidence in a northern Swedish county. *Community Dent Oral Epidemiology* 1986;14
- 4) Witkop CJ Jr. Amelogenesis imperfecta, dentinogenesis imperfecta and dentin dysplasia revisited. Problems in classification. *J. Oral pathology* 1988 17: 547-553
- 5) Forteza S. Amelogenesis imperfecta. *Quintessence Int.* 1980;8-9
- 6) Collins MA, Mauriello SM, Tyndall DA, Wright

JT. Dental anomalies associated with amelogenesis imperfecta: A radiographic assessment. *Oral Med Oral Pathol Oral Radiol Endodont* 1999;358-364

7) Aldred MJ, Crawford PJM, Variable expression in amelogenesis imperfecta with taurodontism. *J Oral Pathol* 1988;17:327-333

8) Persson M, Sundell S. Facial morphology and open bite deformity in amelogenesis imperfecta. A roentgenocephalometric study. *Acta Odontol Scand* 1982; 40: 135-144

9) Coffield KD, Phillips C, Brady M, Roberts MW, Strauss RP, Wright JT. The psychological impact of developmental dental defects in people with hereditary amelogenesis imperfecta. *J AM Dent Assoc.* 2005;136:620-630.

10) Dahl BL. The face height in adult dentate humans. A discussion of physiological and prosthodontics principles illustrated through a case report. *J Oral Rehabilitation* 1995; 22:5 65-569.

11) Dahl BL, Krogstad O. Long term observations of an increased occlusal face height obtained by a combined orthodontic/prosthodontics approach. *J Oral Rehabilitation* 1985; 12: 173-176.

12) Carlsson GE, Ingervall B, Kocak G. Effect of increasing vertical dimension on the masticator system subjects with natural teeth prosthetic Dentistry 1979.41;284-289

13) Hemmings KW, Darbar UR, Vaughan S. Tooth wear treated with direct composite restorations at an increased vertical dimension. Results at 30 months. *J Prosthetic Dent* 2000, 83: 287-293

14) Dawson PE evaluation, Diagnosis and Treatment of Occlusal Problems, ed.2 Toronto: Mosby, 1989.

15) Silverman MM. Vertical dimension must not be increased. *Prosth dent* 1952;2:188-197

16) Mann AW, Pankley LD Oral rehabilitation Part I: Use of the PM instrument in treatment planning and restoring the lower posterior teeth. *J. Prosthetic Dent* 1960;10:135-150

17) Mann AW, Pankley LD. Oral rehabilitation Part II Reconstruction of the upper teeth using a functionally generated path technique. *J. prosthetic Dent.* 1960; 10 :151-162.

18) Jones SSM. The principles of obtaining occlusion in occlusal rehabilitation. *J. Prosthetic Dent* 1960;

***Dental school Torino- department of prosthodontics –PhD resident Biengeneer applied to medical science,
e-mail: iordache.gallarato@gmail.com**

****Director department of Prosthodontics,
Dental School Torino,
e-mail: Stefano.carossa@unito.it**