

Heterotopic pancreas in Meckel's diverticulum in a 7-year-old child with intussusception and recurrent gastrointestinal bleeding: Case report and literature review focusing on

Original

Heterotopic pancreas in Meckel's diverticulum in a 7-year-old child with intussusception and recurrent gastrointestinal bleeding: Case report and literature review focusing on diagnostic controversies / Guana, Riccardo; Valeria, Bucci; Giulia, Carbonaro; Alessia, Cerrina; Luisa, Ferrero; Elisabetta, Teruzzi; Alessandro, Mussa; Isabella, Morra; Jã¼rgen, Schleef. - In: AFRICAN JOURNAL OF PAEDIATRIC SURGERY. - ISSN 0189-6725. - 11:4(2014), pp. 354-358. [10.4103/0189-6725.143172]

Availability:

This version is available at: 11583/2678149 since: 2017-08-09T09:56:57Z

Publisher:

Medknow Publications

Published


DOI:10.4103/0189-6725.143172

Terms of use:

This article is made available under terms and conditions as specified in the corresponding bibliographic description in the repository

Publisher copyright

(Article begins on next page)



African Journal of Paediatric Surgery

| Volume 11 | Issue 4 | Oct-Dec 2014 |

In this issue:

- Indications and outcome of childhood preventable bowel resections in a developing country
- Renal cell carcinoma in children and adolescence: Our experience
- Dorsal inlay inner preputial graft for primary hypospadias repair
- Complicated appendicitis: Analysis of risk factors in children
- A survey of current practices in management of Hirschsprung's disease in Nigeria
- Late-presenting congenital diaphragmatic hernia
- High drain amylase and lipase values predict post-operative pancreatitis for choledochal cyst
- Spectrum of colorectal surgery operations performed in a single paediatric surgery unit in sub-Saharan Africa



Official Journal of:
Association of Paediatric Surgeons of Nigeria [APSON]
Pan-African Paediatric Surgical Association [PAPSA]



Heterotopic pancreas in Meckel's diverticulum in a 7-year-old child with intussusception and recurrent gastrointestinal bleeding: Case report and literature review focusing on diagnostic controversies

Guanà Riccardo, Bucci Valeria, Carbonaro Giulia, Cerrina Alessia, Ferrero Luisa, Teruzzi Elisabetta, Mussa Alessandro, Morra Isabella¹, Schleef Jürgen

ABSTRACT

Meckel's diverticulum, the most common congenital abnormality of the small intestine, may be associated to heterotopic pancreas, often diagnosed incidentally on histopathological examination. Intussusception affects infants between the ages of 5 and 9 months, but it may also occur in older children, teenagers and adults, and in some cases can be derived by a Meckel's diverticulum resulting in acute abdomen. We analyse the management and the recent literature on similar cases, describing diagnostic options. In May 2013, a 7-year-old girl admitted to our hospital with recurrent gastrointestinal bleeding, was discovered to have an ileoileal intussusception with a leading Meckel's diverticulum with heterotopic pancreatic tissue. This association is rare evidence in children and its proper management can be controversial, in particular from a diagnostic point of view. In such cases, preoperative radiological diagnosis can be only suspected in the presence of suggestive signs, more often depicted by ultrasound or computed tomography scan. During laparotomy an accurate exploration of all ileum is recommended, for the possibility to find others heterotopic segments.

Key words: Children, heterotopic pancreas, intussusception, Meckel's diverticulum

INTRODUCTION

Meckel's diverticulum is a blind-ending true diverticulum that contains all of the layers normally found in the ileum.

Department of Pediatrics, Turin University, ¹Department of Anatomical and Cellular Pathology, Regina Margherita Children's Hospital, Turin, Italy

Address for correspondence:

Dr. Guanà Riccardo,
Department of Pediatric General Surgery,
Regina Margherita Children's Hospital, Turin, Italy.
E-mail: riccardoguan@gmail.com

Usually, it occurs on the antimesenteric border of the ileum, 40-60 cm proximal to the ileocecal valve.

The prevalence of Meckel's diverticulum is reported to be approximate 2% of the population and males are as much as 3-4 times more prone to complications than females.

The classic presentation in children is considered as painless rectal bleeding in a toddler younger than 2 years.^[1]

Complications are the result of obstruction, ectopic tissue, or inflammation.

Peptic ulceration of the diverticulum or adjacent mucosa, due to ectopic gastric mucosa, can lead to painless bleeding, perforation, or both.

Usually heterotopic gastric mucosa is found in 62% of cases, pancreatic tissue in 6%, both pancreatic tissue and gastric mucosa in 5%, jejunal mucosa in 2%, Brunner tissue in 2% and both gastric and duodenal mucosa in 2%.^[2]

Rarely, colonic, rectal, endometrial, and hepatobiliary tissues have been noted.

The preoperative imaging studies (ultrasonography, endoscopic ultrasonography, computerised tomography [CT], and Meckel scan) are nonspecific on detecting a complicated Meckel's diverticulum, so quite often the diagnosis is made on clinical suspicion or due to the abdominal complications that a Meckel's diverticulum can produce.^[3]

For example, in older children, intussusception is more likely to be related to underlying pathology, like Meckel's diverticulum.

Intussusception is an abdominal emergency, which can present in all ages but is the most common reason for small bowel obstruction in childhood.

It is a cause of abdominal pain, vomiting, and bloody diarrhoea in infancy but often not considered when evaluating the older child with similar symptoms.

However, consideration of this diagnosis is important, as more than 1/3 of cases present beyond the age of 7.

CASE REPORT

A 7-year-old girl was hospitalised on May 2013 for episodic, intermittent cramping abdominal pain in suspected ileo-colic intussusception.

At patient's history resulted that from 1 month she suffered from recurrent abdominal pain worsened by eating, and weight loss (−2 kg), after an acute episode of gastroenteritis (fever and vomiting).

Two accesses to Emergency Department of another Hospital were reported, for evaluation with subsequent discharge.

At the same time, in the last 3 days, haematochezia and “red currant jelly” stool were reported.

Initially hospitalized in the Gastroenterology Service in the suspicious of Crohn disease, at intestinal ultrasound a long and voluminous ileoileal intussusception associated to sudden abdominal pain was noticed.

The patient was transferred to our Service of Surgery and was submitted to urgent laparotomy through a right transverse abdominal incision.

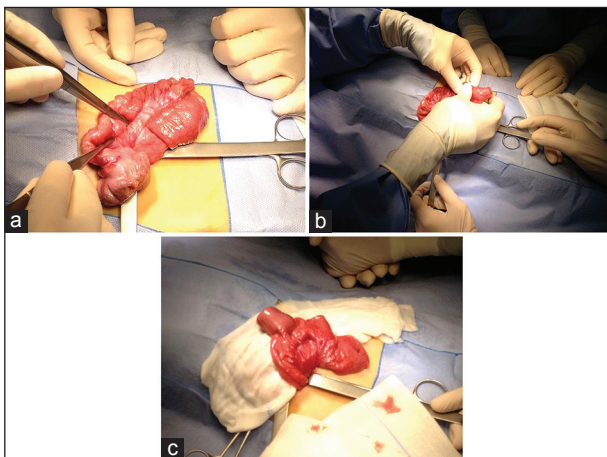


Figure 1: Evidence at surgery. (a) Ileoileal intussusception. (b) Manual reduction. (c) Intussuscepted Meckel's diverticulum

A long tract of ileoileal intussusception was observed, starting about 20 cm from the ileocaecal valve above a Meckel's diverticulum; manual reduction of the intussuscepted ileum was practiced and diverticulum resection through GIA 60 Stapler™ [Figure 1].

The resected diverticulum was sent for histological evaluation.

Postoperative days were uneventful.

One week later the child was discharged and remained asymptomatic postoperatively.

At the histopathological evaluation, the Heinrich classification system was used to classify heterotopic pancreas and consists of three anatomical variations:

Type 1 (Containing acini, islets and ducts)

Type 2 (Acini and ducts, no islets)

Type 3 (Ducts alone).

On gross examination, the diverticulum was 3 cm × 3 cm. On dissection, cut surface was white-yellow.

The histological examination revealed the presence of ectopic pancreatic tissue with pancreatic acini and ducts.

Islets of Langerhans were widely demonstrated (type 1 based on Heinrich classification) [Figure 2].

DISCUSSION

The management of heterotopic pancreas associated to symptomatic Meckel's diverticulum is clear; all authors recommend resection.

A slight difference is present from what happens for the treatment of heterotopic pancreas in the remaining segments of ileum.

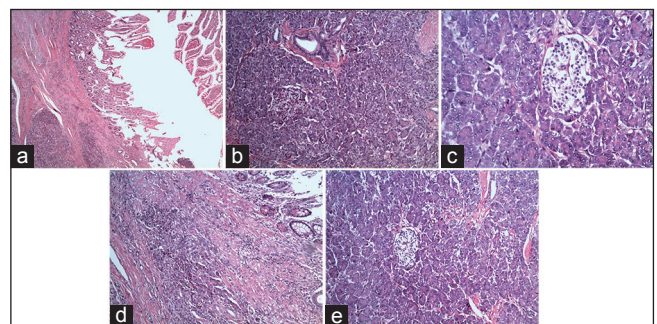


Figure 2: Histology. Pancreatic acini and dilated ducts interspersed by smooth muscle bundles (a, b). Islets of Langerhans were demonstrated (c-e)

In the majority of the cases reported, surgical resections were done, but other therapeutic options could be considered and for example endoscopic mucosal removal can be an attractive, less invasive option for the resection of accessible lesions.

Meckel's diverticulum and heterotopic pancreas has been rarely reported in children.

Starting from 2008, Ogata *et al.* on Pediatric Surgery International reported 12 cases of heterotopic pancreas in children.^[4]

They retrospectively investigated cases of heterotopic pancreas from April 1975 to September 2006.

They discussed the frequencies in the laparotomised patients, and patient's age, gender, operative indication, location of heterotopic pancreas, postoperative diagnosis, and pathology.

A total of 12 patients with heterotopic pancreas, 3 boys and 9 girls, aged 1 day to 10 years of age were investigated.

Ten patients had one pattern of heterotopic pancreas and the remaining two had more than one.

In four cases, heterotopic pancreas was located in Meckel's diverticulum, in three cases in stomach, in three cases in the duodenum, in three in the jejunum, and in two cases in the ileum.

Only in one patient heterotopic pancreas had caused an intussusception.

The remaining 11 cases were identified incidentally during the operation.

In 11 of 12 patients, heterotopic pancreas was removed without postoperative complications.

Classification of pathologies according to Heinrich is as follows: Type I, 4; type II, 4; type III, 2 and unknown, 2.

The authors suggested that incidental heterotopic pancreas should be removed whenever identified during laparotomy.

In 2009, Xiao *et al.* on Journal of International Medical Research described a case of heterotopic pancreas within Meckel's diverticulum with obscure then massive gastrointestinal bleeding in a 12-year-old child.^[5]

They reported a case of a 12-year-old boy with heterotopic pancreas located in a Meckel's diverticulum and presenting as obscure gastrointestinal bleeding.

Upper gastrointestinal endoscopy and colonoscopy did not reveal the source of the bleeding, however, capsule endoscopy revealed a space-occupying lesion in the ileum.

The patient developed massive bleeding and an emergency exploratory laparotomy was performed.

A congested Meckel's diverticulum was discovered 100 cm from the ileocaecal valve using intraoperative endoscopy; the ulcerated tip of the diverticulum appeared to be the source of the bleeding.

At laparotomy Meckel's diverticulum and adjacent ileal segment were resected and an end-to-end anastomosis performed.

Subsequent pathological examination revealed an ileal Meckel's diverticulum with heterotopic pancreas tissue within the submucosa.

The patient remains well, 12 months after the operation, with no evidence of recurrent bleeding.

This case suggested that heterotopic pancreas should be considered as one possible cause of obscure gastrointestinal bleeding in children and capsule endoscopy is a valuable adjuvant tool in the diagnosis of heterotopic pancreas in children.

In 2010, Baysoy *et al.* on Turkish Journal of Paediatrics described double heterotopic pancreas and Meckel's diverticulum in a 5-year-old child.^[6]

They report a 5-year-old boy who presented with melena and hematochezia, which were discovered to be consequent to Meckel's diverticulum.

He also had multiple heterotopic pancreatic tissues in various parts of the gastrointestinal tract.

The reason for this association was not explained, but might involve some abnormalities of signalling molecules expressed in the development of the gastrointestinal tract and associated organs.

In clinical practice, the authors underlined the fact that Meckel's diverticulum and heterotopic pancreatic tissue might occur together or accompany various other gastrointestinal anomalies.

In 2012, Singh *et al.* on Journal of Strength and Conditioning Research described a case of heterotopic pancreas presenting as ileoileal intussusception in a 12-year-old child.^[7]

They reported a case of heterotopic pancreas presenting as ileal polyp leading to ileoileal intussusception in a 12-year-old child.

Finally in 2013, Yang and Guo on Journal of the Pancreas described one case of massive lower gastrointestinal bleeding from Meckel's diverticulum with heterotopic pancreas.^[8]

They described a case of Meckel's diverticulum with heterotopic pancreas who presented massive lower gastrointestinal bleeding.

The authors explained as in lower gastrointestinal bleeding due to Meckel's diverticulum with heterotopic pancreas, was extremely difficult to make a definitive diagnosis preoperatively especially when it onsets rapidly.

In literature, newer and historical diagnostic options proposed for detecting a complicated Meckel's diverticulum are listed below:

- Intestinal sonography
- Plain abdominal X-ray
- Computed tomography scan
- Technetium-99m (Tc-99m) pertechnetate Meckel's scan (can revealed an abnormal focus of uptake in the right lower abdomen)
- Capsule endoscopy
- Double-balloon endoscopy
- Magnetic resonance enterography of the small intestine.

As Meckel's Tc-99m pertechnetate scan, according to Sinha *et al.*, it retains a high diagnostic accuracy in children for detecting a Meckel's diverticulum with ectopic gastric mucosa within it.^[9]

In particular the test yields its highest positive result in children presenting with significant rectal bleeding.

Detecting Meckel's diverticulum endoscopically is very difficult prior to surgery, but a combination of capsule endoscopy and double-balloon endoscopy facilitates examination of the entire small intestine, making diagnosis of Meckel's diverticulum possible.^[10]

About traditional radiologic examinations, diagnosis is often difficult because abdominal plain radiography

and ultrasound are not sufficiently specific, while CT scan is most accurate in differential diagnosis.

Anyway, these imaging studies are capable of identifying an abdominal pain that requires urgent surgical exploration.

In according to some authors, magnetic resonance enterography of the small intestine, a radiation-free technique developed based on CT enterography, which maximises the visibility of the mucosa and intestine structure with the aid of contrast agents, has greatly improved the diagnosis rate of Meckel's diverticulum, particularly in those patients with the disease which cannot be confirmed via double-balloon enteroscopy.^[11]

CONCLUSION

Heterotopic pancreas is a rare congenital lesion, often diagnosed incidentally on histopathological examination but should be considered in the differential diagnosis of intestinal mass lesions.

Meckel's diverticulum is the most common congenital abnormality of the small intestine; it is caused by an incomplete obliteration of the vitelline duct (omphalomesenteric duct).

Two types of complications can involve Meckel's diverticulum and require clinical attention.

One type involves ectopic mucosal tissue and most often leading to gastrointestinal bleeding in younger children.

In the second type, the sequelae of the diverticulum involve an aberrant intra-abdominal structure and could cause intussusception or internal hernia.

In our case both these evidence occurred and explained the setting of urgent laparotomy.

In our report, the presence of intussusception has made possible the ultrasound diagnosis of an abdominal urgency, but we confirm the difficulty of precisely diagnosing Meckel's diverticulum in an acute setting.

Abdominal plain radiography only allowed to diagnose intestinal occlusion or perforation.

Ultrasound could reveal abscessual collections in the pelvis, fluid distension of the diverticulum, segmental thickening of the intestinal walls and invagination.

Computed tomography scan proved to be more specific showing signs suggestive of correct diagnosis.

In particular, evidence of an intraluminal prolonged mass with central area of fat density and peripheral collar was considered suggestive of intraluminal invagination of Meckel's diverticulum. Another diagnostic sign is the evidence of a tubular fluid-filled structure, with thickened, enhanced walls.

In some cases, CT can show an abscessual collection with gas-fluid level (complication of perforation) confirming the need for surgery.

In conclusion, Meckel's diverticulum is a not uncommon condition that in some cases is complicated, resulting in acute abdomen.

Preoperative radiological diagnosis can be only suspected in the presence of suggestive signs, more often depicted by ultrasound or CT scan.

Viewed the previous literature, we underline the concept that in similar cases, during laparotomy an accurate exploration of all ileum is mandatory, for the possibility to find others heterotopic segments.

REFERENCES

1. Robustelli U, Manguso F, Armellino MF, Mannelli MP, Massa MR, Forner AL, *et al.* Acute symptomatic Meckel diverticulum management. Our experience on seven consecutive cases. *Ann Ital Chir* 2014;85:129-35.
2. Burjonrappa S, Khaing P. Meckel's diverticulum and ectopic epithelium: Evaluation of a complex relationship. *J Indian Assoc Pediatr Surg* 2014;19:85-9.
3. Uz Zaman M, Fatima N, Zaman U, Sajjad Z. Wandering Meckel's diverticulum on 99m technetium-pertechnetate scintigraphy: A diagnostic dilemma? *Indian J Nucl Med* 2014;29:30-1.
4. Ogata H, Oshio T, Ishibashi H, Takano S, Yagi M. Heterotopic pancreas in children: review of the literature and report of 12 cases. *Pediatr Surg Int* 2008;24:271-5.
5. Xiao WD, Chen W, Yang H. Heterotopic pancreas within Meckel's diverticulum with obscure then massive gastrointestinal bleeding in a 12-year-old child: Case report and review of the literature. *J Int Med Res* 2009;37:967-72.
6. Baysoy G, Balamtekin N, Uslu N, Karavelioglu A, Talim B, Ozen H. Double heterotopic pancreas and Meckel's diverticulum in a child: Do they have a common origin? *Turk J Pediatr* 2010;52:336-8.
7. Singh S, Batra A, Sangwaiya AK, Marwah N, Rattan KN, Sen R. Heterotopic pancreas presenting as ileoileal intussusception. *J Surg Case Rep* 2012;9:13.
8. Yang X, Guo K. Massive lower gastrointestinal bleeding from Meckel's diverticulum with heterotopic pancreas: Case report and a brief review of the literature. *JOP* 2013;14:269-72.
9. Sinha CK, Pallewatte A, Easty M, De Coppi P, Pierro A, Misra D, *et al.* Meckel's scan in children: A review of 183 cases referred to two paediatric surgery specialist centres over 18 years. *Pediatr Surg Int* 2013;29:511-7.
10. Taniuchi K, Tanaka H, Iwamura S, Mori I. Meckel's diverticulum preoperatively diagnosed by double-balloon endoscopy. *Intern Med* 2012;51:1023-6.
11. Zhou FR, Huang LY, Xie HZ. Meckel's diverticulum bleeding diagnosed with magnetic resonance enterography: A case report. *World J Gastroenterol* 2013;19:2727-30.

Cite this article as: Riccardo G, Valeria B, Giulia C, Alessia C, Luisa F, Elisabetta T, *et al.* Heterotopic pancreas in Meckel's diverticulum in a 7-year-old child with intussusception and recurrent gastrointestinal bleeding: Case report and literature review focusing on diagnostic controversies. *Afr J Paediatr Surg* 2014;11:354-8.

Source of Support: Nil. **Conflict of Interest:** None declared.