

An Image Processing Approach Based on Gnu Image Manipulation Program Gimp to the Panoramic Radiography

Original

An Image Processing Approach Based on Gnu Image Manipulation Program Gimp to the Panoramic Radiography / Sparavigna, Amelia Carolina. - In: INTERNATIONAL JOURNAL OF SCIENCES. - ISSN 2305-3925. - STAMPA. - 4:5(2015), pp. 57-67. [10.18483/ijSci.721]

Availability:

This version is available at: 11583/2614375 since: 2015-09-03T06:56:33Z

Publisher:

England: Alkhaer Publications

Published

DOI:10.18483/ijSci.721

Terms of use:

This article is made available under terms and conditions as specified in the corresponding bibliographic description in the repository

Publisher copyright

(Article begins on next page)

An Image Processing Approach based on GNU Image Manipulation Program GIMP to the Panoramic Radiography

Amelia Carolina Sparavigna¹ 

¹Department of Applied Science and Technology, Politecnico di Torino, Torino, Italy

Abstract: We have recently proposed, in a paper published by the International Journal of Sciences, the use of some freely available image processing tools to enhance images of the fundus of the eye. In particular, we have discussed the use of GIMP, the GNU Image Manipulation Program, and of some wavelet filters and fractional gradient methods from other image processing programs. Here we propose GIMP to enhance the images given by panoramic radiography. This approach can produce an output image, which helps detecting faint details in such radiographic plates, which are quite important for dental treatments. Some case studies are discussed.

Keywords: Image processing, Medical imaging, Panoramic Radiography, GIMP

1. Introduction

Medical imaging is a sub-discipline of the biomedical engineering, a new and rapidly evolving interdisciplinary field, which aims filling the gap between biology and several disciplines of engineering and applied science. It is therefore a branch of the applied science, mainly oriented to the medicine for both diagnostic and therapeutic purposes. In particular, the medical imaging is devoted to the study of non-invasive techniques that aim obtaining images of some internal aspects of the body. Among the well-known techniques of medical imaging, we have radiology, ultrasonography and magnetic resonance. These techniques comprise both technical aspects of data acquisition and problems connected with diagnostic interpretation.

Imaging and image processing turn out to be valuable means to infer some properties of biological structures from the corresponding observed signals [1]. Sometimes, the raw images obtained from diagnostic equipment need an improvement. There are many resources useful for processing images, most of them freely available and quite friendly to use, that can help the user to separate the objects, relevant to the given study, from the background of the image. In a recent paper [2] for instance, we have proposed the use of some tools to enhance images of the fundus of the eye. In particular, we have discussed the use of GIMP, the GNU Image

Manipulation Program, and the use of wavelet filters and fractional gradient tools from other image processing programs [3,4]. Here we propose GIMP to enhance the images given by panoramic radiography. This approach can produce an output image, which helps the detection of faint details in such radiographic plates. Some case studies are discussed.

2. GIMP software

GIMP is a free and open-source software used for processing images and for free-form drawing. It is useful for resizing, cropping and converting images between different formats. It is also collecting several specialized tasks. GIMP is designed to be augmented with plug-ins and extensions, which can improve its functionality.

According to the GIMP user manual, any image can be edited, considering it made of many layers in a stack. A GIMP image then is as a stack of transparencies, where each transparency is a layer. Each layer in an image is made of several channels. In RGB images, there are normally three channels, each consisting of a red, green and blue channel. Colour sublayers look like slightly different grey images; when put together, they make a complete image. A fourth channel can exist, the alpha channel, which measures the opacity of the image.

A toolbox allows accessing the tools available for image editing. Among them, we find filters and

This article is published under the terms of the Creative Commons Attribution License 4.0

Author(s) retain the copyright of this article. Publication rights with Alkhaer Publications.

Published at: <http://www.ijsciences.com/pub/issue/2015-05/>

Article Number: V4201505721; Online ISSN: 2305-3925; Print ISSN: 2410-4477



Amelia Carolina Sparavigna (Correspondence)

d002040@polito.it

+39-011-564-7360

brushes, as well as transformation, selection, layer and masking tools. For what concerns colours and grey-tones of images, we can adjust brightness and contrast, and also change them with the Curves tool. Gradients are also integrated into the toolbox: there are a number of default gradients included with GIMP, such as Laplace and Sobel, suitable for edge detections. Moreover, GIMP has more than a hundred of standard effects and filters, including those supporting sharpening and blurring of images. A part of them we can find in the GIMP Auto submenu. This submenu contains operations which automatically adjust the distribution of grey-tones, without requiring any input from the user. We can “Stretch Contrast”, “Stretch HSV” and “Normalize” the histogram (the reader can find more details in the tutorials at <http://www.gimp.org>).

GIMP supports importing and exporting with a large number of different file formats, the GIMP's native format is designed to store all information GIMP can contain about an image. The software supports image formats such as BMP, JPEG, PNG, GIF and TIFF. Other formats with read/write support include PostScript documents and X bitmap images. It can import Adobe PDF documents and the raw image formats used by many digital cameras, but cannot save to these formats.

3. Panoramic radiography

The panoramic radiography of dental arches is a procedure that produces an image of the teeth, upper and lower jaws and jawbones on a single image. To obtain the projection of the dental arches, which are curvilinear structures, it is necessary to use X-ray techniques based on a rotating tube about the patient's head. Let us note that panoramic radiography is a form of tomography and that these techniques can be compared [5]. In panoramic radiography, images of multiple planes are recorded to have a composite final image. Maxilla and mandible are into focus, whereas the structures that are superficial or deep inside are blurred.

The panoramic radiography is an essential element in oral radiology and dentistry [6-8]. Its principle was described in 1922, but first commercially available machines are of the early 1960s [9]. Today, such radiographic devices, which are fundamental for an initial assessment of the state of teeth prior to a dental treatment, are rather common. After a panoramic image, the dentist can perform a more targeted intra-oral radiography. Panoramic plates are also useful to evaluate the state of dentition in individuals in the age of development, to highlight any irregular tooth or impacted teeth and bone lesions. Moreover, they reveal inflammatory problems or cystic tumours.

In the Figure 1, we can see in the upper panel, a basic panoramic radiograph image. The image is a courtesy of the Coronation Dental Specialty Group on Wikipedia. In the lower panel of the same figure, we can see the output of Sobel filter for edge detection of GIMP. This filter is detecting the edges of objects in the image: in this manner the endodontic, periodontal and coronal-radicular details are enhanced. Let us stress that a sequence of panoramic images can be interesting for the recording the evolution of teeth and the planning of their treatments. This is important, in particular for teeth that have suffered an endodontic treatments, such as root canal treatments, in their medical history [10].

In the Figure 2 we can see how the panels of Figure 2 look like after an inversion of colour tones made by GIMP. In the lower panel of Figure 2, we can see a clear enhancements of the details of the roots of teeth. Panoramic images are also used for the mixed dentition, as shown in the Figure 3 (courtesy Coronation Dental Specialty Group on Wikipedia): in it, we can see the wisdom teeth buds. The image is processed using the Sobel filter: the result is shown in the lower panel with grey-tones inverted.

Here in the following, we discuss some case studies where specific tools of GIMP are applied to enhance the details in images.

3.1 Cysts of the jaws

Bones of jaws, mandible and maxilla, are the bones of human body with the highest prevalence of cysts. Since these cysts rarely cause any symptoms [11], most are discovered during the panoramic radiography. In the X-ray images, cysts appear as radiolucent dark areas, that is, areas permitting the passage of radiant energy that have radiopaque white borders [12]. In the Figure 4 in fact, we see a cyst with the borders enhanced by the Sobel filter of GIMP. Let us emphasize that, with GIMP, we can select an area and process just the selected region.

3.2 Stafne defects

A Stafne defect, also known as Stafne bone cyst, is a depression of the mandible on the lingual surface, that is, the side nearest the tongue. The Stafne defect is thought to be a normal anatomical variant and does not represent a pathologic lesion. This defect is usually discovered by chance during routine dental radiography [13, 14].

In the Figure 5 we can see a panoramic radiograph showing Stafne defect in the right mandible, below the inferior alveolar nerve canal. The image is a courtesy of the Coronation Dental Specialty Group on Wikipedia. After selecting the part of the image containing the defect, we can apply GIMP Auto submenu. It contains operations which automatically adjust the distribution of grey-tones, without

requiring any input from the user. Here we show the results of “Stretch Contrast”, “Stretch HSV” and of “Normalize”. Using these automatic filters we can have some information on the density of bone near and inside the defect.

3.3 Pattern of mental nerve

As discussed in References 15 and 16, the pattern of mental nerve into the mental foramen is an important pre-surgical landmark in mandibular premolar regions. As panoramic radiographs are routinely used in pre-surgical evaluation, the researchers in [16], undertook a study to evaluate the reliability of panoramic X-ray machines for determination of the location of mandibular foramen. The study revealed that the most common pattern of entry of mental nerve was a straight one (about 79% of the total radiographs examined).

The researchers in [16] tell that panoramic radiography may not be a very reliable imaging modality for identifying the presence of an anterior loop of the nerve, a condition which needs to be determined before planning the surgical procedures. In any case, we can try to enhance the images of nerve and mental foramen with GIMP. In Figure 6, we can see the mandibular canal after applying the GIMP Auto submenu “Equalize”, “White Balance” and “Stretch Contrast”. In the Figure 7, we can see an example of image enhancement obtained by GIMP Retinex. This tool improves visual rendering of an image when lighting conditions are not good. The algorithm, which is the root of Retinex filter, the MultiScale Retinex with Color Restoration algorithm, is inspired by the eye biological mechanisms to adapt itself to these conditions. The result of Retinex filter can be adjusted selecting different levels, scales and dynamics. In the Figure 8, we have another example of the use of Retinex.

Retinex can be applied to the whole image, as proposed in the Figure 9: the enhancement of the mental canals in the output image is evident.

4. Conclusion

In this paper we have proposed the use of an image processing program to enhance the images obtained by means of X-ray panoramic radiography. Let us remark that several other researches on image processing for panoramic radiography are available in literature. For instance, image processing can be used to obtain a panoramic X-ray device suitable for complete maxillofacial diagnoses, extending therefore the diagnostic coverage of panoramic images [17]. In [18], the image processing is used to enhance the images, when a reduction of the radiation dose is required, and in [19], an appropriate approach for the robust estimation of noise statistic in dental panoramic X-rays images is given. Here, aiming to

reach a large audience, we have proposed the use of a program, the GIMP, which is freely available on the web. In the paper we have shown that GIMP has several tools which can be quite useful to enhance and investigate the details of panoramic images. Some of them are able of automatically adjust the distribution of grey-tones, without requiring any input from the user. These are, of course, the simplest to use in preliminary investigations. In the case of the analysis of mental canal and foramen, Retinex seems to be the tool providing the best results.

REFERENCES

- 1) Nait-Ali A, Fournier R (Eds.) (2012). Signal and image processing for biometrics (Google eBook), John Wiley & Sons. ISBN: 978-1-84821-385-2
- 2) Sparavigna AC (2014). GIMP and wavelets for medical image processing: Enhancing images of the fundus of the eye. *International Journal of Sciences* 3(8), 35-47.
- 3) Christian Buil, Software Iris, 1999-2010. Freely available at www.astrosurf.com/buil/us/iris/iris.htm
- 4) Marazzato R, Sparavigna AC (2009). Astronomical image processing based on fractional calculus: the AstroFracTool. *arXiv preprint*, arXiv:0910.4637.
- 5) Angelopoulos C, Thomas SL, Hechler S, Parissis N, Hlavacek M (2008). Comparison between digital panoramic radiography and cone-beam computed tomography for the identification of the mandibular canal as part of pre-surgical dental implant assessment. *J. Oral Maxillofacial Surg.* 66(10), 2130-2135. DOI: 10.1016/j.joms.2008.06.021.
- 6) Molander B (1996). Panoramic radiography in dental diagnostics. *Swed. Dent. J. Suppl.* 119, 1-26. PMID: 8971997
- 7) Tal H, Moses O (1991). A comparison of panoramic radiography with computed tomography in the planning of implant surgery. *Dentomaxillofacial Radiology* 20(1), 40-42. PMID: 1884852 <http://dx.doi.org/10.1259/dmfr.20.1.1884852>
- 8) Küttik N, Gönen ZB, Yasar MT, Demirbas AE, Alkan A (2014). Reliability of panoramic radiography in determination of neurosensory disturbances related to dental implant placement in posterior mandible. *Implant dentistry*, 23(6), 648-652. DOI: 10.1097/ID.0000000000000160.
- 9) Hallikainen D (1996). History of panoramic radiography. *Acta Radiol.* 3, 441-555. PMID: 8652310 <http://dx.doi.org/10.3109/02841859609177678>
- 10) Pirte A, Zatykó A, Lajosi P, Venter A, Muresan M (2010). Coronal-radicular and periodontal complications in cases of teeth with endodontic treatments in medical records. *Romanian Journal of Oral Rehabilitation*, 2(2), 8-13.
- 11) Hupp JR, Ellis E, Tucker MR (2008). *Contemporary oral and maxillofacial surgery* (5th ed. ed.). St. Louis, Mo.: Mosby Elsevier. pp. 450-456. ISBN 9780323049030.
- 12) Vv. Aa. (2015). Cysts of the jaws, Wikipedia.
- 13) Wray D, Stenhouse D, Lee D, Clark AJE (2003). *Textbook of general and oral surgery*. Edinburgh [etc.]: Churchill Livingstone. pp. 173-178. ISBN 0443070830.
- 14) Vv. Aa. (2015). Stafne defects, Wikipedia.
- 15) Kaffe I, Ardekian L, Gelerenter I, Taicher S (1994). Location of the mandibular foramen in panoramic radiographs. *Oral Surg. Oral Med Oral Pathol.* 78(5): 662-9. PMID: 7838477 [http://dx.doi.org/10.1016/0030-4220\(94\)90182-1](http://dx.doi.org/10.1016/0030-4220(94)90182-1)
- 16) Iyengar AR, Patil S, Nagesh KS, Mehkri S, Manchanda A. (2013). Detection of anterior loop and other patterns of entry of mental nerve into the mental foramen: A radiographic study in panoramic images. *J. Dent. Implant.* 3, 21-25. DOI: 10.4103/0974-6781.111678
- 17) Kim TG, Lee YS, Kim YP, Park YP, Cheon MW (2014). Study on image processing of panoramic X-ray using deviation improvement software. *Journal of X-Ray Science and Technology* 22(3), 361-368. DOI: 10.3233/XST-140431.

- 18) Muhammed HH (2014). Optimization of radiation doses in panoramic X-ray examination using automated image processing. Imaging Systems and Techniques (IST), 2014 IEEE International Conference on, Santorini. DOI: 10.1109/IST.2014.6958505
- 19) Abdallah YMY, Almoustafa AA, Elhadi G., Mohammed M, Khalafallah O, Khalid T. (2011). Application of analysis approach in noise estimation in panoramic X-rays images using image processing program (MatLab). Canadian Journal on Medicine 2(3), 38-48.

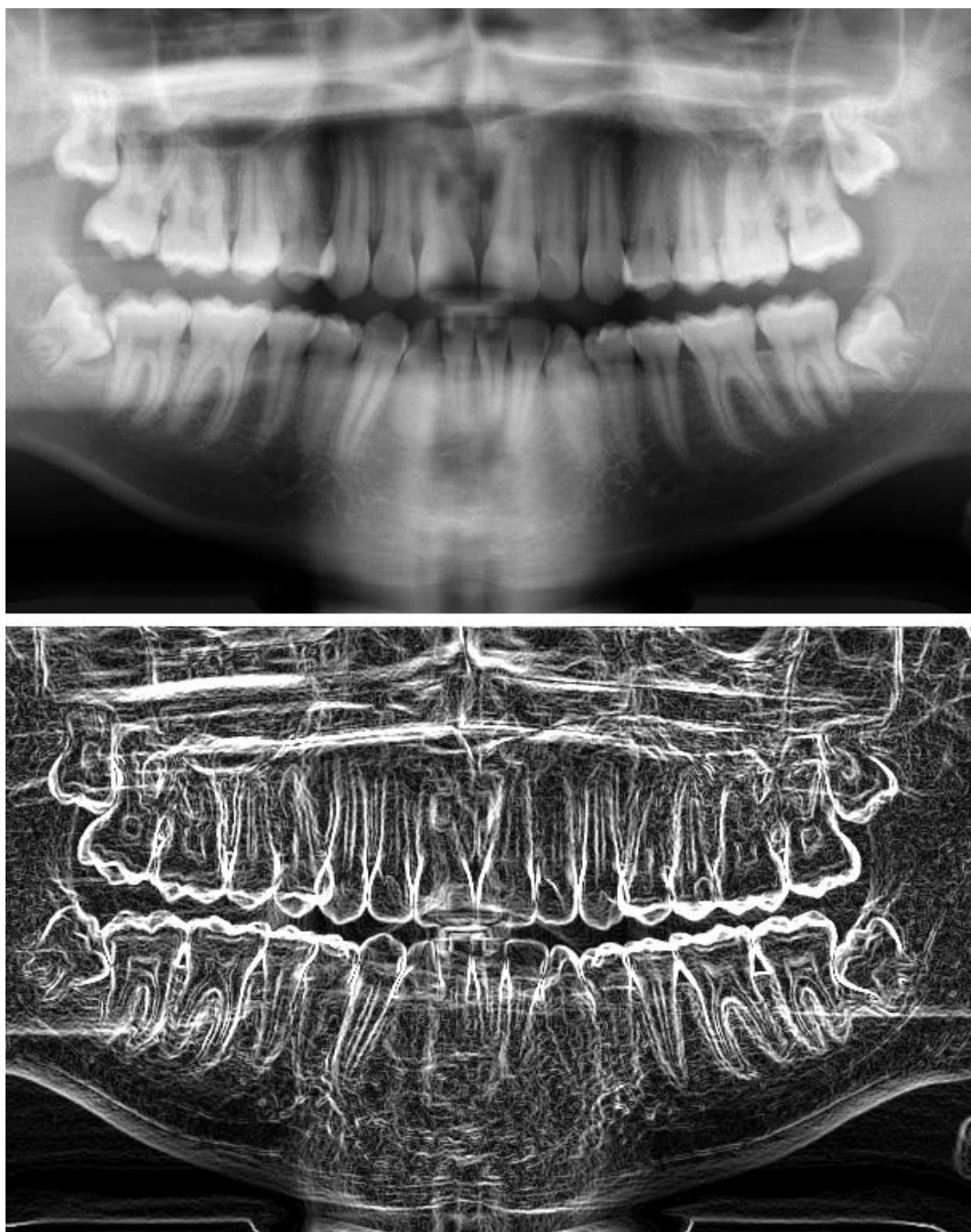


Figure 1 - In the upper panel, we can see a basic panoramic radiograph showing impacted wisdom teeth in a 16 year old. The image is a courtesy of the Coronation Dental Specialty Group on Wikipedia. In the lower panel, we can see the image obtained using the Sobel filter for edge detection of GIMP.

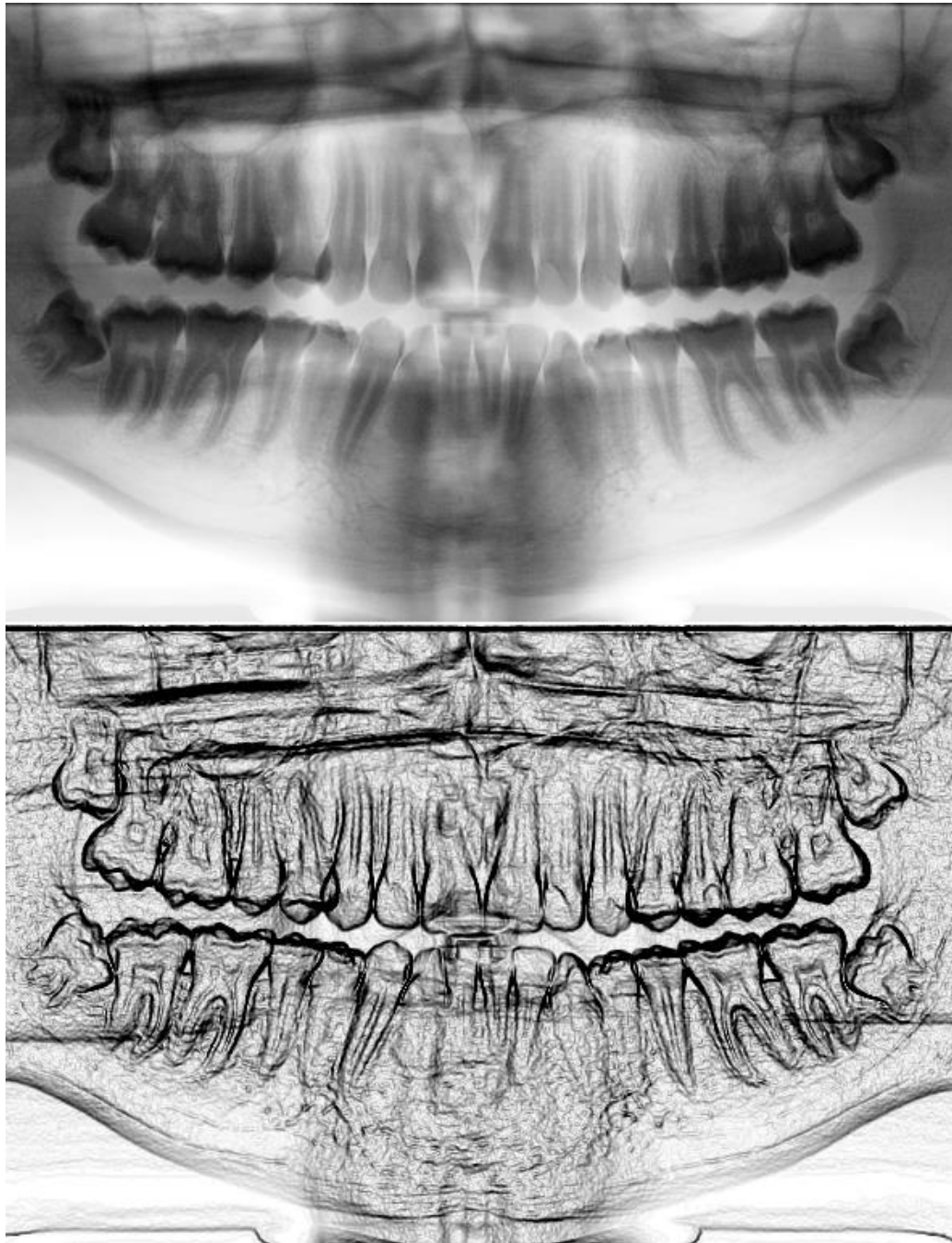


Figure 2 - In the upper panel, we can see the panoramic radiograph of Figure 1 with inverted color tones, as obtained by GIMP. The same for the lower panel, showing the edge detection. Note the details of the roots of teeth.

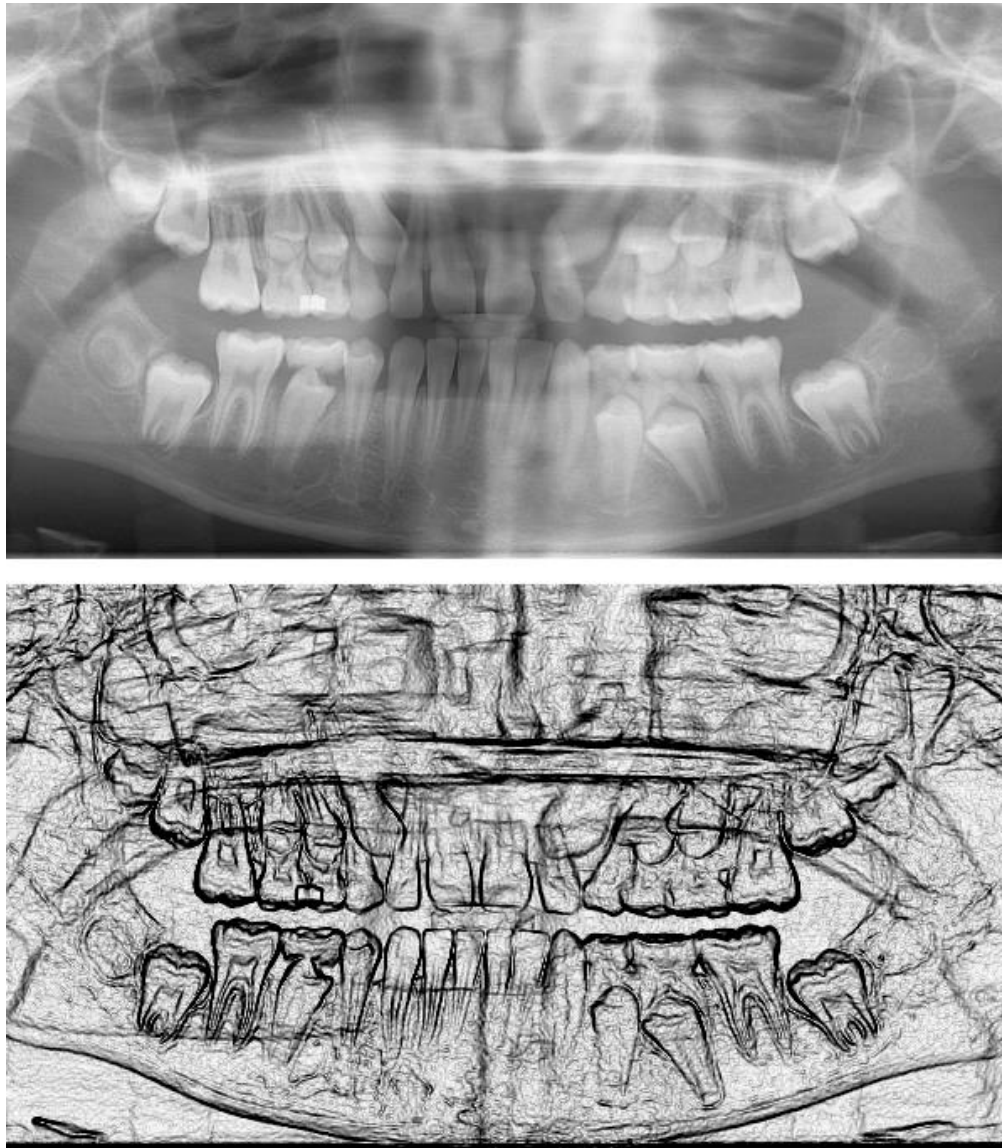


Figure 3 – In the upper panel we can see a panoramic radiograph which is showing the mixed dentition of a nine year old child (courtesy Coronation Dental Specialty Group on Wikipedia). We can see also the wisdom teeth buds. The image is processed using the Sobel filter. The final result is proposed with the grey-tones inverted.

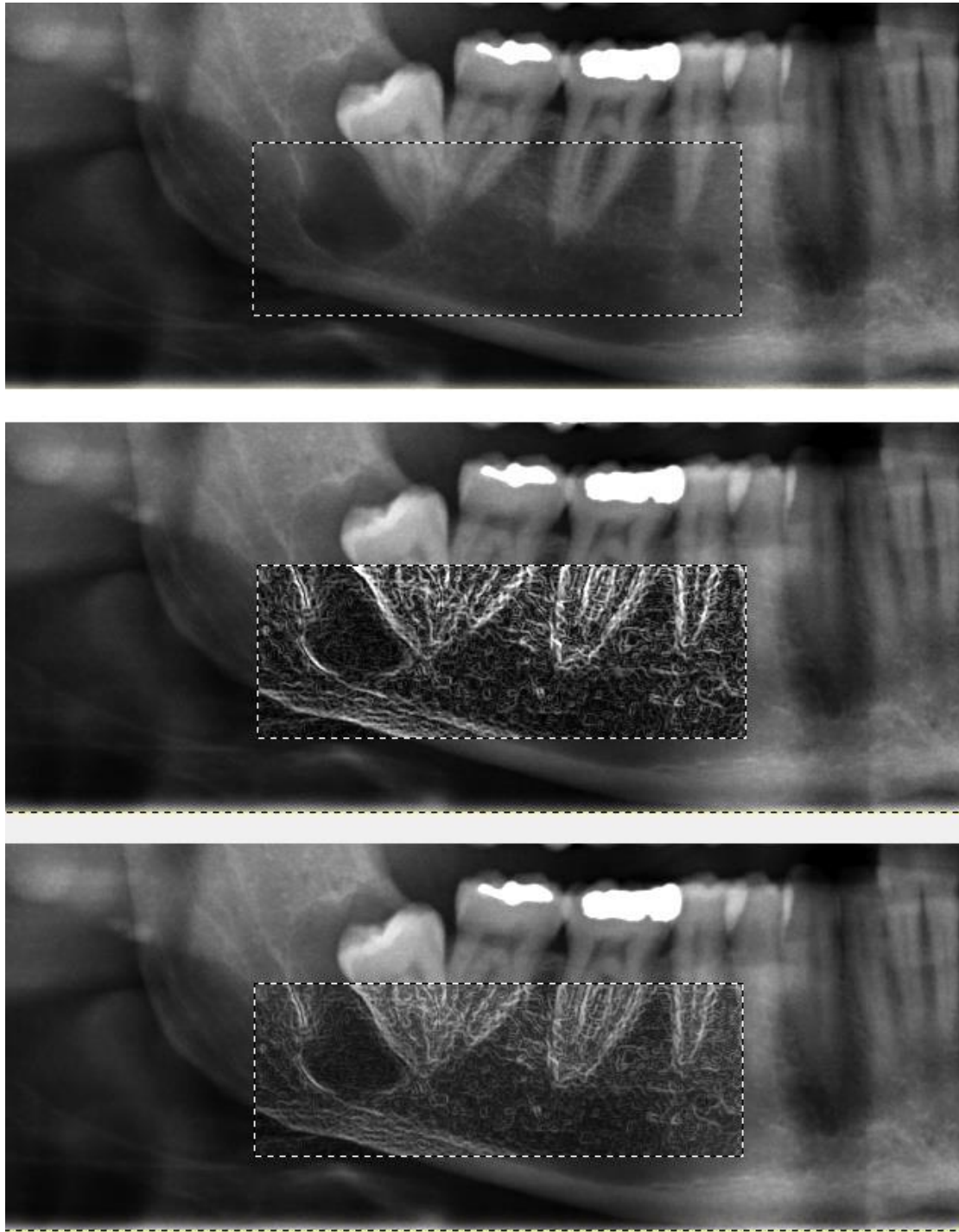


Figure 4 - In the upper panel, we can see a basic panoramic radiograph showing a jaw cyst in the right mandible and an impacted wisdom tooth. The image is a courtesy of the Coronation Dental Specialty Group. GIMP allows selecting an area and processing just the selected region. In the middle, we can see the use of Sobel filter in this area. In the lower panel, the upper and middle panel are superimposed. In fact, GIMP is considering an image as a set of layers which can be independently manipulated.

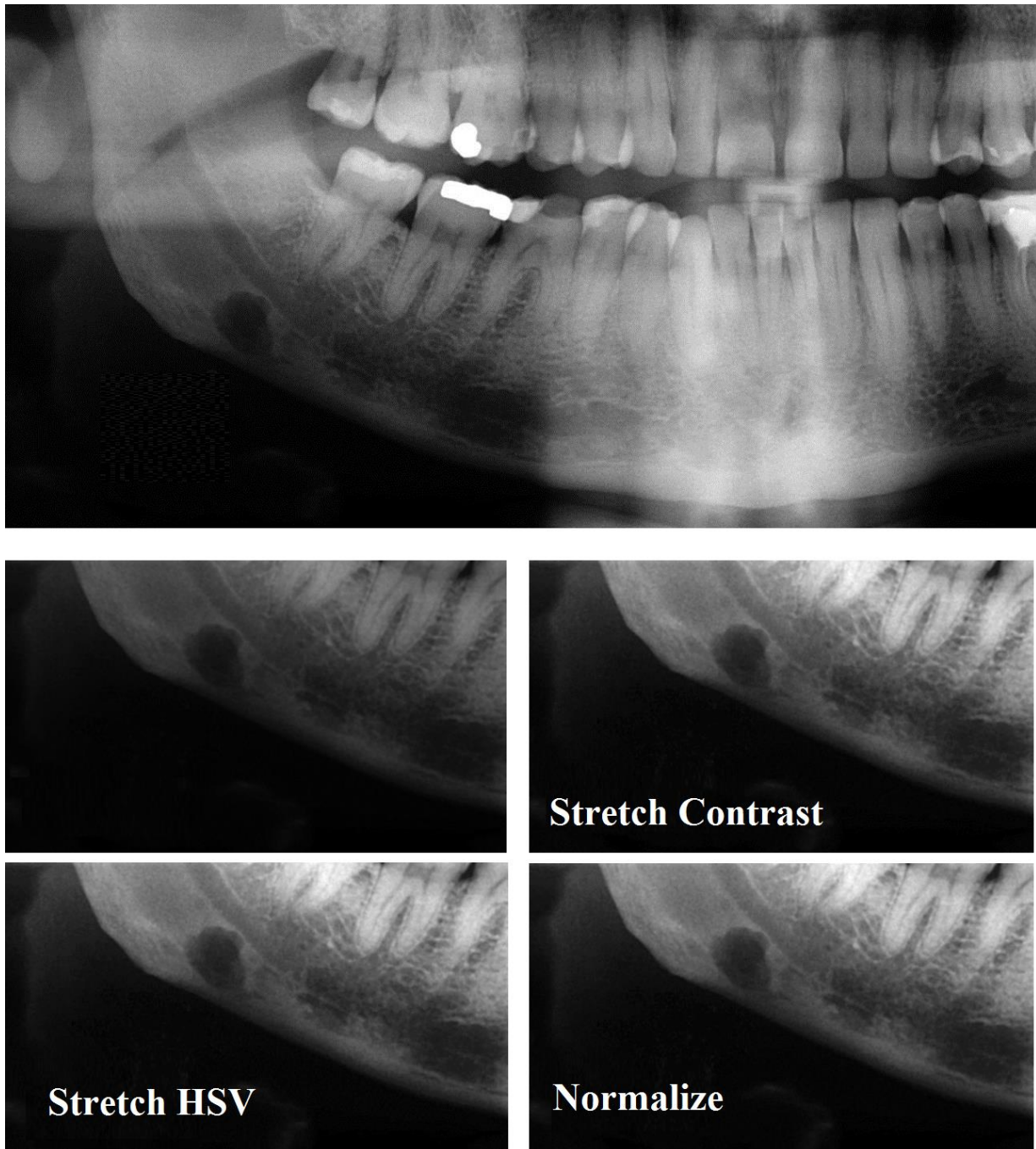


Figure 5 - This is a panoramic radiograph showing Stafne defect in the right mandible, below the inferior alveolar nerve canal. The image is a courtesy of the Coronation Dental Specialty Group on Wikipedia. Stafne defect is thought to be a normal anatomical variant. After selecting the part of the image containing this defect, we can apply GIMP Auto submenu. It contains operations which automatically adjust the distribution of grey-tones, without requiring any input from the user. Here we show the results of “Stretch Contrast”, “Stretch HSV” and of “Normalize”.

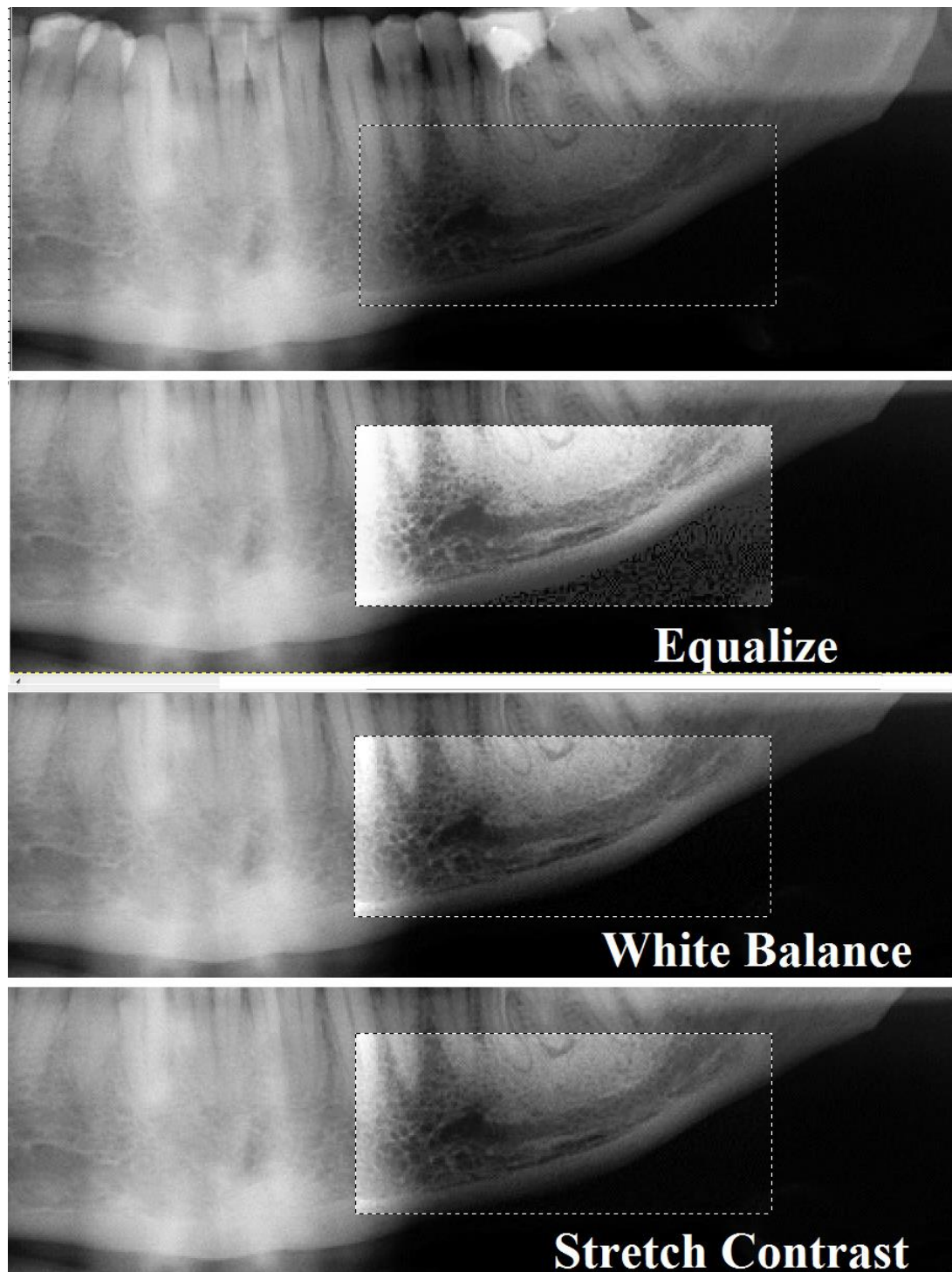


Figure 6 – Panoramic radiographs are routinely used in pre-surgical evaluation. In them, the pattern of mandibular canal and the mental foramen are important landmarks. We can try to enhance the related images using GIMP; here an example from the panoramic image of Figure 5, a courtesy of the Coronation Dental Specialty Group on Wikipedia. We can see the mandibular canal. After selecting the part of the image containing this canal, we can apply the GIMP Auto submenu. Here we used “Equalize”, “White Balance” and “Stretch Contrast”.

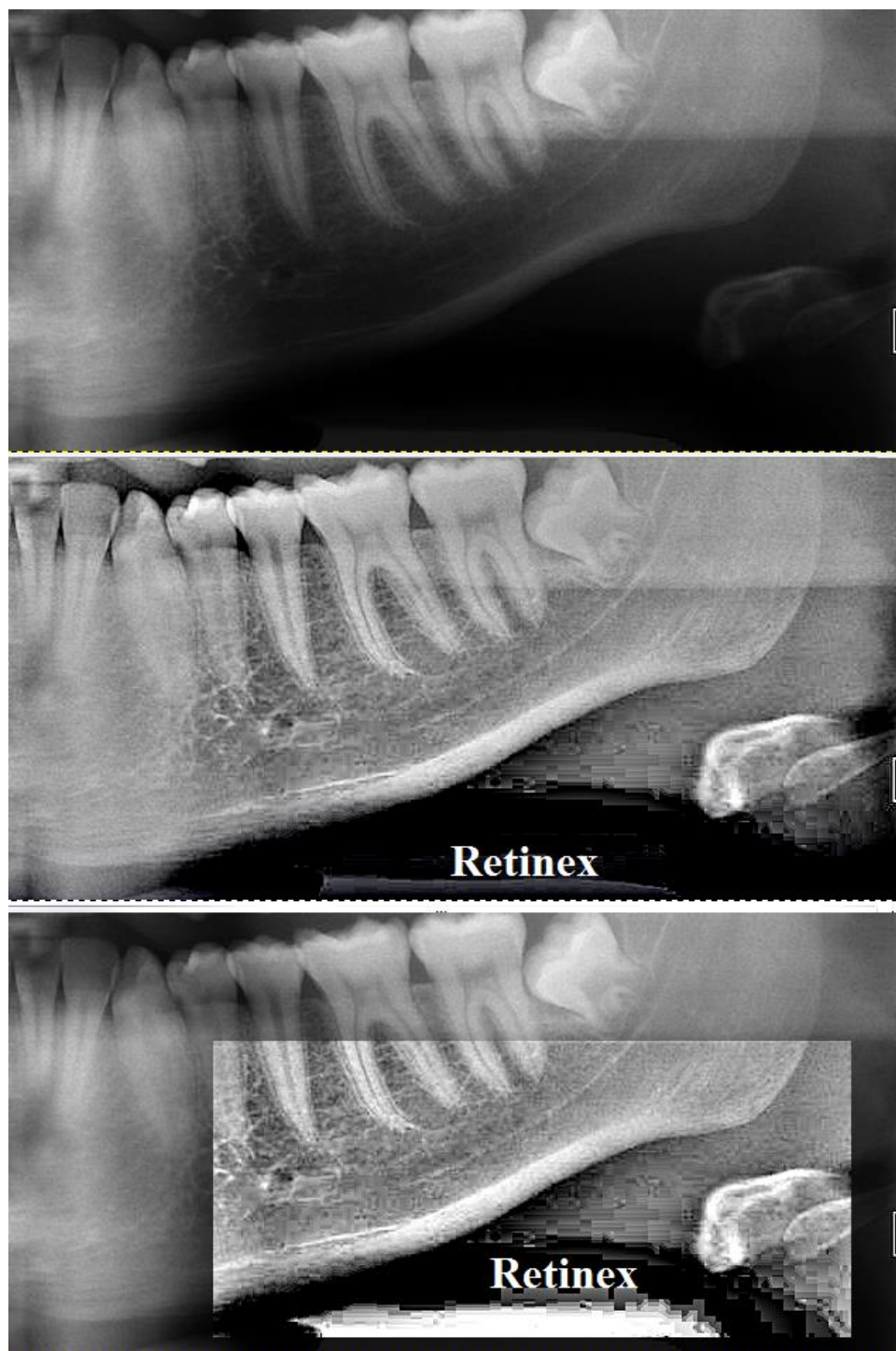

Figure 7 – To enhance the pattern of the mandibular canal and to see the mental foramen, we can use another GIMP tool, the “Retinex” tool. Retinex improves visual rendering of an image when lighting conditions are not good. The algorithm, which is the root of the Retinex filter, the MultiScale Retinex with Color Restoration algorithm, is inspired by the eye biological mechanisms to adapt itself to these conditions. In this figure, Retinex is applied to the whole image (middle) and to a part of it (bottom). The original image (top) is that of Figure 1, a courtesy of the Coronation Dental Specialty Group on Wikipedia.

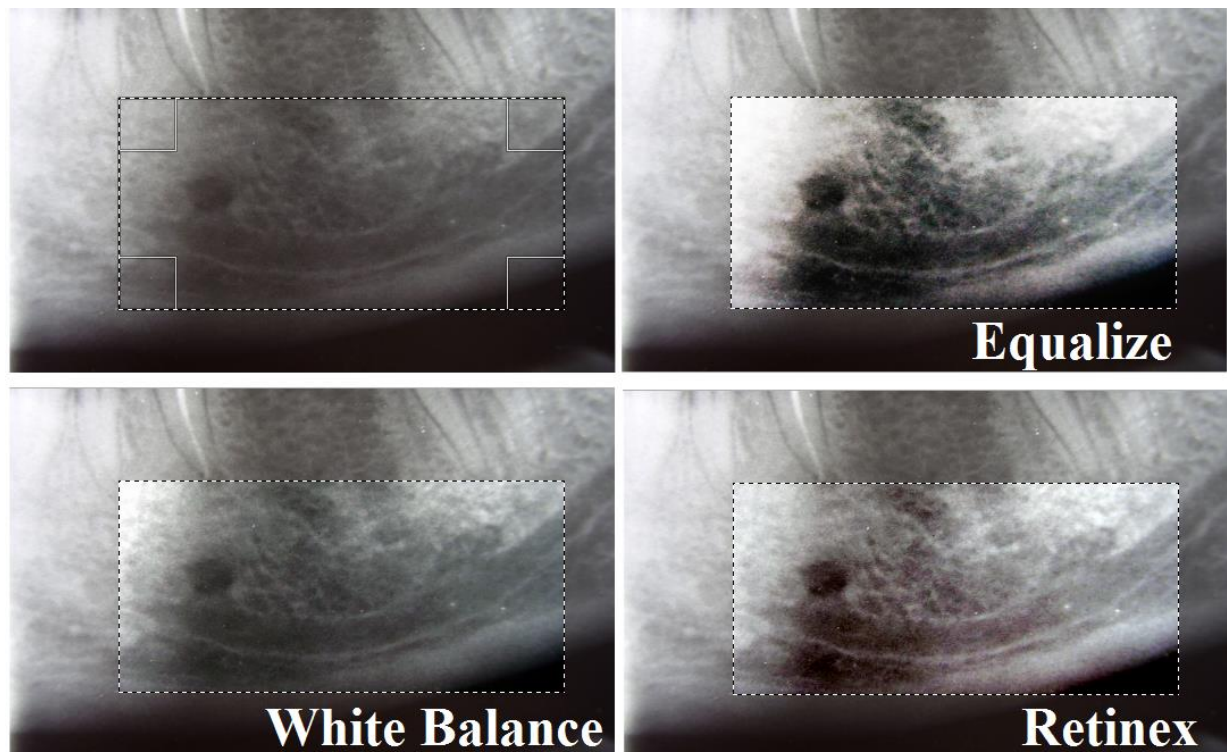


Figure 8 – Another image of mandibular canal and mental foramen. We can see the different results obtained by the GIMP Auto submenu for “Equalize” and “White Balance”, and by the “Retinex” GIMP tool. The original image is a courtesy of Wikipedia User Werneuchen.

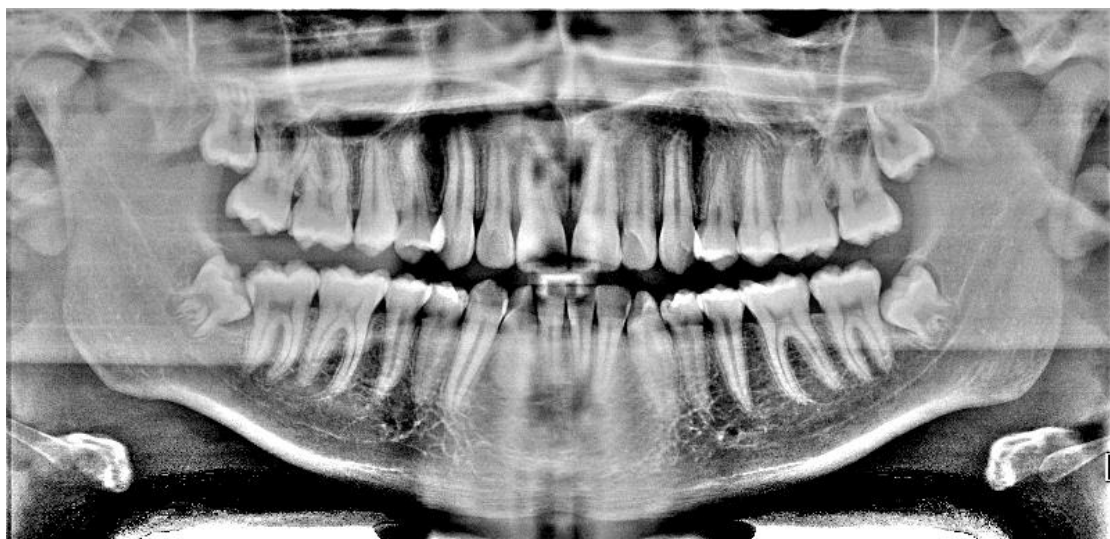

Figure 9 – This is the panoramic image of Figure 1, as we can see it after applying the “Retinex” GIMP tool.