

The use of polymers in the treatment of retinal detachment: current trends and future perspectives

Original

The use of polymers in the treatment of retinal detachment: current trends and future perspectives / Baino, F.. - In: POLYMERS. - ISSN 2073-4360. - ELETTRONICO. - 2:(2010), pp. 286-322. [10.3390/polym2030286]

Availability:

This version is available at: 11583/2432980 since:

Publisher:

Published

DOI:10.3390/polym2030286

Terms of use:

This article is made available under terms and conditions as specified in the corresponding bibliographic description in the repository

Publisher copyright

(Article begins on next page)

Review

The Use of Polymers in the Treatment of Retinal Detachment: Current Trends and Future Perspectives

Francesco Baino

Materials Science and Chemical Engineering Department, Politecnico di Torino, Corso Duca degli Abruzzi 24, 10129 Torino, Italy; E-Mail: francesco.baino@polito.it; Tel.: +39-011-564-4668; Fax: +39-011-564-4699

Received: 2 July 2010; in revised form: 24 August 2010 / Accepted: 24 August 2010 /

Published: 9 September 2010

Abstract: Procedures for the treatment of retinal detachment and related conditions have been successfully improved upon in recent years thanks to the advent of new therapies and biomaterials. This review, after giving an overview on eye structure and function, focuses on the treatment of retinal detachment and examines the role and features of the materials used in vitreoretinal surgery, emphasizing scleral buckling and short-term/long-term vitreous tamponade. Specifically, the limitations of existing biomaterials are underlined, based on experimental studies and with particular reference to cells/material interactions. Finally, current and future trends of biomaterials' research in the field of vitreoretinal surgery are considered and discussed.

Keywords: retina; vitreous; scleral buckling; vitreous substitute; silicone; hydrogel

1. Introduction

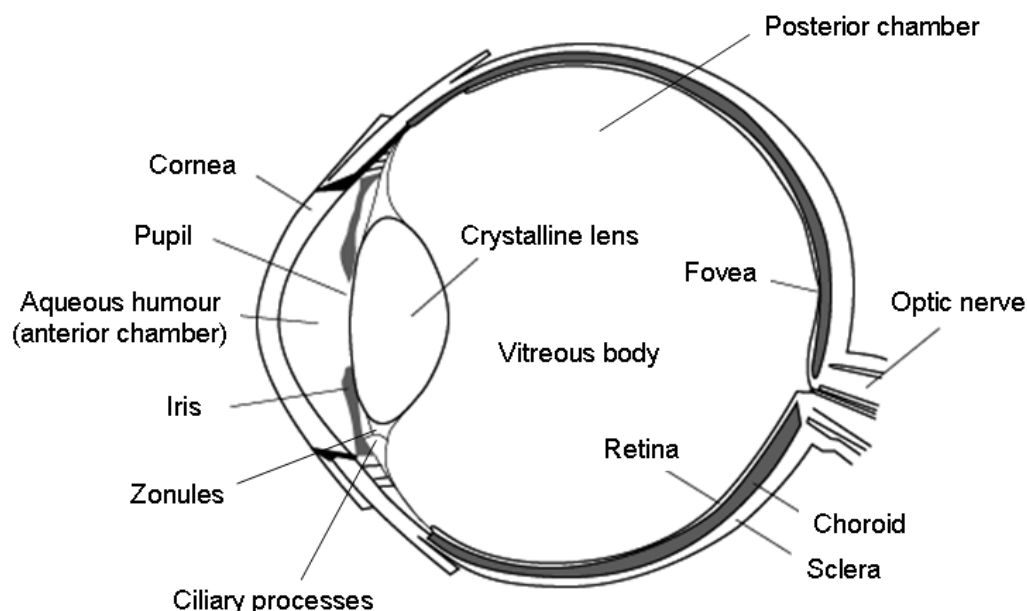
The human eye is a complex organ of vital importance for everyday life. The risk of retinal detachment (RD) in otherwise normal eyes has been estimated at about 0.005% and is more frequent in middle-aged or elderly people [1,2]. The fate of the eyes affected by RD, if not properly treated, is a progressive loss of vision over time and, eventually, complete blindness. Ocular biomaterials and implants have been successfully used in order to enable surgeons to restore vision in ever more complex RD cases [3–6]. The first part of this article provides an overview of eye anatomy and physiology, which should be useful to non-specialist readers. Afterwards, the RD features and the

clinical use of materials in RD treatment are examined. Specifically, the suitability, advantages and drawbacks of the polymeric materials currently in use are outlined and discussed and, finally, a forecast for the future is presented.

2. Anatomy and Physiology of the Eye: Short Overview

The eye is a highly specialized organ devoted to the conversion of photons into spatially organized and temporally resolved electrochemical signals. The main features of eye anatomy, which is briefly described in the following sections, are shown in Figure 1.

Figure 1. Schematic of the eye showing essential features and elements.



2.1. Basic Concepts

The ocular globes, usually named eyeballs, are housed in two proper cone-shaped sockets, termed orbits, within the skull [6]. The orbit size exceeds the size of the eyeball by a considerable margin and the space between bone and ocular globe is filled by fatty tissue. The eyeball is lined with a sheet of connective tissue named Tenon's capsule, which aims to provide a smooth socket for allowing the free movement of the ocular globe. The outer walls of the eye are formed by two distinct tissue layers, the cornea and the sclera. Six extraocular muscles attach to the outer sclera serving to rotate the eye according to desired movements. The corneoscleral envelope forms a closed shell, pierced at the back of the eye by the scleral canal, through which the optic nerve leaves the eye itself. Light enters the eye through the cornea; then traverses the anterior chamber containing the aqueous humor, the pupil, the crystalline lens and the vitreous body, before striking the retina. The crystalline lens is suspended by ligaments known as zonules, which attach to inner fibers of the ciliary muscle. Variations in the tone of these muscle fibers allow the zonules to tug on the lens, so that it can change shape to alter the focal length of the eye in the course of visual accommodation. The ciliary body consists of the ciliary muscle and a highly folded and vascularized inner layer, known as ciliary processes, which secrete a colorless fluid named aqueous humor. This fluid bathes the crystalline lens, flows through the pupil to fill the

anterior chamber and finally nourish the cornea, before draining out of the eye through specialized tissues at the boundary between iris and cornea. Aqueous humor creates a positive pressure within the eye, the intraocular pressure (IOP). The retina covers about two-thirds of the inner surface of the posterior chamber, *i.e.*, the space behind the lens (Figure 1), which is filled with a transparent gelatinous solid (vitreous body).

2.2. The Vitreoretinal System

The posterior chamber of the eye consists of three distinct layers, the sclera, the choroid and the retina, surrounding the vitreous body (Figure 1). The sclera is a protective coat of connective tissue, whereas the choroid is a highly vascularized tissue providing the blood supply to retinal cells.

2.2.1. Retina

The retina is composed of nerve tissue that senses the light entering the eye; the retinal layer is separated from the choroid by Bruch's membrane. From a structural viewpoint, the retina can be divided in 10 sub-layers from the outside (adjacent to Bruch's membrane) to the inside (adjacent to the vitreous body) [7,8]: (i) retinal pigment epithelium (RPE), (ii) outer segments of photoreceptors, (iii) inner segments of photoreceptors, (iv) outer nuclear layer (cell bodies of photoreceptors), (v) outer plexiform layer (photoreceptors axons, horizontal cells' dendrites, bipolar dendrites), (vi) inner nuclear layer (bodies of horizontal, bipolar and amacrine cells), (vii) inner plexiform layer (axons of bipolar and amacrine cells, dendrites of ganglion cells), (viii) ganglion cells layer, (ix) nerve fibers layer (axons from ganglion cells traversing the retina to leave the eye at the optic disc), (x), internal limiting membrane, that separates the retina from the vitreous body.

The photoreceptors are the sensing elements of the retinal layer and can be divided into cones and rods. The outer segment of photoreceptors contains light-sensitive proteins belonging to the group of opsins. Cones and rods are sensitive to different visual conditions as they are characterized by two different pigment molecules and, therefore, by two different light-sensitive proteins, iodopsin and rhodopsin, respectively [9]. Specifically, light causes a chemical reaction with iodopsin in cones, activated in photopic or bright conditions, and with rhodopsin in rods, activated in scotopic or dark conditions. Activated photoreceptors stimulate bipolar cells, which in turn stimulate ganglion cells; the impulses run along the axons of the ganglion cells, then through the optic nerve and towards the visual centre at the back of the brain, where the image is perceived as right-side up.

There are about 6.5 to 7 million cones in each eye, and they are sensitive to bright light and to color. The cones are predominant in the central retinal region (the macula); the fovea, which is the area at the center of the macula, contains only cones and no rods. Essentially, three types of cone opsins (or pigments) can be distinguished and each one is more sensitive to a certain light wavelengths: short (430–440 nm, red region of electromagnetic spectrum), medium (535–540 nm, green region) and long (560–565 nm, blue/violet region) wavelengths. The wavelength of the light perceived as the brightest by the human eye is 555 nm (greenish-yellow). Once a cone pigment is bleached by light, it takes about six minutes to regenerate. There are 120–130 million rods in each eye, and they are sensitive to dim light, movement, and shapes, but do not detect color. The highest concentration of rods is in the peripheral retina, decreasing in density up to the macula. The rod pigment is most sensitive to the light

wavelength of 500 nm. Once a rod pigment is bleached by light, it takes about 30 minutes to regenerate. Defective or damaged cones result in color deficiency, whereas diseased rods result in difficulty in seeing in the dark. Any damage to the macular region involves an acute vision loss, whereas damage to peripheral retina causes a loss of visual field.

2.2.2. Vitreous Body

The vitreous body, often referred to as vitreous humor or simply vitreous, is essentially a clear gel composed of water, hyaluronic acid, collagen fibrils, calcium salts and plasma proteins, and occupies about 75% of the eyeball volume [10–12]. The vitreous body acts as a shock-absorber element protecting the retina from high stresses due to sudden movements, and imparts stability to eye shape and maintains the retina against the Bruch's membrane. A residual feature of fetal vitreous synthesis is the Cloquet's canal, formed by an external shell of dense gel that surrounds a liquid core. This canal hosts the hyaloid artery in the fetus, which grows outward from the end of the optic nerve into the vitreous cavity and extends forward to the crystalline lens. Normally, the hyaloid artery regresses during the last trimester of fetal formation; sometimes, however, it remains after birth without having negative effects on vision. The Cloquet's canal is linked to the posterior capsule of the crystalline lens by the Wieger's ligament; a break to the canal, due to unskillful cataract surgery procedures, allows the liquid vitreal core to flow into the anterior chamber, thereby enhancing the tendency towards posterior vitreous detachment (PVD) [6,13,14].

3. Phenomenology of Retinal Detachment

RD is a significant cause of blindness and, when it occurs, must be considered a serious medical emergency [6,15]. Typically, RD is preceded by flashes of light and/or floaters in the visual field; after its occurrence, the patients perceive a dark shadow interfering with vision.

3.1. Types and Features of Retinal Detachments

RD occurs when the retina peels away from its underlying layer of support tissue. Initial detachment may be localized, but without prompt treatment the entire retina may detach, thereby leading to progressive vision loss and subsequent blindness. Essentially, three types of RD can be distinguished: (i) rhegmatogeneous RD (RRD), (ii) tractional RD (TRD) and (iii) exudative (or serous) RD (ERD). RRD is caused by a hole, tear or break in the retina that allows vitreous fluid to pass from the vitreous cavity into the sub-retinal space between the sensory retina and the retinal pigment epithelium. TRD occurs when fibrovascular tissue, caused by trauma, inflammation or neovascularization, pulls the neurosensory retina away from the RPE. Finally, ERD occurs due to inflammation, injury or vascular abnormalities (e.g., choroid disruption) leading to fluid build-up underneath the retina without the presence of a hole, tear or break.

3.2. Risk Factors

The frequency of RD in otherwise normal eyes is about 0.005%, and mostly due to accidental ocular trauma or strong shocks to the head [1,6]. Some pathological conditions, however, can favor retinal

disorders and, in particular, RD. Severe myopia is often associated with RD cases, as extremely myopic eyes are longitudinally longer than normal ones and, therefore, have a more stretched and thinner retina. In addition, RD can occur after cataract surgery.

TRD can occur in patients suffering from proliferative diabetic retinopathy and proliferative vitreo-retinopathy (PVR) [15–18]. In both retinopathies, abnormal blood vessels (neovascularization) grow within the retina and extend into the vitreous body; in advanced disease, the vessels can pull the retina away from the back wall of the eye causing TRD. TRD may occur also in children affected by retinopathy of prematurity.

It cannot be ignored that eye structures undergo modifications over time; for instance, with age the vitreous humor changes from a gel to a liquid (vitreous liquefaction), thereby leading to PVD [13,14]. As this occurs, the vitreous mass gradually shrinks and collapses, separating and falling away from the retina; PVD, however, is a normal occurrence in people over 50. Commonly, a person having experienced PVD reports seeing flashing lights and/or floating bodies—commonly termed “*muscae volitantes*” (flying flies)—in his or her field of vision. These flashes of light occur when the vitreous tugs on the sensory layer of the retina. The floaters, which are cells or debris released during vitreous detachment, can appear as little dots, circles, lines, clouds or puffs of smoke. Although PVD is a natural age-related phenomenon, it may occur earlier than normal in extremely myopic people, being favored by the over-elongation of the longitudinal axis of the eyeball. Usually, the vitreous makes a clean break as it pulls away from the retina; sometimes, however, the vitreous may adhere tightly onto certain retinal regions creating traction points; hence, horseshoe-shaped rips in the retina can result from persistent tugging and tearing by the vitreous [5,6]. Unless the retinal tear is repaired, fluid can seep through this hole underneath the retina causing RRD.

4. Treatment of Retinal Detachment

The general schedule adopted for RD treatment comprises three fundamental steps: the surgeon must (i) detect all retinal tears, (ii) seal all retinal breaks and (iii) relieve vitreoretinal tractions.

Depending on the patient’s clinical condition and, specifically, on the features of retinal breaks, different approaches can be proposed [3,4,6,15,19,20]. Laser therapy is suitable if no separation of retinal tissues or very small RRD occurred, whereas extensive RD requires surgical treatments to reattach the neural retina to the RPE. RRDs are generally treated by employing either pneumatic retinopexy or scleral buckling, both in conjunction with retinal cryopexy/laser photocoagulation. The repair of TRDs or particularly complicated cases, involving for instance multiple retinal breaks or giant tears, also require the substitution of the vitreous with a tamponade agent (vitrectomy). A short overview of these procedures is given in the following sections.

4.1. Laser Retinopexy

When a small retinal tear occurs, laser treatment may be applied to prevent further accumulation of fluid beneath the retina, thereby minimizing the risk of extensive vision-threatening RDs. The laser is applied around the retinal hole and, over the course of a few weeks, the treated area develops a scar which forms a tight seal between the retina and the underlying tissue. This procedure is sometimes

performed around weak retinal areas in patients who may be at higher risk for RD. Laser retinopexy (endophotocoagulation) can be performed in conjunction with pneumatic retinopexy, scleral buckling and vitrectomy.

In addition, laser therapies are often used to prevent a potential RD. When abnormal retinal blood vessel growth occurs in diseases such as proliferative diabetic retinopathy or retinal vein occlusion, laser must be applied to large areas of the peripheral retina that, having poor blood flow (ischemia), are responsible for releasing growth factors causing neovascularization. If untreated, retinal neovascularization often leads to vitreal hemorrhage, neovascular glaucoma and/or TRD. After laser therapy is applied, the blood vessels tend to stabilize or regress.

4.2. Retinal Cryopexy

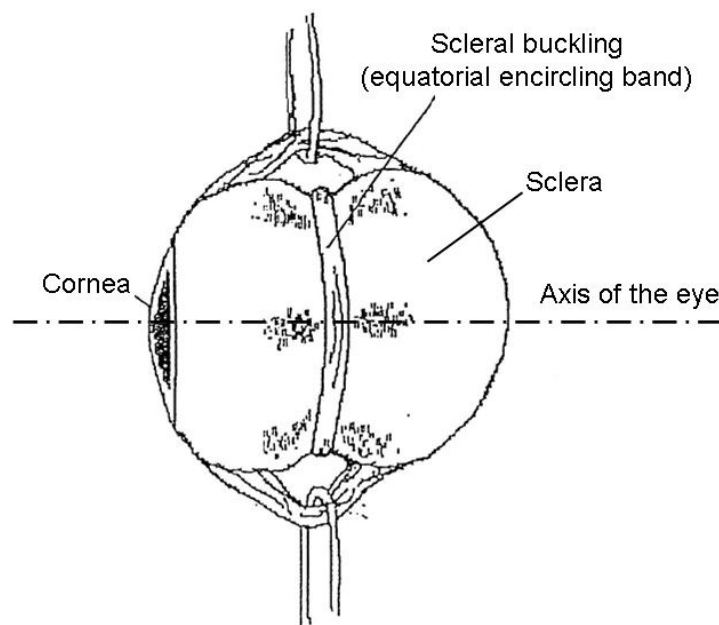
The final result of cryotherapy is similar to that obtained by laser retinopexy: in fact, cryopexy stimulates scar formation allowing the edges of a retinal tear to seal. This is typically done by looking into the eye using an indirect ophthalmoscope, while pushing gently on the outside of the eye using the cryopexy probe. The probe produces a small frozen area that includes the retina and the tissues immediately underneath it, thereby sealing the retinal tear. Cryopexy is used for treating large breaks and in areas that may be hard to reach by laser; it can be used in conjunction with pneumatic retinopexy, scleral buckling and vitrectomy.

4.3. Pneumatic Retinopexy

Pneumatic retinopexy involves the injection of an expansive gas into the eye posterior chamber to flatten the retina, thereby allowing the sub-retinal fluid to be pumped out from beneath it. The patient's head is properly positioned so that the gas bubble floats to the detached area and presses against the detachment. A freezing probe (cryopexy) or laser beam (photocoagulation) can be used to seal the retinal tear. The gas bubble is gradually absorbed by the eye while a seal forms between the retina and the underlying tissue.

4.4. Scleral Buckling

After laser photocoagulation or cryopexy has been performed to seal retinal tears, a scleral buckle may be indented on the sclera (Figure 2). The buckle closes the tear and reduces the eyeball volume, thereby preventing further pulling and separation of the vitreous from the retinal layer. Depending on the RD severity, a buckle may be local (segmental buckle is often called "plombage") or placed around the entire eyeball (equatorial encircling band, as shown in Figure 2). Afterwards, the subretinal fluid, which could interfere with the retina reattachment, is usually drained and the buckle is sutured to the sclera to hold it in place. An inevitable side effect of scleral buckling procedures is myopic shift [21]. Usually, the buckle remains in place for the patient's lifetime and it does not interfere with vision. Temporary buckles can alternatively be chosen, for instance in children to allow eyeball growth, but they need to be surgically removed later.

Figure 2. Scheme of scleral buckling for treating retinal detachment.

4.5. Vitrectomy

Vitrectomy involves the partial or total removal of vitreous humor and its temporary substitution with a gaseous (rarely) or liquid tamponade agent; semisolid or gelatinous vitreous substitutes have also been experimentally tested. This procedure is necessary to clear blood and debris from the eye, to remove scar tissue and to eliminate tractions on the retina. Blood and debris, such as due to vitreous hemorrhage, obscure light as it passes through the eye, thereby resulting in blurred vision. In addition, in some cases of RD, the surgeon's view of the damage might be hindered by bleeding inside the eye and, therefore, vitrectomy in conjunction with scleral buckling must be performed. Vitrectomy is typically performed in treating TRD, as in this case the vitreous pulls away and tugs the retina from its normal position.

5. Materials for Pneumatic Retinopexy

The procedure of pneumatic retinopexy is commonly considered a good surgical option for treating uncomplicated RRDs with a 90% success rate, but often repeated operations are necessary. Table 1 summarizes and compares the advantages and disadvantages of gases used in pneumatic retinopexy procedures.

The first procedure of pneumatic retinopexy was attempted in 1911 by Ohm [22], who injected purified air into the vitreous cavity to adhere the retina to the inner wall of the eye. Air, however, cannot be used as a long-term vitreous substitute, as its intravitreal residence time only lasts a few days [4]. In recent years, air has only occasionally been used in pneumatic retinopexy procedures [23,24]. It has been used in conjunction with other vitreous tamponade agents during vitrectomy procedures, but some evidences suggested that its use is unhelpful [6,25]. Furthermore, air can be used in the course of the so-called D-ACE procedure (Drain, Air, Cryotherapy, Explant) [26].

Table 1. Gases used in the course of pneumatic retinopexy procedures.

Gas	Advantages	Drawbacks	References
Air	Absence of toxicity.	Short persistence time in the vitreous cavity (<5 days). Partial retinal reattachment.	[4,22–26]
SF ₆	Absence of toxicity. Retinal reattachment approximately >90% (today).	Transient IOP rise (from moderate to high). Glaucoma. Cataract.	[27,31,32, 191,192]
SF ₆ /air blends	Analogous to SF ₆ alone.	Analogous to SF ₆ alone.	[33]
Perfluorocarbon gases (PFCGs)	Absence of toxicity. Retinal reattachment approximately >90% (today).	Transient IOP rise (from slight to moderate). Cataract.	[28–30, 191,192]
PFCG/air blends	Analogous to PFCG alone.	Analogous to PFCG alone.	[34]
Xenon	Absence of toxicity. 100% retinal reattachment.	Very short persistence time in the vitreous cavity (<1 day).	[35,36]
Rare gases (argon, helium), CO ₂ , N ₂ O.	Absence of toxicity.	Short persistence time in the vitreous cavity (comparable to air).	[35]

In the early 1970s, Norton used sulfur hexafluoride (SF₆) for pneumatic retinopexy and found the persistence of gas and its expansive features superior to air [27]. In 1980 Lincoff *et al.* [28] proposed the use of perfluorocarbon gases (PFCGs), *i.e.*, C₂F₆, C₃F₈, C₄F₈ and C₅F₁₂; their advantages over SF₆ include a lower requirement of intravitreal injected volumes due to increased expansion and longer persistence thanks to their low solubility [29]. Thus, the use of PFCGs may result in a lower rise in initial IOP than that evaluated with SF₆ (acute glaucoma) because of the smaller injected volume. In addition, their increased persistence (approximately one week *versus* 3–4 days) allows prolonged tamponade, thereby promoting the formation of secure chorioretinal adhesions. Major drawbacks of such gases are the need for patient's post-operative posturing to exert the maximum tamponade effect and the persistence of quite high IOP values that can result in damage to the optic nerve. In addition, cataract formation and damage to ciliary body and retina, especially due to the use of C₃F₈, may occur [30]. SF₆ and PFCGs have been also experimented with for vitrectomy procedures [31,32], but other vitreous substitutes have been found more suitable for such surgery, as will be described later.

Blends of SF₆/air or PFCG/air (with air content <30% vol.) were also used with similar success rates to those obtained by using solely SF₆ or PFCGs [33,34].

Lincoff *et al.* tested a wide series of gases in an animal model, including argon, helium, xenon, N₂O and CO₂, to measure disappearance times [35]. Xenon was also tested in four human patients with excellent clinical outcomes (100% retinal reattachment) [36]. Generally these gases disappeared very rapidly (for instance, in the case of xenon, almost 90% in 3 hours postoperatively) and it was necessary to replace them with aqueous solution; this two-step operative procedure has been abandoned and, at present, SF₆ or PFCGs are the gases of choice for surgeons.

6. Materials for Scleral Buckling

In 1937, Jess performed what may be considered the first scleral buckling by using a gauze pad to temporarily indent the eye wall for approximating the retinal layer with the choroid [37]. The implant was removed after a few weeks and no ocular tissue reactions were reported. Since then, several materials and design styles have been proposed for manufacturing scleral implants. Basically, scleral buckles may be categorized in two classes: (i) permanent implants and (ii) absorbable devices. Materials tested over the years for manufacturing buckles are listed in Table 2 and Table 3. At present, only silicone implants are commercialized and routinely used in clinical practice, and all other non-absorbable devices have progressively fallen into disuse.

Degradable implants in general carry a higher number of problems and less advantages in comparison with permanent ones, and until now all have only been tested experimentally.

6.1. Permanent Buckles

6.1.1. Implants Fallen in Disuse: Historical Overview

Table 2 qualitatively summarizes the complications encountered using different buckling materials proposed in the literature over the years, but have fallen into disuse; silicone is not included here as it will be treated separately in the next section.

Almost 20 years after the procedure reported by Jess [37], Custodis tested a polyviol band as a scleral buckling element [38,39]. After compression over sclera, the implant could expand *in situ* postoperatively, thereby allowing the closure of retinal breaks and the retina reattachment. However, polyviol elicited serious adverse reactions in the ocular tissues was thus not considered suitable for clinical use.

Table 2. Scleral buckling materials having progressively fallen into disuse (chronological order).

Material	Long-term Complications ^a							References ^b
	Scleral Erosion	IOP Increase	Adverse Tissue Response	Friability	Migration, Extrusion	Foreign Body Sensation	Persistent Pain	
Polyviol		+++	+++					[38,39]
Polyethylene	+++	+++						[40–42]
Nylon threads	+++		+					[44,45]
Solid PTFE	++	++	+					[46–48]
Polyester	++		+					[49,50]
Hydrogels				+++	+	+	+	[51–59]
Porous PTFE	+	+	++			+	+	[60–64]
PTFE-coated silicone	+	+	++			+	+	[65–67]

^a Legend: ‘+’ = rare/negligible problem; ‘++’ = occasional/mild problem; ‘+++’ = serious problem.

^b Citation numbers are referred to in the main text.

In response to the failure of polyviol, in the mid 1950s Schepens proposed polyethylene (PE) tubes as encircling scleral elements: PE could be easily manufactured to produce buckles of different diameters, that could easily be tensioned *in situ* by means of a suture placed in the tubing lumen [40,41]. However, Regan reported that the hardness and rigidity of PE tubes exerted too severe a pressure on the ocular globe and, furthermore, the narrow bearing surface of tubes eventually caused erosion of the underlying sclera and choroid [42].

In order to overcome the drawbacks related to PE tubes, in the late 1950s the use of silicone elements was proposed for the first time by Girard *et al.* [43]; this material remains the best choice today and is described in the next section.

As an alternative to PE, in 1958 nylon braided threads were also proposed for scleral buckling [44]: they were not properly used as a “buckle” but rather for suturing the wall of the eye to create a “fold” which then created a buckling effect. This solution was soon abandoned due to scleral inflammation and erosion [44,45].

Solid polytetrafluoroethylene (PTFE) was tested in the mid 1960s by Wolter *et al.* [46,47], but Deodati *et al.* showed that Teflon implants exhibited similar complications to those encountered with PE tubes [48]. Analogous problems were also encountered by using polyester bands as cerclage elements in the early 1970s [49,50].

A particular mention should be made to hydrogel implants, as they were considered superior to silicone implants for almost 20 years (from their introduction in the mid 1970s to their progressive abandonment in the 1990s), especially as they were softer and seemed to carry a lower risk of infection (less than 1% vs. 2–5%) [51,52]. Specifically, three types of hydrogels, *i.e.*, poly(glyceryl methacrylate) (PGMA), poly(2-hydroxyethyl acrylate) (PHEA), and poly[methyl acrylate-*co*-(2-hydroxyethyl acrylate)] (MAI), have been widely investigated [53]. Major advantages of hydrogels are softness, defined swelling under hydration and the potential to act as devices for the controlled release of hydrophilic drugs [54], which is an advantage over solid silicone implants in controlling infection. PGMA was found to suffer from lack of tensile strength when swollen, whereas PHEA exhibits a dramatic tendency to fragment after swelling [55]. MAI, which is commercially sold as Miragel, offers better bulk features and can promote the formation of a strong surrounding capsule [53,54]. Although Miragel has been considered by many surgeons as the ideal solution for scleral buckling, fragmentation of such implants can occur after 10-year follow-up [55–58], as well as buckle overexpansion [56,59], with an associated risk of severe long-term complications (persistent pain, foreign body sensation) and the need of re-operation for implant removal.

Porous expanded PTFE (e-PTFE) was proposed in the form of buckling bands [60–64] or, more recently, as coating on silicone implants [65–67] with variable and controversial outcomes. Potentially, the material could be an alternative to silicone, but further studies of its performances and effects *in vivo* are necessary.

For the purpose of completeness, it is interesting to mention an approach attempted in 1977 by Gloor, who used a silver clasp as an episcleral buckle [68]. The implant was removed after six months due to the pain experienced by patients and to avoid severe eyeball deformations. It should be underlined that, apart from the cotton gauze used by Jess in 1937, this is the only other case involving the use of non-polymeric materials for scleral buckling.

6.1.2. Routinely Used Implants in Clinical Practice

At present, silicone is commonly considered the material of choice in scleral buckling procedures and a wide range of silicone implant styles (over 70) are commercially available for ophthalmic surgeons worldwide. Silicone is a synthetic rubber compound, hydrophobic and highly stable within a wide temperature range. The first silicone scleral buckle, employed by Girard *et al.* in 1959, was a simple rod-shaped element [43]; since then, more than 70 silicone-based implant designs have been developed by surgeons. It has been extensively demonstrated that silicone implants are economical, soft, biochemically inert, non-allergenic and generally well-tolerated by the body.

In vivo they remain soft and flexible, thereby avoiding scleral erosion as shown by PE implants [42]. It is interesting to underline that the changes in silicone implant design have been “evolutionary” rather than “revolutionary”: in fact, many surgeons have contributed their design inputs and have built on the success of their predecessors to achieve new design ideas, and each silicone element has been carefully thought out and developed to meet a specific need, e.g., short surgery time, low cost, indentation depth.

The smoothness of silicone material and the implant rounded contour lead to the development of a tough, collagenous capsule around the implant [69]; at first vascularized, the capsule eventually becomes avascular and translucent over time. In episcleral implants the capsule seals off the buckle, thereby helping to minimize the risk of later infection. As regards intrascleral implants, the capsule also grows between the implant and sclera, thereby giving further protection against scleral erosion [70]. Because dense silicone does not allow tissue in-growth, the implant can easily be taken out in one piece without too much trauma, if removal becomes necessary [71,72].

Silicone sponge buckles, introduced by Lincoff *et al.* for treating large retinal tears [73] are closed-cell foams which have the same chemical composition as solid silicone implants. With respect to dense implants, silicone sponges are designed to be more elastic and to produce a more even buckling effect, which usually increases postoperatively [74]; in addition, the sponges can be impregnated with antibiotics to limit the bacterial colonization of the implant [75]. In most cases silicone sponges are used as episcleral implants, but they can also be placed under scleral flaps if desired.

Although silicone implants are generally considered as “the gold standard” solution for scleral buckling, and rightly so they can occasionally induce some or even all the long-term complications listed in Table 2, as underlined by recent studies [76,77].

6.2. Absorbable Implants

Degradable buckles have been experimented with to overcome the long-term problems related to permanent implants (Table 2), as they are replaced by scar tissue in the normal course of tissue turnover; this process normally takes from a few weeks to a year or more postoperatively depending on the degradation rate of the chosen material. At present, no absorbable buckles are commercially available, and they have only been used as experimental implants.

The major problem with absorbable buckles relates to the ability to retain the buckling effect over time, as the duration of their scleral indentation must be sufficient to allow complete retinal reattachment (anatomic success of the operation).

A wide range of absorbable materials of biological or synthetic origin were tested to achieve a temporary buckling effect; Table 3 gives a qualitative overview of the suitability of different absorbable buckles tested over the years. Biological materials were derived from human or animal tissues, and they were used to perform transplants (autografts, allografts and xenografts) or properly treated to obtain suitable substances, e.g., gelatin or fibrin. Autologous tissues, e.g., patient's tendons [78] or fascia lata tensor muscle [79–81], were proposed to avoid rejection, but such implants require extra-surgery procedures for graft harvesting. Allografts from cadavers, e.g., freeze-dried samples of sclera [82–85], skin [86,87], dura mater [88] or pericardial tissue [89], have been experimented in the past, but they carried the risk of host rejection and diseases transmission from the donor to the patient; therefore, there has only been occasional experimental use of allografts in the last decade [89]. In addition, allografts exhibited generally low elasticity, which limits the ability of accurately tailoring buckles' size and shape. Gelatin sheets derived from pig skin or bone xenografts were widely tested as buckling elements by Schepens and co-workers [90–92] and other groups [93–97], but such grafts revealed problems analogous to those carried by allografts. Fibrin rods were also tested by Grosz *et al.* [98] and Wollensak *et al.* [99] with bad clinical results, as the retina remained partially detached postoperatively due to the short duration of scleral indentation (<1 month).

Table 3. Scleral buckling using absorbable implants.

Origin	Material Type	Adverse Tissue Response ^a	Persistence of Indentation ^b	References ^c
Biological	Surgical gut	+ / ++	● / ●●	[100–104]
	Gelatin	+ / ++	●●	[90–97]
	Tendon	+	●●	[78]
	Fascia lata	+	●●	[79–81]
	Sclera	+	●●	[82–85]
	Fibrin	+	●	[98,99]
	Skin	+ / ++	●●	[86,87]
	Dura mater	+	●●	[88]
	Pericardial patches	+	●●	[89]
	Synthetic	PGA	+	●
PGA/PLA		+	●●	[97,108,109,113]
PDO		+	●●	[97,114,115]
PU		+ / ++	●●●	[116,117]
PLA		+	●●●	[110–112]

^a Legend: '+' = rare/negligible/found in the very early postoperative period; '++' = occasional/mild/found in the early postoperative period; '+++' = serious/persistent.

^b '●' = too short (< 1 month); '●●' = generally sufficient for retinal reattachment; '●●●' = long (>1 year).

^c Refer to the main text for citation numbering.

An interesting approach was attempted in dogs by Dellaporta, who used surgical gut sutures as encircling elements placed within scleral folds to create a temporary indentation [100]. However, after a series of experiments [100–104], this solution was abandoned as the operative technique could involve clinical complications (inflammation of choroid and ciliary body) and the duration of the buckling effect was highly variable (the indentation was found to persist from one week up to five months).

Temporary buckles involving the injection of air [105], autologous fat [106] and hyaluronic acid [107] into the suprachoroidal space were also occasionally attempted; however, this approach was soon abandoned as the surgical procedures could lead to choroid perforation and haemorrhage; the control of buckle size and shape was very poor; and the buckling effect was limited to a few days.

In order to overcome the problems related to biologically-derived absorbable buckles, some synthetic polymers were proposed in the last three decades for manufacturing buckling elements; specifically, five materials were tested *in vivo*: poly(glycolic acid) (PGA) [97,108,109], poly(lactic acid) (PLA) [110–112], PGA/PLA composites [97,108,109,113], polydioxanone (PDO) [97,114,115] and polyurethane (PU) [116,117]. In general, they exhibited some advantages in comparison with biological materials; eliciting minimal or no adverse reactions; offering controllable and predictable absorption kinetics; and being easily shapeable to obtain an implant of desired size and design. Until now, all these polymers were used only experimentally in a limited number of cases (rabbits or humans) and the reports of research are still incomplete. As preliminary results are very promising (especially for PLA [110–112] and PU [116,117] buckles), further systematic experimentation is warranted to investigate their actual suitability for clinical use in humans.

7. Materials for Vitrectomy

Gases are unsatisfactory as long-term tamponade agents because of their short residence time in the vitreous cavity; for this reason, liquids or gelatinous solids, that can respond to head movements maintaining a tamponade effect, should be used in the case of prolonged vitreous substitution. In the course of surgical procedures aiming to treat RD, vitreous substitution may also be combined with scleral buckling.

As outlined by Chirila and co-workers in two fundamental works [118,119], an ideal vitreous substitute should be (i) non-toxic and biocompatible with ocular tissues, (ii) clear and transparent with refractive index and density similar to those of natural vitreous, (iii) biologically and chemically inert, (iv) sufficiently rigid to act as an effective tamponade agent, (v) able to allow the transfer of metabolites and proteins, (vi) preferably non-absorbable and non-biodegradable in order to be maintained in the vitreous cavity for as long as possible, (vii) preferably hydrophilic and insoluble in water, (viii) injectable through a small-gauge needle, (ix) able to maintain its properties after injection, (x) storable and sterilizable without losing the above-mentioned properties.

At present, such materials able to fulfill this set of requisites do not exist, which makes research for an ideal vitreous substitute more and more stimulating and challenging.

7.1. Routinely Used Vitreous Substitutes

7.1.1. Silicone Oils

Since the 1960s, different types of silicone oils (SiOs) have been widely used in the management of complicated forms of RD requiring vitrectomy; such as cases complicated by PVR or proliferative diabetic retinopathy [15,16]; giant retinal tears/vitreous tractions (TRD) [120,121]; or inferior RRD [122]. The use of SiOs as a vitreous substitute for treating RD cases was extensively reviewed by Giordano *et al.* in a fundamental treatise [123], to which the interested reader is referred for more details.

SiOs belong to the class of polydimethylsiloxanes and exhibit excellent stability and transparency; their main physical features are reported in Table 4. The hydrophobic nature of SiOs emphasizes its tamponade effect, thereby ensuring the closure of retinal holes and reducing sub-retinal leakage; the oil resides in the vitreous cavity until it is surgically removed. When the silicone liquid is injected into an aphakic or pseudophakic eye, the oil has access to the anterior chamber and corneal complications may occur, probably because access to nutrients is blocked [124]. Other problems such as angle-closure or pupillary-block glaucoma, inflammation and keratopathy may also be associated with SiOs [121,123]. In order to reduce the risk of pupillary-block glaucoma and to keep the anterior chamber free of silicone in aphakic eye, it is necessary to avoid overfilling and, in addition, inferior peripheral iridectomy can be helpful to allow the silicone globules to return to the vitreous cavity when the patient is in the prone position [125]. Cataract may eventually develop in phakic eyes because of blocked nutrient diffusion across the posterior lens capsule (incidence usually within 6–18 months after surgery) [126,127]. The low density of SiOs (Table 4) causes it to float upon the residual vitreous fluid, which involves a reduced tamponade effect in the case of inferior retinal breaks. In such a situation, placing the patient in the prone position is required. It was demonstrated that residual components of polymerization reactions can diffuse into the retina, thereby causing acute cytotoxicity [128]. The tendency towards oil dispersion and emulsification is the major problem, as cells containing silicone vesicles revealed alteration in their metabolic activities [129]. Emulsification can be successfully reduced by using high-viscosity (>4000 cSt) oils [121,123,129].

Fluorosilicone oil (FSiO) has physical properties similar to those of SiOs, but exhibits a higher emulsification rate and lower intraocular tolerance [123]. FSiO and silicone/fluorosilicone copolymer oil can be useful as intraoperative tools and short-term tamponade agents (<2 months), but they are not recommended for prolonged retinal tamponade due to possible complications, including cataract, glaucoma, uveitis and keratopathy.

7.1.2. Perfluorocarbon Liquids

Perfluorocarbons with more than five carbon atoms in their molecule are liquid at room temperature; their main physical properties (at 20 °C) are reported in Table 4. Perfluorocarbon liquids (PFCLs) for ophthalmic use have been reviewed in detail elsewhere [130]. The higher density of PFCLs in comparison to that of SiOs also allows tamponade of inferior retinal breaks; this feature, together with high transparency, low viscosity and inert behavior, would seem to make PFCLs excellent material for long-term vitreous substitutions [128,130]. In addition, recent studies

demonstrate that they can be successfully used instead of silicone oil, also in RD cases complicated by PVR [131]. However, it cannot be ignored that their persistence over more than four days postoperatively leads to severe complications. In general, the drawbacks related to PFCLs seem to be due to their high density, resulting in mechanical damage to cells through compression and extensive emulsification, rather than to an intrinsic material toxicity [130]. Reported problems include secondary glaucoma from retained intraocular PFCL, as well as central scotomas from retained subfoveal PFCL [132,133]. Toxicity to the RPE and photoreceptors was demonstrated in an animal model with retained subretinal PFCL [134]; other research demonstrated stromal inflammation, loss of endothelial cells and corneal vascularization in aphakic rabbit eyes that were injected with PFCLs [135]. The presence of intravitreal PFCL in rabbits has been shown to cause retinal atrophy with severe thinning of the outer plexiform layer and damage to photoreceptors. Risk factors for retained subretinal PFCL include large peripheral retinotomies greater than 120°, as well as lack of a rinse by saline solution after PFCL removal [136].

Table 4. Typical physical properties of the routinely used vitreous substitutes compared with human vitreous.

Material	RI	Density (g/cm ³)	M _w (Da)	Viscosity (cSt)	References
Silicon oil	1.380–1.404	0.97–0.98	40000–80000	1000–10000	[120,123,128]
Perfluorocarbon liquids	1.20–1.40	1.5–3.0	350–1000	2–5	[128,130]
Human vitreous humor	1.3345–1.3348	1.0053–1.0089	5000000	4–5	[10–12]

7.2. Experimental Vitreous Substitutes

At present, PFCLs are commonly used as short-term substitutes during intraoperative procedures, whereas the preferred agent for prolonged vitreous tamponade remains SiOs. The search for an ideal vitreous substitute, able to actually mimic the features of natural vitreous, is currently in progress; Table 5 summarizes the features of the experimental vitreous substitutes proposed in the literature to date.

It is worth mentioning that the first selection criterion for a material is its optical properties, as a potential vitreous substitute must primarily be clear and transparent to the light. Besides the optical suitability, other properties should be taken into account to evaluate if a specific polymer is a good candidate for vitreous substitution: in this context, the main advantages and drawbacks of the materials listed in Table 5 will be discussed and compared in the following subsections. If available in the literature, quantitative assessment of physical properties of potential vitreous substitutes will also be reported.

7.2.1. Natural Materials

Chronologically, healthy animal donor vitreous was the first material used for vitreous replacement at the beginning of the 20th century, when Deutschmann injected calf and rabbit fresh vitreous into human patients' eyes [137]. Then, human donor vitreous [138,139], or water and physiological solutions [140–142], were also used. No relevant differences in the clinical outcomes were found

between using physiological solutions or donor vitreous. There is a great variability in the reported performances of such agents: in many cases, they were found suitable for the immediate treatment of RD cases, but they failed in the long-term due to postoperative complications, e.g., inflammation of the ocular tissue, cataract, corneal damage, glaucoma and various retinopathies; in addition, their short residence time in the vitreous cavity often did not allow the prolonged flattening of the retina to achieve its complete reattachment.

At present, water-based balanced salt solutions are used only for intravitreal washes in the course of vitreoretinal surgery procedures or after removing other vitreous substitutes such as SiOs [143]. In order to overcome the above-mentioned drawbacks, research progressively moved towards semisynthetic polymers, *i.e.*, modified natural polymers.

7.2.2. Semisynthetic Polymers

As shown in Table 5, the failure of semisynthetic polymers as effective vitreous substitutes was mainly due to them lacking a mid/long-term tamponade effect. This was essentially attributable to their rapid bioabsorption and/or biodegradation *in vivo*; in addition, their physical and mechanical properties were generally poorer than those of natural vitreous.

Collagen

Proctase-treated collagen gel was the first semisynthetic polymer used for vitreous substitution; the choice of collagen seemed reasonable as it is one of the two major components of natural vitreous. Preliminary studies in rabbits by Stenzel *et al.* [144] and in monkeys by Dunn *et al.* [145] showed that the material was generally well tolerated by ocular tissues with mild transient inflammation.

In the early 1970s, collagen gels were tested in humans by Pruett *et al.* [146,147]: a moderate inflammation of ocular tissues was reported, together with other severe complications related to clinical outcomes; in fact, only 19% of the cases exhibited retinal reattachment and all patients recovered only partial vision, due to vitreous opacification causing blurred vision in the patients. In addition the gel underwent fragmentation during injection, thereby decreasing its mechanical properties.

More recently, the use of methylated type I/III collagen overcame some of these drawbacks [148,149]: in fact, after implantation in rabbits, no inflammation and no vitreous/lens/cornea opacification were detected. However, the poor surface tension for tamponading effect made this polymer unsuitable for RD treatment.

Gelatins

Polygeline, a modified gelatin (RI = 1.3390, M_w = 35 kDa), was implanted in both rabbits [150] and humans [151]. The material was generally well-tolerated without adverse tissue reactions and the immediate retinal reattachment was successful in most patients. However, polygeline exhibits a short retention time in the vitreous cavity and a rapid decrease of its viscosity. Attempts to increase the viscosity by adding gelatin, agar, methylcellulose and poly(ethylene glycol) caused inflammation and cloudiness in the vitreous. Therefore, polygeline could be useful only as a short/mid-term vitreous substitute. However, due to its good biocompatibility and excellent optical properties, the material justifies further investigations.

Very recently, Lai investigated the ocular biocompatibility of two chemically modified gelatin hydrogels [152]. The material was not specifically proposed as a vitreous substitute—gelatin was injected in the anterior chamber of rabbit eyes and its use as a controlled drug delivery agent was suggested—but this could be warranted after further studies. The gelatin was cross-linked with glutaraldehyde (GTA) or 1-ethyl-3-(3-dimethyl aminopropyl)-carbodiimide (EDAC); a significant inflammatory reaction was elicited by the presence of GTA-treated material, whereas EDAC-cross-linked gelatin hydrogel exhibited good biocompatibility and was well-tolerated without causing toxicity or other adverse effects. No other studies on such materials are available in the literature, but the results obtained for EDAC-treated gelatin makes this hydrogel worthy of further investigations.

Sodium Hyaluronate and Other Polysaccharides

Sodium hyaluronidate has been extensively tested as a vitreous substitute in humans since the early 1960s [153]. Like collagen, its use was considered since this biopolymer is present in natural vitreous. Sodium hyaluronidate is commercially available in a wide range of pharmaceutical grade solutions, and it showed an excellent biocompatibility and tolerance in ocular tissues. However, these solutions were not suitable for vitreous substitution due to their short residence time in the vitreous cavity and their poor tamponade effect [154]. Recently, longer residence times were observed after cross-linking sodium hyaluronate with divinyl sulfone or formaldehyde, but some problems still remained [155].

It is worth giving a special mention to the so-called “reconstituted vitreous”, a mixture of sodium hyaluronidate and collagen that are the two major structural components of the vitreous body [156]. The basic idea was fascinating, as the researchers’ aim was to mimic nature by duplicating both the composition and the structure of the natural vitreous. After injection at low temperature (~10 °C) the mixture can undergo gelification *in situ* at body temperature. However, *in vivo* studies revealed problems of gel hazing during postoperative follow-up and, occasionally, ocular tissue inflammation; in addition, the material was completely bioabsorbed within five months.

Occasionally, various solutions of different polysaccharides, e.g., dextrin, alginic acid and chondroitin sulfate, was tested as vitreous substitutes in rabbits and humans [157,158]; generally, no or slight inflammation was reported, but the vitreous underwent opacification and often the material failed to reattach the retina.

Gellan Gum/Hyaluronic Acid Gel

Recently, Suri *et al.* mixed gellan gum with hyaluronic acid and proposed it as a short-term vitreous substitute [159]. Gellan gum forms a gel at room temperature and the gel structure is maintained also at body temperature. Preliminary *in vitro* tests carried out by using mouse fibroblast cells showed an excellent biocompatibility (cells viability >90%). However, the rheological and mechanical properties seem to be dramatically insufficient compared to those of natural vitreous. The mechanical properties can be improved by adding CaCl₂ to the gellan gum/HA mixture in order to obtain a highly cross-linked hydrogel. Further *in vivo* studies are undoubtedly necessary to evaluate the properties and performance of this promising material in detail.

Table 5. Features of experimental polymeric vitreous substitutes.

Material		Recipient	Transparent ^b	Hydrophilic ^b	Non- absorbable/ non- degradable ^b	Mechanical similarity to natural vitreous ^b	<i>In situ</i> gelification ^b	Non-traumatic implantation ^b	Injectable without degradation ^b	No mid/long- term clinical complications ^b	References ^c
Origin/class	Type ^a										
Natural	Animal vitreous	Human	+	+	×	+	×	+	+	×	[137]
	Human vitreous	Human	+	+	×	+	×	+	+	×	[138,139]
	Water and physiological solutions	Human	+	+	×	×	×	+	+	×	[140–143]
Semisynthetic polymers	Proctase- treated collagen	Rabbit, monkey, human	+	+	×	+	×	+	×	×	[144–147]
	Methylated collagen	Rabbit	+	+	×	+	×	+	+	+	[148,149]
	Polygeline	Rabbit, human	+	+	×	+	×	+	+	+	[150,151]
	Sodium hyaluronate	Human	+	+	×	×	×	+	+	+	[153–155]
	Sodium hyaluronate + collagen	Monkey	+	+	×	+	+	+	+	+	[156]
	Gellane gum + hyaluronic acid	<i>In vitro</i> tests only	+	+	×	×	+	+	+	–	[159]

Table 5. Cont.

Material		Recipient	Transparent ^b	Hydrophilic ^b	Non- absorbable/ non- degradable ^b	Mechanical similarity to natural vitreous ^b	<i>In situ</i> gelification ^b	Non-traumatic implantation ^b	Injectable without degradation ^b	No mid/long- term clinical complications ^b	References ^c
Origin/class	Type ^a										
Synthetic polymers	PVP	Rabbit, human	+	+	×	+	×	+	×	+	[160–164]
	VP/HEMA copolymer	Rabbit	+	+	×	+	×	×	×	×	[165]
	PAA	Rabbit	+	+	+	+	+	+	+	×	[166–172]
	PGMA	Rabbit	+	+	+	–	×	+	×	+	[173,174]
	PHEA	Rabbit	+	+	–	–	+	+	+	×	[143]
	PHEMA	Rabbit	+	+	+	–	×	×	×	+	[175]
	Silicone gel	Monkey	+	×	+	–	+	+	+	+	[176]
	HPMC	Rabbit	+	+	×	×	×	+	+	+	[177,178]
	Pluronic F127	Rabbit	+	+	×	+	×	+	×	×	[179–181]
	PMAGME	Rabbit	+	+	+	+	×	+	+	×	[182]
	PVA	Rabbit, monkey	+	+	×	+	×	+	+	+	[183–185]
	PVA-MA	<i>In vitro</i> tests only	+	+	×	×	+	+	+	–	[186]
	Adcon-L hydrogel	Rabbit	+	+	×	–	×	+	+	×	[187]
SFAs	Human	+	×	+	–	×	+	+	+	[188–190]	

^a Acronyms: PVP = poly(1-vinyl-2-pyrrolidone); VP = 1-vinyl-2-pyrrolidone; HEMA = 2-hydroxyethyl methacrylate; PAA = polyacrylamide; PGMA = poly(glyceryl methacrylate); PHEA = poly(2-hydroxyethyl acrylate); PHEMA = poly(2-hydroxyethyl methacrylate); HPMC = hydroxypropyl methylcellulose; PMAGME = poly(methyl 2-acrylamidoglycolate methyl ether); PVA = poly(vinyl alcohol); PVA-MA = poly(vinyl alcohol methacrylate); SFAs = semifluorinated alkanes.

^b Legend: ‘+’ = the material exhibits the property; ‘×’ = the material does not exhibit the property; ‘–’ = data not assessed/not available in the literature.

^c References refer to numbering in the main text.

7.2.3. Synthetic Polymers

In general, problems encountered by using semisynthetic polymers taught the following lesson: “It is impossible, at present, to duplicate nature and find a material able to simultaneously reproduce the structure, composition and performance of natural vitreous humor”. Therefore, the “*fil rouge*” of current research has been progressively addressed to find/synthesize highly biocompatible polymers able to duplicate the functional properties of natural vitreous, rather than its structural ones.

It is worth underlining that also SiOs, from a formal viewpoint, are synthetic polymers, but this has already been covered in the previous section devoted to routinely used materials.

Poly(1-vinyl-2-pyrrolidone)

Poly(1-vinyl-2-pyrrolidone) (PVP) was the first synthetic polymer to be tested as a potential vitreous substitute. In the 1950s, PVP solutions with different dilution rates were injected in rabbits' and human eyes [160,161]: PVP exhibited a good biocompatibility, induced less inflammatory reactions than physiological solutions or air but had short retention time in the vitreous cavity; in addition, problems of vitreous opacification were also reported. No other studies on the use of PVP as such are available in the literature. The 1-vinyl-2-pyrrolidone (VP) monomer was polymerized with divinyl glycol (DVG) as cross-linking agent, thereby obtaining a transparent (RI = 1.3390) hydrogel with density and viscosity very similar to those of human vitreous [162,163]. The cross-linked PVP was implanted in rabbits: no damage to the retina was detected, but vitreous opacification occurred; in addition, the polymer underwent biodegradation due to phagocytosis [164]. VP was also copolymerized with 2-hydroxyethyl methacrylate (HEMA) using DVG or diallyl ether (DAE) as cross-linking agents and the resulting hydrogel was implanted in rabbits [165]. This gel was transparent, insoluble in water and exhibited mechanical properties close to those of natural vitreous. From a clinical viewpoint, no particular complications were detected after implantation, with the exception of transient vitreous opacities. However, the process of injection via a small-gauge needle caused polymer fragmentation resulting in a decrease in the hydrogel mechanical properties. In addition, all eyes were characterized by the presence of inflammatory cells and vacuoles containing granular material, which indicates that material phagocytosis occurred [164].

Polyacrylamide

Acrylamide as such is known to be toxic and carcinogenic, but after careful and complete polymerization, the resulting polymer appears to be biocompatible; obviously, the presence of residual monomer can have serious effects *in vivo* on patients' health.

A series of clinical trials concerning the use of polyacrylamide (PAA) as a vitreous substitute in rabbits' eyes were reported by Muller-Jensen *et al.* [166]. The monomers were polymerized directly inside the vitreous cavity without using cross-linking agents: irritation was observed in all cases in the first postoperative days and the vitreous underwent opacification at high PAA concentrations. However, no histological degeneration was observed within three months after implantation. Cross-linked PAA was also implanted in rabbits' eyes after *in situ* polymerization with better clinical outcomes [167]: the material was well-tolerated by tissues and remained clear during the postoperative

follow-up (14 months). A detailed investigation of the optical properties of cross-linked PAA was reported by Refojo *et al.* [168].

For many years, no further study was carried out on the use of PAA as a potential vitreous substitute, but recently acrylamide and bisacryloylcistamine (BAC) were copolymerized with disulfide cross-linking agents [169–172]. The use of disulfide cross-linkers enabled a high purification of the final polymer by removing all residual monomers. Two procedures are possible for implantations: the gels can be formed directly in the eye, or else the final polymer can be injected into the vitreous cavity without undergoing fragmentation or loss of elasticity and mechanical properties, as demonstrated by preliminary tests carried out by using cadaver human eyes. Furthermore, *in vitro* tests showed that the biocompatibility of the gel can be further improved by adding N-phenylacrylamide, *i.e.*, a hydrophobic monomer [170]. This final gel is undoubtedly worthy of further investigations *in vivo* and is a promising candidate for vitreous substitution.

Poly(Glyceryl Methacrylate)

Refojo's group was the first to demonstrate the biocompatibility of PGMA in ocular tissues and to propose its use as a scleral buckling material—as mentioned above—and for vitreous tamponade [173]. Spherical pieces of dehydrated PGMA were implanted in rabbits' vitreous cavities through a small surgical incision and the implants swelled *in situ* after contact with vitreous fluids, thereby reaching postoperatively volumes up to 32-times greater than the initial ones in the dry state. No inflammation or postoperative complications were detected, however the hydrogel was considered unsuitable for clinical use as its implantation was too traumatic and its swelling was too slow and, thus, problems of immediate tamponade occurred.

Hogen-Esch *et al.* synthesized an injectable PGMA hydrogel using very low amounts of cross-linking agents [174]. The gel was able to absorb up to 96%wt. of aqueous saline and, after swelling, remained soft and sufficiently transparent. Even if a slight loss of light transmittance was assessed, the final RI (1.3364) was still very close to that of natural vitreous. After implantation in rabbits' eyes, good clinical outcomes without complications were observed. However, as the hydrogel underwent fragmentation upon injection, no further studies were carried out on PGMA as a vitreous substitute.

Poly(2-hydroxyethyl acrylate)/Poly(2-hydroxyethyl methacrylate)

Poly(2-hydroxyethyl acrylate) (PHEA) was tested by Chan *et al.* [143] in rabbits' eyes as a potential vitreous substitute. PHEA exhibited excellent physical properties, such as high transparency, viscosity similar to that of natural vitreous, non-absorbability and easy injectability, that made it, also theoretically, an ideal vitreous substitute. However, clinical outcomes were not satisfactory, as PHEA induced corneal oedema, glaucoma, damage to the lens as well as its opacification, formation of fibrous membranes and severe retinal complications.

Poly(2-hydroxyethyl methacrylate) (PHEMA) is a solid hydrogel that was well-tolerated by ocular tissues, did not elicit retinal damages, and did not undergo bioabsorption or biodegradation. However, its implantation required difficult surgical procedures and, therefore, was no longer investigated [175].

Silicone Gel

Two silicone gel formulations (A = clear gel, B = hazy gel) were tested in monkeys by Peyman *et al.* [176]. The liquid monomers were injected into the vitreous cavities and polymerization occurred *in situ*. Apart from a minimal postoperative inflammation of one week, no clinical complications were reported. No retinal damage was detected, neither gel lost its cohesiveness and, specifically, the clear gel (formulation A) remained transparent over time. However, due to their hydrophobic nature, the gels remained separated from the retina, thereby losing any tamponade effect. Therefore, it is reasonable to assume that such gels are not suitable for vitreous substitution.

Hydroxypropyl Methylcellulose

Fernandez-Vigo *et al.* injected a solution of hydroxypropyl methylcellulose (HPMC) (viscosity ~6000 cSt, $M_w = 86$ kDa) in rabbits' eyes [177]: HPMC was completely eliminated from the vitreous cavity within 10 weeks after implantation and, therefore, the authors concluded in this first study that HPMC solutions are useful neither as a long-term vitreous substitute nor for sealing retinal holes in RRD due to the lack of tamponade effect. However, the excellent biocompatibility of HPMC was encouraging and the authors carried out another animal study in which they demonstrated that the residence time of HPMC in the vitreous cavity could be controlled by varying its molecular weight [178]. Specifically, by using a product with $M_w = 120$ kDa and viscosity ~6000 cSt. The half-life time of the substitute was 38 days; nonetheless, such a substitute is still unsuitable for prolonged tamponade.

Pluronic F127

Pluronic F127 (P-F127) solutions at a concentration $\geq 20\%$ wt. show thermoreversible gelation behavior [179]. For instance, a 20% wt. P-F127 solution is liquid when cold, but forms a clear gel (RI = 1.032) at 21 °C as the solution is heated. In spite of their attractive physical properties, P-F127 solutions were found to be unsuitable for vitreous substitution. In fact, Davidorf *et al.* [180] showed that the polymer can induce severe retinal toxicity and Dalton *et al.* [181] demonstrated through rheological studies that P-F127 is not easily injectable via a small-gauge needle into the vitreous cavity, thereby complicating surgical procedures.

Poly(methyl 2-acrylamidoglycolate methyl ether)

In the early 1990s, Chirila *et al.* tested several polymers derived from (methyl 2-acrylamidoglycolate methyl ether) as a potential vitreous substitute [182]. Eventually, the homopolymer poly(methyl 2-acrylamidoglycolate methyl ether) (PMAGME), synthesized in 80% wt. of water and without cross-linking agents, was selected for *in vivo* tests in rabbits. Negligible fragmentation upon injection was observed, but severe postoperative clinical complications were reported, including retinal detachment, inflammation, and damage to the optic nerve. The cause of the toxic effect remained unclear as it could have been due to the polymer itself or, maybe more reasonably, to residual acrylamide, which is known to be a neurotoxic product. The authors also reported the results of *in vitro* studies using mouse fibroblast cells, that revealed the cytostatic and cytotoxic effect of the hydrogel

[182]. This demonstrated for the first time that *in vitro* cytotoxicity assay can be very useful for performing a preliminary selection of polymers as potential vitreous substitutes.

Poly(vinyl alcohol)

In the early 1990s, Benlian *et al.* [183] selected poly(vinyl alcohol) (PVA) as a potential vitreous substitute on the basis of its optical properties being very similar to those of natural vitreous, and they evaluated its performances in rabbits' eyes. Postoperative outcomes were good, as no inflammation or damage to the retina was detected after two months of implantation.

Yamauchi *et al.* [184] widely investigated autoclave-sterilized PVA hydrogels consisting of 99% wt. of water; the gels were produced by γ -irradiation of a 7% wt. PVA solution and then injected into rabbits' eyes. Inflammation and vitreous opacification occurred more frequently in the long-term with PVA than with physiological solutions. The short-time optical properties were excellent, as the gels were indistinguishable from the host vitreous in the first postoperative weeks. A mixture of PVA/chondroitin sulfate was also used: it could not be separated into components even after extraction with boiling water, displayed a transparency superior to that of PVA as such and absorbed more water than PVA alone, but it was less biocompatible in rabbits' eyes.

Recently, Maruoka *et al.* [185] prepared PVA hydrogels by treating the polymer solution in autoclave before γ -irradiation (like previously reported by Yamauchi *et al.*) and injected the resulting gels into monkeys' eyes. During the first postoperative weeks inflammatory response and IOP increase was detected, but by 3 months after implantation the eyes regained normal IOP and retinal activity. Due to their good optical properties and long-term biocompatibility, PVA hydrogels are promising candidates for vitreous substitution, but further studies need to be performed to collect more data about their retention time, mechanical properties and ability to reattach the retina.

Poly(vinyl alcohol methacrylate)

Recently, Cavalieri *et al.* [186] carried out preliminary investigations on poly(vinyl alcohol methacrylate) (PVA-MA) to test its potential suitability as a vitreous substitute. The polymer contained a photoinitiator and the gel network could be formed by irradiation at 365 nm; the degree of cross-linking could be tailored by varying the photoinitiator concentration and the radiation exposure time. The ability of *in situ* gelification was an attractive property. The authors reported that gelification did not occur at polymer concentrations lower than 4% wt., and *in vitro* tests using bovine serum showed that hydrogel degradation occurred in the presence of a low degree of cross-linking. Therefore, potentially suitable hydrogels were those synthesized at high polymer concentrations and with a high degree of cross-linking; however, such gels were found to be significantly stiffer than natural vitreous. Further studies addressed at reducing this mismatch between the mechanical properties of PVA-MA and those of natural vitreous are needed to understand whether such a material remains a valid contender for vitreous substitution.

Adcon-L hydrogel

De Jong *et al.* [187] reported in one study the use of Adcon-L hydrogel (a carbohydrate-based hydrogel experimented successfully in neurosurgery) for vitreous substitution in rabbits' eyes. This

material is absolutely unsuitable for this purpose, as severe postoperative complications were reported, such as persistent inflammation, cornea opacification, damage to the lens and toxicity to the retina; in addition, the residence time in the vitreous cavity was very short (~three weeks).

Semifluorinated Alkanes

A final mention should be devoted to semifluorinated alkanes (SFAs). SFAs exhibit a chemical structure of the type R_H-R_F or $R_F-R_H-R_F$, in which short alkyl chains join at one or both ends to a perfluorocarbon chain. SFAs are transparent and have lower density ($1.1-1.7 \text{ g/cm}^3$) than both SiOs and PFCLs [188–190]. At present, SFAs are used as biocompatible solvents for SiOs. In general, the longer the R_H chain in the SFA, and the lower the viscosity of SiO, the better the solubility in each other. Optically clear mixtures of SiOs and SFAs, with a typical density of $1.2-1.3 \text{ g/cm}^3$ can be obtained, and preliminary studies demonstrate that SFAs can be successfully used as such for unfolding and reattaching the retina and as long-term vitreous substitutes [188,190]. In addition, Meinert *et al.* suggested the use of SFAs as solvents for selected drugs [190]: therefore, by injecting the material into the vitreous cavity, it is also possible to carry out an *in situ* pharmaceutical therapy. SFAs exhibit great potential for the replacement of currently used vitreous tamponade agents, but further studies on their biocompatibility and *in vivo* behavior are still necessary. For this reason, we decided to include SFAs in this section of the review even though they are already commercially available and marketed for ophthalmic use.

8. Summary of Current Solutions

Depending on the type of RD and related conditions, different treatment strategies, as well as different materials and implants, are at the surgeon's disposal.

Pneumatic retinopexy is an effective surgical procedure (success rate >90%) for most of RRDs. Specifically, it is useful when a single tear causes the RRD, or multiple breaks are small and close to each other, or else the break is in the upper part of the retina. Recent experimental work seems to indicate that SF_6 and PFCGs led to substantially similar results both in terms of anatomic success rate (retinal reattachment) and as regards the development of cataract in phakic eyes [191,192].

In the case of multiple retinal breaks spread over a wide area, giant tears or TRD, scleral buckling or vitrectomy are commonly performed and these two procedures may be performed together. Today, silicone is considered by surgeons as the “gold standard” material for manufacturing scleral buckles [69–75] and solid/porous silicone implants are marketed worldwide. More than seventy style options for silicone buckles are currently available to the ophthalmic surgeons seeking an implant designed to achieve a particular width, height or shape of the buckle. The evolution continues today as new techniques develop and surgeons identify new needs and suggest new styles to meet such needs.

With regard to tamponade agents, suitable for vitrectomy procedures, today SiOs [123] and PFCLs [130] still remain the preferred choice among surgeons. SiO exhibits attractive features, e.g., permanent retention in the vitreous cavity, remarkable optical clarity and chemical inertness, which make it a promising candidate for vitreous substitution. However, there is convincing evidence that SiO can induce serious long-term complications such as glaucoma, corneal damage and cataract. In addition, the removal of SiO is generally difficult and any amount remaining may be retained

indefinitely. In spite of these drawbacks, in the last years there has been renewed interest toward the use of SiO as vitreous tamponade, stimulated by advances in surgical techniques and oil purification, and by the view that any above-mentioned clinical complications can be successfully treated. PFCLs, thanks to their excellent transparency, high density and intrinsic non-toxicity, remain an effective tool only for intraoperative surgical procedures, as many studies suggest that they should not be used postoperatively for long-term vitreous tamponade.

Although studies previously mentioned indicate that polymer-containing aqueous solutions can only be suitable for short-term vitreous tamponade, (due to their dissipation into the surrounding ocular tissues), it is the author's opinion that, on the contrary, polymeric insoluble gels are very promising candidates for use as long-term vitreous substitutes.

9. Future Forecasts

In conjunction with the tremendous developments that occurred in instrument design and surgical techniques for RD treatment in recent years, the application of advanced materials' concepts for tailoring ocular biomaterials and implants is a particularly challenging area of research. The following paragraphs highlight some key points that, in the author's opinion, should be taken into account when outlining future research in the field of scleral buckling and vitreous substitution materials.

9.1. Open Fields of Research about Scleral Buckles

The low complication rate associated with solid and porous silicone buckles results in a low demand to search for alternative materials/implants to those currently available on the market. Nonetheless, challenging fields of research still remain to be explored in detail and have re-attracted researchers' interest in recent years, such as the development of absorbable materials suitable for temporary buckles. In children, for instance, the use of a permanent silicone buckle could cause severe long-term complications, as the "buckling effect" does not allow the eye to grow physiologically; hence, the buckle has to be removed by a second operation. The use of an absorbable buckle manufactured using a synthetic biodegradable polymer could be a good option to overcome this drawback. In this context, PLA buckles, recently tested by Lansmann *et al.* in rabbits [110–112], seem to be very promising and worthy of clinical trials in human patients.

Another interesting field of research concerns the development of buckles able to release drugs according to desired kinetics. Hydrogel-based (fallen in disuse) [54] and porous silicone (sponge) [75] buckles have already been proposed as depot devices for the slow release of antibiotics. The surface functionalization of solid silicone buckles might also be investigated in order to better control drug release kinetics. *In situ* release of anti-inflammatory drugs can contribute to further reduce some occasional complications, such as scleral inflammation associated to the current silicone implants.

Finally, the author wishes to highlight a novel theme of research based on the synergy between materials science, medical imaging and physico-mathematical modeling. It is known that scleral buckling procedures induce geometric changes in the eyeball, and over indented scleral buckles can promote IOP rise over time, causing long-term complications such as glaucoma [193]. Recently, mathematical models were developed for predicting the deformation of the human eyeball caused by the application of an elastic band (scleral buckle) [194–196]. In particular, the model conceived by

Keelig *et al.* [196] gives results in good accordance with experimental data. By assessing the patients' initial eye geometric, physical and mechanical features through advanced techniques (MRI, high-resolution computerized tomography, ultrasound imaging), it could be possible to simulate eye deformation in response to different scleral buckles, and, therefore, feasibly tailor an "ideal" scleral buckle—in terms of material formulation, size, shape, elasticity—for each single case. As regard to absorbable buckles, analytical models able to predict the persistence of scleral indentation as a function of polymer degradation rate, as well as the modifications of implant geometry may be developed over time. These mathematical models could be helpful tools for surgeons to foresee and prevent postoperative complications as well as for optimizing the RD treatment procedure.

9.2. Towards an Ideal Vitreous Substitute

For years, the search for a vitreous substitute suitable for treating RD cases was primarily addressed to find a biocompatible fluid able to approximate the neural retina to the RPE. This has led to the development of several short-term vitreous tamponade agents (natural and semisynthetic polymers, physiological solutions), as well as gases used for pneumatic retinopexy. However, these materials allowed only a temporary tamponade effect, and were unsuitable for permanent vitreous replacement.

The future of vitreous substitutes is to find a formulation that can be left *in situ* indefinitely without long-term clinical complications, such as compressive damage to cells, IOP rise and postoperative glaucoma. An ideal artificial vitreous should closely mimic the light transmittance of natural vitreous humor, as well as its physical and mechanical properties. Polymeric hydrogels seem to be promising materials for long-term vitreous substitution: they generally show excellent transparency, are highly biocompatible and can act as a viscoelastic shock-absorber, thereby closely mimicking the behavior of natural vitreous. By acting on the formulation and synthesis process of the hydrogel, the density and rigidity of the final vitreous substitute could be tailored in order to match those of natural vitreous. In addition, some experimentally tested hydrogels can gel after injection into the vitreous cavity; *in situ* gelation is a key point because polymers that are injected as gels rather than liquids fragment due to shear stress in the needle, lose their elasticity, and can cause inflammation in ocular tissues. Finally, hydrogels might be used as smart matrices for controlled drug release within the vitreous cavity which could be a very helpful tool to benefit patients suffering from intravitreal affections, such as PVR.

On the basis of data currently available in the literature and discussed in the previous sections, the author suggests that four synthetic polymers seem particularly suitable for prolonged vitreous tamponade and worthy of further investigations: PAA [166–172], PVA [183–185], PVA-MA [186] and SFAs [188–190]. Also, three other materials, HPMC [177,178], the cross-linked gelatins recently tested by Lai [152], and the gellan gum/hyaluronic acid gel proposed by Suri *et al.* [159], exhibit interesting properties, but seem only useful for short-term vitreous substitution.

As a final methodological remark, in the author's opinion it would be desirable to elaborate a standard and detailed protocol for selecting and testing materials proposed as potential vitreous substitutes. In fact, when looking at most of the existing literature, it seems very often the polymers were selected according to ambiguous criteria, and no systematic exploration of their long-term toxicity and rheological properties was carried out prior to *in vivo* experiments. It was therefore difficult to state definitive conclusions as to their suitability as vitreous substitutes. In the future, *in vitro* cytotoxicity

assays and rheological studies should be generally considered and accepted as fundamental eliminatory criteria in the selection of potential vitreous substitutes.

Acknowledgements

Daniela Dolcino, Head of the Ophthalmology Ward at “Santissimi Antonio e Biagio” Hospital of Alessandria (Italy) and Pietro Rossi, Head of the Ophthalmology Ward at “San Martino” Hospital of Genova (Italy) are gratefully acknowledged for fruitful discussions and for strongly stimulating and supporting the author in writing this article.

The author wishes to gratefully dedicate this review article to Giuseppe Heer, Head Emeritus of the Ophthalmology Ward at “Maria Vittoria” Hospital of Turin (Italy) and President of the Italian Foundation for the Treatment of the Retinopathies of Prematurity. Heer, who is celebrating sixty years of clinical activity in 2010, was a pioneer in the field of retinal detachment surgery and he devoted particular attention to the treatment of the retinopathies of prematurity and related ocular diseases.

References and Notes

1. Ivanisevi, M.; Bojic, L.; Eterovic, D. Epidemiological study of nontraumatic phakic rhegmatogenous retinal detachment. *Ophthalmic Res.* **2000**, *32*, 237–239.
2. Li, X. Incidence and epidemiological characteristics of rhegmatogenous retinal detachment in Beijing, China. *Ophthalmology* **2003**, *110*, 2413–2417.
3. Wilkes, S.R. Current therapy of diabetic retinopathy: Laser and vitreoretinal surgery. *J. Natl. Med. Assn.* **1993**, *85*, 841–847.
4. Marcus, D.M.; D’Amico, D.J.; Mukai, S. Pneumatic retinopexy versus scleral buckling for repair of primary rhegmatogenous retinal detachment. *Int. Ophthalmol. Clin.* **1994**, *34*, 97–108.
5. Ciulla, T.A.; Danis, R.P.; Harris, A. Age-related macular degeneration: a review of experimental treatments. *Surv. Ophthalmol.* **1998**, *43*, 134–146.
6. Brinton, D.A.; Wilkinson, C.P. *Retinal Detachment—Principles and Practice*; Oxford University Press: Oxford, UK, 2009.
7. Yamada, E. Some structural features of the fovea centralis in the human retina. *Arch. Ophthalmol.* **1969**, *82*, 151–159.
8. Grierson, I.; Hiscott, P.; Sheridan, C.; Tuglu, I. The pigment epithelium: Friend and foe of the retina. *Proc. Roy. Microsc. Soc.* **1997**, *32*, 161–170.
9. Yokoyama, S. Molecular evolution of vertebrate visual pigments. *Prog. Retin. Eye Res.* **2000**, *19*, 385–419.
10. Gloor, B.P. The vitreous. In *Adler’s Physiology of the Eye*; Moses, R.A., Hart, W.M., Eds.; CV Mosby Co.: St. Louis, MO, USA, 1987; pp. 246–267.
11. Sebag, J. Macromolecular structure of the corpus vitreus. *Prog. Polym. Sci.* **1998**, *23*, 415–446.
12. Chirila, T.V.; Hong, Y. The vitreous humour. In *Handbook of Biomaterial Properties*; Black, J., Hastings, G.W., Eds.; Chapman & Hall: London, UK, 1998; pp. 125–131.
13. Byer, N.E. Natural history of posterior vitreous detachment with early management as the premier line of defense against retinal detachment. *Ophthalmology* **1994**, *101*, 1503–1514.

14. Los, L.I.; Van Der Vorp, R.J.; Van Luyn, M.J.A.; Hooymans, J.M.M. Age-related liquefaction of vitreous body: LM and TEM evaluation of the role of proteoglycans and collagen. *Invest. Ophthalmol. Vis. Sci.* **2003**, *44*, 2828–2833.
15. D’Amico, D.J. Medical progress—Diseases of the retina. *New Engl. J. Med.* **1994**, *331*, 95–106.
16. Michels, R.G. Surgery of retinal detachment with proliferative vitreoretinopathy. *Retina* **1984**, *4*, 63–83.
17. Campochiaro, P.A. Pathogenic mechanisms in proliferative vitreoretinopathy. *Arch. Ophthalmol.* **1997**, *115*, 237–241.
18. Pastor, J.C. Proliferative vitreoretinopathy: An overview. *Surv. Ophthalmol.* **1998**, *43*, 3–18.
19. Schepens, C.L.; Acosta, F. Scleral implants: An historical perspective. *Surv. Ophthalmol.* **1991**, *35*, 447–453.
20. Krauss, J.M.; Puliafito, C.A. Lasers in ophthalmology. *Lasers Surg. Med.* **1995**, *17*, 102–159.
21. Wang, F.; Lee, H.P.; Lu, C. Biomechanical effect of segmental scleral buckling surgery. *Curr. Eye Res.* **2007**, *32*, 133–142.
22. Ohm, J. Ueber die Behandlung der Netzhautablosung durch operative Entleerung der subretinalen Flüssigkeit und Einspiritzung von Luft in den Glaskörper. *Graefes Arch. Clin. Ophthalmol.* **1911**, *79*, 442–450.
23. Algvere, P.V.; Gjotterberg, M.; Olivestedt, G.; Fituri, S. Results of pneumatic retinopexy with air. *Acta Ophthalmol.* **1992**, *70*, 632–636.
24. Sebag, J.; Tang, M. Pneumatic retinopexy using only air. *Retina* **1993**, *13*, 8–12.
25. Wong, D.; Williams, R.L.; German, M.J. Exchange of perfluorodecalin for gas or oil: A model for avoiding slippage. *Graefes Arch. Clin. Exp. Ophthalmol.* **1998**, *236*, 234–237.
26. Gilbert, C.; McLeod, D. D-ACE surgical sequence for selected bullous retinal detachments. *Brit. J. Ophthalmol.* **1985**, *69*, 733–736.
27. Norton, E.W.D. Intraocular gas in the management of selected retinal detachments. *Trans. Am. Acad. Ophthalmol. Otolaryngol.* **1973**, *77*, 85–98.
28. Lincoff, H.A.; Mardirossian, J.; Lincoff, A.; Liggett, P.; Iwamoto, T.; Jakobiec, F. Intravitreal longevity of three perfluorocarbon gases. *Arch. Ophthalmol.* **1980**, *98*, 1610–1611.
29. Chang, S.; Lincoff, H.; Coleman, D.J.; Fuch, W.; Farber, M. Perfluorocarbon gases in vitreous surgery. *Ophthalmology* **1985**, *92*, 651–656.
30. Juzoji, H.; Iwasaki, T.; Usui, M.; Hasemi, M.; Yamakawa, N. Histological study of intraocular changes in rabbits after intravitreal gas injection. *Jpn. J. Ophthalmol.* **1997**, *41*, 278–283.
31. Lean, J.S.; Boone, D.C.; Azen, S.P.; Lai, M.Y.; Linton, K.L.P.; McCuen, B.; Ryan, S.J. Silicone Study Group: Vitrectomy with silicone oil or sulfur hexafluoride gas in eyes with severe proliferative vitreoretinopathy. Results of a randomized clinical trial (Silicone Study Report No. 1). *Arch. Ophthalmol.* **1992**, *110*, 770–779.
32. McCuen, B.; Azen, S.P.; Boone, D.C.; Lai, M.Y.; Linton, K.L.P.; Lean, J.; Ryan, S.J. Silicone Study Group: Vitrectomy with silicone oil or perfluoropropane gas in eyes with severe proliferative vitreoretinopathy. Results of a randomized clinical trial (Silicone Study Report No. 2). *Arch. Ophthalmol.* **1992**, *110*, 780–792.

33. Van Horn, D.L.; Edelhofer, H.F.; Aaberg, T.M.; Pederson, H.J. In vivo effects of air and sulfur hexafluoride gas on rabbit corneal endothelium. *Invest. Ophthalmol.* **1972**, *11*, 1028–1036.
34. Constable, I.J.; Swann, D.A. Vitreous substitution with gases. *Arch. Ophthalmol.* **1975**, *93*, 416–419.
35. Lincoff, A.; Lincoff, H.; Solorzano, C.; Iwamoto, T. Selection of xenon gas for rapidly disappearing retinal tamponade. *Arch. Ophthalmol.* **1982**, *100*, 996–997.
36. Lincoff, H.; Kreissig, I. Applications of xenon gas to clinical retinal detachment. *Arch. Ophthalmol.* **1982**, *100*, 1083–1085.
37. Jess, A. Temporäre Skleraleindellung als Hilfsmittel bei der Operation der Netzhautablosung. *Klin. Monatsbl. Augenheilkd* **1937**, *99*, 318–319.
38. Custodis, E. Bedeutet die Plombenaufnahme auf die Sklera einen Fortschritt in der operativen Behandlung der Netzhautablosung? *Ber. Dtsch. Ophthalmol. Ges.* **1953**, *58*, 102–105.
39. Custodis, E. Scleral buckling without excision with polyviol implant. In *Importance of Vitreous Body with Special Emphasis on Reoperations*; Schepens, C.L., Ed.; CV Mosby Co.: St. Louis, USA, 1960; pp. 175–182.
40. Schepens, C.L.; Okamura, I.D.; Brockhurst, R.J. The scleral buckling procedures. I. Surgical techniques and management. *Arch. Ophthalmol.* **1957**, *58*, 797–811.
41. Schepens, C.L.; Okamura, I.D.; Brockhurst, R.J. The scleral buckling procedures. II. Technical difficulties of primary operations. *Arch. Ophthalmol.* **1958**, *60*, 84–92.
42. Regan, C.D.J. Erosion of the ocular wall by circling polyethylene tubing—A late complication of scleral buckling. *Trans. Am. Acad. Ophthalmol. Otolaryngol.* **1963**, *67*, 335–339.
43. Girard, L.J.; McPherson, A.R. Scleral buckling: full thickness and circumferential, using silicone rubber rodding and photocoagulation. *Arch. Ophthalmol.* **1962**, *67*, 409–420.
44. Arruga, H. Le cerclage équatorial pour traiter le décollement rétinien. *Bull. Soc. Ophthalmol. Fr.* **1958**, *71*, 571–580.
45. Witschel, H.; Faulborn, J. Gewebereaktionen auf Plomben- und Cerclage-material: Polyamid-Silikon-Polyester. *Graefes Arch. Klin. Exp. Ophthalmol.* **1978**, *206*, 217–226.
46. Wolter, J.R.; Fralick, F.B. Use of teflon in retinal separation surgery. *Trans. Am. Ophthalmol. Soc.* **1966**, *64*, 185–203.
47. Wolter, J.R.; Fralick, F.B. Use of Teflon in retinal detachment surgery. *Am. J. Ophthalmol.* **1967**, *63*, 113–123.
48. Deodati, F.; Bec, P.; Camezind, M. Use of Teflon as an indentation material in retinal detachment surgery. *Bull. Soc. Ophthalmol. Fr.* **1971**, *71*, 69–71.
49. Kommerell, G. Cerclage mit 5 mm breiten Mersilene-Band. *Ber. Zusammenkunft Dtsch. Ophthalmol. Ges.* **1972**, *71*, 644–645.
50. Kommerell, G.; Dunzen, R. Mersilene-Band-Cerclage bei prognostisch ungünstiger Netzhautablosung. *Ber. Zusammenkunft Dtsch. Ophthalmol. Ges.* **1977**, *74*, 371–376.
51. D’Hermies, F.; Korobelnik, J.F.; Savoldelli, M.; Chauvaud, D.; Pouliquen, Y. Miragel versus silastic used as episcleral implants in rabbits—An experimental and histopathologic comparative study. *Retina* **1995**, *15*, 62–67.

52. D’Hermies, F.; Korobelnik, J.F.; Meyer, A.; Chauvaud, D.; Pouliquen, Y.; Renard, G. Experimental encircling scleral buckle with silicone and hydrogel: histopathologic and comparative study of 26 rabbit eyes. *Retina* **1999**, *19*, 148–157.
53. Ho, P.C.; Chan, I.M.; Refojo, M.F.; Tolentino, F.I. The MAI hydrophilic implant for scleral buckling—A review. *Ophthalmic Surg. Lasers* **1984**, *15*, 511–515.
54. Refojo, M.F.; Leong, F.L.; Chan, I.M.; Tolentino, F.I. Absorption and release of antibiotics by a hydrophilic implant for scleral buckling. *Retina* **1983**, *3*, 45–49.
55. Roldan-Pallares, M.; Sanz, J.L.D.; Awad-El Susi, S.; Refojo, M.F. Long-term complications of silicone and hydrogel explants in retinal reattachment surgery. *Arch. Ophthalmol.* **1999**, *117*, 197–201.
56. Marin, J.F.; Tolentino, F.I.; Refojo, M.F.; Schepens, C.L. Long-term complications of the MAI hydrogel intrascleral buckling implant. *Arch. Ophthalmol.* **1992**, *110*, 86–88.
57. Hwang, K.I.; Lim, J.I. Hydrogel explant fragmentation 10 years after scleral buckling surgery. *Arch. Ophthalmol.* **1997**, *115*, 1205–1206.
58. Li, K.; Lim, K.S.; Wong, D. Miragel explant fragmentation 10 years after scleral buckling surgery. *Eye* **2003**, *17*, 248–250.
59. Bernardino, C.R.; Mihora, L.D.; Fay, A.M.; Rubin, P.A. Orbital complications of hydrogel scleral buckles. *Ophthalmic Plast. Reconstr. Sur.* **2006**, *22*, 206–208.
60. Lobes, L.A., Jr.; Grand, M.G.; Rehkopf, P.G.; Johnson, B. Polytetrafluoroethylene in experimental retinal detachment surgery. *Ann. Ophthalmol.* **1981**, *13*, 921–923.
61. Tawakol, M.E.; Peyman, G.A.; Liu, K.R.; Kaufman, K.E. Gore-Tex soft tissue bands as scleral explants in rabbits: A preliminary histological study. *Ophthalmic Surg.* **1989**, *20*, 199–201.
62. Korobelnik, J.F.; D’Hermies, F.; Ducourneau, D.; Legeais, J.M.; Chauvaud, D.; Hoang-Xuan, T.; Renard, G. e-PTFE as scleral buckling episcleral implants: An experimental and histopathologic study. *J. Biomed. Mater. Res.* **1999**, *48*, 807–813.
63. Korobelnik, J.F.; D’Hermies, F.; Chauvaud, D.; Legeais, J.M.; Hoang-Xuan, T.; Renard, G. Expanded polytetrafluoroethylene episcleral implants used as encircling scleral buckling—An experimental and histopathologic study. *Ophthalmic Res.* **2000**, *32*, 110–117.
64. Sheu, S.J.; Chou, L.C.; Lee, I.Y.; Wang, C.C. Histopathology of polytetrafluoroethylene (Gore-tex) as a scleral buckle in humans. *Ophthalmic Surg. Lasers* **2001**, *32*, 245–247.
65. Roldan-Pallares, M.; Awad-El Susi, S. Politetrafluoroetileno en la cirugía de indentación escleral. *Arch. Soc. Esp. Ophthalmol.* **2000**, *75*, 605–609.
66. Mortemousque, B.; Diemer, C.; Leger, F.; Barach, D.; Legeais, J.M.; Williamson, W. Evaluation histologique chez le lapin de la biocompatibilité d’un matériel d’indentation episcleral: le S-PTFEe (noyau en silicone recouvert de polytetrafluoroethylene expansé). *J. Fr. Ophthalmol.* **2001**, *24*, 467–473.
67. Mortemousque, B.; Leger, F.; Velou, S.; Graffan, R.; Colin, J.; Korobelnik, J.F. S/e-PTFE episcleral buckling implants: an experimental and histopathologic study. *J. Biomed. Mater. Res.* **2002**, *63*, 686–691.

68. Gloor B.P. Operation der Netzhautablosung bei Lochern im Bereich des hinteren Poles mit einfacher, lang vertraglicher Silberspange und Cerclage. *Klin. Monatsbl. Augenheilkd* **1977**, *171*, 271–277.
69. D’Hermies, F.; Korobelnik, J.F.; Caputo, G.; Mashhour, B.; Chauvaud, D.; Pouliquen, Y.; Renard, G. Encapsulation of scleral buckling materials. *Ophthalmology* **1998**, *105*, 1079–1086.
70. Nguyen, Q.D.; Lashkari, K.; Hirose, T.; Pruett, R.C.; McMeel, J.W.; Schepens, C.L. Erosion and intrusion of silicone rubber scleral buckle. Presentation and management. *Retina* **2001**, *21*, 214–220.
71. Lindsey, P.S.; Pierce, L.H.; Welch, R.B. Removal of scleral buckling elements. Causes and complications. *Arch. Ophthalmol.* **1983**, *101*, 570–573.
72. Wiznia, R.A. Removal of solid silicone rubber exoplants after retinal detachment surgery. *Am. J. Ophthalmol.* **1983**, *95*, 495–497.
73. Lincoff, H.; McLean, J.M. Modifications to the Custodis procedure. II. A new silicone implant for large tears. *Am. J. Ophthalmol.* **1967**, *64*, 877–879.
74. Brown, D.M.; Beardsley, R.M.; Fish, R.H.; Kim, R.Y.; Wong, T.P. Long term stability of circumferential silicone sponge scleral buckling exoplants. *Retina* **2006**, *26*, 645–649.
75. Arribas, N.P.; Olk, R.J.; Schertzer, M.; Okun, E.; Johnston, G.P.; Boniuk, I.; Escoffery, R.F.; Grand, M.G.; Burgess, D.B. Preoperative antibiotic soaking of silicone sponges. Does it make a difference? *Ophthalmology* **1984**, *91*, 1684–1689.
76. Deokule, S.; Reginald, A.; Callear, A. Scleral explant removal: The last decade. *Eye* **2003**, *17*, 697–700.
77. Lincoff, H.; Stopa, M.; Kreissig, I.; Madjarov, B.; Sarup, V.; Saxena, S.; Brodie, S. Cutting the encircling band. *Retina* **2006**, *26*, 650–654.
78. Scott, A.B. Autograft tendon for scleral buckling. *Am. J. Ophthalmol.* **1964**, *57*, 564–567.
79. Havener, W.H.; Olson, R.H. Encircling fascia lata strips for retinal detachment. *Arch. Ophthalmol.* **1962**, *67*, 721–726.
80. Chilaris, G.; Liaricos, S. Fascia of the temporalis muscle in scleral buckling and keratoprosthesis operations. *Am. J. Ophthalmol.* **1973**, *76*, 35–37.
81. Minning, C.A., Jr.; Havener, W.H. Host tolerance of homologous fascia lata in retinal detachment surgery. *Arch. Ophthalmol.* **1983**, *101*, 475–478.
82. Cibis, P.A.; Knobloch, W.H. Scleral implants with preserved human sclera. *Bibl. Ophthalmol.* **1967**, *72*, 293–318.
83. Francois, J.; Verbraeken, H.; Hanssens, M. Scleral pockets and lyophilized sclera in retinal detachments. *Ophthalmologica* **1979**, *179*, 153–157.
84. Vygantas, C.M.; Kanter, P.J. Experimental buckling with homologous sclera and cyanoacrylate. *Arch. Ophthalmol.* **1974**, *91*, 126–129.
85. Regenbogen, L.; Romano, A.; Zuckerman, M.; Stein, R. Histoacryl tissue adhesive in some types of retinal detachment surgery. *Br. J. Ophthalmol.* **1976**, *60*, 561–564.
86. Chien, Y.T. Human skin in retinal detachment surgery. *Chin. Med. J.* **1978**, *4*, 277–279.
87. Zeng, S.Q.; Shui, Y.B.; Hu, C.Z.; Wie, H.R. Verwendung von homologer Kutis als Plombenmaterial in 1585 Fallenvon Ablatiooperation. *J. Tongji Med. Univ.* **1992**, *12*, 54–59.

88. Winter, R.; Khorram-Sefat, C. Microchirurgie der Amotio retinae mit biologischen Plombenmaterial. *Klin. Monatsbl. Augenheilkd* **1988**, *193*, 611–614.
89. Weissgold, D.J.; Millary, R.H.; Bochow, T.A. Rescue of exposed scleral buckles with cadaveric pericardial patch grafts. *Ophthalmology* **2001**, *108*, 753–758.
90. Jacklin, H.N.; MacKenzie-Freeman, H.; Schepens, C.L.; Tablante, R.T. Gelatin as an absorbable implant in scleral buckling procedures—A preliminary report. *Arch. Ophthalmol.* **1968**, *79*, 286–290.
91. Daniele, S.; Jacklin, H.N.; Schepens, C.L.; MacKenzie-Freeman, H. Gelatin as an absorbable implant in scleral buckling procedures—An experimental study. *Arch. Ophthalmol.* **1968**, *80*, 115–119.
92. King, L.M., Jr.; Margherio, R.R.; Schepens, C.L. Gelatin implants in scleral buckling procedures. *Arch. Ophthalmol.* **1975**, *93*, 807–811.
93. Borrás, A. Inclusion of absorbable gelatin film between the scleral lamellae in the treatment of retinal detachment. *Am. J. Ophthalmol.* **1961**, *52*, 561–565.
94. Levit, R.; Seelenfreund, M.H.; Freilich, D.B. Use of ophthalmic gelfilm in retinal surgery. *Ann. Ophthalmol.* **1975**, *7*, 1613–1616.
95. Tanenbaum, H.L.; Chandra, G. Gelatin implants in retina surgery. *Can. J. Ophthalmol.* **1976**, *11*, 52–54.
96. Freilich, D.B.; Morton, H. Absorbable implants in nondrainage procedures for repair of retinal detachments. *Dev. Ophthalmol.* **1981**, *2*, 66–70.
97. Wilson, R.S. New absorbable exoplants using gelatine and synthetic materials. *Trans. Am. Ophthalmol. Soc.* **1983**, *81*, 966–1033.
98. Grosz, I.D.; Vereb, K.; Kerenyi, G. Scleral buckling with Bioplast fibrin in retinal detachment. *Acta Ophthalmol.* **1976**, *54*, 408–416.
99. Wollensak, J.; Engels, T. Operation der Netzhautablosung bei Makulaforamen mit resorbierbarer Plombe. *Klin. Monatsbl. Augenheilkd* **1977**, *171*, 278–282.
100. Dellaporta, A. Experimental studies on a scleral buckling operation. *Am. J. Ophthalmol.* **1956**, *42*, 189–204.
101. Dellaporta, A. Experiments in scleral buckling. I. Temporary scleral buckling with inclusion of plain surgical gut. *Am. J. Ophthalmol.* **1962**, *53*, 593–602.
102. Dellaporta, A. Experiments in scleral buckling. III. Scleral buckling with inclusion of chromic surgical gut. *Am. J. Ophthalmol.* **1962**, *53*, 891–896.
103. Dellaporta, A. Experiments in scleral buckling. V. Prolonged scleral buckling with chromic surgical gut. *Am. J. Ophthalmol.* **1966**, *61*, 768–776.
104. Dellaporta, A. Experimental and clinical studies on scleral encircling operations. *Trans. Am. Ophthalmol. Soc.* **1970**, *68*, 595–666.
105. Smith, R. Suprachoroidal air injection for detached retina; preliminary report. *Br. J. Ophthalmol.* **1952**, *36*, 385–388.
106. Sachsenweger, R.; Hartwig, H. Suprachoroidale (subsklerale) Fettplomben bei Ablatiooperationen. *Klin. Monatsbl. Augenheilkd* **1975**, *167*, 191–198.

107. Mittl, R.N.; Tiwari, R. Suprachoroidal injection of sodium hyaluronate as an ‘internal’ buckling procedure. *Ophthalmic Res.* **1987**, *19*, 255–260.
108. Marti, R.; Gabarro, I.; Burgues, L.; Mariella, V.; Guix, M. New absorbable synthetic explant for the treatment of retinal detachment. *Retina* **1987**, *7*, 102–110.
109. Marti, R.; Gabarro, I.; Burgues, L.L.; Asensi, A.; Bove, J.A.; Casafont, M.C.; Rafat, A.; Vinas, R. Experience sur explants synthétiques pour le traitement du décollement de la rétine. *Ophthalmologie* **1988**, *2*, 403–405.
110. Lansman, S.M.; Karttunen, A.I.; Hirvela, H.K.; Palosaari, J.T.; Kellomaki, M.; Ella, V.; Ohtonen P.P.; Tormala, P.; Waris, T.H.; Ashammakhi N. Persistence of indentation with bioabsorbable poly-L/D-lactide versus silicone sponge scleral buckling implants. *Retina* **2005**, *25*, 581–586.
111. Lansman, S.; Paakko, P.; Ryhanen, J.; Hirvela, H.; Kellomaki, M.; Ella, V.; Tormala, P.; Waris, T.H.; Ashammakhi N. Hystologic analysis of bioabsorbable scleral buckling implants: An experimental study on rabbits. *Retina* **2005**, *25*, 1032–1038.
112. Lansman, S.; Paakko, P.; Ryhanen, J.; Kellomaki, M.; Waris, E.; Tormala, P.; Waris, T.; Ashammakhi, N. Poly-L/D-lactide (PLDLA) 96/4 fibrous implants: histological evaluation in the subcutis of experimental design. *J. Craniofac. Surg.* **2006**, *17*, 1121–1128.
113. Guthoff, R.; Wagner, T.; Holste, J.; Winter, R. Resorbierbare Plombenmateriale in der Amotiochirurgie—Erste tierexperimentelle Untersuchungen. *Klin. Monatsbl. Augenheilkd* **1993**, *202*, 43–48.
114. Marti, R.; Burgues, L.; Gabarro, I.; Mariella, V.; Guix, M. Explant syntetique absorbable de PDS pour le traitement du décollement de la rétine. *J. Fr. Ophthalmol.* **1986**, *9*, 373–379.
115. Biardzka, B.; Kaluzny, J. Experimental and clinical investigations on the suitability of polydioxanone threads for cerclage of the eyeball. *Ophthalmologica* **1988**, *197*, 47–50.
116. Kothe, H.W.; Mahnke, P.F.; Lommatzsch, P. Tierexperimentelle Testung von Polyurethan-Weichschaum (SYSpur) als episclerales Plombenmaterial. *Klin. Monatsbl. Augenheilkd* **1985**, *187*, 209–211.
117. Kothe, H.W.; Lommatzsch, P.K. Klinische Erfahrungen mit Polyurethan-Weichschaumplomben für die Netzhautchirurgie. *Klin. Monatsbl. Augenheilkd* **1985**, *187*, 273–275.
118. Chirila, T.V.; Tahija, S.; Hong, Y.; Vijayasekaran, S.; Constable, I.J. Synthetic polymers as materials for artificial vitreous body: review and recent advances. *J. Biomater. Appl.* **1994**, *9*, 121–137.
119. Chirila, T.V.; Hong, Y.; Dalton, P.D.; Constable, I.J.; Refojo, M.F. The use of hydrophilic polymers as artificial vitreous. *Prog. Polym. Sci.* **1998**, *23*, 475–508.
120. Azen, S.P.; Scott, I.U.; Flynn, H.W.; Lay, M.Y.; Topping, T.M.; Benati, L.; Trask, D.K.; Rogus, L.A. Silicone oil in the repair of complex retinal detachments—A prospective observational multicenter study. *Ophthalmology* **1998**, *105*, 1587–1597.
121. Wolf, S.; Schon, V.; Meier, P.; Wiedemann, P. Silicon oil-RMN3 mixture (“heavy silicon oil”) as internal tamponade for complicated retinal detachment. *Retina* **2003**, *23*, 335–342.
122. Er, H. Primary heavy silicone oil usage in inferior rhegmatogenous retinal detachment. *Ophthalmologica* **2010**, *224*, 122–125.

123. Giordano, G.G.; Refojo, M.F. Silicone oils as vitreous substitutes. *Prog. Polym. Sci.* **1998**, *23*, 509–532.
124. Federman, J.L.; Schubert, H.D. Complications associated with the use of silicone oil in 150 eyes after retina-vitreous surgery. *Ophthalmology* **1988**, *95*, 870–876.
125. Beekhuis, W.H.; Ando, F.; Zivojnovic, R.; Mertens, D.A.; Peperkamp, E. Basal iridectomy at 6 o'clock in the aphakic eye treated with silicone oil: prevention of keratopathy and secondary glaucoma. *Brit. J. Ophthalmol.* **1987**, *71*, 197–200.
126. Borislav, D. Cataract after silicone oil implantation. *Doc. Ophthalmol.* **1993**, *83*, 79–82.
127. Pastor, J.C.; Zarco, J.M.; Delnoz, M.J.; Pampliega, A.; Marinero, P. Clinical consequences of the use of highly purified silicone oil – comparative study of highly and less purified silicon oil. *Eur. J. Ophthalmol.* **1998**, *8*, 179–183.
128. Versura, P.; Cellini, M.; Torreggiani, A.; Bernabini, B.; Rossi, A.; Moretti, M.; Caramazza, R. The biocompatibility of silicone, fluorosilicone and perfluorocarbon liquids as vitreous tamponades. *Ophthalmologica* **2001**, *215*, 276–283.
129. Ohira, A.; Wilson, C.A.; De Juan, E.; Murata, Y.; Soji, T.; Oshima, K. Experimental retinal tolerance to emulsified silicone oil. *Retina* **1991**, *11*, 259–265.
130. Peyman, G.A.; Schulman, J.A.; Sullivan, B. Perfluorocarbon liquids in ophthalmology. *Surv. Ophthalmol.* **1995**, *39*, 375–395.
131. Imamura, Y.; Minami, M.; Ueki, M.; Satoh, B.; Ikeda, T. Use of perfluorocarbon liquid during vitrectomy for severe proliferative diabetic retinopathy. *Brit. J. Ophthalmol.* **2003**, *87*, 563–566.
132. Lesnani, G.; Rossi, T.; Gelso, A. Subfoveal liquid perfluorocarbon. *Retina* **2004**, *24*, 172–176.
133. Foster, R.E.; Smiddy, W.S.; Alfonso, E.C.; Parrish, R.K. Secondary glaucoma associated with retained perfluorophenanthrene. *Am. J. Ophthalmol.* **1994**, *118*, 253–255.
134. De Queiroz, J.M., Jr.; Blanks, J.C.; Ozler, S.A.; Alfaro, D.V.; Liggett, P.E. Subretinal perfluorocarbon liquids: An experimental study. *Retina* **1992**, *12*, 33–39.
135. Moreira, H.; De Queiroz, J.M., Jr.; Liggett, P.E.; McDonnell, P.J. Corneal toxicity study of two perfluorocarbon liquids in rabbit eyes. *Cornea* **1992**, *11*, 376–379.
136. Garcia-Valenzuela, E.; Ito, Y.; Abrams, G.W. Risk factors for retention of subretinal perfluorocarbon liquid in vitreoretinal surgery. *Retina* **2004**, *24*, 746–752.
137. Deutschmann, R. Zur operativen behandlung der netzhautablosung. *Klin. Monastbl. Augenheilkd* **1906**, *44*, 364–370.
138. Cutler, N.L. Vitreous transplantation. *Trans. Am. Acad. Ophthalmol. Otolaryngol.* **1947**, *52*, 253–259.
139. Shafer, D.M.; Bussey, J.L. Further experience with vitreous implants in old retinal detachments. *Arch. Ophthalmol.* **1958**, *60*, 255–257.
140. Elschmig, A. Uber Glaskorperersatz: II. Teil. *Graefes Arch. Ophthalmol.* **1912**, *80*, 514–536.
141. Wood, D.J. Detached retina. *Brit. J. Ophthalmol.* **1920**, *4*, 413–415.
142. Grafton, E.G.; Guyton, J.S. The value of injecting saline into the vitreous as an adjunct to diathermy operations for retinal detachment. *Am. J. Ophthalmol.* **1948**, *31*, 299–303.
143. Chan, I.L.; Tolentino, F.I.; Refojo, M.F.; Fournier, G.; Albert, D.M. Vitreous substitute: experimental studies and review. *Retina* **1984**, *4*, 51–59.

144. Stenzel, K.H.; Dunn, M.W.; Rubin, A.L.; Miyata, T. Collagen gels: design for a vitreous replacement. *Science* **1969**, *164*, 1282–1283.
145. Dunn, M.W.; Stenzel, K.H.; Rubin, A.L.; Miyata, T. Collagen implants in the vitreous. *Arch. Ophthalmol.* **1969**, *82*, 840–844.
146. Pruett, R.C.; Calabria, G.A.; Schepens, C.L. Collagen vitreous substitute: I. Experimental study. *Arch. Ophthalmol.* **1972**, *88*, 540–543.
147. Pruett, R.C.; Schepens, C.L.; Freeman, H.M. Collagen vitreous substitute: II. Preliminary clinical trials. *Arch. Ophthalmol.* **1974**, *91*, 29–32.
148. Nakagawa, M.; Tanaka, M.; Miyata, T. Evaluation of collagen gel and hyaluronic acid as vitreous substitutes. *Ophthalmic Res.* **1997**, *29*, 409–420.
149. Liang, C.P.; Peyman, G.A.; Serracarbassa, P.; Calixto, N.; Chow, A.A.; Rao, P. An evaluation of methylated collagen as a substitute for vitreous and aqueous humour. *Int. Ophthalmol.* **1998**, *22*, 13–18.
150. Oosterhuis, J.A.; Van Haeringen, N.J.; Jeltjes, I.G.; Glasius, E. Polygeline as vitreous substitute: I. Observations in rabbits. *Arch. Ophthalmol.* **1966**, *76*, 258–265.
151. Oosterhuis, J.A. Polygeline as a vitreous substitute: II. Clinical results. *Arch. Ophthalmol.* **1966**, *76*, 374–377.
152. Lai, J.Y. Biocompatibility of chemically cross-linked gelatine hydrogels for ophthalmic use. *J. Mater. Sci. Mater. Med.* **2010**, *21*, 1899–1911.
153. Hruby, K. Hyaluronic acid as vitreous body substitute in retinal detachment. *Klin. Monstbl. Augenheilkd* **1961**, *138*, 484–496.
154. Pruett, R.C.; Schepens, C.L.; Swann, D.A. Hyaluronic acid vitreous substitute: A six-year clinical evaluation. *Arch. Ophthalmol.* **1979**, *97*, 2325–2330.
155. Larsen, N.E.; Pollak, C.T.; Reiner, K.; Leshchiner, E.; Balazs, E.A. Hylan gel biomaterial: Dermal and immunologic compatibility. *J. Biomed. Mater. Res.* **1993**, *27*, 1129–1134.
156. Balazs, E.A.; Sweeney, D.B. The replacement of the vitreous body in the monkey by reconstituted vitreous and by hyaluronic acid. *Bibl. Ophthalmol.* **1966**, *70*, 230–232.
157. Kishimoto, M.; Yamanouchi, U.; Mori, S.; Nakamori, F. Experimental study on the substitute of the vitreous body. *Nippon Ganka Gakkai Zasshi* **1964**, *68*, 1145–1158.
158. Gombos, G.M.; Berman, E.R. Chemical and clinical observation on the fate of various vitreous substitutes. *Acta Ophthalmol.* **1967**, *45*, 794–804.
159. Suri, S.; Banerjee, R. *In vitro* evaluation of in situ gels as short term vitreous substitutes. *J. Biomed. Mater. Res. A* **2006**, *79*, 650–664.
160. Scuderi, G. Experimental research on transplantation of the vitreous (attempts of partial substitution with homogenous vitreous, with heterologous fluid, with solutions of polyvinylpyrrolidone). *Ann. Ottalmol. Clin. Ocul.* **1954**, *80*, 213–220.
161. Hayano, S.; Yoshino, T. Local application of polyvinylpyrrolidone (PVP) for some ocular diseases. *Rinsho Ganka* **1959**, *13*, 449–453.
162. Hong, Y.; Chirila, T.V.; Vijayasekaran, S.; Dalton, P.D.; Tahija, S.G.; Cuypers, M.H.; Constable, I.J. Crosslinked poly(1-vinyl-2-pyrrolidinone) as a vitreous substitute. *J. Biomed. Mater. Res.* **1996**, *30*, 441–448.

163. Hong, Y.; Chirila, T.V.; Cuypers, M.J.H.; Constable, I.J. Polymers of 1-vinyl-2-pyrrolidinone as potential vitreous substitutes: physical selection. *J. Biomater. Appl.* **1996**, *11*, 135–181.
164. Hong, Y.; Chirila, T.V.; Vijaysekaran, S.; Shen, W.; Lou, X.; Dalton, P.D. Biodegradation in vitro and retention in the rabbit eye of crosslinked poly(1-vinyl-2-pyrrolidinone) hydrogel as a vitreous substitute. *J. Biomed. Mater. Res.* **1998**, *39*, 650–659.
165. Chirila, T.V.; Hong, Y. Poly(1-vinyl-2-pyrrolidinone) hydrogels as vitreous substitutes: A rheological study. *Polym. Int.* **1998**, *46*, 183–195.
166. Muller-Jensen, K.; Kohler, H. An attempt to replace the vitreous body by polyacrylamide. *Ber. Zusammenkunft Dtsch. Ophthalmol. Ges.* **1968**, *68*, 181–184.
167. Muller-Jensen, K. Polyacrylamide as an alloplastic vitreous implant. *Graefes Arch. Klin. Exp. Ophthalmol.* **1974**, *189*, 147–158.
168. Refojo, M.F.; Zauberman, H. Optical properties of gels designed for vitreous implantation. *Invest. Ophthalmol.* **1973**, *12*, 465–467.
169. Aliyar, H.A.; Foster, W.J.; Hamilton, P.D.; Ravi, N. Towards the development of an artificial human vitreous. *Polym. Prep.* **2004**, *45*, 469–470.
170. Hamilton, P.D.; Aliyar, H.A.; Ravi, N. Biocompatibility of thiol-containing polyacrylamide polymers suitable for ophthalmic applications. *Polym. Prep.* **2004**, *45*, 495–496.
171. Swindle, K.E.; Hamilton, P.D.; Ravi, N. Advancements in the development of artificial vitreous humour utilizing polyacrylamide copolymers with disulfide crosslinkers. *Polym. Prep.* **2006**, *47*, 59–60.
172. Foster, W.J.; Aliyar, H.A.; Hamilton, P.; Ravi, N. Internal osmotic pressure as a mechanism of retinal attachment in a vitreous substitute. *J. Bioact. Compat. Polym.* **2006**, *21*, 221–235.
173. Daniele, S.; Refojo M.F.; Schepens, C.L.; Freeman, H.M. Glyceryl methacrylate hydrogel as a vitreous implant. *Arch. Ophthalmol.* **1968**, *80*, 120–127.
174. Hogen-Esch, T.E.; Shah, K.R.; Fitzgerald, C.R. Development of injectable poly(glyceryl methacrylate) hydrogels for vitreous prosthesis. *J. Biomed. Mater. Res.* **1976**, *10*, 975–976.
175. Refojo, M.F. Polymers in ophthalmic surgery. *J. Biomed. Mater. Res.* **1971**, *5*, 113–119.
176. Peyman, G.A.; Conway, M.D.; Karacorlu, M. Evaluation of silicone gel as a long-term vitreous substitute in nonhuman-primates. *Ophthalmic Surg. Lasers* **1992**, *23*, 811–817.
177. Fernandez-Vigo, J.; Rey, S.A.D.; Concheiro, A.; Martinez, M. Molecular weight dependence of the pharmacokinetic of hydroxypropyl methylcellulose in the vitreous. *J. Ocul. Pharmacol.* **1990**, *6*, 137–142.
178. Fernandez-Vigo, J.; Refojo, M.F.; Verstraeten, T. Evaluation of a viscoelastic solution of hydroxypropyl methylcellulose as a potential vitreous substitute. *Retina* **1990**, *10*, 148–152.
179. Schmolka, I.R. Artificial Skin. I. preparation and properties of Pluronic F127 gels for the treatment of burns. *J. Biomed. Mater. Res.* **1972**, *6*, 571–582.
180. Davidorf, F.H.; Chambers, R.B.; Kwon, O.W.; Doyle, W.; Gresak, P.; Frank, S.G. Ocular toxicity of vitreal pluronic polyol F-127. *Retina* **1990**, *10*, 297–300.
181. Dalton, P.D.; Chirila, T.V.; Hong, Y.; Jefferson, A. Oscillatory shear experiments as criteria for potential vitreous substitutes. *Polym. Gels Netw.* **1995**, *3*, 429–444.

182. Chirila, T.V.; Constable, I.J.; Hong, Y.; Vijayasekaran, S.; Humphrey, M.; Dalton, P.D.; Tahija, S.G.; Maley, M.L.; Cuypers, M.H.; Sharp, C.; Moore, S.R.; Vague, M.J. Synthetic hydrogel as an artificial vitreous body. A one year animal study of its effects on the retina. *Cells Mater.* **1995**, *5*, 83–96.
183. Benlian, W.; Zhang, J.; Huibin, W. The development of synthetic vitreous body and its experiment in rabbits. In *Polymers and Biomaterials*; Feng, H., Han, Y., Huang, L., Eds.; Elsevier Scientific Publishers B.V.: Amsterdam, The Netherlands, 1991; pp. 397–400.
184. Yamauchi, A. Synthetic vitreous body of PVA hydrogel. In *Polymer Gels—Fundamentals and Biomedical Applications*; De Rossi, D., Kajiwarra, K., Osada, Y., Yamauchi, A., Eds.; Plenum Press: New York, NY, USA, 1991; pp. 127–134.
185. Maruoka, S.; Matsuura, T.; Kawasaki, K.; Okamoto, M.; Yoshiaki, H.; Kodama, M.; Sugiyama, M.; Annaka, M. Biocompatibility of polyvinylalcohol gel as a vitreous substitute. *Curr. Eye Res.* **2006**, *31*, 599–606.
186. Cavalieri, F.; Miano, F.; D’Antona, P.; Paradossi, G. Study of gelling behaviour of poly(vinyl alcohol)-methacrylate for potential utilizations in tissue replacement and drug delivery. *Biomacromolecules* **2004**, *5*, 2439–2446.
187. De Jong, C.; Bali, E.; Libert, J.; Caspers-Velu, L. Adcon-L hydrogel as a vitreous substitute: Preliminary results. *Bull. Soc. Belg. Ophthalmol.* **2000**, *278*, 71–75.
188. Zeana, D.; Becker, J.; Kuckelkorn, R.; Kirchhof, B. Perfluorohexyloctane as a long-term vitreous tamponade in the experimental animal. Experimental perfluorohexyloctane substitution. *Int. Ophthalmol.* **1999**, *23*, 17–24.
189. Wong, D.; Lois, N. Perfluorocarbons and semifluorinated alkanes. *Semin. Ophthalmol.* **2000**, *15*, 25–35.
190. Meinert, H.; Roy, T. Semifluorinated alkanes—A new class of compounds with outstanding properties for use in ophthalmology. *Eur. J. Ophthalmol.* **2000**, *10*, 189–197.
191. Tornambe, P.E. Pneumatic retinopexy: the evolution of case selection and surgical technique: a twelve-year study of 302 eyes. *Trans. Am. Ophthalmol. Soc.* **1997**, *95*, 551–578.
192. Kim, S.S.; Smiddy, W.E.; Feuer, W.J.; Shi, W. Outcomes of sulfur hexafluoride (SF₆) versus perfluoropropane (C₃F₈) gas tamponade for macular hole surgery. *Retina* **2008**, *28*, 1408–1415.
193. Friberg, T.R.; Fourman, S.D. Scleral buckling and ocular rigidity. *Arch. Ophthalmol.* **1990**, *108*, 1622–1627.
194. Seo, J.M.; Park, K.S.; Yu, H.G.; Chung, H. Geometric changes of the eye with an encircling scleral buckle. *J. Kor. Ophthalmol.* **2002**, *43*, 1072–1080.
195. Gonzalez, G.; Fitt, A. The mathematical modelling of human eye. *Math. Today* **2003**, *39*, 20–25.
196. Keeling, S.L.; Propst, G. A mathematical model for the deformation of the eyeball by an elastic band. *Math. Med. Biol.* **2009**, *26*, 165–185.