POLITECNICO DI TORINO
Repository ISTITUZIONALE

A retrospective analysis of the management and surgical treatment of orbital lesions: Outcomes and rationale

Original
A retrospective analysis of the management and surgical treatment of orbital lesions: Outcomes and rationale / Gerbino, G., Gugliotta, Y., Corsico, M., Ramieri, G.. - In: JOURNAL OF CRANIO-MAXILLOFACIAL SURGERY. - ISSN 1010-5182. - 52:10(2024), pp. 1109-1115. [10.1016/j.jcms.2024.06.019]

Availability:
This version is available at: 11583/3016161 since: 2026-09-30T12:05:36Z

Publisher:
Elsevier

Published
DOI:10.1016/j.jcms.2024.06.019

Terms of use:

This article is made available under terms and conditions as specified in the corresponding bibliographic description in the repository

Publisher copyright

(Article begins on next page)

23 October 2026

Journal of Cranio-Maxillo-Facial Surgery 52 (2024) 1109–1115

Contents lists available at ScienceDirect

Journal of Cranio-Maxillo-Facial Surgery

journal homepage: www.jcmfs.com

A retrospective analysis of the management and surgical treatment of orbital lesions: Outcomes and rationale

G. Gerbino [a], Y. Gugliotta [a,*], M. Corsico [b], G. Ramieri [a]

[a] Department of Surgical Sciences, Maxillo - Facial Surgery Unit, AOU Città della Salute e della Scienza, University of Turin, Corso Bramante 88, 10126, Italy
[b] Division of Neuroradiology, Department of Diagnostic Imaging and Radiotherapy, AOU Città della Salute e della Scienza, University of Turin, Corso Bramante 88, 10126, Turin, Italy

ARTICLE INFO

Handling Editor: Prof. Emeka Nkenke

Keywords:
Orbit
Orbital etiology
Orbital neoplasms
Orbital diseases
Orbital pseudotumor

ABSTRACT

The orbital cavity is a subject of interest for various specialists, and achieving optimal outcomes requires comprehensive, multidisciplinary management. This study aims to report 10 years of experience in the preoperative, surgical, and postoperative care of patients with orbital lesions, examining their clinical, radiological, and anatomopathological features and outcomes.

A retrospective review of 125 patients who underwent surgical treatment for intraorbital masses between January 2012 and December 2021 was performed. Outcome measures included postoperative diplopia, exophthalmos, decimal visual acuity, eyeball position, ocular motility, operative time, complications, and aesthetic results. A total of 107 patients were included. All cases were discussed with a neuroradiologist to determine the best therapeutic approach based on preoperative imaging.

Preoperative diplopia was linked to extraconal ($p = 0.03$) and anterior ($p = 0.001$) lesions, and exophthalmos and visual acuity deterioration were associated with intraconal ($p = 0.02$; $p = 0.03$) and retrobulbar ($p = 0.001$; $p = 0.02$) lesions. Complications (11.2%) included diplopia, worsened visual acuity, postoperative blepharoptosis, and postoperative ectropion. Of the patients, 80.4% reported an "excellent" aesthetic outcome.

This study underscores the importance of a multidisciplinary approach based on a thorough analysis of preoperative imaging. Periorbital approaches tailored to the lesion's three-dimensional location enables safe access to most intraorbital lesions, resulting in minimal complications and good aesthetic results.

1. Introduction

The orbit is a small anatomical space which houses several neural and vascular structures determinant for ocular function. The topographic cross-sectional anatomy of the orbit is increasingly complex from the retrobulbar area to the apex, making the treatment of space occupying lesion a challenge because of the need to preserve vital structures for vision (Maroon and Kennerdell, 1984; Tel et al., 2022). The incidence of various type of orbital lesions varies greatly in the literature, and primary orbital tumors are relatively rare entities (Shinder et al., 2011; Bonavolontà et al., 2013). Orbital lesions, which can be classified as intraconal or extraconal depending on the relationship with the extraocular muscle cone, are frequently expressions of a systemic disease, ranging from hematological and inflammatory disorders to malignancies of other parts of the body spreading to orbit as a secondary localization (Tailor et al., 2013; Neems et al., 2018). Therefore, the orbital cavity is field of interest of many different specialists, such as ophthalmologists, neurosurgeons, otolaryngologists, plastic surgeons, and maxillofacial surgeons. Consequently, different surgical approaches are reported for lesions similar in location and size, depending on the individual preferences and preferred procedures of the surgeon and the specialty (Markowski et al., 2014). Different algorithms for surgical approaches to space-occupying lesions within the orbit have been proposed (Rootman et al., 1995; Paluzzi et al., 2015; Bernardo et al., 2017; Montano et al., 2018), and progress in the use of endoscopic techniques has increased the spectrum of choices for targeting orbital pathologies (Castelnuovo et al., 2015). Multidisciplinary management is necessary to choose an appropriate diagnostic and therapeutic approach and to enhance outcomes.

The aim of the present paper is to assess the preoperative, surgical, and postoperative management of patients with orbital lesions, and to report their clinical, radiological, and anatomopathological features and

* Corresponding author. Corso Bramante 88, 10126, Turin, Italy.
E-mail addresses: giovanni.gerbino@unito.it (G. Gerbino), ylenia.gugliotta@unito.it (Y. Gugliotta), guglielmo.ramieri@unito.it (G. Ramieri).

https://doi.org/10.1016/j.jcms.2024.06.019
Received 3 November 2023; Received in revised form 13 December 2023; Accepted 9 June 2024
Available online 10 June 2024
1010-5182/© 2024 The Authors. Published by Elsevier Ltd on behalf of European Association for Cranio-Maxillo-Facial Surgery. This is an open access article under the CC BY license (http://creativecommons.org/licenses/by/4.0/).

outcomes.

2. Materials and methods

2.1. Study design and sample

A retrospective review of patients with intraorbital lesions admitted to xxxxxxxxxxxxxxxxxxxxxx between January 2012 and December 2021 was performed. The inclusion criteria were as follows: lesions confined within the orbit and approached with periorbital incisions; age between 18 and 85 years; complete records; preoperative and postoperative high resolution magnetic resonance imaging (HR MRI); and at least 12 months follow up. Exclusion criteria were lesions with extraorbital extension or those requiring coronal or transcranial approaches; bony lesions of the orbital walls; and history of craniofacial fractures or syndromes.

Data were obtained from the hospital electronic medical records and archived in a database with access limited to the authors involved with data analysis. The study was conducted in accordance with the principles of the Declaration of Helsinki and was approved by the local ethical committee on April 4, 2023 (no. 00075/2022). Written informed consent for the collection and processing of data and images for research purposes was obtained from all patients.

2.2. Study variables and outcome parameters

Study variables included age, sex, histologic diagnosis and radiologic characteristics of the lesions and type of surgery performed. Outcome parameters included the following: severity of preoperative (T0) and postoperative diplopia rated on a scale of 0–3 (Table 1); preoperative and postoperative decimal visual acuity; exophthalmos (defined as a difference between the two eyes of more than 2 mm); clinical preoperative and postoperative position of the eyeball and ocular motility (abnormal or normal, rated by the same surgeon); and complications and operative time.

The degree of postoperative diplopia was clinically assessed 1 week (T1) and 6 months (T2) after surgery; in patients with subjective diplopia or limitations in ocular motility, the Hess-Lancaster test was conducted to confirm the clinical findings.

The aesthetic outcome was graded at T2 on a scale of 0–2: a score of 0 indicated an 'excellent' outcome when no visible surgical sequelae were noted by both the patient and surgeon. A score of 2 represented the worst outcome, indicating the need for surgical correction as reported by either the patient or surgeon. A score of 1 was assigned when some surgical sequelae, such as a scar, were noted by either the patient or surgeon, but both agreed that surgical correction was unnecessary (Zavattero et al., 2017).

2.3. Radiological features

Radiological features were noted at T0. Preoperative HR magnetic resonance imaging (MRI) was performed; the standard protocol consisted of axial SE T1W, TSE T2W and DWI sequences, coronal STIR sequences, and axial and coronal SE T1W sequences with fat saturation obtained after intravenous administration of gadolinium chelates. All cases were discussed with a neuroradiologist to establish a presumptive diagnosis and consequently the most appropriate surgical approach (Lee et al., 2009).

Multiparametric imaging was integrated with computed tomography (CT) and/or fluoro-2-deoxy-D-glucose positron emission tomography (FDG PET) CT postoperatively to complete staging in patients with malignant diseases.

Lesions were classified into superolateral, superomedial, inferomedial, and inferolateral. For this purpose, the orbit was divided into four quadrants, with two perpendicular lines passing through the center of the eyeball in a coronal view, considering the anatomic region where most of the lesion was located (Fig. 1a) (Rootman et al., 1995).

The retrobulbar space was defined by a line passing through the attachment of the optic nerve to the eyeball and orthogonal to a line between this point and the optic foramen in axial view. The posterior three-fifths of the retrobulbar space were defined as the surgical orbital apex (Purohit et al., 2016; Engin et al., 2021; Zurinam et al., 2021) (Fig. 1b).

The aspect of the margins was classified as infiltrative or non-infiltrative.

Table 1
Diplopia severity Category Assignment.

Diplopia Severity Grade	Criteria
3	Diplopia present in primary gaze
2	Diplopia reported in some aspect of daily life
1	Patient reported no diplopia, but on examination was found to have some degree of double vision
0	No subjective or objective diplopia

2.4. Surgical technique

The aim of surgery was diagnostic incisional biopsy in patients with infiltrative, more likely malignant lesions (Fig. 2), and radical excision in patients with lesions whose margins were well defined on preoperative imaging. Frozen section examination was not performed.

Most lesions in the upper quadrants were treated by an upper-lid crease approach (Fig. 3), while the lower quadrants were approached by transconjunctival incisions eventually extended with a lateral canthotomy; transcaruncular incision was used for the lower medial quadrant.

A temporary bone orbitotomy was performed when necessary to approach voluminous retrobulbar masses (Fig. 4). In the first 27 cases, the osteotomies were performed with a conventional drill saw, whereas the last 17 cases were performed with a piezoelectric device; preplating was always performed. A few patients with extraconal medial masses were treated by an endoscopic approach and were excluded from this study.

2.5. Statistical analysis

Descriptive statistics were generated using Microsoft Excel (Microsoft Corp., Redmond, WA, USA). The chi-square test was used for univariate analysis. A value of $p < 0.05$ was considered significant. SPSS Statistics Software (28.0.1.0; IBM Corp., Armonk, NY, USA) was used for analysis.

3. Results

3.1. Demographic, clinical, and radiological characteristics at T0

A total of 125 consecutive patients were identified. Of these, 18 were excluded because of incomplete follow up, leaving 107 patients to be included in this study (51.4% male; mean age 59.2 years; range 21–87 years). Almost one-third of patients (29%) had already been diagnosed with systemic disease in which the ocular symptoms were a new manifestation; most of these patients had hematologic disorders (77.4%), three had malignant oncologic diseases (two breast cancers, one melanoma), three neurofibromatosis type 2, and one patient eosinophilic granulomatosis with polyangiitis.

Clinical features at T0 are summarized in Table 2. The presence of exophthalmos and impaired visual acuity were associated with intraconal ($p = 0.02$; $p = 0.03$) and retrobulbar ($p = 0.001$; $p = 0.02$) lesions. Preoperative diplopia was associated with extraconal ($p = 0.03$) and anterior ($p = 0.001$) masses (Table 2).

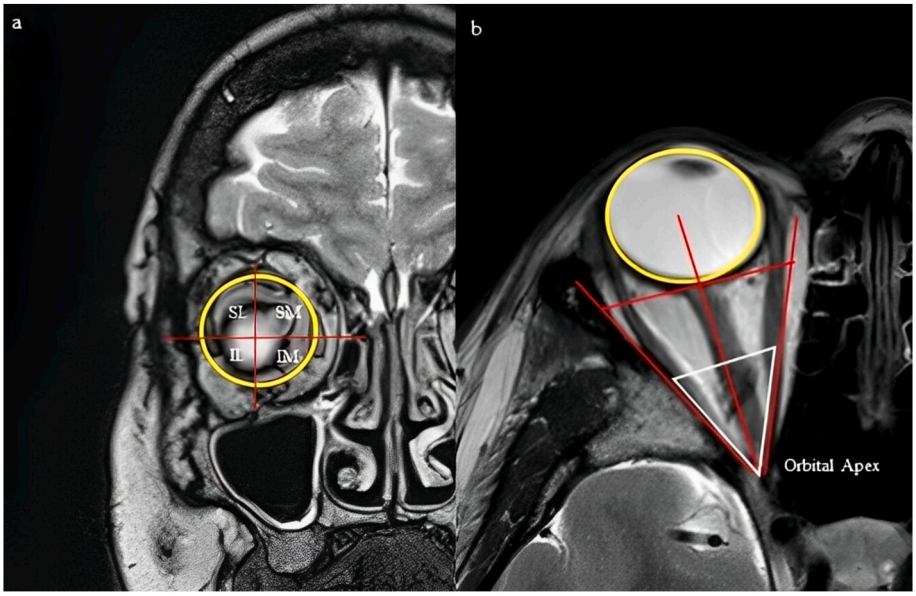

Fig. 1. Quadrants (a) and anteroposterior (b) classification of orbital masses.
Abbreviations: SL: superolateral; SM: superomedial; IL: inferolateral, IM: inferomedial.

Preoperative imaging revealed 50 lesions located in the superolateral quadrant (46.7%); 16 lesions were located superomedially (14.9%), eight inferolaterally (7.5%), and 17 inferomedially (15.9%); 16 patients had lesions located in the surgical orbital apex (15%). Most masses were retrobulbar (71%), and/or intraconal (58.9%). In 59 cases (55.1), the lesion had infiltrating margins; therefore, incisional biopsy was performed. In the remaining 48 cases (44.9%), the lesion was enucleated.

3.2. Pathology reports and clinical outcomes

Etiologies varied widely. Anatomopathological diagnosis and consequent postoperative management of the patients are summarized in Fig. 5.

In the case of lesions with well-defined non-infiltrative lesions (44.9%; n = 107), postoperative imaging at T2 confirmed complete excision of the mass, and no recurrence was detected except for one case of retrobulbar schwannoma that recurred after 8 months and required a second surgery. At the 3-year follow-up, the patient remained disease-free. None of these patients required radicalization surgery or subsequent adjuvant therapies.

In patients with infiltrative lesions, an incisional biopsy was conducted; all specimens provided a consistent diagnosis.

In most cases, the histopathological diagnosis confirmed the need for medical or radiotherapy treatment, particularly in cases of lymphomas and inflammatory diseases (46.7%; n = 107). Patients diagnosed with malignant primary tumors (5.6%: n = 107) were postoperatively discussed with oncologists and radiotherapists. The histopathologic diagnosis played a crucial role in determining the necessity for radicalization and/or adjuvant therapies.

In the three cases (2.8%: n = 107) of secondary malignancies, the primary tumor was re-staged. Given that these patients were all had late-stage cancer and multiple localizations, radical surgery was not performed.

At T1, 12 of 32 patients with preoperative diplopia still had some degree of diplopia, while four patients reported a new onset of grade 1 diplopia. At T2, compared with T0, four patients had worsened or new-onset diplopia; these were considered as complications (Table 3).

The 20% of patients with preoperative exophthalmos reported no reduction in the difference in protrusion of both eyes at T2. All other patients had improvement (Table 3).

Postoperative visual acuity improved in seven of the 17 patients (41.2%) with preoperatively reduced visual acuity. Two patients reported a postoperative reduction in visual acuity, which were considered as complications. No case of postoperative enophthalmos was reported.

The aesthetic outcome at T2 was rated as "excellent" in 86 cases (80.4%) and "good" in 15 cases. In six cases, two postoperative ectropion and four blepharoptosis, the patient or surgeon noted the need for surgical correction (Table 3).

The mean duration of surgery was 39.53 min (range, 15–125 min).

3.3. Surgical complications

Except for one case of significant intraoperative bleeding that required application of a local hemostatic matrix (Floseal-Baxter, Deerfield, IL, USA), no perioperative surgical complications such as infection, bone necrosis, or postoperative bleeding were recorded.

There were 12 (11.2%) long-term postoperative complications (T2) that occurred in a total of eight patients: four cases of worsening or new onset of diplopia, four cases of blepharoptosis, two cases of ectropion, and two cases of significant worsening of visual acuity. Complications were not associated either with the execution of osteotomies or with the location of the lesion (Table 4).

4. Discussion

Lesions of the orbit are rare entities consisting of a variety of different pathologies. Surgical management of these conditions may involve resection, biopsy to guide medical therapy, or orbital decompression to reduce pressure from mass effect (Lee et al., 2020).

This study shows that a joint, careful analysis of preoperative imaging allows the physician to determine whether it is appropriate to enucleate the lesion before a clear histopathologic diagnosis or whether it is safer to define the etiology of the lesion before starting medical or surgical therapy.

In this study, the histopathology reports and 1-year follow up confirmed that excision surgery with periorbital approaches was the best treatment option for all patients with lesions that were defined as “non-infiltrative” at preoperative HR RMN. None of these patients except one needed adjuvant therapies or second surgeries.

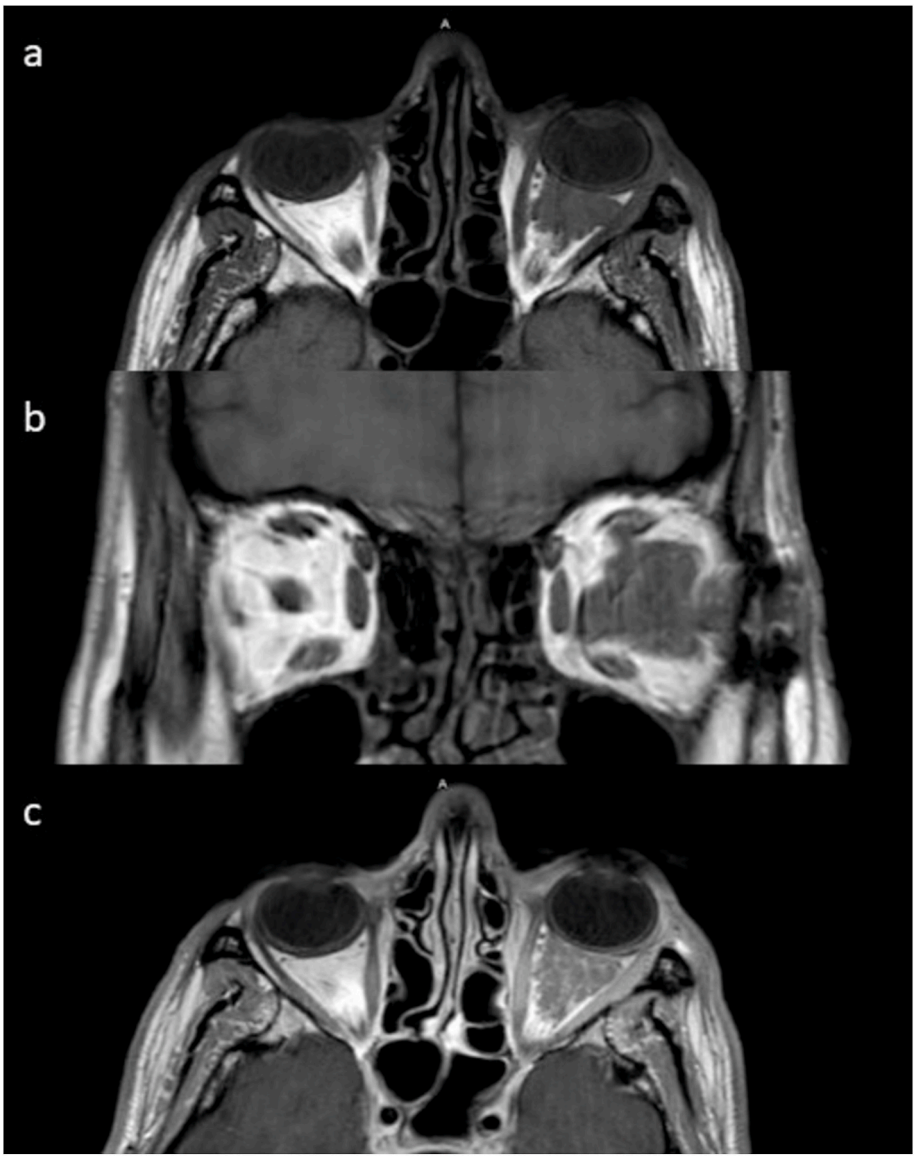

Fig. 2. Patient with intraconal, retrobulbar mucosa-associated lymphoid tissue (MALT) lymphoma preoperatively. HR RMN shows an intraconal, retrobulbar lesion with infiltrative margins, moderately hypointense on T1W images (a, b) with diffuse post-contrast enhancement (c).

In cases of infiltrative lesions, diagnostic biopsy was necessary to assess the most appropriate treatment. Diagnostic incisional biopsy allows the surgeon to avoid inappropriate surgical treatments in pathologies that can benefit from medical or radiation therapies (e.g., lymphomas and inflammatory diseases), and, when radical surgical treatment is indicated, to communicate with certainty to the patient the need to perform a more invasive surgical treatment (e.g., exenteratio orbiatae) and/or subsequent therapies. Incisional biopsy of retrobulbar lesions, especially when close to vital structures, can be challenging and requires careful planning as much as radical enucleation. The guiding principle for surgical management of intraorbital lesions is that the coronal and anteroposterior location of the pathology should dictate the choice of approach (Shields et al., 2004; Paluzzi et al., 2015).

While the use of periorbital incisions for anterior lesions is well supported by a number of studies (Rootman et al., 1995; Bonavolontà et al., 2013; Tailor et al., 2013; Markowski et al., 2014; Paluzzi et al., 2015; Montano et al., 2018; Neems et al., 2018), other routes have been proposed to approach the retrobulbar space.

When addressing lesions located superior and lateral to the optic nerve, in the present study, the upper eyelid crease incision, in combination with lateral orbitotomy, allowed good exposure of both the anterior and posterior masses (Shields et al., 2004) and guaranteed good surgical radicality for all retrobulbar lesions with a small number of complications.

Insofar as possible, the authors prefer this approach to the incision below the eyebrow because it provides a better aesthetic result.

Traditional approaches such as coronal, frontal, frontotemporal, and frontoorbitotemporal craniotomy provide excellent exposure of retrobulbar lesions (Cockerham et al., 2001; Markowski et al., 2014). These extraorbital approaches, other than being much more invasive and prolonging the duration of surgery and recovery, often require the presence of a neurosurgeon and also place the intraorbital structures in contact with the dura, increasing the risk of contamination (Bejjani et al., 2001; Cockerham et al., 2001).

Lesions located below the optic nerve can be approached by transconjunctival or transpalpebral incision (Kiratli et al., 2005; Trevisiol et al., 2021). In line with the meta-analysis by Al-Moraissi et al. (2018), this study confirms that transconjunctival approaches, in combination with cantolisis and temporary lateral bone orbitotomy, provide good access to the lower quadrants with little morbidity, short surgical and

Fig. 3. Patient with a superomedial intraconal low-flow venous malformation preoperatively (a) and postoperatively (b, e). HR RMN typically shows iso-to hypointense lesion on coronal T1W images; axial contrast-enhanced image shows initial patchy enhancement (c). Access to the upper eyelid crease was performed, and the mass was completely enucleated (d).

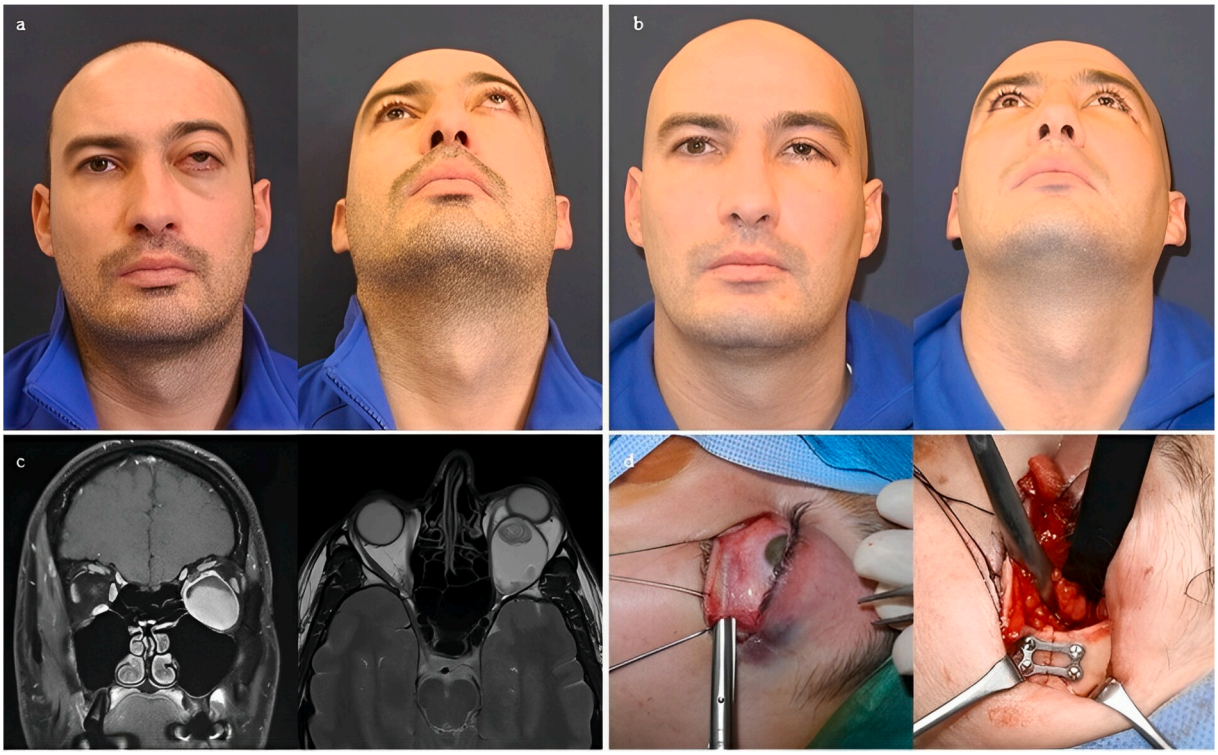

Fig. 4. Patient with intraconal eccrine hidrocystoma of the lower quadrants preoperatively (a) and postoperatively (b). Orbital magnetic resonance imaging disclosed an intraconal well-defined cystic lesion that was hypointense in T1-and hyperintense in T2-weighted images (c). A transconjunctival incision with lateral canthotomy and temporary lateral bone orbitotomy was performed to enucleate the lesion (d).

recovery time, and no visible scar (Shorr et al., 2000; Kiratli et al., 2005; Al-Moraissi et al., 2017, 2018; Trevisiol et al., 2021).

An endoscopic approach to the orbit provides a clear view of the medial orbital apex and excellent access to orbital tumors located medial to the optic nerve (Castelnuovo et al., 2015; Bleier et al., 2016; Colletti et al., 2017; Rimmer et al., 2020).

In this institution, the endoscopic approach has been used for a brief time, and is becoming increasingly used as the necessary learning curve is completed.

In this study, bone orbitotomy, performed to achieve sufficient

Table 2
Summary of clinical characteristics by mass localization at T0.

	Total n (%) N = 107	Intraconal n (%) N = 63	Extraconal n (%) N = 44	P Value[a]	Anterior n (%) N = 31	Retrobulbar n (%) N = 76	P Value[a]
Diplopia (any grade)	32 (29,9)	14 (22,2)	18 (40,9)	0,03	16 (51,6)	16 (21,05)	0,001
Pain	19 (17,75)	11 (17,5)	8 (18,2)	0,9	6 (19,35)	13 (17,1)	0.78
Impaired visual acuity	17 (15,9)	14 (22,2)	3 (6,8)	0,03	1 (3,2)	16 (21)	0.02
Exophthalmos	60 (56,1)	41 (65,1)	19 (43,2)	0,02	10 (32,2)	50 (65,8)	0.001
Eye motility limitation	34 (31,8)	16 (25,4)	18 (40,9)	0,08	14 (45,2)	20 (26,3)	0,06
Ocular dystopia	29 (27,1)	15 (23,8)	14 (31,8)	0,35	12 (38,7)	17 (22,4)	0.08
Blepharotosis	23 (21,5)	13 (20,6)	10 (22,7)	0,79	9 (29)	14 (18,4)	0.2

[a] Chi-square test was conducted Lee et al. (2020).

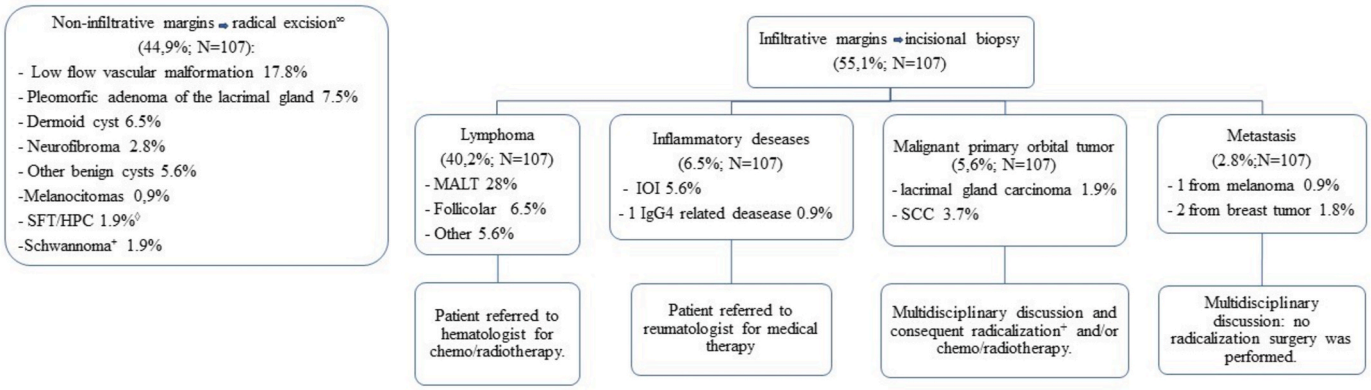

Fig. 5. Histopathological diagnosis and consequent management of the patients.
∞ In all cases, postoperative (T2) imaging confirmed complete excision of the mass.
+Second surgeries were not included in the present study.
Abbreviations: MALT: mucose-associated lymphoid tissue; MF: maxillofacial; IOI: idiopathic orbital inflammation (so-called pseudotumor, nonspecific orbital inflammation); SFT/HPC: solitary fibrous tumor/hemangiopericytoma; SCC: squamous cell carcinoma, FU: follow up; T1: 1-month follow up; T2: 6-month follow up.

Table 3
Summary of clinical outcomes at T1 and T2.

	No. of patients
Diplopia at T2	12
Persistence of preoperative (T0) diplopia	10
Worsened compared to T0[a]	2
Postoperative onset of diplopia	2
Exophthalmos at T2 vs T0	
Absent or Improved	48
Unvariated	12
Postoperative visual acuity at T2 vs T0	
Increased	7
Decreased	2
Unvariated	98
Ocular dystopia at T2 vs T0	
Absent	10
Improved	19
Aesthetic result	
Excellent	86
Good	15
Poor	6

[a] These 2 patients are also included in the "persistence of preoperative (T0) diplopia" row.

surgical space for approaching lesions contiguous to the optic nerve, did not show a statistically significant association with a higher risk of postoperative complications. Hence, patients with retrobulbar lesions, in whom bone orbitotomy was frequently performed, experienced a higher incidence of complications. Notably, no complications related to the osteotomy itself, such as plate infection or exposure, secondary bone displacement, or bone necrosis, were recorded.

Table 4
Distribution of functional complications at T2 by position of the mass and execution of bone orbitotomy.

	New Onset or Worsened Diplopia n (%)	Worsened visual acuity n (%)
Intraconal (N = 63)	3 (4,8)	2 (3,17)
Extraconal (N = 44)	1 (2,3)	0
P value[a]	0,5	0.2
Anterior (N = 31)	0	0
Retrobulbar (N = 76)	4 (5,3)	2 (2,6)
P value[a]	0.19	0.4
Orbitotomy (N = 44)	3 (6,8)	1 (2,3)
No orbitotomy(N = 63)	1 (1,6)	1 (1,6)
P value[a]	0.2	0.8

[a] Chi-square test was conducted.

Limitations of this study were its retrospective design, the long course of the study with patients treated by different surgeons, and the small number of patients given the low incidence of complications. This does not permit one to significantly correlate the position of the lesions and the performance of the lateral bone orbitotomy with the incidence of postoperative diplopia and worsening of visual acuity.

5. Conclusion

This study shows that a joint, careful analysis of preoperative imaging and the use of periorbital approaches, in combination with temporary customized orbitotomy, allow treatment of intraorbital masses

with a low incidence of complications and excellent aesthetic results.

Further studies with larger numbers of patients are needed to evaluate whether the execution of temporary bone orbitotomy affects the incidence of complications.

Funding

None. This research did not receive any specific grant.

Declaration of interest

All authors disclose any financial and personal relationships with other people or organizations that could inappropriately influence (bias) their work.

Financial support

None.

Declaration of generative AI and AI-assisted technologies in the writing process

During the preparation of this work the author(s) did not use any AI-assisted technologies.

Acknowledgements

None.

References

Al-Moraissi, E.A., Thaller, S.R., Ellis, E., 2017. Subciliary vs. transconjunctival approach for the management of orbital floor and periorbital fractures: a systematic review and meta-analysis. J. Cranio-Maxillo-Fac. Surg. 45, 1647–1654.

Al-Moraissi, E., Elsharkawy, A., Al-Tairi, N., Farhan, A., Abotaleb, B., Alsharaee, Y., Oginni, F.O., Al-Zabidi, A., 2018. What surgical approach has the lowest risk of the lower lid complications in the treatment of orbital floor and periorbital fractures? A frequentist network meta-analysis. J. Cranio-Maxillo-Fac. Surg. 46, 2164–2175.

Bejjani, G.K., Cockerham, K.P., Kennerdel, J.S., Maroon, J.C., 2001. A reappraisal of surgery for orbital tumors. Part I: extraorbital approaches. Neurosurg. Focus 10 (1), 6.

Bernardo, A., Evins, A.I., Mattogno, P.P., Quiroga, M., Zacharia, B.E., 2017. The orbit as seen through different surgical windows: extensive anatomosurgical study. World Neurosurg 106, 1030–1046.

Bleier, B.S., Castelnuovo, P., Battaglia, P., Turri-Zanoni, M., Dallan, I., Metson, R., Sedaghat, A.R., Stefko, S.T., Gardner, P.A., Snyderman, C.H., Nogueira, J.F., Ramakrishnan, V.R., Muscatello, L., Lenzi, R., Freitag, S., 2016. Endoscopic endonasal orbital cavernous hemangioma resection: global experience in techniques and outcomes. Int Forum Allergy Rhinol 6, 156–161.

Bonavolontà, G., Strianese, D., Grassi, P., Comune, C., Tranfa, F., Uccello, G., Iuliano, A., 2013. An analysis of 2,480 spaceoccupying lesions of the orbit from 1976 to 2011. Ophthalmic Plast. Reconstr. Surg. 29, 79–86.

Castelnuovo, P., Turri-Zanoni, M., Battaglia, P., Locatelli, D., Dallan, I., 2015. Endoscopic endonasal management of orbital pathologies. Neurosurg Clin N Am 26, 463–472.

Cockerham, K.P., Bejjani, G.K., Kennerdell, J.S., Maroon, J.C., 2001. Surgery for orbital tumors. Part II: transorbital approaches. Neurosurg. Focus 10 (1), 6.

Colletti, G., Saibene, A.M., Pessina, F., Duvina, M., Allevi, F., Felisati, G., Biglioli, F., 2017. A shift in the orbit: immediate endoscopic reconstruction after transnasal orbital tumors resection. J. Craniofac. Surg. 28 (2027), 2029.

Engin, Ö., Adriaensen, G.F.J.P.M., Hoefnagels, F.W.A., Saeed, P., 2021. A systematic review of the surgical anatomy of the orbital apex. Surg. Radiol. Anat. 43, 169–178.

Kiratli, H., Bulur, B., Bilgiç, S., 2005. Transconjunctival approach for retrobulbar intraconal orbital cavernous hemangiomas. Orbital surgeon's perspective. Surg. Neurol. 64 (71), 74.

Lee, A.G., Johnson, M.C., Policeni, B.A., Smoker, W.R., 2009. Imaging for neuro-ophthalmic and orbital disease–a review. Clin. Exp. Ophthalmol. 37, 30–53.

Lee, R.P., Khalafallah, A.M., Gami, A., Mukherjee, D., 2020. The lateral orbitotomy approach for intraorbital lesions. J Neurol Surg B Skull Base 81, 435–441.

Markowski, J., Jagosz-Kandziora, E., Likus, W., Pająk, J., Mrukwa-Kominek, E., Paluch, J., Dziubdziela, W., 2014. Primary orbital tumors: a review of 122 cases during a 23-year period: a histo-clinical study in material from the ENT Department of the Medical University of Silesia. Med Sci Monit 20, 988–994.

Maroon, J.C., Kennerdell, J.S., 1984. Surgical approaches to the orbit. Indications and techniques. J. Neurosurg. 60, 1226–1235.

Montano, N., Lauretti, L., D'Alessandris, Q.G., Rigante, M., Pignotti, F., Olivi, A., Paludetti, G., Pallini, R., Fernandez, E., 2018. Orbital tumors: report of 70 surgically treated cases. World Neurosurg 119, e449 e458.

Neems, L., Echalier, E.L., Subramanian, P.S., 2018. Orbital tumors and inflammatory disorders: diagnosis and management. Int. Ophthalmol. Clin. 58, 181–195.

Paluzzi, A, Gardner, PA, Fernandez-Miranda, JC, Tormenti, MJ, Stefko, ST, Snyderman, CH, Maroon, JC, 2015 Feb. "Round-the-Clock" surgical access to the orbit. J. Neurol. Surg. B Skull Base 76 (1), 12–24. https://doi.org/10.1055/s-0033-1360580. Epub 2014 Sep 2. PMID: 25685644; PMCID: PMC4318736.

Purohit, B.S., Vargas, M.I., Ailianou, A., Merlini, L., Poletti, P.A., Platon, A., Delattre, B. M., Rager, O., Burkhardt, K., Becker, M., 2016. Orbital tumours and tumour-like lesions: exploring the armamentarium of multiparametric imaging. Insights Imaging 7, 43–68.

Rimmer, R.A., Graf, A.E., Fastenberg, J.H., Bilyk, J., Nyquist, G.G., Rosen, M.R., Rabinowitz, M.P., Rabinowitz, M.R., 2020. Management of orbital masses: outcomes of endoscopic and combined approaches with No orbital reconstruction. Allergy Rhinol 11 (1), 7.

Rootman, J., Stewart, B., Goldberg, R.A., 1995. Orbital Surgery. A Conceptual Approach, vol. 151. Lippincott-Raven, p. 289. Philadelphia.

Shields, J.A., Shields, C.L., Scartozzi, R., 2004. Survey of 1264 patients with orbital tumors and simulating lesions: the 2002 Montgomery Lecture, part 1. Ophthalmology 111 (997), 1008.

Shinder, R., Al-Zubidi, N., Esmaeli, B., 2011. Survey of orbital tumors at a comprehensive cancer center in the United States. Head Neck 33, 610–614.

Shorr, N., Baylis, H.I., Goldberg, R.A., Perry, J.D., 2000. Transcaruncular approach to the medial orbit and orbital apex. Ophthalmology 107, 1459–1463.

Tailor, T.D., Gupta, D., Dalley, R.W., Keene, C.D., Anzai, Y., 2013. Orbital neoplasms in adults: clinical, radiologic, and pathologic review. Radiographics 33, 1739–1758.

Tel, A., Murta, F., Sembronio, S., Costa, F., Robiony, M., 2022. Virtual planning, and navigation for targeted excision of intraorbital space-occupying lesions: proposal of a computer-guided protocol. Int. J. Oral Maxillofac. Surg. 51, 269–278.

Trevisiol, L., D'Agostino, A., Gasparini, S., Bettini, P., Bersani, M., Nocini, R., Favero, V., 2021. Transconjunctival and Subciliary Approach in the Treatment of Orbital Fractures: A Study on Oculoplastic Complication 10:2775.

Zavattero, E., Ramieri, G., Roccia, F., Gerbino, G., 2017. Comparison of the outcomes of complex orbital fracture repair with and without a surgical navigation system: a prospective cohort study with historical controls. Plast. Reconstr. Surg. 139, 957–965.

Zurinam, O., Safieh, C., Redler, Y., Orbach, A., Lumelsky, D., Neeman, Z., Briscoe, D., 2021. CT definition of the surgical apex in the orbit. Sci. Rep. 11, 11016.