

What factors influence treatment decision making in acoustic neuroma? Our experience on 103 cases

Original

What factors influence treatment decision making in acoustic neuroma? Our experience on 103 cases / Cassandro, H.; Albera, R.; Debiasi, L.; Albera, A.; Cassandro, E.; Scarpa, A.; Ralli, M.. - In: THE INTERNATIONAL TINNITUS JOURNAL. - ISSN 0946-5448. - 24:1(2020), pp. 21-25. [10.5935/0946-5448.20200005]

Availability:

This version is available at: 11583/2859996 since: 2021-01-08T12:00:59Z

Publisher:

International Tinnitus Journal

Published

DOI:10.5935/0946-5448.20200005

Terms of use:

This article is made available under terms and conditions as specified in the corresponding bibliographic description in the repository

Publisher copyright

(Article begins on next page)

What factors influence treatment decision making in acoustic neuroma? Our experience on 103 cases

HClaudia Cassandro¹
Roberto Albera¹
Luca Debiasi¹
Andrea Albera¹
Ettore Cassandro²
Alfonso Scarpa²
Massimo Ralli^{3*}

ABSTRACT

Acoustic Neuromas (AN) are benign tumors of the vestibulocochlear nerve with symptomatology that includes unilateral sensorineural hearing loss, tinnitus, dizziness, facial and/or trigeminal neuropathy. There are different treatment options of AN: watchful waiting, microsurgical resection, stereotactic radiation and the choice depends by many variables such age, health and hearing of patients as size, location and growing status of tumor. The objective of this retrospective study is to better understand the differences in demographic, hearing status, symptoms, tumor characteristics in patients affected by AN presenting at our clinic and analyze the factors that influence the therapeutic choice. One-hundred three patients affected by AN were included in the study. All subjects underwent a detailed clinical interview and audio-vestibular examination, and Magnetic Resonance Imaging (MRI). Tumor status, growing or stable was estimated comparing new size to any previous MRI with at least a 6-month interval. Descriptive statistics were used for clinical and demographic features of patients. Therapeutic choices related to subjective symptoms were assessed with the chi-square test. Treatment options in our sample included watchful waiting, surgical resection and stereotactic radiosurgery. Overall, 17 patients (16.5%) pursued surgical resection *via* the retrosigmoid approach, 3 patients (2.9%) were treated with gamma knife stereotactic radiosurgery and 83 patients (80.6%) underwent watchful waiting. The decision-making process for AN treatment was based on size of tumor, age, and hearing loss; a statistically significant difference was found at Z test about size of tumor and PTA of patients that underwent retrosigmoid surgery. No statistically significant difference was found at chi-square test between the type of treatment and symptoms ($p=0.719$). The analysis of the data showed that the main elements taken into consideration for surgery were the size of tumor ($p<0.000004$) and, secondly, the PTA threshold; the latter may be due to the fact that patients with bigger tumors had greater hearing impairment ($p<0.001$). Disease progression influenced the therapeutic decision making with a positive correlation between tumor progression and surgery ($p<0.001$). In our sample, active surveillance was the most adopted option for small tumor, slow growth and old age. Microsurgical resection was the preferred treatment in patients with large tumors, hearing deterioration and rapid growth. Stereotactic radiation has been proposed in a few cases of elderly patients with slow growing tumor and mild hearing loss.

Keywords: Acoustic neuromas, vestibular schwannoma, treatment options, shared decision making, sensorineural hearing loss.

¹Department of Surgical Sciences, University of Turin, Turin, Italy

²Department of Medicine and Surgery, University of Salerno, Salerno, Italy

³Department of Sense Organs, Sapienza University Rome, Rome, Italy

*Send correspondence to: Massimo Ralli

Department of Sense Organs, Sapienza University of Rome, Italy, E-mail: Massimo.ralli@uniroma1.it Phone: +39 0649976808

Paper submitted on February 07, 2020; and Accepted on February 28, 2020

INTRODUCTION

Acoustic Neuromas (AN) are benign tumors typically developing from Schwann cells of the vestibulocochlear nerve (also known as vestibular schwannomas). AN often have slow growing with an incidence of 1 per 100.000 people per year and typical presentation occurs in the 5th or 6th decade of life with no sex difference^{1,2}. Clinical symptoms of AN are variable and generally include unilateral sensorineural hearing loss, tinnitus, dizziness, facial and/or trigeminal neuropathy, especially with larger tumors^{3,4}. Rarely, AN can be bilateral, as described in neurofibromatosis Type 1 or Type 2^{5,6}. Management options for AN include watchful waiting, stereotactic radiation and microsurgical resection *via* the translabyrinthine, retrosigmoid or middle cranial fossa approach^{7,8}. The decision making between treatment must consider health status, age and symptoms of patient as well as hearing impairment, location, tumor size and growth status⁹⁻¹¹. Watchful waiting is generally preferred when the tumor is small, if it grows slowly and in the elderly^{12,13}. Treatment options depend on physician expertise, risk tolerance, tumor characteristics and complications such as nerve and vessel injury and meningitis for microsurgical resection, and cerebrospinal fluid leak and hearing loss for stereotactic radiation¹⁴⁻¹⁶. The objective of this retrospective study is to better understand the differences in demographic, hearing status, symptoms, tumor size and growth in patients affected by AN presenting at our university hospital and analyse the factors that influence the therapeutic choice.

MATERIALS AND METHODS

Subject Selection and Characteristics: This retrospective study was conducted on 103 consecutive patients affected by AN presenting at the Otolaryngology Unit of the University of Turin "Le Molinette", Italy, between January 2016 and March 2019; 49 were males (47.6%) and 54 were females (52.4%). Mean age was 57 years (range: 32-83 years, SD=12). Of these patients, some were diagnosed with magnetic resonance imaging (MRI) prescribed after an otolaryngology visit, others with occasional MRI. Tumor size was calculated by greater diameter based on high-resolution T1 axial post contrast gadolinium sequences. Tumor status, growing or stable, was estimated comparing new size to any previous MRI with at least a 6-month interval. The classification proposed by KOOS was adopted¹⁷. AN were on the right side in 50 patients (48.5%) and in the left side in 52 patients (51.5%). Only one patient had a bilateral neuroma (neurofibromatosis type 1). Patients signed a written informed consent; the procedures were performed in accordance with the standards of the ethics committee on human experimentation of the University of Turin, that specifically approved this study, and with the Helsinki Declaration. Inclusion criteria were adult age (≥ 18 years) and radiological diagnosis of AN. Exclusion criteria were concomitant Meniere's disease and previous ear surgery

Audio-vestibular Assessment: A clinical interview investigating medical history, current medications, presence of dizziness, gait and audiological symptoms was performed. All subjects underwent a detailed audio-vestibular examination that included video-otoscopic examination, Pure-Tone Audiometry (PTA) and acoustic immittance measures. PTA was measured using a clinical audiometer (Piano Clinical Audiometer Inventis, Padua, Italy) inside a soundproof booth. PTA was measured at frequencies of 125, 250, 500, 1000, 2000, 3000, 4000, and 8000 Hz; data from the frequencies 500, 1000, 2000 and 4000 Hz were used in the study. Hearing was considered symmetrical if thresholds for each ear occurred within 10 dB of each other. Hearing impairment was ranked as mild, moderate, severe, or profound as follows: mild, 26-40 dB; moderate, 41-70 dB; severe, 71-90 dB, profound, >90 ¹⁸.

Statistical Analysis: Descriptive statistics were used for clinical and demographic features of patients. Therapeutic choices related to subjective symptoms were assessed with the chi-square test. A p value < 0.05 was considered for statistical significance.

RESULTS

The average tumor size was 12 mm (range 1-40 mm); most patients had small tumors (7-15 mm) classified as KOOS I (Figure 1). The clinical symptoms found in our sample and their correlation with the size of the tumor is reported in Table 1. Sensorineural hearing loss was the most frequent symptom, with no substantial difference with respect to the onset of clinical symptoms. On the contrary, tinnitus and dizziness increased over time. Moreover, the incidence of symptoms increased with tumor growth. PTA of affected and unaffected side is showed in Figure 2. Treatment options in our sample included watchful waiting, surgical resection and stereotactic radiosurgery. Overall, 17 patients (16.5%) pursued surgical resection *via* the retrosigmoid approach, 3 patients (2.9%) were treated with gamma knife stereotactic radiosurgery and 83 patients (80.6%) underwent watchful waiting. In our sample, the decision-making process for AN treatment was based on size of tumor, age, and hearing loss; a statistically significant difference was found at Z test about size of tumor and PTA of patients that underwent retrosigmoid surgery (Table 2). No statistically significant difference was found at chi-square test between the type of treatment and symptoms ($p = 0.719$) (>0.05). The analysis of the data showed that the main elements taken into consideration for surgery were the size of tumor ($p < 0.000004$) ($\alpha > 0.05$) and, secondly, the PTA threshold; the latter may be due to the fact that patients with bigger tumors had greater hearing impairment ($p < 0.001$ to the Pearson test) (Table 3). Regarding tumor progression, monitored with follow up MRI, 72 patients (69.9%) showed no tumor growth at MRI and underwent active surveillance, whereas 15 patients (14.6%) showed an increase in tumor size. Sixteen (15.5%) subjects were lost at follow up (missed the second MRI) and were excluded from the study. Patients with increased tumor size underwent

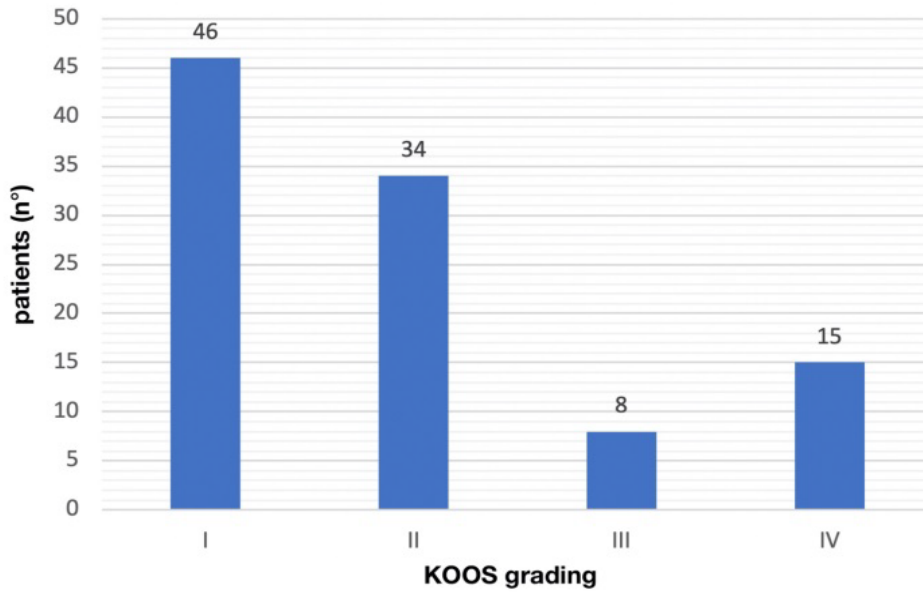


Figure 1: Number of patients in our sample classified following the KOOS grading (I-II-III-IV).

Table 1: Onset and late symptomatology of patients and its correlation with the size of the tumor in accordance with KOOS grading. pt: number of patients; I, II, III, IV: KOOS grading; onset: symptomatology at onset; late: symptomatology at the end.

	Onset (pt=103)	Late (pt=103)	KOOS I (pt=46)	KOOS II (pt=34)	KOOS III (pt=8)	KOOS IV (pt=15)
Hearing loss	82 (79%)	84 (82%)	33	29	8	14
Tinnitus	3 (3%)	64 (62%)	26	18	8	12
Vertigo	11 (11%)	43 (42%)	21	10	6	6
Others	7 (7%)	7 (7%)	5	3	0	0

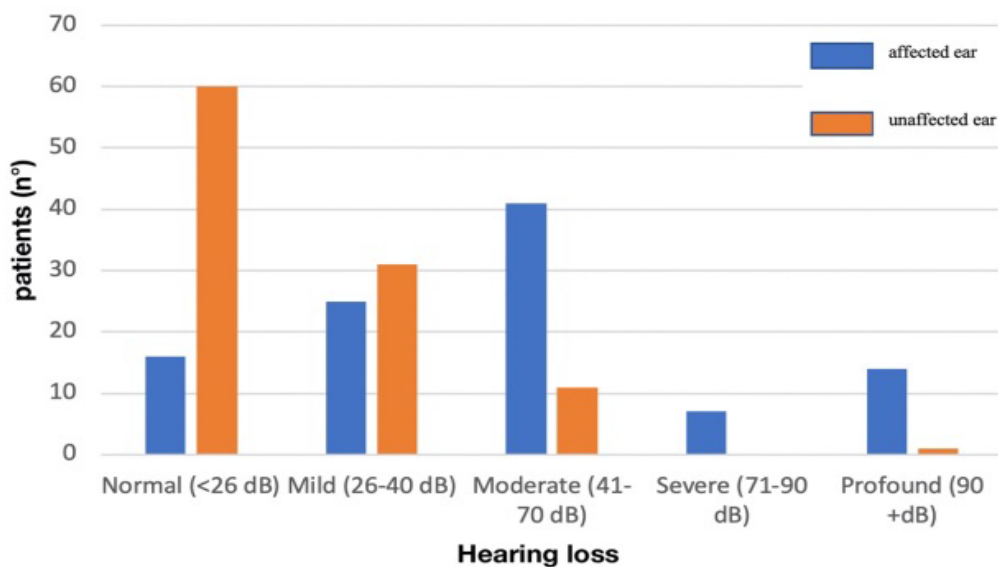


Figure 2: Correlation between number of patients and hearing status in affected and unaffected ear according to hearing loss classification.

Table 2: The treatment decision making in consideration of age, size and hearing of patients (PTA). A statistically significant difference was found at Z test about size of tumor (p value <0.0001) and PTA of patients (p value 0.009). pt: number of patients; SD: standard deviation.

Decision making	Age (mean 57y; SD 12)	Size (mean 12mm; SD 7)	PTA (mean 54dB; SD 28)
Watchful waiting (83pt)	58pt (13%); mean age 58y p value 0.2	11pt (11%); mean 11 mm p value 0.09	52pt (25%); mean 52 dB p value 0.26
Surgery via retrosigmoid approach (17pt)	54pt (12%); mean age 54y p value 0.14	20pt (9%); mean 20 mm p value <0.0001	70pt (38%); mean 70 dB p value 0.009
Gamma knife (3pt)	65pt (13%); mean age 65y p value 0.13	11pt (3%); mean 11 mm p value 0.4	38pt (21%); mean 38 dB p value 0.15

Table 3: Correlation between number of patients, KOOS grading, therapeutic choice and hearing status (PTA) according to hearing loss classification (18).

Hearing	KOOS I (46pt)	KOOS II (34pt)	KOOS III (8pt)	KOOS IV (15pt)	Watchful waiting (83pt)	Surgery via retrosigmoid approach (17pt)	Gamma knife (3pt)
Normal (<26 dB)	11	5	0	0	14	1	1
Mild (26-40 dB)	8	10	2	3	20	4	1
Moderate (41-70 dB)	19	12	3	9	35	6	1
Severe (71-90 dB)	5	1	1	0	6	1	0
Profound (>90 dB)	3	6	2	3	8	5	0

microsurgery resection (5 patients, 33.3%), stereotactic radiation (2 patients, 13.3%), and watchful waiting (3 patients, 20%) as the tumor was slowly growing. In our sample, disease progression influenced the therapeutic decision making with a positive correlation between tumor progression and surgery ($p < 0.001$).

DISCUSSION

In our study we found three conditions that mainly influenced the decision-making process for microsurgical resection: large tumor size, tumor progression and worse hearing classification. In fact, 71% of patients that underwent surgery were classified as grade III or IV according to KOOS classification with a PTA threshold >70 dB nHL. There was no significant association between symptomatology and treatment. Watchful waiting was the option of choice for small tumors (I-II KOOS), tumors with a slow growth and in elderly patients, although no statistically significant difference was found. On average, AN are slow growing; as a result, conservative approach with periodic MRI is a reasonable option. Only 3 patients underwent stereotactic radiation; all of them were classified as grade II at KOOS. In the treatment decision making process, physicians consider the balance of risks and benefits of microsurgery resection or stereotactic radiation compared to watchful waiting. Many studies have evaluated tumor size and growth status in the selection of the proposed approach¹⁹ the choice to treat or not to treat tumor were mostly influenced by growth (>2 mm/year)^{20,21}. Furthermore, it is established that large tumors at diagnosis have higher possibility of growing compared to small tumors^{9,22}. Age has a central role in treatment decision making. Surgical complications are most frequent in elderly patients; evidence shows that a more conservative approach is recommended for patients older than 65^{23,24}. In fact, older patients may choose active surveillance to avoid complications of surgery, thus maintaining a satisfactory quality of life. In a recent meta-analysis, Smouha et al. recommended conservative management of AN in elderly patients with small tumors with no or slight audio vestibular symptoms²⁵. In a review from Myrseth et al. the authors showed that tumor size and surgeon's experience played a significant role for complications such as mortality in 0-2%, facial nerve injury in 2.5-7%, meningitis in 1-3% and cerebrospinal fluid leak in 3-15%²⁶. Stereotactic radiosurgery offer similar tumor control rates compared to microsurgery for

small tumors²⁷⁻²⁹ and a similar rate of complications such as hearing deterioration, trigeminal neuropathy, facial nerve injury, and hydrocephaly compared to surgery³⁰. Furthermore, accumulating evidence has showed that lower doses and a more precise planning may offer greater preservation of hearing and reduction of facial neuropathy compared to surgery for AN patients²⁶⁻³¹.

CONCLUSION

Our data on 103 patients with AN show that active surveillance was the most adopted option and the criteria that influenced the choice were the size of the tumors (small size), the growth rate (slow growth) and old age. When a treatment was proposed, microsurgical resection was the preferred choice in patients with large tumors, hearing deterioration and rapid growth. On the other hand, stereotactic radiation has been proposed in a few cases of elderly patients with slow growing tumor and mild hearing loss.

CONFLICT OF INTEREST

The authors declare no potential conflict of interest on publishing this paper.

REFERENCES

1. Stangerup SE, Tos M, Thomsen J, Caye-Thomasen P. True incidence of vestibular schwannoma? *Neurosurgery*. 2010;67:1335-40.
2. Darrouzet V, Martel J, Enee V, Bebear JP, Guerin J. Vestibular schwannoma surgery outcomes: our multidisciplinary experience in 400 cases over 17 years. *Laryngoscope*. 2004;114:681-8.
3. Jeyakumar A, Seth R, Brickman TM, Dutcher P. The prevalence and clinical course of patients with 'incidental' acoustic neuromas. *Acta Otolaryngol*. 2007;127:1051-7.
4. Matthies C, Samii M. Management of 1000 vestibular schwannomas (acoustic neuromas): clinical presentation. *Neurosurgery*. 1997;40:1-9.
5. Baser ME, Friedman JM, Joe H, Shenton A, Wallace AJ, Ramsden RT, et al. Empirical development of improved diagnostic criteria for neurofibromatosis *Genet Med*. 2011;13:576-81.
6. Neurofibromatosis. Natl Inst Health Consens Dev Conf Consens Statement. 1987;6:1-7.
7. Chamoun R, MacDonald J, Shelton C, Couldwell WT. Surgical approaches for resection of vestibular schwannomas: translabyrinthine, retrosigmoid, and middle fossa approaches. *Neurosurg Focus*. 2012;33:1-6.

8. Tan M, Myrie OA, Lin FR, Niparko JK, Minor LB, Tamargo RJ, et al. Trends in the management of vestibular schwannomas at Johns Hopkins 1997-2007. *Laryngoscope*. 2010;120:144-9.
9. Agrawal Y, Clark JH, Limb CJ, Niparko JK, Francis HW. Predictors of vestibular schwannoma growth and clinical implications. *Otol Neurotol*. 2010;31:807-12.
10. Fucci MJ, Buchman CA, Brackmann DE, Berliner KI. Acoustic tumor growth: implications for treatment choices. *Am J Otol*. 1999;20:495-9.
11. Ralli M, Nola G, Fusconi M, Sparvoli L, Ralli G. Ocular vestibular evoked myogenic potentials and intravestibular intralabyrinthine schwannomas. *Ear Nose Throat J*. 2018;97:21-5.
12. Martin TP, Senthil L, Chavda SV, Walsh R, Irving RM. A protocol for the conservative management of vestibular schwannomas. *Otol Neurotol*. 2009;30:381-5.
13. Strasnick B, Glasscock ME, Haynes D, McMenomey SO, Minor LB. The natural history of untreated acoustic neuromas. *Laryngoscope*. 1994;104:1115-9.
14. Santa Maria PL, Shi Y, Gurgel RK, Corrales CE, Soltys SG, Santa Maria C, et al. Long-Term Hearing Outcomes Following Stereotactic Radiosurgery in Vestibular Schwannoma Patients-A Retrospective Cohort Study. *Neurosurgery*. 2019;85:550-9.
15. Elliott A, Hebb AL, Walling S, Morris DP, Bance M. Hearing preservation in vestibular schwannoma management. *Am J Otolaryngol*. 2015;36:526-34.
16. Limb CJ, Long DM, Niparko JK. Acoustic neuromas after failed radiation therapy: challenges of surgical salvage. *Laryngoscope*. 2005;115:93-8.
17. Koos WT, Day JD, Matula C, Levy DI. Neurotopographic considerations in the microsurgical treatment of small acoustic neurinomas. *J Neurosurg*. 1998;88:506-12.
18. Clark JG. Uses and abuses of hearing loss classification. *ASHA*. 1981;23:493-500.
19. Charabi S, Thomsen J, Mantoni M, Charabi B, Jorgensen B, Borgesen SE, et al. Acoustic neuroma (vestibular schwannoma): growth and surgical and nonsurgical consequences of the wait-and-see policy. *Otolaryngol Head Neck Surg*. 1995;113:5-14.
20. Hoa M, Drazin D, Hanna G, Schwartz MS, Lekovic GP. The approach to the patient with incidentally diagnosed vestibular schwannoma. *Neurosurg Focus*. 2012;33:1-10.
21. Rosenberg SI, Silverstein H, Flanzer JM, Willcox TO, Silverstein J. A comparison of growth rates of acoustic neuromas: nonsurgical patients vs. subtotal resection. *Otolaryngol Head Neck Surg*. 1993;109:482-7.
22. Stangerup SE, Caye-Thomasen P, Tos M, Thomsen J. The natural history of vestibular schwannoma. *Otol Neurotol*. 2006;27:547-52.
23. Roehm PC, Gantz BJ. Management of acoustic neuromas in patients 65 years or older. *Otol Neurotol*. 2007;28:708-14.
24. Oghalai JS, Buxbaum JL, Pitts LH, Jackler RK. The effect of age on acoustic neuroma surgery outcomes. *Otol Neurotol*. 2003;24:473-7.
25. Smouha EE, Yoo M, Mohr K, Davis RP. Conservative management of acoustic neuroma: a meta-analysis and proposed treatment algorithm. *Laryngoscope*. 2005;115:450-4.
26. Myrseth E, Pedersen PH, Moller P, Lund-Johansen M. Treatment of vestibular schwannomas. Why, when and how? *Acta Neurochir (Wien)*. 2007;149:647-60.
27. Chopra R, Kondziolka D, Niranjan A, Lunsford LD, Flickinger JC. Long-term follow-up of acoustic schwannoma radiosurgery with marginal tumor doses of 12 to 13 Gy. *Int J Radiat Oncol Biol Phys*. 2007;68:845-51.
28. Yamakami I, Uchino Y, Kobayashi E, Yamaura A. Conservative management, gamma-knife radiosurgery, and microsurgery for acoustic neurinomas: a systematic review of outcome and risk of three therapeutic options. *Neurol Res*. 2003;25:682-90.
29. Karpinos M, Teh BS, Zeck O, Carpenter LS, Phan C, Mai WY, et al. Treatment of acoustic neuroma: stereotactic radiosurgery vs. microsurgery. *Int J Radiat Oncol Biol Phys*. 2002;54:1410-21.
30. Kaylie DM, Horgan MJ, Delashaw JB, McMenomey SO. A meta-analysis comparing outcomes of microsurgery and gamma knife radiosurgery. *Laryngoscope*. 2000;110:1850-6.
31. Miller RC, Foote RL, Coffey RJ, Sargent DJ, Gorman DA, Schomberg PJ, et al. Decrease in cranial nerve complications after radiosurgery for acoustic neuromas: a prospective study of dose and volume. *Int J Radiat Oncol Biol Phys*. 1999;43:305-11.