

Ossicular Chain Lesions in Tympanic Perforations and Chronic Otitis Media without Cholesteatoma

*Original*

Ossicular Chain Lesions in Tympanic Perforations and Chronic Otitis Media without Cholesteatoma / Albera, R.; Dagna, F.; Filippini, C.; Albera, A.; Canale, A.. - In: THE JOURNAL OF INTERNATIONAL ADVANCED OTOTOLOGY. - ISSN 1308-7649. - 11:2(2015), pp. 143-146. [10.5152/iao.2015.858]

*Availability:*

This version is available at: 11583/2858974 since: 2020-12-24T14:53:37Z

*Publisher:*

AVES

*Published*

DOI:10.5152/iao.2015.858

*Terms of use:*

This article is made available under terms and conditions as specified in the corresponding bibliographic description in the repository

*Publisher copyright*

(Article begins on next page)



Original Article

# Ossicular Chain Lesions in Tympanic Perforations and Chronic Otitis Media without Cholesteatoma

Roberto Albera, Federico Dagna, Claudia Filippini, Andrea Albera, Andrea Canale

Department of Ear Nose Throat, University of Torino, Torino, Italy

**OBJECTIVE:** The first aim was to determine the prevalence, kind, and functional effects on hearing of ossicular chain suffering (OCS) in chronic otitis without cholesteatoma (NCOM) and tympanic perforations (TP). The second aim was to correlate the findings with clinical parameters and hearing level.

**MATERIALS and METHODS:** The study group comprised 250 consecutive patients affected by NCOM and who were subjected to tympanoplasty and never operated on before. Each patient underwent preoperative pure tone audiometry. Ossicles were evaluated during surgery. The incidence of OCS in NCOM was reported in 15–62% of the patients.

**RESULTS:** Ossicular chain suffering was found in 26 out of the 250 patients included in the overall sample (10%). It was found in 7% of the patients affected by TP without otorrhea and in 19% of the patients affected by chronic ear discharge with drum perforation. OCS was found most frequently in posterior eardrum perforations and in patients with bilateral disease. The incus was the ossicle most frequently interested by resorption (92% of the patients). The air conduction threshold and air bone gap were more impaired in NCOM than in TP.

**CONCLUSION:** Ossicular chain damages in patients with non-cholesteatomatous middle ear pathologies are not frequent and are present in no more than 10% of the patients, but lesions found were similar to those reported in patients with cholesteatoma. Otorrhea, posterior perforation, and bilateral disease can be considered as good predictors of OCS.

**KEYWORDS:** Chronic otitis, tympanic perforation, ossicular chain, hearing loss

## INTRODUCTION

Pathological conditions affecting the tympanic membrane and middle ear cleft may cause ossicular chain suffering (OCS) with or without interruption of its anatomical continuity. OCS affects up to 82% of patients with chronic otitis with cholesteatoma (COM); the incus is the ossicle more frequently involved (approximately 78% of patients), and in 45% of patients, lesions can be found in more than one ossicle<sup>[1-3]</sup>. The extension of COM in middle ear cavities directly relates to the rate of OCS, which causes conductive hearing loss that is greater than in patients with an intact ossicular chain, whose magnitude is not related to the severity of OCS<sup>[1]</sup>.

Chronic otitis media without cholesteatoma (NCOM) is a pathological condition characterized by an irreversible tympanic perforation (TP) associated with chronic inflammation of the middle ear and mastoid mucosa causing otorrhea lasting for at least 2–6 weeks<sup>[4]</sup>. Non-cholesteatomatous otitis media must be differentiated by an irreversible TP without otorrhea, in which the mucosa of the middle ear is normal, and the episodes of otorrhea are absent or rare. TP is the most frequent pathology of the drum<sup>[5]</sup>. Tos classified these conditions in a constantly discharging ear, an intermittently secreting ear, and a constantly dry ear with perforation<sup>[5]</sup>. In this paper, we will address the first two conditions as NCOM and the last as TP.

An analysis of OCS in chronic otitis without cholesteatoma is less frequently reported, and the rate of incidence of ossicular suffering is estimated in approximately 15–62% of patients; OCS is more frequently found in granulating otitis media<sup>[5,6]</sup>.

The aim of this retrospective study, which was based on a series of patients subjected to tympanoplasty, was to determine the prevalence and kind of ossicular defects in TP and NCOM; the second aim of the study was to correlate the modifications of the ossicular chain with clinical parameters and hearing function.

## MATERIALS and METHODS

The cohort of study comprised 250 consecutive patients affected by TP or NCOM who underwent tympanoplasty. Patients previously subjected to surgery for the same ear were excluded from the study group. All the patients signed an informed consent prior to their inclusion in the study. The local ethics committee approved the study protocol.

### Corresponding Address:

Federico Dagna, E-mail: federico.dagna@gmail.com

Submitted: 12.01.2015

Revision received: 02.05.2015

Accepted: 04.05.2015

Copyright 2015 © The Mediterranean Society of Otolaryngology and Audiology

In the sample, 111 patients (44%) were males and 139 (56%) females. In 118 patients (47%), the right side was affected, and in 132 (53%), the left side was; in 79 patients (32%), the disease affected both ears. The mean age was 40 years (min 4, max 83, and standard deviation 19).

TP affected no more than two quadrants of the eardrum in 170 patients (68% of the patients), while in 80 patients (32%), it extended to three or four quadrants (subtotal perforation). The site of the two-quadrant perforations was anterior in 23 patients (14%), inferior in 69 (40%), and posterior in 78 (46%).

According to Roland [4], non-cholesteatomatous otitis media was defined as the presence of otorrhea lasting for at least 2 weeks at the time of surgery or by a history of recurrent long-lasting episodes of otorrhea during the previous 2 years. A constantly dry ear with perforation was classified as TP. On this basis, we divided the sample into two: 186 patients (74%) affected by TP and 64 (26%) patients affected by NCOM. Table 1 shows the distribution of perforation sites in the two groups. Differences are not significant.

Each patient underwent pure tone audiometry with the descending technique in a sound-proof booth the day before surgery. The pure tone average (PTA) threshold was determined as the mean value at 0.5-1-2-4 kHz; in the overall sample, the mean air conduction (AC) threshold was 41 dB (SD=19), mean bone conduction (BC) threshold 20 dB (SD=12), and mean air-bone gap (ABG) was 21 dB (SD=11).

For continuous and categorical variables, data were represented as mean (standard deviation) and frequency (percentage), respectively. Data were normally distributed in each patient, and we used Student's t-test to compare continuous variables.

A one-way ANOVA was used to test the differences of means in more than two groups. A post-hoc analysis was performed using the Bonferroni correction. We used the Chi-square or Fisher's exact test when appropriate to compare the groups for categorical variables. All statistical tests were two-sided, and P-values of 0.05 or less were considered statistically significant. Statistical analyses were conducted using the SAS software package (SAS Institute; Cary, NC, USA).

**RESULTS**

Among the overall sample, 26 out of the 250 patients showed OCS (10%). We found OCS in 14 (7%) of the 186 patients with TP and in 12 (19%) of the 64 patients affected by NCOM. The difference was significant (p=0.0112). In 3 patients for each group (6 out of 26, 23%), OCS did not alter the continuity among ossicles.

Among the 26 patients affected by OCS, perforation size was subtotal or anterior in 1 patient each (4%), inferior in 8 patients (30%), and posterior in 16 (62%). The highest rate of OCS was therefore observed in inferior and most frequently, in posterior eardrum perforations (p<0.001).

The malleus presented signs of resorption in 4 patients (15%), whereas the incus presented similar signs in 24 patients (92%) and the stapes in 7 (27%). In 5 patients (19%), the lesion involved both the incus and stapes, and in 4 patients (15%), it affected all three ossicles.

**Table 1.** Site of tympanic perforation in TP and NCOM

	Subtotal	Anterior	Inferior	Posterior
TP (186 patients)	57 (31%)	19 (10%)	54 (29%)	56 (30%)
NCOM (64 patients)	23 (36%)	7 (11%)	14 (22%)	20 (31%)

TP: tympanic perforation; NCOM: non-cholesteatomatous chronic otitis. Differences are not significant (p=0.8719)

**Table 2.** Ossicular lesions found in TP and in NCOM

	Kind of lesion	TP	NCOM	p
Malleus (4 patients)	Absent	0	1 (33%)	>0.999
	Head	1 (100%)	1 (33%)	
	Handle	0	1 (33%)	
Incus (24 patients)	Absent	1 (8%)	4 (33%)	0.3217
	Long process	11 (92%)	8 (67%)	
Stapes (8 patients)	Absent	3 (100%)	4 (80%)	>0.999
		0	1 (20%)	

TP: tympanic perforation; NCOM: non-cholesteatomatous chronic otitis

**Table 3.** Relationship between the condition of the other ear and that of the ossicular chain

	Normal contralateral ear	Pathological contralateral ear
Normal ossicular chain	158 (71%)*	66 (29%)*
Pathological ossicular chain	13 (50%)	13 (50%)

\*p=0.0098 at chi-square test

Table 2 shows the type of ossicular lesions in TP and NCOM. The most frequent lesion found in both groups was the incus long process resorption (92% and 67% respectively, p>0.05).

Half of the patients with OCS had bilateral disease (either TP or NCOM). In these patients, the rate of OCS was significantly higher (p=0.033) than in those affected by unilateral disease (13/66, 16% versus 13/158, 7.6%; Table 3). The rates did not change between the patients with TP and those with NCOM.

Regarding age, patients with TP were significantly younger than those with NCOM (mean age 38 versus 45 years, SD 19 versus 18, p=0.05 at the Student's t test). In the TP group, the patients with and without OCS were aged 38 (SD 18) and 39 (SD 19) years, respectively; in the NCOM group, the patients were aged 49 (SD 21) and 45 years (SD 19), respectively. In both groups, the differences were not significant (p>0.05).

Table 4 and Figure 1 show the hearing threshold in normal ossicular chain and OCS in both the TP and NCOM groups. The bone conduction threshold did not differ significantly at the ANOVA analysis among the 4 conditions (p>0.05). Air conduction and ABG were consistently higher in patients with OCS in both the TP (mean difference for AC was 9 dB, for ABG 6 dB) and NCOM (mean difference for AC was 6 dB, for ABG 9 dB) groups; however these differences did not reach statistical significance. In the TP group, ABG was significantly lesser than that in the NCOM group (p<0.05 at the Student's t test).

**Table 4.** PTA values in TP and NCOM in relation to the presence or absence of OCS

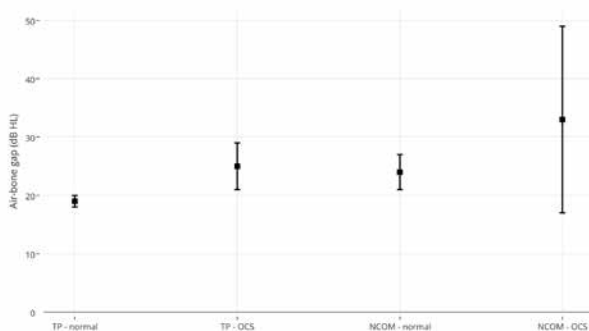
	TP		NCOM	
	Normal ossicular chain 172 patients	Atrophy of the ossicular chain 14 patients	Normal ossicular chain 52 patients	Atrophy of the ossicular chain 12 patients
AC	38 (17) *	47 (17)	47 (20) *	53 (25)
BC	19 (12)	21 (15)	23 (13)	20 (12)
ABG	19 (9) **	25 (8)	24 (12)*	33 (26)**

AC: air conduction; BC: bone conduction; ABG: air–bone gap; TP: tympanic perforation; NCOM: non-cholesteatomatous chronic otitis. Values are expressed in dB HL. Standard deviation in brackets. \* $p < 0.01$ ; \*\* $p < 0.001$

**Table 5.** Air–bone gap in the 20 patients who presented OCS with discontinuity of the ossicular chain

	1 ossicle involved (14 patients)	2 ossicles involved (3 patients)	3 ossicles involved (3 patients)
Air–bone gap	19 (19)	25 (9)	25 (12)

Values are expressed in dB HL. Standard deviation in brackets. Differences are not significant at ANOVA ( $p > 0.05$ )

**Figure 1.** Mean air–bone gap values in the absence and presence of ossicular chain lesions in relation to the pathology (TP and NCOM). Statistical significance was  $p < 0.01$  and  $p < 0.0001$ , respectively

The air–bone gap was not significantly related to the number of ossicles involved in OCS (Table 5).

## DISCUSSION

The aim of this study was to first describe ossicular chain defects in non-cholesteatomatous otitis media and then to correlate them with clinical parameters.

The non-cholesteatomatous pathology of the middle ear is currently classified in TP and NCOM [4]; the only difference between these two conditions is the presence or absence of inflammatory reaction of the middle ear mucosa. In our sample, majority of the patients was affected by TP (74%). In such patients, the surgical indication aimed to restore tympanic integrity to prevent recurrent otitis, allowing normal water contact and improving hearing function, while in those affected by NCOM, surgery aimed at curing the chronic discharge. According to our data and because some patients affected by TP were not operated on due to comorbidities or their own will, we can conclude that TP is far more frequent than NCOM.

Data about OCS in non-cholesteatomatous chronic otitis are scarce in literature, and few papers systematically present and discuss the modifications found. In 1979, Tos [3] compared OCS in cholesteatomatous and non-cholesteatomatous otitis media and found ossicular lesions in 62% of patients with granulating otitis media, 43% of those with sequelae of the otitis, and in 77% of those with adhesive otitis media. More recently, Zanhert [6] reported OCS in 15% of non-cholesteatomatous middle ear pathologies. In our sample, we found OCS in 10% of the patients. This rate is lower than data reported in previous papers, but we had a larger number of minor middle ear lesions (for example, Tos reported many patients with adhesive otitis; this disease was excluded from this study).

OCS was more frequently found in posterior TP (62%,  $p < 0.001$ ). This correlation can be explained by the anatomical contiguity between the ossicular chain and the site of TP. This conclusion is consistent with that of Tos [3–5], who reported a lesser degree of correlation in the presence of middle ear inflammation.

OCS was significantly more frequent in patients with NCOM; therefore, the presence of mucosal chronic inflammation increases the risk of ossicular resorption. The incus was the ossicle more frequently affected (92%), and in particular, its long process. The malleus and stapes involvement ranged from 7% to 33%; this is consistent with previous data reported in both COM and NCOM [1, 3, 6]. In general, the distribution of the malleus, incus, and stapes suffering in NCOM is similar to that found in COM [1], while in TP, there is a higher prevalence of incus suffering, which is found in approximately 80% of the overall patients with OCS.

The rate of OCS was higher in patients with bilateral middle ear pathologies (16% versus 7.6%,  $p = 0.03$ , Table 3). Patients with bilateral disease, which is perhaps an expression of a longer or more severe disease correlated to local or biological factors, have two times the risk of OCS, and this preoperative condition can act as a valuable predictor. On the contrary, age was not related to the presence of OCS in either the TP or NCOM groups ( $p > 0.05$ ).

Regarding hearing function, ABG in patients affected by chronic otitis media is usually related to the ossicular chain condition; in particular, a narrow ABG would suggest ossicle integrity, whereas a wide ABG would predict ossicular resorption [7]. This was not fully confirmed by our study. Although ABG tended to be greater in patients with OCS both in the TP and NCOM groups, differences were not significant. Based on the differences between hearing levels in those with and without OCS (Table 4), we hypothesize that two-thirds of ABG is re-

lated to TP and that one-thirds is related to OCS. Moreover, ABG was larger in NCOM than in TP regardless of the association with OCS as a consequence of the impairment of sound transmission determined by middle ear inflammatory tissue.

Finally, ABG was not related to the extension of ossicular chain damage (Table 5) because from a functional point of view, chain discontinuity leads to hearing impairment regardless of the type or number of involved ossicles<sup>[1]</sup>.

The mean BC threshold did not differ in relation to the pathology (TP or NCOM) and to the presence/absence of OCS; therefore the non-cholesteatomatous chronic middle ear pathologies do not alter the cochlear function. This is a remarkable difference with COM, in which we observed BC impairment in presence of OCS<sup>[1]</sup>. Our hypothesis, supported by histopathological and biological evidence<sup>[8,9]</sup>, is that differences exist in middle/inner ear interaction between COM and NCOM/TP.

In conclusion, ossicular chain damages in patients with non-cholesteatomatous middle ear pathology are not frequent and are in no more than 10% of patients. Ossicle resorption is almost 3 times more frequent in NCOM and follows a distribution similar to that of COM. In TP, ossicle resorption is almost limited to the incus. Considering TP, the presence of recurrent otorrhea, posterior perforation, and bilateral disease can all be considered as good predictors of OCS and should be considered together with imaging findings (i.e., submillimeter multislice CT scan) to plan surgery.

**Ethics Committee Approval:** Ethics committee approval was received for this study from the Local Ethics Committee.

**Informed Consent:** Written informed consent has been obtained from all participants.

**Peer-review:** Externally peer-reviewed.

**Author Contributions:** Concept - A.R., C.A.; Design - A.R., C.A.; Supervision - A.R.; Data Collection and/or Processing - A.A., F.C.; Analysis and/or Interpretation - A.R., C.A., D.F.; Literature Review - D.F., A.A.; Writing - A.R., D.F., F.C.

**Conflict of Interest:** No conflict of interest was declared by the authors.

**Financial Disclosure:** The authors declared that this study has received no financial support.

## REFERENCES

1. Albera R, Canale A, Piumetto E, Lacilla M, Dagna F. Ossicular chain lesions in cholesteatoma. *Acta Otorhinolaryngol Ital* 2012; 32: 309-13.
2. Jeng FC, Tsai MH, Brown CJ. Relationship of preoperative findings and ossicular discontinuity in chronic otitis media. *Otol Neurotol* 2003; 24: 29-32. [\[CrossRef\]](#)
3. Tos M. Pathology of the ossicular chain in various chronic middle ear diseases. *J Laryngol* 1979; 93: 769-80. [\[CrossRef\]](#)
4. Roland PS. Chronic suppurative otitis media: a clinical overview. *Ear Nose Throat J* 2002; 81 (8 Suppl 1): 8-10.
5. Tos M. *Manual of middle ear surgery*. Thieme Ed Stuttgart 1993.
6. Zanhert T. Reconstruction of the middle ear with passive implants. *HNO* 2011; 59: 964-73.
7. Carrillo RJ, Yang NW, Abes GT. Probabilities of ossicular discontinuity in chronic suppurative otitis media using pure-tone audiometry. *Otol Neurotol* 2007; 28: 103-7. [\[CrossRef\]](#)
8. Cureoglu S, Schachern PA, Paparella MM, Lindgren BR. Cochlear changes in chronic otitis media. *Laryngoscope* 2004; 114: 622-6. [\[CrossRef\]](#)
9. Juhn SK, Jung MK, Hoffman MD, Drew BR, Preciado DA, Sausen NJ, et al. The role of inflammatory mediators in the pathogenesis of otitis media and sequelae. *Clin Exp Otorhinolaryngol* 2008; 1: 117-38. [\[CrossRef\]](#)