POLITECNICO DI TORINO
Repository ISTITUZIONALE

Standard vs mini-laparoscopic pyeloplasty: Perioperative outcomes and cosmetic results

Original
Standard vs mini-laparoscopic pyeloplasty: Perioperative outcomes and cosmetic results / Fiori, Cristian; Morra, Ivano; Bertolo, Riccardo; Mele, Fabrizio; Chiarissi, Marco Lucci; Porpiglia, Francesco. - In: BJU INTERNATIONAL. - ISSN 1464-4096. - 111:3 B(2012), pp. E121-E126. [10.1111/j.1464-410X.2012.11376.x]

Availability:
This version is available at: 11583/2811294 since: 2020-04-12T22:52:48Z

Publisher:
Blackwell Science Limited

Published
DOI:10.1111/j.1464-410X.2012.11376.x

Terms of use:

This article is made available under terms and conditions as specified in the corresponding bibliographic description in the repository

Publisher copyright

(Article begins on next page)

12 October 2024

BJUI BJU INTERNATIONAL

Standard vs mini-laparoscopic pyeloplasty: perioperative outcomes and cosmetic results

Cristian Fiori, Ivano Morra, Riccardo Bertolo, Fabrizio Mele, Marco Lucci Chiarissi and Francesco Porpiglia

Division of Urology, University of Turin, 'San Luigi Gonzaga' Hospital, Orbassano, Turin, Italy

Accepted for publication 10 May 2012

Study Type – Therapy (case series)
Level of Evidence 4

OBJECTIVE

- To evaluate perioperative and cosmetic results after pure mini-laparoscopic pyeloplasty (mLP) compared with standard LP (sLP) in an adult population.

PATIENTS AND METHODS

- From April 2009 to June 2010, 12 patients underwent mLP for pelvi-ureteric junction (PUJ) obstruction (PUJO). For comparison, 24 patients that had previously undergone sLP were pooled from our institutional database.
- All patients were assessed preoperatively with physical examination, abdominal ultrasonography, intravenous urography or computed tomography and renal scintigraphy (RS). In all cases, an Anderson-Hynes transperitoneal approach was used.
- After surgery, cosmetic results were assessed using a Patient Scar Assessment Questionnaire (PSAQ), and RS measured reconstructive success at 1-year after LP.
- Demographic and perioperative variables were recorded. Groups were compared using chi-squared and Wilcoxon-Mann-Whitney tests ($P < 0.05$ was considered significant).

RESULTS

- Baseline characteristics were similar between the groups. There were no differences in operative duration or blood loss. One mLP required conversion to sLP due to minor bleeding.
- Analgesic consumption and the pain visual analogue scale scores were not significantly different between the sLP and mLP cohorts.
- The average postoperative hospital stay for the mLP group was significantly shorter than that for the sLP group ($P = 0.024$).
- Complication and success rates between the groups were not significantly different.
- PSAQ scores showed that mLP patients were significantly more satisfied with their cosmetic result.

CONCLUSIONS

- mLP appears to be safe, feasible and effective in the treatment of PUJOs.
- Cosmetically, mLP is better than sLP.

KEYWORDS

mini-laparoscopy, laparoscopy, pyeloplasty, pelvi-ureteric junction obstruction, LESS

What's known on the subject? and What does the study add?

New techniques and instrumentation in laparoscopy including the use of 'single-port' devices and natural orifice transluminal endoscopic surgery have been proposed to reduce the invasiveness of these procedures. The introduction of small laparoscopic instruments (<3 mm) continues to further the field. To date, mini-laparoscopic instruments have been used in many urological procedures, e.g. pyeloplasty in the paediatric population. However, data of pure mini-laparoscopic pyeloplasty (mLP) for the treatment of pelvi-ureteric junction obstruction in the adult population are lacking.

In a selected adult population mLP is feasible and safe. Perioperative and 1-year functional results are comparable with those of standard LP, while cosmetic results of mLP are more appreciated by the patients.

INTRODUCTION

Due to reduced morbidity and shorter hospital stays, laparoscopy has largely replaced open surgery for the treatment of many urological diseases [1,2]. Refinement of technique and instrumentation has continually reduced the invasiveness of laparoscopic surgery since its inception. With this aim, new techniques in laparoscopy including the use of 'single-port' devices and natural orifice transluminal endoscopic surgery have been studied [3–6]. The introduction of smaller laparoscopic instruments (≤3 mm) continues to further the field. The 2- and 3-mm ports are virtually incision less and do not require suturing upon closure. The end result for the patient is essentially a 'scarless' incision. Moreover, many consider that 2- or 3-mm incisions rather than 5- or 10-mm incisions reduce pain and translate to shorter hospital stays, faster recovery, and diminished wound morbidity. To date, mini-laparoscopic instruments have been used in many urological procedures, including renal cyst decortication, orchidopexy, lymphocele marsupialisation, pelvic lymph node dissection and adrenalectomy [3,7,8].

© 2012 THE AUTHORS

Since it was first described, the laparoscopic pyeloplasty (LP) has gained popularity for the treatment of PUJ obstruction (PUJO). In fact, several studies have reported equivalent success using laparoscopic vs open techniques [9–11]. However, due to the well-established advantages of minimal invasive surgery, LP has become the first choice for the treatment of PUJO at many advanced laparoscopic centres. Efforts to further reduce invasiveness have resulted in laparoendoscopic single-site (LESS) surgery [12–14]. However, the role of pure mini-LP (mLP; 3-mm instruments) in this setting is relatively unexplored in adult population [14,15].

The aim of the present study was to analyse the perioperative outcomes and cosmetic results of pure mLP in an adult population compared with standard LP (sLP).

PATIENTS AND METHODS

From April 2009 to June 2010, 12 patients underwent mLP for PUJO. Inclusion criteria were as follows: age > 18 years, body mass index (BMI) < 25 kg/m^2, no history of major abdominal surgery, a primary PUJO, and no previous surgery on the affected kidney. This series of patients represents our first experience with this technique.

Patients undergoing mLP were compared with 24 (2:1) matched patients undergoing sLP. Comparison patients were taken from our prospectively maintained, Institutional Review Board-approved database of LP procedures performed before October 2005. Matching criteria included gender, age, BMI, and clinical history (primary PUJO, no previous major abdominal or ipsilateral renal surgery).

All patients in both groups were preoperatively assessed with physical examination, abdominal ultrasonography, IVU or CT and renal scintigraphy (RS).

SURGICAL TECHNIQUES

In all cases, an Anderson-Hynes LP using a transperitoneal approach was performed by the same surgeon (F.P.). Under general anaesthesia, the patient was placed in a 45 ° lateral decubitus position, and a pneumoperitoneum was achieved using a Veress needle at the level of the umbilicus. An intra-abdominal pressure of 12–14 mmHg was maintained.

MLP

Depending on the patient's body habitus, the initial port (3.9 mm) was placed at or 2 cm lateral to the umbilicus. A 3-mm 30 ° miniature scope was then inserted through the initial port. For procedures on the left renal pelvis, two mini ports were placed under direct vision along the left midclavicular line. When possible in the case of a left PUJO, a transmesocolic approach was used as previously described [16]. In other cases, a standard colon retracting approach was used. For right-sided PUJOs, two mini ports were placed along the right midclavicular line and a fourth port was placed below the xiphoid for the purpose of liver retraction (Fig. 1). The PUJ was reached via an incision in the posterior peritoneum and, if necessary, via a colonic hepatic flexure-reflecting approach.

After resection of the PUJ, suspension of the renal pelvis from the abdominal wall using a straight needle facilitated pelvi-ureteric anastomosis. The posterior portion of the anastomosis was made using a running 5-0 monofilament suture with a 4/8 round needle that was inserted through the mini port. Then, a 6 F JJ ureteric stent was placed over a guidewire and inserted in a retrograde fashion using flexible pneumocystoscopy, as previously described [17]. The anterior portion of the anastomosis was made with a separate running suture. Upon completion of the procedure a 12 F intraperitoneal drain was placed through the umbilical port. All 3.9-mm ports and 3-mm instruments were manufactured by Karl Storz® (Tuttlingen, Germany).

SLP

A 12-mm port was placed at or 2 cm lateral to the umbilicus. A 10-mm 30 ° scope was then used to visualize subsequent port placements. In cases of left PUJOs, a 12-mm port (for 5–10 mm instruments) and a 7-mm port (for 5 mm instruments) were placed along the left midclavicular line. When possible, a transmesocolic approach was used. In cases of right PUJOs, two ports (7 and 12 mm) were placed along the right midclavicular line, and a fourth port (5 mm) was placed below the xiphoid for liver retraction. All other steps were performed as described above. Hem-o-Lok® clips were used to ensure haemostasis when necessary.

FIG. 1. Cosmetic results after mLP. Note that scars from the operative ports are small and that the umbilical scar is unidentifiable.

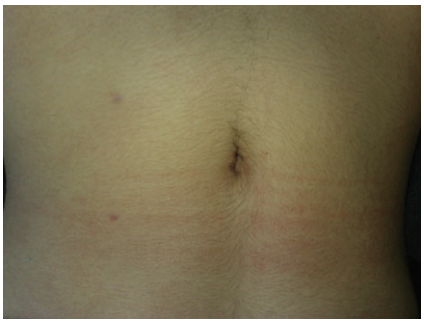

PERIOPERATIVE OUTCOMES

Apart from the demographic variables we recorded operative duration, blood loss, perioperative complications according to the Clavien-Dindo system [18], day of catheter removal, pain visual analogue scale (VAS) score and use of analgesics (1 g i.v. paracetamol in vials) for all patients. We recorded only those pain medications required ≥24 h after the procedure. Early postoperative analgesic therapy (<24 h after surgery) that was prescribed by the anaesthesiologist was not considered. Patients were then followed, and length of postoperative hospital stay was recorded.

COSMETIC RESULTS

To evaluate cosmetic results, the Patient Scar Assessment Questionnaire (PSAQ) [19], a standard scoring system developed for plastic and reconstructive surgery, was administered to all mLP patients 3 months after mLP. Because the scoring system was not readily available at the time of surgery for the sLP group, the PSAQ was administered during control visits at time points >3 months after surgery.

FUNCTIONAL RESULTS

RS was performed 12 months after surgery. The parameters used to determine reconstructive success were clinical

© 2012 THE AUTHORS
BJU INTERNATIONAL © 2012 BJU INTERNATIONAL

TABLE 1 (a) Baseline characteristics of patients and (b) Perioperative and functional results

	mLP	sLP	P
(a) Demographic data			
Total number of patents	12	24	
Female, n/N or n (%)	11/12	20 (83.3)	0.502
Male, n/N or n (%)	1/12	4 (16.7)	0.502
Mean (SD) age, years	41.1 (11.6)	40.6 (9.2)	0.889
Mean (SD) BMI, kg/m^2	22.4 (2.3)	23.2 (2.8)	0.399
Median (range) ASA score	2 (1–3)	2 (1–4)	–
Left sided, n/N or n (%)	8/12	15 (62.5)	0.811
Right sided, n/N or n (%)	4/12	9 (37.5)	0.811
Crossing vessels, n (%)	4/12	9 (37.5)	0.811
Significant hydronephrosis (>grade II) at preoperative CT or IVU, n/N or n (%)	12/12	23 (95.8)	0.476
Flank pain or renal colic, n/N or n (%)	8/12	18 (75.0)	0.599
Recurrent UTI, no. (%)	3/12	4 (16.6)	0.552
Patients with significant comorbidities, n/N or n (%)	6/12	15 (62.5)	0.478
Hypertension, n	4	8	
Diabetes, n	3	4	
Hypercholesterolaemia, n	2	6	
(b) Perioperative and functional results			
Mean (SD):			
Operative duration, min	128 (30)	135 (38)	0.582
Time to complete PU suture, min	23 (5)	22 (4)	0.520
Blood loss, mL			
n/N or n (%):			
Transmesocolic approach on the left side	4/8	9/15	0.650
Conversion to hybrid procedure	1/12	–	–
Conversion to open procedure	0	0	–
Intraoperative complications	0	0	–
Mean (SD):			
VAS score POD 1 to the discharge	1.3 (0.7)	1.7 (0.8)	0.151
Paracetamol, vials per patient	0.25 (0.45)	0.40 (0.58)	0.435
Catheter removal, days	2.5 (0.7)	2.8 (0.9)	0.320
Postoperative hospital stay, days	3.0 (0.7)	3.7 (0.9)	0.024
JJ-stent removal, days	28 (2.1)	28.1 (2.3)	0.900
n/N or n (%):			
Significant hydronephrosis (> grade II) at 6-month CT (or IVU)	0	0	–
$T_{1/2}$ < 20′ at renal scintigraphy	11/12	23 (95.8)	0.609
Pain relief after intervention in symptomatic patients (%)	7/8	18/18 (100)	0.132
Recurrent UTI after surgery	0	0	–

ASA, American Society of Anesthesiologists; PU, pelvi-ureteric; POD, postoperative day.

resolution of symptoms and radiographic evidence of $T_{1/2}$ < 20 min on RS [13].

STATISTICAL ANALYSIS

Groups were compared using chi-squared and Wilcoxon-Mann-Whitney tests for categorical and continuous variables, respectively. Statistical significance was set at $P < 0.05$. All reported P-values were two-sided.

RESULTS

Baseline characteristics between the two groups, including age, gender, American Society of Anesthesiologists score, side of procedure and BMI, were similar (Table 1).

PERIOPERATIVE OUTCOMES

Perioperative outcomes are summarised in Table 2. There were no differences in operative duration or blood loss. There was one mLP case (one of 12) that required conversion to sLP due to minor bleeding that could not be controlled with bipolar forceps. In this case, a 3.9-mm port was exchanged with a 12-mm port such that a suction device and Hem-o-Lok applier could be used. There were no major intraoperative complications and no conversions to open procedures were required in the two groups. Analgesic consumption and the pain VAS

© 2012 THE AUTHORS

TABLE 2 Cosmetic results

Cosmetic results, mean (SD)	mLP	sLP	*P*
Total PSAQ	29.8 (1.8)	51.7 (1.4)	<0.001
Appearance	10.2 (0.8)	17.2 (0.7)	<0.001
Consciousness	6.3 (0.7)	11.3 (0.8)	<0.001
Satisfaction with appearance	8.1 (0.3)	17.8 (1.0)	<0.001
Satisfaction with symptoms	5.1 (0.3)	5.3 (0.5)	0.326

FIG. 2. Cosmetics results after sLP. The scar of the operative ports and umbilical port are evident.

score were not significantly different between the sLP and mLP cohorts. The average postoperative hospital stay was significantly shorter for the mLP group compared with the sLP group ($P = 0.024$, Table 2).

In the mLP group, two of 12 patients had postoperative complications. One individual had a grade I complication according to the Clavien system [18], a fever treated by antibiotic therapy. The other patient had a grade III complication, a urine leak with collection in the surgical drain and a percutaneous nephrostomy tube was placed. In the sLP group, five of 24 patients (20.8%) had postoperative complications. There were three cases (12.5%) of grade I/II complications (two fevers treated by antibiotic therapy and one serum haemoglobin drop treated by blood transfusion) and two (8.3%) cases of grade III complications: urine leak requiring percutaneous nephrostomy tube placement and gross haematuria requiring percutaneous clot irrigation of the renal pelvis.

No grade > IIIa complications were recorded, and no differences were recorded for overall ($P = 0.766$) or severe (>grade II, $P = 1.000$) complications between the two groups.

COSMETIC RESULTS

The PSAQ scores showed that patients who received mLPs were significantly more satisfied with their cosmetic result than those who had sLPs. This was true both for overall and subscale scores (Table 2, Figs 1 and 2).

FUNCTIONAL RESULTS

All patients but one in the mLP group (11/12) had a $T_{1/2} < 20$ min on RS performed 1 year after surgery [13]. In addition, all symptomatic patients had clinical resolution of symptoms with a success rate at 1 year postoperatively of 11/12 mLP patients. In the sLP group, all patients but one (23/24; 95.8%) had a $T_{1/2} < 20$ min on RS and clinical resolution of symptoms. No significant differences were recorded between the groups in terms of success rates ($P = 0.609$).

DISCUSSION

LP was first proposed by Schuessler *et al.* [20] in 1993. Due to its favourable result profile and the well-known advantages of minimally invasive surgery, it has become the first choice for the treatment of PUJOs at many centres. To further reduce the invasiveness of such procedures, some authors have proposed the LESS pyeloplasty. To date, most authors have concluded that LESS pyeloplasty is feasible, safe and perioperative outcomes are similar to those of conventional LPs [11–13]. However, cosmetic results of mini-laparoscopic procedures were often not considered or were investigated in a non-standardised way [21–24]. The main drawback of the LESS procedure seems to be the loss of triangulation – the basic rule of laparoscopy. The clashing of instruments, use of additional ports (one or more), and use of articulating instruments make this procedure's learning curve steep.

Miniaturisation of laparoscopic instruments (≤3 mm) has not only reduced the invasiveness of procedures but has also given way to 'mini-laparoscopic' surgery. Although previously reserved for diagnostic purposes only, mini-laparoscopic techniques are increasingly used for therapeutic procedures in urology including adrenalectomies, nephrectomies, renal cyst marsupialisations and orchidopexies [3,7,8]. Because reconstructive procedures do not require extraction of a surgical specimen, an increasing number of these may be completed using mini-laparoscopy to reduce surgical scarring. mLP has been proposed in the paediatric population; however, data regarding mLP in the adult population are lacking to date [24].

Based on the these considerations coupled with our previous LP experience and encouraging experience with mini-laparoscopy [24], we chose to conduct the current case-control study comparing mLP and sLP performed by one surgeon at a single institution. To ensure patient safely while developing this novel approach, we instituted several inclusion criteria. These included patients that were not obese without previous significant abdominal or renal surgery. The matched-paired analysis allowed us to compare two homogeneous groups. In fact, there were no differences in demographic variables (Table 1).

A transperitoneal approach was used for both the mLPs and sLPs included in the present study. Compared with a retroperitoneoscopic approach, this approach allowed us to increase our operative field and better manage renal abnormalities (e.g. malrotation and crossing vessels) [16]. mLP allows for all traditional steps of a pyeloplasty without losing triangulation and without the use of flexible instruments or special tools.

PERIOPERATIVE OUTCOMES

The results of the present study confirm that mLP is safe in a select adult population. In the present study, mLP operative durations were similar to those of sLPs. Interestingly, this finding is in contrast to

© 2012 THE AUTHORS
BJU INTERNATIONAL © 2012 BJU INTERNATIONAL

previous reports in which the mean operative duration for mini-laparoscopy was ≈20% longer than the standard laparoscopic procedure [3]. Postoperative outcomes including analgesic consumption and pain VAS score were not significantly different between the sLP and mLP cohorts. The average postoperative hospital stay for the mLP group was significantly less than that of the sLP group ($P = 0.024$), suggesting that mini-laparoscopy could improve postoperative outcomes. In one case, the mLP was converted to a hybrid procedure, which included all 3.9-mm ports except for one, due to minor bleeding that could not be controlled with bipolar forceps. In this case, a 12-mm port was used at the level of umbilicus, and the 3-mm scope was switched to the lateral 3.9-mm port such that it was in the surgeon's right hand. This allowed for the use of standard bipolar forceps, a suction device and the introduction of a 10-mm Hem-o-Lok applier through the 12-mm port. The procedure was completed without further problems. There was one major (>II according to the Clavien System) complication in the mLP group and two in the sLP group ($P = 1.000$). All applicable complications were managed with a percutaneous approach and did not require re-intervention. The complication rates of both groups in the present study were comparable to published rates for sLP and LESS pyeloplasty [10–16,20].

COSMETIC RESULTS

The PSAQ scores showed a statistically significant advantage for cosmetic results in the mLP group. The fact that the questionnaire was completed after >3 months after surgery by the sLP group (vs ≤3 months after surgery by the mLP group) is potentially a source of bias. However, to our knowledge, few reports have been published with standardised comparisons between mLPs and sLPs. In fact, most studies compare the broad categories of minimally invasive procedures (mini-laparoscopy, LESS) to standard laparoscopic procedures.

FUNCTIONAL RESULTS

Although functional success was not the primary endpoint of the present study, success rates at 1-year functional follow-up for our populations were 11/12 and 23/24 (95.8%) in the mLP and sLP groups, respectively ($P = 0.609$). These are comparable to published success rates for sLP and LESS [11–13]. Dismembered pyeloplasty success rates range from 90–95% [25–27].

The mini-laparoscopic approach undoubtedly has disadvantages. The image quality provided by the 3-mm scope is not ideal during active bleeding, even if minor, as it causes light absorption and decreases image quality. The suction cannula has poor flow and sometimes fails to maintain a clear surgical field. Furthermore, due to port size limitations, mini-laparoscopic clips and Hem-o-Lok applicators are unavailable. For these reasons, bleeding should be prevented during the preliminary phases of the intervention by exercising meticulous dissection technique around the PUJ. Even if the principles of laparoscopic surgery are respected, no special instruments are needed, and the learning curve for mLP is acceptable, we think that significant laparoscopic experience is required before attempting mLP.

The present study has the following limitations. First, retrospective case-control studies allow for the introduction of confounding variables, selection bias and information bias. Nevertheless, the reader should note that our retrospective data are based on a prospectively maintained database, which should reduce biases. Secondly, the present study is limited by a small sample size and selective enrolment, including certain favourable characteristics, e.g. primary PUJOs, normal BMIs and no previous major abdominal surgeries. Moreover, women mainly composed the population studied: this could have overemphasised the importance placed upon cosmesis. As a result, this report may not accurately represent the general public. Also, concerning the shorter postoperative hospital stays we observed in mLP cohort, the urological staff could have been pushing for quicker discharge for the patients who underwent mLP. Finally, even if satisfaction with cosmetic results was recorded in a standardised fashion, there could have been another bias as the patients who were undergoing mLP were told they were getting a 'special' mini-invasive approach with (potentially) excellent cosmesis.

Notwithstanding these limits, the present results show that mLP is safe and effective for the treatment of PUJOs. This approach has improved postoperative outcomes vs sLP such as significantly reduced postoperative hospital stays. Cosmetically, patients in the mLP were significantly more satisfied with their results. We think that this technique, among other minimally invasive options, can play an important roll toward 'scarless' surgery. Further studies with a larger sample size are required to confirm the present data. We hope that further studies can also determine the advantage, if any, of this procedure over standard laparoscopy or techniques such as LESS.

CONFLICT OF INTEREST

None declared.

REFERENCES

1 **Kaouk JH, Gill IS.** Laparoscopic reconstructive urology. *J Urol* 2003; **170**: 1070–8
2 **Calvert RC, Morsy MM, Zelhof B, Rhodes M, Burgess NA.** Comparison of laparoscopic and open pyeloplasty in 100 patients with pelvi-ureteric junction obstruction. *Surg Endosc* 2008; **22**: 411–4
3 **Soble JJ, Gill IS.** Needlescopic urology: incorporating 2-mm instruments in laparoscopic surgery. *Urology* 1998; **52**: 187–94
4 **Liao CH, Lai MK, Li HY, Chen SC, Chueh SC.** Laparoscopic adrenalectomy using needlescopic instruments for adrenal tumors less than 5 cm in 112 cases. *Eur Urol* 2008; **54**: 640–6
5 **Autorino R, Cadeddu JA, Desai MM *et al*.** Laparoendoscopic single-site and natural orifice transluminal endoscopic surgery in urology: a critical analysis of the literature. *Eur Urol* 2011; **59**: 26–45
6 **Gettman MT, White WM, Aron M *et al*.** Where do we really stand with LESS and NOTES? *Eur Urol* 2011; **59**: 231–4
7 **Gill IS.** Needlescopic surgery: current status. *Urol Clin North Am* 2001; **28**: 71–83
8 **Soulie M, Seguin P, Richeux L *et al*.** Urological complications of laparoscopic surgery: experience with 350 procedures at a single center. *J Urol* 2001; **165**: 1960–3
9 **Lee RS, Borer JG.** Robotic surgery for

© 2012 THE AUTHORS

ureteropelvic junction obstruction. *Curr Opin Urol* 2006; **16**: 291–4
10 **Bauer JJ, Bishoff JI, Moore RG, Chen RN, Iverson AJ, Kavoussi LR.** Laparoscopic versus open pyeloplasty: assessment of objective and subjective outcome. *J Urol* 1999; **162**: 692–5
11 **Desai MM, Rao PP, Aron M *et al*.** Scarless single port transumbilical nephrectomy and pyeloplasty: first clinical report. *BJU Int* 2008; **101**: 83–8
12 **Tracy CR, Raman JD, Bagrodia A, Cadeddu JA.** Perioperative outcomes in patients undergoing conventional laparoscopic versus laparoendoscopic single-site pyeloplasty. *Urology* 2009; **74**: 1029–35
13 **Stein RJ, Berger AK, Brandina R *et al*.** Laparoendoscopic single-site pyeloplasty: a comparison with the standard laparoscopic technique. *BJU Int* 2010; **107**: 811–16
14 **Tan HL.** Laparoscopic Anderson-Hynes dismembered pyeloplasty in children using needlescopic instrumentation. *Urol Clin North Am* 2001; **28**: 43–51
15 **Munteanu R, Cauni V, Iosifescu R *et al*.** Hynes-Andersen pyeloplasty by mini-laparoscopy transperitoneal approach. *Chirurgia (Bucur)* 2007; **102**: 89–93
16 **Porpiglia F, Billia M, Volpe A, Morra I, Scarpa RM.** Transperitoneal left laparoscopic pyeloplasty with transmesocolic access to the pelvi-ureteric junction: technique description and results with a minimum follow-up of 1 year. *BJU Int* 2007; **101**: 1024–28
17 **Fiori C, Morra I, Di Stasio A, Grande S, Scarpa RM, Porpiglia F.** Flexible pneumocystoscopy for double J stenting during laparoscopic and robot assisted pyeloplasty: our experience. *Int J Urol* 2010; **17**: 192–95
18 **Dindo D, Demartines N, Clavien PA.** Classification of surgical complications: a new proposal with evaluation in a cohort of 6336 patients and results of a survey. *Ann Surg* 2004; **240**: 205–10
19 **Durani P, McGrouther DA, Ferguson MW.** The patient scar assessment questionnaire: a reliable and valid patient-reported outcomes measure for linear scars. *Plast Reconstr Surg* 2009; **123**: 1481–89
20 **Schuessler WW, Grune MT, Preminger GM.** Laparoscopic dismembered pyeloplasty. *J Urol* 1993; **150**: 1795–9
21 **Look M, Chew SP, Tan YC *et al*.** Post-operative pain in needlescopic versus conventional laparoscopic cholecystectomy: a prospective randomised trial. *J R Coll Surg Edinb* 2001; **463**: 138–42
22 **Sarli L, Iusco D, Gobbi S, Porrini C, Ferro M, Roncoroni L.** Randomized clinical trial of laparoscopic cholecystectomy performed with mini-instruments. *Br J Surg* 2003; **90**: 1345–8
23 **Pini G, Goezen AS, Schulze M, Hruza M, Klein J, Rassweiler JJ.** Small-incision access retroperitoneoscopic technique (SMART) pyeloplasty in adult patients: comparison of cosmetic and post-operative pain outcomes in a matched-pair analysis with standard retroperitoneoscopy: preliminary report. *World J Urol* 2011; [Epub ahead of print]. DOI: 10.1007/s00345-011-0740-x
24 **Porpiglia F, Fiori C.** Mini-Laparoscopy in urology: current indications and future perspectives. Karl-Storz Endoscopy Silver Book. 2011
25 **Jarrett TW, Chan DY, Charambura TC, Fugita O, Kavoussi LR.** Laparoscopic pyeloplasty: the first 100 cases. *J Urol* 2002; **167**: 1253–56
26 **Zhang X, Li HZ, Ma X *et al*.** Retrospective comparison of retroperitoneal laparoscopic versus open dismembered pyeloplasty for ureteropelvic junction obstruction. *J Urol* 2006; **176**: 1077–80
27 **Fernbach SK, Maizels M, Conway JJ.** Ultrasound grading of hydronephrosis: introduction to the system used by the Society for Fetal Urology. *Pediatr Radiol* 1993; **23**: 478–80

Correspondence: Francesco Porpiglia, Division of Urology, Department of Clinical and Biological Sciences, University of Turin 'San Luigi' Hospital, Regione Gonzole 10, 10043 Orbassano (Turin), Italy.
e-mail: porpiglia@libero.it

Abbreviations: **BMI**, body mass index; **LESS**, laparoendoscopic single-site (surgery); **(s)(m)LP**, (standard) (mini-) laparoscopic pyeloplasty; **PSAQ**, Patient Scar Assessment Questionnaire; **PUJO**, PUJ obstruction; **VAS**, visual analogue scale.

© 2012 THE AUTHORS
BJU INTERNATIONAL © 2012 BJU INTERNATIONAL