

Different approaches to the prostate: The upcoming role of a purpose-built single-port robotic system

*Original*

Different approaches to the prostate: The upcoming role of a purpose-built single-port robotic system / Kaouk, Jihad; Garisto, Juan; Bertolo, Riccardo. - In: ARAB JOURNAL OF UROLOGY. - ISSN 2090-598X. - 16:3(2018), pp. 302-306. [10.1016/j.aju.2018.04.003]

*Availability:*

This version is available at: 11583/2811431 since: 2020-04-13T20:56:18Z

*Publisher:*

Taylor & Francis

*Published*

DOI:10.1016/j.aju.2018.04.003

*Terms of use:*

This article is made available under terms and conditions as specified in the corresponding bibliographic description in the repository

*Publisher copyright*

(Article begins on next page)



## Different approaches to the prostate: The upcoming role of a purpose-built single-port robotic system

Jihad Kaouk, Juan Garisto & Riccardo Bertolo

To cite this article: Jihad Kaouk, Juan Garisto & Riccardo Bertolo (2018) Different approaches to the prostate: The upcoming role of a purpose-built single-port robotic system, Arab Journal of Urology, 16:3, 302-306, DOI: [10.1016/j.aju.2018.04.003](https://doi.org/10.1016/j.aju.2018.04.003)

To link to this article: <https://doi.org/10.1016/j.aju.2018.04.003>



© Arab Association of Urology



Published online: 18 Mar 2019.



Submit your article to this journal [↗](#)




Article views: 86



View related articles [↗](#)



View Crossmark data [↗](#)



PELVIC SURGERY  
ORIGINAL ARTICLE

# Different approaches to the prostate: The upcoming role of a purpose-built single-port robotic system

Jihad Kaouk\*, Juan Garisto, Riccardo Bertolo

Glickman Urological and Kidney Institute, Cleveland Clinic, Cleveland, OH, USA

Received 17 March 2018, Received in revised form 27 March 2018, Accepted 11 April 2018  
Available online 24 May 2018

## KEYWORDS

LESS;  
Prostatectomy;  
Robot;  
Single-port;  
Single-site;  
Surgical technique

## ABBREVIATIONS

LESS, laparo-  
endoscopic single-site  
surgery;  
RP, radical prostatect-  
omy;  
SP, single-port

**Abstract** With the aim of minimising the patient's postoperative pain, expediting recovery and improving cosmesis, the idea of performing a laparoscopic procedure through a single abdominal incision was introduced. In the present report, we describe five different access routes to the prostate that may be at the surgeon's disposal with the potential of decreasing patient's perioperative morbidity. Robotic radical prostatectomy has been refined and became a standard of care in surgery for localised prostate cancer. The advent of single-port robotic surgery has prompted the re-discovery of different access routes to the prostate and ideally all of them are feasible. The potential for avoiding the abdominal cavity will decrease the surgical morbidity and minimise the surgical dissection. In the near future, each of the described approaches could be chosen on the basis of the patient's preoperative comorbidities, body habitus, anatomy, and disease characteristics and location.

© 2018 Production and hosting by Elsevier B.V. on behalf of Arab Association of Urology. This is an open access article under the CC BY-NC-ND license (<http://creativecommons.org/licenses/by-nc-nd/4.0/>).

## Introduction

With the aim of minimising the patient's postoperative pain, expediting recovery and improving cosmesis, the

idea of performing a laparoscopic procedure through a single abdominal incision was introduced [1].

Since then, laparo-endoscopic single-site surgery (LESS) has evolved significantly over recent years. Wide ranges of surgical procedures have been successfully performed by this contemporary approach [2]. Nevertheless, its role in the field of minimally invasive urological surgery has remained anecdotal due to the significant technical challenges requiring consistent efforts of the surgeon when compared with the standard laparoscopic approach [3]. Certainly, after the initial enthusiasm, the interest towards LESS has declined.

\* Corresponding author at: Glickman Urology and Kidney Institute, Cleveland Clinic, 9500 Euclid Ave, Q10, Cleveland, OH 44195, USA.  
E-mail address: [kaoukj@ccf.org](mailto:kaoukj@ccf.org) (J. Kaouk).

Peer review under responsibility of Arab Association of Urology.



Production and hosting by Elsevier

With technological advancement, it had been postulated that a robotic platform could be applied to LESS with the aim of facilitating the approach [4,5]. Indeed, in 2009, Kaouk et al. [6] reported the first successful series of robot-assisted LESS procedure in humans. They noted that robot-assistance was able to facilitate the dissection and the suturing [7]. After that, numerous robot-assisted LESS procedures have been described worldwide [8–10].

### **Evolution of minimally-invasive surgical approaches to the prostate**

During the last decade, there has been a great effort by urologists to develop technical modifications and refinements of the radical prostatectomy (RP) technique, with the aim of improving the clinical outcomes and minimising the patient's morbidity.

Undoubtedly, the advent of laparoscopy and later robotics has triggered the re-discovery of different access routes to the prostate. Indeed, the surgical accesses to the prostate were limited with the standard laparoscopic approach; whilst robot-assisted LESS has widened the possibilities.

In the present report, we describe five different access routes to the prostate that may be at the surgeon's disposal with the potential of decreasing patient's perioperative morbidity.

### **Evolution of robot-assisted LESS instruments**

Although the da Vinci system® (Intuitive Surgical Inc., Sunnyvale, CA, USA) was shown to be helpful, it was not specifically designed for LESS. A novel set of instrumentation that adapts to the da Vinci Si system and employs curved laparoscopic cannulas, namely the 'da Vinci Single-Site', was then designed to be specific for LESS.

The new robot-assisted LESS instruments were reported to be feasible in both pre-clinical [11,12] and clinical studies [13,14], but the introduction of such dedicated instrumentation represented a minimal step forward.

In fact, the lacking EndoWrist technology, representing one of the main advantages over standard laparoscopy of robotic surgery, remained a major limitation.

The new da Vinci purpose-built Single-Port Surgical System (SP1098, Intuitive Surgical Inc.) was then introduced featuring a system with one arm on which a scope and three robotic instruments can be inserted into the patient through a single robotic multichannel port [14].

Like the da Vinci EndoWrist® Instruments (Intuitive Surgical Inc.), the da Vinci SP EndoWrist instruments have seven degrees of freedom at the distal end, and the system software is designed to provide exact translation of the surgeon's hand and finger movements at the

console to precise and tremor-free movements of the instruments. The EndoWrist SP instruments incorporate an additional joint providing an 'elbow,' so that instruments can triangulate at the surgical site through a single port. The EndoWrist SP instruments are also longer and incorporate a 'snake-style' wrist similar to the 5-mm multiport EndoWrist instruments.

### **Surgical approaches to the prostate**

#### *Transperitoneal approach (Fig. 1, arrow 1)*

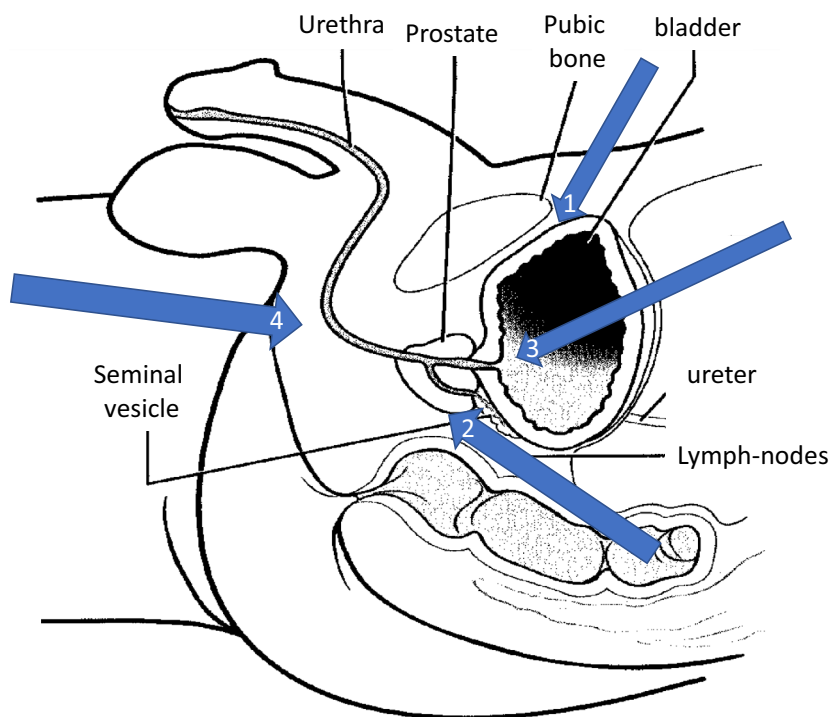
A 2.5-cm incision above the belly button is made to allow the insertion of the 2.5-cm robotic port. If it is necessary, an extra 5-mm port can be electively placed on the right-side para-rectal line, at the level of the umbilicus (Fig. 1).

After the peritoneal space is gained, the peritoneum is incised to gain the pelvic fossa. The main steps of the procedures are: bladder mobilisation, the defatting of the prostate and the incision of the endopelvic fascia, the management of the dorsal venous complex, the bladder neck dissection, the seminal vesicle dissection, the prostatic dissection, the dissection of the prostatic apex and urethra, and the vesico-urethral anastomosis, as previously described.

Such an approach is not limited by prostate size. Moreover, limited or even extended lymph node dissection can be effectively performed by the transperitoneal approach.

#### *Retzius-sparing approach (Fig. 1, arrow 2)*

The standard multiport robot-assisted approach was first described by Galfano et al. [16]. The parietal peritoneum is incised at the anterior surface of the Douglas space. The seminal vesicles and the vas deferens are isolated and incised. Denonvilliers' fascia is separated by the postero-lateral surface of the prostate in an antegrade direction, reaching the prostatic apex so that a completely intrafascial plane is maintained. The bladder neck is isolated and sectioned. In order to evert the mucosa and to easily identify the bladder neck orifice for performing the anastomosis, four short cardinal sutures can be positioned. The anterior surface of the prostate is bluntly isolated from the dorsal venous complex without any incision. The apex isolation is completed, and the urethra is incised, completing the RP. Anastomosis is performed using a running suture starting from the 3 o'clock position. After the anterior sutures into the bladder neck are passed, the catheter is pushed into the bladder and the anastomosis is completed. The final step of the procedure is represented by the closure of the parietal peritoneum at the Douglas space level. Several advantages have been suggested for the Retzius-sparing approach, such as the complete



**Fig. 1** Pelvic anatomy (sagittal view). Each arrow indicates the different possible approaches to the prostate: (1) conventional approaches (transperitoneal and extraperitoneal), (2) Retzius-sparing, (3) transvesical, and (4) transperineal.

intrafascial dissection, the avoidance of the Santorini plexus and pubourethral ligaments, and a smaller surgical dissection allowing for impressively high potency rate and early return of continence [15,16]. On the other side, the limited space available with such an approach may bring some disadvantages, especially in men with large prostates. Several reports have studied the impact of prostate gland size on the outcomes: Retzius-sparing approach is oncologically and functionally equivalent regardless of the prostate size but is technically demanding for larger prostates [17].

#### *Extraperitoneal approach (Fig. 1, arrow 1)*

A lower, umbilical 2.5-cm 'U' incision is made, the anterior rectus fascia is incised and the rectus muscle fibres are vertically separated. Then the pre-peritoneal space is created using finger dissection. A balloon trocar is the best way to complete the dissection. In expertise hands, the dissection can be performed under view using the optic itself.

The multichannel trocar is then placed just beneath the rectus muscle. In addition, a 12-mm port can be inserted into the left fossa to facilitate the use of standard laparoscopic instruments if required. The procedure is then performed according to the main steps as aforementioned.

Such an approach can be considered in cases of previous major intra-abdominal surgeries. A drawback is represented by the limitation in performing an extended lymph node dissection if required.

#### *Transvesical approach (Fig. 1, arrow 3)*

Currently, such an approach has been described on pre-clinical models only. The cadaver is placed in lithotomy. A 3-cm midline incision is made in the suprapubic area, 4 cm above the symphysis pubis. A retropubic access is achieved. The bladder is distended via a urethral catheter and a GelPOINT® (Applied Medical, Rancho Santa Margarita, CA, USA) is introduced percutaneously into the bladder. Then, a multichannel single-port is inserted through the GelPOINT to accommodate the oval articulating camera (12 × 10 mm) and three 6-mm double-jointed articulating instruments. An extra 8-mm accessory port in the GelPOINT is used for suctioning and introduction of sutures. The SP robotic platform is docked from the patient's side. Pneumovesicium is obtained after CO<sub>2</sub> insufflation, providing an adequate space for the mobilisation of the robotic arms. The initial step is to perform an incision distal to the trigone to expose the peripheral zone of the prostate and avoid the ureteric orifices. The incision is deepened through the full thickness of the detrusor in order to expose the

vas deferens and the seminal vesicles. The vas deferens is divided bilaterally and both the seminal vesicles are completely mobilised and maintained on anterior retraction. Thereafter, Denonvilliers' fascia is incised, and then the posterior dissection is performed along the pre-rectal fat up to the prostatic apex. The posterior bladder neck incision is extended on both sides to encircle the bladder neck.

The bladder neck incision is initially deepened from the 7 to 11 o'clock position on the left side and from the 1 to 4 o'clock position contra-laterally. This manoeuvre gives exposure to the lateral prostate surface medially and the levator ani fibres laterally. These incisions are joined in the midline (at the 12 o'clock position) to expose the anterior surface of the prostate and the dorsal vein complex. The lateral prostate pedicles are divided using the robotic scissors and the neurovascular bundles are managed on the basis of the clinical indication. The management of the dorsal vein complex is performed on the basis of the surgeon's preference.

The urethra is divided just distal to the prostatic apex. The completely mobilised prostate is placed within the bladder. The vesico-urethral anastomosis is made using a running suture. The remainder of the bladder is closed anteriorly in a 'racket-handle' fashion from within the bladder. Then, the prostate specimen is extracted.

The unique aspects of the novel purpose-built single-port platform lead to several advantages of the transvesical approach if compared with a multiport transperitoneal robotic approach. The access through the suprapubic incision with the Gelport is technically simple and avoids the risks inherent to intraperitoneal access, such as injures to hollow viscus. In addition, the transvesical access avoids the need for a steep Trendelenburg position, with undoubted advantages in patients with comorbidities. After the single-port system is docked, the SP cannula is positioned inside the bladder providing an acceptable pneumovesicum due to the effective seal from the multi-access platform. With sufficient bladder distention and the ergonomic design of the purpose-built system with the EndoWrist technology instruments, there is the ideal surgical space for intracorporeal triangulation making even the anterior resection of the prostate feasible. Moreover, pneumoperitoneum is bypassed with the transvesical approach excluding the possible deleterious effects of CO<sub>2</sub> absorption on the cardiopulmonary physiology of patients.

In the near future, using such an approach, RP could even be tried under epidural anaesthesia [18]. Such an approach has been attempted with the DaVinci Si multi-ports platform too [19].

#### *Transperineal approach (Fig. 1, arrow 4)*

The patient has to be placed in exaggerated dorsal lithotomy with a 15° Trendelenburg position to facilitate the access to the perineum. Position requirements exclude some patients from the perineal approach, including those with severe ankylosis of the hips or spine, or such extreme obesity that the weight on the diaphragm requires excessive ventilatory pressure that restricts cardiac filling [17]. A 2.5-cm semilunar incision is made in the midline, between the ischial tuberosities. The subcutaneous tissue is dissected and the central tendon of the perineal body is identified and cut. The recto-urethralis muscle is then found and transected to expose the space inferior to the membranous urethra. In this manner, the external sphincter is identified and retracted superiorly. At this point, the 2.5-cm multichannel single-port is placed. Three 6-mm robotic instruments and a 10° 12-mm articulating camera are accommodated. The robotic device is then docked beside the patient. The entire procedure is performed using standard insufflation with pressures of 12–15 mmHg. The key steps of open transperineal RP are reproduced. Once the single-port robotic device is docked, the posterior prostatic space is developed to expose the levator ani muscles on either side of the posterior aspect of the prostate. The levator ani fibres are split along the lateral aspects of the prostate, and Denonvilliers' fascia is opened. This is performed in a way that preserves the neurovascular bundles bilaterally. Once Denonvilliers' fascia is open, the posterior plane of the prostate is delineated and followed to find the insertion of the seminal vesicles and vas deferens bilaterally. Once this is done, bilateral vascular pedicles to the prostate are identified and ligated. The prostatic apex and urethra are dissected and the urethra is sharply cut to expose the catheter. The catheter may be clipped to maintain fluid in the catheter balloon and the catheter is cut. The proximal portion of the catheter may be used to place traction on the prostate. The junction between the bladder neck and prostate is identified and opened. Once this is done, the clip on the catheter is removed to allow emptying of the catheter balloon and the release of the prostate is completed.

The potential advantages of perineal RP could be less postoperative discomfort, more rapid resumption of physical activity and return to work. Moreover, transperineal RP may be easier in patients with previous pelvic surgery.

It is known from the open perineal approach literature that urine control postoperatively is mostly immediate due to preserved urethra-sphincter complex anatomy [20–24].



## Conclusions

Robotic RP has been refined and became a standard of care in surgery for prostate cancer. The advent of single-port robotic surgery has prompted the re-discovery of different access routes to the prostate. All of them are ideally feasible. The potential for avoiding the abdominal cavity will decrease the surgical morbidity and minimize the surgical dissection. In the near future, each of the described approaches could be chosen on the basis of the patient's preoperative comorbidities, body habitus, anatomy, and disease characteristics and location.

## Conflict of interest and financial disclosures

Jihad H. Kaouk certifies that all conflicts of interest, including specific financial interests and relationships and affiliations relevant to the subject matter or materials discussed in the manuscript (e.g. Employment/affiliation, grants or funding, consultancies, honoraria, stock ownership or options, expert testimony, royalties, or patent filed, received or pending) are the following: Endocare Inc., Intuitive.

Nothing to disclose: Riccardo Bertolo, Juan Garisto.

## References

- [1] Autorino R, Cadeddu JA, Desai MM, Gettman M, Gill IS, Kavoussi LR, et al. Laparoendoscopic single site and natural orifice transluminal endoscopic surgery in urology: a critical analysis of the literature. *Eur Urol* 2011;**59**:26–45.
- [2] Kaouk JH, Autorino R, Kim FJ, Han DH, Lee SW, Yinghao S, et al. Laparoendoscopic single-site surgery in urology: worldwide multi-institutional analysis of 1076 cases. *Eur Urol* 2011;**60**:998–1005.
- [3] Tang B, Hou S, Cuschieri SA. Ergonomics of and technologies for single-port laparoscopic surgery. *Minim Invasive Ther Allied Technol* 2012;**21**:46–54.
- [4] White MA, Haber GP, Autorino R, Khanna R, Altunrende F, Yang B, et al. Robotic laparoendoscopic single-site surgery. *BJU Int* 2010;**106**:923–7.
- [5] Rane A, Autorino R. Robotic natural orifice transluminal endoscopic surgery and laparoendoscopic single-site surgery: current status. *Curr Opin Urol* 2011;**21**:71–7.
- [6] Kaouk JH, Goel RK, Haber GP, Crouzet S, Stein RJ. Robotic single-port transumbilical surgery in humans: initial report. *BJU Int* 2009;**103**:366–9.
- [7] White MA, Autorino R, Spana G, Hillyer S, Stein RJ, Kaouk JH. Robotic laparoendoscopic single site urological surgery: analysis of 50 consecutive cases. *J Urol* 2012;**187**:1696–701.
- [8] Won Lee J, Arkoncel FR, Rha KH, Choi KH, Yu HS, Chae Y, et al. Urologic robot-assisted laparoendoscopic single-site surgery using a homemade singleport device: a single-center experience of 68 cases. *J Endourol* 2011;**25**:1481–5.
- [9] Olweny EO, Park SK, Tan YK, Gurbuz C, Cadeddu JA, Best SL. Perioperative comparison of robotic assisted laparoendoscopic single-site (LESS) pyeloplasty versus conventional LESS pyeloplasty. *Eur Urol* 2012;**61**:410–4.
- [10] Haber GP, White MA, Autorino R, Escobar PF, Kroh MD, Chalikhonda S, et al. Novel robotic da Vinci instruments for laparoendoscopic single-site surgery. *Urology* 2010;**76**:1279–82.
- [11] Kaouk JH, Autorino R, Laydner H, Hillyer S, Yakoubi R, Isac W, et al. Robotic single-site kidney surgery: evaluation of second-generation instruments in a cadaver model. *Urology* 2012;**79**:975–9.
- [12] Cestari A, Buffi NM, Lista G, Lughezzani G, Larcher A, Lazzeri M, et al. Feasibility and preliminary clinical outcomes of robotic laparoendoscopic single-site (R-LESS) pyeloplasty using a new single-port platform. *Eur Urol* 2012;**62**:175–9.
- [13] Mathieu R, Verhoest G, Vincendeau S, Manunta A, Bensalah K. Robotic-assisted laparoendoscopic single-site radical nephrectomy: first experience with the novel Da Vinci single-site platform. *World J Urol* 2014;**32**:273–6.
- [14] Kaouk JH, Haber GP, Autorino R, Crouzet S, Ouzzane A, Flamand V, et al. A novel robotic system for single-port urologic surgery: first clinical investigation. *Eur Urol* 2014;**66**:1033–43. <https://doi.org/10.1016/j.eururo.2014.06.039>.
- [15] Galfano A, Ascione A, Grimaldi S, Petralia G, Strada E, Bocciardi AM. A new anatomic approach for robot-assisted laparoscopic prostatectomy: a feasibility study for completely intrafascial surgery. *Eur Urol* 2010;**58**:457–61.
- [16] Galfano A, Di Trapani D, Sozzi F, Strada E, Petralia G, Bramerio M, et al. Beyond the learning curve of the Retzius-sparing approach for robot-assisted laparoscopic radical prostatectomy: oncologic and functional results of the first 200 patients with  $\geq 1$  year of follow-up. *Eur Urol* 2013;**64**:974–80.
- [17] Santok GD, Abdel Raheem A, Kim LH, Change K, Lum TG, Chung BH, et al. Perioperative and short-term outcomes of Retzius-sparing robot-assisted laparoscopic radical prostatectomy stratified by gland size. *BJU Int* 2017;**119**:135–41. <https://doi.org/10.1111/bju.13632>.
- [18] Kaouk J, Sagalovich D, Garisto J. Robotic transvesical partial prostatectomy using a purpose-built single port robotic system. *BJU Int* 2018. <https://doi.org/10.1111/bju.14194> [Epub ahead of print].
- [19] Kaouk J, Garisto J, Sagalovich D, Dagenais J, Bertolo R, Klein E. Robotic single-port partial prostatectomy for anterior tumors: transvesical approach. *Urology* 2018. Accepted for publication.
- [20] Maurice MJ, Kaouk JH. Robotic radical perineal cystectomy and extended pelvic lymphadenectomy: initial investigation using a purpose-built single-port robotic system. *BJU Int* 2017;**120**:881–4. <https://doi.org/10.1111/bju.13947>.
- [21] Ramirez D, Maurice MJ, Kaouk JH. Robotic perineal radical prostatectomy and pelvic lymph node dissection using a purpose-built single-port robotic platform. *BJU Int* 2016;**118**:829–33. <https://doi.org/10.1111/bju.13581>.
- [22] Kaouk JH, Akca O, Zargar H, Caputo P, Ramirez D, Andrade H, et al. Descriptive technique and initial results for robotic radical perineal prostatectomy. *Urology* 2016;**94**:129–38. <https://doi.org/10.1016/j.urology.2016.02.063>.
- [23] Akca O, Zargar H, Kaouk JH. Robotic surgery revives radical perineal prostatectomy. *Eur Urol* 2015;**68**:340–1. <https://doi.org/10.1016/j.eururo.2015.03.001>.
- [24] Laydner H, Akça O, Autorino R, Eyraud R, Zargar H, Brandao LF, et al. Perineal robot-assisted laparoscopic radical prostatectomy: feasibility study in the cadaver model. *J Endourol* 2014;**28**:1479–86. <https://doi.org/10.1089/end.2014.0244>.