

Biomaterials and implants for orbital floor repair

Original

Biomaterials and implants for orbital floor repair / Baino, Francesco. - In: ACTA BIOMATERIALIA. - ISSN 1742-7061. - STAMPA. - 7:(2011), pp. 3248-3266. [10.1016/j.actbio.2011.05.016]

Availability:

This version is available at: 11583/2467783 since:

Publisher:

Elsevier

Published

DOI:10.1016/j.actbio.2011.05.016

Terms of use:

This article is made available under terms and conditions as specified in the corresponding bibliographic description in the repository

Publisher copyright

(Article begins on next page)

Biomaterials and implants for orbital floor repair

Francesco Baino*

This is the author post-print version of an article published on *Acta Biomaterialia*, Vol. 7, pp. 3248-3266, 2011 (ISSN 1742-7061).
The final publication is available at
<http://dx.doi.org/10.1016/j.actbio.2011.05.016>
This version does not contain journal formatting and may contain minor changes with respect to the published edition.
The present version is accessible on PORTO, the Open Access Repository of the Politecnico of Torino, in compliance with the publisher's copyright policy.
Copyright owner: *Elsevier*.

*Materials Science and Chemical Engineering Department, Politecnico di Torino, Corso Duca degli
Abruzzi 24, 10129 Torino, Italy.*

*Corresponding author: F. Baino

Tel.: +39 011 564 4668

Fax: +39 011 564 4699

Abstract

Treatment of orbital floor fractures and defects is often a complex issue. Repair of these injuries essentially aims to restore the continuity of the orbital floor and to provide an adequate support to the orbital contents. Several materials and implants have been proposed over the years for orbital floor reconstruction, in the hope to achieve the best clinical outcomes to the patients. Autografts have been traditionally considered as the “gold standard” choice due to the absence of immunological response, but they are available in limited amount and carry the need for extra-surgery. In order to overcome the drawbacks related to autografts, researchers’ and surgeons’ attention has been progressively attracted by alloplastic materials, that can be commercially produced and easily tailored to fit a wide range of specific clinical needs. In this review, the advantages and limitations of the various biomaterials proposed and tested for orbital floor repair are critically examined and discussed. Criteria and guidelines for optimal material/implant choice, as well as future research directions are also presented, in an attempt to understand whether an ideal biomaterial already exists today or a truly functional implant will eventually materialize in the next few years.

Keywords: Orbital floor surgery; Biocompatibility; Autograft; Alloplastic; Tissue regeneration.

1. Introduction

Orbital floor fractures alone or in conjunction with other facial skeletal damages are the most commonly encountered midfacial fractures, second only to nasal ones. According to Ng et al. [1] and Chang and Manolidis [2], orbital floor fractures were first described by MacKenzie in 1844 in Paris. More than one century later, in 1957 Smith and Regan [3] described inferior rectus muscle entrapment with decreased ocular motility in the setting of an orbital fracture and coined the term “blow-out fracture”. Since the 1960s, different surgical routes have been proposed for the effective management of orbital floor fractures [4-11].

It should be taken into account that the management of orbital floor injuries is complicated not only by their technical difficulty *per se*, but also by the required extensive medical competences – ranging from maxillofacial to otolarygologic to ophthalmic field – and by the multitude of factors necessary to make a correct decision as to the proper timing of the repair.

In addition to timing- and surgery-related issues, another key factor in the treatment of orbital fractures is the choice of the material used for tissue(s) reconstruction. A wide number of studies describing orbital fracture repair with a considerable variety of autogenous, allogenic and alloplastic materials is available in the literature. However, direct comparison between different materials are rather rare and, therefore, it is not trivial to draw definite conclusions as to which material is best suitable to repair these injuries. The present review addresses this issue: specifically, the advantages and limitations of currently adopted biomaterials and implants are critically examined, and possible new research direction towards a truly ideal device are described and discussed.

The article can be divided in three parts, that are devoted to present an essential medical background, a comprehensive materials/implants review and some indications/remarks for material choice/prospective research, respectively. The first part comprises the section 2, that gives the reader a concise overview of the features, treatment and complications of orbital floor fractures; in such a context, Table 1 also provides a short glossary of the medical terms that are not explained

directly in the text or that may be unclear or unknown to non-specialist readers. The second part includes the sections 3-8, in which the different classes of biomaterials and implants used for treating orbital floor fractures are extensively reviewed. In the third part, constituted by the sections 9-11, the performances of the different materials and implants in current use are critically compared and discussed, and a forecast about future challenges is presented.

2. Orbital floor fractures: a short overview

2.1. Aetiology and features

Damage to the facial skeleton is usually the result of low-, medium- or high-velocity trauma, for instance due to a motor vehicle or traffic accident. A fracture in the orbital floor commonly causes the herniation of orbital fat and other orbital contents into the maxillary sinus(es), which results in an increase of the orbital volume (Fig. 1). Orbital floor fractures can occur as isolated injuries or in combination with extensive facial bony disruption. The orbital floor is most vulnerable to fracture because of the thinness of the roof of maxillary sinus, existence of the infraorbital canal and curvature of the floor. Immediately behind the orbital rim, the floor is concave, whereas further back it becomes convex forming the so-called posterior ledge, in which the bony structure appears thicker and less prone to deformation in case of fracture.

Pure orbital floor fractures, often referred to as isolated orbital fractures, commonly result from an impact injury to the ocular globe and upper eyelid. In most cases, the object is large enough not to perforate the eyeball and small enough not to cause fracture of the orbital rim. Two possible mechanisms have been proposed to explain orbital floor fractures: (i) hydraulic theory (HT) and (ii) bone conduction theory (BCT) [12]. HT involves the direct transmission of pressure from the ocular globe and intraorbital contents to the periocular structures, which eventually leads to the blowing out of the orbital floor. In fact, most fractures occurs in the posterior medial region, which is the

thinnest bony orbital area. The second mechanism (BCT), which is generally less favoured, involves indirect transmission of pressure from the orbital rim along the bone to the floor.

Although most pure orbital fractures affect the medial region of the infraorbital floor, any fracture type, size or geometry is – at least virtually – possible.

Several clinical symptoms are associated to orbital fractures, including decreased visual acuity, blepharoptosis, and ipsilateral hypoesthesia, dysesthesia or hyperalgesia related to the infraorbital nerve. Binocular vertical or oblique diplopia is caused by restricted ocular movements and occurs most commonly in upward gaze; it can be attributed to incarceration of the orbital contents/extraocular muscles, muscle contusion or damage to the nerves of extraocular muscles. Furthermore, patients may complain of epistaxis and eyelid swelling after nose blowing. Periorbital ecchymosis and oedema accompanied by pain are obvious external signs and symptoms. Subconjunctival haemorrhage caused by rupture of blood vessels on the conjunctiva usually resolves without treatment within 1-2 weeks. Enophthalmos, that is most commonly caused by enlarged orbital cavity after blow-out fracture, may be also discerned although it can be initially hidden by the swelling of surrounding tissues. It may also result from retrobulbar or peribulbar haemorrhage. Orbital emphysema related to the communication with maxillary sinus as well as orbital haemorrhage may occur; occasionally, intraorbital air may cause occlusion of central retinal artery and lead to severe visual loss.

2.2. Treatment

Timing of repair and modality of surgical intervention are critical issues that strongly affect the overall outcomes of orbital floor fractures treatment [13-16]. In 2002, Burnstine [17] reviewed about 20 years of literature on the management of orbital floor fractures and suggested a set of recommendations to approach and treat such injuries. Specifically, Burnstine [17] described three time periods for repair: immediate, within 2 weeks, and late (after a prolonged observation time).

Immediate surgical treatment is recommended in cases of fractures characterized by orbital soft tissue entrapment with nonresolving oculocardiac reflex, early enophthalmos or hypoglobus associated to marked facial asymmetry [18]. Early surgery is also warranted in children with evidence of muscle entrapment, which can lead to muscle or fat ischemia and result in severe permanent diplopia: several studies demonstrated that, in these potentially critical cases, earlier surgery time yielded better clinical outcomes [19-21].

Surgical repair within 2 weeks is warranted in adults with symptomatic diplopia with positive force duction testing, evidence of muscle or perimuscular soft tissue entrapment and minimal clinical improvement over time under drug therapy [17]. Surgical treatment should be always considered if progressive infraorbital hypoesthesia should occur [22], as well as for repairing orbital defects greater than 50% of the orbital floor that are depressed with resultant enophthalmos [17].

Finally, medical treatment may be preferred to immediate or early surgical correction in patients exhibiting weak enophthalmos (< 2 mm), lack of marked hypoglobus, absence of an entrapped muscle or tissue, good ocular motility, a fracture involving less than 50% of the orbital floor and lack of diplopia. In addition, medical therapy should be used if surgical correction is contraindicated, for instance in patents who are unable to tolerate anaesthesia. The patient can be treated with oral antibiotics due to the disruption of the integrity of the orbit in communication with the maxillary sinus. Controlled administration of corticosteroid drugs may also benefit the patient by reducing the oedema of orbit/muscle. This allows a more correct assessment of the relative contribution to enophthalmos and muscle/tissue entrapment due to the fracture versus that due to the oedema. Nose blowing should be firmly discouraged to avoid creating or worsening orbital emphysema; nasal decongestants can be used if not contraindicated. If poor clinical improvement is achieved after 2 weeks, surgical intervention should be performed; late corrections, however, may not produce as good results as early intervention.

Transmaxillary, subciliary and transconjunctival approaches are the traditional surgical routes adopted for repairing orbital floor fractures [2-8,12,15]; the latter two options are generally

preferred by most surgeons as they are minimally invasive. The main advantage of transconjunctival route is the absence of visible external eyelid scar. These open approaches, however, have been reported to exhibit a non-negligible eyelid complication rate, including scleral show or gross ectropion [2]. In order to overcome these drawbacks, endoscopic-assisted approach via a transmaxillary route has been recently introduced with general consensus of surgeons, as it decreases the incidence of sequelae related to eyelid or periorbital incisions [9-11]. The various steps involved in this surgical technique are illustrated in Fig. 2 for the reader's benefit and better understanding.

Over the years, many studies have sought to identify the optimal surgical modality for the successful treatment of blow-out fractures of the inferior orbital wall. Each specific approach, as well as proper combinations of the current methods, can offer different advantages depending on location and shape of the fracture. An interesting clinical analysis and comparison of the various approaches was recently reported by Kwon et al. [23].

2.3. Surgery outcomes and possible complications

Although in most cases the procedure of orbital floor repair can ensue in a complete success from a surgical viewpoint, the patient might consider the outcome as unsatisfactory. This crucial issue should be carefully taken into account in order to ensure a good quality of life, in the broadest sense, to the patient. Surgeon and patient should be in mutual agreement about the realistic outcome of the repair, and the patient should be aware on the possible risks and complications related to orbital surgery. Each case should be considered individually to maximize the potential for restoration of orbital structures, cosmetic appearance and visual function [12,15,24-26].

The common postsurgical sequelae are ectropion or entropion, which can be minimized by meticulous dissection and re-suspension of soft tissues.

In general, partial or total loss of vision is the most dramatic complication that may occur after orbital floor surgery. Visual deterioration or blindness may be due to retrobulbar haematoma, a luckily rare complication, which may eventually result in retinal ischemia due to elevated intraocular pressure (IOP) or direct compression of the optic nerve.

Other ominous consequences and side effects can resolve spontaneously or require additional surgical procedure. No absolute promises about an immediate resolution of any pre-surgical neuralgia should be made: in fact, neuralgia associated to infraorbital nerve may often persist after surgery, and a significant improvement of this problem may take 6 months or more.

Transient postoperative diplopia is expected and usually resolved spontaneously within 2-3 months; if persistent, it may become a serious complication. If isolated to extreme positions of gaze, it may be negligible and almost unnoticed by the patient; otherwise, if diplopia affects functional positions of gaze, the use of corrective lenses can be suggested, or, as an ultimate solution, eye muscle surgery can be recommended to properly reposition the extraocular muscles.

Postoperative enophthalmos is another potential complication due to the difficulty in accurately assessing the orbital volume intraoperatively. It often worsens over time owing to orbital fat atrophy and, in this case, additional surgical procedures are required.

Complications often directly related to the implant, such as extrusion, infection or chronic inflammation, can also require extra-surgery to remove the foreign material.

3. Materials for orbital floor reconstruction

Basically, the goal of an orbital floor implant is to repair the traumatic defect, lifting the eyeball into its correct position and thereby avoiding enophthalmos. An ideal implant biomaterial should be (i) biocompatible, (ii) available in sufficient quantities, (iii) strong enough to support the orbital contents and the related compressive forces, (iv) easy to be shaped to fit the orbital defect and regional anatomy, (v) easily fixable *in situ*, (vi) not prone to migration, (vii) osteoinductive and

(viii) bioresorbable with minimal foreign-body reaction. To find a proper material for orbital floor reconstruction is not an easy task. This has been proved by the wide number of substances of biological or synthetic origin that have been experimented during the last 50 years (Table 2), in the hope that a truly functional biomaterial will eventually materialize. Today, a myriad of implants is at surgeon's disposal and available on the market for treating orbital floor fractures.

In 1996 Neigel and Ruzicka [27] reviewed the allogenic materials used in orbital floor surgery, whereas two years later Choudhry and Krause [28] gave some indications for material selection, focusing their attention on autografts and, specifically, on autologous bone. In 2004, Mok et al. [29] and Potter and Ellis [30] reviewed both biologically-derived and alloplastic materials for orbital floor fracture management. In 2010, Betz et al. [31] published an excellent contribution to maxillofacial and ophthalmic literature, in which the potential of tissue-engineered constructs for orbital floor regeneration was highlighted.

The present article extensively deals with the evolution of orbital floor biomaterials and implants, particularly underlining the advances that have been made in such a context over the last few years, as well as the promise for the future. Specifically, the following sections give an extensive overview of the biomaterials tested for orbital floor repair both clinically (if the implant has been definitely approved for medical use) and experimentally; some examples of implants are collected in Fig. 3.

4. Biological materials

Over the years, a wide range of biological materials has been tested in the field of orbital floor repair. They have been derived from human or animal tissues and could be used for performing transplants (autografts, allografts and xenografts) or properly treated for obtaining suitable substances to be used as implant materials. In general, biological materials carry some problems, such as limited availability and morbidity at the harvest site for autologous tissues and risks of viral

infections and disease transmission (especially in the past) for donor (living or cadaver) tissue; in addition, the resorption rate of such materials can vary greatly depending on their origin.

4.1. Autografts

The use of autografts requires an appropriate amount of patient's autologous tissue, harvested from a donor site, which is properly shaped in order to match defect dimensions, thereby providing a rigid structural support to the surrounding tissues and structures.

4.1.1. Autologous bone

In principle, autografts from patient's bone are considered by the majority of surgeons as the "gold standard" material for bone tissue repair [32]. In the field of orbital floor repair, preferential donor sites include split calvarial bone, maxillary wall, mandibular symphysis, antral bone, rib, parietal bone and iliac crest [33-43]. Specifically, calvarial bone seems to be the best option for orbital reconstruction [44,45]. The graft can be placed as-such [46], fixated by screws and/or plates [47] or used in conjunction with an alloplastic material, such as titanium mesh or porous polyethylene [48,49].

The advantages of autologous bone are its inherent strength, rigidity and vascularisation potential [28]. Most of all, autografts exhibit excellent biocompatibility and tolerance after implantation: because autologous bone grafts are incorporated in the organism, as living tissue and elicit no immune reaction to self-antigens, foreign body reactions such as infection, extrusion, collagenous capsule formation and ocular tethering are minimized.

After careful selection, Chowdhury and Krause [28] indicated autologous bone as the preferable material of choice in orbital floor reconstruction. Over the years, this conclusion was supported by

other comparative studies [50-53], and the unique advantages of using autologous bone have been further highlighted in recent research reports [41,42].

In 2009, Rudagi et al. [41] reconstructed orbital floor fractures in 11 patients by using autogeneous mandibular symphyseal bone grafts. The patients were monitored for 1.5 years postoperatively: a good restoration of the orbital floor was reported and extraocular movements were intact in all cases; there were also transient complications, such as enophthalmos and diplopia, that resolved spontaneously by few months after surgery. Only one patient exhibited symptoms of infection after 9 months of follow-up; after removal of the titanium plates used for graft stabilization the infection significantly subsided, and therefore this complication was deemed not associated to the autogeneous material.

Sakakibara et al. [42] used 1 mm-thick autogenous iliac crest grafts (Fig. 3a) for repairing orbital floor fractures in 101 patients. At 6-month follow-up, computed tomography (CT) scanning showed normal orbit morphology and ossification of the transplanted bone grafts; persistent diplopia was observed in 15 patients. The authors emphasized the easiness of shaping and cutting the iliac crest graft to fit orbit's curvature, thanks to material softness, pliability and flexibility.

Shetty et al. in 2009 [54] and Ram et al. in 2010 [55] underlined the particular suitability of autologous bone grafts for repairing large orbital floor defects.

However, the use of autologous bone is associated with several less favourable aspects. First, it is not always easy to contour bone according to the desired shape and size, which may depend on graft's harvest site; furthermore, the graft can break if it is bent beyond its natural capacity. In the case of large defects involving multiple fractures and disruption of bony buttresses, other biomaterials are preferred or combined to autologous bone. In such a context, Ellis and Tan [56] demonstrated that a better accuracy of reconstruction can be achieved by using titanium mesh rather than cranial bone grafts.

One of the major drawbacks of autologous bone is its unpredictable resorption, that can vary within a quite wide range and depends on the graft origin [47,57-59]. It was demonstrated that, generally,

the resorption rate of bone of membranous embryological origin is slower than that of endochondral grafts [57-59]. Cancellous bone is less resistant to resorption than cortical bone due to its porous nature [46]. Some authors reported that it is possible to decrease graft resorption by fixating it rigidly to the surrounding tissues, as this can promote implant vascularisation and new bone ingrowth [47,58,59].

Further problems associated to the use of autologous bone grafts concerns the material harvesting from a donor site, including significant increase in surgery time and patient's time under general anaesthesia [28]. For the most part, the donor graft is harvested without particular complications, but general risks include infection and haematoma at the donor site and/or injury to the healthy tissue, increased time of recovery and additional postoperative pain. Furthermore, extra-surgery creates a bony defect at the patient's donor site and an additional scar. Certain donor sites are associated to possible site-specific complications [28,33,34]: for instance, bone harvesting from cranium may induce dural tears, subarachnoid haemorrhage and intracerebral haematoma; cases of haemiparesis following an intracranial bleed are also reported [33].

4.1.2. Cartilage

The currently used autologous cartilage grafts include ear [60] and nasal septum [61-63] cartilage. As already described for autologous bone, postoperative complications such as infection, extrusion and chronic inflammatory reactions are less prevalent than with alloplastic materials [28]. If compared to autologous bone, cartilage is usually easier to harvest and to shape, and it can provide a long-term support to the surrounding tissues without undergoing resorption even after follow-up of several years.

Constantian [60] used conchal cartilage to fill orbital defects smaller than 4 cm² and emphasized the easiness of graft tailoring, as the natural curvature of concha nicely fitted that of orbital floor. In the work by Lai et al. [61], 13 patients who presented with orbital blow-out fractures underwent

reconstruction with nasoseptal cartilage: there were no recipient or donor site complications except for one patient with persistent manifest enophthalmos requiring a second operation. Kraus et al. [62] used septal cartilage grafts for 20 orbital floor reconstructions and reported uncomplicated harvesting, minimal donor site morbidity and postoperative surgery-related complications (enophthalmos, lower lid oedema) in 2 patients (graft material was not associated to these adverse outcomes). Successful use of nasoseptal cartilage for the repair of orbital floor in children was also reported [63].

As highlighted by Bayat et al. [64] in a recent work, cartilage actually has a great potential as grafting material since it is an easily accessible, abundant, autogenous source able to provide adequate support to the orbital floor and minimal donor site morbidity. Therefore, it is a bit surprising that it is an underutilized material for reconstruction of orbital blow-out fractures.

4.1.3. Occasionally used autologous materials

Tensor fascia lata [65] and periosteum transplants [66] have been occasionally tested in orbital floor surgery. The use of these grafts led to good clinical outcomes, with complication rates comparable to those of bone and cartilage autografts. The major drawbacks of these two grafts seem to be their limited ability to hold orbital contents in place, which makes them suitable to repair only small orbital defects ($< 1 \text{ cm}^2$), and difficult harvesting.

4.2. Allografts

A partial solution to the patient's drawbacks associated with autografts is the use of allografts (often called homografts), i.e. the transplant of hard/soft tissue(s) from another living patient or from cadavers [27,32,37]. Specifically, the advantages over autologous grafts include lack of donor site morbidity, decreased surgery time, opportunity of pre-forming and customizing the implant before

surgery, and – at least virtually – unlimited availability of grafting material with particular reference to banked bone.

However, especially in the past, allografts were associated to the risk of disease transmission from donor to patient (for instance, cases of hepatitis C [67] and HIV [68] transmission have been reported) and their use often involved the need for immunosuppressant drugs administration. Currently, at least in Europe, a wide legislation exists and the donors/graft sources are carefully checked before the allograft is released for clinical use [69-71].

It is worth mentioning that, however, the use of allografts may be limited by ethical and religious issues.

Lyophilized dura mater (often called “lyodura”) [72-74] and banked demineralised bone [27,75] are the most commonly employed allografts, but the use of allogenic cartilage [73,76] is also documented. Complications associated with the use of lyodura (e.g. enophthalmos, infection, extrusion) were generally found comparable to those related to autologous bone. For such a reason, this material has been considered for many years the “allogenic standard” for the reconstruction of the orbital floor, until cases of Creutzfeldt-Jakob disease transmission were reported in cadaveric dura mater transplantation [77,78]; since then, autologous or alloplastic materials have been preferred in clinical practice.

The use of demineralised bone implants was alternatively advocated and castigated over the last two decades. Neigel and Ruzicka [27] reviewed the use of this material in the context of orbital floor repair and concluded that it induces osteoconduction, resembling the behaviour of autologous bone graft, and induces the differentiation of mesenchymal cells into chondroblasts. However, recent studies showed that demineralised bone graft exhibits poor mechanical properties to ensure adequate support to the surrounding host tissues: Sallam et al. used demineralised human bone sheets (thickness within 100-300 µm) in 12 patients and found that this form of material is unsuitable when enophthalmos exists and the graft might be too weak to support orbital contents [75].

A factor that often discourages the use of allografts is their high resorption rate, which is statistically higher than that observed with autologous implants [28].

4.3. Xenografts and animal-derived materials

Occasionally, transplant materials from donor animals have been also used. In the last 1980s Webster [79] proposed the use of lyophilized porcine dermis and found this material suitable for orbital floor repair. More recently, Morax et al. [80] implanted bovine heterologous bone in a series of 20 patients and found it suitable in the repair of orbital fractures: the material demonstrated to be safe and no evidence of biological incompatibility, inflammation or infection was detected in all cases.

In other fields of the broad world of bone reconstruction, however, the use of xenografts was sometimes associated to worrisome complications, such as disease transmission, severe immunogenic response and unpredictable resorption rates, usually higher than that of autologous bone. All these factors have discouraged the use of animal grafts in recent years, also considering that a wide range of other materials and implant options are available to surgeons.

If only a small linear fracture (< 5 mm) is found by surgeon after orbital exploration, a thin sheet of gelatin (commonly called “gelfilm”) can be placed over the defect site to prevent scarring of orbital tissue into the fracture line [81-84]. Gelatin is prepared by partial hydrolysis of collagen from animal tissues such as skin and bones; specifically, pigskin gelatin has been used for many decades in general surgery and is commercially available to surgeons in form of sheets of various width (generally from 1 to few mm²) and thickness (generally within 0.5-1 mm). In the field of orbital floor repair, gelatin has been associated to relatively rare clinical complications [83]. Collagenous mesh was also successfully used to repair orbital floor fracture in children without postoperative complications [85].

In the context of xenografts, it is interesting to mention a recent study by Costa et al. [86], who tested bovine sclera as a barrier material avoiding fat and eye muscle herniation to maxillary sinus from surgically-induced orbital floor fractures in an animal model (18 rabbits). The standard bony defect, made in the left infra-orbital border of each animal, was filled either with bovine sclera (9 rabbits) or silicone sheet (control group of 9 rabbits). Animal with bovine sclera showed severe inflammatory reaction at 30 days, moderated reaction at 45 days and absence of inflammation at 60 days, whereas the group receiving silicon implants exhibited mild inflammatory reaction at 30 days and no inflammation at 45 and 60 days. Bovine sclera was considered by the authors biocompatible (inflammatory reaction disappeared in 60 days) and suitable for orbital floor repair, as it was not reabsorbed, ensured an adequate “barrier effect” and allowed partial bony regeneration.

5. Bioceramics

5.1. Hydroxyapatite and other calcium phosphates

Hydroxyapatite (HA), due to its chemical and crystallographic similarity to bone mineral, is an excellent material for bone defects repair [87]. Since the early 1990s, HA and carbonated apatite cements are commercially available as mouldable bone substitutes in the broad field of craniofacial reconstruction [88-91]. Mathur et al. [92] reported an interesting overview on the use of HA cements in the context of craniofacial surgery, including orbital floor repair.

HA was also tested in form of porous blocks (scaffolds) [93-95]; custom-made HA implants can be fabricated by computer-aided design and computer-aided machinery (CAD-CAM) from data obtained through CT, which provided a high anatomic accuracy. Orbital HA implants are generally considered safe and an excellent alternative to autologous grafts and synthetic materials [96], but problems of brittleness can occur.

In an extensive study on 405 patients reported by Nam et al. in 2006 [97], the clinical outcomes associated to the use of coral-derived HA (Biocoral[®]) (191 cases) and porous polyethylene (214 cases) implants were compared in detail. Postoperative enophthalmos was statistically more frequent in HA-treated patients in comparison to patients treated with porous polyethylene; no other significant differences in postoperative outcomes between the both groups were highlighted.

HA was also used for manufacturing commercially marketed HA/polyethylene composite implants (see the sect. 8).

Recently, porous biphasic β -tricalcium phosphate (β -TCP)/HA plates (weight ratio β -TCP/HA = 77 : 23) were implanted in cats as orbital implants [98]. These scaffolds were highly biocompatible and did not elicit any kind of adverse postoperative complications; furthermore, their porous network (mean pores size $\sim 198 \mu\text{m}$) allowed fibrovascular tissue in-growth inside the implant, thereby increasing its stability *in situ*.

5.2. Bioactive glasses

As first demonstrated by Hench and co-workers in the early 1970s [99], bioactive glasses exhibit the unique property to bond to bone stimulating new bone growth. They are excellent materials for bone substitution and have been extensively investigated over the years in form of dense implants, powders or porous scaffolds by several researchers worldwide [100-104]. To the best of the author's knowledge, only one research group affiliated to Turku University Hospital (Finland) has investigated the potential of bioactive glasses in the context of orbital fracture repair [105-107].

In 2000, Kinnunen et al. [105] compared the use of bioactive glass implant with conventional cartilage grafts for the repair of orbital floor defects after trauma in 28 patients operated from 1991 to 1995. None of 14 patients treated with bioactive glass showed any evidence of implant-related postoperative complications; in addition, their clinical outcomes (1 case of infraorbital nerve

paraesthesia and 1 case of entropion) were better than those the cartilage group (3 cases of diplopia, 2 case of infraorbital nerve paraesthesia and 1 case of enophthalmos).

One year later, Aitasalo et al. [106] reported a retrospective study of 36 patients operated from 1995 to 1999: the bioactive glass implants did not cause a foreign body reaction in the bone or soft tissue and no infection, haemorrhage and implant resorption/displacement/extrusion were seen after 1-year follow-up; one implant needed to be removed due to persistent diplopia after 3 months of implantation. CT investigations qualitatively demonstrated new bone growth around the implanted material.

In 2008, the same research group reported the results obtained after implanting bioactive glass plates in 49 patients operated from 1998 to 2001 [107]. Glass plates were brittle, rigid and cannot be moulded, shaped, or fixed with screws by the surgeon. Therefore, the main challenge in using such implants in orbital reconstruction was selecting the proper plate size and shape compatible with the bone defect (Fig. 3b). To address this issue, a specific stainless steel prototype template was used to guide selection of the correct glass plate which, once implanted into the orbit, fitted to the surrounding orbit bone defect margins and anatomy. With this method, the glass plate covered the entire orbit bone defect, thereby ensuring proper positioning of the plate in the orbit. After postoperative follow-up of 2 years, no signs of implant-related infection, extrusion or displacement were assessed; furthermore, the implants did not cause any foreign body reaction and only a minor resorption was found on the margins of the glass plates; new bone formation on glass surface was also observed.

From the data reported in this recent study, bioactive glass plate actually appears to be a promising and reliable implant for orbital floor reconstruction: it is slowly biodegradable, bioactive and biocompatible; in addition, if the implant is carefully selected, it allows the achievement of excellent functional and aesthetic results.

6. Metals

6.1. Titanium

Since many decades, titanium has been successfully and extensively used in orthopaedics and dentistry for manufacturing bone screws, joint endoprotheses and dental implants [108,109], as well as in the field of craniofacial reconstruction and orbital floor repair [54,110-118]. Titanium is highly biocompatible and thanks to its physico-mechanical properties is an ideal candidate for the reconstruction of bone defects requiring substitutes with high rigidity and strength. An attractive feature of titanium is its ability to be incorporated in the surrounding tissues and to osteointegrate [112]. Titanium mesh seems to be particularly suitable for repairing large orbital fractures [54,113,116]. In an extensive case report on 55 patients Gear et al. [113] used a titanium mesh to repair orbital defects larger than 2 cm and reported the achievement of good functional results together with a minimal risk of infection after 44 months of follow-up.

Titanium safety was particularly emphasized in some studies that reported no or minimal postoperative infections in patients treated with titanium implants [56,110,113].

In 2003, Ellis and Tan [56] presented an interesting study to evaluate the adequacy of internal orbital reconstruction in pure blowout fractures using either cranial bone grafts or titanium mesh implants in 58 patients. For this purpose, preoperative and postoperative CT analysis was performed in all patients. Although there was a great individual variability and both materials could be successfully used, the authors observed that the orbits reconstructed with titanium mesh showed better overall reconstructions than those reconstructed with bone grafts.

Although the majority of reports showed that the use of titanium in orbital surgery can lead to highly satisfactory results, the occurrence of serious postoperative clinical complications was occasionally reported. Schubert et al. [112] implanted large segments of titanium mesh in 8 patients to reconstruct orbital and midface defects with direct communication between the mesh and nasal-oral-pharyngeal area and paranasal sinuses: biopsy examination at 3 months revealed incorporation

of the titanium with fibrous soft tissue covered by mucosal type epithelium and an acute inflammation that evolved into a mild, chronic state after 31 months.

It has been also underlined that titanium, even if incorporated in the surrounding tissue, is a non-absorbable material and, therefore, it cannot be replaced by new soft or bone tissue and will remain *in situ* indefinitely, causing possible late side effects (infection, implant corrosion, toxicity due to metal ion release [108,109,119]).

Another non-negligible disadvantage of titanium implants, especially for custom-made devices, is the high cost [114,115]. However, Kozakiewicz et al. [117] demonstrated that it is possible to make relatively inexpensive anatomical models of patient's orbit on the basis of CT data and rapid prototyping techniques; such models are suitable templates to shape the titanium mesh and to aid the correct implant placement during surgery (Fig. 3c). Furthermore, Lieger et al. [118] recently developed a financially viable CAD/CAM technique for manufacturing titanium implants to be used in orbit reconstruction surgery, obtaining excellent clinical outcomes.

6.2. Cobalt alloys

Cobalt-based alloys have been used for decades in orthopaedic surgery and dentistry due to their high resistance to corrosion. The most commonly used cobalt alloy is Vitallium[®], with typical weight composition of 60.6% Co, 31.5 Cr, 6.0 Mo, 1.9% residuum (Si, Mn, C) [120].

To the best of the author's knowledge, only one case report about the use of this alloys for orbit repair is available in the literature. In 1991, Sargent and Fulks [121] reconstructed 66 internal orbital defects of 54 patients with Vitallium[®] meshes: there were no postoperative orbital infections and none of the implants required removal. The authors found the material to be well-tolerated by tissues, suitable for treating large orbital defects and recommended its use in the clinical practice.

As shown by Sullivan et al. [122], Vitallium[®] meshes produces significant artifacts on both CT and MRI scanning, which makes it very difficult to detect orbital pathologies. This drawback and the

increasing availability of other effective materials are perhaps the reason why cobalt alloys have not been further investigated for orbital surgery applications.

7. Polymers

7.1. Permanent implants

7.1.1. Silicone

Silicone has been extensively proposed for almost 50 years as a suitable material for various surgical applications due to its attractive properties including biological/chemical inertness, flexibility, ease of handling and low cost. In retinal detachment surgery, for instance, silicone elements for scleral buckling are the unique scleral implants approved for clinical use and available on the market worldwide [123].

In 1963, silicone was introduced by Lipshutz and Ardizzone [124] in the management of orbital floor fractures. Since then, the use of silicone sheets (commercially named Silastic[®], and hence commonly referred to as “silastic” foils) for orbital floor surgery was alternatively advocated and castigated and this controversy still lingers on [125].

In 2010, Prowse et al. [126] conducted a detailed retrospective review of 81 patients who had orbital floor reconstruction from 1995 to 2007 and compared the performance of silicone implants (58 patients) with that of non-silicone ones (autografts, titanium mesh, resorbable plates) materials (23 patients). Statistically significant advantages were found in the silicone group if compared to the other one, especially in the number of patients with palpable implants (24% vs. 63%), without any postoperative complaints (67% vs. 32%), or requiring subsequent surgery for complications related to their implants (5% vs. 23%). Therefore, the authors concluded – in good agreement with the majority of surgeons – that the appropriate use of silicone implants for orbital floor

reconstruction can lead to good results, with low complication rates including an acceptably low rate of infection and extrusion, as well as high patient satisfaction. The good *in vivo* behaviour of silicone was commonly attributed to its excellent biochemical inertness and to the fact that a smooth collagenous capsule forms around the material, decreasing the chance of later infection and migration of the implant.

However, over the years some reports described an unacceptable incidence rate of various implant-related complications including infraorbital cysts formation, infection, extrusion and implant displacement [127-130]. The occurrence of all these problems was described in a detailed study by Laxenaire et al. [131] who monitored a group of 137 patients receiving silicone implants; 19 cases required implant removal. In this study, the authors considered the formation of a fibrous capsule around the implanted material as a risk factors for the development of cysts, fistulas and infections in the implant surroundings. This was also partially attributed to the fact that silicone does not bond either to soft tissues or bone [132].

As reported by Morrison et al. [133], the majority of silicone-related complications generally occurs in the early postoperative period and the chance of complication decreases with longer asymptomatic period. Long-term complications were also occasionally reported: Brown and Banks [134] documented the late extrusion of a silicone implant through facial skin in 3 patients after 10, 16 and 17 years of implantation, respectively, and Miyasaka et al. [135] recently presented a case of one patient suffering from chronic infection, persistent pain and diplopia, and therefore requiring implant removal after 28 years of implantation.

7.1.2. Polyethylene

Porous ultra-high density polyethylene (PE), marketed under the commercial name of Medpor[®] (Porex Surgical, USA), has been successfully used for almost 20 years in the surgical management of orbital defects worldwide. Sheets of various size and thickness (typically within 0.4-1.5 mm) are

commercially available, and they can be easily adapted by surgeons to fit the needs of each case (Fig. 3d). The presence of pores promotes tissue in-growth and implant vascularisation and reduces foreign-body reactions and capsule formation.

In 1993, Romano et al. [136] first reported the use of porous PE sheets for repairing facial fractures in 140 patients: the material could be easily cut and contoured according to specific surgical needs, allowed soft tissue in-growth and did not elicit adverse reaction, except for the case of one patient who required implant removal due to infection.

Dougherty and Wellisz [132] compared the tissue reactions induced by porous PE plates and silicone sheets in an animal model (New Zealand rabbits): silicone was encapsulated in fibrous tissue, whereas PE exhibited soft and vascular tissue in-growth after 1 week of implantation. Fibrovascular tissue in-growth in porous PE sheets implanted in human patients was recently investigated in detail by Patel et al. [137], who reported an excellent integration of the synthetic implant with the host tissues.

Recently, Lupi et al. [138] used porous PE sheets for orbital floor reconstruction in both posttraumatic (27 cases) and postoncologic (5 cases) patients. There were no cases of implant migration, extrusion or enophthalmos; only diplopia persisted in 2 patients after 6 months of follow-up. The implant was considered safe and represented a stable platform for orbital soft tissues growth; in addition, with respect to other alloplastic materials, porous PE was deemed to be more suitable in the case of large defects requiring an extensive support.

In a comparative study, Wang et al. [116] considered porous PE, together with titanium mesh, the ideal material to be used for orbital floor repair. Perforated PE sheets were found particularly suitable for repairing large defects of the orbital floor [55,116].

Even if the clinical outcomes after implantation of porous PE implants were generally good, some authors reported a non-negligible complication rate associated to the use of such material [139,140]; Fialkov et al. [129] specifically registered a higher infection rate associated to porous PE with respect to other alloplastic implants.

7.1.3. Polytetrafluoroethylene

Polytetrafluoroethylene (PTFE), being biologically and chemically inert, non-antigenic, sterilizable via autoclave and easily mouldable to conform to various solid shapes, is an ideal implant biomaterial. At present, expanded PTFE (ePTFE) is primarily used in abdominal and vascular surgery, but it was also proposed in the context of ophthalmic surgery to repair posttraumatic orbital floor defects. In 1990, Breton et al. [141] successfully used ePTFE (Gore-Tex[®]) in 30 cases of orbital fractures in presence of limited loss of bone (defect size < 1.5 cm). In 1994, Hanson et al. [142] implanted 1-mm thick Gore-Tex[®] sheets in sheep and found the material very suitable for orbital floor repair: specifically, ePTFE provided stability to surgically-created enophthalmos and caused essentially no foreign body reaction. More recently, Elmazar et al. [96] implanted ePTFE grafts reinforced with fluorinated ethylene propylene (FEP-ePTFE) in cats; specifically, the efficacy and biocompatibility of ePTFE and FEP-ePTFE were compared to those of HA and autogeneous bone graft for reconstructing the orbital floor. ePTFE and FEP-ePTFE were malleable enough to be contoured during defect repair and strong enough to support the orbital contents; minimal inflammatory response was reported, and as healing progressed a growth of host tissue into the material was noted, which augmented the stability of the implant avoiding the risk of extrusion.

7.1.4. Nylon

To the best of the author's knowledge, the use of nylon in orbital floor surgery is relatively recent. In 2007, Majmundar and Hamilton [143] reported preliminary clinical experiences involving the repair of limited orbital floor fracture by using smooth nylon sheets (SupraFOIL[®], medical grade nylon 6). One year later, Nunery et al. [144] reported the excellent clinical outcomes obtained after implanting a single 0.4-mm thick nylon foil (Supramid[®], medical grade nylon 6) in 102 human

patients: in 101 orbits, normal globe position and full extraocular motility without diplopia was accomplished; one orbit had persistent enophthalmos, thereby requiring a second procedure. In 2008, Park et al. [145] reported a retrospective study of 181 patients having undergone repair of orbital fractures by using nylon sheets (SupraFOIL[®]) from 1995 to 2003. The authors found the smooth nylon foil implant to be safe and effective in orbital fracture repair. The low rate of complications – 1 patient had an acute postoperative orbital haemorrhage and 2 patients had late orbital infections – was also deemed to be related to implant fixation: a titanium screw secured just posterior to the orbital rim could decrease long-term complications by providing more stability with respect to implants left without fixation.

Nylon sheets seem to be a promising alternative to other alloplastic materials (e.g. silastic foils), at least in uncomplicated orbital floor fractures.

7.1.5. Hydrogels

In the context of polymeric biomaterials, it is interesting to mention the valuable study reported by Betz et al. in 2009 [146]. The authors proposed a tissue engineering approach for orbital bone repair based upon a cyclic acetal biomaterial formed from 5-ethyl-5-(hydroxymethyl)- β,β -dimethyl-1,3-dioxane-2-ethanol diacrylate (EHD) and poly(ethylene glycol) diacrylate (PEGDA), that can be eventually fabricated into an EH-PEG hydrogel by radical polymerization. EH-PEG hydrogels were implanted into 8-mm rabbit orbital floor defects; experimental groups included unloaded EH-PEG hydrogels and EH-PEG hydrogels containing 0.25 μg and 2.5 μg BMP-2/implant. Unloaded hydrogel was initially bordered by a fibrin clot (7 days) and then by fibrous encapsulation (28 days); BMP-2 loaded EH-PEG hydrogels, independent of concentration, were surrounded by fibroblasts at both time points. Histological analysis also demonstrated that significant bone growth was present at the 2.5 μg BMP-2/implant group at 28 days.

In the author's opinion, this work is very important both in the context of orbital floor repair and in the broader field of bone tissue engineering, as it demonstrates that the EH-PEG construct is a viable option for use and delivery of BMP-2 *in vivo*. The great potential of this tissue engineering approach was also highlighted in a valuable recent review [31]. However, it cannot be ignored that the amount of BMP needed for humans, compared to rabbits or rodents, is significantly higher, which makes the use of BMPs very expensive.

7.2. Absorbable implants

Absorbable polymers have been widely used for more than 30 years in many fields of surgical practice, and in the 1990s absorbable plate-screw systems have been commercially introduced as an efficient device for fixation of fractures in the cranio-maxillofacial region [147], as well as in the field of orbital surgery [148].

Absorbable synthetic polymers exhibit interesting features, as they offer more controllable and predictable absorption kinetics than those of biological grafts and can be easily tailored to obtain an implant of desired size and shape [149]. Comprehensive reviews dealing with the properties, biodegradability and surgical applications of resorbable polymers are available to interested readers [150-152].

7.2.1. Poly(lactic acid)

The first clinical use of poly(lactic acid) (PLA) in the management of orbital floor fractures was reported in 1972 by Cutright and Hunsuck [153], who demonstrated its suitability as an alternative to biological materials.

In 1990, Rozema et al. [154] tested 0.4-mm thick concave poly(L-lactide) (PLLA) implants (Fig. 3e) in goats having an artificial defects in the bony floor of both orbits. After 19 weeks of

implantation, new bone formation was observed, and after 78 postoperative weeks the new bone had fully covered the PLLA plate on the antral and orbital side; no inflammation and/or extrusion were reported. At 5 years of follow-up, no complications related to the PLLA orbital floor implant were observed.

More recently, De Roche et al. evaluated in a couple of studies the suitability of poly(L/DL lactide) (P(L/DL)LA) for the reconstruction of orbital defects in sheep [155,156]. In their first report in 1998, they compared polydioxanone and P(L/DL)LA membranes for the reconstruction of large orbital wall defects in a long-term experiment over 1 year, and found that P(L/DL)LA implants alone exhibited the best performance as compared with combinations involving autogenous bone grafts and titanium miniplate fixation [155]. In 2001, the same research group reconstructed large bilateral orbital wall defects in sheep by using (i) P(L/DL)LA microporous 0.5 mm-thick membranes without further support on one side, and (ii) 0.25 mm-thick microporous membrane supported by solid polylactide buttresses and stabilized by polylactide dowels on the opposite side [156]. After 12 months, a symmetrical reconstruction of the normal anatomy of the orbits was found in CT and X-ray examinations; in contrast, histological investigations revealed massive foreign body reactions around degrading buttress implants and dowels especially.

These results [156] are partially consistent with those obtained by Bergsma et al. [157], who observed a very mild tissue reaction around the implants and limited mass loss of the material after 5 years of implantation, but is consistent with the findings of another study in which PLLA plates and screws were used for treating zygomatic fractures in human patients [158].

Cordewener et al. [159] evaluated the long-term clinical results of PLLA implants in orbital floor defects by using MRI. After 78 months of implantation, none of the patients exhibited clinical complications (diplopia, restriction of ocular motility) or bone/soft tissue abnormalities at the operation site, and therefore the authors recommended the use of PLLA as a safe and successful implant material for repairing orbital floor defects in humans.

Bergsma et al. [160] observed tissue swelling as a long-term complication following PLLA implantation for orbital floor repair, and suggested that residual PLLA particles (i.e. the remnants of non-degraded material) could be not fully biocompatible.

In 2001, Balogh et al. [161] reported a study on 18 patients with fractured orbits treated with PLA implants. No postoperative complications were observed at 24 to 43 months of follow-up, except for a transient eyelid inflammation that resolved spontaneously. The authors also underlined that the material could be easily remodelled once heated, thereby allowing a precise adaptation of the implant to the orbital structures.

Very recently, Lieger et al. [162] implanted triangle form P(L/DL)LA plates in 46 patients to restore orbital floor or wall defects. None of the patients showed clinical foreign-body reactions. There was no evidence of infection in all patients; diplopia was seen in 6 patients 3 months postoperatively but normalized in 5 patients at 6 months; mild enophthalmos was seen in 2 patients postoperatively at 1 year. No sagging of the reconstructed area was found on CT evaluation.

7.2.2. Poly(glycolic acid)

In 1994, Hatton et al. [163] performed *in vitro* tests on PGA membranes in order to evaluate their suitability as a materials for orbital floor repair. After 2 weeks of culture, osteoblasts penetrated the PGA membrane and deposited calcified collagenous bone-like tissue within the material as it underwent progressive resorption. One year later, PGA membranes constituted by woven polymeric fibres were successfully implanted in 12 human patients by McVicar et al. [164]. PGA was found highly suitable for orbital floor repair as it did not induce long-term infection or migration, which is sometimes associated to non-absorbable alloplastic implants.

However, as PGA is known to lose its structural integrity by ~2 months of implantation and to be resorbed almost totally (> 90%) by ~9 months [165], the researchers' attention was progressively

drawn by materials having slower kinetics of degradation, such as PLA/PGA composites, that are able to ensure adequate structural and mechanical support postoperatively at the implant site.

7.2.3. PLA/PGA implants

In the two last decades, several studies widely demonstrated the suitability of PLA/PGA implants for craniofacial reconstruction surgery [148,149,166], as well as for orbital floor repair (Fig. 3f). Since the mid 1990s, resorbable PLA/PGA plate-screw systems began to be marketed worldwide and are currently available for clinical use.

In 2001, Hollier et al. [167] used a resorbable PLLA/PGA mesh plate (Lactosorb[®]) in 12 patients with large orbital defects ($> 1 \text{ cm}^2$). The authors found some unsatisfactory results and concluded that resorbable meshes are acceptable implants for orbital floor repair only in selected patients, suggesting to treat large floor defects by non-absorbable alloplastic materials and to avoid the placement of the mesh over the infraorbital rim for preventing possible local inflammatory reaction. One year later, 5 patients with orbital defects were treated using the same materials via a transantral endoscopic approach and no graft-related complications were reported.

In 2007, Tuncer et al. [168] reported a retrospective study about the use of Biosorb[®] PDX plates (Bionx Implants, Finland), with weight ratio PGA/PLLA = 4, for the reconstruction of orbital floor in 17 patients: in all cases, no evidence of postoperative infection or diplopia was seen. One patient required reoperation due to implant displacement, but no other problems were reported after 15-month follow-up. The resorbable mesh system was able to maintain the orbital contents against herniation forces during the initial phase of healing and was bioabsorbed through natural processes after its support was no longer needed.

Although PLA/PGA composite resorbable meshes have many advantages, postoperative inflammation may occur, as already observed for PLA implants [156,158,160]. Uygur et al. [169] recently highlighted that a considerable complication related to such implants is local inflammatory

reaction along the infraorbital rim, and patient's ocular motility may be restricted because of the formation of fibrotic bands passing through the holes of the resorbable mesh. These implants are generally considered an excellent option in children, who still have a developing skeleton [170].

7.2.4. Polydioxanone

Polydioxanone (PDO) is commonly adopted in the clinical practice as material for resorbable sutures that disappear ~6 months postoperatively, but its use as an orbital implant is also documented. There is a controversy about its use in orbital floor surgery: some authors associated PDO to unacceptable clinical outcomes [171-173], but in other reports PDO performance was found comparable to that of other alloplastic materials [84,174]. For this reason, at present PDO is rarely used as-such, but rather in combination with polyglactine 910 (Ethisorb[®]) (see the sect. 7.2.5.).

Merten and Luhr [171] evaluated PDO sheets for repair of experimentally-created orbital defects in pigs. The implants were completely absorbed after 29 weeks, replaced by fibrous tissue and coated by mucosa on the sinus side. Hydrolytic breakdown products of PDO implant elicited irritation in the surrounding tissue evoking a secondary foreign-body reaction.

Kontio et al. [172] treated orbital fractures in 16 patients using PDO implants and reported an increasing rate of enophthalmos as follow-up increased, reaching 37.5% after 36 weeks of implantation. In addition, 4 cases of fibrotic sinuses occurred and 1 patient required the removal of implant fragments after 16 weeks due to inflammation.

Baumann et al. [173] reconstructed 31 orbits by using PDO sheets and reported unsatisfactory results, as 7 patients developed enophthalmos, postoperative diplopia persisted in 10 patients after 6 months of implantation and 2 patients required implant removal due to haematoma and extrusion.

In a comparative study reported by Jank et al. [174], orbital defects were corrected by using different implant materials, including PDO (81 patients), lyophilized dura mater (120 patients) and Ethisorb[®] (Johnson & Johnson, USA) (136 patients) (see also the sect 7.2.5.). As regards the long-

term complications, no statistical significant differences among the three groups were observed; the clinical outcomes were good, no revision surgery were required and a low enophthalmos rate (~1 %) was reported also for PDO implants, apparently in contrast to the data reported by Kontio et al. [172] and Baumann et al. [173].

More recently, Becker et al. [84] considered PDO foils very suitable to repair small orbital fractures (< 2 mm), whereas the use of non-absorbable materials was suggested for large defects.

7.2.5. Polyglactine 910/PDO implants

Polyglactin 910/PDO (PG910/PDO) flexible membranes are marketed worldwide under the commercial name of Ethisorb[®] (Johnson & Johnson, USA) for several years; PG910 (commercial name: Vicryl[®]) is a PLA/PGA copolymer with weight ratio PLA/PGA = 1 : 9 and it is commonly used as a material for making surgical sutures.

In 1999, Piotrowsky and Mayer-Zuchi [175] first reported a retrospective study on the treatment of orbital lesions in 85 patients operated from 1988 to 1996 by using PG910/PDO patches. Orbital reconstruction was considered very good in 71 patients even in severely injured cases; therefore, the material was considered appropriate for orbital surgery and appeared as a valuable alternative to autologous bone especially for the treatment of large defects, thanks to the easiness of contourability.

In 2003, Jank et al. [174] reported an interesting comparative study with the aim to investigate whether PG910/PDO membranes showed better long-term results with regard to diplopia, bulbous motility and exophthalmos/enophthalmos compared to the use of lyophilized dura mater patches and PDO sheets. The use of PG910/PDO patches led to very good clinical outcomes and resulted in a significantly lower incidence of exophthalmos 3 months after surgery compared to PDO; however, after 24 months of implantation no statistical difference among the three groups was

observed (2% exophthalmos, 1% enophthalmos, 4% reduction of bulbous motility and 3% diplopia were found in all three groups).

In 2005, Buchel et al. [176] reviewed the charts of 87 patients who underwent orbital floor fracture reconstruction by Ethisorb[®] membrane (Fig. 3g); 3 patients had permanent implant-related postoperative complications (diplopia, enophthalmos) that in 2 cases required revision surgery. The authors concluded that the PG910/PDO patch was very effective in the repair of small-to-mid orbital floor defects (up to 4 cm²).

8. Composites

HA-reinforced high-density composite (HAPEX[™]) has been marketed and successfully adopted for several years as a bone replacement material in the context of orbital floor repair [177,178] and middle ear prostheses [179]. Zhang et al. [180] recently suggested the use of HA/PE composite material as a skull implant for the repair of cranial defects. The combination of stiff, osteoinductive but brittle HA with low-modulus, tough and bioinert PE produces a biomedical composite exhibiting attractive properties for bone substitution. A detailed overview of the clinical use of HA/PE composites for bone reconstructive surgery was recently reported by Tanner [181].

In the mid 2000s, a titanium/PE composite implant (Medpor[®] Titan[™], developed by Porex Surgical, USA) was developed to overcome specific drawbacks of bare titanium meshes and implanted with good clinical outcomes [182,183]. When cut, traditional titanium mesh may exhibit many sharp points and edges that can make its insertion quite difficult. A thin coating of high-density PE placed on both sides of a titanium mesh (Fig. 3h) minimizes sharp edges even when the implant is cut. The titanium mesh is radio-opaque, making the implant visible on radiographs or CT scans. Furthermore, this new device allows the surgeon to bend and contour a thin implant material to the desired shape while providing the strength usually associated with a much thicker traditional

Medpor[®] implant. An analogous device (SynPOR[®]) was also recently developed by Synthes, another medical implant company.

In the last decade, other innovative composites were experimentally proposed for orbital floor reconstruction, but, to the best of the author's knowledge, none of them has been definitely approved for clinical use.

In 2010, Asamura et al. [184] proposed the use of a periosteum/polymer complex produced by joining periosteum to a HA/PLLA/poly(caprolactone) (PCL) sheet; in this pilot study, autologous iliac crest bone was also implanted in a control group of patients. The anatomical position and movement of the eyeball were normal postoperatively in both groups; therefore, the authors deemed the periosteum-polymer composite as a promising alternative to autologous bone, overcoming the problems of limited autograft availability and possible morbidity at the donor site.

Asamura and co-workers again in 2010 [185] used gelatin hydrogel as a carrier for slow release of BMP-2 in dogs: specifically, they coupled a BMP-2-loaded gelatin sheet with a biodegradable PLA-based foil and grafted this composite into bone defect sites of a canine orbital floor fracture model. Bone structural analysis, carried out by using radiography, histologic examination and CT, showed highly enhanced new bone formation and defect healing at 5 weeks in comparison to the implanted biodegradable PLA-based foil directly saturated with the same amount of BMP-2 (absence of the gelatin carrier for BMP-2). This study shows the great potential carried by controlled release of BMPs in an attempt at improving bone healing and surgical outcomes.

Patel et al. [186] incorporated HA nanoparticles (20-70 nm) within cyclic acetal hydrogels to create nanocomposites that were used to repair surgically-created orbital floor defects in an animal model (rabbits). Preliminary histomorphometric results indicated that the nanocomposite material elicited a positive *in vivo* response in terms of bone growth; however, complete restoration of orbital floor defects were not achieved after 28 days of implantation.

A particular mention should be dedicated to the work of Rohner et al. [187], who tested bone-marrow-coated PCL scaffolds for the reconstruction of orbital defects in pigs. Before implantation,

fibrous PCL scaffolds fabricated by rapid prototyping (porosity ~65 %vol.) were soaked for 30 min in heparinised bone marrow, which was freshly harvested from the iliac crest of the same animal. Histomorphometric results after 3 months of implantation showed that the bone marrow-coated implants induced a significantly higher bone in-growth in comparison with non-coated PCL scaffolds.

9. Overview of comparative studies – does an ideal biomaterial exist?

No generally-recognized consensus exists on the best choice of biomaterials/implants for orbital floor reconstruction, but several options are at surgeon's disposal and available on the market (Table 2). The choice of an optimal material for orbital skeleton repair is influenced by many factors including the specific characteristics of the injury, cost, patient's clinical history and experience/opinion of the surgeon.

It is worth underlining once more that a careful history and physical examination of the patient is vital for the diagnosis of orbital floor fractures and, accordingly, for the choice of a suitable implant material, if required. Axial and coronal CT scans should be obtained in order to discern the extent of the orbital cavity injuries, as well as any other facial fractures that might be present. The two most important characteristics of the fracture to be determined are the size/shape of the damage and whether or not any orbital contents have prolapsed through the fracture into the maxillary sinus. Exhaustive knowledge of all these factors is essential to guide surgeons towards the best choice for each patient.

A valuable resource to help surgeons in selecting the optimal material(s) is provided by useful comparative studies reported in the literature.

To the best of the author's knowledge, the first extensive comparative study on the performance of different biomaterials for orbital floor repair was reported in 1998 by Chowdhury and Krause [28], who concluded that when a blowout fracture with a clinically significant orbital floor defect occurs,

autologous material is preferable for the orbital floor graft. On the basis of his own clinical experience, also in 1998 Kellman [50] suggested that autologous grafts should be generally preferred to alloplastic materials, as he encountered minimal postoperative inflammation and no extrusion of autologous bone. However, Kellman [50] also underlined that bone grafts can undergo resorption, thereby resulting in delayed changes in globe position that may require later revision surgery.

Mathog [51] also agreed with Chowdhury and Krause [28], but he underlined that comparison among the performance of different materials is often difficult, as the majority of reports available in the literature does not address uniformly the indications for surgery, the surgical techniques and the follow-up period of observation.

More recently, Wang et al. [116] implanted shaped autologous bone, titanium mesh and porous PE (Medpor[®]) under the periosteum of the orbital floor in 5, 10 and 6 patients, respectively. Accurate CT scanning was performed to investigate surgical outcomes. All the patients had good results, including significant improvement in appearance and function after surgery, without exhibiting severe permanent complications. The authors suggested that porous PE and titanium mesh can be preferred to autologous bone as they need no extra-surgery for harvesting the material; specifically, titanium meshes are particularly suitable for treating fractures with large defects that were not easy to fix without obvious enophthalmos, and porous PE is recommended when there is a need for restoring the orbital volume.

Ellis and Tan [56] and Al-Sukhun and Lindqvist [53] compared autologous bone with biodegradable mesh and titanium, and suggested to avoid using bone graft due to long operative duration and postoperative graft resorption seen on CT scanning.

In 2003 Elmazar et al. [96] compared the efficacy of ePTFE to that of HA and autologous bone in an animal model (short-hair cats). ePTFE were more easily shapable and countourable than HA or bone, allowed tissue in-growth thereby becoming biologically fixed to the surrounding bony and soft tissues, did not elicit infections and evoked minimal foreign body/inflammatory reaction.

In 2006 Nam et al. [97] reported the clinical outcomes of 405 patients who received HA implants (191 cases) or porous PE (214 cases). Postoperative enophthalmos was statistically more frequent in HA-treated patients in comparison to the patients treated with porous PE; no other significant differences in postoperative outcomes between the both groups were highlighted.

Shetty et al. [54] treated 10 patients suffering from orbital blow-out fractures with different materials and concluded that calvarial graft, titanium mesh and porous PE appear to have equal potential to offer stable and safe reconstruction of the fractured orbital floor.

In a randomized controlled clinical study on 24 patients with orbital floor defects of approximately 1 cm², Becker et al. [84] recently evaluated the use of a collagen membrane compared with a PDO foil. Intraoperative complications occurred neither in the collagen membrane group nor in the PDO group; furthermore, no complications such as infections were observed perioperatively and postoperatively. After 6 months, CT investigations revealed a complete reposition of orbital tissue and even bone regeneration in both groups. Diplopia and infraorbital nerve hypoesthesia were completely reversed after half a year. The authors concluded that relatively small defects (< 1 cm²) of the orbital floor can be successfully restored with a PDO foil or a collagen membrane, whereas larger defects require implants with higher and more prolonged stability (e.g. titanium meshes).

Very recently, Tabrizi et al. [183] evaluated orbital floor reconstruction in 101 patients by using autogenous bone and different alloplastic materials (Medpor[®], Medpor[®] Titan[™], titanium mesh and resorbable plates). The authors concluded that autologous bone graft elicited minimal postoperative infection and was an excellent choice for treating major orbital defects; titanium mesh, Medpor[®] and Medpor[®] Titan[™] provided excellent structural support and could be successfully used in large orbital floor defects; resorbable plates were good alternative materials in pediatric patients.

In a recent study, Ram et al. [55] compared the efficacy of iliac crest grafts (10 patients) and Medpor[®] implants (10 patients). The clinical outcomes were highly satisfactory and almost equal in both groups, and the authors stated that porous PE is a valuable option in patients where harvesting of graft is not feasible.

From the results and suggestions reported in the literature, we can conclude that, at present, an ideal biomaterial does not exist, but the choice of orbital wall implants has to be carefully individualized. Size and shape of the fracture, presence of adequate surrounding stable bone and need for orbital rim reconstruction are all factors that play a crucial role in the decision-making process.

From a general viewpoint, it is worth underlining that today the commonly recognized “gold standard” in reconstructive bone surgery consists in the use of autografts, which involves harvesting the patient’s own tissue from a donor site and transplanting it to the damaged region. Autologous bone causes no immunological problems, but can be collected only in limited amount, and its harvesting can induce death of healthy tissue at the donor site; in addition, problems related to second site morbidity, mismatching in mechanical properties with respect to host bone, and tendency towards resorption may occur. Synthetic biomaterials are a good alternative and allow to overcome these limitations, but at present none of them can be ultimately considered as the ideal option.

10. Summary and indications for material choice

Orbital fractures due to trauma usually ensue in damages to the floor and the medial wall, the thinnest bone in the body. In some cases, surgical treatment is not mandatory and drug therapy can be recommended, as previously discussed in the sect. 2.2. Clinical indications for fracture repair are the patients’ symptoms and generally include severe diplopia, entrapment of extraocular muscles, large fractures (> 50% of the wall) and enophthalmos greater than 2 mm [2,8,12,17]. If surgical correction is indicated, the surgeon must decide which material to use to repair the defect. As described in detail in the previous sections, the choices at the surgeon’s disposal vary from autologous bone grafts to synthetic implants such as silastic sheets, porous PE and titanium meshes. Each solution accomplishes the twofold goal of covering the bone defect and preventing the prolapse of orbital tissues into the sinus(es). The major issues that mainly weigh in the surgeon’s

decision on what material to use include the damage extension, the evaluation of extrusion and infection rate associated to the different materials, the difficulty of harvesting material (especially for autografts) and the possible risk of foreign body reaction. As the orbital floor is a very complicated structure from an anatomical viewpoint, it is obvious that, unless the material is custom-made by rapid prototyping, it must be easily shapable during operation for optimal results.

Autologous bone is generally recognized by the majority of surgeons as the preferred material for grafting. The drawbacks of using autografts include extra-surgery due to graft harvesting and morbidity at the donor site; the advantage is that, by using the patient's own tissue, the chances of rejection are negligible [28,32].

Synthetic polymeric implants available on the market have shown to be highly biocompatible and to have, generally, small extrusion rates. At present, the most commonly used polymeric implants are silastic sheets and porous PE.

Advantages of silastic sheets are that a smooth collageneous capsule forms around the material, decreasing the chance of later infection and migration of the implant [126,132]. Furthermore, because of its smooth surface, the orbital tissues will not become incorporated into the sheet, thereby decreasing the chance of diplopia associated to fibrovascular tissue in-growth and allowing an easy implant removal in the case of reoperation.

From another viewpoint, however, fibrovascular in-growth – this is the case of porous PE – can be considered an added value, since it ensures the mechanical stability of the implant and decreases the chance of material extrusion [132,137]. Nonetheless, the difference in extrusion rates between silastic sheets and porous PE seems to be clinically insignificant. Pliability is similar, ease of shaping, conforming and placement are comparable and both of them are commercially available in different thicknesses. The use of porous PE can be particularly recommended for treating large defects, since manufacturing companies make products of various shapes and size to conform to the natural orbit dimensions [55,116,138]; for instance, Porex Surgical has developed ½ orbit, ¾ orbit

and whole orbit implants to fit the needs depending on the size of the defect, that may be secondary to trauma or also due to orbital tumour resection.

HA is, at least virtually, a good alternative to polymeric implants due to its crystallographic and compositional similarity to natural bone; however, intra- and postoperative problems – including difficult shapability – related to material brittleness may occur [96].

Titanium mesh can be also used, but it must be fixed to the surrounding and stable bone with screws. Titanium implants are very suitable for treating large fractures or fractures also involving the orbital rim where more reconstruction is needed [54,113,116]. Two issues should be carefully taken into account if titanium is used. The first is that the surgeon, after cutting the mesh to conform it to the shape and size of the defect, must burr down or smooth the resulting sharp edges to avoid abrasion. The second issue is that the titanium mesh will allow a considerable tissue in-growth through its holes; in order to prevent the tissue from “sticking down” to the surface, the implant can be properly covered with another material, such as porous PE sheet, silastic sheet, banked dura mater or pericranium.

A new device has recently become available to allows the surgeon to avoid the above-mentioned hassle with the use of titanium implants. This kind of implant (commercially referred to as Medpor[®] Titan[™] or SynPOR[®]) is a titanium sheet covered on both sides by a thin sheet of porous PE [182,183]. The new design provides a smooth surface on both sides of the implant; after cutting, the sharp edges of the cut titanium are “hidden” by the PE layer, thereby eliminating the need for burring down the edges. This implant can be recommended for the repair of large orbital floor fractures involving the inferior orbital rim.

In summary, autografts, e.g. split calvarial, rib or iliac crest bone grafts, are currently considered the “gold standard” option by surgeons and, accordingly, are the preferred choice. Autologous bone is also particularly suitable when the patient has an extremely large defect [28].

If the use of autografts is not possible, among the synthetic biomaterials silastic sheets and porous PE (Medpor[®]) can be considered a good options for fractures that involve neither the orbital rim nor

the entire wall of the orbit. Porous PE is also suitable to repair mid to large complex or multiple orbital defects. For very large reconstructions (typically $> 4 \text{ cm}^2$), bare titanium mesh, PE-coated titanium (Medpor[®] Titan[™] or SynPOR[®]), or a combination between titanium and nonabrasive material, are recommended. Absorbable plates or sheets (e.g. Lactosorb[®], Ethisorb[®]) are generally preferred in patients with developing skeleton (children) [170]. If only a small linear fracture ($< 5 \text{ mm}$) is found after orbital exploration, a thin sheet of gelatin can be placed over the defect site to prevent scarring of orbital tissue into the fracture line [81-84].

However, it is evident that the criteria for choosing the optimal implant material are rather empirical and, therefore, there is a real need for multicentric, randomized controlled trials using a large sample size to derive definite guidelines and classifications regarding the most appropriate materials for orbital fractures repair. The development in the next few years of a standard protocol to guide the maxillofacial and ophthalmic surgeons in the decision-making process would be very desirable, in order to minimize the possible intra-, peri- and postoperative complications and further improve the patient's life quality.

11. Concluding remarks and promises for the future

The data from existing literature demonstrate that orbital floor reconstruction is often a complex issue and, at present, none of the biomaterials used in clinical practice can be really considered as the ideal one. In the next few years, the development of new biomaterials and implants exhibiting superior performance with respect to the existing commercial solutions would be highly desirable. These new products should be easy to be sterilized and used by surgeons; specifically, the easiness of contouring/tailoring and implantation are crucial issues, since the biomaterial is usually shaped by surgeon during operation, for instance by simple cutting, in order to meet the specific needs of any patient. An ideal material for orbital floor repair should ensure adequate mechanical support to the surrounding tissues and be also resorbable, i.e. able to safely dissolve once it has performed its

function, thereby leaving the body to remodel the tissue to its natural form. Eventually, an optimal biomaterial should be bioactive, i.e. able to promote native tissue regeneration by stimulating cells activity without altering cells physiological metabolism or releasing toxic products in the organism. It is worth underlining that maybe the most critical limitation of the commercially available biomaterials for orbital floor repair is the lack of bioactivity. In such a context, three types of novel biomaterials might have a promising potential to overcome this drawback and be viewed as interesting promises for the future: (i) surface-treated titanium, (ii) photoactive polymers and (iii) bioactive glasses.

Bone-bonding ability of surface-treated titanium was extensively studied over the last decade by several research groups [188-191]. A first approach, involving alkali-treatment of titanium, was developed by Kokubo and co-workers [188,189]: when titanium is soaked in NaOH, a hydrated titanium oxide gel layer containing alkali ions is formed on its surface; this gel can be dehydrated and densified to form an amorphous alkali titanate layer by heat treatment below 600 °C. After soaking in simulated body fluid (SBF), the alkali ions are released from the amorphous alkali titanate layer and hydronium ions enter the surface layer, thereby resulting in the formation of a titanium oxide hydrogel layer. The released Na⁺ ions increase the pH of the SBF and its degree of supersaturation with respect to apatite, and therefore the titanium oxide hydrogel eventually induces HA nucleation on titanium surface. Another approach to induce HA formation on the surface of titanium alloys was recently developed by Ferraris et al. [191], who reported a thermo-chemical treatment including a first acid etching in hydrofluoric acid and a subsequent controlled oxidation in hydrogen peroxide. As extensively demonstrated since the early 1970s [99], the formation of a HA layer is essential to impart bone-bonding ability to the implant. Therefore, the use of surface-treated titanium for orbital floor reconstruction could be a valuable resource to improve the surgical outcomes; however, these implants are permanent and will remain *in situ* indefinitely.

Very recently, Chiono et al. [192] demonstrated that the use of photoactive biocompatible conjugate polymer, such as chitosan-g-fluorescein (CHFL), are able to stimulate HA deposition upon visible

light irradiation. The authors suggested that the use of these polymers in the clinical practice may lead to new therapeutic options in the field of bone and dental repair, exploiting the photoexcitation mechanism as a tool for biomineralization; indeed, this challenging research topic will be worthy of extensive experimental work in the next few years.

As the third promise for the future, bioactive glasses are maybe the most reliable option, as they have been commercialized worldwide for 25 years [102] and already used experimentally for orbital floor repair [105-107]. From manufacturing viewpoint they are very versatile, as they can be synthesized in form of powders, granules or porous scaffolds of various size and shape matching those of the tissue portion that they are aimed at substituting [103]. Custom-made glass-derived scaffolds for orbital floor repair could be fabricated by using rapid prototyping techniques [193-195]. CT- and MRI-derived files can be used as input data for CAD/CAM manufacturing systems in order to produce scaffolds matching exactly the dimensional features of bone defects; in this way, surgery time would be shortened as intraoperative implant shaping by surgeon would be no longer necessary. Glass-derived products can be easily sterilized, for instance by β - or γ -irradiation, without undergoing degradation. Bioactive glasses have also been proven to promote osteogenesis at the implant site, as they can induce stem cells differentiation into osteoblasts and their ionic dissolution products have a direct effect in stimulating bone cells genes towards a path of regeneration and self-repair [104]. If glasses are processed in form of mesoporous materials, they can also easily incorporate specific molecules, for instance anti-inflammatory drugs, to be released *in situ* postoperatively to elicit an appropriate therapeutic effect [196-198]. In this context, a valuable resource towards the development of an ideal biomaterial for orbital floor repair can come from bioactive glass/polymer composites: the mechanical properties, degradation rate and bioactivity of the final material can be tailored by choosing different glass/polymer combinations and by acting on the interactions between organic and inorganic phases [199]. For instance, glass/polymer interactions at the macro-scale can be achieved by simple blending, but more intimate interactions at the nanoscale can be obtained only by using more complex processing

methods, such as sol-gel techniques [200]. The use of polymeric hydrogels for manufacturing composite materials can also have a great potential in imparting drug-release ability to the final implant [146]. Very comprehensive reviews dealing with bioactive glass, glass-ceramic and glass/polymer composite scaffolds for bone repair have been recently published and are available to interested readers [201-203].

The three above-mentioned “promises for the future” owe their attractive features primarily to material properties. In addition, it is worth mentioning a fourth option that was already pointed out in a recent work by Betz et al. [31], who recommended the use of tissue-engineered polymeric constructs, such as BMP-loaded hydrogels, in the field of orbital floor and general maxillofacial reconstruction thanks to their unique regenerative potential. In fact, BMPs can promote bone regeneration, thereby accelerating orbital injury healing, and furthermore the BMP-accelerated bone in-growth inside the implant can contribute to overcome the problems related to polymeric matrix integrity over time; this latter advantage is particularly useful if the polymer should be absorbable. The prospects of manufacturing and making commercially available this tissue-engineered product is challenging and could constitute an outstanding advance towards a truly ideal biomaterial; however, some problems and limitations associated to the release of biologically active growth factors, such as BMPs, cannot be ignored. As extensively discussed by Haidar et al. [204,205] in a couple of recent reviews on this topic, the clinical efficacy of BMPs strongly depend on the carrier system used to ensure a sustained, multistep and prolonged delivery of adequate protein concentrations to the desired site of tissue repair or restoration; the foremost limitations include the rapid diffusion of osteogenic protein away from the site of application and the loss of its bioactivity, resulting in suboptimal local induction and thus incompleteness or failure of bone regeneration. Hence, the design of a safe and effective delivery system that immobilizes growth factors, controls their release at therapeutic levels over proper periods of time for bone induction, has release kinetics calibrated to local requirements and, ultimately, degrades without eliciting unexpected side effects still remain a challenge. However, promising results have been very recently reported by Betz et al.

[146] and Asamura et al. [185] in animal models of orbital floor defects. Eventually, a non-negligible drawback associated to biologically active growth factors is their high cost, which could further prevent their use in the common clinical practice.

With respect to currently available commercial products for orbital floor surgery (Table 3), the previously described four types of innovative biomaterials/implants are expected to carry significant added values in terms of biocompatibility, bioactivity and bone regeneration ability, together with the potential of acting as matrices for drug therapy *in situ*. In the next few years, an ever increasing synergy among materials scientists, chemists, physicists, biologists, surgeons and researchers of medical implant industries would be desirable in an attempt to select and market more suitable and cost-effective biomaterials for orbital floor surgery, in order to further improve the patient's life quality.

Acknowledgements

Dr. Daniela Dolcino, Head of the Ophthalmology Ward at “Ss. Antonio e Biagio” Hospital of Alessandria (Italy), is gratefully acknowledged for strongly stimulating and supporting the author in writing this article.

Conflict of interest

The author has no conflict of interest with one or more companies whose products are mentioned in the manuscript.

Note of the author

This article is dedicated to Prof. Giuseppe Heer, great ophthalmologist and Head Emeritus of the Ophthalmology Ward at “Maria Vittoria” Hospital of Turin (Italy), on occasion of his 60 years of clinical activity and 85th birthday.

References

- [1] Ng P, Chu C, Young N, Soo M. Imaging of orbital floor fracture. *Australas Radiol* 1996;40:264-8.
- [2] Chang EW, Monolidis S. Orbital floor fracture management. *Facial Plast Surg* 2005;21:207-13.
- [3] Smith B, Regan WF Jr. Blow-out fracture of the orbit: mechanism and correction of internal orbital fracture. *Am J Ophthalmol* 1957;44:733-9.
- [4] Tenzel RR, Miller GR. Orbital blow-out fracture repair, conjunctival approach. *Am J Ophthalmol* 1971;71:1141-2.
- [5] Walter WL. Early surgical repair of blowout fractures of the orbital floor by using the transantral approach. *South Med J* 1972;65:1229-43.
- [6] Sachs ME. Orbital floor fractures: the maxillary approach. *Adv Ophthalmol Plast Reconstr Surg* 1981;6:387-91.
- [7] Wilkins RB, Havins WE. Current treatment of blow-out fractures. *Ophthalmology* 1982;89:464-6.
- [8] Patel BC, Hoffman J. Management of complex orbital fractures. *Facial Plast Surg* 1998;14:83-104.
- [9] Strong EB, Kim KK, Diaz RC. Endoscopic approach to orbital blowout fracture repair. *Otolaryngol Head Neck Surg* 2004;131:683-95.
- [10] Farwell DG, Strong EB. Endoscopic repair of orbital floor fractures. *Otolaryngol Clin North Am* 2007;40:319-28.

- [11] Ducic Y, Verret D. Endoscopic transantral repair of orbital floor fractures. *Otolaryngol Head Neck Surg* 2009;140:849-54.
- [12] Hammer B. *Orbital Fractures. Diagnosis, operative treatment, secondary corrections.* Bern: Hogrefe & Huber Publishers; 1995.
- [13] Hawes MJ, Dortzbach RK. Surgery on orbital floor fractures. Influence on time of repair and fracture size. *Ophthalmology* 1983;90:1066-70.
- [14] Holt GR, Holt JE. Management of orbital trauma and foreign bodies. *Otolaryngol Clin North Am* 1988;21:35-52.
- [15] Hartstein ME, Roper-Hall G. Update on orbital floor fractures: indications and timing for repair. *Facial Plast Surg* 2000;16:95-106.
- [16] Manolidis S, Weeks BH, Kirby M, Scarlett M, Hollier L. Classification and surgical management of orbital fractures: experience with 111 orbital reconstructions. *J Craniofac Surg* 2002;13:726-37.
- [17] Burnstine MA. Clinical recommendations for repair of isolated orbital floor fractures: an evidence-based analysis. *Ophthalmology* 2002;109:1207-10.
- [18] Sires BS, Stanley RB Jr, Levine LM. Oculocardiac reflex caused by orbital floor trapdoor fracture: an indication for urgent repair. *Arch Ophthalmol* 1998;116:955-6.
- [19] Bansagi ZC, Meyer DR. Internal orbital fractures in the pediatric age group: characterization and management. *Arch Ophthalmol* 2000;107:829-36.
- [20] Wachler BS, Holds JB. The missing muscle syndrome in blowout fractures: an indication for urgent repair. *Ophthal Plast Reconstr Surg* 1998;17-8.
- [21] Jordan DR, Allen LH, White J, Harvey J, Pashby R, Esmaeli B. Intervention within days for some orbital floor fractures: the white-eyed blowout. *Ophthal Plast Reconstr Surg* 1998;14:379-90.
- [22] Boush GA, Lemke BN. Progressive infraorbital nerve hypesthesia as a primary indication for blow-out fracture repair. *Ophthal Plast Reconstr Surg* 1994;10:271-5.

- [23] Kwon JH, Kim JG, Moon JH, Cho JH. Clinical analysis of surgical approaches for orbital floor fractures. *Arch Facial Plast Surg* 2008;10:21-4.
- [24] Cole P, Boyd V, Banerji S, Hollier LH Jr. Comprehensive management of orbital fractures. *Plast Reconstr Surg* 2007;120:S57-S63.
- [25] Carroll SC, Ng SGJ. Outcomes of orbital floor fractures in children and adolescents. *Br J Ophthalmol* 2010;94:736-9.
- [26] Gosau M, Schoneich M, Draenert FG, Ettl T, Driemel O, Reichert TE. Retrospective analysis of orbital floor fractures – complications, outcome and review of literature. *Clin Oral Invest*, in press. DOI: 10.1007/s00784-010-0385-y
- [27] Neigel JM, Ruzicka PO. Use of demineralised bone implants in orbital and craniofacial surgery. *Ophthal Plast Reconstr Surg* 1996;12:108-20.
- [28] Chowdhury K, Krause GE. Selection of materials for orbital floor reconstruction. *Arch Otolaryngol Head Neck Surg* 1998;124:1398-1401.
- [29] Mok D, Lessard L, Cordoba C, Harris PG, Nikolis A. A review of materials currently used in orbital floor reconstruction. *Can J Plast Surg* 2004;12:134-40.
- [30] Potter JK, Ellis E. Biomaterials for reconstruction of the internal orbit. *J Oral Maxillofac Surg* 2004;62:1280-97.
- [31] Betz MW, Caccamese JF, Coletti DP, Sauk JJ, Fisher JP. Challenges associated with regeneration of orbital floor bone. *Tissue Eng B* 2010;16:541-50.
- [32] Schlickewei W, Schlickewei C. The use of bone substitutes in the treatment of bone defects – The clinical view and history. *Macromol Symp* 2007;253:10-23.
- [33] Young VL, Schuster RH, Harris LW. Intracerebral hematoma complicating split calvarial bone-graft harvesting. *Plast Reconstr Surg* 1990;86:763-5.
- [34] Kline RM Jr, Wolfe SA. Complications associated with the harvesting of cranial bone grafts. *Plast Reconstr Surg* 1995;95:5-20.

- [35] Mintz SM, Ettinger A, Schmamel T, Gleason MJ. Contralateral coronoid process bone grafts for orbital reconstruction: an anatomic and clinical study. *J Oral Maxillofac Surg* 1998;56:1140-5.
- [36] Johnson EP, Raftopoulos I. In situ splitting of a rib graft for reconstruction of the orbital floor. *Plast Reconstr Surg* 1999;103:1709-11.
- [37] Courtney DJ, Thomas S, Whitfield PH. Isolated orbital blowout fractures: survey and review. *Br J Oral Maxillofac Surg* 2000;38:496-503.
- [38] Iatrou I, Theologie-Lygidakis N, Angelopoulos A. Use of membrane and bone grafts in the reconstruction of orbital fractures. *Oral Surg Oral Med Oral Pathol Oral Radiol Endod* 2001;91:281-6.
- [39] Kakibuchi M, Fukuda K, Yamada N, Matsuda K, Kawai K, Kubo T, Sakagami M. A simple method for harvesting a thin iliac bone graft for reconstruction of the orbital wall. *Plast Reconstr Surg* 2003;111:961-2.
- [40] Nishiike S, Nagai M, Nakagawa A, Konishi M, Kato T, Sakata Y, Yasukara T, Harada T. Endoscopic transantral orbital floor repair with antral bone grafts. *Arch Otolaryngol Head Neck Surg* 2005;131:911-5.
- [41] Rudagi BM, Rajshekar H, Mahindra U, Kharkar V, Saluja H. Autogenous mandibular symphysis graft for orbital floor reconstruction: a preliminary study. *J Maxillofac Oral Surg* 2009;8:141-4.
- [42] Sakakibara S, Hashikawa K, Terashi H, Tahara S. Reconstruction of the orbital floor with sheets of autogenous iliac cancellous bone. *J Oral Maxillofac Surg* 2009;67:957-61.
- [43] Cieslik T, Skowronek J, Cieslik M, Cieslik-Bielicka A. Bone graft application from anterior sinus maxillary wall in orbital floor reconstruction. *J Craniofac Surg* 2009;20:512-5.
- [44] Ilankovan VT, Jackson IT. Experience in the use of calvarial bone grafts in orbital reconstruction. *Br J Oral Maxillofac Surg* 1992;30:92-6.

- [45] Guo L, Tian W, Feng F, Long I, Li P, Tang W. reconstruction of orbital floor fractures – comparison of individual prefabricated titaniumk implants and calvarial bone grafts. *Ann Plast Surg* 2002;63:624-31.
- [46] Ozaki W, Buchman SR. Volume maintenance of onlay bone grafts in the craniofacial skeleton: micro-architecture versus embryologic origin. *Plast Reconstr Surg* 1998;102:291-9.
- [47] Glassman RD, Manson PN, Vanderkolk CA, Iliff NT, Yaremchuk MJ, Petty P, Defresne CR, Markowitz BL. Rigid fixation of internal orbital fractures. *Plast Reconstr Surg* 1990; 86:1103-11.
- [48] Sullivan PK, Rosenstein DA, Holmes RE, Craig D, Manson PN. Bone graft reconstruction of the monkey orbital floor with iliac grafts an titanium mesh plates. *Plast Reconstr Surg* 1993;91:769-77.
- [49] Hwang K, Hita Y. Alloplastic template fixation of blow-out fracture. *J Craniofac Surg* 2002;13:510-2.
- [50] Kellman RM. Bone grafting for defects of the orbital floor. *Arch Otolaryngol Head Neck Surg* 1998;124:1402.
- [51] Mathog RH. Surgery of traumatic defects of the orbital floor. *Arch Otolaryngol Head Neck Surg* 1998;124:1402-3.
- [52] Zoumaras J, Vandervord J, Gates R, Hassall M, Lotz N. Autologous tissue vs synthetic material for orbital floor reconstitution. *Aust N Z J Surg* 2009;79:A55.
- [53] Al-Sukhun J, Lindqvist C. A comparative study of 2 implants used to repair inferior orbital wall bony defects: autogenous bone graft versus bioresorbable poly-L/DL-lactide [P(L/DL)LA 70/30] plate. *J Oral Maxillofac Surg* 2006;64:1038-48.
- [54] Shetty P, Kumar SG, Baliga M, Uppal N. Options in orbital floor reconstruction in blowout fractures: a review of ten cases. *J Maxillofac Oral Surg* 2009;8:137-40.
- [55] Ram H, Singh RK, Mohammad S, Gupta AK. Efficacy of iliac crest vs. Medpor in orbital floor reconstruction. *J Maxillofac Oral Surg* 2010;9:134-41.

- [56] Ellis E, Tan Y. Assessment of internal orbital reconstruction for pure blowout fractures: cranial bone versus titanium mesh. *J Oral Maxillofac Surg* 2003;61:442-53.
- [57] Zins JE, Whitaker LA. Membranous versus endochondral bone. Implications for craniofacial reconstruction. *Plast Reconstr Surg* 1983;72:778-85.
- [58] Lin KY, Bartlett SP, Yaremchuk MJ, Fallon M, Grossman RF, Whitaker RA. The effect of rigid fixation on the survival of onlay bone grafts: an experimental study. *Plast Reconstr Surg* 1990;86:449-56.
- [59] Philips JH, Rahn BA. Fixation effect on membranous and endochondral onlay bone graft revascularization and bone deposition. *Plast Reconstr Surg* 1990;85:891-7.
- [60] Constantian MB. Use of auricular cartilage in orbital floor reconstruction. *Plast Reconstr Surg* 1982;69:951-5.
- [61] Lai A, Gliklich RE, Rubin PAD. Repair of orbital blow-out fractures with nasoseptal cartilage. *Laryngoscope* 1998;108:645-50.
- [62] Kraus M, Gatot A, Fliss D. Repair of traumatic inferior orbital wall defects with nasoseptal cartilage. *J Oral Maxillofac Surg* 2001;59:1307-401
- [63] Kraus M, Gatot A, Kaplan DM, Fliss DM. Post-traumatic orbital floor reconstruction with nasoseptal cartilage in children. *Int J Pediatric Otorhinolaryngol* 2002;64:187-92.
- [64] Bayat M, Momen-Heravi F, Khalilzadeh O, Mirhosseni Z, Sadeghi-Tari A. Comparison of conchal cartilage graft with nasal septal cartilage graft for reconstruction of orbital floor blowout fractures. *Br J Oral Maxillofac Surg* 2010;48:617-20.
- [65] Celikoz B, Duman H, Selmanpakoglu N. Reconstruction of the orbital floor with lyophilized tensor fascia lata. *J Oral Maxillofac Surg* 1997;55:240-4.
- [66] Dost P. Orbital floor reconstruction with autologous periosteum transplant. *Laryngorhinootologie* 1996;75:57-8.

- [67] Aho AJ, Hirn M, Aro HT, Heikkila JT, Meurman O. Bone bank service in Finland. Experience of bacteriologic, serologic and clinical results of the Turku Bone Bank 1972-1995. *Acta Orthop Scand* 1998;69:559-65.
- [68] Campbell DG, Li P. Sterilization of HIV with irradiation: relevance to infected bone allografts. *Aust N Z J Surg* 1999;69:517-21.
- [69] Commission Directive 2004/23/EC (March 31, 2004) of the EU Parliament and the Council on setting standards of quality and safety for the donation, procurement, testing, processing, preservation, storage and distribution of human tissues and cells.
- [70] Commission Directive 2006/17/EC (February 8, 2006) implementing Directive 2004/23/EC.
- [71] Commission Directive 2006/86/EC (October 24, 2006) implementing Directive 2004/23/EC.
- [72] Waite PD, Clanton JT. Orbital floor reconstruction with lyophilized dura. *J Oral Maxillofac Surg* 1988;46:727-30.
- [73] Chen JM, Zingg M, Laedrach K, Raveh J. Early surgical intervention for orbital floor fractures: a clinical evaluation of lyophilized dura and cartilage reconstruction. *J Oral Maxillofac Surg* 1992;50:935-41.
- [74] Munoz-Guerra MF, Sastre-Perez JS, Rodriguez-Campo JF, Naval-Gias L. Reconstruction of orbital fractures with dehydrated human dura matter. *J Oral Maxillofac Surg* 2000;58:361-6.
- [75] Sallam MM, Hashem HA, Shokier HMR. Use of demineralised bone sheets in reconstruction of orbital floor trap door fracture. *J Appl Sci Res* 2010;6:653-8.
- [76] Bevivino JR, Nguyen PN, Yen LJ. Reconstruction of traumatic orbital floor defects using irradiated cartilage homografts. *Ann Plast Surg* 1994;33:32-7.
- [77] Nakumura Y, Aso E, Yanagawa H. relative risk of Creutzfeldt-Jakob disease with cadaveric dura mater transplantation in Japan. *Neurology* 1999;53:218-20.
- [78] Munoz-Guerra MF. Human dura mater and Creutzfeldt-Jakob disease. *J Oral Maxillofac Surg* 2001;59:595.

- [79] Webster K. Orbital floor repair with lyophilized porcine dermis. *Oral Surg Oral Med Oral Pathology* 1988; 65:161-4.
- [80] Morax S, Hurbli T, Smida R. Bovine heterologous bone graft in orbital surgery. *Ann Chir Plast Esthet* 1993;38:445-50.
- [81] Burres SA, Cohn AM, Mathog RH. Repair of orbital blowout fractures with Marlex and gelfilm. *Laryngoscope* 1981;91:1881-6.
- [82] Mermer RW, Orban RE Jr. Repair of orbital floor fractures with absorbable gelatin film. *J Craniofacial Trauma* 1995;1:30-4.
- [83] Cheung D, Brown L, Sampath R. Localized inferior orbital fibrosis associated with porcine dermal collagen xenograft orbital floor implant. *Ophthal Plast Reconstr Surg* 2004;20:257-9.
- [84] Becker ST, Terheyden H, Fabel M, Kandzia C, Moller B, Wiltfang J. Comparison of collagen membranes and polydioxanone for reconstruction of the orbital floor after fractures. *J Craniofac Surg* 2010;21:1066-8.
- [85] Chrobok V, Pellant A, Novak J, Brozik J. Reconstruction of an orbital floor fracture in a 4-year-old child. *Acta Med* 2008;51:229-31.
- [86] Costa JMC, Patrocínio LG, Rossi RD, Amorim ABC, Patrocínio JA. Bovine sclerae graft for orbital floor fracture in rabbits. *Arq Int Otorrinolaringol* 2005;9:181-8.
- [87] LeGeros RZ. Biodegradation and bioresorption of calcium phosphate ceramics. *Clin Mater* 1993;14:65-88.
- [88] Costantino PD, Friedman CD, Jones K, Chow LC, Pelzer HJ, Sisson GA. Hydroxyapatite cement. I: basic chemistry and histologic properties. *Arch Otolaryngol Head Neck Surg* 1991;117:379-84.
- [89] Friedman CD, Costantino PD, Jones K, Chow LC, Pelzer HJ, Sisson GA. Hydroxyapatite cement. II: obliteration and reconstruction of the cat frontal sinus. *Arch Otolaryngol Head Neck Surg* 1991;117:385-9.

- [90] Costantino PD, Friedman CD, Jones K, Chow LC, Sisson GA. Experimental hydroxyapatite cement cranioplasty. 1992;90:174-85.
- [91] Friedman CD, Costantino PD, Takagi S, Chow LC. BoneSource™ hydroxyapatite cement: a novel biomaterial for craniofacial skeletal tissue engineering and reconstruction. J Biomed Mater Res 1998;43:428-32.
- [92] Mathur KK, Tatum SA, Kellman RM. Carbonated apatite and hydroxyapatite in craniofacial reconstruction. Arch Facial Plast Surg 2003;5:379-83.
- [93] Ono I, Gunji H, Suda K, Kaneko F, Yago K. Orbital reconstruction with hydroxyapatite ceramic implants. Scand J Plast Reconstr Surg Hand Surg 1994;28:193-8.
- [94] Levy RA, Chu TMG, Halloran JW, Feinberg SE, Hollister S. CT-generated porous hydroxyapatite orbital floor prosthesis as a prototype bioimplant. Am J Neurorad 1997;18:1522-5.
- [95] Lemke BN, Kikkawa DO. Repair of orbital floor fractures with hydroxyapatite block scaffolding. Ophthal Plast Reconstr Surg 1999;15:161-5.
- [96] Elmazar H, Jackson IT, Degner D, Miyawaki T, Barakat K, Andrus L, Bradford M. The efficacy of Gore-Tex vs hydroxyapatite and bone graft in reconstruction of orbital floor defects. Eur J Plast Surg 2003;25:362-8.
- [97] Nam SB, Bae YC, Moon JS, Kang YS. Analysis of the postoperative outcome in 405 cases of orbital fracture using 2 synthetic orbital implants. Ann Plast Surg 2006;56:263-7.
- [98] Reyes JP, Celorico JR, Dela Cuesta LC, Filio JM, Daan LG, Bernardo ST, Abano JM. Bioceramic orbital plate implants. Adv Technol Mater Mater Process 2005;7:1-4.
- [99] Hench LL, Splinter RJ, Allen WC, Greenlee TK. Bonding mechanisms at the interface of ceramic prosthetic materials. J Biomed Mater Res 1972;2:117-41.
- [100] Hench LL. Biomaterials: a forecast for the future. Biomaterials 1998;19:1419-23.
- [101] Hench LL, Polak J. Third-generation biomedical materials. Science 2002;295:1014-7.
- [102] Hench LL. The story of Bioglass®. J Mater Sci: Mater Med 2006;17:967-78.

- [103] Jones JR, Gentleman E, Polak J. Bioactive glass scaffolds for bone regeneration. *Elements* 2007;3:393-9.
- [104] Hench LL. Genetic design of bioactive glasses. *J Eur Ceram Soc* 2009;29:1257-65.
- [105] Kinnunen I, Aitasalo K, Pollonen M, Varpula M. Reconstruction of orbital fractures using bioactive glass. *J Craniomaxillofac Surg* 2000;28:229-34.
- [106] Aitasalo K, Kinnunen I, Palmgren J, Varpula M. Repair of orbital floor fractures with bioactive glass implants. *J Oral Maxillofac Surg* 2001;59:1390-6.
- [107] Peltola M, Kinnunen I, Aitasalo K. Reconstruction of orbital wall defects with bioactive glass plates. *J Oral Maxillofac Surg* 2008;66:639-46.
- [108] Banovetz JM, Sharp R, Probe RA, Anglen JO. Titanium plate fixation: a review of implant failures. *J Orthop Trauma* 1996;10:389-94.
- [109] Andreiotelli M, Wenz HJ, Kohal RJ. Are ceramic implants a viable alternative to titanium implants? A systematic literature review. *Clin Oral Implants Res* 2009;20:32-47.
- [110] Mackenzie DJ, Arora B, Hansen J. Orbital floor repair with titanium mesh screen. *J Craniomaxillofac Trauma* 1999;5:9-18.
- [111] Park HS, Kim YK, Yoon CH. Various applications of titanium mesh screen implant to orbital wall fractures. *J Craniofacial Surg* 2001;12:555-60.
- [112] Schubert W, Gear AJ, Lee C, Hilger PA, Haus E, Migliori MR, Mann DA, Benjamin CI. Incorporation of titanium mesh in orbital and midface reconstruction. *Plast Reconstr Surg* 2002;110:1022-32.
- [113] Gear AJ, Lokeh A, Aldridge JH, Migliori MR, Benjamin CI, Schubert W. Safety of titanium mesh for orbital reconstruction. *Ann Plast Surg* 2002;48:1-9.
- [114] Hughes CW, Page K, Bibb R, Taylor J, Revington P. The custom-made titanium orbital floor prosthesis in reconstruction for orbital floor fractures. *Br J Oral Maxillofac Surg* 2003;41:50-3.

- [115] Schon R, Metzger MC, Zizelmann C, Weyer N, Schmelzeisen R. Individually preformed titanium mesh implants for true-to-original repair of orbital fractures. *Int J Oral Maxillofac Surg* 2006;35:990-5.
- [116] Wang S, Xiao J, Liu L, Lin Y, Li X, Tang W, Wang H, Long J, Zheng X, Tian W. Orbital floor reconstruction: a retrospective study of 21 cases. *Oral Surg Oral Med Oral Pathol Oral Radiol Endod* 2008;106:324-30.
- [117] Kozakiewicz M, Elgalal M, Loba P, Komunski P, Arkuszewski P, Broniarczyk-Loba A, Stefanczyk L. clinical applications of pre-bent titanium implants for orbital floor fractures. *J Cranio-Maxillofac Surg* 2009;37:229-34.
- [118] Lieger O, Richards R, Liu M, Lloyd T. Computer-assisted design and manufacture of implants in the late reconstruction of extensive orbital fractures. *Arch facial Plast Surg* 2010;12:186-91.
- [119] Adya N, Alam M, Ravindranath T, Mubeen A, Saluja B. Corrosion in titanium dental implants. literature review. *J Ind Prosthodont Soc* 2005;5:126-31.
- [120] Dobbs HS, Robertson JLM. Heat treatment of cast Co-Cr-Mo for orthopaedic implant use. *J Mater Sci* 1983;18:391-401.
- [121] Sargent LA, Fulks KD. Reconstruction of internal orbit fractures with Vitallium mesh. *Plast Reconstr Surg* 1991;88:31-8.
- [122] Sullivan PK, Smith JF, Rozzelle A. Cranio-orbital reconstruction: safety and image quality of metallic implants on CT and MRI scanning. *Plast Reconstr Surg* 1994;94:589-96.
- [123] Bairo F. Scleral buckling biomaterials and implants for retinal detachment surgery. *Med Eng Phys* 2010;32:945-56.
- [124] Lipshutz H, Ardizzone RA. The use of silicone rubber in the immediate reconstruction of fractures of the floor of the orbit. *J Trauma* 1963;3:563-8.

- [125] Laxenaire A, Levy J, Blanchard P, Lerondeau JC, Tesnier F, Scheffer P Silastic implants and reconstruction of the orbital floor: review of twenty year's experience. *Ann Chir Plast Esthet* 1996;4:631-8.
- [126] Prowse SJB, Hold PM, Gilmour RF, Pratap U, Mah E, Kimble FW. Orbital floor reconstruction: a case for silicone. A 12 years experience. *J Plast Reconstr Aesthet Surg* 2010;63:1105-9.
- [127] Schmidt BL, Lee C, Young DM, O'Brien J. Infraorbital squamous epithelial cyst: an unusual complication of silastic implantation. *J Craniofac Surg* 1998;9:452-5.
- [128] Liu D, Al-Sadhan Y. Orbital floor implnat migration across the ethmoidal sinuses and nasal septum. *Am J Ophthalmol* 1999;128:122-3.
- [129] Fialkov JA, Holy C, Forrest CR, Philips JH, Antonyshyn OM. Postoperative infections in craniofacial reconstructive procedures. *J Craniofac Surg* 2001;12:362-8.
- [130] Klisovic DD, Katz SE, Lubow M. The wayward implant: orbital silicone plate extrusion associated with squamous epithelial downgrowth and infection. *Orbit* 2002;21:149-54.
- [131] Laxenaire A, Levy J, Blanchard P, Lerondeau JC, Tesnier F, Scheffer P. Complications of silastic implants used in orbital repair. *Rev Stomatol Chir Maxillofac* 1997;98:96-9.
- [132] Dougherty WR, Wellisz T. The natural history of alloplastic implants in orbital floor reconstruction: an animal model. *J Craniofac Surg* 1994;5:26-33.
- [133] Morrison AD, Sanderson RC, Moos KF. The use of silastic as an orbital implant for reconstruction of orbital wall defects: review of 311 cases treated over 20 years. *J Oral Maxillofac Surg* 1995;53:412-7.
- [134] Brown AE, Banks P. Late extrusion of alloplastic orbital floor implants. *Br J Oral Maxillofac Surg* 1993;31:154-7.
- [135] Miyasaka M, Tanaka R, Hanai U, Yamazaki A, Iida M, Akamatsu T. A case of chronic infection 28 years after silicone orbital implant. *Tokai J Exp Clin Med* 2008;33:35-8.

- [136] Romano JJ, Iliff NT, Manson PN. Use of Medpor porous polyethylene implants in 140 patients with facial fractures. *J Craniofac Surg* 1993;4:142-7.
- [137] Patel PJ, Rees HC, Olver JM. *Arch Ophthalmol* 2003;121:400-3.
- [138] Lupi E, Messi M, Ascani G, Balercia P. Orbital floor repair using Medpor porous polyethylene implants. *Invest Ophthalmol Vis Sci* 2004;45:E4700.
- [139] Sevin K, Askar I, Saray A, Yormuk E. Exposure of high-density porous polyethylene (Medpor[®]) used for contour restoration and treatment. *Br J Oral Maxillofac Surg* 2000;38:44-9.
- [140] Villareal PM, Monje F, Morillo AJ, Junquera LM, Gonzalez C, Barbon JJ. Porous polyethylene implants in orbital floor reconstruction. *Plast Reconstr Surg* 2002;109:877-87.
- [141] Breton P, Crezoit E, Blachard P, Fiere A, Freidel M. The role of Gore-Tex in orbital injuries. Apropos of 30 cases. *Rev Stomatol Chir Maxillofac* 1990;91:52-4.
- [142] Hanson LJ, Donovan MG, Hellstein JW, Dickerson NC. Experimental evaluation of expanded polytetrafluoroethylene for reconstruction of orbital floor defects. *J Oral Maxillofac Surg* 1994;52:1050-5.
- [143] Majmundar MV, Hamilton JS. Repair of orbital floor fractures with SupraFOIL smooth nylon foil. *Arch Facial Plast Surg* 2007;9:64-5.
- [144] Nunery WR, Tao JP, Johl S. Nylon foil "wraparound" repair of combined orbital floor and medial wall fractures. *Ophthal Plast Reconstr Surg* 2008;24:271-5.
- [145] Park DJJ, Garibaldi DC, Iliff NT, Grant MP, Merbs SL. Smooth nylon foil (SupraFOIL) orbital implants in orbital fractures: a case series of 181 patients. *Ophthal Plast Reconstr Surg* 2008;24:266-70.
- [146] Betz MW, Caccamese JF, Coletti DP, Sauk JJ, Fisher JP. Tissue response and orbital floor regeneration using cyclic acetal hydrogels. *J Biomed Mater Res A* 2009;90:819-29.
- [147] Francel TJ, Bireley BC, Ringelman PR, Manson PN. The fate of plates and screws after facial fracture reconstruction. *Plast Reconstr Surg* 1992;90:568-73.

- [148] Enislidis G, Pichorner S, Kainberger F, Ewers R. Lactosorb panel and screws for repair of large orbital floor defects. *J Craniomaxillofac Surg* 1997;25:316-21.
- [149] Kontakis GM, Pagkalos JE, Tosoudinis TI, Melissas J, Katonis P. Bioabsorbable materials in orthopaedics. *Acta Orthop Belg* 2007;73:159-69.
- [150] Williams DF. Review: biodegradation of surgical polymers. *J Mater Sci* 1982;17:1233-46.
- [151] Lyu SP, Untereker D. Degradability of polymers for implantable biomedical devices. *Int J Mol Sci* 2009;10:4033-65.
- [152] Pillai CKS, Sharma CP. Review paper: absorbable polymeric surgical sutures: chemistry, production, properties, biodegradability and performance. *J Biomater Appl* 2011;291-366.
- [153] Cutright DE, Hunsuck EE. The repair of fractures of the orbital floor using biodegradable polylactic acid. *Oral Surg* 1972;33:28-34.
- [154] Rozema FR, Bos RRM, Pennings AJ, Jansen HWB. Poly(L-lactide) implants in repair of defects of the orbital floor: an animal study. *J Oral Maxillofac Surg* 1990;48:1305-9.
- [155] De Roche R, Kuhn A, De Roche-Weber P, Gogolewski S, Printzten G, Geissmann A, De Jager M, Hammer B, Prein J, Rahn B. Experimentelle Rekonstruktion der Orbita beim Schaf mit biodegradablen Implantaten. *Mund Kiefer Gesichts Chir* 1998;2(Suppl 1):117-20.
- [156] De Roche R, Adolphs N, Kuhn A, Gogolewski S, Hammer B, Rahn B. Reconstruction of the orbits with polylactate implants: animal experimental results after 12 months and clinical, prospects. *Mund Kiefer Gesichts Chir* 2001;5:49-56.
- [157] Bergsma JE, Rozema FR, Bos RRM, De Bruijn WC, Boering G. Poly(L-lactic)acid implants in repair of defects of the orbital floor. A five-year animal study. *Cells Mater* 1994;4:31-6.
- [158] Bergsma JE, Rozema FR, Bos RRM, De Bruijn WC. Foreign body reactions to resorbable poly(L-lactide) bone plates and screws used for the fixation of unstable zygomatic fractures. *J Oral Maxillofac Surg* 1993;51:666-70.

- [159] Cordewener FW, Bos RM, Rozema FR, Houtman WA. Poly(L-Lactide) implants for repair of human orbital floor defects: clinical and magnetic resonance imaging evaluation of long-term results. *J Oral Maxillofac Surg* 1996;54:9-13.
- [160] Bergsma JE, De Bruijn WC, Rozema FR, Bos RRM, Boering G. Late degradation tissue response to poly(L-lactide) bone plates and screws. *Biomaterials* 1995;16:25-31.
- [161] Balogh C, Lucas R, Kraft T, Breton P, Freidel M. Lactic acid polymer implants in the repair of traumatic defects of the orbital floor. *Rev Stomatol Chir Maxillofac* 2001;102:109-14.
- [162] Lieger O, Schaller B, Zix J, Kellner F, Iizuka T. Repair of orbital floor fractures using bioresorbable poly-L/DL-lactide plates. *Arch Facial Plast Surg* 2010;12:399-404.
- [163] Hatton PV, Walsh J, Brook JM. The response of cultured bone cells to resorbable polyglycolic acid and silicone membranes for use in orbital floor fracture repair. *Clin Mater* 1994;17:71-80.
- [164] McVicar I, Hatton PV, Brook IM. Self-reinforced polyglycolic acid membrane: a bioresorbable material for orbital floor repair. Initial clinical report. *Br J Oral Maxillofac Surg* 1995;33:220-3.
- [165] Williams DF. Review: biodegradation of surgical polymers. *J Mater Sci* 1982;17:1233-46.
- [166] Edwards RC, Kiely KD, Eppley BL. The fate of resorbable poly-L-lactic/polyglycolic acid (Lactosorb) bone fixation devices in orthognathic surgery. *J Oral Maxillofac Surg* 2001;59:19-25.
- [167] Hollier LH, Rogers N, Berzin E, Stal S. Resorbable mesh in the treatment of orbital floor fractures. *J Craniofac Surg* 2001;12:242-6.
- [168] Tuncer S, Yavuzer R, Kandal S, Demir YH, Ozmen S, Latifoglu O, Atabay K. Reconstruction of traumatic orbital floor fractures with resorbable mesh plate. *J Craniofac Surg* 2007;18:598-605.
- [169] Uygur S, Cukurluoglu O, Ozmen S, Guclu TH, Sezgin B. Resorbable mesh plate in the treatment of blow-out fracture might cause gaze restriction. *J Craniofac Surg* 2009;20:71-2.
- [170] Eppley BL, Morales L, Wood R, Pensler J, Goldstein J, Havlik RJ, Habal M, Losken A, Williams JK, Burnstein F, Rozzelle AA, Sadove AM. Resorbable PLLA-PGA plate and screw

fixation in pediatric craniofacial surgery: clinical experience in 1883 patients. *Plast Reconstr Surg* 2004;114:850-6.

[171] Merten HA, Luhr HG. Resorbable synthetics (PDS foils) for bridging extensive orbital wall defects in an animal experiment comparison. *Fortschr Kiefer Gesichtschir* 1994;39:186-90.

[172] Kontio R, Suuronen R, Salonen O, Paukku P, Konttinen YT, Lindqvist C. Effectiveness of operative treatment of internal orbital floor fracture with polydioxanone implant. *Int J Oral Maxillofac Surg* 2001;30:278-85.

[173] Baumann A, Burggasser G, Gauss N, Ewers R. Orbital floor reconstruction with an alloplastic resorbable polydioxanone sheet. *Int J Oral Maxillofac Surg* 2002;31:367-73.

[174] Jank S, Emshoff R, Schuchter B, Strobl H, Brandlmaier I, Norer B. Orbital floor reconstruction with flexible Ethisorb patches: a retrospective long-term follow-up study. *Oral Surg Oral Med Oral Pathol Oral Radiol Endod* 2003;95:16-22.

[175] Piotrowski WP, Mayer-Zuchi U. The use of polyglactine 910-polidioxanon in the treatment of defects of the orbital roof. *J Oral Maxillofac Surg* 1999;75:1301-5.

[176] Buchel P, Rahal A, Seto I, Iizuka T. Reconstruction of orbital floor fracture with polyglactine 910-polydioxanon patch (Ethisorb): a retrospective study. *J Oral Maxillofac Surg* 2005;63:646-50.

[177] Downes RN, Vardy S, Tanner TE, Bonfield W. Hydroxyapatite-polyethylene composite in orbital surgery. In: Bonfield W, Hastings GW, Tanner TE, editors. *Bioceramics Volume 4*. Oxford: Butterworth Heinmann; 1991. p. 239-46.

[178] Tanner TE, Downes RN, Bonfield W. Clinical applications of hydroxyapatite reinforced polyethylene. *Br Ceram Trans* 1994;93:104-7.

[179] Meijer AGW, Segenhout HM, Albers FWJ, Van de Want HJL. Histopathology of biocompatible hydroxyapatite-polyethylene composite in ossiculoplasty. *ORL J Otorhinolaryngol Relat Spec* 2002;64:173-9.

[180] Zhang Y, Tanner TE, Gurav N, Di Silvio L. In vitro osteoblastic response to 30%vol hydroxyapatite-polyethylene composite. *J Biomed Mater Res A* 2007;81:409-17.

- [181] Tanner KE. Bioactive ceramic-reinforced composites for bone augmentation. *J R Soc Interface* 2010;7:S541-S557.
- [182] Merbs SL, Iliff NT, Grant NT, Garibaldi DC. Use of MEDPOR TITAN implants in orbital reconstruction. *Invest Ophthalmol Vis Sci* 2005;46:E4210.
- [183] Tabrizi R, Ozkan TB, Mohammadinejad C, Minaee N. Orbital floor reconstruction. *J Craniofac Surg* 2010;21:1142-6.
- [184] Asamura S, Ikada Y, Matsunaga K, Wada M, Isogai N. Treatment of orbital floor fracture using a periosteum–polymer complex. *J Craniomaxillofac Surg* 2010;38:197-203.
- [185] Asamura S, Mochizuki Y, Yamamoto M, Tabata Y, Isogai N. Bone regeneration using a Bone Morphogenetic Protein-2 saturated slow-release gelatin hydrogel sheet: evaluation in a canine orbital floor fracture model. *Annals Plast Surg* 2010;64:496-502.
- [186] Patel M, Betz MW, Geibel E, Patel KJ, Caccamese JF, Coletti DP, Sauk JJ, Fisher JP. Cyclic acetal hydroxyapatite nanocomposites for orbital bone regeneration. *Tissue Eng A* 2010;16:55-65.
- [187] Rohner D, Hutmacher DW, Cheng TK, Oberholzer M, Hammer B. in vivo efficacy of bone-marrow-coated polycaprolactone scaffolds for the reconstruction of orbital defects in pigs. *J Biomed Mater Res B* 2003;66:574-80.
- [188] Nishiguchi S, Nakamura T, Kobayashi M, Kim HM, Miyaji F, Kokubo T. the effect of heat treatment on bone-bonding ability of alkali-treated titanium. *Biomaterials* 1999;20:401-500.
- [189] Nishiguchi S, Kato H, Fujita H, Oka M, Kim HM, Kokubo T, Nakamura T. Titanium metals form direct bonding to bone after alkali and heat treatment. *Biomaterials* 2001;22:2525-33.
- [190] Jonasova L, Muller FA, Helebrant H, Strnad J, Greil P. Hydroxyapatite formation on alkali-treated titanium with different content of Na⁺ in the surface layer. *Biomaterials* 2002;23:3095-101.
- [191] Ferraris S, Spriano S, Pan G, Venturello A, Bianchi CL, Chiesa R, Faga MG, Maina G, Verné E. Surface modification of Ti–6Al–4V alloy for biomineralization and specific biological response: Part I, inorganic modification. *J Mater Sci Mater Med* 2011;22:533-45.

- [192] Chiono V, Gentile P, Boccafoschi F, Carmagnola I, Ninov M, Georgieva V, Georgiev G, Ciardelli G. Photoactive chitosan switching on bone-like apatite deposition. *Biomacromolecules* 2010;11:309-15.
- [193] Quadrani P, Pasini A, Mattioli-Belmonte M, Zannoni C, Tampieri A, Landi E, Giantomassi F, Natali D, Casali F, Biagini G, Tomei-Minardi A. High-resolution 3D scaffold model for engineered tissue fabrication using a rapid prototyping technique. *Med Biol Eng Comput* 2005;43:196-9.
- [194] Hollister SJ. Porous scaffold design for tissue engineering. *Nature Mater* 2005;4:518-24.
- [195] Bergmann C, Lindner M, Zhang W, Koczur K, Kirsten A, Telle R, Fischer H. 3D printing of bone substitute implants using calcium phosphate and bioactive glasses. *J Eur Ceram Soc* 2010;30:2563-7.
- [196] Xia W, Chang J. Preparation, *in vitro* bioactivity and drug release property of well ordered 58S bioactive glass. *J Non-Cryst Solids* 2008;354:1338-41.
- [197] Xia W, Chang J. Well ordered mesoporous bioactive glasses (MBG): a promising bioactive drug delivery system. *J Control Rel* 2006;110:522-30.
- [198] Zhu Y, Kaskel S. Comparison of the *in vitro* bioactivity and drug release property of mesoporous bioactive glasses (MBGs) and bioactive glasses (BGs) scaffolds. *Microp Mesop Mater* 2009;118:176-82.
- [199] Rezwan K, Chen QZ, Blaker JJ, Boccaccini AR. Biodegradable and bioactive porous polymer/inorganic composite scaffolds for bone tissue engineering. *Biomaterials* 2006;27:3413-31.
- [200] Jones JR. New trends in bioactive scaffolds: the importance of nanostructure. *J Eur Ceram Soc* 2009;29:1275-81.
- [201] Gerhardt LC, Boccaccini AR. Bioactive glass and glass-ceramic scaffolds for bone tissue engineering. *Materials* 2010;3:3867-910.
- [202] Rahaman MN, Day DE, Bal BS, Fu Q, Jung SB, Bonewald LF, Tomsia AP. Bioactive glass in tissue engineering. *Acta Biomaterialia*, in press. DOI: 10.1016/j.actbio.2011.03.016

[203] Baino F, Vitale-Brovarone C. 3-D glass-derived scaffolds for bone tissue engineering: current trends and forecasts for the future. *J Biomed Mater Res A*, in press. DOI: 10.1002/jbm.a.33072

[204] Haidar ZS, Hamdy RC, Tabrizian M. Delivery of recombinant bone morphogenetic proteins for bone regeneration and repair. Part A: current challenges in BMP release. *Biotechnol Lett* 2009;31:1817-24.

[205] Haidar ZS, Hamdy RC, Tabrizian M. Delivery of recombinant bone morphogenetic proteins for bone regeneration and repair. Part B: delivery systems for BMPs in orthopaedic and craniofacial tissue engineering. *Biotechnol Lett* 2009;31:1825-35.

Tables

Table 1

Medical glossary (terms listed alphabetically).

Term	Explanation
Blepharoptosis	Drooping of the upper eyelid.
Bone morphogenetic protein (BMPs)	Group of growth factors, also known as cytokines, able to induce and regulate the formation of bone and cartilage. Dysregulation in BMP signalling may involve a multitude of diseases and pathological processes, including cancer.
Conjunctiva	Clear mucous membrane constituted by stratified columnar epithelium that covers the sclera and lines the inside of the eyelids. It contributes to eye lubrication by producing mucus and tears, although in a smaller amount with respect to lachrymal glands. In addition, it prevents the entrance of pathogen agents and foreign body into the eye.
Diplopia	Commonly referred to as “double vision”, it can occur when patient’s eyes are not correctly aligned while aiming at an object and, therefore, two non-matching images are simultaneously sent to the viewer’s brain. It is often the first manifestation of many systemic disorders, especially concerning muscular or neurologic processes. An accurate and clear description of the symptoms – e.g. constant or intermittent; variable or

	unchanging; at near or at far; monocular or binocular; horizontal, vertical or oblique – is critical to appropriate diagnosis and management.
Dysesthesia	Unpleasant, abnormal sensation produced by normal stimuli, with particular reference to touch; this altered sensation may be considered as a kind of pain.
Ectropion	Turning out of the eyelid (usually the lower eyelid), so that its inner surface is exposed.
Entropion	Folding inwards of the eyelid (usually the lower eyelid), so that the eyelashes constantly rub against the cornea.
Enophthalmos	Recession of the eyeball within the orbit. It may be a congenital anomaly or be acquired as a result of trauma, such as blow-out fracture of the orbit. It is also referred to as endophthalmos.
Epistaxis	Hemorrhage from the nose. It is commonly referred to as nosebleed.
Exophthalmos	Also referred to as proptosis, it results in a bulging of the eye anteriorly out of the orbit. It can be either bilateral or unilateral, and is usually due to orbital tumor, trauma or swelling of surrounding tissue(s) resulting from trauma. Trauma to the orbit can cause bleeding behind the eye, a condition called retrobulbar hemorrhage; the resulting increased pressure pushes the eye out of the socket, thereby leading to exophthalmos.
Extraocular muscles	Group of 6 muscles, attaching to the sclera, that control the movements of the eye.
Hyperalgesia	Abnormally increased sensitivity to pain; it is usually due to damage to nociceptors or peripheral nerve.

Hypoesthesia	Abnormally reduced sensitivity to sensory stimuli, particularly to touch.
Hypoglobus	Downward displacement of the ocular globe; its causes and symptoms are quite similar to those observed for enophthalmos.
Infraorbital nerve	Name of the maxillary nerve after entering the infraorbital canal. It innervates the lower eyelid, the upper lip and part of the nasal vestibule.
Intraocular pressure (IOP)	Measure of the fluid pressure inside the eye (mean value in normal population ~15.5 mmHg). IOP above 21 mmHg indicates ocular hypertension, that may eventually develop into glaucoma and involve damage to the optic nerve.
Maxillary sinus	Located in the body of the maxilla, it is the largest of paranasal sinuses and characterized by pyramidal shape. This sinus, often termed maxillary antrum, has three recesses: an alveolar recess (inferior region, bounded by the alveolar process of the maxilla, a zygomatic recess (lateral region) bounded by the zygomatic bone, and an infraorbital recess (superior region) bounded by the inferior orbital surface of the maxilla (orbital floor).
Retina	Light-sensitive tissue of the eye. It lines the inner surface of the ocular globe and can be viewed as a highly-specialized multilayered neural structure. The neurons that are directly sensitive to light are the photoreceptor cells, i.e. rods, that function mainly in dim light and provide black-and-white vision, and cones, that support daytime vision and the perception of colours.
Sclera	Opaque, fibrous, protective, outer layer of the eye. Primarily constituted by collagen, it maintains the shape

	<p>of the globe, offers resistance to internal and external forces and provides an attachment for the extraocular muscle insertions. The thickness of the sclera varies from 1 mm at the posterior pole to 0.3 mm just behind the rectus muscle insertions. It is commonly referred to as the “white of the eye”.</p>
--	---

Table 2

Overview of the biomaterials/implants used for orbital floor repair.

Class	Material	Type ^a	Recipient ^b	Remarks and some examples of commercial products	References
Autografts	Bone	A	H	Resorption rate depending on bone type (cancellous, cortical) and origin (harvesting site)	[28,33-59]
	Cartilage	P	H	Easy and non-traumatic harvesting	[60-64]
	Fascia lata	A	H		[65]
	Periosteum	A	H		[66]
Allografts	Lyophilized dura mater	A	H	Possible problems related to its use, with particular reference to the transmission of Creutzfeldt-Jakob disease	[72-74]
	Demineralised bone	A	H	Allogenic bone banks are available to surgeons	[27,75]
	Cartilage	P	H		[73,76]
Xenografts and animal-derived substances	Bovine bone	A	H		[80]
	Gelatin	A	H	Commercial products: Gelfilm [®] (thin sheets)	[81-85]
	Bovine sclera	P	AM	Experimented in an animal model (rabbits) only	[86]
Bioceramics	Hydroxyapatite (HA)	P	H	Commercial product: Biocoral [®] (coral-derived HA);	[88-98]

				HA-containing cements.	
	Bioactive glasses	A	H	Slowly resorbable. In principle, the behaviour of bioactive glasses can be tailored acting on their composition (amount of the different oxides) and, accordingly, the glass dissolution rate can be properly modulated.	[105-107]
Metals	Titanium	P	H	Commercial product: MatrixORBITAL [®]	[54,110-118]
	Cobalt alloys	P	H	Commercial alloy name: Vitallium [®]	[121]
Polymers	Silicone	P	H	Commercial products: Silastic [®] sheets	[124-135]
	Polyethylene (PE)	P	H	Commercial implant: Medpor [®] (porous PE)	[55,116,129,132,136-140]
	Polytetrafluoroethylene (PTFE)	P	H	Expanded PTFE (Gore-Tex [®]) is clinically used	[96,141,142]
	Nylon	P	H	Commercial product: SupraFOIL [®] sheets	[143-145]
	BMP-loaded hydrogel	P	AM	Experimented in an animal model (rabbits) only	[31,146]
	Poly(lactic acid) (PLA)	A	H	Very slow resorption rate. Commercial product: Biosorb [®] FX (P(L/DL)LA copolymer)	[153-162]

	Poly(glycolic acid) (PGA)	A	H		[163-165]
	PLA/PGA	A	H	Commercial products: Lactosorb [®] , Biosorb [®] PDX	[167-170]
	Polydioxanone (PDO)	A	H	Commercial product: Vicryl [®]	[84,171-174]
	Polyglactine 910/PDO	A	H	Commercial product: Ethisorb [®]	[174-176]
Composites	HA/PE	P	H	Commercial product: HAPEX TM	[177,178,181]
	Titanium/PE	P	H	Commercial products: Medpor [®] Titan TM ; SynPOR [®]	[182,183]
	Periosteum joined to a HA/PLLA/PCL sheet	A	H		[184]
	BMP-loaded gelatin hydrogel/PLA-based polymer sheet	A	AM	Experimented in an animal model (dogs) only	[185]
	HA nanoparticles/cyclic acetal hydrogels	P	AM	Experimented in an animal model (rabbits) only	[186]
	Bone-marrow-coated PCL scaffold	A	AM	Experimented in an animal model (pigs) only	[187]

^a P = permanent; A = absorbable.

^b H = human patients; AM = animal model only

Figure

Fig. 1. Tomographical image (coronal plane) showing patient’s right orbital floor fracture, vertical elongation of right orbit and, accordingly, reduction in size of right maxillary (1, orbital cavities; 2, maxillary sinuses; 3, fracture area).

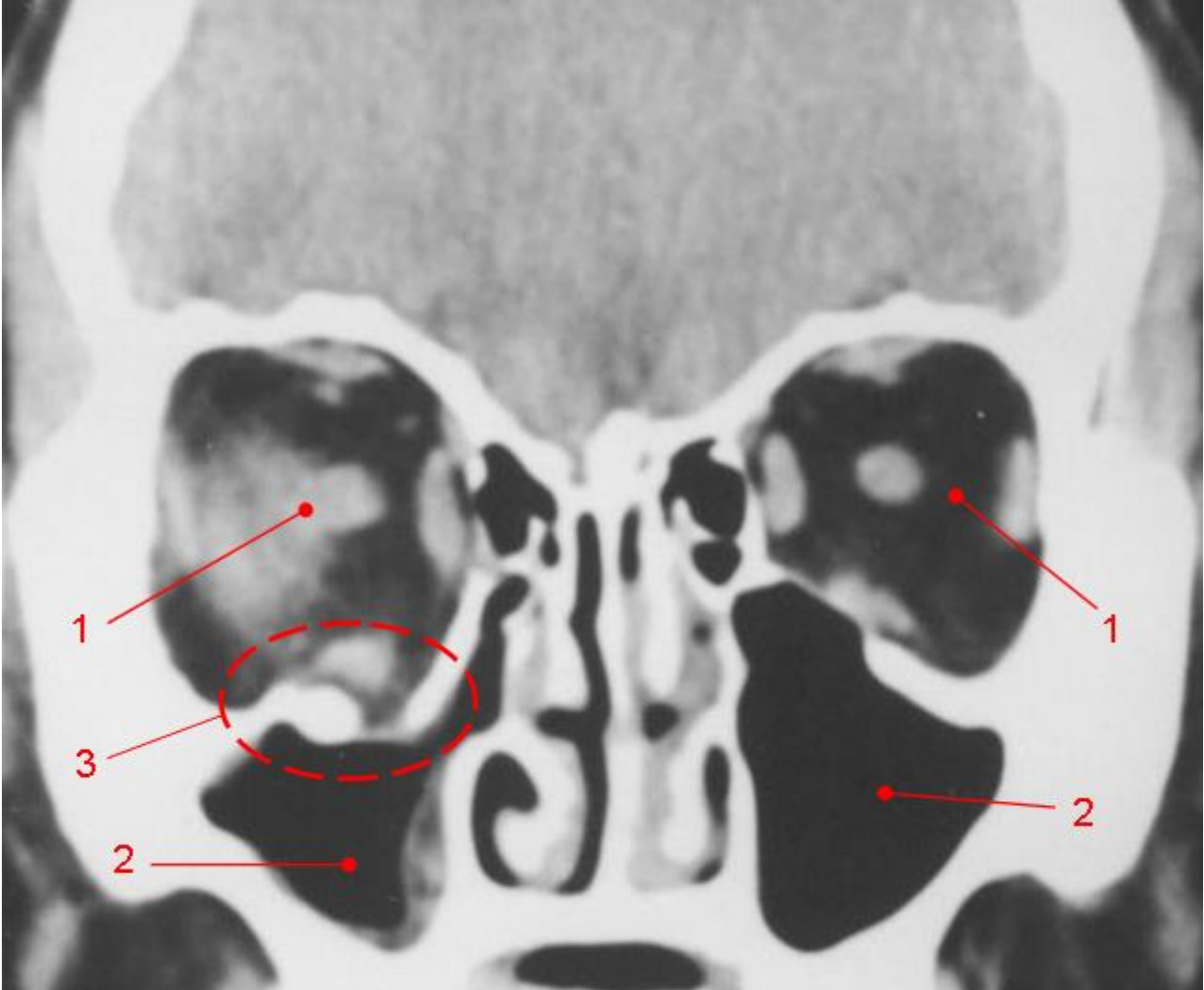


Fig. 2. Endoscopic transantral approach for orbital floor fracture repair: (a) upper gingivobuccal incision; (b) maxilla exposure for osseous cuts; (c) removal of bone window taking care to preserve the medial and lateral buttresses and the infraorbital nerve (the bone window may be discarded, replaced in situ at the end of operation or used as an autograft, according to material quality and surgeon's preferences); (d) orbital exploration performed through the endoscope (herniated orbital contents are visible); (e) reduction of herniated orbital contents within the orbit from the transantral route; (f) fracture stabilization with a proper implant (biologically-derived or alloplastic material). (Images adapted from Ducic and Verret [11] with permission.)

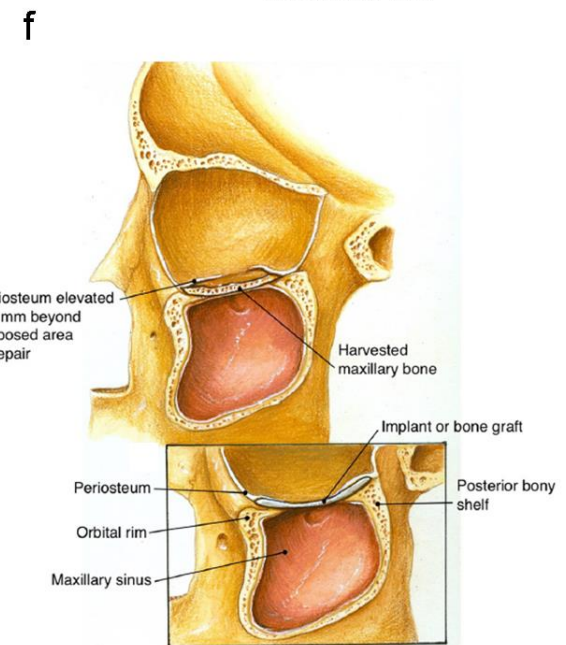
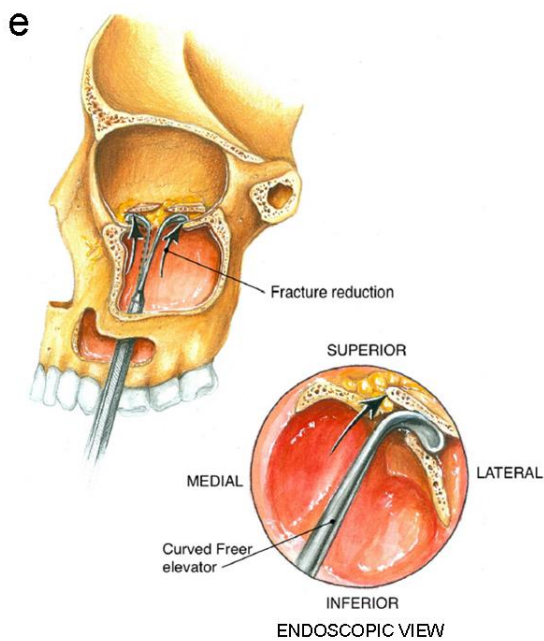
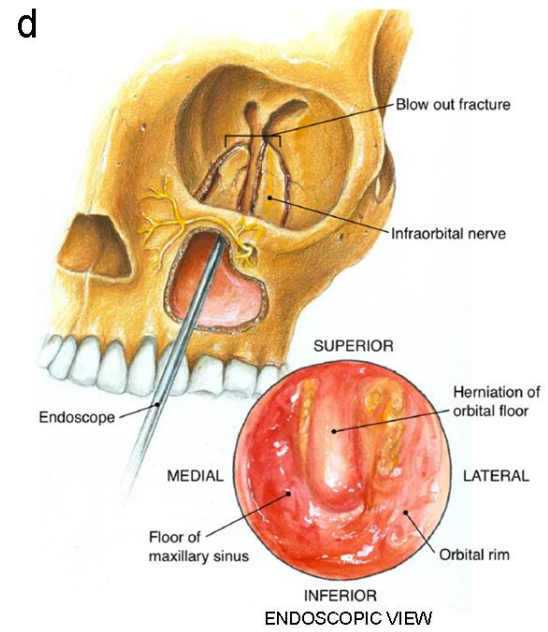
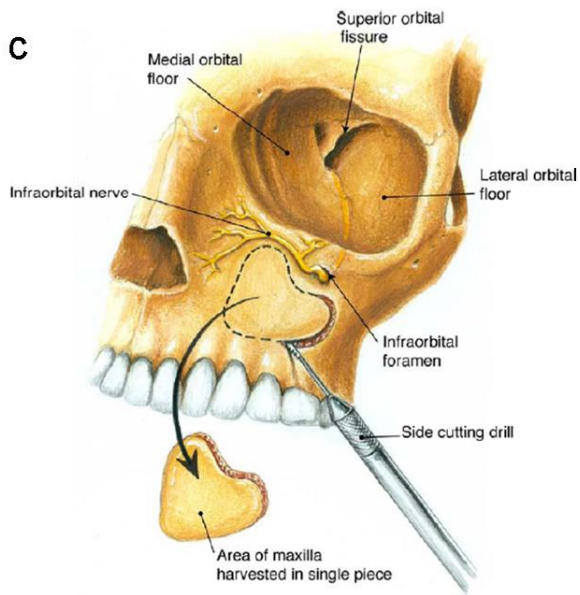
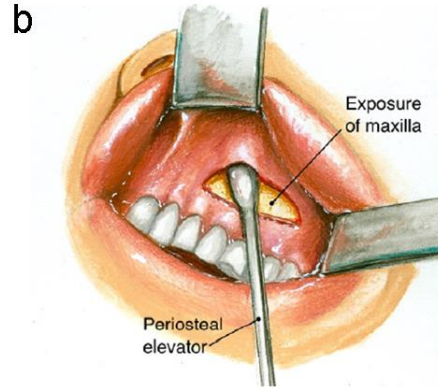
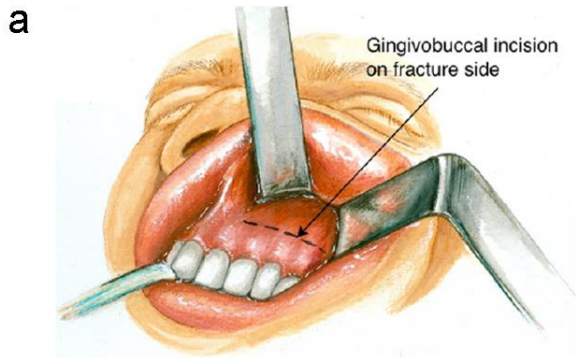


Fig. 3. Some examples of biomaterials/implants used for orbital floor repair: (a) iliac crest autograft (adapted from Sakakibara et al. [42] with permission); (b) bioactive glass plates with their corresponding “kidney-shaped” and “drop-shaped” stainless steel templates (adapted from Peltola et al. [107] with permission); (c) titanium mesh on a solid orbital model (adapted from Kozakiewick et al. [117] with permission); (d) porous polyethylene sheet (Medpor[®]) (courtesy from Porex Surgical, USA); (e) poly(L-lactide) implant (adapted from Rozema et al. [154] with permission); (f) poly(L-lactic) acid/polyglycolic acid composite implant (Lactosorb[®] panel) (adapted from Enislidis et al. [148]); (g) polyglactin 910/polydioxanone patch (Ethisorb[®]) (adapted from Buchel et al. [176]); (h) upper and lower side of titanium/polyethylene composite implant (Medpor[®] Titan[™]) (courtesy from Porex Surgical, USA).

