

Towards an ideal biomaterial for vitreous replacement: historical overview and future trends

Original

Towards an ideal biomaterial for vitreous replacement: historical overview and future trends / Baino, Francesco. - In: ACTA BIOMATERIALIA. - ISSN 1742-7061. - STAMPA. - 7:(2011), pp. 921-935. [10.1016/j.actbio.2010.10.030]

Availability:

This version is available at: 11583/2467781 since:

Publisher:

Elsevier

Published

DOI:10.1016/j.actbio.2010.10.030

Terms of use:

This article is made available under terms and conditions as specified in the corresponding bibliographic description in the repository

Publisher copyright

(Article begins on next page)

Towards an ideal biomaterial for vitreous replacement: historical overview and future trends

Francesco Baino*

This is the author post-print version of an article published on *Acta Biomaterialia*, Vol. 7, pp. 921-935, 2011 (ISSN 1742-7061).
The final publication is available at
<http://dx.doi.org/10.1016/j.actbio.2010.10.030>
This version does not contain journal formatting and may contain minor changes with respect to the published edition.
The present version is accessible on PORTO, the Open Access Repository of the Politecnico of Torino, in compliance with the publisher's copyright policy.
Copyright owner: *Elsevier*.

*Materials Science and Chemical Engineering Department, Politecnico di Torino, Corso Duca degli
Abruzzi 24, 10129 Torino, Italy.*

*Corresponding author: F. Baino

Phone.: +39 011 564 4668

Fax: +39 011 564 4699

E-Mail: francesco.baino@polito.it

Abstract

The removal of the natural vitreous body from the eye and its substitution with a tamponade agent may be necessary mainly in cases of complicated retinal detachment. Many materials have been variously proposed and tested over the years in an attempt to find an ideal vitreous substitute. This review highlights the evolution of the research in the field of vitreous replacement and chronicles the main advances that have been made in such a context. The suitability and limitations of the vitreous tamponade agents and substitutes in current clinical use are examined, and the promises of experimentally tested biomaterials are described and discussed. Future trends for the research are also considered; specifically, the great potential carried by polymeric hydrogels is emphasized, as they seem to be very effective in closely mimicking the features of the natural vitreous and they could successfully act as long-term vitreous substitutes without inducing clinical complications in the patient's eye.

Keywords: Vitreous substitution; Retinal detachment; Silicone oil; Perfluorocarbons; Polymers; Hydrogels.

1. Introduction

The substitution of the vitreous body is one of the most interesting and challenging field of research in ophthalmology. The surgical treatment of complicated cases of retinal detachment (RD) requires typically the availability of a vitreous tamponade agent able to restore the volume and internal pressure of the ocular globe and to approximate the detached neurosensory retina to the retinal pigment epithelium (RPE). Although over the years a lot of clinical and experimental work has been performed in order to find an appropriate vitreous substitute, at present a truly functional candidate for long-term use does not exist yet. The various disadvantages of the vitreous tamponade agents

clinically used today – sulphur hexafluoride, perfluorocarbon gases, perfluorocarbon liquids, silicone-based oils – led to the investigation of several alternative materials, ranging from donor vitreous to synthetic polymers, in the search for an ideal biomaterial that may be left safely in the vitreous cavity for long-term tamponade.

This article, after giving an overview on the anatomy and physiology of the vitreous body, as well as on the surgical procedures adopted for its substitution, focuses on the materials that are currently employed in the clinical practice or experimentally tested for vitreous replacement. Their suitability, advantages and drawbacks are outlined and extensively discussed; particular emphasis is laid on polymeric insoluble gels, that are the most promising candidates for long-term vitreous replacement. Eventually, some methodological remarks about the need for elaborating standard guidelines to select potential vitreous substitutes are presented at the end of the work.

Table 1 provides a short glossary of the medical terms that are not explained directly in the text, or that may result unclear or unknown to non-specialist readers.

2. The vitreous body: short overview

The key ocular components are shown in Fig. 1, that gives an overview on the anatomy of the eye. The vitreous body (*corpus vitreus*), often termed vitreous humour or simply vitreous, is a clear, transparent gel filling the posterior cavity of the eye and occupying more than two-thirds of the ocular volume [1-3].

2.1. Vitreous embryogenesis

From a developmental viewpoint, it is a common practice to distinguish between “primary” and “secondary” vitreous [4]. The term primary vitreous refers to a particular stage of embryonic development, starting at the third gestational week, in which the hyaloid artery grows into the

vitreous cavity from the optic nerve head towards the crystalline lens. This vascular system ramifies and fans out to occupy almost the whole vitreous cavity. At the end of the sixth gestational week, the development of the secondary vitreous (avascular vitreous) begins. Traditional theories argued that the primary vitreous is compressed by newly formed tissue originating near the retina and expanding towards the centre of the vitreous cavity; this tissue, *i.e.* the secondary vitreous, forms the definitive vitreous and remains in the eye after birth [4]. Usually, the hyaloid artery and its branches disappear almost completely before birth, leaving a clear central zone through the vitreous termed Cloquet's canal, that would represent the area of contact between primary and secondary vitreous. Occasionally, the artery may not fully regress (condition called "persistent hyaloid artery"); more commonly, small remnants of the artery may remain and be seen sometimes as floaters by the patient.

Modern theories, which were recently presented in detail by Ponsioen *et al.* [5], have introduced the concept of interactive remodeling of the vitreous: during embryonic development, the human vitreous body is described as a highly dynamic matrix in which the primary vitreous is gradually replaced by the secondary vitreous, thereby rejecting the concept of a strict spatial separation between the two.

During the fourth gestational month the zonular system or "tertiary" vitreous is produced at the level of the developing ciliary body. The zonules are the ligaments suspending the crystalline lens and enabling it to change shape for near or distant vision (visual accommodation). The definition of tertiary vitreous is not related to a subsequent developmental stage of the secondary vitreous, but it was coined due to the intimate association between the zonular system (Fig. 1) and the vitreous body.

2.2. Features and functions of the vitreous

In human adults the vitreous weights approximately 4 g, has a density of 1.0053-1.0089 g cm⁻³, a refractive index (RI) of 1.3345-1.3348 and its pH ranges within 7.0-7.4 [1-3]. The vitreous is a composite gel mainly composed of water (98-99 %wt.), collagen fibres (type II, V/XI, VI and IX), glycosaminoglycans (primarily hyaluronic acid) and other non-collagenous structural proteins (opticon, fibrillin), together with hyalocytes (90%) and fibroblasts (10%) near the vitreous cortex. Hyaluronan molecules are not uniformly distributed within the vitreous but their highest concentration was found in the posterior vitreous cortex [6]. Furthermore, hyaluronic acid is present in polydisperse populations consisting of molecules of varying hydrodynamic size, which may account for its viscoelastic properties [7].

From a structural viewpoint, the vitreous is a fascinating result of natural evolution as the collagen fibres provide a rigid scaffold while the hyaluronan macromolecules impart shock-absorbing properties to the whole system. Comprehensive pictures of the supramolecular organization of the vitreous gel were provided elsewhere [2,3,5,8]; furthermore, a detailed overview on vitreous remodeling and its relation with collagen turnover was recently presented by Ponsioen *et al.* [5]. Details on the viscoelastic and mechanical properties of the human vitreous were reported by Zimmermann [9] and Lee *et al.* [10], whereas the rheological properties of the animal (porcine and bovine) vitreous were carefully assessed by Nickerson *et al.* [11].

From an anatomical viewpoint, to the best of the author's knowledge the most appropriate and fascinating description of the vitreous body was given by Worst and co-workers, who developed the fascinating concept of "cisternal anatomy" of the vitreous [4,12].

From a functional viewpoint, the vitreous protects the surrounding structures and tissues during mechanical trauma, allows the circulation of metabolic solutes and nutrients throughout the eye, regulates the oxygen tension within the eye, contributes to maintain the shape of the ocular globe and keeps the crystalline lens and the retina in place.

2.3. Aging of the vitreous

With age, the vitreous mass gradually shrinks and collapses in the course of a phenomenon called syneresis, that may eventually lead to posterior vitreous detachment (PVD) [13,14]. PVD is a degenerative process in which the vitreous cortex detaches from the retina. The collagen fibres of the vitreous are held apart by electrical charges but, with ageing, these repulsive charges tend to reduce: therefore, the fibres may clump together and the hyaluronan molecules, previously located around the collagen fibres, become dissociated and so they form adjacent liquid lacunae. Vitreous liquefaction can be considered a physiological process: in fact, some post-mortem studies have recently demonstrated that about 50% of the vitreous gel is liquefied in people over 80 [15,16].

PVD may also occur earlier than normal in myopic people, as well as in patients who experienced cataract surgery.

Recent researches have provided new insight about the onset, progression and traction effects of PVD [17]. It was observed that PVD begins in the perifoveal macula and its early stages persist chronically and progress slowly over months to years. Vitreous traction forces resulting from perifoveal PVD with vitreofoveolar adhesion may cause localized cystoid foveal thickening, which may eventually involve the formation of a macular hole. Epiretinal membranes develop from cortical vitreous remnants left on the retinal surface after PVD and play a crucial role, for instance, in promoting RD. In general, PVD may cause problems in the retinal areas where attachment to vitreous is tight, since small, often horseshoe-shaped breaks in the retina can result from persistent tugging and tearing by the vitreous [18-20]. If the retinal hole is not repaired, the vitreous fluid can flow into the sub-retinal space, thereby causing RD.

3. Need, search and surgical procedures for vitreous substitution

Vitreous replacement is necessary if the vitreous body itself becomes dysfunctional, due to various pathological conditions, or in the case of the surgical treatment of complicated RDs.

Essentially, the vitreous may become dysfunctional due to opacification, liquefaction or physical collapse; these pathological conditions may be caused by developmental abnormalities, various inflammatory diseases related to infections or retinal diseases, vitreous haemorrhage, tumours, diabetes or degenerative processes [20-22]. Age-related PVD may be accompanied by vitreous bleeding and it can predispose to RD due to the traction forces developing at the points of tight vitreoretinal adhesion [18-20]. Vitreous damage can be also caused by trauma or the presence of intraocular foreign bodies. All these conditions may result in poor vision or even blindness.

It is necessary to stress further that an intact vitreous is essential to a healthy human eye: in fact, as recently highlighted by Holekamp [23], age-related vitreous alterations, such as its liquefaction, often accompany several ocular diseases. The vitreous gel is known to play a key role in regulating oxygen distribution within the eye; as the gel undergoes age-related liquefaction this function is impaired and the resultant elevated intraocular oxygen tension may lead to oxidative stress within the eye, thereby contributing to disease states such as nuclear cataract and primary open-angle glaucoma.

However, the treatment of a pathological vitreous is not the most common reason for which vitreous substitution is necessary; in fact, it is the treatment of complicated RD cases that primarily requires the need for vitrectomy procedures, *i.e.* the full or partial replacement of the vitreous body (Fig. 2).

Par plana vitrectomy was introduced by Machemer in the early 1970s [24]: it is generally necessary if the surgeon's view of retinal break(s) is hindered by vitreous bleeding, and it is recommended in severe cases of RD, such as tractional RD (TRD) or RD associated with PVR; this surgical technique can be also combined with scleral buckling procedures. The retinal holes are sealed by laser photocoagulation or cryotherapy. The vitreous substitute, injected into the vitreous cavity

during the surgical procedure, should provide tamponade to the neurosensory retina against the RPE and prevent the formation of new vitreoretinal tractions, which might induce retinal re-detachment. In the current clinical practice, surgeons often inject a gas tamponade agent into the vitreous cavity; postoperatively, the gas is gradually replaced by the eye fluid, that can be considered the ideal and physiological vitreous substitute. In cases of RD associated with severe vitreoretinal diseases (PVR), however, the use of a vitreous substitute with appropriate features for prolonged postoperative tamponade is required.

In uncomplicated cases of rhegmatogenous RD (RRD), pneumatic retinopexy may be also used (Fig. 3). This technique, introduced in 1986 by Hilton and Grizzard [25], is less complex than vitrectomy as it does not require vitreous removal and can be performed under local anaesthesia. Pneumatic retinopexy involves the injection of an expansive gas into the vitreous cavity to flatten the retina for allowing the sub-retinal fluid to be pumped out from beneath it. The patient's head is properly positioned so that the gas bubble floats exactly to the detached area and presses against it; cryopexy or laser photocoagulation are used for sealing the retinal tear. The gas bubble is gradually absorbed by the eye while a scar forms around the retinal hole, thereby sealing it securely. The successful retinal reattachment rate associated to pneumatic retinopexy is over 90%, but this procedure can be performed only in selected cases and often repeated operations are necessary, as widely stressed in the literature [26].

Therefore, the search for suitable substitutes that can be left safely in place after vitrectomy is a challenging and attractive field of research in ophthalmology. As outlined by Chirila and co-workers in two fundamental contributions to ophthalmic literature [27,28], an ideal artificial vitreous should fulfil a complex series of requisites; specifically it should be (i) non-toxic and biocompatible with the ocular tissues, (ii) clear and transparent with RI and density similar to those of the natural vitreous, (iii) able to maintain its light transparency postoperatively without undergoing opacification; (iv) biologically and chemically inert, (v) appropriately rigid to act as an effective tamponade agent, (vi) able to allow the transfer of metabolites, proteins and solutes, (vii)

preferably non-absorbable and non-biodegradable in order to be maintained in the vitreous cavity for a period as long as possible (ideally indefinitely), (viii) preferably hydrophilic and insoluble in water, (ix) injectable through a small-gauge needle, (x) able to maintain its properties after injection, (xi) storable and sterilizable without lacking of the above-mentioned properties.

At present, a materials able to fulfill this complex set of requisites does not exist yet, although many experimentations have been carried out over the years and, as stated by Sebag [29], “the history has witnessed the injection of nearly ever imaginable substance into the vitreous”. One of the major issue concerns the ability of the potential substitute to allow the diffusion of oxygen, nutrients and solutes within the eye. As extensively underlined by Laude *et al.* [30], this function becomes essential for those vitrectomized patients who need intravitreal drug therapy for the treatment of neovascular age-related macular degeneration (AMD).

Therefore, it is clear that the design and development of an actual suitable vitreous substitutes is a complex issue, and achieving this will involve close collaboration between synthetic chemists, materials scientists, physicists, biologists and ophthalmic surgeons.

4. First attempts of vitreous replacement: vitreous transplants

Chronologically, healthy animal donor vitreous was the first material used for vitreous replacement at the beginning of the 20th century, when Deutschmann injected calf and rabbit fresh vitreous into human patients’ eyes [31]; later, human donor vitreous [32,33] was also used. Such agents failed as they induced severe inflammation in the patients’ eyes due to immunological response; postoperative complications such as cataract, corneal damage, glaucoma and various retinal diseases were also reported.

5. Vitreous tamponade agents currently used in the clinical practice

Over the years, several materials ranging from gases to liquid agents have been found suitable to replace the vitreous and, therefore, used in human patients. Table 2 collects the materials in current use; they will be examined in detail in the following sections.

5.1. Gases

5.1.1. Air

Air was the first gas to be injected into the eye for reattaching the neurosensory retina to the RPE: in 1911, Ohm [34] injected purified air into the vitreous cavity to treat a RRD case. In 1938, Rosengren reattached a retina by using intravitreal air injection combined with diathermy and drainage of sub-retinal fluid [35]. In 1969, Norton *et al.* highlighted the advantages of this technique for treating giant retinal tears [36]. Although further studies demonstrated that air is not suitable as a long-lasting tamponade agent due to its short residence time (few days), however since the mid 1980s air has been successfully used in some procedures of pneumatic retinopexy [37-39]. Air has been also experimented in conjunction with other vitreous tamponade agents during vitrectomy procedures, for instance in the perfluorocarbon liquids-air exchange [20,40]. Furthermore, air can be used during the so-called D-ACE procedure (Drain, Air, Cryotherapy, Explant) introduced by McLeod and co-workers in the mid 1980s [41].

5.1.2. Sulphur hexafluoride and perfluorocarbon gases

In the 1970s, intravitreal expanding gases began to be used during pars plana vitrectomy procedures. In 1973, Norton first experimented sulphur hexafluoride (SF₆) [42] and found the

persistence of the gas superior to air, that has an intravitreal residence time of only a few days . In 1980 Lincoff *et al.* [43] proposed the use of perfluorocarbon gases (PFCGs), consisting of a hydrocarbon molecule in which all the hydrogen atoms are replaced by fluorine atoms. Various PFCGs were proposed over the years [43-46] but, at present, C₃F₈ is the agent of choice [20]. In general, their advantages with respect to SF₆ include lower required intravitreal injected volumes due to increased expansion and longer persistence thanks to their low solubility [45,46]. Thus, the use of PFCGs may result in a lower rise in initial intraocular pressure (IOP) than that evaluated with SF₆ (acute glaucoma) because of the smaller injected volume; in addition, their increased persistence (from 1 week to 2 months or more depending on the specific PFCG versus 3-4 days of air) allows prolonged tamponade thereby promoting the formation of secure chorioretinal adhesions. The major drawbacks related to gases are the need for patient's post-operative posturing to exert the maximum tamponade effect and the persistence of quite high IOP values that could result in damage to the optic nerve; furthermore, cataract formation and possible damage to ciliary body and retina may occur [20,47,48].

SF₆ and PFCGs have been also used in cases of RD associated to PVR [49,50], but silicone oil was found a more suitable tamponade agent as it led to better clinical outcomes.

SF₆/air and C₃F₈/air mixtures were also experimented: the duration of intraocular gas tamponade could be controlled by varying the concentration of air and other gases. The success rate was similar to that obtained by using SF₆ or PFCGs alone [51,52].

At present, SF₆ and C₃F₈ are the gases of choice for vitreous tamponade; in addition, such gases are also successfully used in pneumatic retinopexy procedures [20,37,53]. Unfortunately, holes located in the inferior retina are not easily amenable to closure by intraocular gases [54].

5.1.3. Occasionally used gases

In the early 1980s, Lincoff *et al.* tested five gases – Argon, Helium, Xenon, N₂O and CO₂ – in rabbits' eyes to evaluate their longevity into the vitreous cavity [55]. Xenon was considered the most promising and it was also used in 4 human patients with successful retinal reattachment in all cases [56]. The major drawback related to Xenon was that it disappeared very rapidly (almost 90% disappeared by 3 hours postoperatively) and, therefore, it was necessary to replace the gas with aqueous solution to ensure an adequate tamponade effect preventing ocular hypotension.

5.2. Liquids

5.2.1. Physiological solutions

Water [57,58] and balanced salts solutions [59] were the first liquids to be injected intravitreally for retinal tamponade. No relevant differences in the clinical outcomes were found in using physiological solutions or donor vitreous. The low viscosity and the short residence time in the vitreous cavity of the physiological solutions prevented an adequate tamponade effect. However, saline solutions are still used after the removal of other tamponade agents such as silicone oil; furthermore, physiological solutions are employed for intravitreal rinses that are necessary, for instance, to ensure a complete removal of perfluorocarbon liquids from the vitreous cavity (see the section 5.2.3.).

5.2.2. Silicone-based oils

Over the years, different types of silicone oil and silicone oil derivatives have been proposed and investigated as vitreous substitutes. The most relevant features of these oils are summarized in Table 3.

The first use of silicone oil for treating RD in humans was attempted in 1962 by Cibis, who encountered some difficulties in managing the oil and reported several postoperative complications [21]. After the development of pars plana vitrectomy in the mid 1970s, the results of the use of silicone oil significantly improved and its use as a long-term vitreous substitute became rather widespread. The features, advantages, drawbacks and indications for use of silicone-based oils for vitreoretinal surgery have been reviewed in detail by Giordano *et al.* in a fundamental treatise of ophthalmic literature [60].

Formally, silicone oils for ophthalmic use are synthetic polymers belonging to the class of polydimethylsiloxanes. As reported in Table 3, the viscosity of the silicone oils varies within a quite wide range, but the agent of choice is generally considered the 5000 cSt oil; in the mid 1990s it was approved by FDA for intravitreal use in the USA and, since then, is marketed worldwide.

Today, silicone oil is usually recommended for long-term retinal support and tamponade; in the past, silicone oil was also used as an intraoperative tool for stabilizing the retina [61] and unrolling the flaps of retinal tears [62], but this use was almost abandoned since perfluorocarbon liquids, which exhibit a higher surface tension at the water interface, have been introduced for intraoperative use in the 1980s (see the section 5.2.3.). It is necessary to underline that the low density of silicone oil in comparison with water and aqueous solutions (Table 3) causes it to float upon residual vitreal fluid, which leads to a reduced or absent tamponade effect in the case of inferior retinal breaks. In aphakic eyes, the eye is usually filled by silicone oil up to the level of the pupil; surgeons must be careful to avoid overfilling and the ANDO iridectomy can be helpful to prevent the pupillary block, the migration of the oil in the anterior chamber of the eye and the

development of postoperative glaucoma, kerathopathy and other complications [63-65]. Many studies have suggested the use of silicone oil as the preferred choice in the case of long-standing RRD, TRD, giant retinal tears and RD caused by proliferative diabetic retinopathy (PDR) [66-81]. In addition, silicone oil is usually employed in the first surgical procedure in patients unable to position for gases, with need to air travel immediately after surgery [82] or suffering from AIDS and related retinal complications [83,84].

Although in most cases silicone oil is well-tolerated by ocular tissues, its use in vitreoretinal surgery has been repeatedly castigated, and the controversy about its actual suitability as a long-term vitreous substitute still lingers on. On one hand, silicone oil is a very promising candidate for prolonged vitreous substitution as it can be retained indefinitely in the vitreous cavity without losing its optical transparency and chemical inertness; in addition, it can provide extended retinal tamponade and is considered to prevent postoperative iris neovascularisation [74,79,82,85,86]. On the other hand, however, there is convincing evidence that silicone oil can induce severe long-term complications in the patient's eye, such as glaucoma, cataract, corneal damage and the so-called "silicone retinopathy" [60,87,88]. In these cases the surgical removal of the silicone oil is necessary, but any remaining amount might be retained indefinitely in the eye. Retinal re-detachment may also occur after the removal of silicone oil [89]. In the last two decades, the incidence of the various complications has been progressively reduced by the improvement of oil purification technologies (the residual components of polymerization reactions were demonstrated to be toxic [90]), the advances in surgical techniques and the possibility of treating successfully most of these postoperative diseases. Several evidences have suggested that the main cause of the above-mentioned complications is not an intrinsic oil toxicity – which is a typical feature of the low molecular weight monomers and polymerization residues [90] – but an abnormal cells behaviour caused by the emulsification and dispersion of the silicone oil [91,92]. In fact, the cells in contact with the oil may incorporate silicone vesicles, whose presence can interfere with the transport of

metabolites. The emulsification rate, being related to fluid viscosity, can be successfully reduced by employing oils with viscosity higher than 5000 cSt.

Therefore, although silicone oil exhibits very suitable properties for vitreous substitution, it should be used in very critical or desperate cases, preferably for temporary vitreous replacement and, in general, only when the other surgical procedures showed to be unsuccessful.

Besides the silicone oil, it is necessary to mention the use of other two silicone-based oil, *i.e.* poly(methyl-3,3,3-trifluoropropylsiloxane) (fluorosilicone oil) and poly(methyl-3,3,3-trifluoropropylsiloxane-*co*-dimethylsiloxane) (silicone/fluorosilicone copolymer oil), that are often referred to as second-generation silicone oils.

Fluorosilicone oil exhibits properties similar to those of silicone oil, but has a higher emulsification rate and a lower intraocular tolerance: in fact, complications that have been associated with silicone oil also occur with fluorosilicone oil, but within a shorter time period [92-94]. Fluorosilicone oil, being heavier than water (Table 3), was used to flatten the retina intraoperatively with the patient in prone position for displacing the sub-retinal fluid thanks to the difference of density. In addition, fluorosilicone oil was successfully used for extended tamponade of inferior retinal breaks [93,94].

Silicone/fluorosilicone copolymer oil is a polysiloxane derivative that was investigated especially by Refojo's group [95,96]. It was used for the intraoperative fixation of the retina, for short-term vitreous substitution and as a vehicle for the intravitreal release of drugs preventing PVR [95-97].

Likewise fluorosilicone oil, silicone/fluorosilicone copolymer oil is heavier than silicone oil (Table 3) and, therefore, can be successfully used in cases of inferiorly or posteriorly located retinal breaks.

In comparison with silicone oil, silicone/fluorosilicone copolymer oil has a lower viscosity (Table 3), which facilitates the oil injection into the eye, as well as its removal. The use of silicone/fluorosilicone copolymer oil for prolonged vitreous substitution induced unwanted side effects similar or more serious to those observed in presence of perfluorocarbon liquids (see the section 5.2.3.). Doi *et al.* injected silicone/fluorosilicone copolymer oil into rabbits eyes [96]; after 6 months of retinal tamponade, they found the disappearance of the outer plexiform layer and the

disorganization of the photoreceptor layer. Therefore, the authors suggested the use of silicone/fluorosilicone copolymer oil only as an intraoperative tool or for short-term retinal tamponade (< 2 months) [96].

Finally, it is interesting to mention a clever approach suggested by Dailey *et al.* [98], who attempted to overcome the problem of poor surface tension by using magnetic silicone-based fluid as a vitreous substitute coupled with a magnetic band (scleral buckle) around the eye. The magnetic field resulting from the scleral buckle would contribute to maintain the vitreous substitute, in which metal nanoparticles were dispersed, in contact with the retina. However, it can not be ignored that magnetic iron, cobalt, nickel and rare-earth metals are all potentially toxic to ocular tissues. Therefore, the toxicity of constituents and the possible removal of the buckle after successful retinal reattachment are crucial issues that should be carefully taken into account in future studies.

5.2.3. Perfluorocarbon liquids

Perfluorocarbon liquids (PFCLs) are colourless and odourless; the most relevant properties of the three PFCLs marketed for vitrectomy procedures are reported in Table 4. The first use of PFCLs for vitreous substitution was reported in 1984 by Miyamoto *et al.*, who injected perfluoroether in rabbit eyes; however, this tamponade agent was deemed unsuitable as a long-term vitreous substitute as it induced the formation of preretinal membranes, retinal disorganization and eventual RD after remaining in the vitreous cavity from 4 to 6 months [99]. Chang *et al.* tested perfluorotributylamine as a long-term vitreous substitute in rabbit eyes and also found unwanted side effects such as retinal disorganization and cells deposition in the vitreous cortex and in the posterior crystalline lens [100]. Therefore, researchers' attention was drawn by the use of PFCLs only as intraoperative tools. In 1988 PFCLs were first used in human eyes as an adjunct in the management of RDs associated with PVR [101]. Since then, PFCLs have been successfully employed in the intraoperative management of RRDs complicated by PVR [102-104] and giant retinal tears [105-107], and TRD in PDR

[108,109]; in addition, they were also used as short-term postoperative vitreous substitutes in particularly complicated RD cases [110,111]. PFCLs were also successfully used in the management of suprachoroidal haemorrhages [112].

It is important to further stress that PFCLs should not be used for prolonged vitreous substitution. As already mentioned, the early experimental studies in rabbits where PFCLs were used for long-term vitreous substitution showed the occurrence of severe complications [99,100]. However, if PFCLs were removed from 2 to 4 days after instillation, no significant side effects were observed; for instance, no morphological changes in the retina were observed in animal models by using pigs [113] and monkeys [114]. The use of PFCLs in human eyes, thanks to the development of appropriate surgical procedures, has generally led to few postoperative complications; if PFCLs are used as short-term postoperative tamponade agents, unfortunately a second operation for their removal is unavoidable for the patient.

There have been some case reports in which retinal damage has been attributed to intravitreal [115-117] or sub-retinal retention [118-121] of PFCLs both in animal models and in humans. In fact, in spite of an apparently adequate removal of PFCL at the end of the surgical procedure, PFCL bubbles may remain in the vitreous cavity postoperatively. Residual PFCL can be detected, for instance, by ophthalmic ultrasound analysis; patients with remaining intravitreal PFCL must be carefully monitored to detect any sign of retinal toxicity, and an additional procedure should be performed to remove the residual PFCL bubbles. In presence of RRD with severe PVR or TRD with massive proliferation, the penetration of PFCL into the sub-retinal space may be an additional risk, especially with large retinotomies [121]; in that case, a careful PFCL-air or PFCL-physiological solution exchange must be performed, as well as drainage/active aspiration through the same retinotomy or through an additional one.

The postoperative complications related to PFCLs seem to be due to their high density (Table 4), resulting in mechanical damage to cells through compression and extensive emulsification, rather than to an intrinsic toxicity of the material [122]. In addition to retinal damage, other reported

complications include postoperative glaucoma due to retained intravitreal PFCL in human eyes [116,120] and corneal toxicity (loss of endothelial cells, stromal inflammation, neovascularisation) in aphakic rabbit eyes [115].

Weinberger *et al.* also reported the case of seven patients with PFCL droplets in the anterior chamber; after a 9-month follow-up, however, no signs of corneal damage or intraocular toxicity were detected [123].

5.2.4. Semifluorinated alkanes and heavy oils

The use of semifluorinated alkanes (SFAs) in vitreoretinal surgery is relatively new. Many evidences seem to indicate that SFAs can offer the potential to act as long-term vitreous substitutes. These materials consist of short alkyl chains joined at one end or both ends to a perfluorocarbon chain, thereby corresponding to the general formulas $F(CF_2)_n(CH_2)_mH$ and $F(CF_2)_n(CH_2)_m(CF_2)_nF$ ($n, m = 3-20$ in both cases), respectively. SFAs are colourless (RI ~ 1.3), immiscible with water and physically, chemically, physiologically inert [124]. Generally, SFAs are less viscous (kinematic viscosity ~ 2.5 cSt) than the other currently used intravitreal materials (Table 3 and Table 4); in addition, they can be more easily handled than silicone-based oils and their density ($1.1-1.7$ g cm⁻³) is lower than that of PFCLs [124-126]. SFAs are approved for clinical use in Europe and they are mainly marketed as biocompatible solvents for silicone oil; in addition, it was demonstrated that SFAs can be successfully used as such as intraoperative tools for unfolding and reattaching the retina [127,128] and as long-term vitreous tamponade agents [129,130]. Optically clear mixtures of silicone oil and SFAs (the so-called “heavy oils” or third-generation silicone oils), with typical density ranging within $1.0-1.3$ g cm⁻³, have been also successfully tested in the treatment of complicated RD cases (Table 5). For instance, Densiron-68[®] was recently found to be safe and effective both in the treatment of primary inferior RRD cases [131] and in the reoperation of persisting macular holes [132]. Long-term tamponade by using this heavy oil resulted in a high

anatomic success and was generally accompanied by a functional improvement of patients' visual acuity [131-134] and mild postoperative complications [135]. Also the recently experimented HWS 46-3000 was well tolerated by ocular tissue and its use was accompanied by a high rate of success in treating complicated RD cases [136]. On the contrary, Oxane HD was found unsuitable for clinical use due to the relevant incidence of adverse effects including oil emulsification, glaucoma and cataract [137-139]. A comprehensive review about the use of heavy oils in vitreoretinal surgery was recently published by Heimann *et al.* [140].

Furthermore, Meinert *et al.* underlined that SFAs carry the great potential of acting as solvents for intravitreal drugs that could be released *in situ* postoperatively [126].

There are many reasonable evidences that both SFAs as such and, particularly, some heavy oils can be considered very promising candidates for long-term vitreous substitution thanks to their attractive characteristics, including good retinal tolerance [141] and reduced emulsification with respect to silicone oil [142]. At least ideally, they could successfully replace the agents currently adopted for vitreous substitution, but they are not in common use yet.

6. Towards an ideal artificial vitreous: polymers mimicking the features of natural vitreous

The drawbacks and limitations related to the currently used vitreous substitutes have led to the investigation of a wide variety of materials in the search for an ideal artificial vitreous. Table 6 lists the various candidates that have been experimentally proposed from the mid 1950s up to now: to the best of the author's knowledge, none of them has been approved for clinical use.

According to the author's view, the researchers have essentially tried to duplicate the natural vitreous by following two approaches: (i) bio-mimicry of the chemical composition of the natural vitreous, in an attempt to reproduce its structure and properties; (ii) bio-mimicry of the peculiar features of the natural vitreous, rather than its composition or structure. The final aim was to find an appropriate biomaterial to be left *in situ* safely and indefinitely without undergoing degradation

and/or losing its physico-mechanical features. The first approach, involving the use of modified natural polymers, substantially failed: some potential substitutes for short-term use have been suggested, but the various studies have demonstrated that is impossible to duplicate Nature and to make up a “natural” vitreous artificially. Therefore, the researchers’ attention has been progressively drawn by synthetic polymers, that are chemically different from natural vitreous but are potentially able to mimic its physico-mechanical properties.

The following sections give an overview about the potential vitreous substitutes tested in both approaches. In the mid 1990s, Chirila and co-workers extensively reviewed the early attempts of vitreous replacement by using hydrophilic polymers [27,28], and in 2000 Colthurst *et al.* [143] gave an overview on new advances; more recently, part of a review on the biomaterials used in the treatment of RD was dedicated to this topic, but such a work was still incomplete [144]. The history and performances of experimental polymers are now exhaustively reviewed, and the advances of the last decade, as well as the promises for the future, are particularly highlighted.

6.1. First approach: compositional/structural bio-mimicry

6.1.1. Hyaluronic acid

Hyaluronic acid and its derivatives, such as sodium hyaluronate, have been widely tested as vitreous substitutes in humans since the early 1960s [145]. The choice of hyaluronic acid seemed rather reasonable as it is one of the two major components – together with collagen – of the natural vitreous. Sodium hyaluronate is commercially available in a wide range of solutions for pharmaceutical use, and it showed an excellent biocompatibility and tolerance in ocular tissues. However, these solutions were found unsuitable for prolonged postoperative vitreous tamponade due to their short residence time in the vitreous cavity [146].

6.1.2. Gelatin and collagen

Gelatin is a collagen derivative marketed worldwide in various forms. Such as hyaluronic acid, the use of this material was suggested by the fact that collagen is present in the composition of natural vitreous.

In 1966, Oosterhuis and co-workers implanted polygeline, a polymer of urea and polypeptides derived from degraded gelatin, in rabbits' eyes [147]. Further studies in humans [148] showed that the material ($RI = 1.3390$, $M_w = 35$ kDa) was well-tolerated in all cases without adverse tissue reactions and the immediate retinal reattachment was achieved in most of the patients. However, polygeline exhibited a short retention time in the vitreous cavity and a rapid decrease of its viscosity. The attempts to increase the material viscosity by adding gelatin, agar, methylcellulose and poly(ethylene glycol) caused inflammation in ocular tissues and vitreous opacification. Therefore, polygeline was deemed suitable only as a short-time vitreous substitute. Despite the good biocompatibility and optical properties, there has been no other studies about the ocular use of polygeline.

In the last 1960s proctase-treated collagen gel was also tested for vitreous replacement in animal models. Studies in rabbits by Stenzel *et al.* [149] and in monkeys by Dunn *et al.* [150] showed that collagen did not elicit adverse effects in ocular tissues except for a mild transient inflammation.

In the early 1970s, Pruett and co-workers tested collagen gels in human patients [151,152]: a moderate inflammation of ocular tissues was reported, together with other severe complications related to clinical outcomes; only 19% of the cases exhibited retinal reattachment and all patients had blurred vision due to vitreous opacification. In addition the gel underwent fragmentation during injection, thereby decreasing its mechanical properties.

More recently, some of these drawbacks were overcome by using methylated type I/III collagen [153,154]. After material implantation in rabbits' eye, no inflammation and no vitreous/lens/cornea

opacification were detected; however, the poor tamponade effect due to low surface tension made this polymer unsuitable for RD treatment.

6.1.3. Hyaluronate/collagen gel mixture

A special mention should be dedicated to the so-called “reconstituted vitreous”, a mixture of sodium hyaluronate and collagen that are the two major structural components of the vitreous body. The basic idea, proposed in the 1960s by Balazs *et al.* [155], was very fascinating since the researchers’ aim was to mimic Nature by duplicating both the composition and the structure of the natural vitreous. After injection at low temperature (~10 °C) the mixture underwent gelification *in situ* at body temperature. However, *in vivo* studies revealed problems of gel hazing during postoperative follow-up and, occasionally, ocular tissue inflammation; in addition, the material was completely bioabsorbed within 5 months after implantation.

More recently, Nakagawa *et al.* injected different formulations of hyaluronate/collagen gels into rabbits eyes [153]; however, these gels were not considered suitable for long-term vitreous substitution due to their water solubility and, therefore, their tendency to become viscous solutions rather than gels over time, thereby producing a poor tamponade effect on the retina.

6.1.4. Hyaluronic acid/gellan gum gel

In 2006, Suri *et al.* suggested the use of a mixture of hyaluronic acid and gellan gum for vitreous replacement [156]. Gellan gum formed a gel at room temperature and the gel structure was maintained also at the body temperature. *In vitro* cytotoxicity tests by using mouse fibroblast cells showed an excellent biocompatibility (cells viability > 90%). However, the rheological and mechanical properties were found dramatically insufficient with respect to those of natural vitreous. An attempt to improve the mechanical properties of the gel was also done by adding CaCl₂ to the

gellan gum/HA mixture in order to obtain a highly cross-linked hydrogel, but further studies are necessary. However, the gel does not seem suitable for long-term tamponade as it degrades after 1 week of soaking in simulated body fluids.

6.1.5. Occasionally tested polysaccharides

Various solutions of different polysaccharides, *e.g.* dextran, dextran sulphate, sodium alginate, alginic acid and chondroitin sulphate, were occasionally tested as vitreous substitutes in animal models and humans [157,158]. No or mild inflammation was usually reported, but often the vitreous underwent hazing and the materials failed to reattach the retina due to their poor tamponade effect.

6.2. Second approach: functional bio-mimicry

6.2.1. Poly(1-vinyl-2-pyrrolidone)

Chronologically, poly(1-vinyl-2-pyrrolidone) (PVP) was the first synthetic polymer to be tested as a potential vitreous substitute. In 1954, Scuderi [159] injected variable amounts of PVP solutions in rabbits' eyes; no histological adverse reaction was reported, but problems of opacification occurred. In 1959, Hayano and Hoshino tested PVP solutions with different dilution rates in human eyes with RRD [160]: PVP induced less inflammatory reactions than physiological solutions but no data about polymer retention in the vitreous cavity were reported. No other studies about the use of PVP solutions are available in the literature.

More recently, Chirila and co-workers performed a careful selection of PVP gels on the basis of their viscoelastic properties; eventually, the 1-vinyl-2-pyrrolidone (VP) monomer was polymerized with divinyl glycol (DVG) as cross-linking agent to obtain a transparent (RI = 1.3390) hydrogel

with density and viscosity very similar to those of human vitreous [161,162]. The cross-linked PVP was implanted in rabbits' eyes: no damage to the retina was detected, but vitreous opacification occurred; in addition, the polymer underwent biodegradation due to phagocytosis [163]. VP was also copolymerized with 2-hydroxyethyl methacrylate (HEMA) using DVG or diallyl ether (DAE) as cross-linking agents and the so-obtained hydrogel was implanted in rabbits' eyes [164]. The resulting gel was clear, transparent, insoluble in water and exhibited mechanical properties close to those of natural vitreous. From a clinical viewpoint, no adverse effects were detected after implantation, except for transient vitreous opacities. However, the process of injection via a small-gauge needle caused polymer fragmentation resulting in a decrease in the hydrogel mechanical properties. Furthermore, all eyes were characterized by the presence of inflammatory cells and vacuoles containing granular material, which indicates that material underwent phagocytosis [163]. Dalton *et al.* performed a detailed study on selected cross-linked PVP-based polymers and suggested that rheological analysis can provide useful eliminatory criteria in the selection of potential vitreous substitutes [165].

6.2.2. Polyacrylamide

Although acrylamide as such is highly toxic, after complete polymerization the resulting polymer exhibits a good biocompatibility; obviously, the presence of residual monomer can have dramatic effects *in vivo* on patients' health.

In 1968, Muller-Jensen *et al.* [166] reported several clinical trials concerning the use of polyacrilamide (PAA) as a vitreous substitute in rabbits' eyes. The monomers were polymerized directly inside the vitreous cavity without using cross-linking agents: irritation was observed in all cases in the course of the first postoperative days and the vitreous underwent opacification at high PAA concentrations; however, no histological degeneration was observed within 3 months after implantation. Cross-linked PAA was also implanted in rabbits' eyes after *in situ* polymerization

with better clinical outcomes [167]: the material was well-tolerated by tissues and remained clear after 14 months from implantation. In 1973, Refojo *et al.* [168] reported a detailed investigation about the optical properties of cross-linked PAA.

For many years, no further study performed about the use of PAA as potential vitreous substitute; in the mid 2000s, acrylamide and bisacryloylcistamine (BAC) were copolymerized with disulfide cross-linking agents by Ravi and co-workers [169-173]. The use of disulfide cross-linkers allowed to obtain a high purification of the final polymer by removing all the residual monomers. Two procedures are possible for implantations: the gels can be formed directly in the eye, or else the final polymer can be injected into the vitreous cavity without undergoing fragmentation or loss of elasticity and mechanical properties, as demonstrated by preliminary tests carried out by using cadaver human eyes or *ex vivo* porcine eyes as recipients [169,173]. Furthermore, *in vitro* tests showed that the biocompatibility of the gel can be further improved by adding N-phenylacrylamide (hydrophobic monomer) [170]. These promising results justify further investigations about the suitability of PAA as artificial vitreous.

6.2.3. Poly(glyceryl methacrylate)

In 1968, Refojo and co-workers first used poly(glyceryl methacrylate) (PGMA) as a vitreous substitute [174]. Spherical pieces of dehydrated PGMA were implanted in rabbits' vitreous cavities through a small surgical incision and the implants swelled *in situ* after contact with vitreous fluids, thereby reaching postoperatively volumes up to 32 times greater than the initial ones in the dry state. The hydrogel was found highly biocompatible (no inflammations or clinical complications were detected), but PGMA was eventually considered unsuitable for clinical use as its implantation was too traumatic; furthermore, its swelling was too slow, thereby causing problems of immediate tamponade.

In 1976, Hogen-Esch *et al.* synthesized an injectable PGMA hydrogel using very low amounts of cross-linking agents [175]. The gel was able to absorb up to 96%wt. of saline solution and, after swelling remained soft and sufficiently transparent. Although a slight loss of light transmittance was assessed, the final RI (1.3364) was still very close to that of natural vitreous. After implantation in rabbits' eyes, good clinical outcomes without complications were observed; however, as the hydrogel underwent fragmentation upon injection, no further studies were carried out on PGMA as a vitreous substitute.

6.2.4. *Poly(2-hydroxyethyl methacrylate)*

In the early 1970s Refojo implanted poly(2-hydroxyethyl methacrylate) (PHEMA) solid pieces in rabbits' eyes [176]. PHEMA was well-tolerated by ocular tissues, did not elicit retinal damages and did not undergo bioabsorption or biodegradation. It was insoluble in water and, being solid, could maintain its position postoperatively in the vitreous cavity better than a liquid agent. However, its implantation required difficult and often too traumatic surgical procedures and, therefore, it was no longer investigated.

6.2.5. *Poly(2-hydroxyethyl acrylate)*

In the early 1980s Chan *et al.* tested poly(2-hydroxyethyl acrylate) (PHEA) as a potential vitreous substitute in rabbits' eyes [177]. The hydrogel exhibited excellent physical properties, such as high transparency, viscosity similar to that of natural vitreous, non-absorbability and easy injectability, which made it, also theoretically, an ideal artificial vitreous. However, some adverse effects were reported: in fact, PHEA induced corneal oedema, glaucoma, damage to the lens as well as its opacification, formation of fibrous membranes in the vitreous cavity and severe retinal complications. Therefore, the material was considered unsuitable for clinical use.

6.2.6. Hydroxypropyl methylcellulose

In 1990, Fernandez-Vigo *et al.* injected a solution of hydroxypropyl methylcellulose (HPMC) (viscosity ~6000 cSt, $M_w = 86$ kDa) in rabbits' eyes [178]: HPMC was completely eliminated from the vitreous cavity within 10 weeks after implantation and, therefore, HPMC solutions were deemed unsuitable both for long-term vitreous replacement and for sealing retinal holes in RRD due to the lacking of tamponade effect. However, the excellent biocompatibility of HPMC encourage the same research group to perform another animal study in which they demonstrated that it was possible to control and tailor the residence time of HPMC in the vitreous cavity by varying its molecular weight [179]. Specifically, by using a product with $M_w = 120$ kDa and viscosity ~6000 cSt the half-life time of the substitute was 38 days; nonetheless, such a substitute was still unsuitable for prolonged tamponade.

6.2.7. Pluronic F127

Pluronic F127 (P-F127) solutions at concentration of 20%wt. and above show thermoreversible gelation behaviour [180]: for instance, a 20%wt. P-F127 solution is liquid when cold, but forms a clear gel ($RI = 1.032$) at 21°C as the solution is heated. In spite of their attractive physical properties, P-F127 solutions were found to be unsuitable for vitreous substitution: in fact, in 1990 Davidorf *et al.* [181] showed that the polymer can induce severe retinal toxicity and, therefore, it was considered unsuitable for clinical use.

6.2.8. Poly(vinyl alcohol)

In 1991, Benlian *et al.* first selected poly(vinyl alcohol) (PVA) as a potential vitreous substitute on the basis of its optical properties [182]. The preliminary results after implantation in rabbits' eyes were promising, as no inflammation or damage to the retina was detected after 2 months of follow-up.

In 1991 Yamauchi *et al.* [183] also reported an extensive investigation on autoclave-sterilized PVA hydrogels consisting of 99% wt. of water. The gels were produced by γ -irradiation of a 7%wt. PVA solution and then injected into rabbits' eyes; a comparison of performance with respect to saline solution was also reported. Inflammation and long-term vitreous opacification occurred more frequently with PVA than with physiological solutions. The short-time optical properties were excellent, as the gels were indistinguishable from the host vitreous during the first postoperative weeks. A mixture of PVA/chondroitin sulphate was also experimented: it displayed a transparency superior to that of PVA as such and absorbed more water than PVA alone, but it was found less biocompatible in rabbits' eyes.

In 2006, Maruoka *et al.* [184] prepared PVA hydrogels by treating the polymer solution in autoclave before γ -irradiation and injected the so-obtained gels into monkeys' eyes. During the first postoperative weeks, ocular inflammation and IOP increase occurred; after 3 months of implantation the eyes regained normal IOP and retinal activity.

In 2010, Leone *et al.* synthesized PVA hydrogels using different amounts of trisodium trimetaphosphate (TSTMP) as cross-linking agent [185]. The authors performed a very comprehensive characterization of the materials, including light transmittance, water content assessment, rheological measurements (oscillatory shear stress analysis, shear creep analysis and thixotropic properties) and *in vitro* cytotoxicity assays; in addition, the diffusion behaviour of the hydrogel by using a model solute was assessed. All these tests seemed to show that the hydrogel with molar ratio TSTMP/PVA = 1 : 8 fulfilled the requirements for a good vitreous substitute.

Due to their good optical properties, rheological features and long-term biocompatibility PVA hydrogels are promising candidates for vitreous substitution, but further studies need to be

performed to collect more data about their retention time, mechanical properties and ability to reattach the retina.

6.2.9. Silicone gel

In 1992, Peyman *et al.* [186] injected silicone gel in monkeys' eyes; specifically, two polymer formulations – clear and cloudy gels – were tested. The liquid monomers were injected into the vitreous cavities and polymerization occurred *in situ*. Apart from a minimal inflammation lasting for 1 week postoperatively, no other adverse effects were reported. No retinal damage was detected, both gels maintained their cohesiveness and, specifically, the clear gel remained transparent postoperatively. However, silicone gels were hydrophobic: therefore, they exerted a very poor tamponade effect on the retina remaining separated from it. Therefore, silicone gels were deemed unsuitable for the treatment of RD cases.

6.2.10. Poly(methyl 2-acrylamidoglycolate methyl ether)

In 1995, Chirila *et al.* performed a careful selection among several polymers derived from (methyl 2-acrylamidoglycolate methyl ether) as potential vitreous substitute [187]. Eventually, the homopolymer poly(methyl 2-acrylamidoglycolate methyl ether) (PMAGME), synthesized in 80%wt. of water and without cross-linking agents, was selected for *in vivo* tests in rabbits. Negligible fragmentation upon injection was observed, but severe postoperative clinical complications were reported, including RD, inflammation and damage to the optic nerve. The cause of the toxic effect remained unclear, as it could be due to the polymer itself or, maybe more reasonably, to residual toxic acrylamide. The authors first reported the results of *in vitro* studies using mouse fibroblast cells, that revealed the cytostatic and cytotoxic effect of the hydrogel [187].

For the first time, *in vitro* cytotoxicity assay was suggested as an important criterion for preliminary selection of biomaterials as potential vitreous substitutes.

6.2.11. Adcon[®]-L hydrogel

In 2000, De Jong *et al.* [188] reported in one study the use of Adcon[®]-L hydrogel for vitreous substitution in the right eye of 5 rabbits. Adcon[®]-L hydrogel – a polymer of proteoglycans esters in porcine gelatin – is highly biocompatible and it is currently used in neurosurgery without unwanted side effects. However, this materials was found unsuitable as a vitreous substitute, as severe postoperative complications were reported. In fact, the obtained results suggested a potential retinal toxicity of this hydrogel, as well as such as an important and persistent postoperative inflammation reaction. Other reported complications were cornea opacification in 2 rabbits and cataract in all rabbits; in addition, the biodegradation rate of the hydrogel was rather fast and it had totally disappeared from the vitreous cavity after 3 weeks.

6.2.12. Poly(vinyl alcohol methacrylate)

In 2004, Cavalieri *et al.* [189] carried out preliminary investigations on poly(vinyl alcohol methacrylate) (PVA-MA) to test its potential suitability as a vitreous substitute. The polymer contained a photoinitiator and the gel network could be formed by irradiation at 365 nm; the degree of cross-linking could be tailored by varying the photoinitiator concentration and the radiation exposure time. PVA-MA was found able to gel *in situ*; specifically, gelification did not occur at polymer concentrations lower than 4%wt. *In vitro* tests by using bovine serum showed that hydrogel degradation occurred in presence of a low cross-linking degree. Therefore, potentially suitable PVA-MA hydrogels were deemed to be those synthesized at high polymer concentrations and with a high degree of cross-linking; however, such gels were found to be significantly stiffer

than natural vitreous. Further studies addressed at reducing this mismatch between the mechanical properties of PVA-MA and those of natural vitreous are needed to understand whether such a material remains a valid contender for vitreous substitution.

6.3. A meeting point between the two approaches: a promise for the future

As mentioned above, maybe the major limitation of the modified-natural polymers is their short residence time in the vitreous cavity and poor tamponade effect, which makes them unsuitable in the treatment of RD cases. The development of hyaluronic acid and gelatin hydrogels could provide a new class of substitutes combining a composition similar to that of the natural vitreous with appropriate physico-mechanical properties, degradation kinetics and tamponade ability.

6.3.1. Cross-linked hyaluronic acid

In the early 1990s, Balazs and co-workers developed the so-called “hylan gel”, obtained by cross-linking sodium hyaluronate by divinyl sulphone or formaldehyde [190]. The gel, tested in rabbits and monkeys, was water-insoluble and biocompatible; however it could enter the sub-retinal space through retinal breaks due to its insufficient coherence.

Very recently, promising results were achieved by Su *et al.* [191], who synthesized an hydrogel formed by oxidated hyaluronic acid cross-linked with adipic acid dihydrazide (ADH). The refractive index of the final hydrogel ranged within 1.3420-1.3442, which is quite similar to that of human vitreous. *In vitro* degradation tests showed that the hydrogel maintain the gel matrix over 35 days, depending on the ADH concentration. Interestingly, the cytotoxicity was evaluated by using RPE cells and the materials was found to be non-toxic. In addition, the hydrogel was injected into the vitreous cavity of rabbits' eyes: no adverse reactions were detected after 3 weeks. Further tests

on the mechanical properties of the gel are necessary, but these preliminary results make it an interesting candidate as a potential long-term vitreous substitute.

6.3.2. Cross-linked gelatin

In 2010, Lai investigated in detail the ocular biocompatibility of two chemically modified gelatin hydrogels [192]. These materials were proposed as aqueous humour substitutes and matrices for controlled drug delivery; potential application in the context of vitreous replacement may be also deemed. The gelatin base was cross-linked with glutaraldehyde (GTA) or 1-ethyl-3-(3-dimethyl aminopropyl)carbodiimide (EDAC); a significant inflammatory reaction was elicited by the presence of GTA-treated material, whereas the gelatin cross-linked with EDAC exhibited good biocompatibility and were well-tolerated without eliciting adverse effects. These preliminary results warrant further studies, particularly to assess the potential residence time of the gelatin hydrogel in the vitreous cavity.

7. Hydrogels: the best candidates for vitreous substitution?

The existing literature demonstrates that, ideally, optically transparent and biocompatible solutions of several polymers can be successfully used as short-term vitreous substitutes without inducing clinical postoperative complications in the patient's eye. On the contrary, the search for a suitable biomaterial to be used as a long-term substitute is a more complex issue. Essentially, the major problem is to find an appropriate formulation that can be left *in situ* indefinitely without unwanted long-term side effects requiring the removal of the substitute. An ideal candidate as an artificial vitreous should closely mimic the light transmittance of the natural vitreous humour, as well as its physical and mechanical properties; most importantly, it should not change its features postoperatively. Polymeric hydrogels seem to be promising materials for long-term vitreous

replacement, as they generally show excellent transparency, are highly biocompatible and can act as viscoelastic shock-absorbing materials, thereby closely mimicking the behaviour of natural vitreous. By acting on the formulation and synthesis process of the hydrogel, the density and rigidity of the final vitreous substitute could be properly tailored in order to match those of natural vitreous. In addition, some experimentally tested hydrogels can gel after injection into the vitreous cavity, thereby avoiding gel fragmentation due to shear stresses during injection via small-gauge needles. An interesting approach to solve this dramatic problems was proposed very recently by Ravi and co-workers [169,173], who studied the *in situ* regelation of PAA gels. Finally, hydrogels might be used as smart matrices for controlled drug release within the vitreous cavity of patients suffering from serious intravitreal affections, such as PVR.

At present, cross-linked PVA [184,185] and PAA [169,173] seem to be the most promising candidates as long-term vitreous substitutes, and, therefore, they are undoubtedly worthy of further investigation and experimentation in the next years.

8. Criteria and guidelines for selecting suitable vitreous substitutes

Over the years, many substances have been proposed as potential candidates for vitreous substitution but in most cases they were selected according to ambiguously defined criteria. In general, ease of injection and good optical transparency (before and after injection) have been considered the primary criteria of choice, but often no systematic investigation of the biocompatibility of the potential vitreous substitute, as well as of the injection-induced changes in its rheological properties has been carried out prior to *in vivo* tests.

In the mid 1990s, Chirila *et al.* [187] in a study about PMAGME suggested for the first time the use of *in vitro* cytotoxicity test as an eliminatory criterion in the selection of polymers as potential vitreous substitutes; such tests are also useful because they avoid unnecessary animal experiments. Another important eliminatory criterion starts from the consideration that the natural vitreous body

possesses viscoelastic properties: therefore, a potential candidate for prolonged vitreous substitution should be viscoelastic and exhibit rheological properties similar to those of the natural vitreous. Under this viewpoint, cross-linked gels showed to be very suitable for vitreous replacement. However, a serious problem has to be considered: the shear stresses due to the procedure of polymer injection into the vitreous cavity causes a large deformation of the gel, that may exhibit physical properties different from those displayed before injection. A detailed study of Dalton *et al.* clearly demonstrated that a careful rheological analysis plays a crucial role in the selection of hydrogels as vitreous substitutes [165]. Specifically, the effect of the gel injection through small-gauge needles should be investigated, since it can have detrimental consequences on the mechanical properties of the polymer.

In the next years, it would be very useful to elaborate a standard and detailed protocol for selecting and testing the materials proposed as potential vitreous substitutes. Very recently, Leone *et al.* published a comprehensive and actually complete research work about the suitability of different cross-linked PVA hydrogels for vitreous replacement [185]. By taking this work as a starting point and on the basis of the suggestions provided over the years by other authors [27,165], it is possible to draft an ideal testing protocol that should include the following investigations before eventual *in vivo* experimentations:

- (i) light transmittance (for instance by UV-vis spectrophotometry);
- (ii) assessment of the kinetics of hydration, water uptake and swelling (for instance, by weight measurements);
- (iii) rheological measurements: oscillatory shear stress analysis, shear creep analysis and thixotropic properties (a rheometer is necessary for such analyses);
- (iv) assessment of the diffusion coefficient of a model solute (for instance by means of NMR spectroscopy, as done for the first time by Leone *et al.* in a pilot study [185]);
- (v) *in vitro* biocompatibility, cells proliferation and cells viability (the appropriate ISO standard should be followed [193]; the cell type for preliminary tests could be mouse

fibroblasts, as already done by Chirila *et al.* [165], Suri *et al.* [156], Leone *et al.* [185], or RPE cells as done by Su *et al.* [191];

- (vi) evaluation of the possible degradation of the vitreous substitute during injection: *ex vivo* animal or human cadaver eyes could be used, as done by Ravi and co-workers [169,173].

9. Conclusions

The replacement of the vitreous body is a challenging but also complex issue of ophthalmic research. Although several and various substances have been proposed over the years as potential vitreous substitutes, at present only silicone oil is used in the clinical practice for long-term vitreous substitution, although it may induce several clinical complications. Gases are used as temporary vitreous substitutes, and PFCLs are recommended for intraoperative use only during vitrectomy procedures. The future of vitreous substitutes is to find an appropriate biomaterial that can be left *in situ* indefinitely without long-term complications. Primarily, an ideal artificial vitreous should mimic the light transmittance and the mechanical properties of the natural vitreous. Polymeric hydrogels seem to be promising materials for long-term vitreous replacement, as they exhibit excellent transparency, are highly biocompatible and can act as viscoelastic shock-absorbers, thereby closely mimicking the behaviour of the natural vitreous. By acting on the formulation and synthesis process of the hydrogels, the density and rigidity of the final vitreous substitute could be tailored in order to match those of natural vitreous. Furthermore, it has been demonstrated that some hydrogels can undergo *in situ* gelation after injection into the vitreous cavity, thereby avoiding unwanted injection-induced changes in the final gel. Eventually, hydrogels may be also used as matrices for intravitreal drug release. On the basis of studies performed in the literature up to now, cross-linked PVA and PAA seem to be the most promising candidates, but they were not yet approved for clinical use.

Another class of very attractive substances comprises SFAs and the so-called “heavy oils” (mixtures of silicone oil and SFAs), that in the last decade have been successfully experimented in the management of primary and persistent RRD cases with very good long-term clinical outcomes. Further studies about the potential and performances of these tamponade agents are currently in progress, but they are already marketed worldwide and used by several ophthalmic surgeons in the clinical practice.

The development in the next years of a standard protocol for selecting and investigating potential vitreous substitutes would be very desirable, as it would be an useful tool for the researchers working on this topic.

Acknowledgements

Dr. Daniela Dolcino, Head of the Ophthalmology Ward at “SS. Antonio e Biagio” Hospital of Alessandria (Italy), is gratefully acknowledged for strongly stimulating and supporting the author in writing this article. Prof. Pietro Rossi, Head of the Ophthalmology Ward at “San Martino” Hospital of Genova (Italy), is kindly acknowledged for his actually essential help.

Note of the author

This articles belongs to a series of contributions written as a festschrift in honour of Prof. Giuseppe Heer to celebrate his 60 years of clinical activity (and on occasion of his 85th birthday). Prof. Heer, Head Emeritus of the Ophthalmology Ward at “Maria Vittoria” Hospital of Turin (Italy) and President of the Italian Foundation against the Retinopathies of Prematurity, has been a pioneer of vitreoretinal surgery.

References

- [1] Gloor BP. The vitreous. In: Moses RA, Hart WM, editors. *Adler's Physiology of the Eye*. St. Louis: The CV Mosby Co.; 1987. p. 246-67.
- [2] Sebag J. Macromolecular structure of the corpus vitreus. *Prog Polym Sci* 1998;23:415-46.
- [3] Chirila TV, Hong Y. The vitreous humour. In: Black J, Hastings GW, editors. *Handbook of Biomaterial Properties*. London: Chapman & Hall; 1998. p. 125-31.
- [4] Worst JGF, Los LI. *Cisternal anatomy of the vitreous*. Amsterdam: Kugler Publication; 1995.
- [5] Ponsioen TL, Hooymans JMM, Los LI. Remodelling of the human vitreous and vitreoretinal interface – a dynamic process. *Prog Retinal Eye Res*, in press.
- [6] Le Goff MM, Bishop PN. Adult vitreous structure and postnatal changes. *Eye* 2008;22:1214-22.
- [7] Noulas AV, Skandalis SS, Feretis E, Theocharis DA, Karamanos NK. Variations in content and structure of glycosaminoglycans of the vitreous gel from different mammalian species. *Biomed Chromatogr* 2004; 18:457-61.
- [8] Bishop PN. Structural macromolecules and supramolecular organisation of the vitreous gel. *Prog Retinal Eye Res* 2000;19:323-44.
- [9] Zimmerman RL. In vivo measurements of the viscoelasticity of the human vitreous humor. *Biophys J* 1980;29:539-44.
- [10] Lee B, Litt M, Buchsbaum G. Rheology of the vitreous body. Part I: Viscoelasticity of human vitreous. *Biorheology* 1992;29:521-33.
- [11] Nickerson CS, Park J, Kornfield JA, Karageozian H. Rheological properties of the vitreous and the role of hyaluronic acid. *J Biomech* 2008;41:1840-6.
- [12] Jongebloed WL, Worst JF. The cisternal anatomy of the vitreous body. *Doc Ophthalmol* 1987;63:183-96.
- [13] Byer NE. Natural history of posterior vitreous detachment with early management as the premier line of defense against retinal detachment. *Ophthalmology* 1994;101:1503-14.

- [14] Los LI, Van Der Vorp RJ, Van Luyn MJA, Hooymans JMM. Age-related liquefaction of vitreous body: LM and TEM evaluation of the role of proteoglycans and collagen. *Invest Ophthalmol Vis Sci* 2003;44:2828-33.
- [15] Chuo JY, *et al.* Risk factors for posterior vitreous detachment: a case-control study. *Am J Ophthalmol* 2006;142:931-7.
- [16] Diaz-Llopis M, Cervera E. Posterior vitreous detachment and pharmacological vitreolysis: the new age of enzymatic vitrectomy. *Arch Soc Esp Oftalmol* 2007;82:465-6.
- [17] Johnson MW. Posterior vitreous detachment: evolution and complications of its early stages. *Am J Ophthalmol* 2010;149:371-82.
- [18] D'Amico DJ. Medical progress – diseases of the retina. *N Engl J Med* 1994;331:95-106.
- [19] Ciulla TA, Danis RP, Harris A. Age-related macular degeneration: a review of experimental treatments. *Surv Ophthalmol* 1998;43:134-46.
- [20] Brinton DA, Wilkinson CP. *Retinal Detachment – Principles and Practice*. Oxford: University Press Inc.; 2009.
- [21] Cibis PA. *Vitreoretinal Pathology and Surgery in Retinal Detachment*. St Louis: The CV Mosby Co.; 1965.
- [22] Fuller DG, Hutton WL. *Presurgical Evaluation of Eyes with Opaque Media*. New York: Grune & Stratton; 1982.
- [23] Holekamp N. The vitreous gel: more than meets the eye. *Am J Ophthalmol* 2010;149:32-6.
- [24] Machemer R. The development of pars plana vitrectomy: a personal account. *Graefes Arch Clin Exp Ophthalmol* 1995;233:453-68.
- [25] Hilton GF, Grizzard WS. Pneumatic retinopexy: a two-step outpatient operation without conjunctival incision. *Ophthalmology* 1986;93:626-41.
- [26] Tornambe PE. Pneumatic retinopexy: the evolution of case selection and surgical technique. A twelve-year study of 302 eyes. *Trans Am Ophthalmol Soc* 1997;95:551-78.

- [27] Chirila TV, Tahija S, Hong Y, Vijayasekaran S, Constable IJ. Synthetic polymers as materials for artificial vitreous body: review and recent advances. *J Biomater Appl* 1994;9:121-37.
- [28] Chirila TV, Hong Y, Dalton PD, Constable IJ, Refojo MF. The use of hydrophilic polymers as artificial vitreous. *Prog Polym Sci* 1998;23:475-508.
- [29] Sebag J. *The Vitreous – Structure, Function and Pathobiology*. New York: Springer; 1989.
- [30] Laude A, Tan LE, Wilson CG, Lascaratos G, Elashry M, Aslam T, Patton N, Dhillon B. Intravitreal therapy for neovascular age-related macular degeneration and inter-individual variations in vitreous pharmacokinetics. *Prog Ret Eye Res*, in press.
- [31] Deutschmann R. Zur Operativen Behandlung der Netzhautablosung. *Klein Monstbl Augenheilkd* 1906;44:364-70.
- [32] Cutler NL. Vitreous transplantation. *Trans Am Acad Ophthalmol Otolaryngol* 1947;52:253-9.
- [33] Shafer DM, Bussey JL. Further experience with vitreous implants in old retinal detachments. *Arch Ophthalmol* 1958;60:255-7.
- [34] Ohm, J. Ueber die Behandlung der Netzhautablosung durch operative Entleerung der subretinalen Flüssigkeit und Einspritzung von Luft in den Glaskörper. *Graefes Arch Clin Ophthalmol* 1911;79:442-50.
- [35] Rosengren B. Results of treatment of detachment of the retina with diathermy and injection of air into the vitreous. *Acta Ophthalmol* 1938;16:573-9.
- [36] Norton EWD, Aaberg T, Fung W, Curtin VT. Giant retinal tears. I. Clinical management with intravitreal air. *Trans Am Ophthalmol Soc* 1969;67:374-93.
- [37] Marcus DM, D'Amico DJ, Mukai S. Pneumatic retinopexy versus scleral buckling for repair of primary rhegmatogenous retinal detachment. *Int Ophthalmol Clin* 1994;34:97-108.
- [38] Algvere PV, Gjotterberg M, Olivestedt G, Fitori S. Results of pneumatic retinopexy with air. *Acta Ophthalmol* 1992;70:632-6.
- [39] Sebag J, Tang M. Pneumatic retinopexy using only air. *Retina* 1993;13:8-12.

- [40] Wong D, Williams RL, German MJ. Exchange of perfluorodecalin for gas or oil: a model for avoiding slippage. *Graefes Arch Clin Exp Ophthalmol* 1998;236:234-7.
- [41] Gilbert C, McLeod D. D-ACE surgical sequence for selected bullous retinal detachments. *Br J Ophthalmol* 1985;69:733-6.
- [42] Norton EWD. Intraocular gas in the management of selected retinal detachments. *Trans Am Acad Ophthalmol Otolaryngol* 1973;77:85-98.
- [43] Lincoff HA, Mardirossian J, Lincoff A, Liggett P, Iwamoto T, Jakobiec F. Intravitreal longevity of three perfluorocarbon gases. *Arch Ophthalmol* 1980;98:1610-1.
- [44] Lincoff H, Maisel JM, Lincoff A. Intravitreal disappearance rates of four perfluorocarbon gases. *Arch Ophthalmol* 1984;102:928-9.
- [45] Chang S, Lincoff H, Coleman DJ, Fuch W, Farber M. Perfluorocarbon gases in vitreous surgery. *Ophthalmology* 1985;92:651-6.
- [46] Crittenden JJ, De Juan E, Tiedeman J. Expansion of long-acting gas bubbles for intraocular use. *Arch Ophthalmol* 1985;103:831-4.
- [47] Van Horn DL, Edelhauser HF, Aaberg TM, Pederson HJ. In vivo effects of air and sulphur hexafluoride gas on rabbit corneal endothelium. *Invest Ophthalmol* 1972;11:1028-36.
- [48] Juzoji H, Iwasaki T, Usui M, Hasemi M, Yamakawa N. Histological study of intraocular changes in rabbits after intravitreal gas injection. *Jpn J Ophthalmol* 1997;41:278-83.
- [49] Lean JS, Boone DC, Azen SP, Lai MY, Linton KLP, McCuen B, Ryan SJ. Silicone Study Group: Vitrectomy with silicone oil or sulphur hexafluoride gas in eyes with severe proliferative vitreoretinopathy. Results of a randomized clinical trial (Silicone Study Report No. 1). *Arch Ophthalmol* 1992;110:770-9.
- [50] McCuen B, Azen SP, Boone DC, Lai MY, Linton KLP, Lean J, Ryan SJ. Silicone Study Group: Vitrectomy with silicone oil or perfluoropropane gas in eyes with severe proliferative vitreoretinopathy. Results of a randomized clinical trial (Silicone Study Report No. 2). *Arch Ophthalmol* 1992;110:780-92.

- [51] Constable IJ, Swann DA. Vitreous substitution with gases. *Arch Ophthalmol* 1975;93:416-9.
- [52] Thompson JT. The absorption of mixtures of air and perfluoropropane after pars plana vitrectomy. *Arch Ophthalmol* 1992;110:1594-7.
- [53] Bochow TW, Olk RJ, Hershey JM. Pneumatic retinopexy perfluoroethane (C₂F₆) in the treatment of rhegmatogenous retinal detachment. *Arch Ophthalmol* 1992;110:1723-4.
- [54] Chang TS, Pelzek CD, Nguyen RL, Purohit SS, Scott GR, Hay D. Inverted pneumatic retinopexy: a method of treating retinal detachments associated with inferior retinal breaks. *Ophthalmology* 2003;110:589-94.
- [55] Lincoff A, Lincoff H, Solorzano C, Iwamoto T. Selection of xenon gas for rapidly disappearing retinal tamponade. *Arch Ophthalmol* 1982;100:996-7.
- [56] Lincoff H, Kreissig I. Applications of xenon gas to clinical retinal detachment. *Arch Ophthalmol* 1982;100:1083-5.
- [57] Elschnig A. Uber Glaskorperersatz: II. Teil. *Graefes Arch Ophthalmol* 1912;80:514-36.
- [58] Wood DJ. Detached retina. *Br J Ophthalmol* 1920;4:413-5.
- [59] Grafton EG, Guyton JS. The value of injecting saline into the vitreous as an adjunct to diathermy operations for retinal detachment. *Am J Ophthalmol* 1948;31:299-303.
- [60] Giordano GG, Refojo MF. Silicone oils as vitreous substitutes. *Prog Polym Sci* 1998;23:509-32.
- [61] Scott JD. The treatment of massive vitreous retraction by the separation of preretinal membranes using liquid silicone. *Mod Probl Ophthalmol* 1975;15:285-90.
- [62] Cibis PA, Becker B, Okun E, Canaan S. The use of liquid silicone in retinal detachment surgery. *Arch Ophthalmol* 1962;68:590-9.
- [63] Ando F. Intraocular hypertension resulting from substitut block by silicone oil. *Am J Ophthalmol* 1985;99:87-8.

- [64] Beekhuis WH, Ando F, Zivojnovic R, Mertens DA, Peperkamp E. Basal iridectomy at 6 o'clock in the aphakic eye treated with silicone oil: prevention of keratopathy and secondary glaucoma. *Br J Ophthalmol* 1987;71:197-200.
- [65] Madreperla SA, McCuen BW. Inferior peripheral iridectomy in patients receiving silicone oil. Rates of postoperative closure and effect on oil position. *Retina* 1995;15:87-90.
- [66] Grey RHB, Leaver PK. Silicone oil in the treatment of massive preretinal retraction. I. Results in 105 eyes. *Br J Ophthalmol* 1979;63:355-60.
- [67] Leaver PK, Grey RH, Garner A. Silicone oil injection in the treatment of massive preretinal retraction. II. Late complications in 93 eyes. *Br J Ophthalmol* 1979;63:361-7.
- [68] Leaver PK, Cooling RJ, Feretis EB, Lean JS, McLeod D. Vitrectomy and fluid/silicone-oil exchange for giant retinal tears: results at six months. *Br J Ophthalmol* 1984;68:432-8.
- [69] Gonvers M. Temporary silicone oil tamponade in the management of retinal detachment with proliferative vitreoretinopathy. *Am J Ophthalmol* 1985;100:239-45.
- [70] Ando F, Miyake Y, Oshima K, Yamanaka A. Temporary use of intraocular silicone oil in the treatment of complicated retinal detachment. *Graefes Arch Clin Exp Ophthalmol* 1986;224:32-3.
- [71] McCuen BW, Landers MB, Machemer R. The use of silicone oil following failed vitrectomy for retinal detachment with advanced proliferative vitreoretinopathy. *Graefes Arch Clin Exp Ophthalmol* 1986;224:38-9.
- [72] Cox MS, Trese MT, Murphy PL. Silicone oil for advanced proliferative vitreoretinopathy. *Ophthalmology* 1986;93:646-50.
- [73] Glaser BM. Treatment of giant retinal tears combined with proliferative vitreoretinopathy. *Ophthalmology* 1986;93:1193-7.
- [74] McLeod D. Silicone-oil injection during closed microsurgery for diabetic traction retinal detachment. *Graefes Arch Clin Exp Ophthalmol* 1986;224:55-9.

- [75] Rinkoff JS, De Juan E, McCuen BW. Silicone oil for retinal detachment with advanced proliferative vitreoretinopathy following failed vitrectomy for proliferative diabetic retinopathy. *Am J Ophthalmol* 1986;101:181-6.
- [76] Lucke KH, Foerster MH, Laqua H. Long-term results of vitrectomy and silicone oil in 500 cases of complicated retinal detachments. *Am J Ophthalmol* 1987;104:624-33.
- [77] Yeo JH, Glaser BM, Michels RG. Silicone oil in the treatment of complicated retinal detachments. *Ophthalmology* 1987;94:1109-13.
- [78] Sell CH, McCuen BW, Landers MB, Machemer R. Long-term results of successful vitrectomy with silicone oil for advanced proliferative vitreoretinopathy. *Am J Ophthalmol* 1987;103:24-8.
- [79] Gonvers M. Temporary silicone oil tamponade in the treatment of complicated diabetic retinal detachment. *Graefes Arch Clin Exp Ophthalmol* 1990;228:415-22.
- [80] Wolf S, Schon V, Meier P, Wiedemann, P. Silicone oil-RMN3 mixture (“heavy silicon oil”) as internal tamponade for complicated retinal detachment. *Retina* 2003;23:335-42.
- [81] Er H. Primary heavy silicone oil usage in inferior rhegmatogenous retinal detachment. *Ophthalmologica* 2010;224:122-5.
- [82] Lewis H, Aarberg TM. Causes of failure after repeat vitreoretinal surgery for recurrent proliferative vitreoretinopathy. *Am J Ophthalmol* 1991;111:15-9.
- [83] Orellana J, Teich SA, Lieberman RM, Restrepo S, Peairs R. Treatment of retinal detachments in patients with the acquired immune deficiency syndrome. *Ophthalmology* 1991;98:939-43.
- [84] Irvine A, Lonn L, Schwartz D, Zarbin M, Ballesteros F, Kroll S. Retinal detachment in AIDS: long term results after repair with silicone oil. *Br J Ophthalmol* 1997;81:180-3.
- [85] Heimann K, Dahl B, Dimopoulos S, Lemmen KD. Pars plana vitrectomy and silicone oil injection in proliferative diabetic retinopathy. *Graefes Arch Clin Exp Ophthalmol* 1989;227:152-6.
- [86] Federman JL, Eagle RC. Extensive peripheral retinectomy combined with posterior 360 degrees retinotomy for retinal reattachment in advanced proliferative vitreoretinopathy cases. *Ophthalmology* 1990;97:1305-20.

- [87] Federman JL, Schubert HD. Complications associated with the use of silicone oil in 150 eyes after retina-vitreous surgery. *Ophthalmology* 1988;95:870-6.
- [88] Borislav D. Cataract after silicone oil implantation. *Doc Ophthalmol* 1993;83:79-82.
- [89] Jonas JB, Knorr HLJ, Rank RM, Budde VM. Retinal redetachment after removal of intraocular silicone oil tamponade. *Br J Ophthalmol* 2001;85:1203-7
- [90] Pastor JC, Zarco JM, Delnozaj MJ, Pampliega A, Marinero P. Clinical consequences of the use of highly purified silicone oil – comparative study of highly and less purified silicone oil. *Eur J Ophthalmol* 1998;8:179-83.
- [91] Ohira A, Wilson CA, De Juan E, Murata Y, Soji T, Oshima K. Experimental retinal tolerance to emulsified silicone oil. *Retina* 1991;11:259-65.
- [92] Versura P, Cellini M, Torreggiani A, Bernabini B, Rossi A, Moretti M, Caramazza R. The biocompatibility of silicone, fluorosilicone and perfluorocarbon liquids as vitreous tamponades. *Ophthalmologica* 2001;215:276-83.
- [93] Gremillion CM, Peyman GA, Chen MS, Chang KB. Fluorosilicone oil in the treatment of retinal detachment. *Br J Ophthalmol* 1990;74:643-6.
- [94] Yamamoto S, Takeuchi S. Silicone oil and fluorosilicone. *Semin Ophthalmol* 2000;15:15-24.
- [95] Doi M, Refojo MF. Histopathology of rabbit eyes with intravitreal silicone-fluorosilicone copolymer. *Exp Eye Res* 1994;59:737-46.
- [96] Doi M, Refojo MF. Histopathology of rabbit eyes with silicone-fluorosilicone copolymer oil as 6 month internal retinal tamponade. *Exp Eye Res* 1995;61:469-78.
- [97] Araiz JJ, Refojo MF, Arroyo MH, Leong FL, Albert DM, Tolentino FI. Antiproliferative effect of retinoic acid in intravitreal silicone oil in an animal model of proliferative vitreoretinopathy. *Invest Ophthalmol Vis Sci* 1993;34:522-30.
- [98] Dailey JP, Philips JP, Li C, Riffle JS. Synthesis of silicone magnetic fluid for use in eye surgery. *J Magn Magn Mater* 1999;194:140-8.

- [99] Miyamoto K, Refojo MF, Tolentino FI, Fournier GA, Albert DM. Perfluoroether liquid as a long-term vitreous substitute. An experimental study. *Retina* 1984;4:264-268.
- [100] Chang S, Zimmerman NJ, Iwamoto T, Ortiz R, Faris D. Experimental vitreous replacement with perfluorotributylamine. *Am J Ophthalmol* 1987;103:29-37.
- [101] Chang S, Ozmert E, Zimmerman NJ. Intraoperative perfluorocarbon liquids in the management of proliferative vitreoretinopathy. *Am J Ophthalmol* 1988;106:668-674.
- [102] Stolba U, Binder S, Velikay M, Datlinger P, Wedrich A. Use of perfluorocarbon liquids in proliferative retinopathy: results and complications. *Br J Ophthalmol* 1995;59:1106-10.
- [103] Loewenstein A, Humaryun MS, De Juan E Jr, Campochiaro PA, Haller JA. Perfluoroperhydrophenanthrene versus perfluoro-*n*-octane in vitreoretinal surgery. *Ophthalmology* 2000;107:1078-82.
- [104] Scott IU, Flynn HW Jr, Murray TG, Fewer VJ. Outcomes of surgery for retinal detachment associated with proliferative vitreoretinopathy using perfluoro-*n*-octane: a multicenter study. *Am J Ophthalmol* 2003;136:454-63.
- [105] Schulman JA, Peyman GA, Blinder KJ, Alturki WA, Desai UR, Nelson NC Jr. management of giant retinal tears with perfluoroperhydrophenanthrene (Vitreon). *Jpn J Ophthalmol* 1993;37:70-7.
- [106] Ie D, Glaser BM, Sjaarda RN, Thompson JT, Steinberg LE, Gordon LW. The use of perfluoro-*n*-octane in the management of giant retinal tears without proliferative vitreoretinopathy. *Retina* 1994;14:323-8.
- [107] Scott IU, Murray TG, Flynn HW Jr, Feuer WJ, Schiffman JC. Outcomes and complications associated with giant retinal tear management using perfluoro-*n*-octane. *Ophthalmology* 2002;109:1828-33.
- [108] Itoh R, Ijeda T, Sawa H, Kulzumi K, Yasuhara T, Yamamoto Y, Kusada E. The use of perfluorocarbon liquids in diabetic vitrectomy. *Ophthalmic Surg Lasers* 1999;30:672-5.

- [109] Imamura Y, Minami M, Ueki M, Satoh B, Ikeda T. Use of perfluorocarbon liquid during vitrectomy for severe proliferative diabetic retinopathy. *Br J Ophthalmol* 2003;87:563-6.
- [110] Bottoni F, Sborgia M, Arpa P, De Casa N, Bertazzi E, Monticelli M, De Molfetta V. Perfluorocarbon liquids as postoperative short-term vitreous substitutes in complicated retinal detachment. *Graefes Arch Clin Exp Ophthalmol* 1993;231:619-28.
- [111] Rofail M, Lee LR. Perfluoro-*n*-octane as a postoperative vitreoretinal tamponade in the management of giant retinal tears. *Retina* 2005;25:897-901.
- [112] Desai UR, Peyman GA, Chen CJ, Nelson NC, Alturki WA, Blinder KJ, Paris CL. Use of perfluoroperhydrophenanthrene in the management of suprachoroidal hemorrhages. *Ophthalmology* 1992;99:1542-7.
- [113] Flores-Aguilar M *et al.* Intraocular tolerance of perfluorooctylbromide (perflubrom). *Retina* 1995;15:3-13.
- [114] Conway MD, Peyman GA, Karacorlu M, Bhatt N, Soike KF, Clark LC Jr, Hoffmann RE. Perfluorooctylbromide (PFOB) as a vitreous substitute in non-human primates. *Int Ophthalmol* 1993;17:259-64.
- [115] Moreira H, De Queiroz JM Jr, Liggett PE, McDonnell PJ. Corneal toxicity study of two perfluorocarbon liquids in rabbit eyes. *Cornea* 1992;11:376-9.
- [116] Foster RE, Smiddy WS, Alfonso EC, Parrish RK. Secondary glaucoma associated with retained perfluorophenanthrene. *Am J Ophthalmol* 1994;118:253-5.
- [117] Batman C, Cekic O. Effect of the long-term use of perfluoroperhydrophenanthrene on the retina. *Ophthalmic Surg Lasers* 1998;29:144-6.
- [118] De Queiroz JM Jr, Blanks JC, Ozler SA, Alfaro DV, Liggett PE. Subretinal perfluorocarbon liquids: An experimental study. *Retina* 1992;12:33-9.
- [119] Lee GA, Finnegan SJ, Bourke RD. Subretinal perfluorodecalin toxicity. *Aust N Z Ophthalmol* 1998;26:57-60.
- [120] Lesnoni G, Rossi T, Gelso A. Subfoveal liquid perfluorocarbon. *Retina* 2004;24:172-6.

- [121] Garcia-Valenzuela E, Ito Y, Abrams GW. Risk factors for retention of subretinal perfluorocarbon liquid in vitreoretinal surgery. *Retina* 2004;24:746-52.
- [122] Peyman GA, Schulman JA, Sullivan B. Perfluorocarbon liquids in ophthalmology. *Surv Ophthalmol* 1995;39:375-95.
- [123] Weinberger D, Goldenberg-Cohen N, Axer-Siegel R, Gatton DD, Yassur Y. Long-term follow-up of perfluorocarbon liquid in the anterior chamber. *Retina* 1998;18:233-7.
- [124] Zeana D, Becker J, Kuckelkorn R, Kirchhof B. Perfluorohexyloctane as a long-term vitreous tamponade in the experimental animal. Experimental perfluorohexyloctane substitution. *Int Ophthalmol* 1999;23:17-24.
- [125] Wong D, Lois N. Perfluorocarbons and semifluorinated alkanes. *Semin Ophthalmol* 2000;15:25-35.
- [126] Meinert H, Roy T. Semifluorinated alkanes – A new class of compounds with outstanding properties for use in ophthalmology. *Eur J Ophthalmol* 2000;10:189-97.
- [127] Kobuch K, Menz DH, Hoerauf H, Dresch J, Gabel VP. New substances for intraocular tamponades: perfluorocarbon liquids, hydrofluorocarbon liquids and hydrofluorocarbon liquids in vitreoretinal surgery. *Graefes Arch Clin Exp Ophthalmol* 2001;239:635-42.
- [128] Roider J, Hoerauf H, Kobuch K, Gabel VP. Clinical findings on the use of long-term heavy tamponades (semifluorinated alkanes and their oligomers) in complicated retinal detachment surgery. *Graefes Arch Clin Exp Ophthalmol* 2002;240:965-71.
- [129] Jonas JB, Jger M. Perfluorohexyloctane endotamponade for treatment of persisting macular hole. *Eur J Ophthalmol* 2003;13:103-4.
- [130] Kirchhof B, Wong D, Van Meurs J, Hilgers RD, Macek M, Lois N, Schrage NF. Use of perfluorohexyloctane as a long-term internal tamponade agent in complicated retinal detachment surgery. *Am J Ophthalmol* 2002;133:95-101.

- [131] Romano MR, Stappler T, Marticorena J, Groenewald C, Pearce I, Gibran SK, Wong D, Heimann H. Primary vitrectomy with Densiron-68 for rhegmatogenous retinal detachment. *Graefes Arch Clin Exp Ophthalmol* 2008;246:1541-6.
- [132] Lappas A, Foerster AMH, Kirchof B. Use of heavy silicone oil (Densiron-68[®]) in the treatment of persistent macular holes. *Acta Ophthalmol* 2009;87:866-70.
- [133] Wong D, Van Meurs JC, Stappler T, Groenewald C, Pearce IA, McGalliard JN, Manousakis E, Herbert EN. A pilot study on the use of a perfluorohexyloctane/silicone oil solution as a heavier than water internal tamponade agent. *Br J Ophthalmol* 2005;89:662-5.
- [134] Auriol S, Pagot-Mathis V, Mahieu L, Lemoine C, Mathis A. Efficacy and safety of heavy silicone oil Densiron 68 in the treatment of complicated retinal detachment with large inferior retinectomy. *Graefes Arch Clin Exp Ophthalmol* 2008;246:1383-9.
- [135] Li W, Zheng J, Zheng Q, Wu R, Wang X, Xu M. Clinical complications of Densiron 68 intraocular tamponade for complicated retinal detachment. *Eye* 2010;24:21-8.
- [136] Rizzo S, Genovesi-Ebert F, Vento A, Cresti F, Di Bartolo E, Belting C. A new heavy silicone oil (HWS 46-3000) used as a prolonged internal tamponade agent in complicated vitreoretinal surgery: a pilot study. *Retina* 2007;27:613-20.
- [137] Lai WW, Wong D, Li KK, Leow PL. Emulsification and inverted hypopyon formation of oxane HD in the anterior chamber. *Graefes Arch Clin Exp Ophthalmol* 2008;246:1633-5.
- [138] Wickham L, Tranos P, Hiscott P, Charteris D. The use of silicone oil-RMN3 (Oxane HD) as heavier-than-water internal tamponade in complicated inferior retinal detachment surgery. *Graefes Arch Clin Exp Ophthalmol* 2010;248:1225-31.
- [139] Meng Q, Zhang S, Cheng H, Chen X, Jin Y. Long-term outcomes of Oxane HD as intraocular tamponade in the treatment of complicated retinal detachments. *Graefes Arch Clin Exp Ophthalmol* 2010;248:1091-6.
- [140] Heimann H, Stappler T, Wong D. Heavy tamponade 1: a review of indications, use, and complications. *Eye* 2008;22:1342-59.

- [141] Mackiewicz J *et al.* In vivo retinal tolerance of various heavy silicone oils. *Invest Ophthalmol Vis Sci* 2007;48:1873-83.
- [142] Caramoy A, Schroder S, Fauser S, Kirshhof B. In vitro emulsification assessment of new silicone oils. *Br J Ophthalmol* 2010;94:509-12.
- [143] Colthurst MJ, Willimas RL, Hiscott PS, Grierson I. Biomaterials used in the posterior segment of the eye. *Biomaterials* 2000;21:649-65.
- [144] Bairo F. The use of polymers in the treatment of retinal detachment: current trends and future perspectives. *Polymers* 2010;2:286-322.
- [145] Hruby K. Hyaluronic acid as vitreous body substitute in retinal detachment. *Klein Monstbl Augenheilkd* 1961;138:484-96.
- [146] Pruett RC, Schepens CL, Swann DA. Hyaluronic acid vitreous substitute: a six-year clinical evaluation. *Arch Ophthalmol* 1979;97:2325-30.
- [147] Oosterhuis JA, Van Haeringen NJ, Jeltse IG, Glasius E. Polygeline as vitreous substitute: I. Observations in rabbits. *Arch Ophthalmol* 1966;76:258-65.
- [148] Oosterhuis JA. Polygeline as a vitreous substitute: II. Clinical results. *Arch Ophthalmol* 1966;76:374-7.
- [149] Stenzel KH, Dunn MW, Rubin AL, Miyata T. Collagen gels: design for a vitreous replacement. *Science* 1969;164:1282-3.
- [150] Dunn MW, Stenzel KH, Rubin AL, Miyata T. Collagen implants in the vitreous. *Arch Ophthalmol* 1969;82:840-4.
- [151] Pruett RC, Calabria GA, Schepens CL. Collagen vitreous substitute: I. Experimental study. *Arch Ophthalmol* 1972;88:540-3.
- [152] Pruett RC, Schepens CL, Freeman HM. Collagen vitreous substitute: II. Preliminary clinical trials. *Arch Ophthalmol* 1974;91:29-32.
- [153] Nakagawa M, Tanaka M, Miyata T. Evaluation of collagen gel and hyaluronic acid as vitreous substitutes. *Ophthalmic Res* 1997;29:409-20.

- [154] Liang CP, Peyman GA, Serracarbassa P, Calixto N, Chow AA, Rao P. An evaluation of methylated collagen as a substitute for vitreous and aqueous humour. *Int Ophthalmol* 1998;22:13-8.
- [155] Balazs EA, Sweeney DB. The replacement of the vitreous body in the monkey by reconstituted vitreous and by hyaluronic acid. *Bibl Ophthalmol* 1966;70:230-2.
- [156] Suri S, Banerjee R. In vitro evaluation of in situ gels as short term vitreous substitutes. *J Biomed Mater Res A* 2006;79:650-64.
- [157] Kishimoto M, Yamanouchi U, Mori S, Nakamori F. Experimental study on the substitute of the vitreous body. *Nippon Ganka Gakkai Zasshi* 1964;68:1145-58.
- [158] Gombos GM, Berman ER. Chemical and clinical observation on the fate of various vitreous substitutes. *Acta Ophthalmol* 1967;45:794-804.
- [159] Scuderi G. Experimental research on transplantation of the vitreous (attempts of partial substitution with homogenous vitreous, with heterologous fluid, with solutions of polyvinylpyrrolidone). *Ann Ottalmol Clin Ocul* 1954;80:213-20.
- [160] Hayano S, Yoshino T. Local application of polyvinylpyrrolidone (PVP) for some ocular diseases. *Rinsho Ganka* 1959;13:449-53.
- [161] Hong Y, Chirila TV, Vijayasekaran S, Dalton PD, Tahija SG, Cuypers MH, Constable IJ. Crosslinked poly(1-vinyl-2-pyrrolidinone) as a vitreous substitute. *J Biomed Mater Res* 1996;30:441-8.
- [162] Hong Y, Chirila TV, Cuypers MJH, Constable IJ. Polymers of 1-vinyl-2-pyrrolidinone as potential vitreous substitutes: physical selection. *J Biomater Appl* 1996;11:135-81.
- [163] Hong Y, Chirila TV, Vijaysekaran S, Shen W, Lou X, Dalton PD. Biodegradation in vitro and retention in the rabbit eye of crosslinked poly(1-vinyl-2-pyrrolidinone) hydrogel as a vitreous substitute. *J Biomed Mater Res* 1998;39:650-9.
- [164] Chirila TV, Hong Y. Poly(1-vinyl-2-pyrrolidinone) hydrogels as vitreous substitutes: a rheological study. *Polym Int* 1998;46:183-95.

- [165] Dalton PD, Chirila TV, Hong Y, Jefferson A. Oscillatory shear experiments as criteria for potential vitreous substitutes. *Polym Gels Netw* 1995;3:429-44.
- [166] Muller-Jensen K, Kohler H. An attempt to replace the vitreous body by polyacrylamide. *Ber Zusammenkunft Dtsch Ophthalmol Ges* 1968;68:181-4.
- [167] Muller-Jensen K. Polyacrylamide as an alloplastic vitreous implant. *Graefes Arch Klin Exp Ophthalmol* 1974;189:147-58.
- [168] Refojo MF, Zauberman H. Optical properties of gels designed for vitreous implantation. *Invest Ophthalmol* 1973;12:465-7.
- [169] Aliyar HA, Foster WJ, Hamilton PD, Ravi N. Towards the development of an artificial human vitreous. *Polym Prep* 2004;45:469-70.
- [170] Hamilton PD, Aliyar HA, Ravi N. Biocompatibility of thiol-containing polyacrylamide polymers suitable for ophthalmic applications. *Polym Prep* 2004;45:495-6.
- [171] Swindle KE, Hamilton PD, Ravi N. Advancements in the development of artificial vitreous humour utilizing polyacrylamide copolymers with disulfide crosslinkers. *Polym Prep* 2006;47:59-60.
- [172] Foster WJ, Aliyar HA, Hamilton P, Ravi N. Internal osmotic pressure as a mechanism of retinal attachment in a vitreous substitute. *J Bioactive Compatible Polym* 2006;21:221-35.
- [173] Swindle KE, Hamilton PD, Ravi N. In situ formation of hydrogels as vitreous substitutes: viscoelastic comparison to porcine vitreous. *J Biomed Mater res A* 2008;87:656-65.
- [174] Daniele S, Refojo MF, Schepens CL, Freeman HM. Glyceryl methacrylate hydrogel as a vitreous implant. *Arch Ophthalmol* 1968;80:120-7.
- [175] Hogen-Esch TE, Shah KR, Fitzgerald CR. Development of injectable poly(glyceryl methacrylate) hydrogels for vitreous prosthesis. *J Biomed Mater Res* 1976;10:975-6.
- [176] Refojo MF. Polymers in ophthalmic surgery. *J Biomed Mater Res* 1971;5:113-9.
- [177] Chan IL, Tolentino FI, Refojo MF, Fournier G, Albert DM. Vitreous substitute: experimental studies and review. *Retina* 1984;4:51-9.

- [178] Fernandez-Vigo J, Rey SAD, Concheiro A, Martinez M. Molecular weight dependence of the pharmacokinetic of hydroxypropyl methylcellulose in the vitreous. *J Ocul Pharmacol* 1990;6:137-142.
- [179] Fernandez-Vigo J, Refojo MF, Verstraeten T. Evaluation of a viscoelastic solution of hydroxypropyl methylcellulose as a potential vitreous substitute. *Retina* 1990;10:148-152.
- [180] Schmolka IR. Artificial Skin. I. preparation and properties of Pluronic F127 gels for the treatment of burns. *J Biomed Mater Res* 1972;6:571-82.
- 181[146] Davidorf FH, Chambers, RB, Kwon OW, Doyle W, Gresak P, Frank SG. Ocular toxicity of vitreal pluronic polyol F-127. *Retina* 1990;10:297-300.
- [182] Benlian W, Zhang J, Huibin W. The development of synthetic vitreous body and its experiment in rabbits. In: Feng H, Han Y, Huang L, editors. *Polymers and Biomaterials*. Amsterdam: Elsevier Scientific Publishers B.V.; 1991. p. 397-400.
- [183] Yamauchi A. Synthetic vitreous body of PVA hydrogel. In: De Rossi D, Kajiwara K, Osada Y, Yamauchi A, editors. *Polymer Gels – Fundamentals and Biomedical Applications*. New York: Plenum Press; 1991. p. 127-34.
- [184] Maruoka S *et al.* Biocompatibility of polyvinylalcohol gel as a vitreous substitute. *Curr Eye Res* 2006;31:599-606.
- [185] Leone G, Consumi M, Aggravi M, Donati A, Lamponi S, Magnani A. PVA/STMP based hydrogels as potential substitutes of human vitreous. *J Mater Sci: Mater Med*, in press.
- [186] Peyman GA, Conway MD, Karacorlu M. Evaluation of silicone gel as a long-term vitreous substitute in nonhuman-primates. *Ophthalmic Surg Lasers* 1992;23:811-7.
- [187] Chirila TV *et al.* Synthetic hydrogel as an artificial vitreous body. A one year animal study of its effects on the retina. *Cells Mater* 1995;5:83-96.
- [188] De Jong C, Bali E, Libert J, Caspers-Velu L. Adcon-L hydrogel as a vitreous substitute: preliminary results. *Bull Soc Belge Ophthalmol* 2000;278:71-5.

- [189] Cavalieri F, Miano F, D'Antona P, Paradossi G. Study of gelling behaviour of poly(vinyl alcohol)-methacrylate for potential utilizations in tissue replacement and drug delivery. *Biomacromolecules* 2004;5:2439-46.
- [190] Larsen NE, Pollak CT, Reiner K, Leshchiner E, Balazs EA. Hylan gel biomaterial: dermal and immunologic compatibility. *J Biomed Mater Res* 1993;27:1129-34.
- [191] Su WY, Chen KH, Chen YC, Lee YH, Tseng CL, Lin FH. An injectable oxidated hyaluronic acid/adipic acid dihydrazide hydrogel as a vitreous substitute. *J Biomater Sci Polym Ed*, in press.
- [192] Lai JY. Biocompatibility of chemically cross-linked gelatine hydrogels for ophthalmic use. *J Mater Sci: Mater Med* 2010;21:1899-911.
- [193] ISO 10993-5. Biological evaluation of medical devices. Part 5: Tests for cytotoxicity : in vitro methods.

Figure

Fig. 1. The structure of the eye with its essential elements: 1 = cornea, 2 = anterior chamber, 3 = aqueous humour, 4 = pupil, 5 = iris, 6 = posterior chamber, 7 = crystalline lens, 8 = zonule, 9 = ciliary body, 10 = vitreous body, 11 = retina, 12 = macula, 13 = fovea, 14 = head of the optic nerve, 15 = optic nerve, 16 = choroid, 17 = sclera, 18 = lateral rectus muscle, 19 = medial rectus muscle, 20 = conjunctiva.

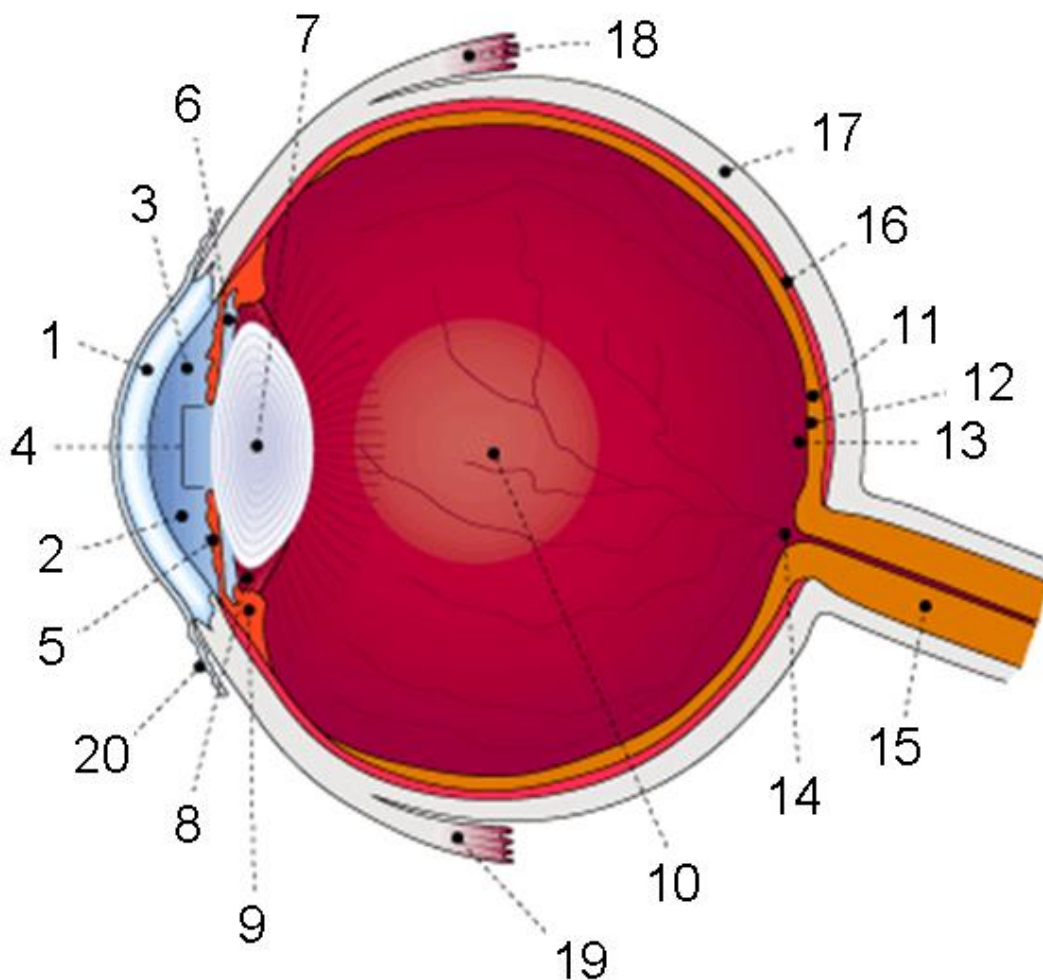


Fig. 2. Typical 3-port pars plana vitrectomy procedure: the aspiration pipe (the so-called “vitrector”) (1) allows the slow removal of the natural vitreous, the infusion pipe (2) is used to replace the vitreous with an appropriate substitute and the light pipe (3) is useful to surgeon for exploring the vitreous cavity and for examining the retina.

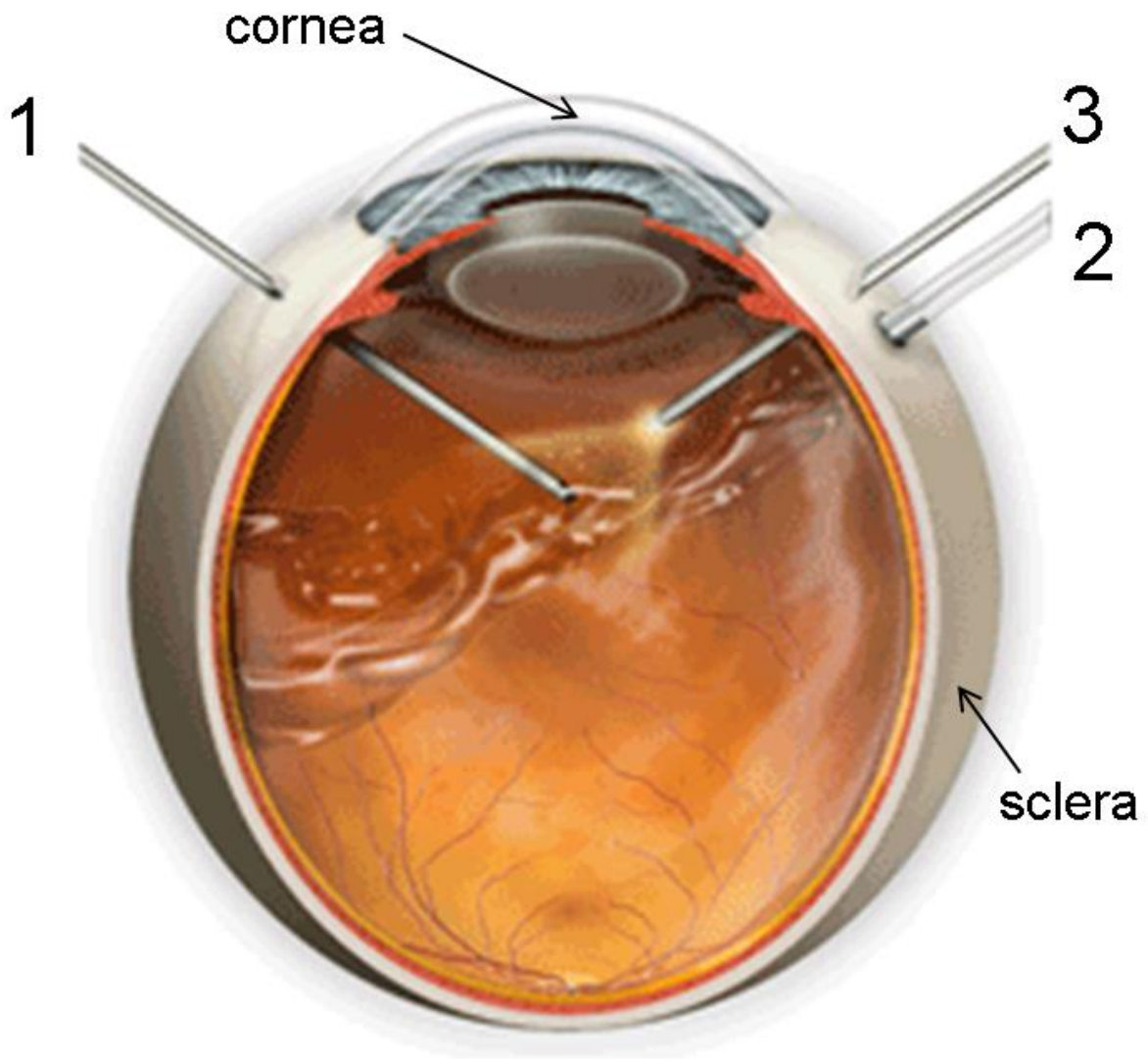


Fig. 3. Pneumatic retinopexy: (a) surgical procedures and (b) successful clinical outcomes.

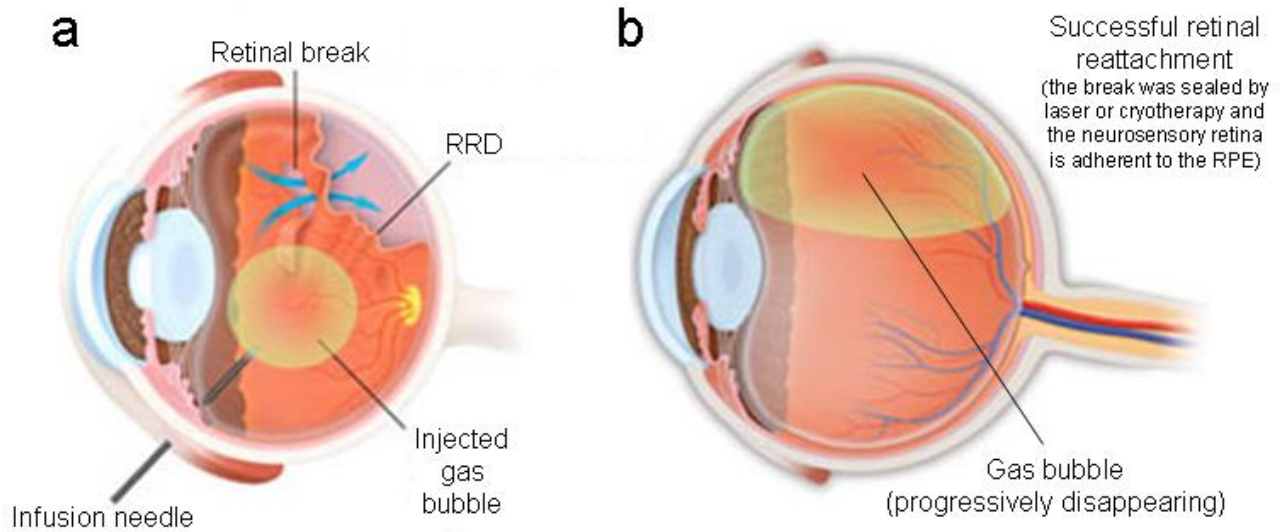


Table 1

Medical glossary (terms listed alphabetically).

Term	Explanation
Age-related macular degeneration (AMD)	Pathology usually affecting older adults and resulting in a loss of vision in the center of the visual field. AMD “dry” form results from the results from the atrophy of the retinal pigment epithelial; AMD “wet” form causes vision loss due to abnormal blood vessel growth below the macula.
Cataract	Clouding that develops in the crystalline lens or in its envelop, varying in degree from slight to complete opacity. It prevents clear vision and may require the surgical removal of the lens.
Diabetic retinopathy	Retinopathy caused by complications of diabetes mellitus. It progresses from mild non-proliferative abnormalities, characterized by increased vascular permeability, to proliferative diabetic retinopathy, featured by the growth of new blood vessels on the retina and posterior surface of the vitreous. Macular edema can develop at all stages of this retinopathy.
Epiretinal membranes	Scar tissue-like membranes that form over the macula; they may be involved in retinal detachment and other vitreoretinal diseases.
Fibroblasts	Cells located in the vitreous humour; they are involved in the synthesis of the constituents (collagens, glycosaminoglycans, glycoprotein and others) of the extracellular matrix.
Fovea	Small pit, located in the centre of the macula, containing the highest concentration of cone cells in the retina; it is responsible for central vision and visual acuity.
Glaucoma	Group of ocular diseases associated with increased intraocular pressure, thereby involving damage to the optic nerve. Glaucoma has been appropriately defined the “silent thief of sight”, as the loss of vision normally occurs gradually over a long period of time and is often recognized only when the disease is quite advanced.
Hyalocytes	Main cells located in the vitreous humour. Their role is not fully clear; they exhibit functional characteristics similar to those of macrophages and

	are involved in maintaining the vitreous transparent and avascular.
Intraocular pressure (IOP)	Represents a measurement of the fluid pressure inside the eye (mean value in normal population ~15.5 mmHg). IOP above 21 mmHg indicates ocular hypertension, that may eventually develop into glaucoma.
Macula	Oval-shaped (~5 mm) highly pigmented yellow region near the centre of the retina in human eyes.
Outer plexiform layer	Retinal layer containing the axons of photoreceptors, together with horizontal cells dendrites and bipolar dendrites.
Photoreceptors	Sensing elements of the retina. They are divided in cones and rods, that are sensitive to different visual conditions since they contain two different light-sensitive proteins in their outer segment.
Proliferative vitreoretinopathy (PVR)	It involves the formation of scar tissue in the vitreous cavity; the so-formed vitreoretinal membranes are a risk factor for tractional retinal detachment.
Retinal pigment epithelium (RPE)	Retinal layer firmly attached to the underlying choroid; it plays a key role in retinal physiology by forming the outer blood-retinal barrier and by supporting the function of the photoreceptors (cones and rods).
Rhegmatogenous retinal detachment (RRD)	Retinal detachment in which fluid from vitreous cavity enters the sub-retinal space through a full-thickness retinal break.
Tractional retinal detachment (TRD)	Retina detachment in which the retina is mechanically lifted up as a result of vitreoretinal tractions.

Table 2

Overview of the main vitreous tamponade agents and substitutes used in the clinical practice (human patients).

Year (first use)	Substance	Type ^a	Remarks	References ^b
1911	Air	G	Short residence time (few days); suitable for air/PFCL exchange	[34-41]
1912	Water	L	Short residence time	[57,58]
1948	Saline solutions	L	Short residence time; suitable for saline/PFCL exchange and for rinsing the vitreous cavity	[59]
1962	Silicone oil	L	Long-term vitreous substitute, with problems of oil toxicity mainly due to emulsification	[21,60-92]
1973	SF ₆	G	Short residence time; cataract, problems due to IOP rise	[42,46,47-49,51]
1980	C ₂ F ₆ , C ₄ F ₈ , C ₃ F ₈	G	More prolonged tamponade than SF ₆ ; cataract, problems due to IOP rise	[43-48,50-54]
1982	Xenon	G	Very short residence time (few hours)	[55,56]
1988	Perfluoro- <i>n</i> -octane, perfluorodecalin	L	Intraoperative use only is strongly recommended; it is usually the agent of choice	[101-104,106-111,115,118-123]
1990	Fluosilicone oil	L	Useful in the treatment of inferior RD; drawbacks analogous to those of silicone oil	[92-97]
1992	Perfluorotetradecahydrophenantrene	L	Intraoperative use only is strongly recommended	[103,105,112,116,117,122]

2002	Perfluorohexyloctane	L	Good clinical outcomes; cataract; removal recommended after 2-3 months from operation	[124,126-130]
2003	Oxane HD [®]	L	Adverse affects including emulsification, cataract, IOP rise	[137-142]
2005	Densiron-68 [®]	L	Good clinical outcomes; possible emulsification (oil removal after 3 months from instillation is strongly recommended)	[131-135,140-142]
2007	HW 46-3000	L	Very good success rate in retinal reattachment; high rate of cataract formation; no inflammation and emulsification.	[136]

^a G = gas; L = liquid.

^b References refer to numbering in the text.

Table 3

Relevant physical properties of silicone-based oils (adapted from [60,92,94]).

Oil	RI (at RT)	Density (g cm ⁻³)	Kinematic viscosity (cSt)
Silicone oil	1.404	0.97	1000-12000
Fluorosilicone oil	1.382	1.29	1000-10000
Silicone/fluorosilicone copolymer oil	1.387	1.16	170-200

Table 4

Relevant physical properties of the most commonly used perfluorocarbon liquids (adapted from [92,122]).

Perfluorocarbon liquid	RI (at RT)	Density (g cm ⁻³)	Kinematic viscosity (cSt)
Perfluoro- <i>n</i> -octane	1.28	1.73	0.8
Perfluorodecalin	1.31	1.93	2.7
Perfluorotetradecahydroph enantrene	1.33	2.02	8.0

Table 5

Relevant physical properties of the most commonly experimented heavy oils (adapted from [140,141]).

Heavy oil	Composition	RI (at RT)	Density (g cm ⁻³)	Kinematic viscosity (cSt)
Oxane HD [®]	5700 cSt silicone oil + RMN-3 (partially fluorinated olefin)	1.40	1.02	~3300
Densiron-68 [®]	5000 cSt silicone oil + F ₆ H ₈	1.387	1.06	~1500
HW 46-3000	10 ⁵ cSt silicone oil + F ₄ H ₆	1.369	1.105	~3100

Table 6

Experimental polymers for vitreous substitution.

Year (first use)	Polymer	Type ^a	Recipient ^b	Toxicity	Persistence ^c	Remarks	References ^d
1954	Poly(1-vinyl-2-pyrrolidone) solutions	SP	A	No	ST		[159,160]
1961	Hyaluronic acid solutions	MNP	H	No	ST		[145,146]
1966	Polygeline	MNP	A, H	No	ST		[147,148]
1966	Hyaluronate/collagen gel	MNP	A	No	ST		[153,155]
1968	Polyacrylamide	SP	A	No	LT	Promising physico-mechanical properties; possible gel degradation during injection	[167-173]
1968	Poly(glyceryl methacrylate)	SP	A	No	LT	Traumatic implantation (dense pieces) or degradation during injection (gel).	[174,175]
1969	Collagen	MNP	A, H	Yes	ST	Unsuitable	[149-152]
1971	Poly(2-hydroxyethyl methacrylate)	SP	A	No	LT	Unsuitable (too traumatic implantation)	[176]
1984	Poly(2-hydroxyethyl acrylate)	SP	A	Yes	LT	Unsuitable	[177]
1990	Hydroxypropyl methylcellulose	SP	A	No	ST		[178,179]
1990	Pluronic F127	SP	A	Yes	ST	Unsuitable	[181]
1991	Poly(vinyl alcohol) hydrogels	SP	A	No	LT	Good maintenance of physico-mechanical properties	[182-185]
1992	Silicone gel	SP	A	No	LT	Lacking of retinal tamponade effect	[186]
1993	Hyaluronic acid hydrogel	MNP	A	No	ST/LT	Potential problems of gel coherence. Degradation time (> 1 month) depending on the amount of cross-linking agent	[190,191]
1995	Poly(1-vinyl-2-pyrrolidone) hydrogels	SP	A	No	LT	Possible gel degradation during injection	[161-165]

1995	Poly(methyl 2-acrylamidoglycolate methyl ether)	SP	A	Yes	LT	Unsuitable	[187]
1997	Methylated collagen	MNP	A	No	ST		[153,154]
2000	Adcon [®] -L hydrogel	SP	A	Yes	ST	Unsuitable	[188]
2004	Poly(vinyl alcohol methacrylate)	SP	IV	No	LT	Significantly stiffer than natural vitreous	[189]
2006	Hyaluronic acid/gellan gum	MNP	IV	No	ST	Insufficient mechanical properties	[156]
2010	Gelatin hydrogels	MNP	A	No	ST		[192]

^a MNP = modified natural polymers; SP = synthetic polymers.

^b A = animal; H = human; IV = *in vitro* only.

^c ST = short-term (due to resorption or degradation); LT = long-term. The indication is given also in case of toxicity.

^d References refer to numbering in the test.

