

Maxillary Sinusitis Following Orthognathic Surgery: Should It Be Considered Odontogenic Sinusitis?

Original

Maxillary Sinusitis Following Orthognathic Surgery: Should It Be Considered Odontogenic Sinusitis? / Imbrogno, Giorgio; Lorenzi, Andrea; Borloni, Roberto; Scaini, Riccardo; Testori, Tiziano; Felisati, Giovanni; Saibene, Alberto Maria; Craig, John R.. - In: CLINICAL CASE REPORTS. - ISSN 2050-0904. - 12:12(2024). [10.1002/ccr3.9654]

Availability:

This version is available at: 11583/3006343 since: 2026-01-08T12:31:41Z

Publisher:

Wiley

Published

DOI:10.1002/ccr3.9654

Terms of use:



This article is made available under terms and conditions as specified in the corresponding bibliographic description in the repository

Publisher copyright

(Article begins on next page)

CASE REPORT OPEN ACCESS

Maxillary Sinusitis Following Orthognathic Surgery: Should It Be Considered Odontogenic Sinusitis?

Giorgio Imbrogno¹ | Andrea Lorenzi²  | Roberto Borloni¹ | Riccardo Scaini³ | Tiziano Testori³ | Giovanni Felisati¹ | Alberto Maria Saibene¹  | John R. Craig⁴

¹Otolaryngology Unit, Santi Paolo e Carlo Hospital, Department of Health Sciences, Università Degli Studi di Milano, Milan, Italy | ²Division of Otolaryngology, Department of Surgical Sciences, Università Degli Studi di Torino, Turin, Italy | ³Dental Clinic, Section of Implant Dentistry and Oral Rehabilitation, IRCCS Galeazzi Sant'Ambrogio Hospital, Milan, Italy | ⁴Department of Otolaryngology-Head and Neck Surgery, Henry Ford Health, Detroit, Michigan, USA

Correspondence: Alberto Maria Saibene (alberto.saibene@gmail.com)

Received: 29 August 2024 | **Revised:** 10 October 2024 | **Accepted:** 24 October 2024

Funding: The authors received no specific funding for this work.

Keywords: dental hardware infection | endoscopic sinus surgery | fungus ball | odontogenic sinusitis | orthognathic surgery complications

ABSTRACT

Maxillary sinusitis is a recognized complication following dental procedures, but its occurrence after orthognathic surgery, such as Le Fort osteotomies, remains less documented. This case report presents a 58-year-old female who developed unilateral maxillary sinusitis 23 years post-orthognathic surgery. The patient was asymptomatic, aside from occasional cacosmia, and was incidentally found to have sinus opacification on a computed tomography (CT) scan performed for implant-prosthetic rehabilitation. Nasal endoscopy revealed purulence and mucosal edema, prompting endoscopic sinus surgery (ESS). Intraoperatively, purulent material and fungal debris were removed from the maxillary sinus, confirming bacterial sinusitis with a concurrent fungal ball. *S. salivarius* and *Klebsiella* species were identified from the cultures. The patient's condition improved following the removal of both the sinus contents and the retained titanium plates and screws. This case underscores the potential for maxillary sinusitis to develop long after orthognathic surgery, particularly in the presence of retained dental hardware. It highlights the importance of thorough imaging and endoscopic evaluation in patients with a history of dental or facial surgeries presenting with sinonasal symptoms. Additionally, it raises questions about the role of retained hardware in the persistence or recurrence of infection and the possible association with fungal ball formation. The need for further research to establish guidelines for the management of sinusitis in such contexts, particularly regarding the removal of facial hardware, is emphasized.

Taxonomy Classification: Ear, Nose and Throat, Otolaryngology, Surgery

1 | Introduction

Odontogenic sinusitis (ODS) represents a unique subset of paranasal sinus disorders directly stemming from dental pathologies or interventions. This condition typically manifests as bacterial maxillary sinusitis that may extend to other sinuses, often linked to either infectious processes in adjacent maxillary teeth

or as a result of iatrogenic injuries during dental procedures [1–3]. ODS is implicated in 25%–40% of all chronic maxillary sinusitis cases, most often presenting unilaterally. It accounts for 45%–75% of cases where unilateral maxillary sinus opacification is observed on computed tomography (CT) scans. ODS is predominantly unilateral and most commonly presents in the fifth decade of life, affecting males and females equally [3].

Giorgio Imbrogno, Andrea Lorenzi, Alberto Maria Saibene, and John R. Craig have contributed equally to this manuscript.

This is an open access article under the terms of the [Creative Commons Attribution-NonCommercial](https://creativecommons.org/licenses/by-nc/4.0/) License, which permits use, distribution and reproduction in any medium, provided the original work is properly cited and is not used for commercial purposes.

© 2024 The Author(s). *Clinical Case Reports* published by John Wiley & Sons Ltd.

Summary

- This case report highlights the potential for maxillary sinusitis development following orthognathic surgery, which may be classified as odontogenic sinusitis (ODS).
- The findings emphasize the importance of considering retained dental hardware as a potential nidus for infection and the role of endoscopic sinus surgery in managing such cases.

The increasing prevalence of dental implants and complex reconstructive dental procedures has broadened the spectrum of potential etiologies for ODS [4, 5]. Common dental causes include apical periodontitis, often related to pulpal necrosis, and oroantral communications, which may occur post-extraction or as a complication of dental surgeries. The often-indolent nature of ODS, combined with its potential for acute exacerbations that can lead to orbital, intracranial, or osseous complications, underscores the need for heightened awareness and timely diagnosis [3, 6, 7].

Microbiologically, ODS is predominantly polymicrobial, reflecting the diverse oral flora typical of the causative dental infections. Anaerobes such as *Prevotella* spp. and *Peptostreptococcus* spp. are frequently isolated, along with facultative anaerobes like α -hemolytic streptococci [8, 9]. This complex microbiological landscape not only challenges treatment strategies but also highlights the interconnectedness of oral health and sinus pathology [10, 11].

Sinusitis following maxillary advancement procedures was classified among the complications of dental treatment or pathology according to the classification proposed by the Milan group [12–14]. However, there are few cases described in the literature [4]. Furthermore, the current consensus on the diagnosis of ODS [2] does not include this type of complication among the etiologies due to the need for more data on this condition. Therefore there is an inherent debate on whether sinusitis following maxillary osteotomy should be regarded as an ODS [15].

We present a case of a patient who developed unilateral maxillary sinusitis with a fungus ball after a prior orthognathic surgery, with microbiological features suggesting possible ODS.

2 | Case History/Examination

A 58-year-old female was referred to our otolaryngology outpatient service (Santi Paolo e Carlo Hospital, Milan, Italy) incidental sinus disease was identified on head computed tomography (CT) scan performed for implant-prosthetic rehabilitation purposes. Figure 1 is the CT showing left maxillary, frontal, and ethmoidal sinus opacification with intramaxillary hyperdensities within a soft tissue density. The remaining paranasal cavities are well-aerated. Titanium micro-screws were seen in the alveolar process and floor of the left maxillary sinus, which had been placed during an orthognathic surgery 23 years prior which included Le Fort osteotomies. The patient was otherwise healthy and did not report any other prior surgery other than the aforementioned orthognathic procedure and the removal of the plates and screws on the right side.

During the first otolaryngological examination, the patient reported at first to be completely symptom-free and unaware of the infectious process. Upon specific questioning, the patient admitted to having occasionally experienced cacosmia, without any additional sinonasal symptoms (sinus pressure, nasal obstruction, rhinorrhea, or postnasal drip) starting 18–24 months before our evaluation. Nasal endoscopy revealed left-sided middle meatal mucosal edema and purulence draining from behind a medialized bulging uncinate process. Routine blood examinations, including blood count with differentials and C-reactive protein, were in the normal range. As the patient was unaware of the condition, she had not performed any treatment, either systemic or topic, before our evaluation.

2.1 | Methods

Given the patient's subjective cacosmia and clinical and radiological findings consistent with left-sided purulent sinusitis and possible fungal ball, endoscopic sinonasal surgery (ESS) was performed. Additionally, the patient's maxillo-facial

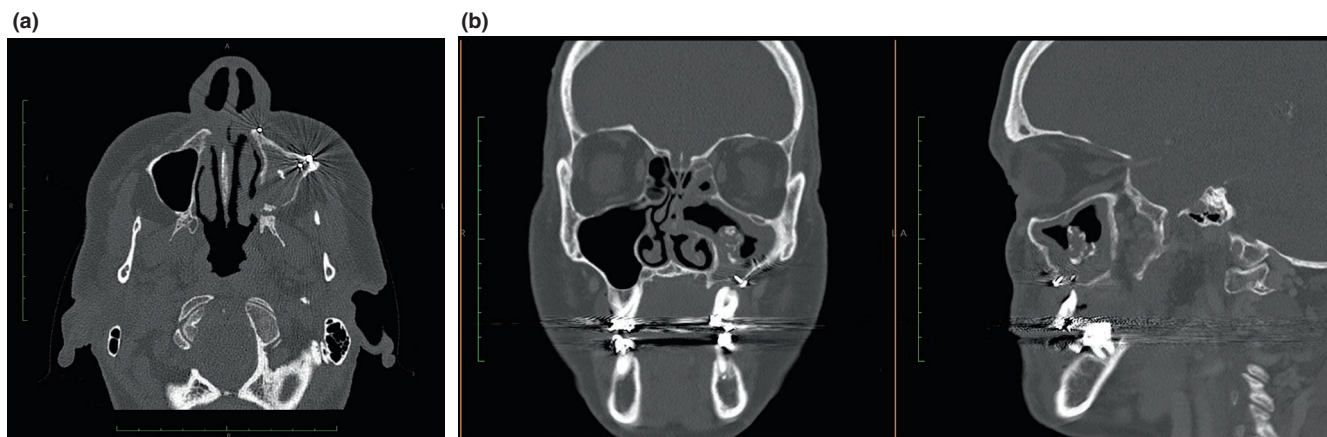


FIGURE 1 | Preoperative plain head CT scan (a, axial view; b, left, coronal view; right, sagittal view). The left maxillary sinus is partially obliterated with an iron-like central hyperdense formation suggestive of a fungus ball. Micro-screws and plates are visible in all views.

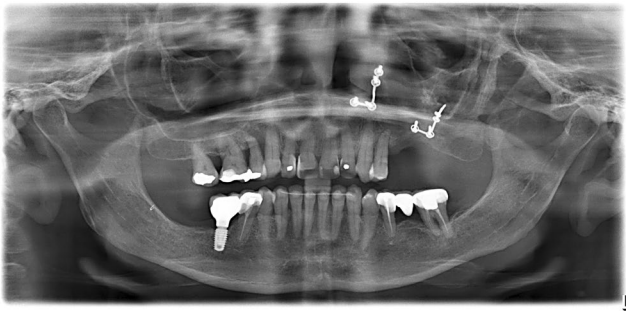


FIGURE 2 | Preoperative orthopantomogram showing a left maxillary sinus hyperdense formation and the two plates with respective screws.

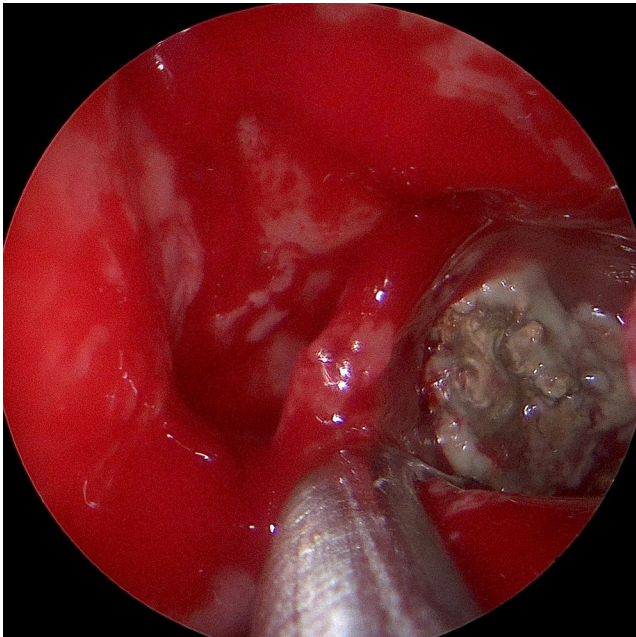


FIGURE 3 | Intraoperative view of the left maxillary sinus with a well-visible fungus ball.

surgeon wished to remove the remaining plates and screws as they could be persistent infectious niduses, so an orthopantomogram was also obtained to facilitate titanium plate localization (Figure 2).

During ESS, copious purulence and likely fungal debris were removed from the maxillary sinus via a wide maxillary antrostomy (see Figure 3). The extracted material was subsequently sent for culture and histological analysis. As the patient was little symptomatic and the fungus ball was considered the source of the disease, the extent of surgery was limited to middle meatal antrostomy alone. Next, the maxillo-facial surgeon transorally removed the two mini-plates, and the associated screws were removed (Figure 4).

The maxillary sinus purulence grew *S. salivarius* and two strains of *Klebsiella* (*K. oxytoca* and *K. variicola*) on culture, and the solid debris contained fungal hyphae on final surgical pathology. Together, these results confirmed both bacterial sinusitis and a concurrent fungal ball.

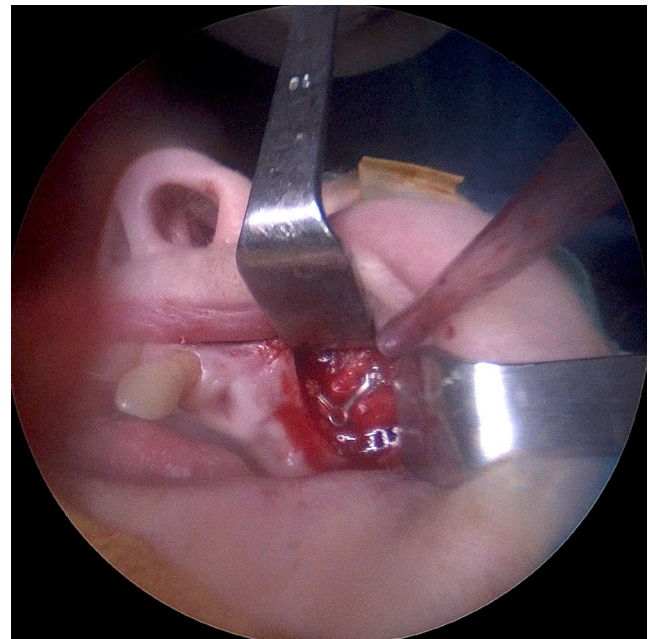


FIGURE 4 | Intraoperative view showing the intraoral access for plate removal.

3 | Conclusion and Results

There were no intraoperative or postoperative surgical complications, and the patient's sinus and oral surgical sites healed completely postoperatively.

An endoscopic evaluation was performed 1 month after surgery, showing complete healing of the surgery site, with no residual purulence or fungus ball. The patient remained asymptomatic during the 6-month follow-up.

4 | Discussion

This case highlights the potential for sinusitis development following Le Fort osteotomies, which fulfills the modern criteria for ODS based on there being purulent (bacterial) maxillary sinusitis adjacent to the site of a prior oral/dental procedure with indwelling hardware [2]. Additionally, sinus culture revealed at least one organism that is likely of dental origin. However, there was also the nuance of the concurrent fungal ball, and whether this developed as part of the ODS disease process or in relation to the facial hardware is difficult to know for certain.

It is open to debate how a likely-dental organism such as *S. salivarius* reached the maxillary sinus. While we cannot rule out an occasional (and unfortunate) passage from the dental environment to the nasal cavities, it seems more likely that the infection is somehow related either to the original surgical procedure or to the retained hardware. More specifically, on one hand, we might hypothesize the presence of an oroantral communication at the time of LeFort surgery, which allowed the penetration of pathogens inside the maxillary sinus. Conversely, it is possible that bacteria submucosally first reached and infected the plates

and from there, through bony blood vessels and lymphatic pathways, to the maxillary sinus.

Though the identification of a fungus ball is not necessarily associated with ODS per se [16–18], several studies highlighted the presence of retained hardware or metal-based endodontic material as a risk factor for the formation of fungus balls [19–21]. Such relationships have not been explored prospectively and some authors argue that the high concentrations of zinc and calcium found inside paranasal sinus fungus balls might be (also or only) due to endogenous factors [22]. Our findings suggest that retained dental hardware may serve as a reservoir for diverse microbial populations, potentially protected by biofilm formation, which could lead to persistent or recurrent infections. On the contrary, this patient did not present any other potential risk factor for developing a fungal disease. She was immunocompetent, wasn't in treatment for any condition (including diabetes mellitus), and did not show signs of non-fungus-ball related invasive mycoses including SARS-CoV-2-associated mucormycosis. Given these characteristics, the diagnosis of ODS-associated fungus ball seemed the most consistent.

The diagnosis of ODS in the context of retained dental hardware requires a high index of suspicion, particularly in patients presenting with atypical or chronic sinonasal symptoms. In this case, the discovery of sinus opacification on CT, initially performed for implant-prosthetic rehabilitation, underscores the importance of comprehensive imaging in patients with a history of dental/facial surgeries. The nasal endoscopy findings of mucosal edema, purulent discharge, and medialization of the uncinate process were crucial in confirming the diagnosis and planning the surgical intervention as defined in the recent ODS literature [2, 23, 24].

ESS was necessary to clear the infectious sinusitis, and the removal of the titanium mini-plates may have prevented the re-development of either bacterial or fungal growth. The choice of performing middle maxillary antrostomy alone despite the CT findings of extra maxillary spread was based on recent research showing that limited surgery can be effective in the setting of ODS [25]. Future research is needed to determine whether facial hardware is always necessary to remove a possible nidus of infection. Many patients live with indwelling midfacial hardware following such surgeries without complication, and no study to date has explored whether removing such hardware in the setting of infectious sinusitis prevents disease recurrence. Until such evidence, surgeon judgment is necessary on a case-by-case basis.

It has to be noted though that the patient had extremely mild to no symptoms and did not have any risk factors for a shift toward invasive mycosis (including diabetes, immunodepression, and long-term immunodepressive medication). Therefore a watchful waiting approach could have been considered (as suggested by recent consensus) [17] if the patient did not consent to surgery or in low-resources settings, where ESS might not be an available option.

In summary, this case contributes to prior studies supporting sinusitis may follow maxillary advancement procedures, and can fall under the umbrella of ODS due to oral surgical complications

[12, 26]. It also highlights the need for future research in establishing whether there is a causative connection between indwelling facial hardware, metal-based endodontic material, or metal foreign bodies and fungus ball formation [2, 5, 19, 20, 27], and whether midfacial hardware removal is necessary in all cases of bacterial and fungal maxillary sinusitis.

Author Contributions

Giorgio Imbrogno: data curation, writing – original draft. **Andrea Lorenzi:** data curation, writing – original draft. **Roberto Borloni:** formal analysis, writing – review and editing. **Riccardo Scaini:** formal analysis, writing – review and editing. **Tiziano Testori:** formal analysis, writing – review and editing. **Giovanni Felisati:** formal analysis, writing – review and editing. **Alberto Maria Saibene:** conceptualization, writing – review and editing. **John R. Craig:** conceptualization, writing – review and editing.

Acknowledgments

Open access publishing facilitated by Università degli Studi di Milano, as part of the Wiley - CRUI-CARE agreement.

Consent

Written informed consent for publishing this report was obtained from the patient in accordance with the journal's patient consent policy.

Conflicts of Interest

The authors declare no conflicts of interest.

Data Availability Statement

Data sharing is not applicable to this article as no datasets were generated or analyzed during the current study.

References

1. A. Whyte and R. Boeddinghaus, "Imaging of Odontogenic Sinusitis," *Clinical Radiology* 74 (2019): 503–516.
2. J. R. Craig, D. M. Poetker, U. Aksoy, et al., "Diagnosing Odontogenic Sinusitis: An International Multidisciplinary Consensus Statement," *International Forum of Allergy & Rhinology* 11 (2021): 1235–1248.
3. J. R. Craig, "Odontogenic Sinusitis: A State-Of-The-Art Review," *World Journal of Otorhinolaryngology—Head and Neck Surgery* 8 (2022): 8–15.
4. F. Allevi, G. L. Fadda, C. Rosso, et al., "Treatment of Sinusitis Following Dental Implantation: A Systematic Review and Meta-Analysis," *American Journal of Rhinology & Allergy* 36 (2022): 539–549.
5. F. Allevi, G. L. Fadda, C. Rosso, et al., "Diagnostic Criteria for Odontogenic Sinusitis: A Systematic Review," *American Journal of Rhinology & Allergy* 35 (2021): 713–721.
6. J. E. Douglas, T. Patel, B. Rullan-Oliver, et al., "Odontogenic Sinusitis Is a Common Cause of Operative Extra-Sinus Infectious Complications," *American Journal of Rhinology & Allergy* 36 (2022): 808–815.
7. J. R. Craig, A. J. Cheema, R. T. Dunn, S. Vemuri, and E. L. Peterson, "Extrasinus Complications From Odontogenic Sinusitis: A Systematic Review," *Otolaryngology and Head and Neck Surgery* 166 (2022): 623–632.
8. A. M. Saibene, C. Vassena, C. Pipolo, et al., "Odontogenic and Rhinogenic Chronic Sinusitis: A Modern Microbiological Comparison," *International Forum of Allergy & Rhinology* 6 (2016): 41–45.

9. A. Yassin-Kassab, P. Bhargava, R. J. Tibbetts, Z. H. Griggs, E. I. Peterson, and J. R. Craig, "Comparison of Bacterial Maxillary Sinus Cultures Between Odontogenic Sinusitis and Chronic Rhinosinusitis," *International Forum of Allergy & Rhinology* 11 (2021): 40–47.
10. M. Areizaga-Madina, B. Pardo-Peláez, and J. Montero, "Microbiology of Maxillary Sinus Infections: Systematic Review on the Relationship of Infectious Sinus Pathology With Oral Pathology," *Oral-Prophylaxe* 3 (2023): 134–145.
11. L. Drago, C. Vassena, A. M. Saibene, M. del Fabbro, and G. Felisati, "A Case of Coinfection in a Chronic Maxillary Sinusitis of Odontogenic Origin: Identification of *Dialister pneumosintes*," *Journal of Endodontia* 39 (2013): 1084–1087.
12. M. Molteni, A. M. Bulfamante, C. Pipolo, et al., "Odontogenic Sinusitis and Sinonasal Complications of Dental Treatments: A Retrospective Case Series of 480 Patients With Critical Assessment of the Current Classification," *Acta Otorhinolaryngologica Italica* 40 (2020): 282–289.
13. A. M. Saibene, F. Collurà, C. Pipolo, et al., "Odontogenic Rhinosinusitis and Sinonasal Complications of Dental Disease or Treatment: Prospective Validation of a Classification and Treatment Protocol," *European Archives of Oto-Rhino-Laryngology* 276 (2019): 401–406.
14. G. Felisati, M. Chiapasco, P. Lozza, et al., "Sinonasal Complications Resulting From Dental Treatment: Outcome-Oriented Proposal of Classification and Surgical Protocol," *American Journal of Rhinology & Allergy* 27 (2013): e101–e106.
15. M. A. Kwiatkowska and J. R. Craig, "Unilateral Sinus Disease: What Is, and Is Not Odontogenic Sinusitis?," *Otolaryngologic Clinics of North America* 57 (2024): 1099–1117, <https://doi.org/10.1016/j.otc.2024.06.005>.
16. G. L. Fadda, F. Allevi, C. Rosso, et al., "Treatment of Paranasal Sinus Fungus Ball: A Systematic Review and Meta-Analysis," *Annals of Otolaryngology, Rhinology, and Laryngology* 130 (2021): 1302–1310.
17. A. M. Saibene, F. Allevi, C. Calvo-Henriquez, et al., "Comprehensive Management of Paranasal Sinus Fungus Balls: A Young-IFOS Consensus Statement," *International Forum of Allergy & Rhinology* 13 (2023): 877–885.
18. A. M. Bulfamante, C. Pipolo, U. D'Agostino Fiorenza, et al., "Spontaneous Healing in Maxillary Fungus Ball: Beware of Asymptomatic Patients," *Clinical Case Reports* 9 (2021): 1865–1869.
19. S. A. Han, S. Kim, Y. Seo, S. K. Yang, C.-S. Rhee, and D. H. Han, "Dental Implant as a Potential Risk Factor for Maxillary Sinus Fungus Ball," *Scientific Reports* 14 (2024): 2483.
20. P. Nicolai, M. Mensi, F. Marsili, et al., "Maxillary Fungus Ball: Zinc-Oxide Endodontic Materials as a Risk Factor," *Acta Otorhinolaryngologica Italica* 35 (2015): 93–96.
21. M. Mensi, M. Piccioni, F. Marsili, P. Nicolai, P. L. Sapelli, and N. Latronico, "Risk of Maxillary Fungus Ball in Patients With Endodontic Treatment on Maxillary Teeth: A Case-Control Study," *Oral Surgery, Oral Medicine, Oral Pathology, Oral Radiology, and Endodontics* 103 (2007): 433–436.
22. Z. Jiang, K. Zhang, W. Huang, and Q. Yuan, "A Preliminary Study on Sinus Fungus Ball With MicroCT and X-Ray Fluorescence Technique," *PLoS One* 11 (2016): e0148515.
23. J. R. Craig, R. W. Tatarzyn, T. L. Aghaloo, et al., "Management of Odontogenic Sinusitis: Multidisciplinary Consensus Statement," *International Forum of Allergy & Rhinology* 10 (2020): 901–912.
24. A. Safadi, A. M. Saibene, and J. R. Craig, "Sinus Evaluation for Odontogenic Sinusitis," *Otolaryngologic Clinics of North America* 57 (2024): 1031–1050, <https://doi.org/10.1016/j.otc.2024.06.002>.
25. J. R. Craig, A. M. Saibene, N. D. Adappa, et al., "Maxillary Antrostomy Versus Complete Sinus Surgery for Odontogenic Sinusitis With Frontal Sinus Extension," *Laryngoscope* (2024): 1–7, <https://doi.org/10.1002/lary.31731>.
26. A. M. Saibene, C. Pipolo, R. Borloni, and G. Felisati, "ENT and Dentist Cooperation in the Management of Odontogenic Sinusitis. A Review," *Acta Otorhinolaryngologica Italica* 41 (2021): S116–S123.
27. D. H. Lee and S. C. Lim, "Maxillary Fungus Ball Caused by Retained Foreign Bodies for 25 Years," *Journal of Craniofacial Surgery* 23 (2012): e176–e177.