

Optical coherence tomography angiography for chronic venous insufficiency and venous leg ulcer

Original

Optical coherence tomography angiography for chronic venous insufficiency and venous leg ulcer / Rotunno, Giulia; Deinsberger, Julia; Meiburger, Kristen; Krainz, Lisa; Bugyi, Lukasz; Haindl, Richard; Leitgeb, Rainer; Weber, Benedikt; Drexler, Wolfgang; Liu, Mengyang. - ELETTRONICO. - 12627:(2023), p. 85. (Intervento presentato al convegno European Conferences on Biomedical Optics (ECBO) tenutosi a Munich (DE) nel 25 - 29 June 2023) [10.1117/12.2670767].

Availability:

This version is available at: 11583/2982079 since: 2023-10-02T09:17:01Z

Publisher:

SPIE

Published

DOI:10.1117/12.2670767

Terms of use:

This article is made available under terms and conditions as specified in the corresponding bibliographic description in the repository

Publisher copyright

SPIE postprint/Author's Accepted Manuscript e/o postprint versione editoriale/Version of Record con

Copyright 2023 Society of PhotoOptical Instrumentation Engineers (SPIE). One print or electronic copy may be made for personal use only. Systematic reproduction and distribution, duplication of any material in this publication for a fee or for commercial purposes, and modification of the contents of the publication are prohibited.

(Article begins on next page)

Optical Coherence Tomography Angiography for Chronic Venous Insufficiency and Venous Leg Ulcer

Giulia Rotunno*^a and Julia Deinsberger*^b, Kristen M. Meiburger^a, Lisa Krainz^c, Lukasz Bugyi^c, Richard Haindl^c, Rainer Leitgeb^c, Benedikt Weber^b, Wolfgang Drexler^c, Mengyang Liu**^c

^aPolitoBIOMed Lab, Department of Electronics and Telecommunications, Politecnico di Torino, Torino, Italy; ^bDepartment of Dermatology, Medical University of Vienna, Vienna, Austria; ^cCenter for Medical Physics and Biomedical Engineering, Medical University of Vienna, Vienna, Austria

*These authors contributed equally

**mengyang.liu@meduniwien.ac.at

ABSTRACT

Chronic venous insufficiency (CVI) ranks among the most common health care issues worldwide. The current diagnosis of CVI is done by clinical examination and duplex ultrasound, which can only detect visible physical changes and deeper vascular structures whereas the superficial cutaneous vasculature cannot be resolved. There is indeed a lack of information that can potentially be extracted from the cutaneous microvasculature of patients affected by CVI. In this work, we designed and applied an optical coherence tomography angiography (OCTA) system, which is customized for lower extremity imaging of patients. Featuring fast imaging speed, large field of view, high spatial resolution, and most importantly non-invasiveness, this OCTA system was successfully applied in CVI and venous leg ulcer patient imaging. Using the OCTA results acquired from a cohort of 27 human subjects, we can clearly distinguish the vascular patterns uniquely associated with various stages of CVI. The findings of this study give an unexplored indicator to the disease of CVI and venous leg ulcer. With more patients to be recruited, we believe that OCTA imaging results for CVI can be used as a powerful tool in CVI screening and diagnosis.

1. DESCRIPTION OF PURPOSE

The purpose of this work is to analyze the microvascular pattern of different chronic venous insufficiency (CVI) stages through optical coherence tomography angiography (OCTA) imaging, which allows a 3D visualization of the microvascular network at a high resolution up to 1 mm in depth. CVI ranks among the most common health care issues worldwide. Since the prevalence increases with age, venous ulcers pose an increasingly relevant public health issue associated with significant morbidity of affected patients and a substantial socioeconomic burden [1, 2]. The estimated prevalence of CVI, including all clinical stages from telangiectasias to venous leg ulcers, amounts up to approximately 90% of the total population [3]. It evolves due to venous reflux, obstruction or a combination of both [4]. In later stages of severe CVI, skin changes and venous leg ulcers (VLU) develop as a result of chronic inflammation of the skin and subcutaneous tissue. The Clinical-Etiology-Anatomic-Pathophysiologic (CEAP) system is the preferred classification scheme used today to describe severity, localization, and etiology [5]. Diagnostic procedures primarily include anamneses, physical examination, and duplex ultrasound [6]. However, using duplex ultrasound, it is to date not feasible to assess the superficial cutaneous vasculature. Therefore, we investigated the potential of OCTA to gain a better understanding of the microvascular network of the skin in patients with CVI.

2. METHODS

2.1 Subjects and Experimental Procedure

In this study, we recruited 21 patients with different stages of CVI (C1-C6) as well as 6 healthy controls (C0) (Table 1). Prior to OCTA imaging, all subjects underwent a physical examination and a Doppler ultrasonography of both legs. They were staged according to the CEAP classification. Table 1 shows the number of subjects recruited for this study from stage C0 (healthy control) up to stage C6 (ulcer). Finally, the subjects were imaged using OCTA at multiple locations on the lower legs, especially where clinical signs of CVI, like varices or skin changes, were observed. All

subjects gave informed consent before the experiments and the whole experiment protocol was approved by the Ethics Committee of the Medical University of Vienna (INS 621000 0510 and 1246 2013).

Table 1. Number of patients and OCTA volumes analyzed per each “C” stage of the CEAP classification

STAGE of the CEAP Classification	Number of patients	Number of OCTA volumes
C0: No visible or palpable signs of venous disease	6	20
C1: Telangiectasias or reticular veins	2	7
C2: Varicose veins	4	19
C4b: Lipodermatosclerosis or atrophie blanche	4	16
C4c: Corona phlebectatica	5	15
C6: Active venous ulcer	6	18

2.2 The OCT System

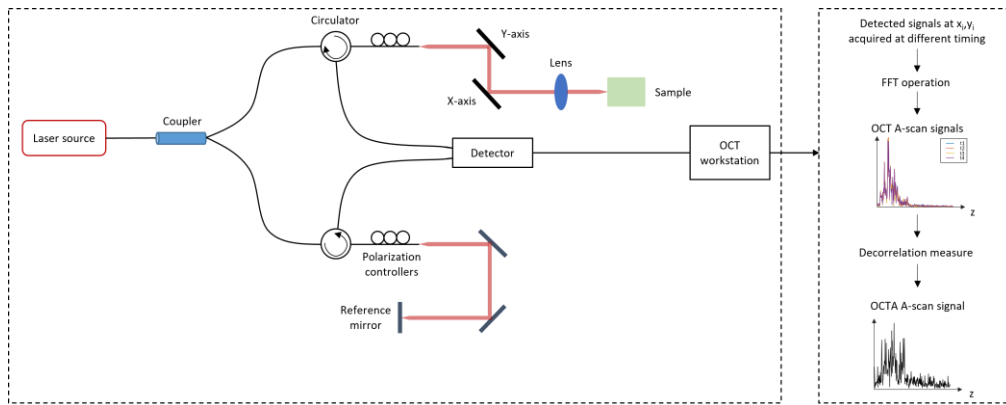


Figure 1. Schematic representation of the imaging setup (a) and OCTA signal reconstruction flowchart (b)). [7]

Figure 1 shows the schematic of the system used for this study. An akinetic swept source (SS-OCT-1310, Insight Photonic Solutions, Inc, U.S.) was used as the OCT source. The central wavelength of the source is 1310 nm and the bandwidth is 29 nm, which are optimal for skin imaging. The sweep rate is 222.22 kHz. The lateral resolution is measured to be 31.5 μm and the axial resolution is 22 μm in air. A scanning range of 10 mm \times 10 mm is used.

2.3 Volume reconstruction and post-processing

To obtain an OCTA signal, we acquired 4 consecutive B-scans at the same location. An intensity-based approach was used to reconstruct the OCTA images. These images were then post-processed to suppress the artifacts induced by laser power variation, motion, and projection (shadow). Finally, we applied image smoothing, contrast enhancement, and depth color coding to improve the image quality.

3. RESULTS

Results of OCTA imaging show that the cutaneous microvasculature in healthy subjects consists of mostly straight and homogeneous vessels (Fig. 2a). Telangiectasias in patients with CEAP C1 correspond to thicker, more tortuous vessels, which are surrounded by a healthy-looking vascular network (Fig. 2b). Varicose veins in patients with CEAP C2 can be observed as voluminous pink spots in the depth color coded image (~ 1 mm depth) (Fig. 2c). However, the affected vessels are located too deep to achieve a sharp image using OCTA. In CEAP C4b, including patients with lipodermatosclerosis, a pattern of disrupted small vessels with superficial dotted vasculature can be observed (Fig. 2d). Corona phlebectatica, corresponding to CEAP C4c, appears as highly tortuous, thick vessels (Fig. 2e). In CEAP C6, corresponding to a venous leg ulcer, OCTA *en face* images of periulcerous skin show a pattern of dotted vessels aligned almost perpendicularly to the skin surface (Fig. 2f).

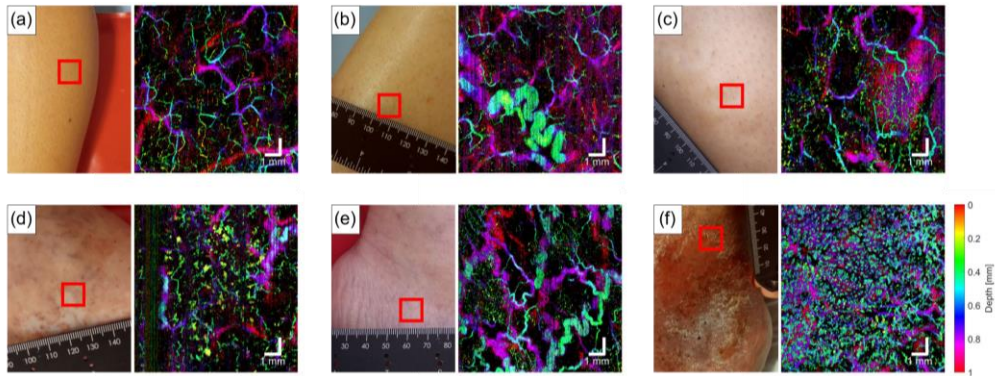


Figure 2. Imaging location and the corresponding OCTA depth color coded maximum intensity projection (MIP) of a healthy subject (a), a patient with CEAP stage C1 (b), a patient with CEAP stage C2 (c), a patient with CEAP stage C4b (d), a patient with CEAP stage C4c (e), a patient with CEAP stage C6 (f).

4. NEW OR BREAKTHROUGH WORK TO BE PRESENTED

To the best of the authors' knowledge, this work is the first demonstration of OCTA in CVI and VLU staging. The results not only pave the way for a brand-new clinical translational possibility for the non-invasive imaging method of OCTA, but more importantly, can provide an easy-to-use, accurate tool to assess changes in the cutaneous microvasculature.

ACKNOWLEDGMENTS

This research is partially funded by the Photonics Public Private Partnership (PPP): H2020-ICT-2020-2 with Grant Agreement ID 101016964 (REAP).

M. Liu is funded by the H2020-MSCA-IF-2019 project SkinOptima with Grant Agreement ID 894325.

REFERENCES

- [1] Rabe, E., et al., *Bonn Vein Study by the German Society of Phlebology: Epidemiological study to investigate the prevalence and severity of chronic venous disorders in the urban and rural residential populations*. Phlebologie, 2003. **32**: p. 1-14.
- [2] Nicolaides, A.N. and N. Labropoulos, *Burden and Suffering in Chronic Venous Disease*. Adv Ther, 2019. **36**(Suppl 1): p. 1-4.
- [3] Rabe, F., Pannier-Fischer, F., Broman, K., et al., *Bonner Venenstudie der Deutschen Gesellschaft für Phlebologie: Epidemiologische Untersuchung zur Frage der Häufigkeit und Ausprägung von chronischen Venenkrankheiten in der städtischen und ländlichen Wohnbevölkerung*. Phlebologie, 2003. **32**(1-14).
- [4] Santler, B. and T. Goerge, *Chronic venous insufficiency - a review of pathophysiology, diagnosis, and treatment*. J Dtsch Dermatol Ges, 2017. **15**(5): p. 538-556.
- [5] Lurie, F., et al., *The 2020 update of the CEAP classification system and reporting standards*, in *Journal of Vascular Surgery: Venous and Lymphatic Disorders*. 2020. p. 342-352.
- [6] Gloviczki, P., et al., *The care of patients with varicose veins and associated chronic venous diseases: clinical practice guidelines of the Society for Vascular Surgery and the American Venous Forum*. J Vasc Surg, 2011. **53**(5 Suppl): p. 2s-48s.
- [7] Meiburger, Kristen M., et al., *Automatic segmentation and classification methods using optical coherence tomography angiography (OCTA): a review and handbook*. Applied Sciences, 11.20 (2021): 9734.