

The Cheatham-Platinum 10-zig: First stent dedicated for adult congenital interventions?

*Original*

The Cheatham-Platinum 10-zig: First stent dedicated for adult congenital interventions? / Fraise, Alain; Bautista-Rodriguez, Carles; Piccinelli, Enrico; Kempny, Aleksander. - In: INTERNATIONAL JOURNAL OF CARDIOLOGY CONGENITAL HEART DISEASE. - ISSN 2666-6685. - ELETTRONICO. - 5:(2021), p. 100125.  
[10.1016/j.ijcchd.2021.100125]

*Availability:*

This version is available at: 11583/2970595 since: 2022-08-10T19:59:05Z

*Publisher:*

Elsevier

*Published*

DOI:10.1016/j.ijcchd.2021.100125

*Terms of use:*

This article is made available under terms and conditions as specified in the corresponding bibliographic description in the repository


*Publisher copyright*

(Article begins on next page)

Contents lists available at [ScienceDirect](https://www.sciencedirect.com)

# International Journal of Cardiology Congenital Heart Disease

journal homepage: [www.journals.elsevier.com/international-journal-of-cardiology-congenital-heart-disease](http://www.journals.elsevier.com/international-journal-of-cardiology-congenital-heart-disease)



## The Cheatham-Platinum 10-zig: First stent dedicated for adult congenital interventions?

### ARTICLE INFO

#### Keywords

Catheter interventions  
Stent  
Off label procedures

In this issue of the Journal, Bates et al. report their experience with the Cheatham-Platinum 10-zig stent (NuMED, Hopkinton, NY, USA.) for transcatheter treatment of congenital heart diseases (CHD), including 8 patients with right ventricular outflow tract (RVOT) interventions and 9 patients with aortic coarctation (CoA) repair. All CoA patients and the majority of RVOT patients were adults, with a median age of 27 years. All procedures were successful. The authors concluded that the 10-zig Cheatham-Platinum (CP) stent can be used successfully and safely in CHD.

To date, the CP stent is the only stent that has specifically been created for CHD interventions. The first CP model, with 8-zig, was released in the late 90'. It received the CE mark in January 2004, for CoA, whereas the United States Food and Drug Administration (FDA) only approved it in March 2016 for CoA stenting, and in October 2017 for RVOT interventions. The 10-zig pattern stent (CP10) received FDA approval in October 2017, whereas further CE approval happened only in January 2019, for both CP8 and CP10. This was 4 years after the CP10 was first used in Bates' study. This complex and time-consuming pathway illustrates the administrative hurdles and the challenges congenital interventionists face when choosing equipment. In the USA, it took around 20 years to get the CP stent approved by the FDA, preventing most of the centres and interventionists to use it. For many years, the covered version of the CP8 was the only balloon-expandable stent available to treat life-threatening complications, like acute aortic dissection or conduit rupture following balloon dilation or bare stent implantation [2]. Moreover, apart from CoA and RVOT lesions, a broad spectrum of stenoses or defects in CHD interventions can be treated with the CP stent, whilst the stent is not approved for this, despite numerous published papers: branch pulmonary stenoses [3], vena

cavae stenoses [3], Fontan anastomoses stenoses [3], Fontan fenestration closure [4], Mustard obstructions and leaks [5] and sinus venosus defects closure [6].

With limited shortening and being expandable up to 30mm in diameter, the advantage of the CP10 over the CP8 is considerable for adult CHD interventions (Fig. 1). When used for RVOT pre-stenting, it will potentially expand the indication for percutaneous pulmonary valve implantation, especially in very large outflow tracts. Another interesting example is the percutaneous repair of superior sinus venosus atrial septal defect (SVASD). Nowadays, most SVASDs are indeed repaired using the covered CP10. However, this stent is still not CE marked or FDA approved for this procedure. Moreover, some countries, like the United Kingdom, have restricted the use of the longer (7 and 8 cm) version of the covered CP10, which is often more suitable for the repair of these defects. Having only the 6cm long covered CP10 for SVASD repair increases the complexity of the procedure, with sometimes the need to implant another bare stent in the upper part of the superior vena cava, to improve the stability of the covered CP10 (Figs. 2 and 3).

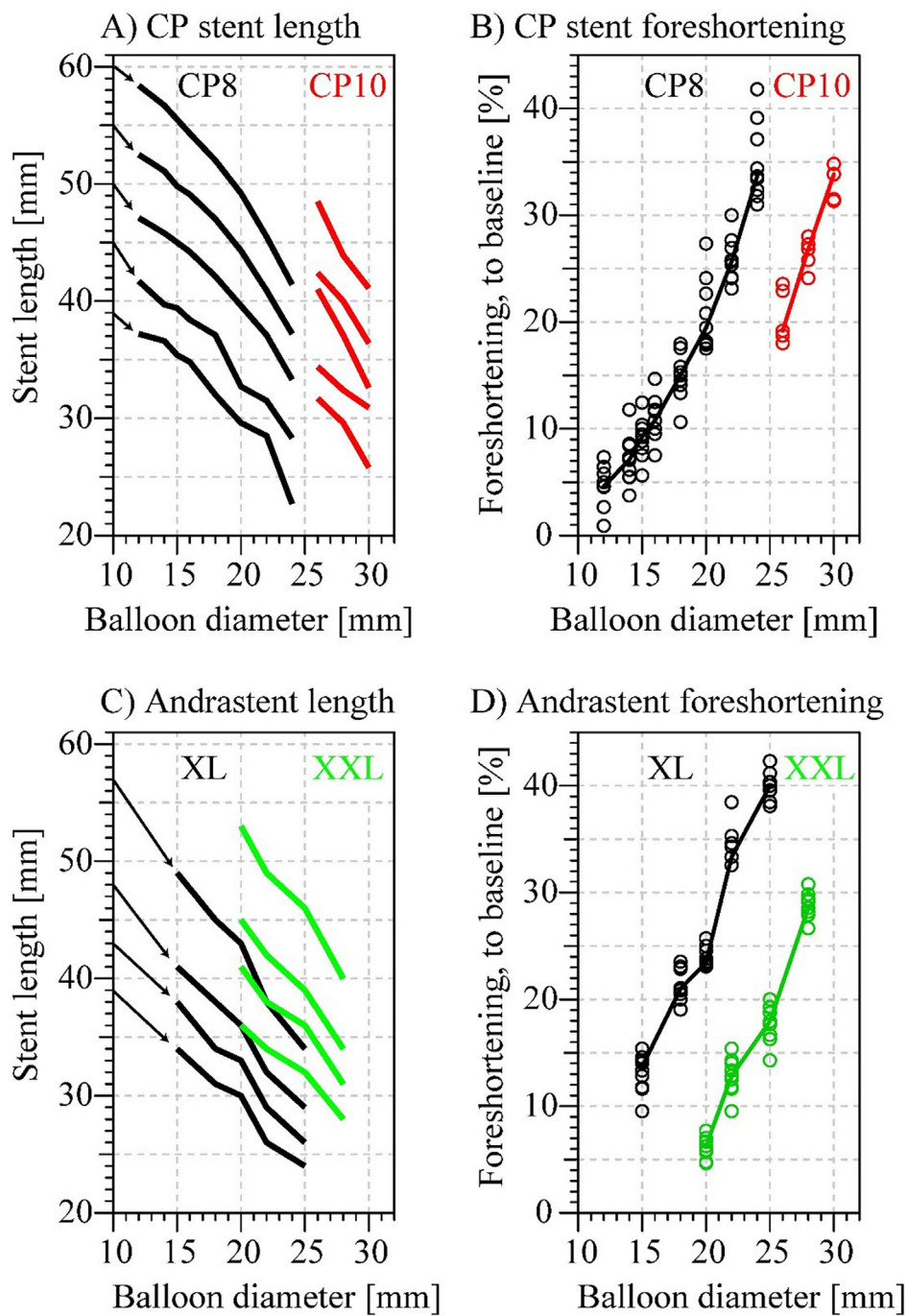
Bates and colleagues should be congratulated for their successful and pioneering experience with the CP10 stent, although it should be acknowledged that most of the procedures reported in the study could have also been achieved with the CE approved CP8. However, reporting such highly successful use of off-label equipment should help adult CHD interventionists to use the CP10 in the future. Ideally, the CP10 should rather be used for procedures where high radial force is crucial or stent foreshortening is undesirable, such as SVASD percutaneous closure.

DOI of original article: <https://doi.org/10.1016/j.ijcchd.2021.100089>.

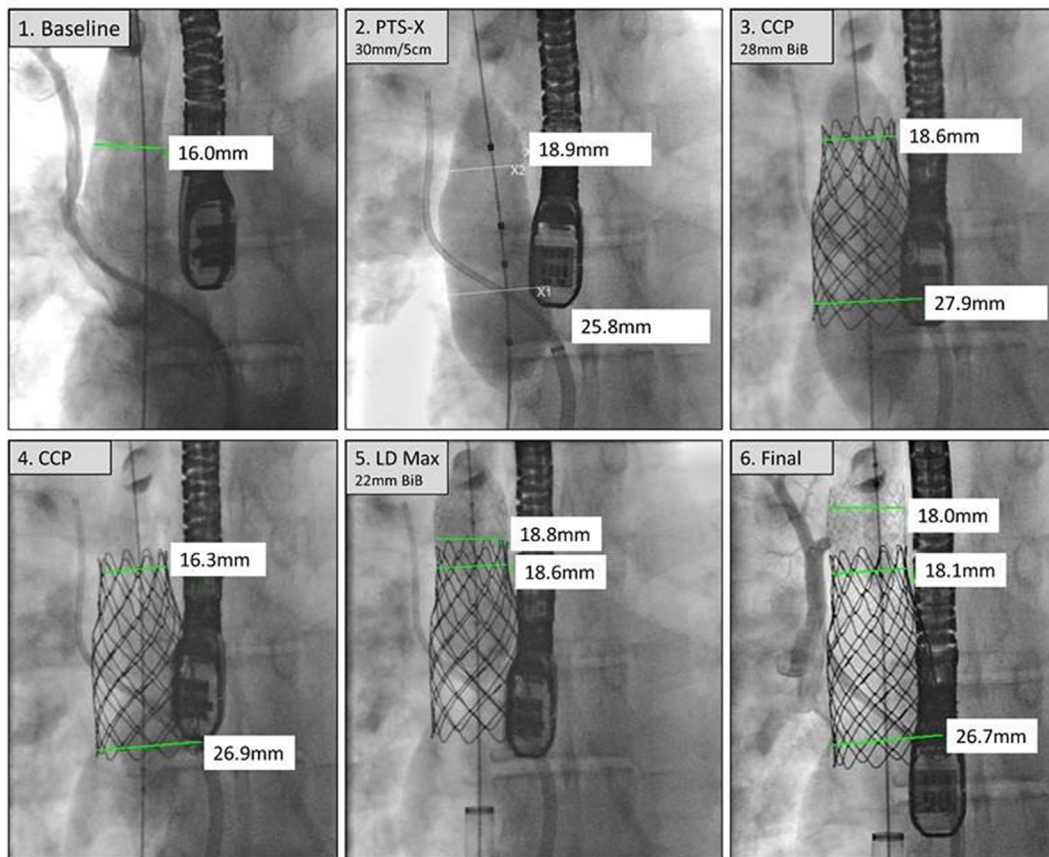
<https://doi.org/10.1016/j.ijcchd.2021.100125>

Received 22 March 2021; Accepted 25 March 2021

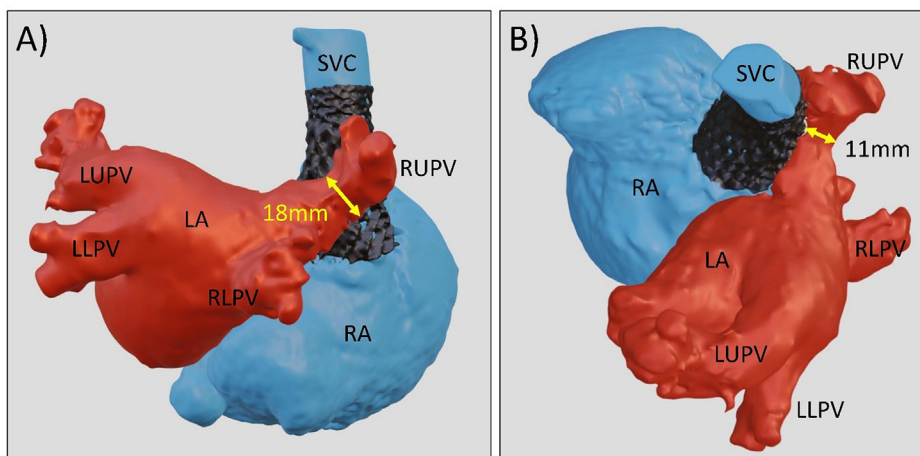
2666-6685/© 2021 The Authors. Published by Elsevier B.V. This is an open access article under the CC BY-NC-ND license (<http://creativecommons.org/licenses/by-nc-nd/4.0/>).



**Fig. 1.** CP stent and Andrastent characteristics: CP stent in 8-zig (CP8) and 10-zig (CP10) version with their diameter vs. length characteristics (A) and foreshortening percentage compared to baseline length (B). Numeric data obtained from vendor website. For A, arrows indicate the baseline stent length, with CP8 and CP10 in 60, 55, 50, 45 and 39mm. The CP10 expands the range of CP stents and offers relatively similar foreshortening characteristics.



**Fig. 2.** Percutaneous repair of superior sinus venosus atrial septal defect using a 6cm covered, 10-zig CP stent: Example of percutaneous repair of superior sinus venosus atrial septal defect, using a 6cm 10zig covered CP stent (CP10), with angiography of superior vena cava and right upper pulmonary vein [1], balloon sizing [2], CP10 implantation [3]. Whilst the CP10 remained in stable position [4], its position had to be secured using another 36/12 LD Max (Medtronic, Dublin, Ireland) bare stent [5], enabling stable anchoring in the superior vena cava [6].



**Fig. 3.** 3D reconstruction after percutaneous repair of superior sinus venosus atrial septal defect: Posterior (A) and modified superior (B) view of a 3D reconstruction based on computed tomography, in a patient after percutaneous repair of superior sinus venosus atrial septal defect, using a covered, 6cm, 10zig CP stent (CP10) and a further, LD Max bare stent, implanted in the superior vena cava (SVC), in order to stabilize the CP10. Pulmonary veins, including the right upper (RUPV), right lower (RLPV), left upper (LUPV) and left lower (LLPV) are draining to the left atrium (LA), with a minimal diameter of the RUPV-LA tunnel behind the stent (arrows) at 11 × 18mm. The CP10 extends low enough to the right atrium (RA), to fully cover the atrial septal defect.

**Declaration of competing interest**

Alain fraisse is consultant and proctor for Abbott, Occlutech and Medtronic.

**References**

[1] Bates O, Jones MI, Qureshi SA, Rosenthal E, Butera G. Cheatham-Platinum 10-zig stents for transcatheter treatment of congenital heart diseases: a new tool to widen the spectrum of treatable conditions. *Int J Cardiol-CHD* 2021.

[2] Delaney JW, Goldstein BH, Bishnoi RN, Bisselou KSM, McEnaney K, Minahan M, Ringel RE. Covered CP stent for treatment of right ventricular conduit injury during melody transcatheter pulmonary valve replacement. *Circ Cardiovasc Interv* 2018;11: e006598.

[3] Ewert P, Schubert S, Peters B, Abdul-Khaliq H, Nagdyman N, Lange PE. The CP stent—short, long, covered—for the treatment of aortic coarctation, stenosis of pulmonary arteries and caval veins, and Fontan anastomosis in children and adults: an evaluation of 60 stents in 53 patients. *Heart* 2005 Jul;91(7):948–53.

[4] Marini I D, Boudjemline Y, Agnoletti G. Closure of extracardiac Fontan fenestration by using the covered Cheatham Platinum stent. *Cathet Cardiovasc Interv* 2007 Jun 1; 69(7):1002–6.

- [5] Dragulescu A, Sidibe N, Aubert F, Fraisse A. Successful use of covered stent to treat superior systemic baffle obstruction and leak after atrial switch procedure. *Pediatr Cardiol* 2008;29(5):954–6.
- [6] Hansen JH, Duong P, Jivanji SGM, Jones M, Kabir S, Butera G, Qureshi SA, Rosenthal E. Transcatheter correction of superior sinus venosus atrial septal defects as an alternative to surgical treatment. *J Am Coll Cardiol* 2020;75:1266–78.

Alain Fraisse<sup>\*</sup>, Carles Bautista-Rodriguez, Enrico Piccinelli  
*Paediatric Cardiology Services, Royal Brompton Hospital and Harefield NHS  
Foundation Trust, United Kingdom  
National Heart and Lung Institute, Imperial College London, United Kingdom*

Aleksander Kempny  
*Paediatric Cardiology Services, Royal Brompton Hospital and Harefield NHS  
Foundation Trust, United Kingdom  
Adult Congenital Heart Disease Unit, Royal Brompton Hospital and Harefield  
NHS Foundation Trust, United Kingdom*

<sup>\*</sup> Corresponding author. Cardiology Services, Royal Brompton Hospital  
and Harefield NHS Foundation Trust, Sydney Street, SW3 6NP, London,  
United Kingdom.

*E-mail address:* [a.fraisse@rbht.nhs.uk](mailto:a.fraisse@rbht.nhs.uk) (A. Fraisse).