

3D mixed reality holograms for preoperative surgical planning of nephron-sparing surgery: evaluation of surgeons' perception

*Original*

3D mixed reality holograms for preoperative surgical planning of nephron-sparing surgery: evaluation of surgeons' perception / Checcucci, Enrico; Amparore, Daniele; Pecoraro, Angela; Peretti, Dario; Aimar, Roberta; De Cillis, Sabrina; Piramide, Federico; Volpi, Gabriele; Piazzolla, Pietro; Manfrin, Diego; Manfredi, Matteo; Fiori, Cristin; Porpiglia, Francesco. - In: MINERVA UROLOGICA E NEFROLOGICA. - ISSN 1827-1758. - 73:3(2021), pp. 367-375. [10.23736/S2724-6051.19.03610-5]

*Availability:*

This version is available at: 11583/2755492 since: 2019-09-26T14:55:45Z

*Publisher:*

Edizioni Minerva Medica

*Published*

DOI:10.23736/S2724-6051.19.03610-5

*Terms of use:*

This article is made available under terms and conditions as specified in the corresponding bibliographic description in the repository

*Publisher copyright*

(Article begins on next page)

## ORIGINAL ARTICLE

# 3D mixed reality holograms for preoperative surgical planning of nephron-sparing surgery: evaluation of surgeons' perception

Enrico CHECCUCCI <sup>1</sup> \*, Daniele AMPARORE <sup>1</sup>, Angela PECORARO <sup>1</sup>,  
Dario PERETTI <sup>1</sup>, Roberta AIMAR <sup>1</sup>, Sabrina DE CILLIS <sup>1</sup>, Federico PIRAMIDE <sup>1</sup>,  
Gabriele VOLPI <sup>1</sup>, Pietro PIAZZOLLA <sup>2</sup>, Diego MANFRIN <sup>1</sup>, Matteo MANFREDI <sup>1</sup>,  
Cristian FIORI <sup>1</sup>, Francesco PORPIGLIA <sup>1</sup>

<sup>1</sup>Division of Urology, Department of Oncology, School of Medicine, San Luigi Gonzaga Hospital, University of Turin, Orbassano, Turin, Italy; <sup>2</sup>Department of Management and Production Engineer, Polytechnic University of Turin, Turin, Italy

\*Corresponding author: Enrico Checcucci, Division of Urology, Department of Oncology, School of Medicine, San Luigi Gonzaga Hospital, University of Turin, Orbassano, Turin, Italy. E-mail: [checcu.e@hotmail.it](mailto:checcu.e@hotmail.it)

## ABSTRACT

**BACKGROUND:** 3D reconstructions are gaining a wide diffusion in nephron-sparing surgery (NSS) planning. They have usually been studied on common 2D flat supports, with limitations regarding real depth comprehension and interaction. Nowadays, it is possible to visualize kidney 3D reconstructions as holograms in a “mixed reality” (MR) setting. The aim of this study was to test the face and content validity of this technology, and to assess the role of 3D holograms in aiding preoperative planning for highly complex renal tumors amenable by NSS.

**METHODS:** We evaluated surgeons' perception of mixed reality for partial nephrectomy during a urological international meeting organized at our Institution in January 2019. Thanks to the images of preoperative CT, hyper-accuracy 3D (HA3D™) reconstructions were performed. Then, a virtual environment was created, and it interacted with the models in mixed reality setting by using HoloLens. We submitted to all the attendees a questionnaire, expressed by the Likert scale (1-10), about their opinion over the use and application of the MR. Moreover, the attendees had the chance to perform a first-hand MR experience; then, they were asked to choose their clamping and resection approach.

**RESULTS:** Overall 172 questionnaires were collected. The scores obtained regarding both surgical planning (scored 8/10) and anatomical accuracy (9/10) were very positive. High satisfaction toward the potential role of this technology in surgical planning and understanding of surgical complexity (both scored 9/10) were expressed. After a first-hand experience with HoloLens and MR, 64.4% and 44.4% of the surgeons changed their clamping and resection approach, respectively – compared to CT image visualization only – choosing a more selective one.

**CONCLUSIONS:** Our study suggests that surgeons perceive holograms and MR as a useful and interesting tool for the preoperative setting before partial nephrectomy, in the direction of an ever more precise surgery.

(Cite this article as: Checcucci E, Amparore D, Pecoraro A, Peretti D, Aimar R, De Cillis S, *et al.* 3D mixed reality holograms for preoperative surgical planning of nephron-sparing surgery: evaluation of surgeons' perception. *Minerva Urol Nephrol* 2021;73:367-75. DOI: 10.23736/S2724-6051.19.03610-5)

**KEY WORDS:** Augmented reality; Kidney neoplasms; Nephrectomy; Robotics.

Three-dimensional reconstructions are rapidly gaining a wide diffusion and are becoming part of the standard preoperative assessment of patients with renal masses.<sup>1</sup> When it comes to partial nephrectomy, a deep and detailed understanding of the surgical anatomy of every single

case is the key point for a successful intervention.<sup>2</sup> To date, 3D reconstructions have usually been studied on common 2D flat supports, with evident limitations regarding the real depth comprehension and interaction. This kind of model still leaves much of the understanding of the

most complex renal masses to everyone's spatial awareness, with the risk of complicating communication between experts.

Nowadays, it is possible to visualize kidney 3D reconstructions as holograms, overcoming the above-mentioned limitations. These holograms are especially useful in the "mixed reality" (MR) setting; virtual elements are superimposed on the real surgical field and can interact with physical elements. This is possible by 3D-anchoring the virtual elements within the real-world environment. The MR concept was made commercially available in 2016 by Microsoft HoloLens. This technology permits true 3D-depth reconstructions, overlapped on real anatomy, with the potential benefits of high mobility, angle independency, gesture control, and easy sharing of holograms.

In this article, we describe our experience with 3D holograms in order to facilitate and improve the results of partial nephrectomies, testing the face and content validity of this technology, and assessing their role in supporting the surgical planning for the most challenging renal lesions amenable by nephron sparing surgery.

## Materials and methods

### Study population

In the present study, all the participants of the 9<sup>th</sup> Techno-Urology Meeting that took place in San Luigi Gonzaga Hospital, Orbassano, Turin, Italy, in January 2019<sup>3</sup> (both surgeons and attendees) had the possibility of experiencing mixed reality.

Preoperatively, the surgeons visualized their clinical case, with 2D CT images and the 3D holograms, of cases scheduled for robot-assisted partial nephrectomy (RAPN) in the operative room; moreover, the same information, and virtual images as well, were projected in the auditorium and all the attendees could visualize the same images as the surgeons. A purpose-built Face and Content Validity questionnaire was distributed.

In parallel, a "mixed reality room" was set up close to the auditorium, and the attendees could experience MR firsthand. Again, a purpose-built Mixed Reality Room Experience questionnaire was distributed.

### 3D virtual rendering and hologram development

As we previously described, the Hyper Accuracy 3D virtual models (HA3D™) of the kidneys, arteries, veins, calyceal systems, and tumors of the patients scheduled for live surgery RAPNs were realized based on the preoperative CT images,<sup>1</sup> thanks to a collaboration between urologists and bioengineers by using dedicated software by M3DICS<sup>4</sup> (Figure 1). The final output was in .stl format.

Then, the files were converted into .fbx files by using the open-source SW Blender; subsequently, they were imported into Unity by weAR;<sup>5</sup> the whole team created the virtual environment, and defined the UX (User Experience) and how to interact with the models in mixed reality. The final app was built and deployed to Microsoft HoloLens Devices.

Specifically, for this preliminary study, we decided to simplify the user experience as much as possible, because the users were inexperienced. In fact, we decided to fix the position of the 3D model in space, and to change perspective by having participants walk around it, instead of making it possible to move the entire reconstruction. The only part which could move was the tumor, in order to allow the surgeon to visualize the resection bed.

Moreover, we decided to limit gestures only

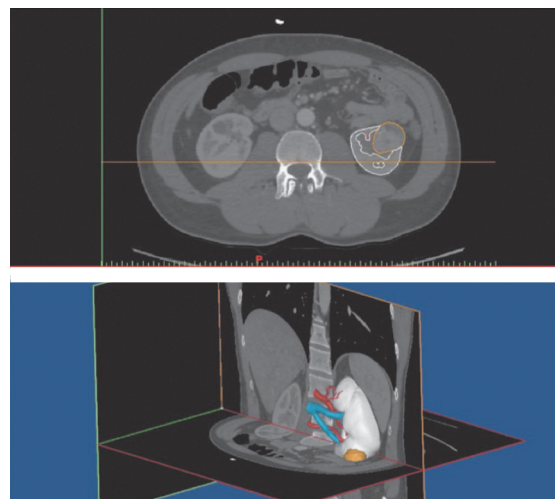


Figure 1.—CT segmentation and 3D rendering to realize HA3D™ reconstruction.




Figure 2.—The surgeon wore the Holo-Lens in the operative room in order to explain the surgical planning of his partial nephrectomy to the auditorium. The attendees could watch the same images that the surgeon visualized on his head-mount display.

to “Air Tap,” and the interactive objects were defined this way: 1) kidney parenchyma: switch from solid to invisible; and 2) tumor: removable by clicking and moving a hand in the space.

Since it was difficult to reposition the tumor after removal, we added a red “reset” button to reset both the scene to starting position and the state of the models by “air tapping” on it.

#### Face and Content Validity questionnaire

Before performing the live surgical procedure, surgeons were invited to wear the HoloLens and were able to visualize the 3D virtual models in the MR setting. The 3D reconstructions were simultaneously broadcasted in the auditorium where the other attendees were able to actively discuss the preoperative planning of the procedure, through real-time audio connection (Figure 2).

In order to evaluate the usefulness of MR, a Face and Content Validity questionnaire (F&C) was submitted to the attendees. It was made of open-ended questions of ordinal ten-point rating Likert scales (where 1 was “strongly no” and 10 was “definitely yes”). It was composed of four different fields, focused on overall usefulness, anatomical accuracy, surgical planning and organ-specific questions.

The questionnaire was created according to the face and content validity concepts.<sup>6</sup> Subjective questions for face validity (Q1, Q3 b, c and QS) or objective questions (Q1 a; Q2 a, b and Q3

a) for content validity) were included. Content validity was tested using the content validity ratio (CVR).<sup>7</sup>

#### Mixed Reality Room questionnaire

Specifically, for this MR experience, a 3D hologram of a patient who already underwent RAPN at our institution was realized (Figure 3). All the attendees who wanted to experience the MR were invited to view the CT images of the patient. They then wore the HoloLens (Figure 4).

In our purpose-built questionnaire, first, the participants were asked to express their surgical experience (“resident,” “young urologist,” or “experienced urologist” – the latter for those

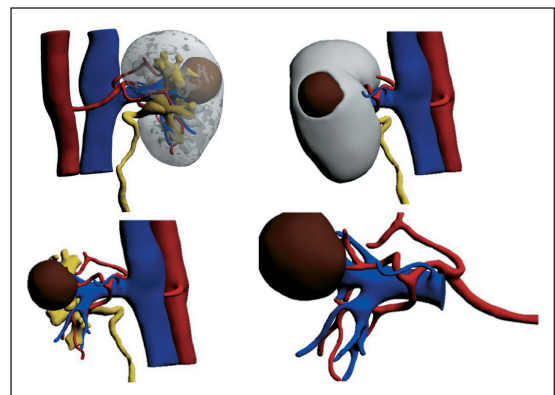


Figure 3.—HA3D™ reconstruction of the virtual model visualized by the attendees during “mixed reality room” experience.



Figure 4.—In the “mixed-reality room” the attendees had the possibility to live a firsthand experience with MR.

with >10 years of robotic surgery practice). Second, they were asked what kind of clamping (global, selective, superselective) and what kind of resection (enucleation, close margin enucleoresection, standard enucleoresection) they would have considered after watching the video of the CT scans.

Then, after watching the hologram, they were asked again which procedure they would recommend in other words, either to confirm their previous choice based on CT scans, or to switch to a different one. Finally, they were asked to

evaluate the usefulness of this new technology, the anatomical details of the models, and the usefulness of holograms in surgical planning. An extract of both questionnaires is reported in Supplementary Digital Material 1: Supplementary Figure 1, Supplementary Figure 2.

**Statistical analysis**

Regarding continuous variables, data were expressed as means and standard deviations (SDs). For categorical variables, as frequencies and proportions or medians and interquartile ranges (IQRs).

The answers given by the responders were analyzed by using sign tests. Univariate regression analysis was performed to test the impact of the surgeon’s experience in changing opinions. Statistical significance was set at P<0.050. The statistical analysis was carried out using Statistic 8.0 Software (StatSoft, Tulsa, OK).

**Results**

Six patients underwent RAPN during the 9<sup>th</sup> Techno-Urology Meeting. For each patient, a

TABLE I.—*Perioperative variables, complications and pathological data.*

Case number	Operative time (min)	Renal artery clamping	WIT (min)	UCS violation	Renorrhaphy
1	144	Yes	No	No	Double layer
2	128	No	Ultraselctive (19)	No	Double layer
3	109	Yes	Selective (19)	No	Double layer
4	131	No	No	Yes	Single layer
5	153	Yes	No	No	Double layer
6	221	Yes	Selective (22)	Yes	Double layer
7 (mixed reality room case)	84	Yes	Selective (14)	No	Single layer

WIT: Warm ischemia time; UCS: urinary collecting system; EBL: estimated blood losses; ISUP: International Society of Urological Pathology.

TABLE II.—*Preoperative data focused on tumors’ characteristics.*

Case number	Solitary kidney	Side	Face	Lesion size (mm)	Cystic features	cT stage	Polar score
1	No	Right	Anterior	60	No	cT1b	Upper/lower pole
2	No	Left	Posterior	46	No	cT1b	Mediorenal
3	No	Left	Anterior	65	No	cT1b	Upper/lower pole
4	No	Right	Posterior	85	No	cT2	Upper/lower pole
5	No	Right	Anterior	35	No	cT1a	Mediorenal
6	No	Right	Posterior	52	No	cT1b	Mediorenal
7 (mixed reality room case)	No	Right	Anterior	37	No	cT1a	Mediorenal

UCS: Urinary collecting system.

This document is protected by international copyright laws. No additional reproduction is authorized. It is permitted for personal use to download and save only one file and print only one copy of this Article. It is not permitted to make additional copies (either sporadically or systematically, either printed or electronic) of the Article for any purpose. It is not permitted to distribute the electronic copy of the article through online internet and/or intranet file sharing systems, electronic mailing or any other means which may allow access to the Article. The use of all or any part of the Article for any Commercial Use is not permitted. The production of derivative works from the Article is not permitted. It is not permitted to remove, cover, overlay, obscure, block, or change any copyright notices or terms of use which the Publisher may post on the Article. It is not permitted to frame or use framing techniques to enclose any trademark, logo, or other proprietary information of the Publisher.

case specific hologram was realized and studied by the surgeon preoperatively.

The baseline tumor characteristics (tumor size and complexity as assessed by PADUA score),<sup>8</sup> intraoperative data (operative time, ischemia time, blood losses, and complications), postoperative complications, and final pathology of the clinical cases used for this study, are reported in Table I, II.

**Face and content validity**

Overall, 172 questionnaires were collected. Regarding the answers provided by the attendees, the overall median usefulness of holograms (question Q1a) was 8/10 (IQR 8–10). Their role in addition to bidimensional imaging (question Q1b) was scored at 9/10 (IQR 8-10). The role of this tool in preoperative patient counselling (question Q1c) was rated 9/10 (IQR 8-10). 3D virtual models were rated 9/10 (IQR 8-10) (question Q2a and Q2b) on the accuracy in reproducing anatomical details.

The role in the preoperative planning (question Q3a) was rated 9/10 (IQR 8-10). The usefulness in the assessing of surgical complexity

(question Q3b) was rated 9/10 (IQR 8-9). The potential benefit to oncological efficacy and functional outcomes after surgery (question Q3c) was rated 9/10 (IQR 7-9).

Concerning the specific question section, the holograms' usefulness in the planning of the clamping and the tumor resection was rated 9/10 (IQR 8-9) and 9/10 (IQR 8-9), respectively (Q.S.a and Q.S.b). The overall results are presented in Figure 5.

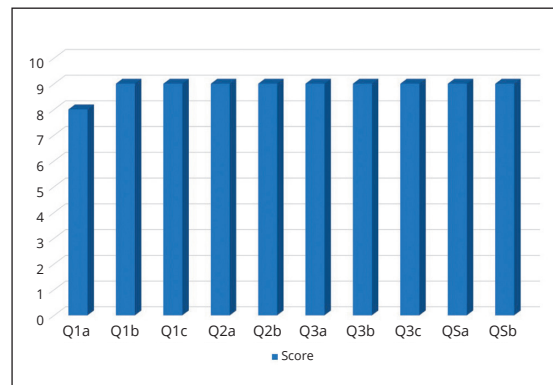


Figure 5.—Overall results of Face and Content Validity Questionnaire.

Intraoperative complications	Postoperative complications (Clavien)	% delta eGFR	Size at pathology (mm)	Histology	ISUP grade	Marginal status	pT stage
No	No	-3.7	60	cc-RCC	1	Negative	pT1b
No	No	+2.1	70	AML	-	-	-
No	No	+8.4	55	Chromophobe	-	Negative	pT3a
No	Yes	-29.7	105	Papillary	2	-	pT2b
No	No	+23.3	35	cc-RCC	1	Negative	pT1a
No	No	-19.7	65	cc-RCC	2	Negative	pT1b
No	No	+3.8	32	cc-RCC	2	Negative	pT1a

Rim location	Renal sinus	UCS	Exophyticness	Clinical size category	PADUA score
Medial	Not involved	Not involved	<50% exophytic	4-7 cm	8
Lateral	Not involved	Not involved	>50% exophytic	4-7 cm	8
Lateral	Not involved	Not involved	<50% exophytic	4-7 cm	8
Medial	Involved	Involved	>50% exophytic	>7 cm	11
Lateral	Not involved	Not involved	>50% exophytic	<4 cm	7
Lateral	Involved	Involved	<50% exophytic	4-7 cm	11
Lateral	Involved	Not involved	<50% exophytic	<4 cm	9

This document is protected by international copyright laws. No additional reproduction is authorized. It is permitted for personal use to download and save only one file and print only one copy of this Article. It is not permitted to make additional copies (either sporadically or systematically, either printed or electronic) of the Article for any purpose. It is not permitted to distribute the electronic copy of the article through online internet and/or intranet file sharing systems, electronic mailing or any other means which may allow access to the Article. The use of all or any part of the Article for any Commercial Use is not permitted. The production of derivative works from the Article is not permitted. It is not permitted to remove, cover, overlay, obscure, block, or change any copyright notices or terms of use which the Publisher may post on the Article. It is not permitted to frame or use framing techniques to enclose any trademark, logo, or other proprietary information of the Publisher.

**Mixed Reality Room questionnaire**

Overall, 90 participants agreed to experience MR and filled out the dedicated questionnaire. Among them, 40 were expert urologists, 20 young urologists, and 30 urology residents. With regards to the choice of clamping, after the visualization of 3D holograms, 58 (64.4%) participants changed their minds; in all these cases, a more selective clamping was chosen (from global to selective or to super-selective clamping).

Concerning the resection technique, 40 (44.4%) participants changed their minds, choosing a more conservative resection approach again (from enucleoresection to enucleation).

After stratifying by expertise, the number of modified indications regarding the type of clamping and the type of resection remained significant in the subgroups, with the expert urologists, the urologists, and the residents in urology, changing their opinions in 20, 24, and 14 cases, respectively (P<0.001, Table III).

Moreover, after stratifying by expertise, the number of modified indications in favor of a more conservative approach remained significant in the subgroups, with the expert urologists, the urologists, and the residents in urology, changing their opinions in 34, 8, and 26 cases, respectively (P<0.001, Table IV).

Univariable regression analysis did not find the responder's experience as significantly having an impact on changing the surgical indication for the displayed cases (P>0.05).

Concerning the personal MX experience evaluation (face validity) the participants scored 9 (IQR 8-10) for the usefulness of this technology, the reproduction of the anatomical details of the holograms, and the usefulness in surgical planning.

**Discussion**

Multiple new technologies have been used in the last years in order to improve preoperative planning. In this context, in the last decade, 3D printed models have become widespread. Surgeons use these 3D reconstructions for the assessment of complex procedures, in particular in the case of complicated tumors.<sup>9</sup> Moreover, they also improve patients' comprehension of their condition and the correlated surgery.<sup>1, 10</sup>

Especially in the case of nephron sparing surgery for complex renal lesions, in order to improve the postoperative renal function that is related to parenchymal volume preservation,<sup>11-13</sup> many experiments have been proposed using the assistance of 3D virtual images during surgical procedures<sup>14</sup> obtaining augmented reality interventions.

TABLE III.—*Sign test for how many surgeons changed their answers after the 3D experience.*

	N. of surgeons who answered	N. of surgeons who changed answer about type of clamping	N. of surgeons who changed answer about type of resection	P value*
Overall	90	60 (66.6%)	40 (44.4%)	<0.001
Expert urologist	40	20 (22.2%)	16 (17.7%)	
Urologist	20	24 (26.6%)	10 (11.1%)	
Residents	30	14 (15.5%)	14 (15.5%)	

\*P value <0.05 from the sign test can be interpreted the number surgeon changing is greater than 0%.

TABLE IV.—*Sign test for how many surgeons chose a more conservative approach after the 3D experience, considering both types of clamping and of resection (the type of clamping used for more conservative approach was defined as selective or super selective clamping; the type of resection used for a more conservative approach was defined as enucleation or close margin enucleoresection).*

	N. of surgeons who answered	N. of surgeons who chose a nephron-sparing surgery after 3D	N. of surgeons who changed answer for nephron-sparing surgery after 3D	P value*
Overall	90	82 (91.1%)	68 (75.5%)	<0.001
Expert urologist	40	36 (40%)	34 (37.7%)	
Urologist	20	16 (17.7%)	8 (8.8%)	
Residents	30	30 (33.3%)	26 (28.8%)	

\*P value <0.05 from the sign test can be interpreted the number surgeon changing is greater than 0%.

This document is protected by international copyright laws. No additional reproduction is authorized. It is permitted for personal use to download and save only one file and print only one copy of this Article. It is not permitted to make additional copies (either sporadically or systematically, either printed or electronic) of the Article for any purpose. It is not permitted to distribute the electronic copy of the article through online internet and/or intranet file sharing systems, electronic mailing or any other means which may allow access to the Article. The use of all or any part of the Article for any Commercial Use is not permitted. The production of derivative works from the Article is not permitted. It is not permitted to remove, cover, overlay, obscure, block, or change any copyright notices or terms of use which the Publisher may post on the Article. It is not permitted to frame or use framing techniques to enclose any trademark, logo, or other proprietary information of the Publisher.

Our group already demonstrated the importance of 3D models in the preoperative planning: in 90% of the patients who underwent RAPN using 3D virtual models preoperatively, intraoperative management of the renal artery was performed as previously planned, with all the selective clamping being successful.<sup>15</sup> Moreover, a wider use of 3D models in the presurgical setting might allow a larger adoption of nephron-sparing procedures, even in the case of highly complex renal masses,<sup>2, 16</sup> especially with robotics.<sup>17</sup>

However, kidney 3D reconstructions are normally studied on flat (2D) screens, limiting the true depth experience and the possibilities of interaction in 3D space.

Hence, the need remains to develop a new technology able to offer visualization in a 3D environment.

Over the years, the connection between human input and computer input has been clearly defined. The human input is enabled by multiple instruments such as keyboards, computer mice, touch, ink, voice, and even Kinect skeletal tracking. Recent improvements of sensors and processing software are determining an innovation: computer input from environments. The combination of these three elements – computer processing, human input, and environmental input – give life to true mixed reality experiences.

Movements in the real world can be converted in movements in the digital world. Without environmental input, experiences cannot blend between physical and digital realities.

These virtual environments are created with the use of displays inside headsets known as head mounted displays (HMDs). The HoloLens, an HMDs recently introduced manufactured by Microsoft, using modern motion sensors and tracking, allows the exploration of a real environment while watching a hologram, positioned realistically in space.

Thanks to a collaboration between the Case Western University and Microsoft, the first application of mixed reality in the medical field was announced in 2016.<sup>18</sup> Microsoft showed the possibility to visualize 3D reconstructions in the real space and how to modify their position and size with simple gestures. The user is also allowed to physically move around the virtual ob-

jects in order to better assess model's depth: this specific element was presented as a fundamental improvement in the comprehension of human anatomy, especially in urology.<sup>19</sup>

MR in preoperative planning has rapidly gained a wide diffusion and preoperative planning appears to be the principal field of application for this new technology.<sup>20</sup> Very few experiments with the use of holograms during surgery are described to date.<sup>21</sup>

A preliminary experiment was reported with immersive MR during percutaneous nephrolithotomy (PCNL), showing an improving surgeon's understanding of the optimal calix of entry and the stone's location, size, and orientation.<sup>22</sup> Especially for nephron-sparing surgery only one study reported the application of holograms in this setting.

Antonelli *et al.*<sup>23</sup> developed an MR experience thanks to the zSpace® workstation, basically a Windows®-based computer with a stereoscopic screen that can be used to watch objects in augmented reality. In their preliminary experiment, the authors concluded that MR could improve preoperative planning for partial nephrectomy and proved it could be more efficient than standard CT scan.

In the present study, using a previously validated questionnaire format,<sup>1</sup> we assessed the face and content validity of 3D holograms and MR experience for kidney lesions, on the basis of the evaluation by urologists of holograms' capacity to correctly recreate the real-life situation, and their usefulness.

We showed encouraging results on the role of this innovative technology in the current urological practice. Promising results were obtained for both surgical planning (scored 8/10) and anatomical accuracy (9/10). The urologists who filled in the questionnaire expressed a high satisfaction about the potential role of this technology in surgical planning and understanding of surgical complexity (both scored 9/10).

Regarding the face validity items, the scores were impressive ( $\geq 9/10$  for all the questions), but their subjective nature did not allow to draw definitive conclusions on their validation. On the contrary, the results obtained with the content validity items were tested by the content validity

ratio (CVR); the values obtained for each question, ranging between 0.17 and 0.27, in relationship to the population number of the study, were adequate to achieve validation of the model.

A more precise evaluation of the potential usefulness of this technology was assessed with the “mixed reality room” experience. After a firsthand experience with HoloLens and MR, 64.4% of the surgeons changed their clamping approach, choosing a more selective one. In fact, the clamping approach changed from global to selective or superselective clamp.

Even in the subgroup of “expert” urologists (with >10 years of robotic surgical experience), 60% changed their clamping indication. Moreover, 44.4% of the participants changed their choice towards a more conservative resection technique after the hologram's visualization (from nuclearesction to enucleation).

### Limitations of the study

The present study is not devoid of limitations. Firstly, the HA3D™ models were performed by expert urologists and bioengineers manually. Secondly the responders in the “mixed reality room” were unblinded when watching the clinical case; one could argue that they were pushed to change the indication just because of the impressive and attractive 3D reconstruction.

Another issue in using this kind of technology is represented by the costs. No studies have been conducted to determine the cost-effectiveness of this new technology, but we can suppose that its costs will interfere on a wider diffusion in the next years.

Notwithstanding these limitations, this is a pilot study that has explored the potential benefit of emerging holograms and mixed reality technology, showing a potential benefit in surgical planning before partial nephrectomy.

### Conclusions

Our study suggests that holograms and MR are perceived as a useful tool for the purpose of surgical planning before partial nephrectomy in the direction of precision surgery. Further research is mandatory to support these promising results, as present evidence remains limited.

### References

1. Porpiglia F, Bertolo R, Checcucci E, Amparore D, Autorino R, Dasgupta P, *et al.*; ESUT Research Group. Development and validation of 3D printed virtual models for robot-assisted radical prostatectomy and partial nephrectomy: urologists' and patients' perception. *World J Urol* 2018;36:201–7.
2. Bertolo R, Autorino R, Fiori C, Amparore D, Checcucci E, Mottrie A, *et al.* Expanding the Indications of Robotic Partial Nephrectomy for Highly Complex Renal Tumors: Urologists' Perception of the Impact of Hyperaccuracy Three-Dimensional Reconstruction. *J Laparoendosc Adv Surg Tech A* 2019;29:233–9.
3. 9th techno-urology meeting (TUM) the advent of artificial intelligence. TUM; 2019 [Internet]. Available from: <http://www.technourologymeeting.com/> [cited 2019, Feb 7].
4. Medics3D tools for medicine. Medics3D; 2019 [Internet]. Available from: <https://www.medics3d.com/> [cited 2019, Feb 7].
5. Wear: enable the future of augmented reality. Wear Mobile; 2019 [Internet]. Available from: <https://wear-mobile.com/> [cited 2019, Feb 7].
6. Gravetter FJ, Forzano LA. Research methods for the behavioral sciences. Fourth edition. Stamford, CT: Cengage Learning; 2012. p.78.
7. Cite Seer X. CSR; 2019 [Internet]. Available from: <http://citeseerx.ist.psu.edu/viewdoc/download?doi=10.1.1.460.9380&rep=rep1&type=pdf> [cited 2019, Feb 7].
8. Ficarra V, Novara G, Secco S, Macchi V, Porzionato A, De Caro R, *et al.* Preoperative aspects and dimensions used for an anatomical (PADUA) classification of renal tumours in patients who are candidates for nephron-sparing surgery. *Eur Urol* 2009;56:786–93.
9. Komai Y, Sugimoto M, Gotohda N, Matsubara N, Kobayashi T, Sakai Y, *et al.* Patient-specific 3-dimensional printed kidney designed for “4D” surgical navigation: a novel aid to facilitate minimally invasive off-clamp partial nephrectomy in complex tumor cases. *Urology* 2016;91:226–33.
10. Powers MK, Lee BR, Silberstein J. Three-dimensional printing of surgical anatomy. *Curr Opin Urol* 2016;26:283–8.
11. Bertolo R, Fiori C, Piramide F, Amparore D, Barrera M, Sardo D, *et al.* Assessment of the relationship between renal volume and renal function after minimally-invasive partial nephrectomy: the role of computed tomography and nuclear renal scan. *Minerva Urol Nefrol* 2018;70:509–17.
12. Bertolo RG, Zargar H, Autorino R, Fiori C, Kaouk JH, Russo P, *et al.* Estimated glomerular filtration rate, renal scan and volumetric assessment of the kidney before and after partial nephrectomy: a review of the current literature. *Minerva Urol Nefrol* 2017;69:539–47.
13. Beksac AT, Shah QN, Paulucci DJ, Lewis S, Taouli B, Badani KK. A Comparison of Excisional Volume Loss Calculation Methods to Predict Functional Outcome After Partial Nephrectomy. *J Endourol* 2019;33:35–41.
14. Teber D, Guven S, Simpfendorfer T, Baumhauer M, Guven EO, Yencilek F, *et al.* Augmented reality: a new tool to improve surgical accuracy during laparoscopic partial nephrectomy? Preliminary in vitro and in vivo results. *Eur Urol* 2009;56:332–8.
15. Porpiglia F, Fiori C, Checcucci E, Amparore D, Bertolo R. Hyperaccuracy Three-dimensional Reconstruction Is Able to Maximize the Efficacy of Selective Clamping During Robot-assisted Partial Nephrectomy for Complex Renal Masses. *Eur Urol* 2018;74:651–60.
16. Andrade HS, Zargar H, Akca O, Kara O, Caputo PA,

Ramirez D, *et al.* Is Robotic Partial Nephrectomy Safe for T3a Renal Cell Carcinoma? Experience of a High-Volume Center. *J Endourol* 2017;31:153–7.

17. Xia L, Wang X, Xu T, Guzzo TJ. Systematic Review and Meta-Analysis of Comparative Studies Reporting Perioperative Outcomes of Robot-Assisted Partial Nephrectomy Versus Open Partial Nephrectomy. *J Endourol* 2017;31:893–909.

18. CWRU takes the stage at Microsoft's Build conference to show how HoloLens can transform learning. Case Western Reserve University; 2016 [Internet]. Available from: <http://case.edu/hololens/> [cited 2016, Sep 19].

19. Hamacher A. 2017 Annual Meeting of The Korean Urological Association. Korean Urology Association; 2017 [Internet]. Available from: [http://www.urology.or.kr/abstract/2017\\_fall/eng/program/pro\\_plenary\\_3.html](http://www.urology.or.kr/abstract/2017_fall/eng/program/pro_plenary_3.html) [cited 2018, Sep 20].

20. Hamacher A, Kim SJ, Cho ST, Pardeshi S, Lee SH, Eun

SJ, *et al.* Application of Virtual, Augmented, and Mixed Reality to Urology. *Int Neurourol J* 2016;20:172–81. Epub 2016 Sep 23. [Review. Erratum in: *Int Neurourol J* 2016;20:375]

21. Rymuza B, Grodecki K, Kamiński J, Scisło P, Huczek Z. Holographic imaging during transcatheter aortic valve implantation procedure in bicuspid aortic valve stenosis. *Kardiol Pol* 2017;75:1056.

22. Parkhomenko E, O'Leary M, Safiullah S, Walia S, Owyong M, Lin C, *et al.* Pilot Assessment of Immersive Virtual Reality Renal Models as an Educational and Preoperative Planning Tool for Percutaneous Nephrolithotomy. *J Endourol* 2019;33:283–8.

23. Antonelli A, Vecchia A, Palumbo C, Peroni A, Mirabella G, Cozzoli A, *et al.* Holographic Reconstructions for Preoperative Planning before Partial Nephrectomy: A Head-to-Head Comparison with Standard CT Scan. *Urol Int* 2019;102:212–7.

*Conflicts of interest.*—The authors certify that there is no conflict of interest with any financial organization regarding the material discussed in the manuscript.

*Authors' contributions.*—Francesco Porpiglia has given substantial contributions to study concept and design, Roberta Aimar, Sabrina De Cillis, Federico Piramide, Gabriele Volpi and Dario Peretti to data acquisition, Enrico Checcucci, Daniele Amparore, Angela Pecoraro, Pietro Piazzolla and Diego Manfrin to manuscript writing, Cristian Fiori and Matteo Manfredi to critical revision of the manuscript for important intellectual content, Francesco Porpiglia to manuscript supervision. All authors read and approved the final version of the manuscript.

*Acknowledgements.*—The authors acknowledge the professional engineers who collaborated in this study and all the participants at the Techno-Urology Meeting who filled in the questionnaire.

*History.*—Article first published online: September 5, 2019. - Manuscript accepted: September 4, 2019. - Manuscript received: August 20, 2019.

*Supplementary data.*—For supplementary materials, please see the HTML version of this article at [www.minervamedica.it](http://www.minervamedica.it)